

Figure S1

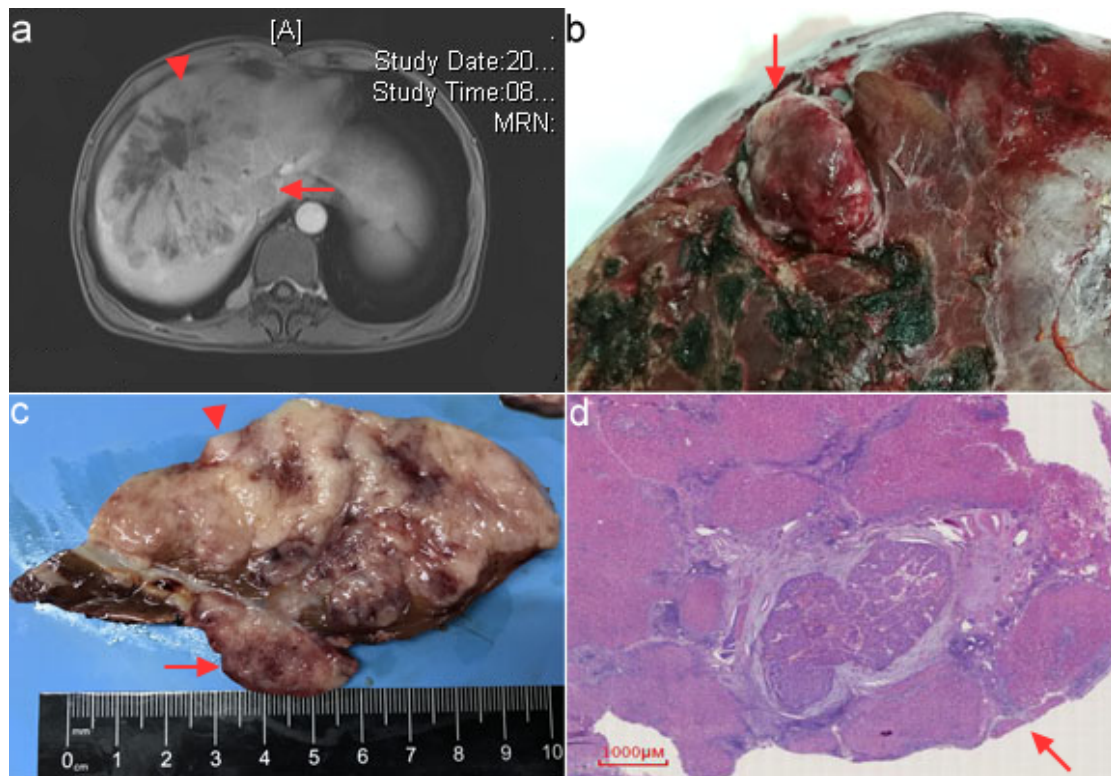


Figure S1

Diagnosis algorithm of HCC patient combined with IVCTT. A Venous phase of magnetic resonance imaging (MRI) displayed huge single lesion (13 cm in diameter, arrowhead) located at right lobe of the liver, with filling-defect shadow (arrow) at IVC area of the same section, B resected sample displayed *en bloc* resection of the tumor and thrombus (arrow), C Gross sectional specimen, D Microscopic pathology of the HCC and IVCTT (magnification 1000 μm).