

Clinical Study

Thinner Corneas Appear to Have More Striking Effects of Corneal Collagen Crosslinking in Patients with Progressive Keratoconus

Yunfei Han,^{1,2} Yanyun Xu,¹ Wei Zhu,³ Yuling Liu,² Zhen Liu,² Xiaoxiao Dou,¹ and Guoying Mu¹

¹Department of Ophthalmology, Shandong Provincial Hospital Affiliated to Shandong University, Jinan 250021, China

²Department of Ophthalmology, The Second People's Hospital of Liaocheng, Linqing 252600, China

³Department of Ophthalmology, Jinan Central Hospital Affiliated to Shandong University, Jinan 250013, China

Correspondence should be addressed to Guoying Mu; mgeyeyes@163.com

Received 24 October 2016; Accepted 16 January 2017; Published 14 March 2017

Academic Editor: Dirk Sandner

Copyright © 2017 Yunfei Han et al. This is an open access article distributed under the Creative Commons Attribution License, which permits unrestricted use, distribution, and reproduction in any medium, provided the original work is properly cited.

Purpose. To analyze the outcomes and difference after UVA/riboflavin corneal collagen crosslinking (CXL) in four different corneal thickness groups of patients with progressive keratoconus. **Methods.** Retrospective study. Eyes with progressive keratoconus after CXL were divided into 4 subgroups as follows: group 1, thinnest corneal thickness (TCT) $\leq 400 \mu\text{m}$; group 2, $400 \mu\text{m} < \text{TCT} \leq 450 \mu\text{m}$; group 3, $450 \mu\text{m} < \text{TCT} \leq 500 \mu\text{m}$; group 4, $\text{TCT} \geq 500 \mu\text{m}$. Baseline, 6-month, and 12-month visual acuity, corneal topography, TCT, and endothelial cell density were evaluated. **Results.** The analysis included 123 eyes of 101 patients. At 6 and 12 months after CXL, there was a mean improvement about visual acuity and keratometry values in all patients. There was a reduction in the change of maximum keratometry (K_{max}) with the increase of TCT. After 1 year of treatment, it was $3.04 \pm 0.75 \text{ D}$ in group 1, $2.38 \pm 0.51 \text{ D}$ in group 2, $1.57 \pm 0.35 \text{ D}$ in group 3, and $0.31 \pm 0.20 \text{ D}$ in group 4. **Conclusion.** CXL is successful in halting the progression of keratoconus and there was a negative linear correlation between TCT and K_{max} . Advanced cases of progressive keratoconus seemed to obtain more benefits from the flattening effects of CXL.

1. Introduction

Keratoconus (KC) is a corneal noninflammatory degeneration characterized by bilateral conical protrusion and corneal thinning. It can vary from slightly irregular astigmatism to severe visual impairment resulting from the increased corneal protrusion and subepithelial scarring [1]. KC leads to biomechanical alterations, but its underlying pathogenesis is not clear. Corneal collagen crosslinking (CXL) is a noninvasive therapeutic approach to improve the biomechanical and biochemical properties of the cornea and is the only treatment to date that addresses the pathophysiology of KC [2]. In the traditional view, CXL is generally performed on the eyes with a corneal thickness of at least $400 \mu\text{m}$ to avoid the cytotoxic effects of the UVA on the corneal endothelium, lens, and other intraocular tissues. In fact, in many patients with advanced stages of KC, corneal thickness usually exceeds that of the standard. Hence, various measures have been

suggested to circumvent, for example, using hypoosmolar riboflavin solution, customized epithelial debridement technique, and contact lens-assisted CXL [3]. In terms of safety and effectiveness, these techniques also achieved good results. We were interested in the potential correlation after CXL in different corneal thickness groups and whether there was an association between pre-CXL corneal thickness and the change of K_{max} (ΔK_{max} defined as the difference in K_{max} between the preoperative and the last registered visit). So, we did this analysis.

2. Patients and Methods

2.1. Patients. A retrospective cohort study was performed at the Department of Ophthalmology, Shandong Provincial Hospital affiliated to Shandong University. All patients were diagnosed as progressive keratoconus. 101 patients (123 eyes) were enrolled in this analysis from March 2014 to September

2015. The patients were divided into 4 subgroups as follows: group 1, keratoconus with thinnest corneal thickness (TCT) less than 400 μm ; group 2, keratoconus with TCT between 400 μm and 450 μm ; group 3, keratoconus with TCT between 450 μm and 500 μm , and group 4, keratoconus with TCT 500 μm or more. The progressive keratoconus was defined as 1 or more of the following changes over a period of 24 months: an increase of 1.00 diopter (D) or more in the steepest keratometry (K) measurement, an increase of 1.00 D or more in manifest cylinder, and an increase of 0.50 D or more in manifest refraction spherical equivalent (MRSE) [4].

Exclusion criteria included a history of corneal surgery, corneal pachymetry less than 340 μm , a history of chemical injury or delayed epithelial healing, and pregnancy or lactation during the course of the study.

2.2. Surgical Technique. The procedure was performed under sterile conditions in the outpatient operation room. After topical anesthesia with proparacaine hydrochloride 0.5% eye drops (Alcaine, Alcon Laboratories Inc), corneal epithelium was mechanically removed within the central 9 mm diameter area using a mechanical microkeratome (Amadeus II, Ziemers, Switzerland). 0.1% solution of riboflavin (Ricola; Sooft Italia S.p.A, Montegiorgio, Italy) was applied to the denuded stroma every 3 minutes for 30 minutes. Saturation of the corneal stroma and the presence of riboflavin in the anterior chamber were monitored using the blue light of the slit lamp. In eyes with a denuded corneal thickness below 400 μm measured with optical coherence tomography (OCT, Cirrus HD-OCT 4000; Carl Zeiss Meditec Inc, Hacienda Drive, Dublin, USA), 0.1% hypoosmolar riboflavin solution, which was generated by diluting vitamin B2-riboflavin-5-phosphate 0.5% (Shandong Fangming Pharmaceutical Limited by Share Ltd., Shandong, China) with physiological salt solution (sodium chloride 0.9% solution; 310 mOsmol/L; Sichuan Kelun Pharmaceutical Limited by Share Ltd., Sichuan, China), was administered every 10 seconds for 2 minutes until 400 μm was achieved. Subsequently, the cornea was irradiated with a calibrated ultraviolet A light source (370 nm, 3.0 mW/cm², UV-X illumination system version 1000, UVXTM, IROCAG, Zurich, Switzerland) for 30 minutes at a distance of 5 cm. During ultraviolet A irradiation, isotonic or hypoosmolar riboflavin was applied every 3 minutes to maintain the riboflavin saturation in the corneal stroma. Postoperative treatment comprised therapeutic bandage contact lens, antibiotic eye drops 4 times daily for 1 week, and fluorometholone eye drops 0.1% 4 times a day for 4 weeks.

2.3. Follow-Up Evaluation. Patients were examined at baseline, 6, and 12 months after CXL. All patients were requested to discontinue contact lens wear before each evaluation. Examinations included UCVA, BCVA, K_{max} , K1, K2, slit lamp evaluation, TCT (corneal topography, Allegro Topolyzer Vario, WaveLight GmbH, Erlangen, Germany), IOP (Non-contact Tonometer, Canon Full Auto Tonometer TX-F, Japan), and endothelial cell density (ECD, Specular Microscope SP-3000P, Japan).

2.4. Statistical Analysis. Statistical analysis was performed using SPSS software version 20.0 (SPSS, Inc.). Continuous variables were expressed with means \pm standard deviation or median according to their normal distribution or not. Comparison between four groups was performed using one-factor ANOVA or Kruskal-Wallis *H* test. Comparison before and after operation was performed using paired *t*-test or Wilcoxon signed-rank test. Correlation between preoperative corneal thickness and ΔK_{max} was tested by the Spearman rank correlation. A *P* value less than 0.05 was considered statistically significant.

3. Results

3.1. Patient Demographics. 123 eyes of 101 patients were treated, with a male to female preponderance of 3:1; mean age was 22.7 \pm 5.1 years (range, 14–37 years); mean TCT was 445.5 μm (range, 348–544 μm). There were 31 patients (25.2%) in group 1, 41 patients (33.3%) in group 2, 36 patients (29.3%) in group 3, 15 patients (12.2%) in group 4. Post-therapy follow-up duration was 12 months.

3.2. Six-Month Outcomes of CXL. Table 1 shows the outcomes of surgery at 6-month follow-up in the overall group. Before treatment, the mean TCT was 445.5 μm (SD \pm 48.7), mean K_{max} was 58.99 D (SD \pm 9.99), mean K1 was 47.14 D (SD \pm 4.45), mean K2 was 50.33 D (SD \pm 5.73), UCVA was 0.80 logMAR (SD \pm 0.36), and the BCVA was 0.35 logMAR (SD \pm 0.33). Six months after treatment, K_{max} was significantly decreased to a mean value of 57.24 D; K1 and K2 decreased to 46.83 D and 49.84 D, respectively. There was a tendency toward visual acuity improvement, reaching 0.72 logMAR (SD \pm 0.36) for UCVA and 0.25 logMAR (SD \pm 0.28) for BCVA. However, statistical analysis of IOP and ECD also showed statistically significant variation before and after treatment during the follow-up period (*P* = 0.016, *P* < 0.001, resp.). The initial mean TCT was 445.7 μm (SD \pm 48.65). Six months after CXL, there was a significant reduction with a value of 421.6 μm (SD \pm 48.2, *P* < 0.001).

3.3. One-Year Outcomes of CXL. Table 1 shows the outcomes of surgery at 12-month follow-up in the overall group. One year after treatment, K_{max} was significantly decreased to a mean value of 57.05 D; K1 and K2 decreased to 46.56 D and 49.56 D, respectively. There was a tendency toward visual acuity improvement, reaching 0.68 logMAR (SD \pm 0.35) for UCVA and 0.20 logMAR (SD \pm 0.26) for BCVA. However, statistical analysis of IOP and ECD also showed statistically significant variation before and after treatment during the follow-up period (*P* < 0.001 and *P* = 0.001). The initial mean TCT was 445.5 μm (SD \pm 48.7). Twelve months after treatment, there was a significant reduction with a value of 422.3 μm (SD \pm 45.9, *P* < 0.001).

Table 2 shows the changes of parameters compared with baseline by groups. There was a mean improvement about UCVA, BCVA, K1, K2, and K_{max} in the four groups. In the meanwhile, there was a decrease in TCT and ECD.

3.4. Comparison of ΔK_{max} between the Four Study Groups. In the subgroup of eyes with keratoconus, analysis showed a

TABLE 1: Baseline, 6, and 12 months outcomes after CXL in all eyes ($n = 123$).

Parameter	Preop	6 mo postop	12 mo postop
TCT (μm)	445.5 \pm 48.7	421.6 \pm 48.2*	422.3 \pm 45.9*
K_{max} (D)	58.99 \pm 9.99	57.24 \pm 9.21*	57.05 \pm 9.23*
K1 (D)	47.14 \pm 4.45	46.83 \pm 4.37*	46.56 \pm 4.25*
K2 (D)	50.33 \pm 5.73	49.84 \pm 5.42*	49.56 \pm 5.34*
UCVA (logMAR)	0.80 \pm 0.36	0.72 \pm 0.36*	0.68 \pm 0.35*
BCVA (logMAR)	0.35 \pm 0.33	0.25 \pm 0.28*	0.20 \pm 0.26*
IOP (mmHg)	9.97 \pm 1.90	11.16 \pm 2.92*	11.34 \pm 2.09*
ECD (cells/ mm^3)	3048.32 \pm 335.52	2982.70 \pm 362.29*	2951.48 \pm 363.15*

* $P < 0.05$, the difference was statistically significant.

trend toward a reduction in ΔK_{max} with the increase of TCT. After six months of CXL, the ΔK_{max} was 2.80 D (SD \pm 0.61) in group 1, 2.02 D (SD \pm 0.47) in group 2, 1.62 D (SD \pm 0.31) in group 3, and 0.05 D (SD \pm 0.23) in group 4. The difference between the four groups was statistically significant. One year after CXL, the ΔK_{max} was 3.04 D (SD \pm 0.75) in group 1, 2.38 D (SD \pm 0.51) in group 2, 1.57 D (SD \pm 0.35) in group 3, and 0.31 D (SD \pm 0.20) in group 4. The difference between the four groups was statistically significant (Tables 3 and 4, Figures 1 and 2).

3.5. The Relationship between Pre-CXL TCT and the ΔK_{max}

In order to study the relationship between the two variables, we drew the scatter plot and then fit a line with linear regression and found that they had a negative linear correlation (Figure 3 and Figure 4). Also, this correlation was statistically significant (correlation coefficient was -0.326 and -0.383 , resp., $P < 0.001$).

In order to study the change of ΔK_{max} along with TCT, we used regression analysis to access. Set TCT as the independent variable x , ΔK_{max} as the dependent variable y . The regression equation was as follows: $y = 9.311 - 0.017 \times x$. That is, in the TCT of each increase in one unit (μm), the average ΔK_{max} will decline 0.017 D.

4. Discussion

In 2003, Wollensak et al. first reported the corneal collagen crosslinking induced by riboflavin/ultraviolet A for the treatment of keratoconus [5]. Since then, a lot of similar studies began to emerge. Several reports have established the CXL as being safe and effective. For example, after 36 months follow-up, Wittig-Silva et al. reported 94 patients (100 eyes) who had CXL gained a significant flattening compared with controls [6]. In France, 42 eyes (68.8%) coming from 142 patients (142 eyes) diagnosed with keratoconus had stopped progression after CXL treatment. Viswanathan and Males found K_{max} of 51 eyes decreased about 0.96 D [7]. Similarly, our study also demonstrated the efficacy of CXL with UVA-riboflavin in the stabilization of keratoconus and recovery of visual acuity. Before treatment, the mean K_{max} was 58.99 D (SD \pm 9.99), mean K1 was 47.14 D (SD \pm 4.45), mean K2 was 50.33 D (SD \pm 5.73), UCVA was 0.80 logMAR (SD \pm 0.36), and the BCVA was 0.35 logMAR (SD \pm 0.33). One year after treatment, K_{max} was significantly decreased to a mean

value of 57.05 D, K1 and K2 decreased to 46.56 D and 49.56 D, respectively, and UCVA increased to 1.68 logMAR (SD \pm 0.35) and BCVA to 0.20 logMAR (SD \pm 0.26).

It has been reported that CXL increases stiffness by a factor of 1.5 [8]. Research studies indicated the cytotoxic UVA irradiance level for keratocytes as 0.5 mW/cm² and demonstrated a variable degree of apoptosis and cell loss in the anterior 250–300 μm of the corneal stroma with a surface irradiance of 3 mW/cm² [9]. An irradiance level of 0.37 mW/cm² at the endothelial cell layer is cytotoxic for the endothelial cells [10, 11]. When the surface irradiance is 3 mW/cm², the 0.37 mW/cm² irradiance reached a depth of 300 μm in the anterior of the cornea. So we determined the lower limit of the thinnest pachymetry as 340 μm with epithelium taking into account.

As is known to all, the aim of CXL is to halt progression of keratoconus and to preserve usable visual acuity. So, the maximum K (K_{max}) value derived from corneal topography analysis is very important and often been used to evaluate the efficacy of treatment. Flattening of K_{max} is a measure for treatment success, and steepening is an indication of poorer procedure efficacy. This is the focus of our analysis and the place of interest. Most of the studies reported a K_{max} reduction of 1-2 D after 1-year post-CXL. Hashemi et al. reported that K_{max} and K_{mean} decreased slightly (by 0.16 D and 0.1 D, resp.) at 5 years after the CXL procedure [12]. Hersh et al. reported a reduction of 1.70 D based on their RCT of 48 eyes [4]. Henriquez et al. reported a 2.66 D reduction in K_{max} based on their randomized prospective comparative study of 10 eyes [13].

In our retrospective analysis, these cases were divided into four groups according to TCT. After six months of treatment, it was 2.80 D (SD \pm 0.61) in group 1, 2.02 D (SD \pm 0.47) in group 2, 1.62 D (SD \pm 0.31) in group 3, and 0.05 D (SD \pm 0.23) in group 4. After 1 year of treatment, ΔK_{max} was 3.04 D (SD \pm 0.75) in group 1, 2.38 D (SD \pm 0.51) in group 2, 1.57 D (SD \pm 0.35) in group 3, and 0.31 D (SD \pm 0.20) in group 4. It is obvious that the change of K_{max} became smaller as the TCT increases. We found significant flattening of 3.04 D induced by CXL in the advanced subgroup ($< 400 \mu\text{m}$), which was more than in the mild to moderate subgroup. These results are similar to another study using accelerated CXL. It also showed a more striking effect on K_{max} reduction in thin versus thick corneas 6 months after CXL [14]. This phenomenon may be due to

TABLE 2: One-year outcomes of CXL by group.

Parameter	Group 1 (n = 31)		Group 2 (n = 41)		Group 3 (n = 36)		Group 4 (n = 15)	
	Preop	12 mo postop	Preop	12 mo postop	Preop	12 mo postop	Preop	12 mo postop
TCT (μm)	376.7 \pm 15.9	357.7 \pm 15.8*	429.8 \pm 10.7	406.6 \pm 18.8*	470.8 \pm 14.5	446.9 \pm 16.5*	515.3 \pm 9.6	483.5 \pm 5.1*
K1 (D)	51.57 \pm 6.09	50.71 \pm 5.68	47.50 \pm 3.25	46.87 \pm 3.29*	45.17 \pm 2.38	44.76 \pm 2.39	44.28 \pm 1.24	43.83 \pm 1.30*
K2 (D)	55.74 \pm 7.33	54.31 \pm 6.67	51.15 \pm 4.46	50.44 \pm 4.47*	47.55 \pm 3.46	47.09 \pm 3.37	46.62 \pm 2.44	46.18 \pm 2.74*
K _{max} (D)	62.83 \pm 9.24	59.20 \pm 10.70*	59.45 \pm 6.90	57.18 \pm 5.37*	57.80 \pm 8.58	55.33 \pm 9.60*	50.50 \pm 4.53	50.95 \pm 5.19
UCVA (logMAR)	0.90 \pm 0.38	0.69 \pm 0.43*	0.93 \pm 0.42	0.81 \pm 0.35*	0.91 \pm 0.29	0.74 \pm 0.30*	0.53 \pm 0.47	0.28 \pm 0.26*
BCVA (logMAR)	0.46 \pm 0.48	0.21 \pm 0.32*	0.49 \pm 0.29	0.29 \pm 0.34*	0.32 \pm 0.33	0.15 \pm 0.18*	0.10 \pm 0.20	0.08 \pm 0.15*
IOP (mmHg)	9.99 \pm 2.49	10.93 \pm 2.39*	9.75 \pm 1.33	12.25 \pm 1.61*	10.13 \pm 2.00	10.90 \pm 2.18	12.43 \pm 1.45	13.58 \pm 3.89*
ECD (cells/mm ³)	3151.33 \pm 279.07	2807.33 \pm 674.75*	3090.81 \pm 493.20	2874.54 \pm 537.35*	3036.50 \pm 416.94	2942.91 \pm 392.95*	2870.33 \pm 110.42	2805.68 \pm 116.97*

*P < 0.05, the difference was statistically significant between preop and 12 mo postop.

TABLE 3: Comparison of ΔK_{\max} between the four groups at 6-month follow-up.

	Group 1	Group 2	Group 3	Group 4
ΔK_{\max} (D)	2.80 ± 0.61	2.02 ± 0.47	1.62 ± 0.31	0.05 ± 0.23
χ^2		16.476		
P value		0.001*		

*P < 0.05, the difference was statistically significant.

TABLE 4: Comparison of ΔK_{\max} between the four groups at 1-year follow-up.

	Group 1	Group 2	Group 3	Group 4
ΔK_{\max} (D)	3.04 ± 0.75	2.38 ± 0.51	1.57 ± 0.35	0.31 ± 0.20
χ^2		17.603		
P value		0.001*		

*P < 0.05, the difference was statistically significant.

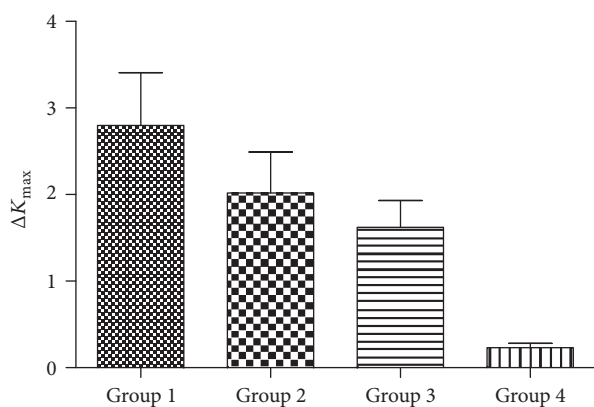


FIGURE 1: Comparison of ΔK_{\max} between four groups after six months of treatment.

the following reasons: first, the main reason for the more striking flattening effect of CXL in thin corneas is the anterior localization of the CXL effect resulting in an overall higher relative proportion of crosslinked stroma in thin corneas. Second, there was a difference in the thickness of corneal stroma in mild to moderate patients versus advanced cases of keratoconus. Stroma is the major structural part of the cornea which maintains the bulk of the mechanical strength of the cornea while maintaining the high degree of transparency required for the light transmission. It consists of collagen types I, III, V, and VI that are synthesized by the keratocytes along with the proteoglycan macromolecules [15]. HRT II confocal microscopy showed clear vertical and horizontal transition zones with a slight spread of edema and a regular number of cells in the untreated corneal periphery and at depths 345 μm (range, 275–345 μm). The deep corneal stroma beyond 350 μm did not show any changes in endothelial density or morphology [16]. A three-year prospective nonrandomized open trial by in vivo corneal micromorphological microscopy found that there existed demarcation

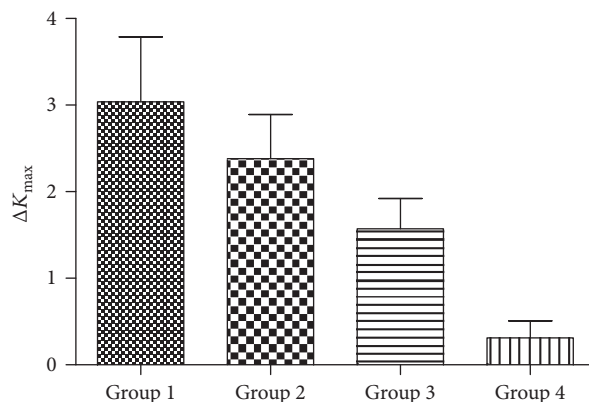


FIGURE 2: Comparison of ΔK_{\max} between four groups after 1 year of treatment.

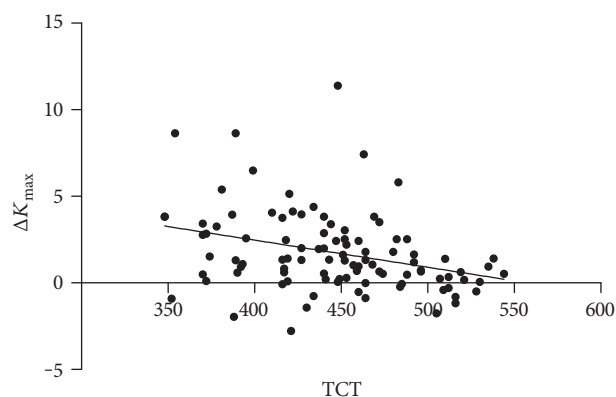


FIGURE 3: The scatter plot between TCT and ΔK_{\max} after 6 months of treatment.

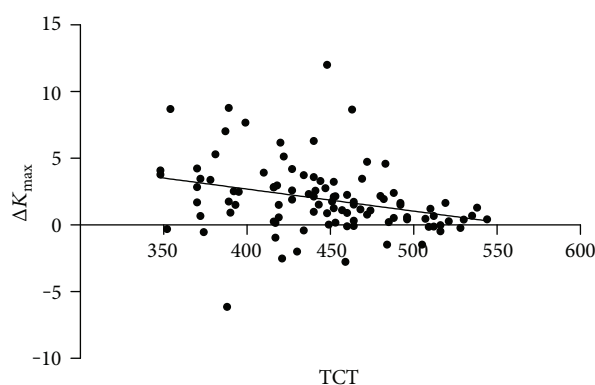


FIGURE 4: The scatter plot between TCT and ΔK_{\max} after 12 months of treatment.

lines between treated and untreated stroma to a depth of 340 μm including epithelium [17]. Third, from the biomechanical view, it may be due to the localization of CXL effect in the anterior portion of the stroma [18]. Wollensak et al. found the collagen diameter in the treated rabbit corneas increased by 12.2% anteriorly and by 4.6% posteriorly, and

the collagen diameter was significantly larger in the anterior stroma than in the posterior stroma [19]. Finally, thin cornea group was administered by hypotonic riboflavin solution until adequate thickness was achieved. The deepithelialized cornea can swell to double its normal thickness and creating collagen-free “lakes” [20]. Perhaps this allows ultraviolet light to become more convenient to permeate.

We found that there was a negative linear correlation between TCT and ΔK_{\max} . This has very important guiding significance before surgery, and it can predict the CXL effect.

With regard to TCT, there was a statistically thinning between preoperative and 1-year postoperative in both groups. Similar results were reported by Poli et al. in their 3-year prospective study of CXL [21]. In addition, a systematic review and meta-analysis which included 1171 participants with 1557 affected eyes found a slight decrease in CCT from baseline to 12 months post-CXL and then recovered to baseline after more than 18 months [22]. Perhaps the reason is the follow-up period was too short to be observed.

In addition, we found that ECD and IOP changed during the 12 months post-CXL ($P < 0.05$), but there were no changes in the size and shape of the endothelial cells, and the decrease in the number of the endothelial cells did not induce any endothelial cell-related complications such as corneal edema. There was no relationship between ECD changes and the change in TCT from preoperative to 6 months and 1 year postoperative, suggesting no clinical diminution in endothelial cell function from the procedure. The most common complication was corneal haze, which is temporary and does not disrupt vision. The postoperative temporary haze was often paracentral and compatible with good visual results. It may not be actually related to CXL itself but rather to the ongoing disease process and corneal remodeling [23].

In conclusion, this study has demonstrated the efficacy and safety of CXL with UVA-riboflavin in the stabilization of keratoconus. Keratoconic corneas with the thinnest pachymetry values less than $400 \mu\text{m}$ had the greatest changes of maximum keratometry values. Advanced cases of progressive keratoconus seemed to obtain more benefits from the flattening effects of corneal CXL. There was a negative linear correlation between TCT and ΔK_{\max} at the same time. However, further long-term follow-up studies with a larger number of participants are warranted.

Conflicts of Interest

The authors declare that there is no conflict of interest regarding the publication of this paper.

Authors' Contributions

Yunfei Han and Yanyun Xu are co-first authors who have equal contribution to the present study.

References

[1] J. Vazirani and S. Basu, “Keratoconus: current perspectives,” *Clinical Ophthalmology*, vol. 7, pp. 2019–2030, 2013.

- [2] P. T. Ashwin and P. J. McDonnell, “Collagen cross-linkage: a comprehensive review and directions for future research,” *The British Journal of Ophthalmology*, vol. 94, no. 8, pp. 965–970, 2010.
- [3] X. Chen, A. Stojanovic, J. R. Eidet, and T. P. Utheim, “Corneal collagen cross-linking (CXL) in thin corneas,” *Eye Vision (London)*, vol. 2, no. 15, pp. 1–7, 2015.
- [4] P. S. Hersh, S. A. Greenstein, and K. L. Fry, “Corneal collagen crosslinking for keratoconus and corneal ectasia: one-year results,” *Journal of Cataract and Refractive Surgery*, vol. 37, no. 1, pp. 149–160, 2011.
- [5] G. Wollensak, E. Spoerl, and T. Seiler, “Riboflavin/ultraviolet-a-induced collagen crosslinking for the treatment of keratoconus,” *American Journal of Ophthalmology*, vol. 135, no. 5, pp. 620–627, 2003.
- [6] C. Wittig-Silva, M. Whiting, E. Lamoureux, R. G. Lindsay, L. J. Sullivan, and G. R. Snibson, “A randomized controlled trial of corneal collagen cross-linking in progressive keratoconus: preliminary results,” *Journal of Refractive Surgery*, vol. 24, no. 7, pp. S720–S725, 2008.
- [7] D. Viswanathan and J. Males, “Prospective longitudinal study of corneal collagen cross-linking in progressive keratoconus,” *Clinical and Experimental Ophthalmology*, vol. 41, no. 6, pp. 531–536, 2013.
- [8] E. Lanchares, M. A. del Buey, J. A. Cristóbal, L. Lavilla, and B. Calvo, “Biomechanical property analysis after corneal collagen cross-linking in relation to ultraviolet A irradiation time,” *Graefes Archive for Clinical and Experimental Ophthalmology*, vol. 249, no. 8, pp. 1223–1227, 2011.
- [9] G. Wollensak, “Histological changes in human cornea after cross-linking with riboflavin and ultraviolet A,” *Acta Ophthalmologica*, vol. 88, no. 2, pp. e17–e18, 2010.
- [10] G. Wollensak, E. Spoerl, F. Reber, F. Reber, and T. Seiler, “Keratocyte cytotoxicity of riboflavin/UVA treatment in vitro,” *Eye*, vol. 18, no. 7, pp. 718–722, 2004.
- [11] G. Wollensak, E. Spoerl, M. Wilsch, and T. Seiler, “Endothelial cell damage after riboflavin-ultraviolet: a treatment in the rabbit,” *Journal of Cataract and Refractive Surgery*, vol. 29, no. 9, pp. 1786–1790, 2003.
- [12] H. Hashemi, M. A. Seyedian, M. Mirafteb, A. Fotouhi, and S. Asgari, “Corneal collagen cross-linking with riboflavin and ultraviolet a irradiation for keratoconus: long-term results,” *Ophthalmology*, vol. 120, no. 8, pp. 1515–1520, 2013.
- [13] M. A. Henriquez, L. Izquierdo Jr, C. Bernilla, P. A. Zakrzewski, and M. Mannis, “Riboflavin/ultraviolet A corneal collagen cross-linking for the treatment of keratoconus: visual outcomes and Scheimpflug analysis,” *Cornea*, vol. 30, no. 3, pp. 281–286, 2011.
- [14] M. Koç, M. M. Uzel, Y. Koban, I. Durukan, K. Tekin, and P. Yılmazbaş, “Comparison of results of accelerated corneal cross-linking with hypotonic riboflavin solution performed on corneas thicker and thinner than $400 \mu\text{m}$,” *Cornea*, vol. 35, no. 2, pp. 151–156, 2016.
- [15] A. Daxer and P. Fratzl, “Collagen fibril orientation in the human corneal stroma and its implication in keratoconus,” *Investigative Ophthalmology & Visual Science*, vol. 38, no. 1, pp. 121–129, 1997.
- [16] C. Mazzotta, A. Balestrazzi, C. Traversi et al., “Treatment of progressive keratoconus by riboflavin-UVA-induced cross-linking of corneal collagen ultrastructural analysis by Heidelberg Retinal Tomograph II in vivo confocal microscopy in humans,” *Cornea*, vol. 26, no. 4, pp. 390–397, 2007.

- [17] C. Mazzotta, C. Traversi, S. Baiocchi et al., "Corneal healing after riboflavin ultraviolet-A collagen cross-linking determined by confocal laser scanning microscopy in vivo: early and late modifications," *American Journal of Ophthalmology*, vol. 146, no. 4, pp. 527–533, 2008.
- [18] M. Kohlhaas, E. Spoerl, T. Schilde, G. Unger, C. Wittig, and L. E. Pillunat, "Biomechanical evidence of the distribution of cross-links in corneas treated with riboflavin and ultraviolet A light," *Journal of Cataract and Refractive Surgery*, vol. 32, no. 2, pp. 279–283, 2006.
- [19] G. Wollensak, M. Wilsch, E. Spoerl, and T. Seiler, "Collagen fiber diameter in the rabbit cornea after collagen crosslinking by riboflavin/UVA," *Cornea*, vol. 23, no. 5, pp. 503–507, 2004.
- [20] F. Hafezi, M. Mrochen, H. P. Iseli, and T. Seiler, "Collagen crosslinking with ultraviolet-A and hypotonic riboflavin solution in thin corneas," *Journal of Cataract and Refractive Surgery*, vol. 35, no. 4, pp. 621–624, 2009.
- [21] M. Poli, P. L. Cornut, T. Balmitgere, F. Aptel, H. Janin, and C. Burillon, "Prospective study of corneal collagen cross-linking efficacy and tolerance in the treatment of keratoconus and corneal ectasia: 3-year results," *Cornea*, vol. 32, no. 5, pp. 583–590, 2013.
- [22] T. Chunyu, P. XiuJun, F. Zhengjun, Z. Xia, and Z. Feihu, "Corneal collagen cross-linking in keratoconus: a systematic review and meta-analysis," *Scientific Reports*, vol. 4, article 5652, 2014.
- [23] L. S. Lim, R. Beuerman, L. Lim, and D. T. Tan, "Late-onset deep stromal scarring after riboflavin-UV-A corneal collagen cross-linking for mild keratoconus," *Archives of Ophthalmology*, vol. 129, no. 3, pp. 360–362, 2011.



Hindawi
Submit your manuscripts at
<https://www.hindawi.com>

