

Research Article

Low-Rank Matrix Denoising Algorithm-Based MRI Image Diagnosis of Uterine Malignant Tumor and Postoperative Care

Liqiong Cao ¹, Huiting Zhang ², and Yanling Liu ³

¹Department of Gynecology and Oncology, Chenzhou No.1 People's Hospital, Chenzhou 423000, Hunan, China

²Department Zone 2 of Breast, Sun Yat-sen University Cancer Center, Guangzhou, China

³Department of Oncology, Chenzhou No.1 People's Hospital, Chenzhou 423000, Hunan, China

Correspondence should be addressed to Yanling Liu; 141003320112@st.sdju.edu.cn

Received 13 December 2021; Revised 29 January 2022; Accepted 1 February 2022; Published 14 March 2022

Academic Editor: M Pallikonda Rajasekaran

Copyright © 2022 Liqiong Cao et al. This is an open access article distributed under the Creative Commons Attribution License, which permits unrestricted use, distribution, and reproduction in any medium, provided the original work is properly cited.

This paper aimed to discuss regarding diagnosis and postoperative care of uterine malignant tumor, the effect of MRI image based on low-rank matrix denoising algorithm in diagnosis, and postoperative care of uterine malignant tumor. 100 patients with uterine malignant tumor are selected for MRI examination and the MRI examination based on low-rank matrix denoising algorithm. The accuracy, sensitivity, and specificity of the two kinds of MRI are evaluated and compared by three or more experienced doctors through a double-blind method. At the same time, under the guidance of MRI image after denoising, relevant postoperative care is carried out. The results are compared with the previous results in our hospital. The results showed that the sensitivity, specificity, and accuracy of denoised MRI images in the diagnosis of uterine malignant tumors are higher than those of ordinary MRI. After denoising, the postoperative nursing guided by the MRI image effectively reduces the occurrence of postoperative complications. In postoperative nursing, the overall satisfaction of patients with nursing increases by 10.9%. *Conclusion.* The MRI image based on the low-rank matrix denoising algorithm has an obvious effect on diagnosis and postoperative care of uterine malignant tumor.

1. Introduction

The uterus is a unique female reproductive organ [1, 2]. Various reasons, such as early marriage, prolificacy, and sexual disorder, have a certain impact on the uterus and induce uterine malignant tumor [3]. Uterine malignant tumor is the most common malignant tumor in females, generally including cervical cancer and endometrial cancer [4]. For malignant tumor, the best prevention is regular physical examination, early diagnosis, early treatment, and perfect postoperative care to prolong the survival period of patients. Magnetic resonance imaging (MRI) can be used to clearly see the tissue structure of the human body, so it has become a conventional method for the diagnosis and treatment of human diseases [5]. However, MRI is easy to be polluted by noise in the imaging process, which makes the image quality poor and has a certain impact on the doctor's diagnosis [6].

Thung et al. (2018) found that the denoising algorithm based on low rank matrix has better denoising effect than other latest denoising algorithms [7]. Halder et al. (2020) showed that the denoising algorithm based on low rank matrix can perform high-resolution quantitative diffusion of MRI from relatively fast acquisition [8]. In the study of MRI in the diagnosis of uterine malignant tumor, Malek et al. (2019) found that the computer-aided method based on MRI can effectively distinguish myoma of uterus and leiomyoma [9]. Huang et al. (2019) studied that MRI combined with AI has a certain effect on distinguishing uterine sarcoma and improving the prognosis [10].

The research of the above scholars shows that the denoising algorithm based on low-rank matrix has a good effect in image denoising. However, it is not commonly used in MRI image denoising. Therefore, the research innovation is that MRI images play a certain role in the diagnosis of uterine tumors. Noise-contaminated MRI images may affect

clinicians' judgment of uterine tumors. Therefore, the algorithm based on low-rank matrix is used to effectively remove the noise in MRI images to significantly improve the quality of MRI images and help doctors diagnose diseases more accurately. Therefore, the role of MRI image based on the low-rank matrix denoising algorithm in the diagnosis of uterine malignant tumor and postoperative care is studied.

2. Materials and Methods

2.1. General Information. The subjects were examined with MRI and MRI based on the low-rank matrix denoising algorithm to compare the sensitivity and specificity of the two methods for uterine tumors. After the operation, the patients were given the postoperative care under the guidance of MRI based on the low-rank matrix denoising algorithm, and the difference between the care data of uterine malignant tumor and that of the hospital before was observed. The two methods were compared to show the role of the MRI image based on low rank matrix denoising algorithm in the diagnosis of uterine malignant tumor and postoperative care.

One hundred patients with uterine malignant tumor admitted to the hospital from June 2019 to August 2020 were selected as the research objects. Each patient was given pathological diagnosis and clinical examination. The experimental operations carried out were agreed by the patients and their families and agreed by the ethics committee of hospital. After the patient was diagnosed with uterine malignant tumor, the relevant clinical data were collected. The age of the subjects was between 29 and 75 years, with an average of 44.39 ± 9.25 years. The main clinical symptoms were irregular uterine bleeding in 32 cases, abnormal vaginal discharge in 30 cases, other symptoms in 23 cases, and 15 cases without symptoms. After admission, all patients underwent MRI examination. Conventional and enhanced scans from the inferior pole of the left kidney to the perineum plane were performed with MRI equipment. After the scan, the doctor carried out the diagnosis. At the same time, patients underwent MRI examination based on the low-rank matrix denoising algorithm. The inclusion and exclusion criteria were as follows:

Inclusion criteria: (1) received surgical treatment during hospitalization; (2) did not receive radiotherapy, chemotherapy, and endocrine therapy before operation; (3) not allergic; and (4) suspected of uterine malignancy through clinical symptoms and routine gynecological examination before operation.

Exclusion criteria: (1) may have consciousness disorder; (2) unable to complete the operation or the gynecologist in the same group was not designated to complete the operation; (3) had other serious diseases; and (4) did not cooperate with the examination or MRI.

2.2. MRI Based on the Low-Rank Matrix Denoising Algorithm.

In general, any image is composed of many rows and many columns from the aspect of matrix. When these rows and columns are taken apart, each row and column of the image

is highly correlated. Because the rank of image matrix is much smaller than the number of rows and columns, any image has low rank from the perspective of matrix. For MRI images, the noise pollution in the imaging process will destroy the correlation of each row and column in the image matrix, which will increase the rank of the image matrix and affect the image quality. Therefore, the low-rank matrix denoising algorithm aims at the problem of rank rise and makes certain restrictions on the rank of the image matrix in the process of MRI imaging, so as to achieve the effect of image denoising.

If the noisy image is Y , the noiseless image is I , and the noise matrix is N , Y can be expressed as:

$$Y = I + N. \quad (1)$$

However, because I and N are unknown, there may be errors in practical application. Therefore, in order to balance the sparsity of the noise matrix and the low rank of the real image, it is necessary to introduce the super parameter λ . The specific equation is as follows:

$$\min_{I,N} \lambda \|N\|_1 + \|I\|_*, \quad \text{s.t. } Y = I + N. \quad (2)$$

In (2), $\|I\|_*$ is the nuclear norm of the sum of all singular values in the image matrix.

Figure 1 shows the core steps of the denoising algorithm involved.

2.3. Postoperative Care. MRI based on the low-rank matrix denoising algorithm was used to diagnose the patient's condition and customize the operation plan. Combined with the physical quality of patients, the operation was carried out. After operation, blood pressure and other indexes of patients were continuously detected. According to the cases, the preoperative complications were treated. After anesthesia recovery, the physical and mental status of the patients was evaluated according to the operation records, and the patients who felt pain were given timely analgesic treatment. The patient's wound was checked regularly to prevent infection. Regular examination of urine routine was carried out to prevent the occurrence of urinary tract infection. Comfort and psychological counseling were given in time, so that patients could keep good sleep and rest and recovered their physical strength as soon as possible. For the elderly patients, the care of respiratory diseases was strengthened to exercise the lung function of patients. According to the observation of ventilation and defecation, diet should be adjusted timely to avoid cardiovascular disease and digestive system disease in elderly patients.

Postoperative complications such as urinary retention, bleeding, nausea, and vomiting should be indicated by MRI. For patients with possible complications, early prevention was carried out. The incidence of complications was statistically analyzed.

2.4. Observation Index. For the diagnosis of uterine malignant tumor with the MRI image, a double-blind method was used to analyze and judge. MRI images and MRI images

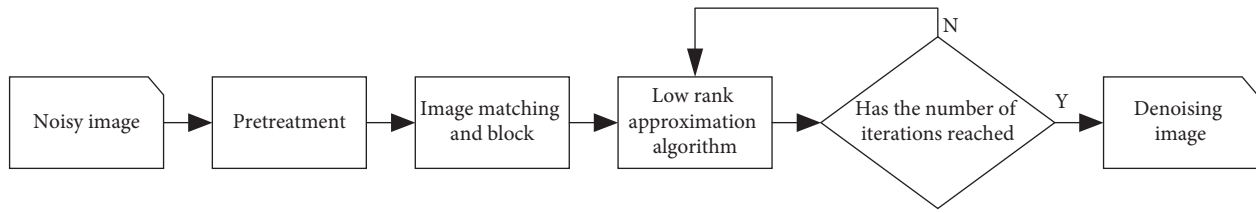


FIGURE 1: Core algorithm steps.

based on the low rank-matrix denoising algorithm were read by three or more experienced doctors and the diagnosis results were made. The unified results of all doctors were obtained and the accuracy, sensitivity, and specificity of the two kinds of MRI were compared. Accuracy was the close degree of MRI results with the actual situation of patients with uterine malignant tumor, sensitivity was the ability of MRI to detect patients with uterine malignant tumor, and specificity was the ability of MRI to detect patients without uterine malignant tumor.

Postoperative care was evaluated through the patient satisfaction with care staff and the occurrence of complications. Satisfaction evaluation was divided into three levels: very satisfied, satisfied, and dissatisfied. All patients were investigated with care satisfaction before discharge. The satisfaction was compared with that of the previous unified survey in hospital, and the total satisfaction rate of patients with postoperative care was obtained.

2.5. Statistical Analysis. SPSS18.0 software was used for data analysis, and $(\bar{x} \pm s)$ was used to describe the measurement data. Chi-square test was used for statistical analysis of counting data. The structure was expressed by rate or constituent ratio, and $p < 0.05$ meant that the difference was statistically significant.

3. Results

3.1. Basic Information of Patients. 100 patients with uterine malignant tumor were selected and diagnosed by MRI and MRI based on the low-rank matrix denoising algorithm. Table 1 shows the statistical analysis results of 100 patients with uterine malignant tumor. Among them, there are 46 patients with cervical cancer, 32 patients with endometrial cancer, 10 patients with uterine leiomyosarcoma, 3 patients with uterine lymphoma, and 9 patients with trophoblastic tumor. Through these 100 patients, the prevalence of uterine cancer in the population can be inferred. Cervical cancer is the most common, followed by endometrial cancer.

3.2. Effect Analysis of the Low-Rank Matrix Denoising Algorithm. Through the denoising of the clinical MRI image based on the low-rank matrix denoising algorithm, the visual effect and clarity of the denoising effect image are compared with the original MRI image. The results show that the denoised MRI image has a better visual effect, and it can effectively retain the details of the image itself while minimizing the noise pollution, and the image edge structure is

TABLE 1: Distribution of uterine malignant tumors.

Tumor type	Number of cases
Cervical cancer	46
Violation of the uterus	19
Violation of the side of the uterus	18
Violation of the vagina	9
Endometrial cancer	32
Uterine leiomyosarcoma	10
Uterine lymphoma	3
Trophoblastic tumor	9

also well processed. Therefore, the denoising algorithm based on low rank matrix can not only effectively suppress the noise pollution in the process of MRI imaging but also deal with the details well, which contribute a lot to the improvement of MRI image quality (Figure 2).

3.3. Comparison of Two Kinds of MRI in the Diagnosis of Uterine Malignant Tumor. Tables 2 and 3 show the diagnostic results of two kinds of MRI in 100 patients with uterine malignant tumor. Table 2 shows the diagnosis results of common MRI images for uterine malignant tumor. Among 46 cases with cervical cancer, 40 cases are detected by MRI, and the detection rate is 93.4%; among 32 cases of endometrial carcinoma, 30 cases are detected by MRI, and the detection rate is 93.8%; among 10 cases of uterine leiomyosarcoma, 8 cases are detected by MRI, and the detection rate is 80.0%; 3 cases of uterine lymphoma are all detected by MRI, and the detection rate is 100%; and among 9 cases of trophoblastic tumor, 7 cases are detected by MRI and the detection rate is 77.7%.

Table 3 shows the diagnostic results of MRI images denoised by low-rank matrix for uterine malignant tumor. Table 3 shows that in 46 cases with cervical cancer, 45 cases are diagnosed by MRI after denoising, and the detection rate is 97.8%; among 32 cases of endometrial cancer, 31 cases are detected by MRI after denoising, and the detection rate is 96.8%; 10 cases of uterine leiomyosarcoma are all detected by MRI after denoising, and the detection rate is 100.0%; 3 cases of uterine lymphoma are all detected by MRI after denoising; 9 cases of trophoblastic tumors are all detected by MRI after denoising, and the detection rate is 100%.

The two methods are compared. After denoising, the detection rate of cervical cancer is increased by 4.4%, the detection rate of endometrial cancer is increased by 3.0%, the detection rate of uterine leiomyosarcoma is increased from 80% to 100%, and the detection rate of trophoblastic tumor

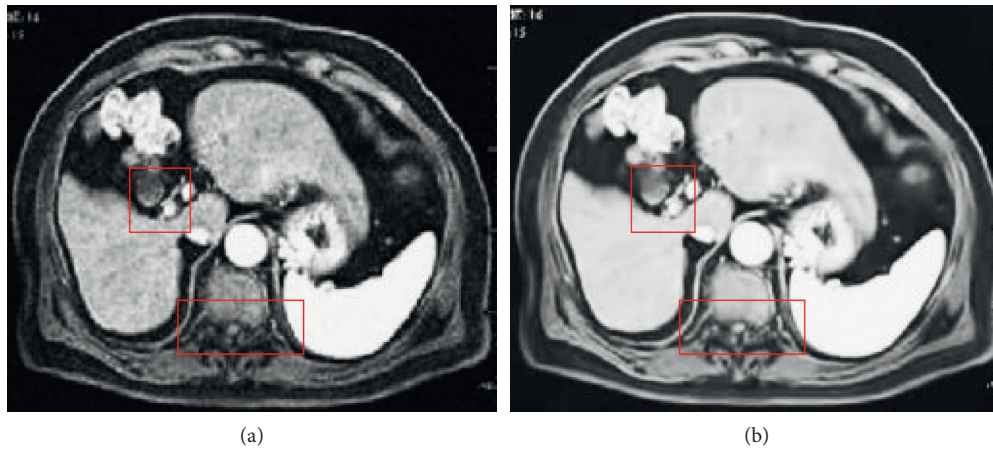


FIGURE 2: Comparison of original MRI image and denoising result image. (a) MRI image. (b) MRI image after low rank matrix denoising.

TABLE 2: Diagnosis results of uterine malignant tumor based on MRI.

Tumor type	Actual number of cases	Number of cases detected by MRI	Percentage (%)
Cervical cancer	46	43	93.4
Endometrial cancer	32	30	93.8
Uterine leiomyosarcoma	10	8	80.0
Uterine lymphoma	3	3	100
Trophoblastic tumor	9	7	77.7

TABLE 3: Diagnosis results of uterine malignant tumor using MRI based on the low-rank matrix denoising algorithm.

Tumor type	Actual number of cases	Number of cases detected by MRI based on the low-rank matrix denoising algorithm	Percentage (%)
Cervical cancer	46	45	97.8
Endometrial cancer	32	31	96.8
Uterine leiomyosarcoma	10	10	100
Uterine lymphoma	3	3	100
Trophoblastic tumor	9	9	100

is also increased to 100%. Therefore, the low-rank matrix denoised MRI image improves the detection rate of various uterine malignant tumors and provides better auxiliary conditions for clinicians to master the disease.

Figure 3 shows the sensitivity, specificity, and accuracy of MRI and MRI based on the low-rank matrix denoising algorithm for the diagnosis of uterine malignant tumor. It shows that the sensitivity, specificity, and accuracy of MRI image based on low-rank matrix denoising algorithm for the diagnosis of uterine malignant tumor are higher than those for the ordinary MRI image. Therefore, the MRI image processed by low-rank matrix denoising algorithm can effectively improve the diagnosis of uterine malignant tumor.

3.4. Postoperative Care Results. Figure 4 shows the statistical analysis results of postoperative complications in patients with uterine malignant tumor. It shows that after care, the incidence of various complications is reduced, except for ureterovaginal fistula. In patients, there is one case of postoperative ureterovaginal fistula, accounting for 1.0% of

the cases. The incidence of urinary retention, vesical vaginal fistula, lymphatic cyst, and intestinal obstruction decreases by 3.87%, 0.79%, 0.57%, and 1.94%, respectively. Therefore, after the care based on denoising MRI, the occurrence of postoperative complications in patients with uterine malignant tumor is reduced, and the quality of life of patients is improved.

Table 4 shows the survey results of 100 patients' satisfaction with this care after the care based on denoising MRI. This satisfaction survey is divided into three levels: very satisfied, satisfied, and dissatisfied. The data results in Table 4 show that the overall satisfaction of patients has been significantly improved after the care based on denoising MRI. The number of patients who are very satisfied with the care increases from 26.3% to 39.0%, the number of patients who are satisfied with the care increases to 43.0%, and the number of patients who express dissatisfaction decreases from 28.9% to 18.0%. The overall satisfaction of patients also increases from 71.1% to 82.0%. To sum up, the survey results of patients' satisfaction with care show that the care work under the guidance of MRI based on the low-rank matrix

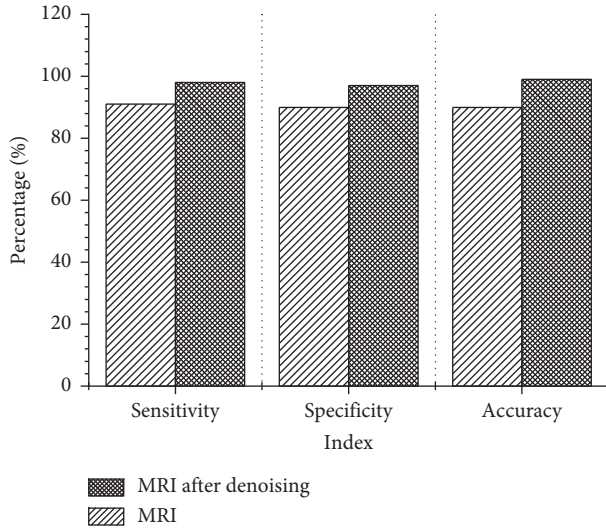


FIGURE 3: Comparison of sensitivity, specificity, and accuracy of two kinds of MRI in diagnosis of uterine malignant tumor.

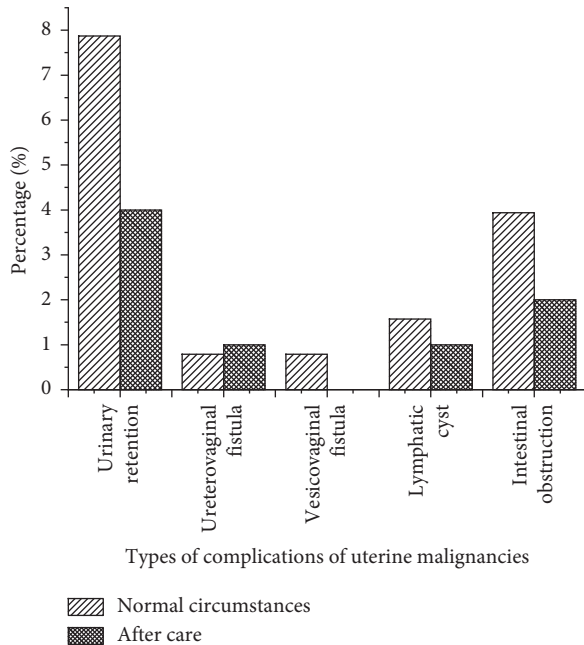


FIGURE 4: Comparison of postoperative complications of uterine malignant tumor.

TABLE 4: Comparison of care satisfaction.

Satisfaction	Normal circumstances (%)	After care (%)
Very satisfied	26.3	39.0
Satisfied	44.7	43.0
Not satisfied	28.9	18.0
Overall satisfaction rate	71.1	82.0

denoising algorithm not only reduces the occurrence of postoperative complications but also improves the recognition of patients for care work.

4. Discussion

In China, about 700 thousand people lose their lives due to cancer every year, and 53000 of them die of cervical cancer [11]. Uterine malignant tumor has become the main cause of endangering women’s life and health, especially cervical cancer [12]. For the diagnosis of uterine malignant tumor, MRI is the most commonly used imaging technology in clinic. MRI not only has a good resolution and contrast for the tissue structure of the body but can also form a three-dimensional image, which can better show the location and structure of the lesion [13]. However, in the process of MRI imaging, it is also easy to be polluted by noise, which affects MRI imaging [14]. In the research of MRI image denoising, some studies suggest that the denoising method based on low-rank matrix has a better denoising effect on MRI image [15]. Therefore, the role of MRI based on the low-rank matrix denoising algorithm in the diagnosis and postoperative care of uterine malignant tumor has been studied.

The research results show that the denoising algorithm based on low-rank matrix can not only improve the visual effect of the MRI image but also better process the details and edge contour of the MRI image, which is consistent with the research results of Gu et al. [16]. The sensitivity, specificity, and accuracy of MRI based on the low-rank matrix denoising algorithm are better than ordinary MRI in diagnosis of uterine malignant tumor. At the same time, research results of postoperative care guided by the MRI image after denoising show that targeted care not only reduces the incidence of postoperative complications of patients with uterine malignant tumor but also improves the satisfaction of patients for care. Therefore, the MRI image after denoising is used for the diagnosis of uterine malignant tumor and the guidance of postoperative care. For doctors, they can diagnose the disease more quickly and accurately. For patients, the life quality can be improved.

5. Conclusion

In view of the diagnosis and postoperative care of uterine malignant tumor, the role of the MRI image based on low-rank matrix denoising algorithm in the diagnosis and postoperative care of uterine malignant tumor is studied. The results show that the denoising algorithm based on low-rank matrix improves the MRI image quality and improves the diagnostic rate of uterine malignant tumor. In addition, under the guidance of MRI after denoising, targeted postoperative care for patients can reduce the incidence of postoperative complications and further improve the life quality of patients. Therefore, this study provides a reference for the diagnosis and treatment of uterine malignant tumor. Of course, there are still some research deficiencies. For example, the number of research objects in this experiment is too small and the sample is relatively single. Therefore, in the follow-up study, the number of samples can be further increased, and patients from multiple hospitals can be taken as the research subject to make the results more reliable and provide a powerful reference for the diagnosis and treatment of uterine malignancies in the follow-up clinic.

Data Availability

The data used to support the findings of this study are available from the corresponding author upon request.

Conflicts of Interest

The authors declare no conflicts of interest.

References

- [1] D. Liang, L. Li, Y. He, and W. Jiang, "Primary uterine angiosarcoma: a case report in China with the literature review," *Indian Journal of Pathology & Microbiology*, vol. 63, no. Supplement, pp. S94–S97, 2020.
- [2] A. Ogino, T. Hirai, T. Serizawa, and A. Yoshino, "Gamma knife surgery for brain metastases from uterine malignant tumor," *World Neurosurgery*, vol. 139, pp. e363–e372, 2020.
- [3] M. L. Xu, Y. L. Liu, S. Zeng, H. Wang, G. Weng, and F. Li, "Primary vaginal Ewing sarcoma with uterine fibroid: a case report," *Medicine*, vol. 99, no. 27, Article ID e20859, 2020.
- [4] T. H. Kim, J. W. Kim, S. Y. Kim, and J. Y. Cho, "What MRI features suspect malignant pure mesenchymal uterine tumors rather than uterine leiomyoma with cystic degeneration?" *Journal of Gynecologic Oncology*, vol. 29, no. 3, 2018.
- [5] D. F. Xie, Y. R. Li, H. L. Yang et al., "Denoising arterial spin labeling perfusion MRI with deep machine learning," *Magnetic Resonance Imaging*, vol. 68, pp. 95–105, 2020.
- [6] S. Q. Li, J. J. Zhou, D. Liang, and Q. Liu, "MRI denoising using progressively distribution-based neural network," *Magnetic Resonance Imaging*, vol. 71, pp. 55–68, 2020.
- [7] K. H. Thung, P. T. Yap, E. Adeli, S. W. Lee, and D. Shen, "Conversion and time-to-conversion predictions of mild cognitive impairment using low-rank affinity pursuit denoising and matrix completion," *Medical Image Analysis*, vol. 45, pp. 68–82, 2018.
- [8] J. P. Haldar, Y. S. Liu, C. Y. Liao, Q. Fan, and K. Setsompop, "Fast submillimeter diffusion MRI using gSlider-SMS and SNR-enhancing joint reconstruction," *Magnetic Resonance in Medicine*, vol. 84, no. 2, pp. 762–776, 2020.
- [9] M. Malek, M. Gity, A. Alidoosti et al., "A machine learning approach for distinguishing uterine sarcoma from leiomyomas based on perfusion weighted MRI parameters," *European Journal of Radiology*, vol. 110, pp. 203–211, 2019.
- [10] Y. T. Huang, Y. L. Huang, K. K. Ng, and G. Lin, "Current status of magnetic resonance imaging in patients with malignant uterine neoplasms: a review," *Korean Journal of Radiology*, vol. 20, no. 1, pp. 18–33, 2019.
- [11] Z. Ma, C. Fan, S. Y. Wang et al., "CTHRC1 affects malignant tumor cell behavior and is regulated by miR-30e-5p in human prostate cancer," *Archives of Biochemistry and Biophysics*, vol. 525, no. 2, pp. 418–424, 2020.
- [12] Y. Wang, M. Xu, and Q. Yang, "A six-microRNA signature predicts survival of patients with uterine corpus endometrial carcinoma," *Current Problems in Cancer*, vol. 43, no. 2, pp. 167–176, 2019.
- [13] D. Li, N. Yin, G. B. Du et al., "A real-world study on diagnosis and treatment of uterine sarcoma in western China," *International Journal of Biological Sciences*, vol. 16, no. 3, pp. 388–395, 2020.
- [14] H. C. Zhu, J. Zhang, and Z. Wang, "Arterial spin labeling perfusion MRI signal denoising using robust principal component analysis," *Journal of Neuroscience Methods*, vol. 295, pp. 10–19, 2018.
- [15] Z. Chen, Y. L. Fu, Y. J. Xiang, and J. Xu, "A novel low-rank model for MRI using the redundant wavelet tight frame," *Neurocomputing*, vol. 289, pp. 180–187, 2018.
- [16] Q. L. Gu, J. D. Trzasko, and A. Banerjee, "Scalable algorithms for locally low-rank matrix modeling," *Knowledge and Information Systems*, vol. 61, no. 3, pp. 1457–1484, 2019.