Journal of Ophthalmology

Complications of Vitreoretinal Surgery

Lead Guest Editor: Manish Nagpal
Guest Editors: Ogugua Okonkwo, Ehab El Rayes, Kwesi Nyan Amissah-Arthur, and Linda Visser

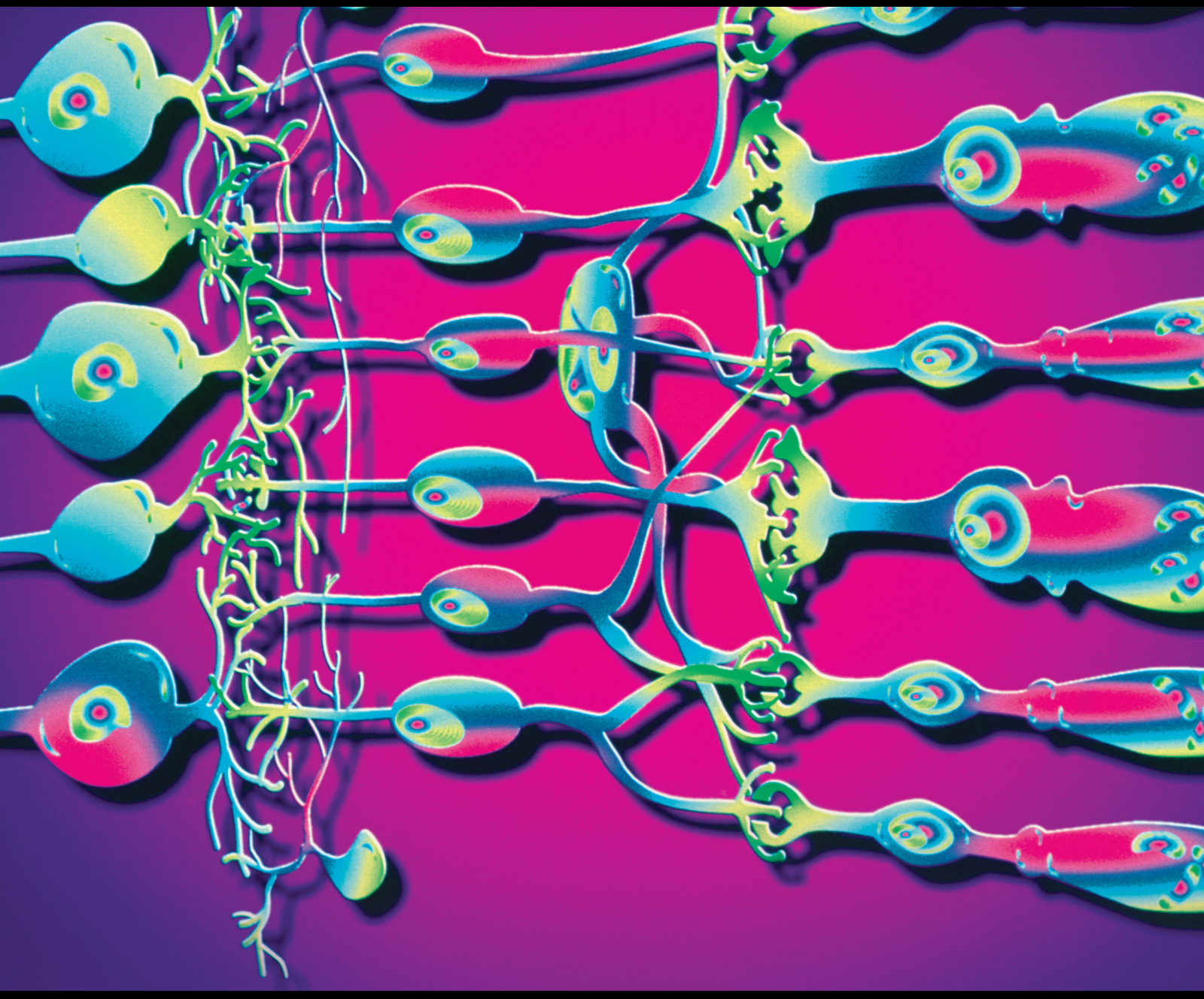

Complications of Vitreoretinal Surgery

Journal of Ophthalmology

Complications of Vitreoretinal Surgery

Lead Guest Editor: Manish Nagpal
Guest Editors: Ogugua Okonkwo, Ehab El Rayes, Kwesi Nyan Amissah-Arthur, and Linda Visser

Copyright © 2022 Hindawi Limited. All rights reserved.

This is a special issue published in "Journal of Ophthalmology." All articles are open access articles distributed under the Creative Commons Attribution License, which permits unrestricted use, distribution, and reproduction in any medium, provided the original work is properly cited.

Chief Editor

Steven F. Abcouwer, USA

Associate Editors

Sentaro Kusuhara, Japan
Tamer A. Macky, Egypt
Lawrence S. Morse, USA
Jena J. Steinle, USA
Tomasz Zarnowski, Poland

Academic Editors

Steven F. Abcouwer, USA
Monica L. Acosta, New Zealand
Hamid Ahmadieh, Iran
Hee B. Ahn, Republic of Korea
Siamak Ansari-Shahrezaei, Austria
Taras Ardan, Czech Republic
Francisco Arnalich-Montiel, Spain
Kofi Asiedu, Ghana
Takayuki Baba, Japan
Stefano Baiocchi, Italy
Angelo Balestrazzi, Italy
Antonio Benito, Spain
Maja Bohac, Croatia
Mehmet Borazan, Turkey
Carlo Cagini, Italy
Gonzalo Carracedo, Spain
Arturo Carta, Italy
Alejandro Cerviño, Spain
Colin Clement, Australia
Inés Contreras, Spain
Ciro Costagliola, United Kingdom
Luca D'Andrea, Italy
Roberto Dell'Omo, Italy
Simone Donati, Italy
Manuel S. Falcão, Portugal
Bao Jian Fan, USA
Paulo Fernandes, Portugal
Michele Figus, Italy
Paolo Fogagnolo, Italy
Maria-Andreea Gamulescu, Germany
Diego García-Ayuso, Spain
Jose M. González-Meijome, Portugal
Vlassis Grigoropoulos, Greece
Carl Peter Herbort, Switzerland
Shigeru Honda, Japan
Pierluigi Iacono, Italy
Claudio Iovino, Italy
Takashi Kojima, Japan
George Kymionis, Greece
Hong LIANG, France
Achim Langenbucher, Germany
Van C. Lansingh, Mexico
Paolo Lanzetta, Italy
Theodore Leng, USA
Shengjie Li, China
Su-Ho Lim, Republic of Korea
Antonio Longo, Italy
Norberto López-Gil, Spain
Andrea Lucisano, Italy
Angel Luis Ortega, Spain
Marco Lupidi, Italy
Edward Manche, USA
Marco Marenco, Italy
Colm McAlinden, United Kingdom
Enrique Mencía-Gutiérrez, Spain
Paolo Milani, Italy
Elad Moisseiev, Israel
Mário Monteiro, Brazil
Paolo Mora, Italy
Majid M. Moshirfar, USA
Jean-Claude Mwanza, USA
Carlo Nucci, Italy
Akio Oishi, Japan
Giovanni William Oliverio, Italy
Neville Osborne, United Kingdom
Ji-jing Pang, USA
Georgios Panos, United Kingdom
Mohit Parekh, United Kingdom
Sudhir Patel, Scotland
Enrico Peiretti, Italy
David P. Piñero, Spain
Eli Pradhan, Nepal
Antonio Queiros, Portugal
Anthony G. Robson, United Kingdom
Mario R. Romano, Italy
Wataru Saito, Japan
Juan A. Sanchis-Gimeno, Spain
Dirk Sandner, Germany
Ana Raquel Santiago, Portugal
Rehman Siddiqui, Pakistan
Bartosz Sikorski, Poland

Shivalingappa K. Swamynathan, USA
Nóra Szentmáry, Hungary
Masaru Takeuchi, Japan
Suphi Taneri, Germany
Miguel Teus, Spain
Biju B. Thomas, USA
Oren Tomkins-Netzer, United Kingdom
Lisa Toto, Italy
Maurizio Uva, Italy
Manuel Vidal-Sanz, Spain
Paolo Vinciguerra, Italy
Nilufer Yesilirmak, Turkey
Vicente Zanon-Moreno, Spain
Yedi Zhou, China

Contents

Hindawi
Journal of Ophthalmology
Volume 2022, Article ID 8434102, 5 pages
https://doi.org/10.1155/2022/8434102

Research Article

Influence of Perfluorooctane Liquids in the Formation of Sticky Silicone Oil

Hirotsugu Takashina,[1] **Akira Watanabe**,[2] **and Tadashi Nakano**[2]

[1]*Department of Ophthalmology, Tokyo Rosai Hospital, 4-13-21 Omori-minami Ota-ku, Tokyo 143-0013, Japan*
[2]*Department of Ophthalmology, The Jikei University School of Medicine, 3-25-8 Nishi-Shimbashi Minato-ku, Tokyo 105-8461, Japan*

Correspondence should be addressed to Hirotsugu Takashina; two-shina@s7.dion.ne.jp

Received 23 August 2021; Revised 26 December 2021; Accepted 19 January 2022; Published 4 February 2022

Academic Editor: Antonio Longo

Copyright © 2022 Hirotsugu Takashina et al. This is an open access article distributed under the Creative Commons Attribution License, which permits unrestricted use, distribution, and reproduction in any medium, provided the original work is properly cited.

Purpose. To examine the influence of perfluorooctane (PFO) in the formation of sticky silicone oil (SO). *Methods*. We performed in vitro experiments using PFO, SO, aqua, and canola oil (CO). The surface tension of CO relative to aqua is very close to that of SO or PFO. First, each material (0.5 ml) was carefully injected into the bottom of a transparent container that was filled with either aqua or CO. Next, a second material (0.5 ml) with a specific gravity that was lower than that of the first material was carefully injected onto the first material. *Results*. When the first material was injected into the container, the shape of the aqua was found to be close to a sphere, while the shapes of SO or PFO were prolate spheroids. Subsequently, when the second material was injected onto the first material, SO and CO completely adhered to the PFO, with the created immiscible droplets exhibiting a smooth surface. However, aqua did not create any immiscible droplets due to absence of adhesion to PFO or SO. *Conclusions*. Sticky SO is composed of PFO and SO, which easily form an immiscible droplet due to the low interfacial tension.

1. Introduction

Silicone oil (SO) tamponade is performed during vitrectomy for severe vitreoretinal diseases (e.g., rhegmatogenous retinal detachment with a giant retinal tear or proliferative vitreoretinopathy). Although subsequent SO removal is desirable in order to avoid future complications in relation to SO tamponade (e.g., oil emulsification or glaucoma), development of "sticky SO" as a complication makes SO removal difficult due to the presence of adhesion to the posterior retina. Dresp et al. reported that prolonged SO tamponade duration was one of the factors affecting the occurrence of sticky SO [1]. In contrast, no significant correlation between the occurrence of sticky SO and the SO tamponade duration was reported in other articles [2, 3]. In fact, Fukumoto et al. reported a remarkable case in which sticky SO occurred during a vitrectomy that used an SO injection [4]. Thus, the influence of SO tamponade duration on the occurrence of sticky SO has yet to be definitively determined. On the other hand, all these previous articles reported that intraoperative handling of perfluorocarbon liquids (PFCLs), such as perfluorooctane (PFO) and perfluorodecalin (PFD), is the potential cause of sticky SO [1–4]. This is especially the case with regard to the handling of PFO, as this has been reported to have a tendency to cause sticky SO to a greater degree than that seen for PFD [2, 3]. Since Dresp et al. mentioned the influence of surface tension on the formation of sticky SO [1], we performed in vitro experiments to elucidate the relationship between interfacial tension and sticky SO, after we experienced a case of sticky SO.

2. Materials and Methods

A 53-year-old male underwent phacovitrectomy (using a 25-gauge system) for rhegmatogenous retinal detachment with a giant nasal retinal tear (from 12 to 5 o'clock) at Tokyo Rosai Hospital. During the surgery, PFO (PERFLUORON; Alcon

Laboratories, Inc., Fort Worth, TX) was injected in order to flatten the detached retina before the performance of thorough vitreous shaving and endophotocoagulation around the retinal tear, and a direct exchange of PFO with SO (SILIKON™ 1000; Alcon Laboratories, Inc., Fort Worth, TX) was performed at the end of the surgery. However, on postoperative day 1, we recognized a horizontal border crossing close to the macula during fundal examination performed with the patient in the seated position (Figure 1(a)). We speculated that the PFO remained in nearly half of the volume of the vitreous cavity, with intraoperative occurrence of severe corneal edema being responsible for this insufficient exchange. Due to the retinal toxicity of PFCL, we performed a second vitrectomy one week later in order to remove the PFO and SO using a Viscous Fluid Control Pak® (Alcon Laboratories, Inc., Fort Worth, TX) (VFC). In the middle of this PFO and SO removal, we found adhesion of the SO to the posterior retina (Figure 1(b)). The VFC needle was not able to reach the adhered SO due to the shortness of the needle, and we diagnosed the presence of sticky SO. At that time, the presence of a colorless and transparent fluid between the sticky SO and the posterior retina was recognized (Figure 1(c)), and it was inferred that the fluid was PFO due to the easy suction that was found when using the backflush needle. Subsequently, when the PFO was removed to approximately twice the optic disc diameter, the sticky SO was separated from the PFO and then ascended in the vitreous cavity. This made it possible to remove the SO using the VFC needle.

We speculated that adhesion of the SO to the retinal surface via PFO was the cause of the sticky SO in our case. So, we performed in vitro experiments using PFO, SO, aqua, and canola oil (CO). Table 1 shows the surface tension, which is the interfacial tension between gas and liquid or solid, and the specific gravity of each material. Table 2 shows the interfacial tension between the different liquids. The numerical values for the surface tension in Table 1 and the interfacial tension in Table 2 are rounded to the nearest integer.

The surface tension of CO relative to aqua is very close to that of SO or PFO, while SO and PFCL have similar characteristics, including being hydrophobic and lipophilic. Therefore, the characteristics of CO in relation to aqua are similar to those of PFO or SO. In the in vitro experiments, first, each material (0.5 ml) was carefully injected into the bottom of a transparent container that was filled with either aqua or CO. Next, a second material (0.5 ml) with a specific gravity that was lower than that of the first material was carefully injected into the first material.

3. Results and Discussion

The shapes of each first material are shown in Figure 2. The shape of aqua was found to be close to a sphere (Figure 2(a)), while the shapes of SO and PFO were prolate spheroids (Figures 2(b)–2(d)).

Subsequently, when the second material was injected into the first material, SO and CO completely adhered to the PFO, with the created immiscible droplets exhibiting a smooth surface. The shapes of each immiscible droplet are shown in Figure 3.

However, the aqua did not create any immiscible droplets due to no adhesion to the PFO or SO (Figure 4), and the second material (Figure 4(a): aqua, Figure 4(b): SO) immediately slid down the first material (Figure 4(a): PFO, Figure 4(b): aqua) after the picture was obtained.

Since Dresp et al. mentioned the influence of surface tension in the formation of sticky SO [1], we performed these experiments using four materials (PFO, SO, aqua, and CO) to assess the adhesiveness between different liquids. CO contains more than 90% oleic acid + linoleic acid, having C-H, C = O, and C-OH bonds, SO contains Si-O bonds, and PFO contains C-F and C-H bonds. These chemical structures determine their surface tensions and interfacial tensions with water and with each other and also the shapes of the immiscible droplets. Since a higher surface tension indicates a stronger intermolecular force, there is matchlessly strongest intermolecular force for aqua among the four materials. Since the difference in intermolecular force between two materials influences the interfacial tension, the interfacial tension between SO and CO is matchlessly lower than the interfacial tensions between aqua and the other materials (Table 2). Similarly, the interfacial tensions between PFO and SO or CO are thought to be matchlessly lower than the interfacial tensions between aqua and PFO, SO, and CO.

We supposed that the matchlessly strongest intermolecular force in aqua was one of the reasons why the shape of aqua in CO was the closest to a sphere in the experiment (Figure 2(a)). In contrast, we supposed that the relatively large influence of the gravitation due to weak intermolecular force was one of the reasons why the shape of SO in CO was a prolate spheroid in the experiment (Figure 2(b)). In fact, the shapes of PFO in aqua (Figure 2(c)) and in CO (Figure 2(d)) were almost the same (spheroids), suggesting that the interfacial tension hardly influenced the shape of a single material. On the other hand, when a second material was injected into the first material, each immiscible droplet was composed of materials having a low surface tension (PFO, SO, and CO) (Figure 3), while aqua did not form any immiscible droplets with either PFO or SO in CO (Figure 4). Therefore, low intermolecular forces were inferred to influence the formation of immiscible droplets.

As described above, the interfacial tension had little influence of the shape of a single material. However, the shapes of the immiscible droplet composed of PFO and SO were considerably different, as seen in Figures 3(a) and 3(b), and the phenomenon might have been influenced by the material which was filled in the transparent container (Figure 3(a): CO; Figure 3(b): aqua). In fact, the contact point among the three immiscible liquids in Figure 3(a) (PFO, SO, and CO) was unclear, while the contact point among the three immiscible liquids in Figure 3(b) (PFO, SO, and aqua) was clear (yellow arrowheads in Figure 3(b)). In Figure 3(b), the interface between PFO and SO was roughly perpendicular to the interface between aqua and the immiscible droplet composed of PFO and SO at the contact point. The roughly perpendicular line at the contact point

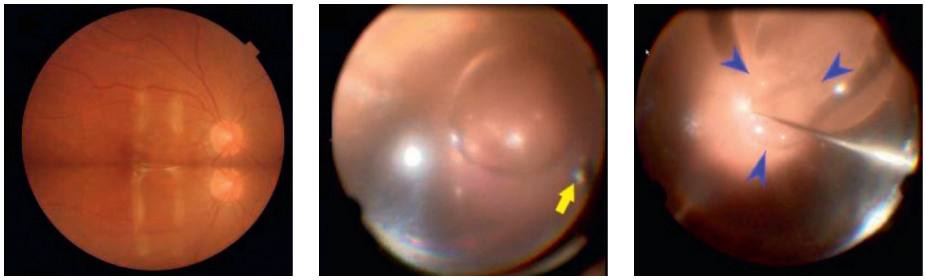

(a) (b) (c)

Figure 1: Fundus findings. A horizontal border crossing close to the macula (a) and sticky silicone oil on the posterior retina are shown. The needle of the Viscous Fluid Control Pak® (yellow arrow) was not able to reach the sticky silicone oil (b). Perfluorooctane was present between the silicone oil and posterior retina (area surrounded by blue arrowheads) (c).

Table 1: Specific gravity and surface tension of each material.

	PFO	SO	Aqua	CO
Specific gravity (g/ml)	1.75 [5]	0.97 [6]	1.0	0.91 [7]
Surface tension (dyne/cm)	17 [5]	21*	72 [1, 8]	31 [9]

PFO = perfluorooctane, SO = silicone oil, CO = canola oil. *Provided by Alcon Japan Ltd.

Table 2: Interfacial tension between different liquids.

	Aqua-PFO	Aqua-SO	Aqua-CO	SO-CO
Interfacial tension (dyne/cm)	40–45 [10]	35 [10]	33 [11]	2–3 [12]

PFO = perfluorooctane, SO = silicone oil, CO = canola oil.



Figure 2: Shape of each material. Aqua in canola oil (a), silicone oil in canola oil (b), perfluorooctane in aqua (c), and perfluorooctane in canola oil (d). Aqua in canola oil was the closest in shape to a sphere (a), while all of the others were prolate spheroids.



Figure 3: Shape of each immiscible droplet exhibiting a smooth surface. The shape of each immiscible droplet exhibiting a smooth surface is shown (the red arrowheads indicate the border between two materials). Silicone oil-perfluorooctane immiscible droplet in canola oil (upper: silicone oil, lower: perfluorooctane) (a), silicone oil-perfluorooctane immiscible droplet in aqua (upper: silicone oil, lower: perfluorooctane) (the yellow arrowheads indicate the contact point among perfluorooctane, silicone oil, and aqua) (b), and canola oil-perfluorooctane immiscible droplet in aqua (upper: canola oil, lower: perfluorooctane) (the yellow arrowheads indicate the contact point among perfluorooctane, canola oil and aqua) (c).



Figure 4: Lack of formation of an immiscible droplet with aqua in canola oil. Upper material: aqua; lower material: perfluorooctane (a). Upper material: silicone oil; lower material: aqua (b). The upper material immediately slid down the lower material after the picture was obtained (a, b).

supports the suggestion that the interfacial tension between PFO and SO is much less than that between aqua and PFO or SO, based on the "Neumann's triangle" theorem, which states that the three vectors of interfacial tension at a contact point among three immiscible liquids are in balance [13]. As a result, PFO and SO easily form an immiscible droplet due to their low interfacial tension.

In our case, after the vitrectomy for PFO and SO removal, no further recurrence of rhegmatogenous retinal detachment was recognized. The PFO-SO immiscible droplet in the vitreous cavity was able to completely and closely attach over the entire giant retinal tear due to the superficial smoothness. This close attachment might be the reason why recurrence of rhegmatogenous retinal detachment was not recognized after PFO and SO removal. If this theory is correct, then the effectiveness of double SO tamponade [14] might be due to the superficial smoothness of the standard SO-heavy SO immiscible droplet.

There are some limitations to our current study. The first is that we used aqua instead of a balanced salt solution (BSS) during our in vitro experiments, since the correct surface tension of BSS has yet to be identified. Since the surface tension for a salt solution is higher than that for distilled water [15], the use of a BSS would have led to a large difference in the surface tension relative to PFO or SO. Thus, the use of aqua did not influence the current results. Second, we did not examine the adhesion between PFO and the retinal surface. In general, the retinal surface is uneven due to the presence of retinal vessels, foveal depression, and optic disc. In addition, it is possible that individual differences in the retinal vessels might exist. Therefore, a correct examination of the adhesion between PFO and the retinal surface is difficult. In anyway, because PFCL can be easily removed, adhesion between PFCL and SO rather than that between PFCL and the retinal surface is important to resolve sticky SO.

4. Conclusions

In conclusion, sticky SO is composed of PFO and SO, which easily form an immiscible droplet due to their low interfacial tension.

Data Availability

The datasets generated and/or analyzed during the current study are not publicly available due to limitations of ethical approval involving the patient data and anonymity, but are available from the corresponding author on reasonable request.

Ethical Approval

This study was approved by the Ethics Committee of the Tokyo Rosai Hospital (IRB No. 02–10, September 23, 2020).

Consent

Written informed consent for publication was obtained from the patient.

Conflicts of Interest

The authors declare no conflicts of interest.

Acknowledgments

The authors thank Hiroyuki Naruke, Yuka Yanagisawa, and Yuka Kobayashi, orthoptists at Tokyo Rosai Hospital, for their helpful discussions.

References

[1] J. H. Dresp and D.-H. Menz, "The phenomenon of "sticky" silicone oil," *Graefe's Archive for Clinical and Experimental Ophthalmology*, vol. 245, no. 6, pp. 863–868, 2007.

[2] H. H. Ghoraba, A. G. Zaky, H. M. Abd Al Fatah, E. E. D. M. El Gemai, and M. A. Heikal, "Sticky silicone oil," *Retina*, vol. 37, no. 8, pp. 1599–1606, 2017.

[3] M. A. Veckeneer, S. de Voogd, E. W. Lindstedt, D.-H. Menz, and J. C. van Meurs, "An epidemic of sticky silicone oil at the Rotterdam Eye Hospital. Patient review and chemical analysis," *Graefe's Archive for Clinical and Experimental Ophthalmology*, vol. 246, no. 6, pp. 917–922, 2008.

[4] M. Fukumoto, Y. Nishida, T. Kida, T. Sato, T. Kobayashi, and T. Ikeda, "A case of silicone oil adhered to the retinal surface via perfluorocarbon liquid," *BMC Ophthalmology*, vol. 18, no. 1, p. 82, 2018.

[5] *PERFLUORON® Package Insert*, Alcon, Geneva, Switzerland, 4th edition, 2017.

[6] *SILIKONTM 1000 Ophthalmic Oil Package Insert*, Alcon, Geneva, Switzerland, 4th edition, 2019.

[7] R. G. Ackman and C. A. Eaton, "Specific gravities of rapeseed and canbra oils," *Journal of the American Oil Chemists' Society*, vol. 54, no. 10, p. 435, 1977.

[8] I. M. Hauner, A. Deblais, J. K. Beattie, H. Kellay, and D. Bonn, "The dynamic surface tension of water," *Journal of Physical Chemistry Letters*, vol. 8, no. 7, pp. 1599–1603, 2017.

[9] S. N. Sahasrabudhe, V. Rodriguez-Martinez, M. O'Meara, and B. E. Farkas, "Density, viscosity, and surface tension of five vegetable oils at elevated temperatures: measurement and modeling," *International Journal of Food Properties*, vol. 20, pp. 1965–1981, 2017.

[10] F. Barca, T. Caporossi, and S. Rizzo, "Silicone oil: different physical proprieties and clinical applications," *BioMed Research International*, vol. 2014, Article ID 502143, 2014.

[11] Y. Cong, W. Zhang, C. Liu, and F. Huang, "Composition and oil- water interfacial tension studies in different vegetable oils," *Food Biophysics*, vol. 15, no. 2, pp. 229–239, 2020.

[12] A. T. Tyowua, M. Targema, and B. P. Binks, "Comparison of vegetable oil- silicone oil interfacial tension data from the du Noüyring and spinning drop methods," *Nigerian Annals of Pure and Applied Sciences*, Maiden Edition of NAPAS, vol. 1, , pp. 209–213, 2018.

[13] H. Y. Erbil, *Surface Chemistry of Solid and Liquid Interfaces*, Blackwell Publishing, Oxford(UK), 2006.
[14] C. MacGregor, A. Jonas, A. Hanifudin, and J. Lochhead, "Ratios for double silicone oil endotamponade – in vitro observations may assist with ratio selection," *BMC Ophthalmology*, vol. 17, no. 1, p. 264, 2017.
[15] U. Paz and H. Rubin, "Surface tension observation in distilled and saline water interface," *Industrial & Engineering Chemistry Fundamentals*, vol. 9, no. 3, pp. 509–511, 1970.

Hindawi
Journal of Ophthalmology
Volume 2021, Article ID 8959153, 10 pages
https://doi.org/10.1155/2021/8959153

Review Article

Managing PVR in the Era of Small Gauge Surgery

Manish Nagpal,[1] **Rakesh Juneja**,[2] **and Sham Talati**[1]

[1]*Department of Retina and Vitreous, Retina Foundation, Ahmedabad, India*
[2]*Department of Retina and Vitreous, Juneja Superspeciality Eye Hospital, Bilaspur, Chhattisgarh, India*

Correspondence should be addressed to Manish Nagpal; drmanishnagpal@yahoo.com

Received 14 May 2021; Accepted 8 November 2021; Published 4 December 2021

Academic Editor: Alessandro Meduri

Copyright © 2021 Manish Nagpal et al. This is an open access article distributed under the Creative Commons Attribution License, which permits unrestricted use, distribution, and reproduction in any medium, provided the original work is properly cited.

Proliferative vitreoretinopathy (PVR) is the leading cause of failed rhegmatogenous retinal detachment (RRD) surgery. Based upon the presence of clinical features and due to associated underlying risk factors, it is classified into various grades based upon its severity and extent of involvement. Despite excellent skills, flawless techniques, and high-end technology applied in the management of RRD, PVR still occurs in 5–10% of cases. Due to the advancements in wide angle viewing systems, advance vitrectomy machines and fluidics, early identification, use of long-term heavy silicon oil tamponades, high-speed cutters, small-gauge vitrectomies, use of perfluorocarbon liquid (PFCL), and small-gauge forceps and scissors, the success rate in the management of PVR has increased leading to improved anatomical outcomes. However, functional outcomes do not correlate well with improved anatomical outcomes. Various complications occur after RRD repair that are responsible for re-retinal detachment and recurrence of PVR. This article highlights causes, risk factors, classification, grading, diagnosis, and approach to management of PVR and post-PVR surgery complications.

1. Introduction

In 1983, on the basis of "massive vitreous traction" or "massive periretinal proliferation," the Retina Society Terminology Committee put forward a classification and Proliferative Vitreoretinopathy (PVR) was identified as an independent clinical entity [1–4]. It leads to growth and contraction of cellular membranes within the vitreous cavity and on both sides of the retinal surface leading to intraretinal fibrosis and failed rhegmatogenous retinal detachment (RRD) repair surgery (Figure 1) [5, 6]. PVR can manifest in various ways like traction, wrinkling of retinal surfaces, rolled edges, starfolds, and retinal shortening. In the past 2–3 decades, even with the evolution of small-gauge and high cut rate vitrectomies, the overall incidence of PVR still remains the same ranging 5–10% as mentioned in literature by various studies causing 75 percent of all primary surgical failures [6–8]. Henceforth, it is very important to identify the development of PVR, the clinical signs, and subtle risk factors and intervene as early as possible for its management because despite best of the efforts and complex long duration surgery and efforts, majority of eyes suffer complications and low vision [9–11].

2. Pathophysiology

PVR develops through a very complex process that involves humoral and cellular factors. The retinal pigment epithelial (RPE) cells, glial cells, fibroblasts, and macrophages act as nidus for its pathogenesis [12]. The various risk factors lead to for membrane formation, ischemia, and subsequent cell death. Cell death triggers a break down in the blood-retinal barrier (BRB) thereby facilitating the influx of chemotactic and mitogenic factors that permit cell proliferation, migration, extracellular matrix deposition, and contraction. Cellular proliferation occurs due to inflammatory mediators and growth factors in vitreous [13–15]. Owing to the production of these pathogenic components, breakdown of BRB, along with retinal tears, and surrounding detachment, there occurs inwards movement of RPE and glial cells causing retinal contraction and other varied features of PVR. Gravity acts as a major factor causing settlement of migrated RPE cells along with other inflammatory mediators that is responsible for increased incidence of PVR in inferior RDs. All these underlying pathogenic mechanisms along with inflammation-induced apoptosis make PVR self-propagatory, complicating retinal detachment surgery leading to

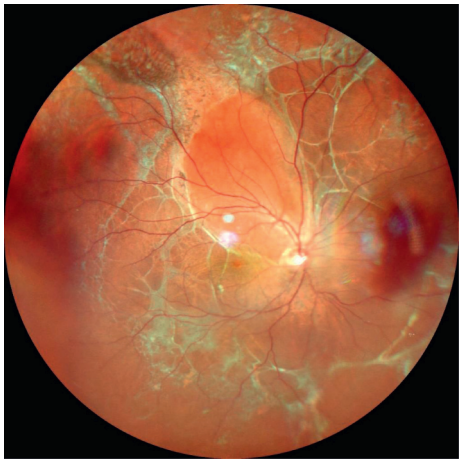

Figure 1: Wide-field color fundus photograph showing retinal detachment with multiple areas of intraretinal and subretinal fibrosis suggestive of proliferative vitreoretinopathy (PVR) changes.

blindness even after a successful uneventful retinal attachment surgery [16–20].

2.1. Causes, Risk Factors, and Clinical Signs for Diagnosis of PVR. PVR may be present spontaneously with primary retinal detachment or may develop even after retinal detachment surgery (Figure 2). Various causes and risk factors have been identified that if present can lead to increased incidence of PVR, few weeks to months after primary surgery. These include choroidal detachment, failed RRD surgery, or multiple retinal surgeries, aphakia, vitreous hemorrhage, high vitreous protein levels, positive smoking history, preoperative retinal folds, horseshoe retinal tears exposing three disc diameters or more of RPE, uveitis, giant retinal tear, intra/postoperative hemorrhage, retinectomy, cryopexy, extensive laser, and injection of air [21–27]. These ignite the cascade of events by igniting movement of RPE cells into vitreous cavity leading to complex pathogenic mechanism resulting in formation of membrane that eventually tends to contract causing PVR complication. The presence of these risk factors during pre-, intra-, or postoperative period warrants the need of a close followup to enable early detection of PVR and needful intervention.

Initially preretinal PVR adopts an immature appearance and consistency. Later on, by 6 to 8 weeks, the membrane becomes more mature, taking on a white, fibrotic appearance. In this stage, PVR can be easily seen clinically and causes retina to become stiff and immobile [28, 29]. These membranes tend to contract over a period of time causing wrinkling, folds, local contraction, and rolled posterior edges (Figure 3). With time, these membranes tend to become more severe causing fixed rigid folds "starfolds" more predominantly in inferior quadrants and tend to bridge with each other further reducing the mobility of retina (Figure 4). Eventually it progresses posteriorly and with PVD leads to formation of advanced PVR causing retina to acquire a funnel shaped appearance (Figure 5).

Various tools in the form of slit lamp biomicroscopy and indirect ophthalmoscopy along with the use of various lenses

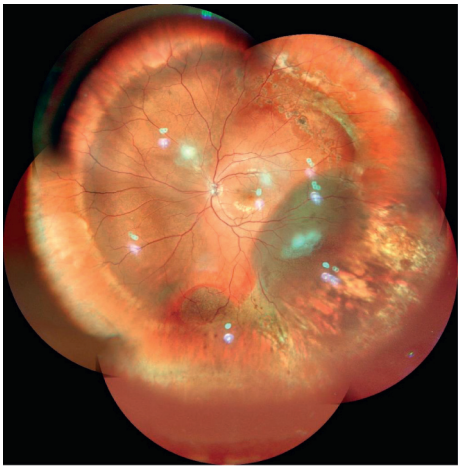

Figure 2: Montage color photograph showing inferotemporal subretinal fluid suggestive of recurrent retinal detachment with attached macula and buckle indentation effect status after buckle surgery.

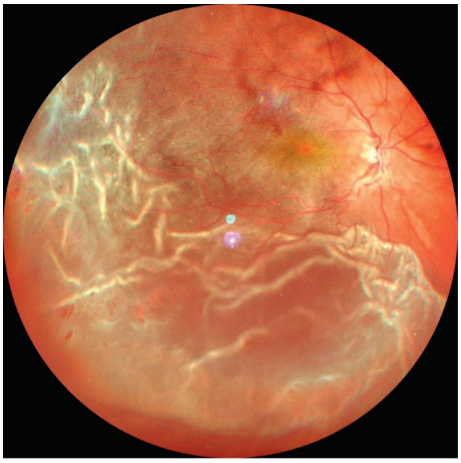

Figure 3: Wide-field color fundus photograph showing retinal detachment with wrinkling of retinal surface (PVR grade B) and multiple retinal breaks seen temporally.

in eyes with clear media and using B-scan in cases of opaque media help in the diagnosis of PVR along with various risk factors. It helps in meticulous planning of surgical approach. Early intervention is better as PVR often leads to substantial vision loss and a poor visual outcome.

2.2. Classification of PVR. In 1983, PVR as a significant clinical entity was noted and a classification for grading of PVR was put forward by the Retina Society Terminology Committee [30–32]. It was initially the most widely used grading system based on clinical signs and geographical distribution pattern. It had numerous limitations. It failed to take into account the anteroposterior epiretinal proliferation and degree of cellular proliferation. In 1989, Silicone Study classification expanded the initial contributions by incorporating (1) membrane location, (2) clinical severity, and (3) membrane geometry [33]. It was difficult to be used in

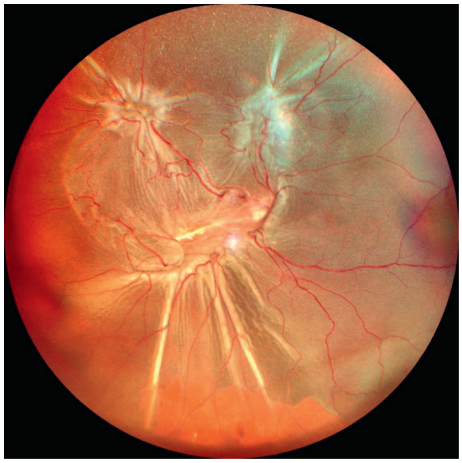

Figure 4: Wide-field color fundus photograph showing total retinal detachment fixed retinal folds suggestive of PVR grade C.

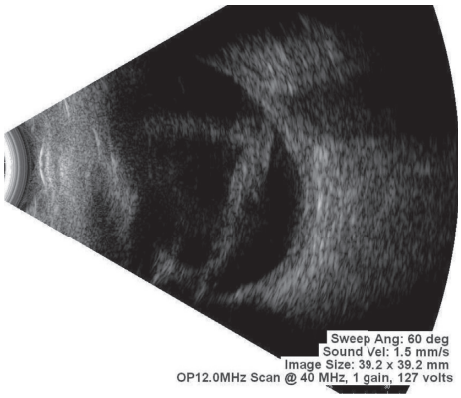

Figure 5: Ultrasonography (B-scan) report suggestive of membranous echoes in vitreous cavity with restricted movements and attachment to optic disc is suggestive of open funnel retinal detachment.

clinical practice and moreover it failed to offer a significant advantage in terms of decision making with regards to treatment. Hence, in 1991, a revised classification was put forward by Machemer et al. [34], which took into consideration more factors while grading the severity of PVR and was widely accepted. It is very essential to classify and grade PVR as it helps in better planning and management of PVR.

2.3. Prevention of PVR. The most important aspect to prevent development of PVR is the early identification of various risk factors that are held responsible. The key feature is to pick up early various subtle signs and along with increased awareness that can help surgeon to modify the plan of management thus helping to prevent this serious complication. If early PVR is noted, it is better to proceed with combined scleral buckling and vitrectomy rather than a single procedure of the two, along with the use of long-term heavy silicon oil tamponades.

2.4. Diagnosis of PVR. Broadly PVR can be divided into two groups: (1) preexisting with rhegmatogenous retinal detachment (RRD). This is seen usually with long standing RRDs. (2) PVRs that occur after primary surgery for RRDs: this usually occurs after a period of 4–6 weeks of initial surgery. Initially retina seems attached with some visual gain which later tends to deteriorate with the development of PVR. During examination, PVR is identified by retinal traction caused by retinal membranes. In most of the cases of PVR, inferior retina is affected more due to gravity-based deposition of RPE cells. Vitreous haze along with the release of pigment cells in vitreous cavity and over the surface of retina can be seen. Posterior PVR is detected by starfolds with folds radiating from a central area of contracted retina, and more diffuse folds and later on subretinal membranes are also seen beneath the retina. These folds may even take an annular configuration pulling the retina over the optic disc [29]. Membranes may be circumferential at or posterior to the vitreous base. With contraction at the posterior edge of the vitreous base, the anterior retina may be stretched centrally while the posterior retina is thrown into radial folds extending from the vitreous base posteriorly.

2.5. Diagnostic Procedures for PVR. Diagnosis of the presence of PVR and its grading based on available classification systems is done with the help of indirect ophthalmoscopy examination with +20D lens. A thorough examination of retina is conducted and grading of PVR is done with the aid of retinal drawing. This can be done in presence of clear media allowing clear view of retina. However, in presence of media opacity obscuring view of retina and henceforth, disabling retinal examination, B-scan is the preferred diagnostic tool. Examiner asks patients to move their eyes while performing B-scan to identify the mobility of detached retina. In the absence of PVR, in a case of RRD, the retina has good mobility on B-scan. In a case of RRD with PVR, the flaps of the retina may assume a "V" pattern at the optic disc with very limited retinal mobility as they approach the optic nerve (open funnel retinal detachment) (Figure 5). With more severe PVR, the retina may assume a "T" pattern on ultrasound at the optic disc (closed funnel retinal detachment) with the detached flaps of retina fused together anterior to the disc, only opening more anterior to the disc with the anterior immobile retina completing the top bar of the "T" (Figure 6).

2.6. Surgery for PVR. The mainstay for management of PVR is surgical intervention. With the evolution of surgical techniques, better instruments, fluidics, facilities, wide angle viewing systems, small-gauge vitrectomies, and heavier silicon oil tamponades, there is a significant rise in success rate of PVR surgeries. PVR may present with single clinical feature or multiple features in different cases. There may be only a starfold at a single location, fixed membranes leading to funnel shaped retina, immobility of retina, contraction, and retinal stiffening and shortening. The main goal of management is to relieve the traction and to reattach the retina. However, in cases with severe PVR, additional maneuvers are required to relieve traction in order to reattach the retina and prevent redetachment [6, 7, 35]. These goals

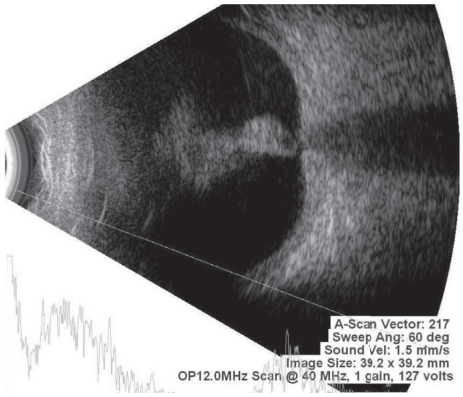

Figure 6: Ultrasonography (B-scan) report suggestive of membranous echoes in vitreous cavity with restricted movements and firm attachment to optic disc (T-pattern) is suggestive of closed funnel retinal detachment.

can be better achieved with the help of a combined and meticulously done scleral buckle and vitrectomy with long-term silicon oil tamponade and also to prevent retinal redetachment and recurrence of PVR to as much extent as possible [36, 37].

Although vitrectomy with removal of entire remnant vitreous, posterior hyaloid, and fibrinous and cellular elements causing traction is the core concept in management of PVR, scleral buckling also has a significant role when treating PVR detachments. Scleral buckles relieve both anteroposterior traction and circumferential traction. In a case of RRD with PVR, encircling bands that support the entire vitreous base are more useful than segmental elements and are frequently used along with PPV [6]. However, Yao et al. in their study have reported to achieve high rates of anatomic success using scleral buckling alone in chronic detachments with PVR [38].

Many surgeons believe and have also published in literature that vitrectomy along with silicon oil is enough for the management of PVR [39]. However, there is enough evidence in literature that suggests that a combined vitrectomy with silicon oil tamponade along with scleral buckling gives better results and higher success rate. Vitrectomy directly allows the surgeon the access to the entire pathological insult going in the removal of, proliferating, and migrating epithelial cells, blood, fibroblast, peeling of membranes causing traction, folds, wrinkling, shortening, and contraction of retina. With the availability and worldwide use of wide angle viewing systems, advanced fluidics, phacoemulsification techniques for the management of lens with IOL implantation, use of direct and indirect contact lenses that enable a very wide crisp panoramic view of retina, small-gauge vitrectors, high-speed cut rates allowing less traction and no incarceration of retina, heavy silicon oil for adequate tamponade, heavy liquids perfluoro-n-octane carbon liquid which is heavier than water (PFCL) causing displacement of subretinal fluid, fiber-optic chandelier illumination allowing access to periphery in great details with bimanual approach to surgeon, small-gauge advance sharp, versatile forceps and scissors allowing smooth bimanual dissection, use of active aspiration by small-gauge soft tip cannulas, and membrane scrappers, the success rate in the management of complex PVRs has gone up to a significant extent.

For PVR surgery, either local or general anesthesia is acceptable. However, owing to prolonged duration of surgery, also based on type and grade of PVR, present and various other patient related factors, and the comfort of the surgeon and the patient, the type of anesthesia is decided as per case.

After a thorough meticulous examination, the severity and stage of PVR are judged, and the approach is planned. The approach consisting of combined scleral buckle with vitrectomy gives more effective outcomes. If a scleral buckle is planned, conjunctiva is opened by limbal peritomy and an encircling 360° scleral buckle is put (Figure 7). Usually to provide long-term support, narrower bands are preferred. Once the scleral buckle part is done, 4 port pars plana entry is done by 23- or 25-gauge trocar cannula. Infusion is attached at the inferotemporal quadrant and superonasal and superotemporal ports are used for endoillumination and cutter. The 4th port is placed based on surgeons' choice as per need of the case for chandelier illumination in order to obtain a good panoramic view and allow the surgeon to perform bimanual surgery at ease (Figure 8). Care needs to be taken to avoid pars ciliaris entry and surgeon should ensure proper entry in vitreous cavity and to avoid entry into suprachoroidal or subretinal space.

One should definitely try that natural lens should be preserved. The natural lens always tends to become cataractous with silicon oil and later can be comfortably removed as a separate procedure or during a combined sitting with silicon oil removal. But, if the cataract is significant enough obscuring the view during retina surgery, it needs to be removed along with retina surgery. Removal of lens along with retina surgery also allows good and thorough shaving of vitreous base. Lens can be removed either by phacoemulsification/small incision cataract surgery of pars plana lensectomy with or without IOL implantation based upon the situation (Figure 9). One must do an inferior iridotomy if IOL is not implanted in the same sitting and the patient is left aphakic to avoid silicon oil coming in contact with corneal endothelium [40].

After dealing with lens and obtaining a clear view of retina, meticulous removal of vitreous is done along with the removal of posterior hyaloid. Intravitreal injection of triamcinolone acetonide helps in identification of vitreous to avoid any remnant vitreous and posterior hyaloid (Figure 10). 23-gauge vitrectomy is the system of choice as it allows ease of access to the entire vitreous base with good fluidics and a sutureless postoperative closure. With the aid of high-speed vitrectomy cutters and scleral depressors, base shaving is also done clearly with minimal to no vitreous incarceration after stabilizing the posterior pole with PFCL by displacing subretinal fluid (Figure 11).

Once the vitreous is removed, it is extremely important to remove all folds, wrinkling, and contraction by identifying the membranes that are responsible for causing them which can be facilitated by using brilliant blue dye (BBD). BBD

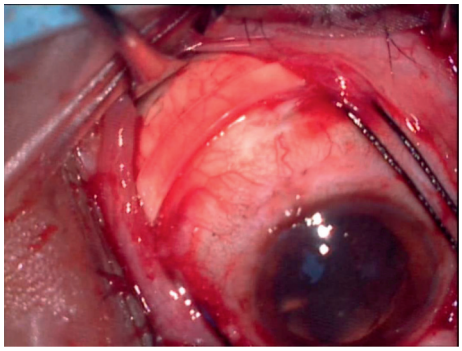

Figure 7: Intraoperative image showing 240 mm encircling silicon band placed underneath conjunctiva which is applied 360 degrees to give support to vitreous base.

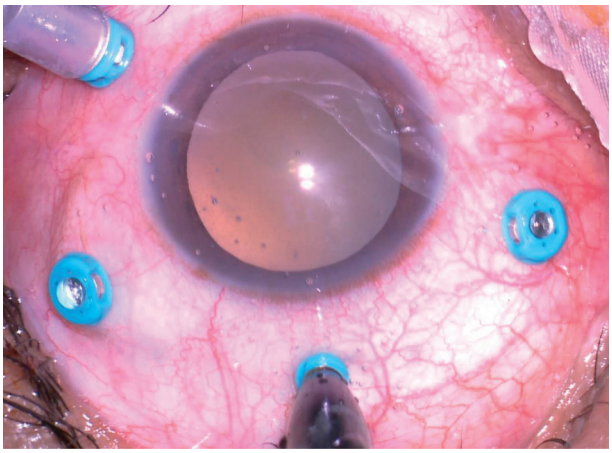

Figure 8: Intraoperative image showing 25 G chandelier illumination placed at 12 o'clock along with other three 25 G cannulas placed in superonasal, superotemporal, and inferotemporal quadrants.

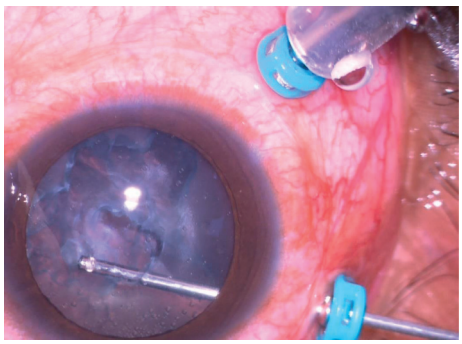

Figure 9: Intraoperative image showing pars plana lensectomy being done with the help of a 25 G vitrectomy cutter.

helps to stain the membranes that can be peeled by forceps or trimmed with cutter as per situation. It is very important to identify all membranes and to remove them all, to enable retina to become mobile again (Figure 12). Due care should be taken that PFCL should not go subretinal through open breaks/tears. It can happen if membranes are still persisting preventing complete flattening of retina.

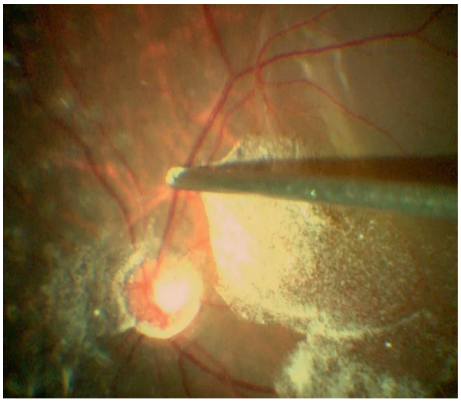

Figure 10: Intraoperative image showing triamcinolone-assisted posterior vitreous detachment (PVD).

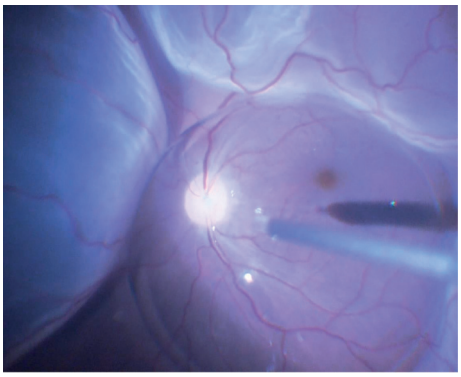

Figure 11: Intraoperative image showing injection of perfluoro carbon liquid (PFCL) stabilizing the posterior pole and pushing the subretinal fluid in the periphery in a case of bullous retinal detachment.

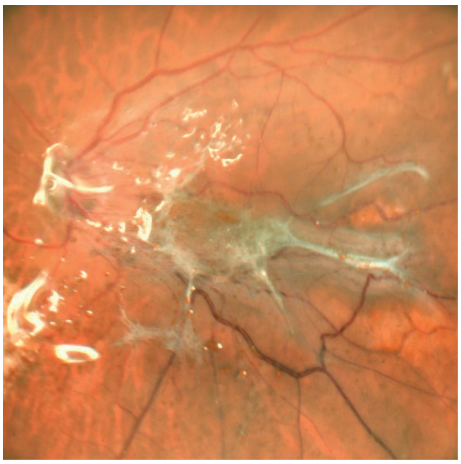

Figure 12: Central color fundus photograph showing Macular Pucker in a case of silicon oil-filled vitrectomized eye which was operated on for retinal detachment with proliferative vitreoretinopathy changes.

In long-standing PVRs, subretinal bands are noted that prevent retinal flattening even after meticulous removal of all preretinal and retinal surface membranes. This warrants

the need of a small retinectomy and removal of these bands assisted with forceps. Once all subretinal bands are removed and even after that retina fails to flatten due to severe contraction or shortening owing to chronicity or long-standing contraction, then retinectomy is needed to achieve retinal flattening. Small-gauge soft tip cannulas are inserted into retinectomies or breaks and subretinal fluid is aspirated by active suction along with fluid-air exchange enabling the surgeon to achieve retinal flattening [41–50].

After retinal flattening, chorioretinal apposition is needed which is done by a good endolaser photocoagulation around all the breaks, retinotomies, and retinectomies followed up at 360° endolaser barrage around the peripheral retina (Figure 13). Excessive laser and heavy burns should be avoided as they may act as precursor of re-PVR and recurrence. Laser is preferred over cryotherapy as cryo leads to excessive inflammation, more complications leading to cellular proliferation, and risk of recurrence of PVR. In certain situations where laser photocoagulation cannot be performed then cryo will serve the purpose of chorioretinal adhesion. Inability to achieve visible laser burns signifies that retinal flattening is still not achieved [50].

Once all breaks are sealed with laser, next step involves the use of a tamponade. Although both gas and silicon oil can be used as tamponading agents, out of both, silicon oil provides long-term and more adequate tamponade in PVRs. Literature suggests that most surgeons prefer silicon oil as tamponade in the management of PVR. The use of gas is associated with restricted air travel and risk of ocular hypertension and an inadequate tamponade leading to more chances of recurrence [51, 52]. Some surgeons prefer direct PFCL-silicon oil exchange but the majority usually prefer fluid-air-silicon oil exchange. Silicon oil is injected with a pressure-assisted delivery system along with the use of a silicon oil tip cannula. Once silicon oil is injected, the infusion pressure is reduced to maintain appropriate intraocular pressure. Once silicon oil touches the sclerotomy port, it pushes the residual air out of the eye and then silicon oil is further injected keeping a close watch on intraocular pressure, as it should be adequate enough.

Various less viscous forms of standard silicon oil are available like 1000, 1300, and 1500 cSt (centistokes). Slightly more viscous form 5000 cSt is also available. Few surgeons prefer less viscous form and few surgeons more viscous form. However, if the breaks are not well closed and residual traction is still present, the oil of any viscosity will seep through and enter into subretinal space through open breaks. The standard silicon oils are lighter than water.

Standard silicon oils fail to provide perfect apposition between oil bubble and peripheral inferior retina causing a gap, which can get filled with proliferating residual cells and debris and leading to recurrence more commonly involving inferior retina. This condition can be avoided by use of heavy fluorinated silicon oil which provides a better tamponade particularly after inferior relaxing retinectomy. However, long-term retention side effects of heavy fluorinated silicon oil are yet known, so they are preferably removed within a time frame of 3 months [53–66]. Once surgery is done, dilute injection of antibiotic is injected in subtenon's space along with anesthetic agent to counter postoperative pain and infection. Conjunctiva is closed if initial peritomy was done for scleral buckle.

Usually within an interval of 3 to 6 months based on various factors along with scar maturity, silicon oil removal is done. Long-term retention may lead to certain unwanted complications. However, after silicon oil removal, there is a significant risk of retinal redetachment [67]. Despite a successful surgery with good retinal flattening, many eyes have a poor visual potential and multiple surgeries may be needed if recurrence is noted [68–70]. Cataract almost always occurs with the use of silicon oil and at times oil gets emulsified leading to glaucoma and requires urgent removal. Band keratopathy may occur even if silicon oil is confined in vitreous. Silicon oil removal is carried out as a separate operating procedure in which silicon oil removal is done with a pressure-assisted silicon oil tip cannula by high-pressure active aspiration using advance modern vitrectomy machines (Figure 14). The vitreous compartment is filled with either air or saline as postoperative tamponade [71].

2.7. Management after Surgery for PVR. Postoperative prone positioning is advised for approximately 10 hours a day for the first 1 week, which can later be reduced to 4–6 hours/day for the next 3 weeks. The idea behind this is to egress out any residual subretinal fluid by retinal pigment epithelium pump mechanism and to promote chorioretinal adhesion leading to retinal scar formation at the site of laser. Postoperative intraocular pressure rise can be seen which needs immediate intervention by oral and topical antiglaucoma medications to avoid any damage to optic nerve and associated pain. Most common cause of raised intraocular pressure is the overfill of silicon oil and at times if medications fail to bring down pressure to a desired value, then a small volume of oil needs to be aspirated out surgically. The cycloplegics, antibiotics, and anti-inflammatory drugs keep a check on postoperative infection and inflammation.

2.8. Complications following Surgery for PVR. Management of PVR is complex and even after a successful retinal attachment complications can occur and patients along with relatives need to be informed along with a written informed consent preoperatively about possible complications. Some intraoperative complications that can occur include bleeding, corneal edema, pupillary constriction, lens clouding, subretinal migration of PFCL and/or oil, gas, choroidal detachment, and choroidal bleeding. Intraoperative bleeding during surgery can be managed by raising the infusion pressure or by applying cautery at the site of bleeding for few minutes to allow clot formation and bleeding to stop. Corneal edema or opacification can develop due to prolonged contact of viscous material and needs epithelial debridement allowing clear visualization during surgery. Pupillary constriction can be managed by use of intraoperative intracameral use of dilating agents or cutting the synechiae or membrane, which is causing obscuration of view. Lens clouding or opacification due to a preexisting significant cataract or due to intraoperative lens touch needs

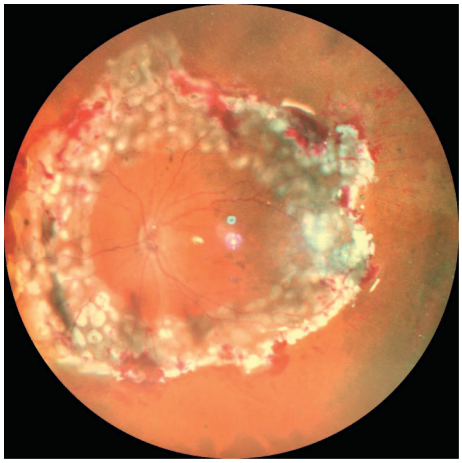

Figure 13: First day postoperative image showing 360-degree lasered retina in a case of extensive PVR.

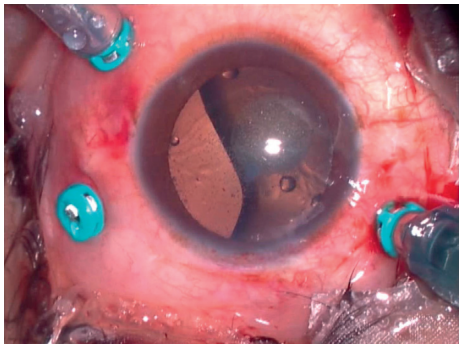

Figure 14: Intraoperative image showing silicon oil removal being done with 25G vitrectomy system.

lensectomy or a planned cataract surgery by phacoemulsification or small incision cataract surgery with or without IOL implantation. Subretinal migration of PFCL or oil needs to be approached by making a small meticulous retinotomy and drainage. Choroidal detachment usually happens due to wrong placement of cannula into suprachoroidal space and is managed by securing infusion line through a separate cannula and reinserting misplaced cannula into vitreous cavity.

A close followup is vital as immediate postoperative complications include ocular hypertension, pupillary block glaucoma, shallowing and closure of the anterior chamber, intraocular inflammation, subretinal hemorrhage, and silicon oil in the anterior chamber. Ocular hypertension needs immediate intervention with anti-glaucoma medications. If medical management fails to lower the intraocular pressure, it usually happens due to silicon oil overfill and some amount of oil needs to be extruded to maintain the desired pressure level. Other complications also may need immediate surgical intervention if causing pain and raised intraocular pressure as they may vision threatening and may lead to permanent vision loss.

Late complications of PVR surgery include regrowth of membranes causing traction, opening of old breaks, formation of new breaks, recurrent retinal detachment

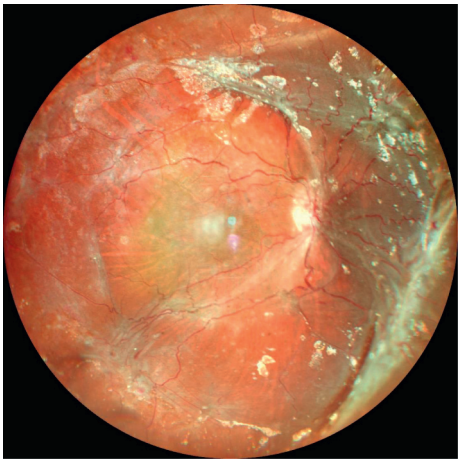

Figure 15: Widefield color fundus photograph showing reretinal detachment under silicon oil in a case of pars plana vitrectomy done for retinal detachment with PVR.

(Figure 15), glaucoma due to emulsified silicon oil, corneal endothelium damage due to silicon oil in anterior chamber leading to band keratopathy, cataract due to silicon oil touch, hypotony-phthisis, squint, double vision due to scleral buckle, infection of scleral buckle, and macular pucker (Figure 12) [72, 73]. For regrowth of membranes and macular pucker, resurgery needs to be planned. Staining is vital to identify any new membranes of remnant ones causing traction and PVR clinical features. Once identified, these membranes need to be peeled to allow retina settle again. Peeling of internal limiting membrane should be done after staining to avoid recurrence of macular pucker. Any new breaks or old opened breaks should be managed by adequate endolaser photocoagulation after settling the retina. Removal of silicon oil is important especially if it is migrating to anterior chamber or causing endothelial toxicity by silicon oil removal surgery. Band-keratopathy needs scraping of cornea along with the application of chelating agent EDTA. In case of a scleral buckle infection or extrusion, surgeon must plan to immediately remove scleral buckle under the cover of antibiotics to prevent further spread of infection. Glaucoma is managed with topical antiglaucoma medications or surgery, and for others reretinal surgery is usually needed and more often leading to very poor visual outcome. All these complications are visually fatal and need to be addressed immediately.

2.9. Results of PVR Surgery. Over the past few decades with advancement in techniques, instrumentation, and machines, the success ratio in anatomical management of PVR has increased a lot. Still, many eyes undergo redetachment that requires resurgery. Once macula is detached for more than few days, it is unlikely to recover more than 10–20% of central vision. Henceforth, anatomical success in terms of successful retinal attachment for a period of 6 months cannot be compared as equivalent to functional success [20]. Prolonged duration of PVR or a more severe PVR indicates that visual potential is lost. Despite the best efforts, visual prognosis remains very poor.

3. Conclusion

PVR is the leading cause for failure of RRD repair and is identified by the growth and contraction of cellular membranes within the vitreous cavity and on both sides of the retinal surface leading to retinal contraction and fixed starfold formation. Various risk factors have been identified that lead to PVR formation. Despite the best of machines, advances in techniques, instrumentation, and the increased success rate in terms of anatomical reattachment, the real meaningful long-term stable successful visual outcome is yet not achieved and many eyes in long course tend to suffer severe vision loss. Medical therapy is also tried but to date no real success. However, we may hope that, with the continual advancements in techniques and technology going on, some way of restoring long-term meaningful visual potential may soon arrive in the medical world.

Data Availability

No data were used to support this study.

Conflicts of Interest

The authors declare that they have no conflicts of interest.

References

[1] G. Hilton, R. Machemer, R. Michels, E. Okun, C. Schepens, and A. Schwartz, "The classification of retinal detachment with proliferative vitreoretinopathy," *Ophthalmology*, vol. 90, no. 2, pp. 121–125, 1983.

[2] W. H. Havener, "Massive vitreous retraction," *International Ophthalmology Clinics*, vol. 16, no. 1, pp. 135–155, 1976.

[3] R. Machemer, "Pathogenesis and classification of massive periretinal proliferation," *British Journal of Ophthalmology*, vol. 62, no. 11, pp. 737–747, 1978.

[4] J. D. Scott, "The treatment of massive vitreous retraction by the separation of pre-retinal membranes using liquid silicone," *Modern Problems in Ophthalmology*, vol. 15, pp. 185–190, 1975.

[5] M. Nagpal, P. Chaudhary, S. Wachasundar, A. Eltayib, and A. Raihan, "Management of recurrent rhegmatogenous retinal detachment," *Indian Journal of Ophthalmology*, vol. 66, no. 12, pp. 1763–1771, 2018.

[6] J. C. Pastor, "Proliferative vitreoretinopathy," *Survey of Ophthalmology*, vol. 43, no. 1, pp. 3–18, 1998.

[7] J. C. Pastor, E. R. de la Rúa, and F. Martín, "Proliferative vitreoretinopathy: risk factors and pathobiology," *Progress in Retinal and Eye Research*, vol. 21, no. 1, pp. 127–144, 2002.

[8] S. Pennock, L. J. Haddock, S. Mukai, and A. Kazlauskas, "Vascular endothelial growth factor Acts primarily via platelet-derived growth factor receptor α to promote proliferative vitreoretinopathy," *American Journal Of Pathology*, vol. 184, no. 11, pp. 3052–3068, 2014.

[9] D. G. Charteris, C. S. Sethi, G. P. Lewis, and S. K. Fisher, "Proliferative vitreoretinopathy-developments in adjunctive treatment and retinal pathology," *Eye*, vol. 16, no. 4, pp. 369–374, 2002.

[10] W. Tseng, R. T. Cortez, G. Ramirez, S. Stinnett, and G. J. Jaffe, "Prevalence and risk factors for proliferative vitreoretinopathy in eyes with rhegmatogenous retinal detachment but no previous vitreoretinal surgery," *American Journal of Ophthalmology*, vol. 137, no. 6, pp. 1105–1115, 2004.

[11] H. Heimann, K. U. Bartz-Schmidt, N. Bornfeld, C. Weiss, R.-D. Hilgers, and M. H. Foerster, "Scleral buckling versus primary vitrectomy in rhegmatogenous retinal detachment," *Ophthalmology*, vol. 114, no. 12, pp. 2142–2154, 2007.

[12] M. M. Rodrigues, D. A. Newsome, and R. Machemer, "Further characterization of epiretinal membranes in human massive periretinal proliferation," *Current Eye Research*, vol. 1, no. 6, pp. 311–315, 1981.

[13] F. Morescalchi, S. Duse, E. Gambicorti, M. R. Romano, C. Costagliola, and F. Semeraro, "Proliferative vitreoretinopathy after eye injuries: an overexpression of growth factors and cytokines leading to a retinal keloid," *Mediators of Inflammation*, vol. 2013, Article ID 269787, 12 pages, 2013.

[14] D.-Y. Yu and S. J. Cringle, "Oxygen distribution and consumption within the retina in vascularised and avascular retinas and in animal models of retinal disease," *Progress in Retinal and Eye Research*, vol. 20, no. 2, pp. 175–208, 2001.

[15] S. G. Elner, V. M. Elner, H. M. Freeman, F. I. Tolentino, and D. M. Albert, "The pathology of anterior (peripheral) proliferative vitreoretinopathy," *Transactions of the American Ophthalmological Society*, vol. 86, pp. 330–353, 1988.

[16] C. Guidry, "The role of Müller cells in fibrocontractive retinal disorders," *Progress in Retinal and Eye Research*, vol. 24, no. 1, pp. 75–86, 2005.

[17] Y. Hui, Y. Shi, and X. Zhang, "TNF-alpha, IL-8 and IL-6 in the early inflamma- tory stage of experimental PVR model induced by macrophages," *Zhonghua Yan Ke Za Zhi*, vol. 35, pp. 140–143, 1999.

[18] A. K. Singh, B. M. Glaser, M. Lemor, and R. G. Michels, "Gravity-dependent distribution of retinal pigment epithelial cells dispersed into the vitreous cavity," *Retina*, vol. 6, no. 2, pp. 77–80, 1986.

[19] I. El Ghrably, D. G. Powe, and G. Orr, "Apoptosis in proliferative vitreoretinopathy," *Investigative Ophthalmology & Visual Science*, vol. 45, no. 5, pp. 1473–1479, 2004.

[20] E. Doyle, E. N. Herbert, C. Bunce, T. H. Williamson, and D. A. H. Laidlaw, "How effective is macula-off retinal detachment surgery. Might good outcome be predicted?" *Eye*, vol. 21, no. 4, pp. 534–540, 2007.

[21] C. H. Kon, R. H. Asaria, N. L. Occleston, P. T. Khaw, and G. W. Aylward, "Risk factors for proliferative vitreoretinopathy after primary vitrectomy: a prospective study," *British Journal of Ophthalmology*, vol. 84, no. 5, pp. 506–511, 2000.

[22] H. Nagasaki, K. Shinagawa, and M. Mochizuki, "Risk factors for proliferative vitreoretinopathy," *Progress in Retinal and Eye Research*, vol. 17, no. 1, pp. 77–98, 1998.

[23] D. Eliott, T. P. Stryjewski, M. T. Andreoli, and C. M. Andreoli, "Smoking is a risk factor for proliferative vitreoretinopathy after traumatic retinal detachment," *Retina*, vol. 37, no. 7, pp. 1229–1235, 2017.

[24] K. Xu, E. K. Chin, S. R. Bennett et al., "Predictive factors for proliferative vitreoretinopathy formation after uncomplicated primary retinal detachment repair," *Retina*, vol. 39, no. 8, pp. 1488–1495, 2019.

[25] A. H. Chignell, L. G. Fison, E. W. Davies, R. E. Hartley, and M. F. Gundry, "Failure in retinal detachment surgery," *British Journal of Ophthalmology*, vol. 57, no. 8, pp. 525–530, 1973.

[26] M. Bonnet, "Clinical factors predisposing to massive proliferative vitreoretinopathy in rhegmatogenous retinal detachment," *Journal of French Ophtalmology*, vol. 17, pp. 530–540, 1994.

[27] M. Cowley, B. P. Conway, P. A. Campochiaro, D. Kaiser, and H. Gaskin, "Clinical risk factors for proliferative vitreoretinopathy," *Archives of Ophthalmology*, vol. 107, no. 8, pp. 1147–1151, 1989.

[28] R. B. Wilkins and D. R. Kulwin, "Wound healing," *Ophthalmology*, vol. 86, no. 4, pp. 507–510, 1979.

[29] J. T. Thompson, "Proliferative vitreoretinopathy," in *Retina*, S. J. Ryan, Ed., Mosby, St. Louis, MO, USA, pp. 2283–2309, 2006.

[30] No authors listed, "The classification of retinal detachment with proliferative vitreoretinopathy," *Ophthalmology*, vol. 90, pp. 121–125, 1983.

[31] J. C. Pastor, M. C. Méndez, M. A. de la Fuente et al., "Intraretinal immunohistochemistry findings in proliferative vitreoretinopathy with retinal shortening," *Ophthalmic Research*, vol. 38, no. 4, pp. 193–200, 2006.

[32] D. G. Charteris, J. Downie, G. W. Aylward, C. Sethi, and P. Luthert, "Intraretinal and periretinal pathology in anterior proliferative vitreoretinopathy," *Graefe's archive for clinical and experimental ophthalmology = Albrecht von Graefes Archiv fur klinische und experimentelle Ophthalmologie*, vol. 245, no. 1, pp. 93–100, 2007.

[33] J. S. Lean, W. H. Stern, A. R. Irvine et al., "Classification of proliferative vitreoretinopathy used in the silicone study," *Ophthalmology*, vol. 96, no. 6, pp. 765–771, 1989.

[34] R. Machemer, T. m. Aaberg, H. M. Freeman, R. I. Alexander, S. L. John, and M. M. Ronald, "An updated classification of retinal detachment with proliferative vitreoretinopathy," *American Journal of Ophthalmology*, vol. 112, no. 2, pp. 159–165, 1991.

[35] R. E. Coffee, L. Jiang, and S. A. Rahman, "Proliferative vitreoretinopathy," *International Ophthalmology Clinics*, vol. 54, no. 2, pp. 91–109, 2014.

[36] R. G. Michels, "Surgery of retinal detachment with proliferative vitreoretinopathy," *Retina*, vol. 4, no. 2, pp. 63–83, 1984.

[37] T. M. Aaberg Sr, "Surgery as the primary management of proliferative vitreoretinopathy," *Archives of Ophthalmology*, vol. 128, no. 8, pp. 1068–1070, 2010.

[38] Y. Yao, L. Jiang, Z.-j. Wang, and M.-n. Zhang, "Scleral buckling procedures for longstanding or chronic rhegmatogenous retinal detachment with subretinal proliferation," *Ophthalmology*, vol. 113, no. 5, pp. 821–825, 2006.

[39] T. Oyagi and K. Emi, "Vitrectomy without scleral buckling for proliferative vitreoretinopathy," *Retina*, vol. 24, no. 2, pp. 215–218, 2004.

[40] W. H. Beekhuis, F. Ando, R. Zivojnovic, D. A. Mertens, and E. Peperkamp, "Basal iridectomy at 6 o'clock in the aphakic eye treated with silicone oil: prevention of keratopathy and secondary glaucoma," *British Journal of Ophthalmology*, vol. 71, no. 3, pp. 197–200, 1987.

[41] C. Furino, T. M. Ferrari, F. Boscia, N. Cardascia, N. Recchimurzo, and C. Sborgia, "Triamcinolone-assisted pars plana vitrectomy for proliferative vitreoretinopathy," *Retina*, vol. 23, no. 6, pp. 771–776, 2003.

[42] J. B. Jonas, A. Söfker, J. Hayler, and R. F. Degenring, "Intravitreal crystalline triamcinolone acetonide as an additional tool in pars plana vitrectomy for complicated proliferative vitreoretinopathy?" *Acta Ophthalmologica Scandinavica*, vol. 81, no. 6, pp. 663–665, 2003.

[43] D. Tognetto, S. Zenoni, G. Sanguinetti, C. Haritoglou, and G. Ravalico, "Staining of the internal limiting membrane with intravitreal triamcinolone acetonide," *Retina*, vol. 25, no. 4, pp. 462–467, 2005.

[44] E. H. Bovey, E. De Ancos, and M. Gonvers, "Retinotomies of 180° or more," *Retina*, vol. 15, no. 5, pp. 394–398, 1995.

[45] F. Metge, P. Massin, and A. Gaudric, "Retinectomies in the treatment of retinal detachments with vitreoretinal proliferation," *Journal Français D'Ophtalmologie*, vol. 20, pp. 345–349, 1997.

[46] A. K. E. Lim, S. M. Alexander, and K. S. Lim, "Combined large radial retinotomy and circumferential retinectomy in the management of advanced proliferative vitreoretinopathy," *Retina*, vol. 29, no. 1, pp. 112–116, 2009.

[47] M. Nagpal, *Outcomes of Retinectomy of 180° or More in Retinal Detachment with Advanced Proliferative Vitreoretinopathy*, 2011.

[48] R. Machemer, "Surgical approaches to subretinal strands," *American Journal of Ophthalmology*, vol. 90, no. 1, pp. 81–85, 1980.

[49] H. Lewis, T. M. Aaberg, G. W. Abrams, H. R. McDonald, G. A. Williams, and W. F. Mieler, "Subretinal membranes in proliferatlve vitreoretinopathy," *Ophthalmology*, vol. 96, no. 9, pp. 1403–1415, 1989.

[50] D. W. Parke and T. M. Aaberg, "Intraocular argon laser photocoagulation in the management of severe proliferative vitreoretinopathy," *American Journal of Ophthalmology*, vol. 97, no. 4, pp. 434–443, 1984.

[51] M. Gonvers, "Temporary silicone oil tamponade in the management of retinal detachment with proliferative vitreoretinopathy," *American Journal of Ophthalmology*, vol. 100, no. 2, pp. 239–245, 1985.

[52] No authors listed, "Vitrectomy with silicone oil or sulfur hexafluoride gas in eyes with severe proliferative vitreoretinopathy: results of a randomized clinical trial. Silicone Study Report 1," *Archives of Ophthalmology*, vol. 110, pp. 770–779, 1992.

[53] L. B. Oliveira and P. A. C. Reis, "Silicone oil tamponade in 23-gauge transconjunctival sutureless vitrectomy," *Retina*, vol. 27, no. 8, pp. 1054–1058, 2007.

[54] H. Heimann, T. Stappler, and D. Wong, "Heavy tamponade 1: a review of indications, use, and complications," *Eye*, vol. 22, no. 10, pp. 1342–1359, 2008.

[55] R. H. Y. Asaria, C. H. Kon, and C. Bunce, "Silicone oil concentrates fibrogenic growth factors in the retro-oil fluid," *British Journal of Ophthalmology*, vol. 88, no. 11, pp. 1439–1442, 2004.

[56] N. Berker, C. Batman, Y. Ozdamar, S. Erandl, O. Aslan, and O. Zdlelđoglu, "Long-term outcomes of heavy silicone oil tamponade for complicated retinal detachment," *European Journal of Ophthalmology*, vol. 17, no. 5, pp. 797–803, 2007.

[57] S. Auriol, V. Pagot-Mathis, L. Mahieu, C. Lemoine, and A. Mathis, "Efficacy and safety of heavy silicone oil Densiron 68 in the treatment of complicated retinal detachment with large inferior retinectomy," *Graefe's Archive for Clinical and Experimental Ophthalmology*, vol. 246, no. 10, pp. 1383–1389, 2008.

[58] A. Duan, H. She, and Y. Qi, "Complications after heavy silicone oil tamponade in complicated retinal detachment," *Retina*, vol. 31, no. 3, pp. 547–552, 2011.

[59] M. A. Majid, H. M. Hussin, S. Biswas, R. J. Haynes, E. J. Mayer, and A. D. Dick, "Emulsification of Densiron-68 used in inferior retinal detachment surgery," *Eye*, vol. 22, no. 1, pp. 152–157, 2008.

[60] S. Wolf, V. Schön, P. Meier, and P. Wiedemann, "Silicone oil-rmn3 mixture ("Heavy silicone oil") as internal tamponade for complicated retinal detachment," *Retina*, vol. 23, no. 3, pp. 335–342, 2003.

[61] D. Wong, J. C. Van Meurs, and T. Stappler, "A pilot study on the use of a perfluorohexyloctane/silicone oil solution as a heavier than water internal tamponade agent," *British Journal of Ophthalmology*, vol. 89, no. 6, pp. 662–665, 2005.

[62] S. Rizzo, F. Genovesi-Ebert, A. Vento, F. Cresti, E. Di Bartolo, and C. Belting, "A new heavy silicone oil (hws 46-3000) used as a prolonged internal tamponade agent in complicated vitreoretinal surgery," *Retina*, vol. 27, no. 5, pp. 613–620, 2007.

[63] D. Sandner, E. Herbrig, and K. Engelmann, "High-density silicone oil (Densiron) as a primary intraocular tamponade: 12-month follow up," *Graefe's Archive for Clinical and Experimental Ophthalmology*, vol. 245, no. 8, pp. 1097–1105, 2007.

[64] T. Stappler, H. Heimann, S. K. Gibran, C. Groenewald, I. A. Pearce, and D. Wong, "Schweres Silikonöl bei PVR," *Ophthalmologe, Der*, vol. 106, no. 4, pp. 320–327, 2009.

[65] W. Li, J. Zheng, Q. Zheng, R. Wu, X. Wang, and M. Xu, "Clinical complications of Densiron 68 intraocular tamponade for complicated retinal detachment," *Eye*, vol. 24, no. 1, pp. 21–28, 2010.

[66] L. Wickham, G. O. Ho-Yen, and C. Bunce, "Surgical failure following primary retinal detachment surgery by vitrectomy: risk factors and functional out- comes," *British Journal of Ophthalmology*, vol. 95, no. 9, pp. 1234–1238, 2010.

[67] M. Nagpal, K. Nagpal, and R. Videkar, "Factors having implications on re-retinal detachments after silicone oil removal," *Indian Journal of Ophthalmology*, vol. 60, no. 6, pp. 517–520, 2012.

[68] M. Halberstadt, D. Domig, L. Kodjikian, F. Koerner, and J. Garweg, "PVR recurrence and the timing of silicone oil removal," *Klinische Monatsblätter für Augenheilkunde*, vol. 223, no. 5, pp. 361–366, 2006.

[69] S. Mondal, N. Hussain, and S. Natarajan, "Retinal redetachment after silicone oil removal in proliferative vitreoretinopathy: a prognostic factor analysis," *American Journal of Ophthalmology*, vol. 146, no. 1, p. 145, 2008.

[70] M. Nagpal, R. Videkar, and N. Mehrotra, "Retina pearls: hybrid technique for silicone oil removal," *Retina Surgery*, vol. 2, 2011.

[71] Z.-M. Song, D. Chen, Z.-S. Ke et al., "A new approach for active removal of 5,000 centistokes silicone oil through 23-gauge cannula," *Retina*, vol. 30, no. 8, pp. 1302–1307, 2010.

[72] M. Bonnet, "Macular changes and fluorescein angiographic findings after repair of proliferative vitreoretinopathy," *Retina*, vol. 14, no. 5, pp. 404–410, 1994.

[73] M. S. Cox, S. P. Azen, C. C. Barr et al., "Macular pucker after successful surgery for proliferative vitreoretinopathy," *Ophthalmology*, vol. 102, no. 12, pp. 1884–1891, 1995.

Hindawi
Journal of Ophthalmology
Volume 2021, Article ID 3648134, 10 pages
https://doi.org/10.1155/2021/3648134

Research Article

Anatomical and Functional Outcomes of Vitrectomy with/without Intravitreal Methotrexate Infusion for Management of Proliferative Vitreoretinopathy Secondary to Rhegmatogenous Retinal Detachment

Samir El Baha,[1,2] **Mahmoud Leila**,[3] **Ahmed Amr**,[2] **and Mohamed M. A. Lolah**[1]

[1]*Department of Ophthalmology, Alexandria University, Alexandria, Egypt*
[2]*El Baha Eye Center, Alexandria, Egypt*
[3]*Retina Department, Research Institute of Ophthalmology, Giza, Egypt*

Correspondence should be addressed to Mahmoud Leila; mahmoudleila@yahoo.com

Received 7 April 2021; Revised 3 June 2021; Accepted 29 June 2021; Published 20 July 2021

Academic Editor: Ogugua Okonkwo

Copyright © 2021 Samir El Baha et al. This is an open access article distributed under the Creative Commons Attribution License, which permits unrestricted use, distribution, and reproduction in any medium, provided the original work is properly cited.

Purpose. To assess the anatomical and functional outcomes of intravitreal infusion of methotrexate (MTX) during pars plana vitrectomy (PPV) for proliferative vitreoretinopathy (PVR) associated with rhegmatogenous retinal detachment (RRD). *Methods*. Comparative interventional nonrandomized study including consecutive patients who had vitrectomy for RRD. The study included six groups. Groups I (established PVR), II (high risk of PVR), and III (no risk of PVR) comprised prospectively recruited study eyes, which received PPV and adjuvant intravitreal MTX infusion equivalent to 400 μg/0.1 mL. Groups IA, IIA, and IIIA comprised retrospectively recruited control groups. Main outcome measures were retinal reattachment at the end of 6 months, visual outcome, and complications. Chi-square test or Fisher's exact test analyzed categorical variables. ANOVA test and Kruskal–Wallis test analyzed quantitative variables. Mann–Whitney *U*-test and independent *t*-test evaluated the difference between each group and its control. Comparison between two paired groups was done by Wilcoxon Rank test. The Kaplan–Meier method was used for survival analysis and the log-rank test estimated differences in event-free survival across the groups. *P* was significant at <0.05. *Results*. The study included 190 eyes of 188 patients. Study Groups I, II, and III included 42, 35, and 24 eyes, respectively. Mean age was 45 years. Male gender constituted 70% of patients. Mean follow-up period was 6 months. Control Groups IA, IIA, and IIIA included 30, 30, and 29 eyes, respectively. Mean age was 50 years. Male gender constituted 50%. Mean follow-up period was 7 months. Median rate of retinal reattachment was 82% in the study eyes versus 86% in the control eyes. The difference in the retinal reattachment rates between each study group and its respective control was not statistically significant, Group I-IA ($p = 0.2$), Group II-IIA ($p = 0.07$), and Group III-IIIA ($p = 0.07$). BCVA improved by a mean of 4 lines in the study eyes versus 3 lines in the control eyes. The difference in visual outcome between each study group and its respective control was statistically significant between Groups II-IIA and III-IIIA, $p = 0.03$, but not between Groups I-IA, $p = 0.07$. We did not detect complications attributed to MTX use in the study eyes. *Conclusion*. Intravitreal infusion of MTX during PPV is a safe adjuvant therapy in RRD patients with and without PVR. MTX yields superior functional outcomes in patients at high risk of PVR and in patients with no risk of PVR compared to PPV without MTX, but not in cases with established PVR. MTX did not confer an additional advantage in terms of retinal reattachment rate. *Summary*. Proliferative vitreoretinopathy is a major cause of failure in surgery for rhegmatogenous retinal detachment. Methotrexate as an adjuvant therapy blocks essential drivers in the pathogenetic cascade leading to PVR. Intravitreal infusion has the advantage of blocking the pathology in its nascence and obviates the need for repeated intravitreal injections of the drug.

1. Introduction

Proliferative vitreoretinopathy (PVR) represents a robust wound-healing response of the retina to injury produced by retinal detachment. The retinal cellular elements involved in this response are legion, and they work in tandem in a multipronged cascade that eventually establishes PVR. The pathogenetic process is based on three factors that are considered the hallmark of PVR. Firstly, migration of retinal pigment epithelial (RPE) cells and cytokine-producing immune cells through the retinal break(s) and dehisced blood-retina barrier (BRB), respectively, along with activation of retinal astrocytes and Müller cells. Secondly, inflammatory cytokines trigger metaplasia of RPE cells into myocontractile cells and proliferation of retinal glial elements. Finally, these cells produce an extracellular matrix and undergo relentless fibrocellular proliferation in the vitreous and along both sides of the retina with the formation of contractile membranes [1–6]. PVR is considered the most implacable complication of retinal detachment that claims 75% of failed retinal detachment surgical repair [7, 8]. Currently, the only treatment of PVR is surgical removal of periretinal membranes, although the functional outcome of surgery is far from satisfactory. Mean percentage of patients gaining ambulatory vision (≥5/200) varies widely from 35.5% to 85% of successful retinal reattachment cases [9–12]. The presence of inflammatory progenitors, the proliferative nature of the disease, and the unsatisfactory functional outcome of PVR surgery catalyzed the hypothesis that antineoplastic drugs used as pharmacologic adjuvants during pars plana vitrectomy (PPV) could halt the sequence of events leading to PVR [5, 7, 8, 13–20]. Methotrexate (MTX) is a folate analogue that inhibits cell proliferation through competitive inhibition of enzymes requiring folate. These enzymes are essential for deoxyribonucleic acid (DNA) and ribonucleic acid (RNA) synthesis [21]. At an intraocular dose of ≤400 μg/0.1 mL, MTX inhibits cytokine-producing immune cells and cellular proliferation; however, it has no effect on cellular migration. Thus, it can effectively neutralize two major components of the pathologic sequence leading to PVR, namely, induction of RPE metaplasia and proliferation of myocontractile cells and glial elements of the retina [13, 14, 21]. Nevertheless, the relatively short therapeutic half-life of MTX when delivered intravitreal is a significant shortcoming when considering the protracted time span of PVR process since nascence through contractile membrane formation. Müller cell activation starts almost immediately; whereas cellular proliferation starts as early as the 4th day after the onset of retinal detachment, and the disease course continues for at least 90 days [6, 7, 16]. Since the therapeutic half-life of MTX inside the vitreous cavity is only 3 to 5 days; therefore, multiple injections are required to suppress the PVR process during that period [22, 23]. In comparison, intravitreal infusion of MTX during PPV has been reported to suppress PVR effectively. The rationale for this route is based on the easy penetrance of the low-molecular weight MTX into the retinal tissues, and hence, the achievement of a stable tissue concentration that produces a uniform dosing of the drug as opposed to a single bolus delivered at the end of surgery [7]. The aim of this study is to assess the anatomical and functional outcomes of intravitreal infusion of MTX during PPV for PVR associated with retinal detachment.

2. Patients and Methods

This is an interventional comparative nonrandomized case series conducted in a retina tertiary care center between February 2019 and January 2021. The study included all consecutive patients who had PPV for rhegmatogenous retinal detachment (RRD). The study included six groups. Groups I, II, and III comprised prospectively recruited study eyes that received PPV and adjuvant intravitreal MTX infusion equivalent to 400 μg/0.1 mL. Group I (established PVR) included eyes with RRD and PVR C located posterior (CP) or anterior (CA) to the equator and involved 1 or more clock hours. Group II (high risk of PVR) included eyes with recent-onset RRD ≤ 1-week duration and no clinical signs of PVR but with one or more risk factors for developing PVR. Group III (no risk of PVR) included eyes with recent-onset RRD ≤ 1-week duration and no clinical signs of PVR or co-exiting risk factors for developing PVR. Groups IA, IIA, and IIIA comprised retrospectively recruited control eyes with established PVR, high risk of PVR, and no risk of PVR, respectively. Patients in these groups had PPV without adjuvant intravitreal MTX infusion. Risk factors for developing PVR were identified as aphakia, high myopia, vitreous hemorrhage, hypotony, suprachoroidal effusion/hemorrhage, giant retinal tear, RRD involving ≥2 quadrants, penetrating trauma with or without retained intraocular foreign body (IOFB), recurrent retinal detachment after previous surgery, intraoperative cryotherapy, and retinotomy or relaxing retinectomy. Staging of PVR followed the guidelines of the Retina Society classification of PVR of 1983 and the updated classification of retinal detachment with PVR of 1991 [24, 25]. Exclusion criteria included patients <18 years old, pregnant and breast-feeding mothers, co-existing pathology that might induce PVR such as proliferative diabetic retinopathy (PDR) or uveitis, co-existing congenital anomalies or hereditary vitreoretinopathies, and patients who were unable to complete at least 6 months of follow-up. Main outcome measures were successful reattachment of the retina at the end of 6 months, with removal of silicone oil or absorption of gas tamponade and without additional surgery, visual outcome, and complications of MTX use. Patients who presented with retinal redetachment after primary PPV underwent repeat surgery within 3 weeks. They were not included in successfully reattached cases even if that was achieved after additional surgery. All recruited patients received full ophthalmological assessment including history taking, best-corrected visual acuity (BCVA) using Snellen's decimal notation, anterior segment slit-lamp examination including applanation tonometry, indirect ophthalmoscopy with 360° scleral indentation and slit-lamp biomicroscopy.

2.1. Surgical Technique. All surgical procedures described herein were performed by a single retina surgeon (S.B.). Surgical technique consisted of a standard 3-port 23-gauge PPV. Patients with co-existing cataract that was dense enough to impede visualization during PPV or in whom sparing a clear crystalline lens would hinder elimination of proliferative membranes underwent phacoemulsification with implantation of a posterior chamber intraocular lens within the capsular bag before starting PPV. In the study groups, MTX infusion was prepared from a commercially available MTX vial (50 mg/2 mL). A volume of MTX equivalent to 40 mg/mL was withdrawn and added to a 500 mL balanced salt saline (BSS) bottle at the start of the infusion line. This would achieve an intraocular concentration equivalent to that of a 400 μg intravitreal MTX injection, given that the volume of the human eye is approximately 5 mL. In the control groups, the infusion line contained pure BSS. The time duration of all surgeries did not exceed 60 minutes. The surgical procedure consisted of core vitrectomy followed by injection of triamcinolone acetonide to help identify the posterior hyaloid. If not already induced, PVD was performed by applying active suction at the edge of the ONH. Once induced PVD was continued as far anteriorly as possible. That was followed by shaving of the vitreous base. The surgeon selected as per his discretion among surgical maneuvers such as cryotherapy, endodiathermy, endolaser, application of scleral band, peeling of epiretinal membranes and/or internal limiting membrane (ILM), removal of subretinal membranes through retinotomy, relaxing retinectomy, use of perfluorocarbon liquid (PFCL), and choice of type of intraocular tamponade. Finally fluid/air exchange was performed followed by air/silicone oil or air/gas exchange. All patients with successful retinal reattachment and no evidence of recurrent retinal proliferation, who received silicone oil tamponade had a second surgery for silicone oil removal 3 months after the initial surgery. Postoperatively, patients were examined at 1-day, 1-week, 1-month, and 3-monthly thereafter.

2.2. Statistical Analysis. Data were described by means, standard deviation and frequency, percentages for quantitative and qualitative variables, respectively. Categorical variables were analyzed by the Chi-square test or Fisher's exact test, while differences in quantitative variables between the 3 groups were analyzed by the one-way ANOVA test for normally distributed variables and the Kruskal–Wallis test for nonnormally distributed ones. Differences between each group and its controls were tested by the Mann–Whitney *U*-test for nonparametric data and by the independent *t*-test for parametric ones. Wilcoxon Rank test was used to compare between two paired groups regarding quantitative data, and nonparametric distribution was done using the Wilcoxon Rank test. Survival analysis was done by the Kaplan–Meier method to estimate the event-free survival, where the event was defined as recurrence of retinal detachment. Differences in event-free survival across the groups were evaluated by the log-rank test. P value < 0.05 was considered significant.

2.2.1. Statistical Power. A two-sided log-rank test with an overall sample size of 190 subjects (89 in the control group and 101 in the treatment group) achieves 80.0% power at a 0.050 significance level to detect a hazard ratio of 1.96 when the proportion surviving in the control group is 0.8950 with a difference in survival of 9%. The study lasts for 24 time periods, of which subject accrual (entry) occurs in the first 13 time periods.

3. Results

3.1. Characteristics of the Study Population (Shown in Table 1). The study included 190 eyes of 188 patients, of which 101 eyes of 99 patients comprised the study groups. Groups I, II, and III included 42, 35, and 24 eyes, respectively. Mean age was 45 years (range: 18-71; SD: 15). Male gender constituted 70% of patients. Mean follow-up period was 6 months (range: 6-8; SD: 0.3). In Group II, recurrent RRD after previous surgery was the main risk factor for PVR (60%), followed by penetrating trauma (11%), vitreous hemorrhage (11%), giant retinal tear (8.5%), and suprachoroidal hemorrhage (8.5%). There was no statistically significant difference between the 3 groups in terms of mean values of gender, age, status of the crystalline lens, baseline BCVA, or follow-up period. Silicone oil tamponade was used in 91% of the overall sample, and in 95%, 83%, and 96% of Groups I, II, and III, respectively. Groups IA, IIA, and IIIA included 30, 30, and 29 eyes, respectively. Mean age was 50 years (range: 20-76; SD: 13). Male gender constituted 50%. Mean follow-up period was 7 months (range: 6-12; SD: 1.7). In Group IIA intraoperative use of cryotherapy was the main risk factor for PVR (93%), followed by high myopia (13%). Silicone oil tamponade was used in 86% of the overall sample, and in 90%, 78%, and 89% of Groups IA, IIA, and IIIA, respectively. Statistically significant differences were present between Groups I and IA in the status of the crystalline lens ($p = 0.01$) and follow-up period ($p = 0.003$), between Groups II and IIA in the follow-up period ($p \leq 0.001$) and between Groups III and IIIA in gender distribution ($p = 0.001$).

3.2. Anatomical and Functional Outcomes (Shown in Tables 2 to 5)

3.2.1. Anatomical Outcome. In the study eyes, we achieved a successful retinal reattachment rate after a single procedure in 74%, 77%, and 96% in Groups I, II, and III, respectively ($p = 0.08$), with a median rate of retinal reattachment 82% of the overall study sample. We did not detect complications in any group attributed to MTX use. Six-month survival analysis was 100%, 59%, and 52% in Groups I, II, and III, respectively ($p = 0.009$). In the control eyes, we achieved a successful retinal reattachment rate after a single procedure in 87%, 93%, and 79% in Groups IA, IIA, and IIIA, respectively, with a median rate of retinal reattachment 86% of the overall control sample. The difference in the retinal reattachment rates between each study group and its respective control was not statistically significant, $p = 0.2$, 0.07, and 0.07. Six-month survival analysis across the study and control eyes revealed a statistically significant difference in

Table 1: Baseline characteristics of the study participants.

Group	Gender, n		Mean age (years)	Lens status, n			Mean follow-up (months)	Mean baseline BCVA*
	Male	Female		Phakic	Pseudophakic	Aphakic		
I, $n = 42$	27	15	41	19	21	2	6	0.02
IA, $n = 30$	16	14	46	5	25	0	7	0.02
**P value	0.35		0.1		0.01		0.003	0.5
II, $n = 35$	23	12	44.5	14	21	0	6	0.07
IIA, $n = 30$	19	11	50	13	17	0	7	0.05
P value	0.8		0.1		0.7		≤0.001	0.3
III, $n = 24$	19	5	49	13	11	0	6	0.08
IIIA, $n = 29$	10	19	55	19	10	0	7	0.03
P value	0.001		0.1		0.4		0.001	0.5

*BCVA, best-corrected visual acuity in Snellen decimal notation; n, number. **P is significant at <0.05.

Table 2: MTX use versus anatomical outcome in each subgroup and no MTX use versus anatomical outcome in control.

		Anatomical outcome		*P value
		Successful	Recurrent	
Subgroups based on MTX indication	IA	26	4	0.2
	I	31	11	
	IIA	28	2	0.07
	II	27	8	
	IIIA	23	6	0.07
	III	23	1	

MTX, methotrexate. *P is significant at <0.05.

Table 3: MTX versus mean visual acuity in each subgroup and no MTX use versus mean visual acuity in control.

		Final BCVA					**P value
		Mean	SD	Median	Minimum	Maximum	
Subgroups based on MTX indication	Control 1	0.04	0.04	0.03	0.001	0.13	0.07
	Established PVR	0.11	0.15	0.05	0.01	0.7	
	Control 2	0.08	0.06	0.1	0.001	0.2	0.03
	High-risk PVR	0.15	0.12	0.16	0.01	0.4	
	Control 3	0.08	0.05	0.1	0.001	0.16	0.03
	No risk of PVR	0.16	0.14	0.16	0.01	0.5	

BCVA, best-corrected visual acuity; MTX, methotrexate; PVR, proliferative vitreoretinopathy; SD, standard deviation. **P is significant at <0.05.

Groups II-IIA, 59% versus 92.5%, respectively, $p = 0.003$. Neither the status of the crystalline lens in the study and the control groups, nor the number of previous recurrences in Groups I–IA and II–IIA were significant contributing factors in the anatomical outcome described herein.

(1) Survival Analysis in the Study and Control Eyes. (Shown in Figures 1(a)–1(c) and 2). Six-month survival was 52%, 59%, and 100% in Groups I, II, and III, respectively, $p = 0.009$. The differences in 6-month survival between Groups I-IA, II-IIA, and III-IIIA were 52% versus 83% ($p = 0.07$), 59% versus 92.5% ($p = 0.003$), and 100% versus 92.6% ($p = 0.8$), respectively.

3.2.2. Functional Outcome. In the study eyes, BCVA improved by 5 lines, 4 lines, and 3 lines in Groups I, II, and III, respectively ($p = 0.05$). Mean improvement of BCVA was 4 lines in the overall study sample. In the control eyes, BCVA improved by 2 lines, 3 lines, and 4 lines in Groups IA, IIA, and IIIA, respectively. Mean improvement of BCVA was 3 lines in the overall control sample. The difference in visual outcome between each study group and its respective control was statistically significant between Groups II-IIA and III-IIIA, $p = 0.03$, but not between Groups I-IA ($p = 0.07$).

4. Discussion

This study assessed the efficacy of MTX infusion during PPV as a pre-emptive measure in RRD without PVR or at high risk for developing PVR and as a therapeutic adjuvant in established PVR cases. The median overall retinal reattachment rates in the study and control groups were 82% versus 86%, respectively. These rates were not statistically significant. All rates were reported after silicone oil removal or absorption of gas. In terms of MTX use, our retinal reattachment rates in Groups I and II were superior to those reported after a single surgery by De Silva et al. [9] (68%),

Table 4: Effect of lens status on anatomical outcome in each subgroup and control.

Lens status				Anatomical outcome		**P value
				Successful count	Recurrent count	
Subgroups based on MTX indication	Control 1	Lens status	Pseudophakic	23	2	0.1
			Aphakic	0	0	
			Phakic	3	2	
	Established PVR	Lens status	Pseudophakic	14	7	0.3
			Aphakic	1	1	
			Phakic	16	3	
	Control 2	Lens status	Pseudophakic	15	2	0.5
			Aphakic	0	0	
			Phakic	13	0	
	High-risk PVR	Lens status	Pseudophakic	16	5	1
			Aphakic	0	0	
			Phakic	11	3	
	Control 3	Lens status	Pseudophakic	7	3	0.6
			Aphakic	0	0	
			Phakic	16	3	
	No risk of PVR	Lens status	Pseudophakic	10	1	0.4
			Aphakic	0	0	
			Phakic	13	0	

MTX, methotrexate; PVR, proliferative vitreoretinopathy. **P is significant at <0.05.

Table 5: Effect of number of recurrences on anatomical outcome and mean visual acuity in each subgroup and control.

Anatomical outcome						**P value
				Successful	Recurrent	
Subgroups based on MTX indication	Control 1	Number of recurrences	0	3	0	0.4
			1	9	1	
			2	8	3	
			3	3	0	
			4	3	0	
	Established PVR	Number of recurrences	0	9	4	0.7
			1	14	3	
			2	5	2	
			3	2	2	
			4	1	0	
	Control 2	Number of recurrences	0	28	2	—
	High-risk PVR	Number of recurrences	0	26	7	0.4
			1	1	1	
	Control 3	Number of recurrences	0	23	6	—
	No risk of PVR	Number of recurrences	0	23	1	—

MTX, methotrexate; PVR, proliferative vitreoretinopathy. **P is significant at <0.05.

Lewis et al. [11] (68%), Silicone study group [12] (67% and 68.5%), Asaria et al. [18] (71.2%), Grigoropoulos et al. [26] (51%), and Charteris et al. [27] (51%; placebo arm of a series of cases with RRD and established PVR grade C). In contrast, higher retinal reattachment rates were reported by Lewis et al. [10] (81%), Lam et al. [28] (81.6%), and Wickham et al. [29] (86.8%; the placebo arm of a series of unselected cases with RRD). The latter authors mentioned that 86% of their patients did not have PVR at presentation. Review of studies on PPV for PVR is shown in Table 6. Our retinal reattachment rate after a single procedure in Group III matched the maximum success rate published in the literature (71%-96%) [30]. Most published data on the use of MTX in RRD are derived from retrospective studies [7, 8, 15], pilot studies [16], or small prospective case series [17]. Benner et al. [8] reported retinal reattachment in all 5 eyes with severe PVR using MTX injection as an adjuvant to extended perfluorocarbon tamponade. The authors delivered 12 injections of MTX in one patient and 5 injections in the remaining 4 patients. Nourinia et al. [16] reported 100% retinal reattachment in a series of 11 eyes with PVR grade C using multiple intrasilicone injections of MTX. However, the authors did not remove silicone oil in more than 80% of their cases. Falavarjani et al. [17] reported retinal reattachment in 95.5% of 22 eyes with PVR grade C that received a single intrasilicone oil injection of MTX. The

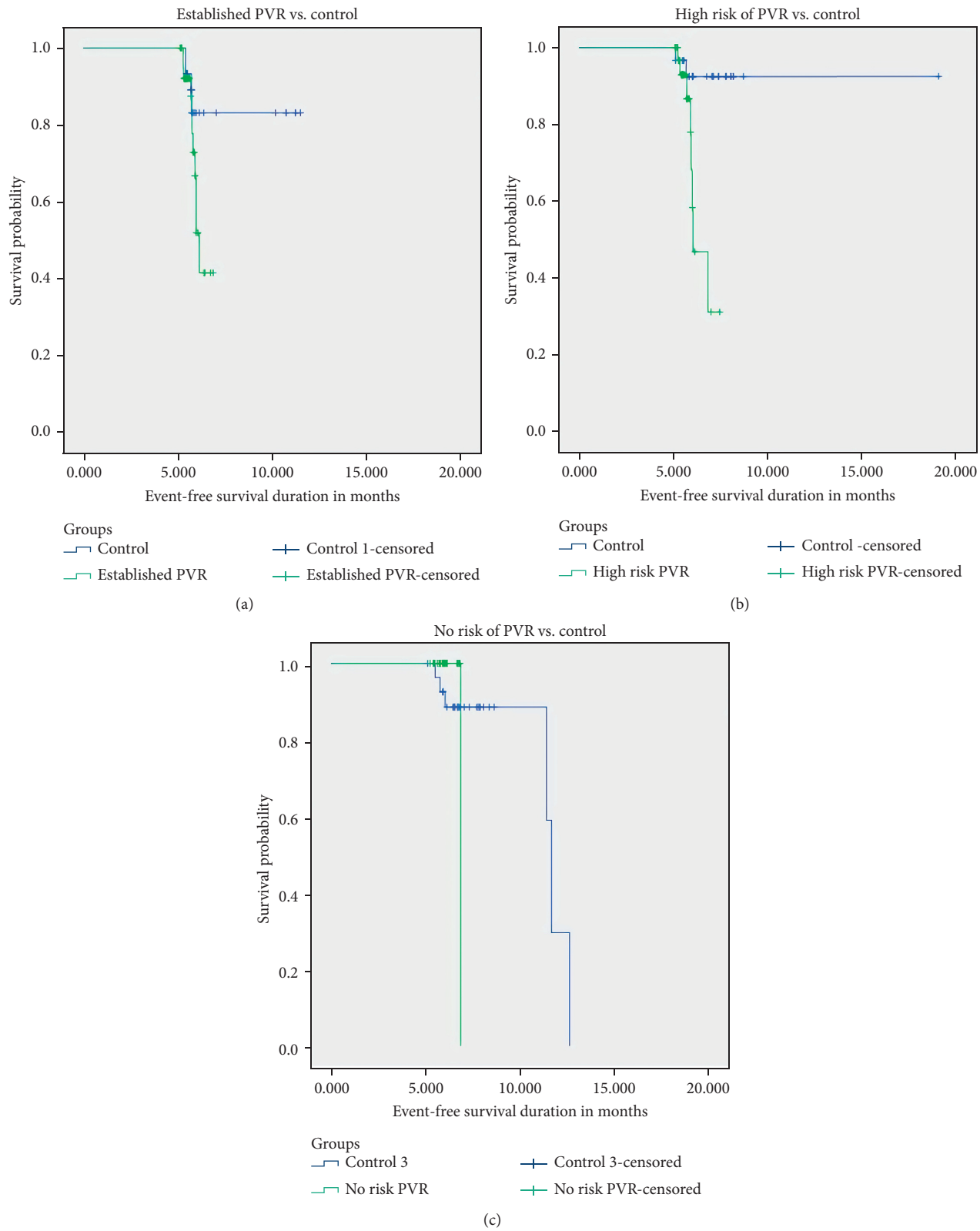

Figure 1: a-c. Six-month Kaplan–Meier survival curve for the study groups and their respective controls. Event refers to retinal redetachment within 6 months postoperatively.

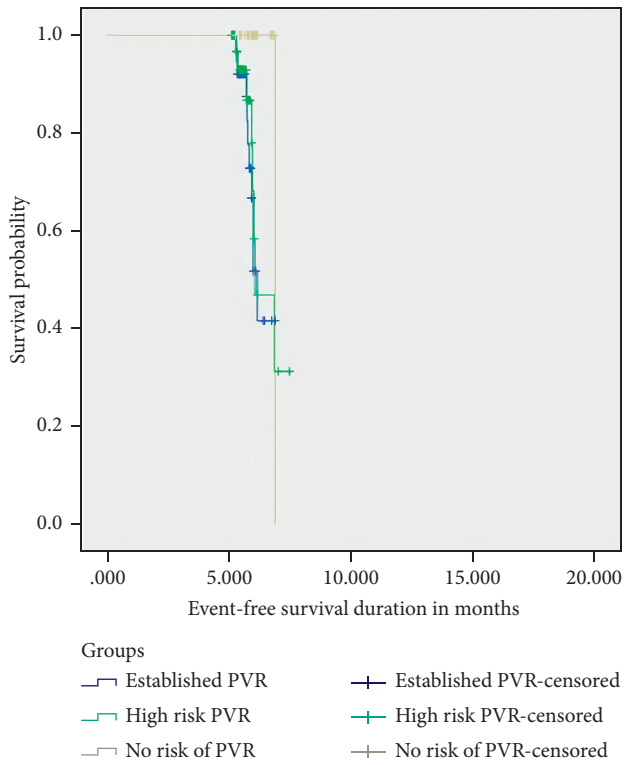

Figure 2: Event-free survival across the study groups.

Table 6: Review of studies on PPV for proliferative vitreoretinopathy complicating rhegmatogenous retinal detachment.

Author	PVR grade	Surgical technique	No. of eyes	Retinal reattachment (%)	Final BCVA
Lewis et al. [10]	23% *C1-C3* 77% *D1-D3*	91.3% PPV + 14% C3F8 8.6% PPV + silicone oil	81	81% (single surgery) 90% (additional surgeries)	85% ≥ 5/200
Lewis and Aaberg [11]	19% *C3* 81% *D1-D3*	78% PPV + C3F8 22% PPV + silicone oil	37	68% (single surgery) 73% (additional surgeries) 13% (attachment posterior to scleral buckle)	59% ≥ 5/200
Silicone Study [12]	PVR C or higher	PPV + C3F8/silicone oil	131 (no prior PPV) 134 (prior PPV)	68.5% 67%	44% ≥ 5/200 35.5% ≥ 5/200
Asaria et al. [18]	At high risk of PVR	PPV + SF6/C3F8/ silicone oil	87 (placebo arm)	71.2%	Stable 12.6% Better 45.9% Worse 41.3%
Charteris et al. [27]	PVR C	PPV + silicone oil	78 (placebo arm)	51% (single surgery)	~2 lines gain
Grigoropoulos et al. [26]	PVR C	PPV + C3F8/silicone oil	304	51% (single surgery) 72% (additional surgeries)	Stable 24% Better 45% Worse 29%
Wickham et al. [29]	86% No PVR	PPV + SF6/C3F8/ silicone oil	288 (placebo arm)	86.8% (single surgery)	—
De silva et al. [9]	PVR C	6% PPV + C3F8 94% PPV + silicone oil	145	68%	76% improved or stable
Lam et al. [28]	PVR C	PPV + silicone oil	147	81.6%	~3 lines gain
Current study, 2020	41.5% PVR C 35% high risk of PVR 24% no risk of PVR	9% PPV + C3F8 91% PPV + silicone oil	42 (PVR C) 35 (high risk of PVR) 24 (no risk of PVR)	74% (single surgery) 77% (single surgery) 96% (single surgery)	4 lines mean gain 54% ≥ 0.1, 11% ≥0.4

BCVA, best-corrected visual acuity; C3F8, octafluoropropane; No., number; PPV, pars plana vitrectomy; PVR, proliferative vitreoretinopathy; SF6, sulfurhexafluoride.

Table 7: Review of studies on PPV and adjuvant methotrexate for proliferative vitreoretinopathy complicating rhegmatogenous retinal detachment.

Author	PVR grade	Surgical technique	No. of eyes	Retinal reattachment (%)	Final BCVA
Sadaka et al. [7]	PVR C	PPV + MTX infusion + SF6/C3F8/ silicone oil	29	90% (single surgery)	66% ≥ 20/200
Benner et al. [8]	PVR C	PPV + extended PFCL tamponade + 5 bi-weekly MTX injections (100–200 μg/0.05 mL)	5	100%	80% > 20/200
Nourinia et al. [16]	PVR C	PPV + intra-silicone oil injection of MTX 250 μg (3 injections, 3-week interval)	11	82% total reattachment 18% reattachment posterior to the equator Silicone oil was not removed in 82% of patients	~6 lines gain
Falavarjani et al. [17]	PVR C	PPV + single intrasilicone oil injection of MTX 250 μg	22 (treatment arm)	95.5%	No statistically significant difference between groups
			22 (control arm)	77.3%	
Current study, 2020	41.5% PVR C	PPV + MTX infusion + C3F8/silicone oil	42 (PVR C)	74% (single surgery)	4 lines mean gain 54% ≥ 0.1, 11% ≥ 0.4
	35% high risk of PVR		35 (high risk of PVR)	77% (single surgery)	
	24% no risk of PVR		24 (no risk of PVR)	96% (single surgery)	

BCVA, best-corrected visual acuity; C3F8, octafluoropropane; μg, microgram; mL, milliliter; MTX, methotrexate; No., number; PFCL, perfluorocarbon liquid; PPV, pars plana vitrectomy; PVR, proliferative vitreoretinopathy; SF6, sulfurhexafluoride.

authors reported no statistically significant difference in rates of retinal redetachment between treatment and control arms. Sadaka et al. [7] used MTX infusion during PPV in an uncontrolled retrospective series of 29 eyes with established PVR and eyes at high risk for developing PVR. The authors reported a retinal reattachment rate of 90%. Review of studies on MTX use for PVR is shown in Table 7. To our knowledge, this study is the largest prospective controlled case series to evaluate MTX infusion in RRD patients. Nevertheless, whether the reattachment rates reported herein in the study eyes were influenced by MTX infusion is uncertain because we did not detect statistical significance in the anatomical parameters tested between the study eyes and the control eyes. In our series, we did not perform electrophysiologic study to assess the toxicity of the dose of methotrexate. The reasons are, firstly, the technical difficulty of performing such test in presence of silicone oil, which is known for its poor electric conductivity, for at least 3 months in most of the patients. Secondly, 41.5% and 34% of patients in the study and control groups, respectively, had established PVR. This represents a significant confounding factor upon interpretation of the electrophysiology results. Nevertheless, we did not detect any of the previously reported complications attributed to MTX use [13]. This finding is of particular importance in corroborating the safety of MTX dose used because the continuous infusion during surgery saturated the ocular tissues with MTX. Furthermore, clearance of the drug was further delayed due to the presence of silicone oil. Both factors would have potentiated the adverse effects of MTX had the dose used been toxic. Another corroborating evidence of the safety of MTX infusion in our series is that 65% of our patients experienced improved vision with a mean improvement of 4 lines. Fifty-five patients (54%) recovered ambulatory vision (≥0.1 Snellen), and 11% had final BCVA of ≥0.4 Snellen. Furthermore, the visual outcome of MTX use in Groups II and III was significantly superior to the respective control groups ($p = 0.03$). An important advantage of MTX infusion is providing stable concentrations of the drug flowing into the ocular tissues. This is compared to the unpredictable therapeutic effect of a single high bolus delivered as intravitreal injection, especially in the presence of intraocular tamponade. The possibility of creation of a depot through saturation of retinal tissues by continuous infusion of MTX and that releases MTX for some time after surgery is interesting and would provide a major advantage over multiple intravitreal injections but yet to be proven by animal studies. Limitations of this study include the discrepant modes of recruiting the study and control groups, and the subsequent inhomogeneity across data in some of the parameters tested, which could be the reason we could not detect the statistical significance of some of the outcomes reported herein.

5. Conclusion

Off-label use of intravitreal infusion of MTX during PPV is a safe adjuvant therapy in RRD patients with and without PVR. MTX yields superior functional outcomes in patients at high risk of PVR and patients with no risk of PVR compared to PPV without MTX but not in established PVR cases. PPV with MTX did not confer an additional advantage in terms of retinal reattachment rate compared to PPV without MTX use.

Data Availability

The data collected from history taking and clinical examination of patients recruited in this study are confidential. Access to these data is restricted by El Baha Eye Center in accordance with patients' data protection policy. Data are available for researchers who meet the criteria for access to confidential data by contacting the lead investigator.

Ethical Approval

The study was approved by the institution review board of the El Baha Eye Center, Alexandria, Egypt. The study adhered strictly to the tenets of the Declaration of Helsinki of 1975 and the revision of 2013. The study required that all participants received a thorough explanation of the surgical maneuvers, entailed off-label use of MTX whenever applicable, possible outcomes, and expected complications, and signed an informed consent prior to enrollment either in person or via the legal custodian. Any female patient in the child-bearing period was informed about the possible teratogenicity of MTX and that she could not get pregnant for at least three months after receiving the drug.

Conflicts of Interest

The authors declare that they have no conflicts of interest.

References

[1] P. S. Hiscott, I. Grierson, and D. McLeod, "Natural history of fibrocellular epiretinal membranes: a quantitative, autoradiographic, and immunohistochemical study," *British Journal of Ophthalmology*, vol. 69, no. 11, pp. 810–823, 1985.

[2] J. C. Pastor, "Proliferative vitreoretinopathy," *Survey of Ophthalmology*, vol. 43, no. 1, pp. 3–18, 1998.

[3] S. Pennock, L. J. Haddock, D. Eliott, S. Mukai, and A. Kazlauskas, "Is neutralizing vitreal growth factors a viable strategy to prevent proliferative vitreoretinopathy?" *Progress in Retinal and Eye Research*, vol. 40, pp. 16–34, 2014.

[4] J. C. Pastor, J. Rojas, S. Pastor-Idoate, S. Di Lauro, L. Gonzalez-Buendia, and S. Delgado-Tirado, "Proliferative vitreoretinopathy: a new concept of disease pathogenesis and practical consequences," *Progress in Retinal and Eye Research*, vol. 51, pp. 125–155, 2016.

[5] V. Sundaram, A. Barsam, and G. Virgili, "Intravitreal low molecular weight heparin and 5-Fluorouracil for the prevention of proliferative vitreoretinopathy following retinal reattachment surgery," *Cochrane Database of Systematic Reviews*, no. 1, pp. 1–17, Article ID CD006421, 2013.

[6] G. P. Lewis, C. S. Sethi, K. A. Linberg, D. G. Charteris, and S. K. Fisher, "Experimental retinal reattachment: a new perspective," *Molecular Neurobiology*, vol. 28, no. 2, pp. 159–176, 2003.

[7] A. Sadaka, R. Sisk, J. Osher, O. Toygar, M. Duncan, and C. Riemann, "Intravitreal methotrexate infusion for proliferative vitreoretinopathy," *Clinical Ophthalmology*, vol. 10, pp. 1811–1817, 2016.

[8] J. D. Benner, D. Dao, J. W. Butler, and K. I. Hamill, "Intravitreal methotrexate for the treatment of proliferative vitreoretinopathy," *BMJ Open Ophthalmology*, vol. 4, no. 1, Article ID e000293, 2019.

[9] D. J. De Silva, A. Kwan, C. Bunce, and J. Bainbridge, "Predicting visual outcome following retinectomy for retinal detachment," *British Journal of Ophthalmology*, vol. 92, no. 7, pp. 954–958, 2008.

[10] H. Lewis, T. M. Aaberg, and G. W. Abrams, "Causes of failure after initial vitreoretinal surgery for severe proliferative vitreoretinopathy," *American Journal of Ophthalmology*, vol. 111, no. 1, pp. 8–14, 1991.

[11] H. Lewis and T. M. Aaberg, "Causes of failure after repeat vitreoretinal surgery for recurrent proliferative vitreoretinopathy," *American Journal of Ophthalmology*, vol. 111, no. 1, pp. 15–19, 1991.

[12] Silicone Study Group, "Vitrectomy with silicone oil or perfluoropropane gas for eyes with severe proliferative vitreoretinopathy: results of a randomized clinical trial. Silicone study report 2," *Archives of Ophthalmology*, vol. 110, no. 6, pp. 780–792, 1992.

[13] P. W. Hardwig, J. S. Pulido, J. C. Erie, K. H. Baratz, and H. Buettner, "Intraocular methotrexate in ocular diseases other than primary central nervous system lymphoma," *American Journal of Ophthalmology*, vol. 142, no. 5, pp. 883–885, 2006.

[14] D. Amarnani, A. I. Machuca-Parra, L. L. Wong et al., "Effect of methotrexate on an in vitro patient-derived model of proliferative vitreoretinopathy," *Investigative Opthalmology and Visual Science*, vol. 58, no. 10, pp. 3940–3949, 2017.

[15] P. W. Hardwig, J. S. Pulido, and S. J. Bakri, "The safety of intraocular methotrexate in silicone-filled eyes," *Retina*, vol. 28, no. 8, pp. 1082–1086, 2008.

[16] R. Nourinia, F. Borna, A. Rahimi et al., "Repeated injection of methotrexate into silicone oil-filled eyes for grade C proliferative vitreoretinopathy: a pilot study," *Ophthalmologica*, vol. 242, no. 2, pp. 113–117, 2019.

[17] K. G. Falavarjani, A. Hadavandkhani, M. M. Parvaresh, M. Modarres, M. Naseripour, and S. A. Alemzadeh, "Intrasilicone oil injection of methotrexate in retinal reattachment surgery for proliferative vitreoretinopathy," *Ocular Immunology and Inflammation*, vol. 28, no. 3, pp. 513–516, 2020.

[18] R. H. Y. Asaria, C. H. Kon, C. Bunce et al., "Adjuvant 5-fluorouracil and heparin prevents proliferative vitreoretinopathy," *Ophthalmology*, vol. 108, no. 7, pp. 1179–1183, 2001.

[19] F. Schaub, R. Hoerster, P. Schiller et al., "Prophylactic intravitreal 5-fluorouracil and heparin to prevent proliferative vitreoretinopathy in high-risk patients with retinal detachment: study protocol for a randomized controlled trial," *Trials*, vol. 19, no. 1, p. 384, 2018.

[20] D. G. Charteris, "Proliferative vitreoretinopathy: revised concepts of pathogenesis and adjunctive treatment," *Eye*, vol. 34, no. 2, pp. 241–245, 2020.

[21] R. B. Nussenblatt, "Philosophy, goals, and approaches to medical therapy," in *Uveitis: Fundamentals and Clinical Practice*, R. B. Nussenblatt and S. M. Whitcup, Eds., pp. 76–113, Mosby - Elsevier, New York, NY, USA, 4th edition, 2010.

[22] G. Velez, P. Yuan, C. Sung et al., "Pharmacokinetics and toxicity of intravitreal chemotherapy for primary intraocular lymphoma," *Archives of Ophthalmology*, vol. 119, no. 10, pp. 1518–1524, 2001.

[23] E. B. Ozkan, A. A. Ozcan, H. T. Sekeroglu, Y. Kuyucu, H. Ozgun, and S. Polat, "Intravitreal injection of methotrexate in an experimental rabbit model: determination of ultrastructural changes," *Indian Journal of Ophthalmology*, vol. 61, no. 7, pp. 329–333, 2013.

[24] The Retina Society Terminology Committee, "The classification of retinal detachment with proliferative vitreoretinopathy," *Ophthalmology*, vol. 90, pp. 121–125, 1983.

[25] R. Machemer, T. M. Aaberg, H. M. Freeman, R. I. Alexander, S. L. John, and M. M. Ronald, "An updated classification of retinal detachment with proliferative vitreoretinopathy," *American Journal of Ophthalmology*, vol. 112, no. 2, pp. 159–165, 1991.

[26] V. G. Grigoropoulos, S. Benson, C. Bunce, and D. G. Charteris, "Functional outcome and prognostic factors in 304 eyes managed by retinectomy," *Graefe's Archive for Clinical and Experimental Ophthalmology*, vol. 245, no. 5, pp. 641–649, 2007.

[27] D. G. Charteris, G. W. Aylward, D. Wong, C. Groenewald, R. H. Y. Asaria, and C. Bunce, "A randomized controlled trial of combined 5-fluorouracil and low-molecular-weight heparin in management of established proliferative vitreoretinopathy," *Ophthalmology*, vol. 111, no. 12, pp. 2240–2245, 2004.

[28] R. F. Lam, B. T. O. Cheung, C. Y. F. Yuen, D. Wong, D. S. C. Lam, and W. W. Lai, "Retinal redetachment after silicone oil removal in proliferative vitreoretinopathy: a prognostic factor analysis," *American Journal of Ophthalmology*, vol. 145, no. 3, pp. 527–533, 2008.

[29] L. Wickham, C. Bunce, D. Wong, D. McGurn, and D. G. Charteris, "Randomized controlled trial of combined 5-fluorouracil and low-molecular-weight heparin in the management of unselected rhegmatogenous retinal detachments undergoing primary vitrectomy," *Ophthalmology*, vol. 114, no. 4, pp. 698–704, 2007.

[30] L. Znaor, A. Medic, S. Binder, A. Vucinovic, J. Marin Lovric, and L. Puljak, "Pars plana vitrectomy versus scleral buckling for repairing simple rhegmatogenous retinal detachments," *Cochrane Database of Systematic Reviews*, no. 3, Article ID CD009562, 2019.

Hindawi
Journal of Ophthalmology
Volume 2021, Article ID 6654604, 5 pages
https://doi.org/10.1155/2021/6654604

Research Article

Isolated Central Epiretinal Membrane: A Rare Complication of Fovea-Sparing Internal Limiting Membrane Peeling Technique

Yen-Chih Chen [1,2,3] **and San-Ni Chen** [1,4,5,6]

[1]*Department of Ophthalmology, Changhua Christian Hospital, Changhua, Taiwan*
[2]*Department of Ophthalmology, Yunlin Christian Hospital, Xiluo, Yunlin, Taiwan*
[3]*Department of Optometry, Central Taiwan University of Science and Technology, Taichung, Taiwan*
[4]*School of Medicine, Chung-Shan Medical University, Taichung, Taiwan*
[5]*School of Medicine, Kaohsiung Medical University, Kaohsiung, Taiwan*
[6]*Department of Optometry, Da-Yeh University, Changhua, Taiwan*

Correspondence should be addressed to San-Ni Chen; 108562@cch.org.tw

Received 5 January 2021; Revised 23 March 2021; Accepted 4 April 2021; Published 15 April 2021

Academic Editor: Ogugua Okonkwo

Copyright © 2021 Yen-Chih Chen and San-Ni Chen. This is an open access article distributed under the Creative Commons Attribution License, which permits unrestricted use, distribution, and reproduction in any medium, provided the original work is properly cited.

Purpose. To report a rare complication presenting as an isolated central epiretinal membrane (ERM) related to fovea-sparing internal limiting membrane (ILM) peeling technique. *Methods*. Five patients who received fovea-sparing ILM peeling were enrolled. Postoperatively, an isolated central ERM developed. Optical coherence tomography (OCT) was used to evaluate the serial anatomic change. *Results*. Among the five included patients, one patient had high myopia with foveoschisis, two patients had vitreomacular traction, and two patients had proliferative diabetic retinopathy with tractional retinal detachment and a fovea cyst. With an average of 5.80 months, OCT showed the gradual development of the isolated central ERM with severe fovea distortion. Four patients received secondary revision surgery, with improvement of the fovea contour and visual acuity. *Conclusion*. The fovea-sparing ILM peeling technique may cause a rare but serious complication as the isolated central ERM, which would cause significant fovea distortion as well as visual deterioration. Timely detection and intervention is recommended to prevent further visual loss. This trial is registered with NCT04445142.

1. Introduction

Internal limiting membrane (ILM) peeling is considered as a fundamental step in vitreomacular surgery, including epiretinal membrane (ERM), lamellar macular holes, full-thickness macular holes (MH), and even for diseases such as diabetic macular edema and retinal vein occlusion [1–4]. Recently, a fovea-sparing ILM peeling method was introduced, which aims to remove a ring of the ILM around the macula while sparing a small portion of the ILM tissue over the fovea. It was found to be safer and to have a better functional outcome than complete ILM peeling, especially for cases with myopic foveoschisis [5] and small size full-thickness MH [6, 7].

However, it is known that ERM may occur without ILM peeling. For patients who underwent fovea-sparing ILM peeling, the central residual ILM may easily cause secondary ERM formation exclusively on the foveal tissue. So far, the number of studies reporting complications regarding fovea-sparing ILM peeling is limited. Here, we report a case series of patients who had undergone fovea-sparing ILM peeling and later developed an isolated central ERM associated with foveal distortion and visual acuity impairment.

2. Materials and Methods

This was a retrospective case series. Patients who underwent fovea-sparing ILM peeling from January 2019 to July 2020 who developed an isolated central ERM were included. All

Table 1: Demographic data of patients.

Case/age/sex/eye	Diagnosis	Time interval of ERM development (months)	Best-corrected visual acuity (logMAR)			Central fovea thickness (um)		
			Before 1st surgery	Before revision surgery	After revision surgery	Before 1st surgery	Before revision surgery	After revision surgery
1/47/F/OD	High myopia with VMT	6	0.2	0.4	0.1	372	390	360
2/10/M/OS	High myopia with foveoschisis	4	1.6	0.7	0.5	428	404	204*
3/54/F/OD	High myopia with VMT	10	0.7	0.5	0.3	532	468	395
4/38/M/OD	PDR + TRD	3	0.5	1.6	0.5	592	465	247
5/40/M/OD	PDR + fovea cyst	6	0.2	1	1	508	569	440

*No revision surgery due to spontaneous membrane peeling. F: female; M: male; PDR: proliferative diabetic retinopathy; VMT: vitreomacular traction; TRD: tractional retinal detachment.

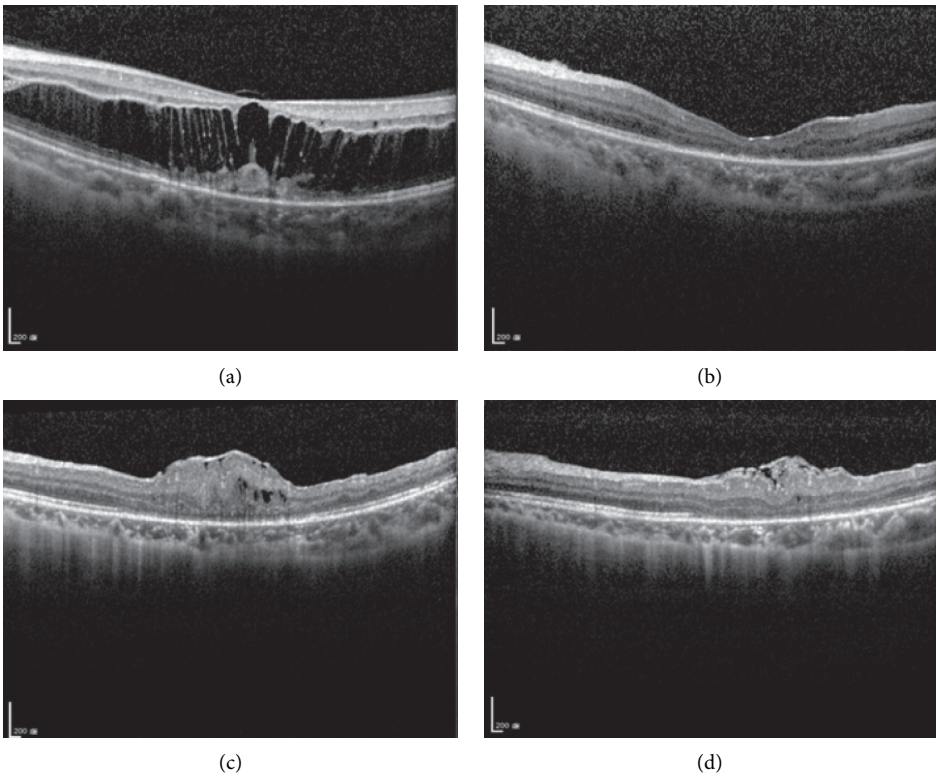

Figure 1: Example of the isolated central epiretinal membrane (ERM) development after fovea-sparing internal limiting membrane (ILM) peeling technique in a case with myopic foveoschisis (case 2). (*a*) A 10-year-old boy had pathologic myopia and macular foveoschisis of the left eye. The best-corrected visual acuity of his left eye was 20/80. He received vitrectomy with fovea-sparing ILM peeling. (*b*) Postoperatively, the foveoschisis improved. (*c*) However, 3 months later, an isolated central fovea ERM gradually developed, and optical coherence tomography (OCT) demonstrated severe contraction of the ERM with bulging fovea contour. The central fovea thickness (CFT) was 404 μm, and his visual acuity deteriorated to 20/100. (*d*) 1 month later, follow-up OCT showed spontaneous peeling of the central ERM with decreased fovea distortion. The CFT improved to 204 μm, and the second revision surgery was therefore postponed.

patients had regular follow-up at our clinic and had undergone ophthalmic examination including visual acuity, slit lamp biomicroscopy, and fundus ophthalmoscopy at each visit. The surgical technique of fovea-sparing ILM peeling was performed as previously described [7]. Spectral domain optical coherence tomography (OCT) (Heidelberg Spectralis; Heidelberg Engineering, Heidelberg, Germany) was used to examine the postoperative anatomy of the retina. The first and second operations were performed by a single and experienced surgeon (SN Chen). The study had the approval

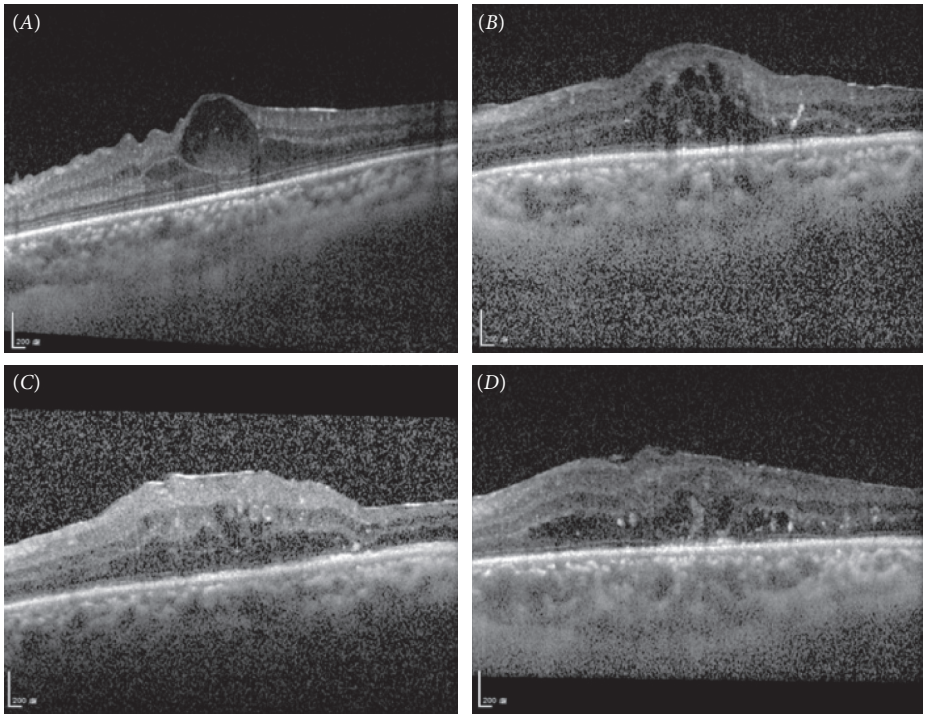

Figure 2: Example of the isolated central epiretinal membrane (ERM) development after fovea-sparing internal limiting membrane (ILM) peeling technique in a case with proliferative diabetic retinopathy with a fovea cyst (case 5). (*A*) A 39-year-old male patient had proliferative diabetic retinopathy and a fovea cyst with very thin fovea tissue. He received vitrectomy due to persistent macular edema despite several antivascular endothelial growth factor injections. During vitrectomy, concerning the very thin fovea tissue, we performed fovea-sparing ILM peeling to prevent inadvertent avulsion of fovea tissue. However, after the surgery, optical coherence tomography (OCT) showed the development of isolated central ERM formation with progression 1 month (*B*) and 3 months (*C*) later. The central fovea thickness (CFT) was 569 μm, and his visual acuity deteriorated to 20/400. We arranged second surgery to remove the central ERM and residual fovea ILM. (*D*) After second surgery, OCT showed improvement in fovea contour. Three months after the revision surgery, the CFT improved to 440 μm, and his visual acuity was 20/100.

of the Institutional Review Board of Changhua Christian Hospital and was performed in accordance with the World Medical Association's Declaration of Helsinki.

3. Statistical Analysis

The statistical analysis was performed using MedCalc software version 19.6.1 (MedCalc Software, Mariakerke, Belgium). The best-corrected visual acuity (BCVA) was converted to the logarithm of the minimal angle of resolution (logMAR) equivalent for statistical analysis. For the four patients receiving revision surgery, Wilcoxon sign rank test was performed to compare the differences of BCVA and central fovea thickness (CFT) on OCT before and after revision surgery. In all analyses, a p value < 0.05 was considered statistically significant.

4. Results

During the inclusion period, 46 patients underwent fovea-sparing ILM peeling surgery. During the follow-up period, five patients were noted to have developed isolated central ERM. The demographics and clinical features of the five patients are reported in Table 1.

There were three high myopia patients; one patient developed foveoschisis (Figure 1), and two patients developed vitreomacular traction (VMT).

Two patients had proliferative diabetic retinopathy; one patient developed tractional retinal detachment, and one patient developed a foveal cyst (Figure 2).

All patients underwent vitrectomy followed by fovea-sparing ILM peeling to prevent damage to the foveal tissue during membrane peeling. For all patients, triamcinolone acetonide was routinely used to stain the vitreous during vitrectomy, and 0.05% indocyanine green (ICG) was used to stain the ILM. Postoperatively, serial OCT revealed the formation of an isolated central ERM with severe contraction at an average of 5.80 ± 2.68 months following surgery. The central ERM caused severe foveal distortion and visual impairment. Four patients underwent revision surgery to remove the central ERM, while one patient (case 2) experienced spontaneous peeling of the central ERM, which was detected on follow-up OCT. For the four patients receiving revision surgery, postoperative mean CFT on OCT, although nonstatistically significant, showed marked improvement (from 473.00 ± 73.47 μm to 360.50 ± 82.45 μm, $p = 0.06$). However, the mean BCVA did not improve significantly (from 0.88 ± 0.55 to 0.48 ± 0.39 in logMAR, $p = 0.20$).

5. Discussion

Fovea-sparing ILM peeling was recently introduced as a safer surgical alternative in cases wherein MH are present or there is impending macular hole formation as it has a lower rate of secondary macular hole formation or foveal thinning [5–7]. According to the authors, the rationale for sparing the ILM is to preserve the delicate anatomy of the fovea, thereby avoiding further loss of the foveal tissue. However, in this case series, we observed a unique pattern of isolated central ERM formation on the residual central foveal ILM in patients who underwent fovea-sparing ILM peeling. The isolated central ERM caused marked foveal distortion on OCT as well as significant visual impairment.

Sparing the foveal ILM has the theoretical advantage of avoiding iatrogenic damage and preserving the end processes of the Müller cells, which are the main structural elements in the physiology of the cones in this area. In addition to a better anatomic outcome, fovea-sparing ILM peeling was reported to have better retinal sensitivity on microperimetry compared with conventional complete ILM peeling in patients with myopic macular retinoschisis [8], macular pucker [9], degenerative lamellar macular hole [10], and full-thickness macular hole [11]. However, glial cells proliferating over the residual central ILM that cause the formation and contraction of the ERM may cause visual impairment after fovea-sparing ILM peeling. An ERM is an avascular and fibrocellular membrane that proliferates on the inner surface of the retina. The ILM is known as a scaffold for cell proliferation and secondary ERM formation. It was reported in previous literature that recurrent ERM was more often observed in cases without ILM peeling [12–14].

The complication of a secondary central ERM resulting from fovea-sparing ILM peeling is rarely reported. In the study by Russo et al. [9], the authors reported that three out of 19 (15.7%) macular pucker patients who underwent fovea-sparing ILM peeling developed recurrent ERM requiring revision surgery to regain vision. However, the authors did not report the unique pattern of isolated central ERM on OCT. From our report, 46 patients underwent fovea-sparing ILM peeling during the inclusion period, and five of these patients developed an isolated central ERM, with an overall occurrence rate of 10.9%. It is speculated that since the parafoveal ILM had been removed, the residual central ILM may be the primary site for fibrocellular membrane proliferation. The centripetal contraction of the membrane would cause severe foveal distortion on follow-up serial OCT.

In our case series, there were two high myopia patients with VMT and one patient with myopic foveoschisis. It is recognized that a secondary macular hole is frequently seen in cases with myopic foveoschisis due to the extremely thin foveolar tissue [15]. To prevent the development of a postoperative macular hole, fovea-sparing ILM peeling was performed. Although the foveoschisis significantly improved on immediate postoperative OCT, an isolated central ERM eventually developed after an average of six months.

From our report, one of our case of myopic foveoschisis was a 10-year-old child. Pediatric ERMs are most commonly associated with trauma and uveitis [16]. We therefore speculated that ocular surgery itself causes surgical trauma, and the marked postoperative inflammation may hasten the development of an isolated central ERM. Although the revision surgery would improve the foveal contour and visual acuity, we observed that the spontaneous peeling of the ERM was accompanied by an improvement in visual acuity in that boy. Spontaneous ERM peeling in young patients is rare. It is believed that when the contracting forces of the ERM are stronger than its adhesions to the retina, the membrane may separate spontaneously [17]. This phenomenon also implies that the isolated central ERM in young patients would develop and contract to a greater degree with time. However, we are uncertain about the incidence of spontaneous ERM peeling without revision surgery. The timing of the revision surgery must be further investigated in the future.

On the other hand, two patients in our case series had diabetic retinopathy; one patient developed tractional retinal detachment, and one patient developed a foveal cyst. So far, there have been no studies on using fovea-sparing ILM peeling in those with diabetic retinopathy. Theoretically, peeling ILM over the fovea may carry a higher risk of postoperative macular hole formation in patients with tractional retinal detachment and foveal cysts, owing to the very thin foveolar tissue. Therefore, we chose to spare the central foveal ILM in these patients. Unfortunately, an isolated central ERM developed postoperatively in both patients. In proliferative diabetic retinopathy, excessive cytokines or growth factors secondary to changes in vascular permeability and retinal ischemia would more easily stimulate glial proliferation and cause the formation of a central ERM [18]. The formation of an isolated central ERM may predispose these patients to diabetic macular edema which will worsen visual acuity. Therefore, caution should be observed when using this technique in patients with diabetic retinopathy.

In our report, four patients required revision surgery after an average follow-up of 5.8 months. By removing the central ERM and foveal ILM, we observed that the foveal thickness as well as visual acuity although not statistically significantly but both showed marked improvement. To improve on this study, longer follow-up periods and a larger number of cases are necessary to evaluate the possible long-term effects of an isolated central ERM and the role of revision surgery on foveal contour and visual acuity.

To the best of our knowledge, this is the first report describing the rare complication of an isolated central ERM on serial OCT in patients who underwent fovea-sparing ILM peeling. However, there are several limitations in our report. First, owing to the rarity of the complication, the number of patients included in the study was small. The five patients in our case series are heterogenous, and the results of the analysis may not be conclusive. However, an analysis comparing only either idiopathic ERM or PDR-related ERM would be difficult. Larger studies and more cases are needed to make a subgroup analysis and analyze the possible risk factors contributing to this complication, respectively.

Second, although we report the rare complication of an isolated central ERM from our patients who underwent fovea-sparing ILM peeling, it is still uncertain if this technique would directly contribute to the formation of an isolated central ERM. Recurrent and residual ERM are commonly observed after conventional ILM peeling. However, the unique pattern of an isolated central ERM is rarely observed. Since the case number is relatively small, larger cohort studies would be needed to prove this assumption. Third, some of our patients already had an ERM prior to undergoing fovea-sparing ILM peeling. During fovea-sparing ILM peeling, both the ERM and ILM at the parafoveal area were removed. However, it is uncertain whether the ERM recently developed or was a recurrence from the peripheral areas. Closer postoperative follow-up visits with OCT may clarify this.

6. Conclusion

In conclusion, although the fovea-sparing ILM peeling technique is theoretically more beneficial than complete ILM peeling, we had demonstrated the rare complication as formation of an isolated central ERM. The central ERM would contract progressively and cause significant visual impairment. Most patients required revision surgery to regain foveal contour and visual acuity. Timely detection and intervention is recommended.

Data Availability

The data used to support the findings of this study are available from the corresponding author upon request.

Ethical Approval

This retrospective chart review study was approved by IRB review. It should be noted that this article does not contain any personal medical information about an identifiable living individual.

Conflicts of Interest

The authors declare that there are no conflicts of interest regarding the publication of this article.

References

[1] T. Yamamoto, N. Akabane, and S. Takeuchi, "Vitrectomy for diabetic macular edema: the role of posterior vitreous detachment and epimacular membrane," *American Journal of Ophthalmology*, vol. 132, no. 3, pp. 369–377, 2001.

[2] N. Lois, J. Burr, J. Norrie et al., "Internal limiting membrane peeling versus no peeling for idiopathic full-thickness macular hole: a pragmatic randomized controlled trial," *Investigative Opthalmology & Visual Science*, vol. 52, no. 3, pp. 1586–1592, 2011.

[3] L. Ternent, L. Vale, C. Boachie, J. M. Burr, and N. Lois, "Cost-effectiveness of internal limiting membrane peeling versus no peeling for patients with an idiopathic full-thickness macular hole: results from a randomised controlled trial," *British Journal of Ophthalmology*, vol. 96, no. 3, pp. 438–443, 2012.

[4] A. Almony, E. Nudleman, G. K. Shah et al., "Techniques, rationale, and outcomes of internal limiting membrane peeling," *Retina*, vol. 32, no. 5, pp. 877–891, 2012.

[5] N. Shimada, Y. Sugamoto, M. Ogawa, H. Takase, and K. Ohno-Matsui, "Fovea-sparing internal limiting membrane peeling for myopic traction maculopathy," *American Journal of Ophthalmology*, vol. 154, no. 4, pp. 693–701, 2012.

[6] T.-C. Ho, C.-M. Yang, J.-S. Huang, C.-H. Yang, and M.-S. Chen, "Foveola nonpeeling internal limiting membrane surgery to prevent inner retinal damages in early stage 2 idiopathic macula hole," *Graefe's Archive for Clinical and Experimental Ophthalmology*, vol. 252, no. 10, pp. 1553–1560, 2014.

[7] T.-C. Ho, C.-M. Yang, J.-S. Huang et al., "Long-term outcome of foveolar internal limiting membrane nonpeeling for myopic traction maculopathy," *Retina*, vol. 34, no. 9, pp. 1833–1840, 2014.

[8] K. Shinohara, N. Shimada, H. Takase et al., "Functional and structural outcomes after fovea-sparing internal limiting membrane peeling for myopic macular retinoschisis by microperimetry," *Retina*, vol. 8, 2019.

[9] A. Russo, F. Morescalchi, E. Gambicorti, A. Cancarini, C. Costagliola, and F. Semeraro, "Epiretinal membrane removal with foveal-sparing internal limiting membrane peeling," *Retina*, vol. 39, no. 11, pp. 2116–2124, 2019.

[10] F. Morescalchi, A. Russo, E. Gambicorti et al., "Peeling of the internal limiting membrane with foveal sparing for treatment of degenerative lamellar hole," *Retina*, vol. 8, 2019.

[11] F. Morescalchi, A. Russo, H. Bahja et al., "Fovea-sparing versus complete internal limiting membrane peeling in vitrectomy for the treatment of macular holes," *Retina*, vol. 4, 2019.

[12] R. Grewing and U. Mester, "Results of surgery for epiretinal membranes and their recurrences," *British Journal of Ophthalmology*, vol. 80, no. 4, pp. 323–326, 1996.

[13] E. H. Bovey, S. Uffer, and F. Achache, "Surgery for epimacular membrane," *Retina*, vol. 24, no. 5, pp. 728–735, 2004.

[14] D. W. Park, P. U. Dugel, J. Garda et al., "Macular pucker removal with and without internal limiting membrane peeling: pilot study," *Ophthalmology*, vol. 110, no. 1, pp. 62–64, 2003.

[15] D. Gaucher, B. Haouchine, R. Tadayoni et al., "Long-term follow-up of high myopic foveoschisis: natural course and surgical outcome," *American Journal of Ophthalmology*, vol. 143, no. 3, pp. 455–462, 2007.

[16] H. A. Khaja, C. A. McCannel, N. N. Diehl et al., "Incidence and clinical characteristics of epiretinal membranes in children," *Archives of Ophthalmology*, vol. 126, no. 5, pp. 632–636, 2008.

[17] C. Harada, T. Harada, Y Mitamura et al., "Diverse NF-kappaB expression in epiretinal membranes after human diabetic retinopathy and proliferative vitreoretinopathy," *Molecular Vision*, vol. 10, pp. 31–36, 2004.

[18] S. Yoshida, Y. Kobayashi, S. Nakao et al., "Differential association of elevated inflammatory cytokines with postoperative fibrous proliferation and neovascularization after unsuccessful vitrectomy in eyes with proliferative diabetic retinopathy," *Clinical Ophthalmology*, vol. 11, pp. 1697–1705, 2017.