Advances in Urology

Management of Upper Tract Urothelial Carcinoma

Guest Editor: Norm D. Smith

Management of Upper Tract Urothelial Carcinoma

Advances in Urology

Management of Upper Tract Urothelial Carcinoma

Guest Editor: Norm D. Smith

Contents

Hindawi Publishing Corporation
Advances in Urology
Volume 2009, Article ID 492462, 1 page
doi:10.1155/2009/492462

Editorial

Management of Upper Tract Urothelial Carcinoma

Norm D. Smith

The Robert H. Lurie Comprehensive Cancer Center and Department of Urology, Feinberg School of Medicine, Northwestern University, Chicago, IL 60611-3008, USA

Correspondence should be addressed to Norm D. Smith, n-smith3@northwestern.edu

Received 30 December 2008; Accepted 30 December 2008

Upper tract urothelial carcinoma (UTUC) of the kidney and ureter is a rare neoplasm with roughly 3000 cases diagnosed in the United States in 2007, compared to approximately 67000 cases of bladder cancer. UTUC accounts for approximately 10% of cancers arising from the kidney and less than 5% of all urothelial malignancies. Predominantly due to the rarity of the disease, there is only limited data to guide clinicians in decision making which consists mostly of small retrospective studies and expert opinion. As such, this special issue of Advances in Urology "Comprehensive Management of Upper Tract Urothelial Carcinoma" focuses both on controversies in management as well as practical issues in the care of patients with UTUC. As the Guest Editor, my goal has been to ask a series of questions and seek answers from international experts in the field.

The first practical matter is to address when endoscopic management of UTUC is appropriate? Our first article "Endoscopic Management of Upper Tract Urothelial Carcinoma" by Katie Moore et al. addresses this issue generally. Then, the paper entitled "Endourologic Management of Upper Tract Transitional Cell Carcinoma Following Cystectomy and Urinary Diversion" by Jeffrey John Tomaszewski et al. tackles the difficult situation of UTUC after radical cystectomy and urinary diversion. Finally, after initial endoscopic management of UTUC, what is the role of upper tract topical chemotherapy or BCG? This topic is the subject of the paper entitled "Review of Topical Treatment of Upper Tract Urothelial Carcinoma" by Kenneth G. Nepple et al.

The next issue of focus is the clinical scenario when UTUC cannot be managed endoscopically. Are laparoscopic and open nephroureterectomy equivalent operations? What is the best way to handle the distal ureter and bladder cuff? These challenging topics are addressed by a series of articles: "Laparoscopic Nephroureterectomy: Oncologic Outcomes and Management of Distal Ureter: Review of the Literature" by Andre Berger and Amr Fergany, "Laparoscopic Nephroureterectomy: The Distal Ureteral Dilemma" by Shalom Srirangam et al., as well as "Laparoscopic Nephroureterectomy and Management of the Distal Ureter: A Review of Current Techniques and Outcomes" by Davis Viprakasit et al. Regardless of open versus laparoscopic approaches to nephroureterectomy, what is the role and extent of lymphadenectomy in the management of UTUC? This critical issue is dealt with in the paper entitled "Retroperitoneal Lymph Nodes in Transitional Cell Carcinoma of the Kidney and Ureter" by Shilajit D. Kundu and Scott E. Eggener.

The last matter is the management of patients with locally advanced or metastatic UTUC. Is there a role for adjuvant chemotherapy? What are the best agents for metastatic UTUC? Can data from bladder cancer be applied to the upper tracts? These timely topics are concentrated upon in the article "The Role of Chemotherapy in Upper Tract Urothelial Carcinoma" by Peter H ODonnell and Walter M. Stadler. Finally, these various issues are brought together and placed into perspective in the review entitled "Comprehensive Management of Upper Tract Urothelial Carcinoma" by Georgios Koukourakis et al.

It has been my privilege to serve as the Guest Editor for this special issue of Advances in Urology "Comprehensive Management of Upper Tract Urothelial Carcinoma."

Norm D. Smith

Hindawi Publishing Corporation
Advances in Urology
Volume 2009, Article ID 620604, 6 pages
doi:10.1155/2009/620604

Review Article

Endoscopic Management of Upper Tract Urothelial Carcinoma

K. Moore, J. Khastgir, and M. Ghei

Department of Urology, Morriston Hospital, Swansea SA6 6NL, UK

Correspondence should be addressed to K. Moore, katiemoore@doctors.org.uk

Received 1 May 2008; Accepted 3 November 2008

Recommended by Norm D. Smith

Nephroureterectomy is currently the gold standard for management of upper urinary tract urothelial carcinoma despite it results. This review article in the loss of a renal unit. The ultimate aim of endoscopic management of this condition is cancer control whilst preserving renal function and the integrity of the urinary tract. Endoscopic treatments of upper tract TCC include the antegrade percutaneous and retrograde ureteroscopic approaches. This review article summarizes the endoscopic management of upper tract urothelial carcinoma, surveillance of the disease after endoscopic management and adjuvant therapy. The main message regarding endoscopic management of upper tract urothelial cancer is that patients must be carefully selected. Patient selection is based on tumour size, grade, and multifocality. Single low-grade tumours, less than 1.5 cm in size, generally have a good outcome with endoscopic treatment provided that they have regular ureteroscopic surveillance. Ureteroscopic treatment of high-grade tumours is essentially palliative. It is essential that patients are motivated and compliant as lifetime follow-up is necessary. However, until large randomized trials with long-term follow-up are performed, endoscopic management cannot be considered a standard treatment and should be limited to poor performance status patients.

1. Introduction

Primary urothelial carcinoma of the upper urinary tract accounts for 5% of all urothelialtumours and 7–10% of all kidney tumours. Nephroureterectomy including a cuff of bladder has been the "gold standard" treatment despite the associated morbidity and loss of a renal unit. Currently, laparoscopic approaches have reduced the size of the incision, length of hospital stay, postoperative pain, and morbidity and give oncological outcomes similar to those of open surgery. However, a laparoscopic nephroureterectomy is still radical surgery that does not spare the renal parenchyma.

The ultimate aim of endoscopic management is cancer control whilst preserving renal function and the integrity of the urinary tract. These procedures were initially reserved for patients with solitary kidneys, bilateral disease, or renal insufficiency but are starting to gain acceptance in the management of small, low-stage, low-grade tumours in patients with normal contralateral kidneys. Endoscopic treatment of the upper urinary tract includes antegrade percutaneous and retrograde ureteroscopic approaches which were first described in the mid 1980s.

2. Tumour Grade and Stage

A key point in choosing the optimum treatment for upper tract urothelial carcinoma is correct staging by endoscopic evaluation and biopsy. There are significant differences in 5 year survival rates ranging from 60–90% in Ta/1 and CIS disease to only 5% in T3/4 disease. The most important factors for survival are tumour stage, grade, and multifocality [1].

In a study of 130 consecutive nephroureterectomy specimens, tumour stage significantly correlated with tumour grade. Five percent of patients with low-grade UTUC had pathologic stage pT2 or higher, while 65% of patients with high-grade tumours had pathologic stage pT2 or higher [2]. Similarly, Murphy et al. reported that 47 of 49 patients (96%) with grade 1 upper tract transitional cell carcinoma also had stage 1 disease [3].

Tumour grade is also related to recurrence rate with Zincke reporting that only 5% of 21 patients with grade 1 or 2 developed a recurrence compared with 50% with grade 3 or 4 disease [4]. Orihela reported that in 14 patients recurrences were almost exclusively in those with multifocal, high-grade, invasive tumours [5]. In general, recurrences are unlikely in

patients with single, low grade small tumours confined to the mucosa with no history of concurrent urothelial tumours elsewhere in the urinary tract. Upper tract recurrence rates were 28.5% in a group with ahistory of bladder lesions compared to 16.6% in a group without bladder disease [6].

However, diagnosis of ureteric lesions is not straight forward. In a study by El-Hakim et al., ureteroscopic appearances of upper tract urothelial carcinoma was only 70% accurate in determining the grade and they suggested biopsies must be taken to in order to determine the true grade [7]. In contrast, a study by Keeley et al. showed transitional cell carcinoma grade on ureteroscopy accurately predicted tumour grade and stage in the surgical specimens. They observed that, of the 30 low or moderate grade ureteroscopic specimens, 27 (90%) proved to be low or moderate grade transitional cell carcinoma in the surgical specimens, while 11 of 12 high grade ureteroscopic specimens (91.6%) proved to be high grade transitional cell carcinoma ($P < .0001$). In 30 low or moderate grade ureteroscopic specimens, 26 (86.6%) had a low stage (Ta or T1) tumour. In contrast, 8 of 12 high grade ureteroscopic specimens (66.7%) had invasive tumour (stage T2 or T3) in the surgical specimen ($P = .0006$) [8]. Thesesame authors also noted how crucial the techniques for handling and processing the small samples obtained via ureteroscopy are. They found that sending multiple samples, including saline washes before and after biopsy, improved the ability to grade tumours ureteroscopically from 42.9% to 90% [8] .

A further study by Williams et al. to determine the accuracy of ureteroscopic biopsy in predicting the histopathology of upper tract TCC looked at 30 biopsies taken between 1998 and 2006. At nephroureterectomy, 2 cases were found to have no tumour. Of the remaining 28 cases, the biopsy grade proved to be identical in 21 (75%). 17 of 25 (68%) of grade 1-2 ureteroscopic specimens had a low stage (T0, Ta, or T1) tumour. In contrast, 3 of 5 (60%) high grade specimens had invasive tumour (T2 or T3). They concluded that ureteroscopic inspection and biopsy provided accurate information regarding the grade and stage of upper tract TCC [9].

Tumour size also appears to influence recurrence rate. One study reported that only 7 of 19 renal units (36%) with tumours larger than 1.5 cm were ever rendered tumour free and 3 of 6 tumour free renal units subsequently developed a recurrence. In contrast, 20 of 22 (91%) of renal units with initial tumours less than 1.5 cm were rendered tumour free and only 5 (25%) tumour free kidneys had recurrences [10]. This finding was echoed by Johnson et al. who found that patients presenting with tumours >1.5 cm in size had ahigher incidence of recurrence and recurred earlier [11]. Johnson et al. confirmed the aggressive nature of high grade disease. In a cohort of 63 patients, tumour progression was seen in 83% of patients with high grade ureteric urothelial carcinoma when nephroureterectomy was not performed [11].

3. Ureteroscopic Management

Developments in ureteroscopic instruments and techniques now allow for ureteroscopic access to the entire upper urinary tract. Small diameter rigid and flexible ureteroscopies with greater deflecting abilities have been combined with endoscopic biopsy techniques and devices for tissue ablation to offer practical approaches to upper urinary tract tumours. Particularly, the holmium:YAG and neodymium:YAG lasers used to cauterize and ablate tumours, delivered through small-diameter, flexible fibres, have allowed treatment of relatively large tumours whilst maintaining homeostasis [11]. Electrosurgical techniques were first used for the treatment of ureteric neoplasms. They are used in a similar way to resectoscopes for other procedures but because of the rigid design of the resectoscope, its use is primarily confined to the distal ureter. Given the thin wall of the ureter, care should be taken to avoid resecting through the full thickness of the wall and also to avoid fulgurating a large area of the ureter as this increases the chances of subsequent stricture formation. Simple fulguration with an electrocautery probe is another electrosurgical technique suitable for very small lesions or for the base of the tumour after removal of the bulk of the lesion [12].

The neodymium:YAG laser has been used widely for the treatment of both bladder and upper tract tumours. The fibre is directed at and placed in close approximation to the tumour, activated at 20 to 30 w and moved over the surface to coagulate the tissue. The laser penetrates to a depth of 5-6 mm. The coagulated tissue is removed with graspers to expose further portions of the tumour which can be treated in the same fashion.

The holmium:YAG laser both coagulates and ablates tissue penetrating to a depth of 0.5 mm. This is useful for ureteric lesions as it can ablate and remove an occlusive tumour opening up the lumen. Irrigation is needed to clear the visual field of tissue debris during treatment.

The two lasers can be used in combination. The neodymium:YAG laser, penetrating to a depth of several millimetres, is used to coagulate the major volume of the tumour, then the coagulated tissue can be removed with the holmium:YAG laser [12].

Schmeller compared laser ablation with electrocautery and found fewer strictures developed in the laser group [13]. However, Martinez-Pineiro et al. found that their laser results did not offer significant benefit compared with electrocautery [6]. Data on electrocautery versus laser treatment is scant (probably due to the small cohort of patients being treated in this manner) but to date there is no convincing evidence that the efficacy of tumour destruction is affected by the method used.

All ureteroscopic interventions should be followed with short term ureteral stenting to prevent any postoperative obstructive sequelae [12].

Complications of ureteroscopic management occur in 8–13% and are mostly minor including perforation in 1-4% (managed by ureteric stenting or percutaneous drainage) and ureteric strictures in 4.9–13.6%. Most strictures can be managed by stenting, laser incision, or balloon dilatation [14].

In a study by Keeley et al., between 1985 and 1995, 92 patients were diagnosed with upper tract TCC. 46 had a diagnostic ureteroscopy followed by open extirpation

and 46 had some form of endoscopic treatment. 8/46 had open surgery following endoscopic therapy and 38 (41 kidneys) had ureteroscopic treatment and follow-up. Semirigid and flexible ureteroscopes were used to examine the collecting system, tumours were biopsied then treated with fulguration, the neodymium:YAG laser and/or the holmium:YAG laser. Patients were treated every 6 to 12 weeks until tumour free and then followed up with further ureteroscopy. At least 1 follow-up ureteroscopic examination was performed in all 38 patients. Of the 41 renal units, 28 (68%) were rendered tumour free after an average of 1.57 ureteroscopic treatments. Complications were generally related to comorbid disease, 1 patient with a solitary kidney developed an episode of acute renal failure with clot retention but recovered to baseline renal function. No patient required a blood transfusion or emergency open surgery for bleeding. 2 patients had ureteric strictures, 1 with a history of pelvic radiotherapy for bladder cancer and 1 following neodymium:YAG laser treatment of a proximal ureteric tumour. No ureteric perforations were noted [10].

Chen and Bagley followed 23 patients with a normal contralateral kidney for a mean of 35 months after initial ureteroscopic treatment of upper tract transitional cell carcinoma (range 8 to 103). 22 tumours were grade 1 to 2 and 1 was grade 2 to 3. There were multiple recurrences (treated ureteroscopically) in 15 of 23 patients (65%) and no recurrences in 8 (35%). Average time to recurrence was 9.5 months (range 2 to 53) with an average of 4 recurrences (1 to 14). There were no metastases or mortality from transitional cell carcinoma. At completion of the study, 4 patients (17%) had persistent disease and 4 (17%) elected to undergo nephroureterectomy. Complications included ureteral strictures in 2 patients treated for distal ureteral tumours. The strictures were treated with endoscopic dilation [15].

A study from Madrid reported a failure of ureteroscopy in 11 of 39 patients (28.2%), mainly due to inability to reach pelvic tumours or to destroy the tumour. Four of these patients were successfully treated by a percutaneous approach and 7 required nephroureterectomy [6]. Similarly, Blute et al. reported a high ureteroscopic failure rate in 14/22 (63.6%) of patients with renal pelvic tumours, indicating that ureteroscopy is not the best procedure for most tumours of the renal pelvis and that these neoplasms are best managed percutaneously [16].

4. Percutaneous Nephroscopic Management

Although ureteroscopy has the theoretical benefit of preserving a closed urinary system, percutaneous access may be necessary when tumours are not accessible via a retrograde route or for larger tumours. Percutaneous nephroscopy offers better visualisation of the renal pelvis while accommodating larger calibre instruments capable of handling a larger tumour burden [12].

After establishing a percutaneous tract, the lesion is initially biopsied and then bebulked. As there is a larger access tract, cold cup biopsy forceps can be used through a standard nephroscope or a cutting loop from a resectoscope. The base of the lesion is resected and sent for histological evaluation and haemostasis is achieved by electrocauterey or laser ablation as previously described. The established nephrostomy tract can be maintained, allowing for repeated treatment or administration of topical adjuvant therapy [12].

Complication rates with the percutaneous approach are low and include blood transfusion in <20% and less commonly, PUJ obstruction from stricture, adjacent organ injury, and pleural injury [1]. Tumour seeding along the nephrostomy tract has been reported [17]. Larger series though, failed to find tract recurrences confirming that this phenomenon is rare. Precautions suggested to minimize seeding include use of an Amplatz sheath to decrease intrarenal pressure during manipulations and immediate irrigation of the collecting system and percutaneous tract with a 5-florouracil solution. One author suggested placing a radioactive iridium wire in the percutaneous tract [18].

Goel et al. reported on 5 year outcomes of 24 patients who underwent primary percutaneous resection of the urothelial tumour. Patients with low stage pT0-1 disease were treated primarily with percutaneous surgery. Patients with multi-segmental pelvicaliceal system involvement, stage greater than pT1, high grade histology or additional ureteral tumours were considered for nephroureterectomy. Topical chemotherapy (mitomycin C or epirubicin) was administered via nephrostomy tube or intravesical instillation after Double-J stent insertion. Surveillance included upper tract cytology, nephroscopy or fiberoptic ureterorenoscopy.

Of the 24, 2 cases had squamous cell carcinoma, 5 had grade 3 transitional cell carcinoma, 15 had grade 1 to 2 transitional cell carcinoma and 2 had no tumour. Control was established with initial percutaneous resection in 18 (75%) cases and second look nephroscopy in 4. All patients with high-grade disease died of malignancy except one (with no further treatment) and 6 of the 15 patients with low-grade noninvasive transitional cell carcinoma underwent nephroureterectomy during follow-up either due to progression of disease, concomitant tumour, or complications. Two patients with solitary kidneys died of renal failure unrelated to malignancy. High grade tumours or tumours greater than T1 were treated with nephroureterectomy early during management. There was no perioperative mortality and in 9 (60%) of the low-grade cases the kidneys were preserved at mean follow-up [19].

In a more recent study, Palou et al. retrospectively reviewed 34 patients who had percutaneous management of their upper tract TCC. 15% had grade 3 tumours with either asolitary kidney or bilateral disease. During a 4.25-year follow-up, recurrence was found in 44% at a median time of 24 months. 9 cases required nephroureterectomy. Renal preservation was achieved in 74%. Overall survival and cancer specific survival was 71% and 93%, respectively [20].

Rouprêt et al. reported on the results of 24 patients who underwent a percutaneous approach to their tumour. Median follow-up was 62 months with recurrences detected in 8/24 at a median time of 17 months. 3 recurrences were in the ipsilateral ureter, 1 in the contralateral ureter, and 4 in the bladder. Five patients with high grade and/or invasive tumour subsequently underwent an open nephroureterectomy, one immediately and the others during follow-up. 5/24

(20.8%) of the patients have died, and 4 of these deaths were attributed to disease progression. They reported 5-year disease specific survival rates as 79.5% and tumour free survival rates as 68%. 4 patients developed perioperative complications; 3 required blood transfusion and 1 developed a collection (which was managed with antibiotics) after inadvertent puncture of the bowel [21].

5. Surveillance

Unlike traditional management with nephroureterectomy, endoscopic treatment of upper tract TCC requires strict ureteroscopic surveillance as both the ureteroscopic and percutaneous approach are associated with a high risk of ipsilateral recurrence. Endoscopic follow-up has been shown to be more sensitive than radiological examination as IVU may miss up to 75% of small recurrences [9]. Surveillance ureteroscopy is usually performed at 3 and 6 months, then 6 monthly for a year, then annually, and it requires a counselled, well-motivated patients to strictly adhere to the follow-up protocol. Surveillance needs to be performed for an indefinite time interval as recurrences have been reported after 8 years of follow-up [22].

In an effort to reduce the anaesthetic risks, costs and time of surveillance, a study from New York reported on their 16 year experience of office-based ureteroscopy for surveillance of TCC after initial endoscopic ablation. 10 patients were treated with endoscopic ablation for TCC. A total of 67 (range 1 to 19 per patient) surveillance ureteroscopies were performed in the office setting. This procedure was performed without anaesthetic (only lignocaine jelly to the urethra) using a flexible ureteroscope. This revealed 7 upper tract TCC recurrences in 5 patients. A thorough ureteroscopic examination in the operating room revealed that only one patient had more extensive disease than was indicated in the office based ureteroscopy. All patients tolerated the office based procedure well with minimal discomfort. There were no acute complications [23].

Urinalysis with dipstick and microscopic examination is an attractive surveillance tool as it is noninvasive, inexpensive, and can be performed in an outpatient setting giving an immediate result. In patients with recurrent upper tract transitional cell carcinoma, urinalysis had a low sensitivity (36.3%) but high specificity (90.6%) in detecting recurrent disease. This low detection rate may be due to the low grade nature of most upper tract transitional cell carcinomas managed with local resection as low grade tumours are less likely to shed diagnostic cells [24]. In a series by Xia, voided cytologies were positive in 33% of grade 1, 71% of grade 2 and 100% of grade 3 upper tract tumours. In recent years adjunct diagnostic techniques such as immunocytologic staining or fluorescence in situ hybridisation have been used for evaluating the presence or absence of malignant cells in urine [25].

6. Adjuvant Therapy

A substantial proportion of patients with endoscopically managed upper tract urothelial carcinoma will develop a recurrence. Adjuvant topical immunotherapy or chemotherapies have been used in an attempt to reduce the risk of tumour recurrence. The most commonly instilled agents are mitomycin-C and BCG. Method of instillation, depending on the approach to the tumour, can be performed via a retrograde ureteral catheter or through a percutaneous nephrostomy tube. Most published reports involve few patients with short follow-up and a relatively high complication rate.

Orihuela and Smith found a lower recurrence rate (16.6% versus 80%) in those patients treated with BCG compared to those who did not recieve adjuvant treatment but a further study by the same group showed no survival advantage [5]. Sharpe et al. reported on the use of BCG via retrograde ureteral catheters in 17 kidneys of 11 patients with abnormal cytology. At a mean follow-up of 36 months cytology had normalised in 8 of 11 patients. 1 patient developed a fever and was treated with antituberculous drugs. In a further study of 18 patients treated with BCG, 7 developed fever on 14 occasions and 1 patient died of sepsis despite prophylactic IV antibiotics. In terms of efficacy, no significant difference was found between the patients treated with BCG and those who were not [26].

Keele et al. looked at 19 patients who underwent a total of 28 treatments with mitomycin C after ureteroscopic treatment for high volume, recurrent or multifocal disease. Following 1 to 4 treatments with MMC, 11 of 19 (58%) were rendered free of disease, 4 required nephroureterectomy for persistent or recurrent disease and no patients developed local or distant progression of disease or any significant side effects [26]. In a study that reported on 14 patients who received MMC, one patient died of aplastic anaemia and sepsis secondary to extravasation during treatment. This same study also found a lower rate of recurrence among patients treated with MMC or BCG compared to those treated with thiotepa or oral 5-fluorouracil [6].

As yet, no study has shown statistical improvement regarding survival and recurrence rates and no protocol of treatment has been accepted. Randomized multicenter trials are needed to assess the efficacy of adjuvant agents.

7. Endoscopic Treatment versus Radical Nephroureterectomy

Rouprêt et al. compared the outcomes in patients who had undergone either open nephroureterectomy or endoscopic surgery (ureteroscopic or percutaneous management) for upper urinary tract transitional cell carcinoma. A retrospective review of the data for patients treated surgically for upper urinary tract transitional cell carcinoma from 1990 to 2004 was performed. Data were analyzed for 97 patients. The surgical procedure was open nephroureterectomy in 54 patients, ureteroscopy in 27, and percutaneous endoscopic ablation in 16. In patients with low-grade tumours ($n = 46$), the 5-year disease-specific survival rate after nephroureterectomy, ureteroscopy, and percutaneous endoscopy was 84%, 80.7%, and 80%, respectively ($P = .89$); the corresponding 5-year

tumour-free survival rates were 75.3%, 71.5%, and 72% ($P = .78$) [27].

Lee et al. had similar findings when reviewing their 13 year experience of percuaneous management of upper tract urothelial carcinoma. They found no significant difference in overall survival when compared with nephroureterctomy. Regardless of treatment modality, patients with low grade lesions did well where as those with high grade lesions were predisposed to tumour recurrence and progression. Also, recurrence rates of bladder TCC appear to be similar after radical nephrectomy or endoscopic surgery [28].

Boorjian et al. reviewed 121 patients who underwent a nephroureterectomy for upper tract TCC over a 10-year period. In comparing patients who underwent nephroureterectomy on the basis of positive cytology findings and filling defects on contrast imaging ($n = 34$) with patients who had nephroureterectomy after ureteroscopic biopsy ($n = 75$) and patients who had nephroureterectomy after ureteroscopic biopsy and laser ablation ($n = 12$), they found no significant difference in postoperative disease status. Disease free rates in the 3 groups were 85.3%, 81.3%, and 83.3%, respectively [29].

8. Conclusions

Many reports of endoscopic surgery for upper tract urothelial carcinoma have emerged but only a few have a reasonable number of patients. Most series are small, with all types of indications (elective and palliative) and tumour characteristics (grade, stage, size, location).

The main message from series of endoscopic management of upper tract urothelial cancer is that patients must be carefully selected. Patient selection is based on tumour size, grade, and multifocality. Single low-grade tumours, less than 1.5 cm in size generally have a good outcome with endoscopic treatment provided they have regular ureteroscopic surveillance. Ureteroscopic treatment of high-grade tumours is essentially palliative. It is essential that patients are motivated and compliant as lifetime follow-up is necessary.

Recurrence rates are high but these recurrences can be treated with further endourological therapy or radical surgery as studies have shown that endological manipulation does not have a negative impact on survival.

The endoscopic approach can be mooted as an alternative approach to nephroureterectomy in poor performance status patients, but, until large, randomized trials with long-term follow-up are performed, it cannot be considered as a standard treatment.

References

[1] A. N. Argyropoulos and D. A. Tolley, "Upper urinary tract transitional cell carcinoma: current treatment overview of minimally invasive approaches," *BJU International*, vol. 99, no. 5, pp. 982–987, 2007.

[2] S. Olgac, M. Mazumdar, G. Dalbagni, and V. E. Reuter, "Urothelial carcinoma of the renal pelvis: a clinicopathologic study of 130 cases," *American Journal of Surgical Pathology*, vol. 28, no. 12, pp. 1545–1552, 2004.

[3] W. M. Murphy, J. B. Beckwith, and G. M. Farrow, "Angiomyolipoma," in *Atlas of Pathology: Tunours of the Kidney, Bladder, and Related Urinary Structures*, pp. 161–174, Armed Forces Institute of Pathology, Washington, DC, USA, 1993.

[4] H. Zincke and R. J. Neves, "Feasibility of conservative surgery for transitional cell cancer of the upper urinary tract," *Urologic Clinics of North America*, vol. 11, no. 4, pp. 717–724, 1984.

[5] E. Orihuela and A. D. Smith, "Percutaneous treatment of transitional cell carcinoma of the upper urinary tract," *Urologic Clinics of North America*, vol. 15, no. 3, pp. 425–431, 1988.

[6] J. A. Martínez-Piñeiro, Ma. J. García Matres, and L. Martínez-Piñeiro, "Endourological treatment of upper tract urothelial carcinomas: analysis of a series of 59 tumors," *The Journal of Urology*, vol. 156, no. 2, pp. 377–385, 1996.

[7] A. El-Hakim, G. H. Weiss, B. R. Lee, and A. D. Smith, "Correlation of ureteroscopic appearance with histologic grade of upper tract transitional cell carcinoma," *Urology*, vol. 63, no. 4, pp. 647–650, 2004.

[8] F. X. Keeley, D. A. Kulp, M. Bibbo, P. A. McCue, and D. H. Bagley, "Diagnostic accuracy of ureteroscopic biopsy in upper tract transitional cell carcinoma," *The Journal of Urology*, vol. 157, no. 1, pp. 33–37, 1997.

[9] S. K. Williams, K. J. Denton, A. Minervini, et al., "Correlation of upper-tract cytology, retrograde pyelography, ureteroscopic appearance, and ureteroscopic biopsy with histologic examination of upper-tract transitional cell carcinoma," *Journal of Endourology*, vol. 22, no. 1, pp. 71–76, 2008.

[10] F. X. Keeley Jr., M. Bibbo, and D. H. Bagley, "Ureteroscopic treatment and surveillance of upper urinary tract transitional cell carcinoma," *The Journal of Urology*, vol. 157, no. 5, pp. 1560–1565, 1997.

[11] G. B. Johnson, M. Fraiman, and M. Grasso, "Broadening experience with the retrograde endoscopic management of upper urinary tract urothelial malignancies," *BJU International*, vol. 95, no. 2, pp. 110–113, 2005.

[12] E. R. Tawfiek and D. H. Bagley, "Upper-tract transitional cell carcinoma," *Urology*, vol. 50, no. 3, pp. 321–329, 1997.

[13] N. T. Schmeller and A. G. Hofstetter, "Laser treatment of ureteral tumors," *The Journal of Urology*, vol. 141, no. 4, pp. 840–843, 1989.

[14] D. W. Soderdahl, M. D. Fabrizio, N. U. Rahman, T. W. Jarrett, and D. H. Bagley, "Endoscopic treatment of upper tract transitional cell carcinoma," *Urologic Oncology*, vol. 23, no. 2, pp. 114–122, 2005.

[15] G. L. Chen and D. H. Bagley, "Ureteroscopic management of upper tract transitional cell carcinoma in patients with normal contralateral kidneys," *The Journal of Urology*, vol. 164, no. 4, pp. 1173–1176, 2000.

[16] M. L. Blute, J. W. Segura, D. E. Patterson, R. C. Benson Jr., and H. Zincke, "Impact of endourology on diagnosis and management of upper urinary tract urothelial cancer," *The Journal of Urology*, vol. 141, no. 6, pp. 1298–1301, 1989.

[17] A. Huang, R. K. Low, and R. deVere White, "Nephrostomy tract tumor seeding following percutaneous manipulation of a ureteral carcinoma," *The Journal of Urology*, vol. 153, no. 3, pp. 1041–1042, 1995.

[18] C. R. J. Woodhouse, M. J. Kellett, and H. J. G. Blooom, "Percutaneous renal surgery and local radiotherapy in the

management of renal pelvic transitional cell carcinoma," *British Journal of Urology*, vol. 58, no. 3, pp. 245–249, 1986.

[19] M. C. Goel, V. Mahendra, and J. G. Roberts, "Percutaneous management of renal pelvic urothelial tumors: long-term followup," *The Journal of Urology*, vol. 169, no. 3, pp. 925–929, 2003.

[20] J. Palou, L. F. Piovesan, J. Huguet, J. Salvador, J. Vicente, and H. Villavicencio, "Percutaneous nephroscopic management of upper urinary tract transitional cell carcinoma: recurrence and long-term followup," *The Journal of Urology*, vol. 172, no. 1, pp. 66–69, 2004.

[21] M. Rouprêt, O. Traxer, M. Tligui, et al., "Upper urinary tract transitional cell carcinoma: recurrence rate after percutaneous endoscopic resection," *European Urology*, vol. 51, no. 3, pp. 709–714, 2007.

[22] I. Iborra, E. Solsona, J. Casanova, J. V. Ricós, J. Rubio, and M. A. Climent, "Conservative elective treatment of upper urinary tract tumors: a multivariate analysis of prognostic factors for recurrence and progression," *The Journal of Urology*, vol. 169, no. 1, pp. 82–85, 2003.

[23] K. Reisiger, G. Hruby, R. V. Clayman, and J. Landman, "Office-based surveillance ureteroscopy after endoscopic treatment of transitional cell carcinoma: technique and clinical outcome," *Urology*, vol. 70, no. 2, pp. 263–266, 2007.

[24] G. L. Chen, E. A. El-Gabry, and D. H. Bagley, "Surveillance of upper urinary tract transitional cell carcinoma: the role of ureteroscopy, retrograde pyelography, cytology and urinalysis," *The Journal of Urology*, vol. 164, no. 6, pp. 1901–1904, 2000.

[25] T. L. Xia, "Cytologic diagnostic value of voided urine in 60 cases of primary transitional cell carcinoma of the renal pelvis and ureter," *Zhonghua Wai Ke Za Zhi*, vol. 27, no. 12, pp. 753–755, 1989 (Chinese).

[26] J. R. Sharpe, G. Duffy, and J. L. Chin, "Intrarenal bacillus Calmette-Guerin therapy for upper urinary tract carcinoma in situ," *The Journal of Urology*, vol. 149, no. 3, pp. 457–460, 1993.

[27] F. X. Keeley Jr. and D. H. Bagley, "Adjuvant mitomycin C following endoscopic treatment of upper tract transitional cell carcinoma," *The Journal of Urology*, vol. 158, no. 6, pp. 2074–2077, 1997.

[28] B. R. Lee, M. E. Jabbour, F. F. Marshall, A. D. Smith, and T. W. Jarrett, "13-year survival comparison of percutaneous and open nephroureterectomy approaches for management of transitional cell carcinoma of renal collecting system: equivalent outcomes," *Journal of Endourology*, vol. 13, no. 4, pp. 289–294, 1999.

[29] S. Boorjian, C. Ng, R. Munver, et al., "Impact of delay to nephroureterectomy for patients undergoing ureteroscopic biopsy and laser tumor ablation of upper tract transitional cell carcinoma," *Urology*, vol. 66, no. 2, pp. 283–287, 2005.

Hindawi Publishing Corporation
Advances in Urology
Volume 2009, Article ID 976401, 6 pages
doi:10.1155/2009/976401

Review Article

Endourologic Management of Upper Tract Transitional Cell Carcinoma following Cystectomy and Urinary Diversion

Jeffrey John Tomaszewski, Marc Christopher Smaldone, and Michael Cecil Ost

Department of Urology, University of Pittsburgh School of Medicine, Pittsburgh, PA 15213, USA

Correspondence should be addressed to Jeffrey John Tomaszewski, tomaszewskijj@upmc.edu

Received 1 May 2008; Revised 28 September 2008; Accepted 3 November 2008

Recommended by Norm D. Smith

Traditionally, nephroureterectomy is the gold standard therapy for upper tract recurrence of transitional cell carcinoma (TCC) following cystectomy and urinary diversion. With advances in endoscopic equipment and improvements in technique, conservative endourologic management via a retrograde or antegrade approach is technically feasible with acceptable outcomes in patients with bilateral disease, solitary renal units, chronic renal insufficiency, or significant medical comorbidities. Contemporary studies have expanded the utility of these techniques to include low-grade, low-volume disease in patients with a normal contralateral kidney. The aim of this report is to review the current outcomes of conservative management for upper tract disease and discuss its application and relevance in patients following cystectomy with lower urinary tract reconstruction.

1. Introduction

Upper tract transitional cell carcinoma (UTTCC) represents 5% of all urothelial cancers [1]. Due to the proposed field defect associated with these lesions, removal of the entire urothelium on the ipsilateral side offers the best chance of surgical cure. For this reason, the traditional and gold standard treatment for UTTCC has been radical nephroureterectomy [2]. However, minimally invasive endoscopic techniques have been developed to treat patients with bilateral upper tract disease, poor candidates for radical surgery, and those with solitary renal units. In more recent times, even healthy patients with low-grade, noninvasive tumors have been managed endoscopically, with the understanding that some may require radical nephroureterectomy if UTTCC should recur or progress.

The incidence of upper tract recurrence following radical cystectomy is low (3–5%), but there is an increased incidence of upper tract recurrence in patients undergoing cystectomy with a prior history of superficial bladder disease [3]. Treatment of upper tract recurrence following lower urinary tract reconstruction is challenging, but with recent technological advances, both ureteroscopic and percutaneous techniques have been utilized for surveillance and management in these complex patients. We review the literature in order to summarize and define the advantages and disadvantages of ureteroscopic and percutaneous management of upper tract TCC following urinary diversion.

2. Discussion

Upper tract transitional cell carcinoma (UTTCC) is relatively uncommon, accounting for approximately 5% of all urothelial tumors and 10% of all renal tumors or approximately 3000 cases per year in the United States [4, 5]. The incidence of upper tract recurrence following radical cystectomy for urothelial cancer ranges from 2% to 6% [3, 6–11], with the majority of recurrence in the first 3 years [3]. Additionally, Tran et al. [3] demonstrated that the risk of upper tract recurrence does not change with time, emphasizing the critical importance of continued surveillance for UTTCC following cystectomy. Patients with associated carcinoma in situ of the bladder or prostatic urethra, recurrent high risk superficial cancer of the bladder, and tumor multifocality are at higher risk of ureteral involvement at the time of cystectomy [3, 12–17]. In the subgroup with ureteral involvement at the time of cystectomy, tumor recurrence in the upper tract was noted in 16–17% [3, 16], with the authors

concluding that these patients require vigorous follow up with urine cytology and upper tract surveillance imaging.

Treatment of upper tract recurrence following cystectomy remains a clinical dilemma. Due to improvements in fiberoptic technology and refinement of endoscopic techniques, conservative management of UTTCC has evolved into a viable treatment alternative with similar efficacy to that of radical therapy in select patients with non-invasive and low-grade disease. Indications for ureteroscopic and/or percutaneous endoscopic management include patients with a solitary kidney, bilateral disease, renal insufficiency, or patients who would require dialysis after nephroureterectomy [18–20]. However, in recent series, minimally invasive procedures have increasingly been utilized in patients with a normal contralateral kidney [21–23]. These studies have concluded that patients who have solitary, small (<1.5 cm), low-grade, and completely resectable tumors are candidates for endoscopic management if they are willing to accept lifelong surveillance for recurrence [21, 24].

Surveillance should be lifelong and tailored to the patient's tumor grade and stage. Our institution's surveillance protocol includes urine cytology every three months, and upper tract imaging (computed tomography urogram, intravenous pyelogram, or retrograde pyelogram) every six months for the first two years, then yearly thereafter [20, 25, 26]. Contemporary surveillance protocols for upper tract disease include surveillance ureteroscopy at frequent defined intervals [26, 27]. In patient's with lower urinary tract reconstruction, this may not be feasible and needs to be tailored to each individual patient. Management of recurrent upper tract TCC is comparable to that of primary upper tract TCC and must be adapted to the tumor characteristics and patient; nephroureterectomy is usually recommended for recurrences that have evidence of grade and stage progression.

A drawback of endoscopy in the management of pelvicaliceal lesions is its low sensitivity for the detection of invasive lesions and thus its low reliability in staging [25, 26, 28]. The correlation between grade and stage of upper tract tumors has previously been demonstrated, thus many rely primarily on the grade of the endoscopic biopsy specimen for pathologic assessment [26, 29]. Abnormal upper tract urinary cytology results have been shown to predict tumor recurrence and correlate with pathologic tumor grade and stage [26, 28, 30].

Surgical resection of a UTTCC following cystectomy and continent or incontinent urinary diversion presents a unique challenge. Although such a recurrence portends an overall poor prognosis, a maximal effort must be made to resect localized disease. Endoscopic management of upper tract abnormalities in patients following urinary diversion is complicated by difficult retrograde access to the upper collecting system [31]. Although technically challenging, endoscopic retrograde, percutaneous antegrade or combined antegrade, and retrograde approaches have been described [31, 32] and can be utilized in the evaluation and treatment of upper tract urothelial cancer recurrence.

3. Retrograde Ureteroscopic Access

The ureteroscopic approach is typically the least invasive surgical treatment option for UTTCC. It is also the most thorough procedure for surveying the entire collecting system for posttreatment surveillance. Advantages include limited morbidity in the setting of an outpatient procedure and the potential oncologic benefit of a closed system [31]. The most challenging aspect of ureteroscopic management following both continent and incontinent lower urinary tract reconstruction is obtaining retrograde access to the ureter.

In cases following continent diversion, the neobladder can be accessed via the urethra using rigid or flexible ureteroscopy [33]. In cases of incontinent urinary diversion, a flexible cystoscope can be passed through the stoma into the reservoir. Mucous and debris is often encountered on initial inspection and must be copiously irrigated to improve visualization [31]. A cystogram or loopogram under fluoroscopic guidance can be performed to help delineating the afferent limb and the ureteral anastomosis. Administration of methylene blue or indigo carmine may aid in the identification of the ureteral anastamoses. Upon identification, the ureteral orifices can be cannulated with guidewires or open-ended ureteral access catheters. The use of contrast to clearly delineate anatomic landmarks can also facilitate a combined antegrade/retrograde approach in select mid-ureteral tumors that may require dual access for complete resection. In select cases ureteral access sheaths can help to facilitate repeated passes of the ureteroscope and tumor basketing. In addition, the use of an access sheath decreases irrigation pressure [34] and may theoretically reduce the possibility of pyelolymphatic backflow and tumor dissemination. Baskets or biopsy forceps can be used for tumor debulking and biopsy, and electrocautery or laser fibers can be used to ablate tumor and control hemorrhage [33]. Disadvantages include potential staging errors, inability to treat large lesions in a single setting, and difficulty in accessing lower pole lesions [35].

Although minimally invasive treatment methods were originally developed for patients that could not undergo open surgery, the ureteroscopic approach to UTTCC has been shown to be an efficacious first-line treatment to address UTTCC of low stage and grade [35]. Ureteroscopy provides adequate access for biopsy under direct vision, and mechanical, ablative, or laser removal of papillary lesions anywhere along the upper tract urothelium. Chen and Bagley [36] treated 23 patients with UTTCC; 8 remained disease-free, and 15 had recurrences treated at a mean follow up of 35 months, with 100% disease-specific survival. Keeley et al. [26] and Martínez-Piñeiro et al. [19] reported tumor-free rates of 76% and 71%, respectively, among patients with low-grade UTTCC. Due to its efficacy, safety, and minimal morbidity, the ureteroscopic approach is a very attractive treatment alternative for low-grade urothelial carcinoma [33].

Nelson et al. [31] reported their experience with retrograde ureteroscopy for the management of 13 renal units in 8 patients following continent neobladder diversion. Indications for evaluation included upper tract filling defect,

positive cytology, or renal calculi. The ureter and renal pelvis were successfully accessed and visualized in 76%, and they were unable to access the ureteral orifices in three remaining patients. While demonstrating that retrograde access is technically feasible in this patient population, attempting to access the collecting system retrograde in reconstructed patients may have severe consequences. Care must be taken to avoid damaging the continence mechanism, perforating the reservoir, or disrupting the ureteral-enteric anastomoses. In our practice, primary ureteroscopic therapy is considered for upper tract evaluation in patients with lower urinary tract reconstruction for small filling defects on upper tract imaging or positive cytology, with the intention of treating small lesions during the initial setting. All patients are counseled that access or treatment failure is a distinct possibility, and that further antegrade or more definitive open or laparoscopic surgical procedures may be warranted. Complications specific to ureteroscopic tumor treatment include extraluminal spillage or propagation of neoplasm, ureteral perforation, and ureteral stricture formation [22]. The reported stricture rate following ureteroscopic management of upper tract TCC has ranged from 5% to 14% [19, 26, 37]. When a ureteral stricture forms following endoscopic management of upper tract TCC, it is imperative to perform a biopsy of the region to rule out malignant disease [36].

4. Percutaneous Access

The evolution of lower urinary tract reconstruction has resulted in a growing number of patients in need of complex upper tract management. Although technically feasible, evaluation and treatment of upper tract abnormalities are complicated by difficult retrograde access to the upper collecting system due to unusual anatomy and lack of anatomic landmarks [31]. The difficulty of accessing both refluxing and nonrefluxing ureterointestinal anastamoses restricts the use of the size and type of endoscopic equipment necessary for complete resection of UTTCC which is challenging from a retrograde approach under ideal circumstances. Although more invasive, a percutaneous approach avoids these difficulties through direct access and offers a high success rate with minimal morbidity [32].

The method of obtaining percutaneous access is similar to what has been described for percutaneous nephrolithotomy. Under fluoroscopic guidance, a direct puncture of the involved calyx or an upper pole or central calyx puncture for renal pelvis, lower pole, or ureteral tumors is recommended [38]. Following tract dilation, a 30Fr access sheath is placed, and rigid or flexible nephroscopy may be performed. Once the offending lesion is visualized, frozen section pathology examination is recommended to rule out a high-grade lesion. The ideal resection modality depends on tumor size and type, but monopolar and bipolar cautery, laser, rollerball electrode, and electrovaporization techniques have been described. The entire tumor should be ablated and the base fulgurated or resected. Flexible nephroscopy should be carried out to ensure that all areas of the kidney are clear of tumor. A nephrostomy tube should be left in place for external drainage to preserve access and to facilitate adjuvant chemotherapy. In select cases, a second look nephroscopy on postoperative day 1-2 to ensure complete resection is recommended. In the case of continent cutaneous diversion, percutaneous access into the pouch under direct vision with a 10 mm trocar has also been described [39]. Historically utilized in cases of large urinary diversion calculi, this technique requires cystoscopy through the continent stoma to achieve percutaneous access under direct vision which has the potential for damage to the continence mechanism as well as the development of stomal stenosis and has only theoretical implications for access to the upper tract.

Smith et al. reported the first large series of percutaneous resections of UTTCC in a solitary kidney [40]. The oncologic efficacy of percutaneous resection has most often been measured in terms of disease recurrence, which has been shown to correlate with tumor grade [20, 41–43]. In review of several large series, recurrence rates for grade 1 (5–20%) [23, 41–44] and grade 2 diseases (6–33%) [23, 41–45] have been reported as significantly lower than recurrence rates for grade 3 disease (31–60%) [23, 41–43]. In addition, tumor grade has been shown to have prognostic significance, and death from low-grade UTTCC is rare [45]. It is important to note that prognosis for high-grade and high-stage UTTCCs is poor regardless of treatment modality. In a series of 25 patients undergoing percutaneous resection of grade 3 disease, Liatsikos et al. reported a 56% recurrence rate and 64% disease-specific survival [43] which is comparable to series examining ureteroscopic resection and radical therapy.

The major advantages of the percutaneous approach in patients following urinary diversion are that it allows direct access and the use of larger endoscopes, improving visualization. Both rigid and flexible endoscopes can be passed through the percutaneous tract, facilitating inspection of the entire calyceal system. The use of larger instruments facilitates the resection of large lesions, and makes tumor removal more efficient. The availability of larger instruments, including resectoscopes, grasping/biopsy forceps, and laser fibers, minimizes resection time allowing complete resection of large tumors in a single setting that would be difficult ureteroscopically [38]. Direct antegrade access also facilitates access to lower pole calyceal tumors. Ureteroscopic access and visualization of the lower pole are limited by the loss of deflection caused by instrument passage through the working channel [22]. The additional benefits of repeat nephroscopy for additional resection and the delivery of adjuvant therapy are facilitated by a percutaneous approach. This is of particular advantage in patients with large (>1 cm) tumor burden, solitary kidney, poor renal function, or significant comorbidites that would preclude open or laparoscopic nephroureterectomy. Bleeding due to the vascularity of the kidney and proximity to the hilum [46] and antegrade tract seeding [47] are complications of percutaneous treatment that despite infrequently being reported are still of significant concern. In comparison to the retrograde approach, percutaneous resection of upper tract TCC is more invasive and is associated with higher complication rates. Major complications of percutaneous resection include perforation, nephrostomy tract seeding, and bleeding. The incidence of blood loss varies among

investigators and depends greatly on the size and extent of the treated lesion as well as ease of access, but transfusion rates up to 37% have been reported [43].

5. Adjuvant Therapy

A beneficial role for topical adjuvant therapy following the resection of UTTCC has not been proven in randomized trials. While retrograde instillation of agents into the collecting system has been described [35, 48], percutaneous resection with simultaneous nephrostomy tube placement facilitates antegrade instillation, maximizing chemotherapeutic agent contact with the urothelium. A disadvantage of retrograde catheterization, particularly in patients with continent urinary diversion, is that cystoscopy with ureteral catheter placement must be performed prior to each instillation.

Currently, there is no consensus as to which technique is more effective. In an initial study comparing outcomes in patients receiving postresection BCG with those who did not, Jabbour and Smith reported a significantly lower recurrence rate in patients with grade 1 tumors who received adjuvant BCG. There was no benefit for patients with grade 2 and grade 3 disease [38]. Rastinehad et al. [49] reported a 25% decreased likelihood of progression at 65 months follow up among 24 renal units with low-grade UTTCC undergoing BCG instillation. Despite the lack of evidence from randomized trials, the potential benefits and relative safety of adjuvant therapy provide an attractive alternative in patients with grade 2 and grade 3 disease in a solitary renal unit, patients with chronic renal insufficiency, or patients that are poor surgical candidates.

6. Conclusions

Nephroureterectomy is the gold standard treatment modality for high-grade and large-burden upper tract TCC recurrence following cystectomy and urinary diversion. However, with technical advances in equipment and increasing facility with endoscopic techniques, a minimally invasive approach is feasible in select patients. In the setting of a solitary kidney, chronic renal insufficiency, or significant comorbidity, preservation of renal function and prevention of recurrence are paramount. Reports of percutaneous tract seeding and recurrence due to pyelovenous backflow are uncommon but are a significant concern with each modality of conservative therapy. When choosing a surgical approach in a patient following lower urinary tract reconstruction, the ease of access, preservation of renal function, and oncologic efficacy must all be taken into consideration. Although technically possible, accessing the lower tract from a retrograde approach can be difficult and the capability for complete resection is limited for larger or lower pole lesions. Although more invasive, a percutaneous approach offers direct access with increased visualization, improved resection capability, and acceptable morbidity rates. Experience with ureteroscopic and percutaneous techniques enables full access to the reconstructed urinary tract and adds to the armamentarium of therapeutic options in the management of upper tract recurrence following cystectomy and urinary diversion.

References

[1] J. J. Munoz and L. M. Ellison, "Upper tract urothelial neoplasms: incidence and survival during the last 2 decades," *The Journal of Urology*, vol. 164, no. 5, pp. 1523–1525, 2000.

[2] M. Craig Hall, S. Womack, A. I. Sagalowsky, T. Carmody, M. D. Erickstad, and C. G. Roehrborn, "Prognostic factors, recurrence, and survival in transitional cell carcinoma of the upper urinary tract: a 30-year experience in 252 patients," *Urology*, vol. 52, no. 4, pp. 594–601, 1998.

[3] W. Tran, A. M. Serio, G. V. Raj, et al., "Longitudinal risk of upper tract recurrence following radical cystectomy for urothelial cancer and the potential implications for long-term surveillance," *The Journal of Urology*, vol. 179, no. 1, pp. 96–100, 2008.

[4] P. Guinan, N. J. Vogelzang, R. Randazzo, et al., "Renal pelvic cancer: a review of 611 patients treated in Illinois 1975–1985," *Urology*, vol. 40, no. 5, pp. 393–399, 1992.

[5] S. H. Landis, T. Murray, S. Bolden, and P. A. Wingo, "Cancer statistics, 1998," *Ca: A Cancer Journal for Clinicians*, vol. 48, no. 1, pp. 6–29, 1998.

[6] J. Furukawa, H. Miyake, I. Hara, A. Takenaka, and M. Fujisawa, "Upper urinary tract recurrence following radical cystectomy for bladder cancer," *International Journal of Urology*, vol. 14, no. 6, pp. 496–499, 2007.

[7] K. M. Sanderson, J. Cai, G. Miranda, D. G. Skinner, and J. P. Stein, "Upper tract urothelial recurrence following radical cystectomy for transitional cell carcinoma of the bladder: an analysis of 1,069 patients with 10-year followup," *The Journal of Urology*, vol. 177, no. 6, pp. 2088–2094, 2007.

[8] C. B. Schwartz, H. Bekirov, and A. Melman, "Urothelial tumors of upper tract following treatment of primary bladder transitional cell carcinoma," *Urology*, vol. 40, no. 6, pp. 509–511, 1992.

[9] T. Shinka, Y. Uekado, H. Aoshi, A. Hirano, and T. Ohkawa, "Occurrence of uroepithelial tumors of the upper urinary tract after the initial diagnosis of bladder cancer," *The Journal of Urology*, vol. 140, no. 4, pp. 745–748, 1988.

[10] H. Zincke, P. J. Garbeff, and J. R. Beahrs, "Upper urinary tract transitional cell cancer after radical cystectomy for bladder cancer," *The Journal of Urology*, vol. 131, no. 1, pp. 50–52, 1984.

[11] K. C. Balaji, M. McGuire, J. Grotas, G. Grimaldi, and P. Russo, "Upper tract recurrences following radical cystectomy: an analysis of prognostic factors, recurrence pattern and stage at presentation," *The Journal of Urology*, vol. 162, no. 5, pp. 1603–1606, 1999.

[12] S. M. Donat, "Staged based directed surveillance of invasive bladder cancer following radical cystectomy: valuable and effective?" *World Journal of Urology*, vol. 24, no. 5, pp. 557–564, 2006.

[13] H. W. Herr, "Extravesical tumor relapse in patients with superficial bladder tumors," *Journal of Clinical Oncology*, vol. 16, no. 3, pp. 1099–1102, 1998.

[14] J. Huguet-Pérez, J. Palou, F. Millán-Rodríguez, J. Salvador-Bayarri, H. Villavicencio-Mavrich, and J. Vicente-Rodríguez, "Upper tract transitional cell carcinoma following cystectomy for bladder cancer," *European Urology*, vol. 40, no. 3, pp. 318–323, 2001.

[15] S. B. Malkowicz and D. G. Skinner, "Development of upper tract carcinoma after cystectomy for bladder carcinoma," *Urology*, vol. 36, no. 1, pp. 20–22, 1990.

[16] M. C. Schumacher, M. Scholz, E. S. Weise, A. Fleischmann, G. N. Thalmann, and U. E. Studer, "Is there an indication for frozen section examination of the ureteral margins during cystectomy for transitional cell carcinoma of the bladder?" *The Journal of Urology*, vol. 176, no. 6, pp. 2409–2413, 2006.

[17] P. D. Sved, P. Gomez, A. M. Nieder, M. Manoharan, S. S. Kim, and M. S. Soloway, "Upper tract tumour after radical cystectomy for transitional cell carcinoma of the bladder: incidence and risk factors," *BJU International*, vol. 94, no. 6, pp. 785–789, 2004.

[18] E. Deligne, M. Colombel, L. Badet, et al., "Conservative management of upper urinary tract tumors," *European Urology*, vol. 42, no. 1, pp. 43–48, 2002.

[19] J. A. Martínez-Piñeiro, Ma. J. García Matres, and L. Martínez-Piñeiro, "Endourological treatment of upper tract urothelial carcinomas: analysis of a series of 59 tumors," *The Journal of Urology*, vol. 156, no. 2, pp. 377–385, 1996.

[20] J. Palou, L. F. Piovesan, J. Huguet, J. Salvador, J. Vicente, and H. Villavicencio, "Percutaneous nephroscopic management of upper urinary tract transitional cell carcinoma: recurrence and long-term followup," *The Journal of Urology*, vol. 172, no. 1, pp. 66–69, 2004.

[21] D. S. Elliott, J. W. Segura, D. Lightner, D. E. Patterson, and M. L. Blute, "Is nephroureterectomy necessary in all cases of upper tract transitional cell carcinoma? Long-term results of conservative endourologic management of upper tract transitional cell carcinoma in individuals with a normal contralateral kidney," *Urology*, vol. 58, no. 2, pp. 174–178, 2001.

[22] J. S. Lam and M. Gupta, "Ureteroscopic management of upper tract transitional cell carcinoma," *Urologic Clinics of North America*, vol. 31, no. 1, pp. 115–128, 2004.

[23] B. R. Lee, M. E. Jabbour, F. F. Marshall, A. D. Smith, and T. W. Jarrett, "13-year survival comparison of percutaneous and open nephroureterectomy approaches for management of transitional cell carcinoma of renal collecting system: equivalent outcomes," *Journal of Endourology*, vol. 13, no. 4, pp. 289–294, 1999.

[24] G. L. Chen and D. H. Bagley, "Ureteroscopic management of upper tract transitional cell carcinoma in patients with normal contralateral kidneys," *The Journal of Urology*, vol. 164, no. 4, pp. 1173–1176, 2000.

[25] K.-L. V. Ho and G. K. Chow, "Ureteroscopic resection of upper-tract transitional-cell carcinoma," *Journal of Endourology*, vol. 19, no. 7, pp. 841–848, 2005.

[26] F. X. Keeley Jr., M. Bibbo, and D. H. Bagley, "Ureteroscopic treatment and surveillance of upper urinary tract transitional cell carcinoma," *The Journal of Urology*, vol. 157, no. 5, pp. 1560–1565, 1997.

[27] S. Razdan, J. Johannes, M. Cox, and D. H. Bagley, "Current practice patterns in urologic management of upper-tract transitional-cell carcinoma," *Journal of Endourology*, vol. 19, no. 3, pp. 366–371, 2005.

[28] S. Boorjian, C. Ng, R. Munver, et al., "Abnormal selective cytology results predict recurrence of upper-tract transitional-cell carcinoma treated with ureteroscopic laser ablation," *Journal of Endourology*, vol. 18, no. 9, pp. 912–916, 2004.

[29] D. M. Murphy, H. Zincke, and W. L. Furlow, "Primary grade 1 transitional cell carcinoma of the renal pelvis and ureter," *The Journal of Urology*, vol. 123, no. 5, pp. 629–631, 1980.

[30] M. Igawa, S. Urakami, H. Shiina, et al., "Limitations of ureteroscopy in diagnosis of invasive upper tract urothelial cancer," *Urologia Internationalis*, vol. 56, no. 1, pp. 13–15, 1996.

[31] C. P. Nelson, J. S. Wolf Jr., J. E. Montie, and G. J. Faerber, "Retrograde ureteroscopy in patients with orthotopic ileal neobladder urinary diversion," *The Journal of Urology*, vol. 170, no. 1, pp. 107–110, 2003.

[32] A. R. El-Nahas, I. Eraky, A. M. El-Assmy, et al., "Percutaneous treatment of large upper tract stones after urinary diversion," *Urology*, vol. 68, no. 3, pp. 500–504, 2006.

[33] G. K. Chow, "Ureteroscopic treatment of pelvic renal tumor in a solitary kidney with orthotopic neobladder," *Journal of Endourology*, vol. 22, no. 9, pp. 2091–2092, 2008.

[34] J. O. L'Esperance, W. O. Ekeruo, C. D. Scales Jr., et al., "Effect of ureteral access sheath on stone-free rates in patients undergoing ureteroscopic management of renal calculi," *Urology*, vol. 66, no. 2, pp. 252–255, 2005.

[35] M. C. Ost, B. A. VanderBrink, B. R. Lee, and A. D. Smith, "Endourologic treatment of upper urinary tract transitional cell carcinoma," *Nature Clinical Practice Urology*, vol. 2, no. 8, pp. 376–383, 2005.

[36] G. L. Chen and D. H. Bagley, "Ureteroscopic surgery for upper tract transitional-cell carcinoma: complications and management," *Journal of Endourology*, vol. 15, no. 4, pp. 399–404, 2001.

[37] D. S. Elliott, M. L. Blute, D. E. Patterson, E. J. Bergstralh, and J. W. Segura, "Long-term follow-up of endoscopically treated upper urinary tract transitional cell carcinoma," *Urology*, vol. 47, no. 6, pp. 819–825, 1996.

[38] M. E. Jabbour and A. D. Smith, "Primary percutaneous approach to upper urinary tract transitional cell carcinoma," *Urologic Clinics of North America*, vol. 27, no. 4, pp. 739–750, 2000.

[39] P. N. Lam, C. C. Te, C. Wong, and B. P. Kropp, "Percutaneous cystolithotomy of large urinary-diversion calculi using a combination of laparoscopic and endourologic techniques," *Journal of Endourology*, vol. 21, no. 2, pp. 155–157, 2007.

[40] A. D. Smith, E. Orihuela, and A. R. Crowley, "Percutaneous management of renal pelvic tumors: a treatment option in selected cases," *The Journal of Urology*, vol. 137, no. 5, pp. 852–856, 1987.

[41] P. E. Clark, S. B. Streem, and M. A. Geisinger, "13-year experience with percutaneous management of upper tract transitional cell carcinoma," *The Journal of Urology*, vol. 161, no. 3, pp. 772–776, 1999.

[42] T. W. Jarrett, P. M. Sweetser, G. H. Weiss, and A. D. Smith, "Percutaneous management of transitional cell carcinoma of the renal collecting system: 9-year experience," *The Journal of Urology*, vol. 154, no. 5, pp. 1629–1635, 1995.

[43] E. N. Liatsikos, C. Z. Dinlenc, R. Kapoor, and A. D. Smith, "Transitional-cell carcinoma of the renal pelvis: ureteroscopic and percutaneous approach," *Journal of Endourology*, vol. 15, no. 4, pp. 377–383, 2001.

[44] A. Patel, P. Soonawalla, S. F. Shepherd, D. P. Dearnaley, M. J. Kellett, and C. R. J. Woodhouse, "Long-term outcome after percutaneous treatment of transitional cell carcinoma of the renal pelvis," *The Journal of Urology*, vol. 155, no. 3, pp. 868–874, 1996.

[45] M. E. Jabbour, F. Desgrandchamps, S. Cazin, P. Teillac, A. Le Duc, and A. D. Smith, "Percutaneous management of grade II upper urinary tract transitional cell carcinoma: the long-term outcome," *The Journal of Urology*, vol. 163, no. 4, pp. 1105–1107, 2000.

[46] M. C. Goel and J. G. Roberts, "Percutaneous resection of renal transitional carcinoma: venous injury and its conservative management," *Urologia Internationalis*, vol. 67, no. 2, pp. 170–172, 2001.

[47] A. Huang, R. K. Low, and R. deVere White, "Nephrostomy tract tumor seeding following percutaneous manipulation of a ureteral carcinoma," *The Journal of Urology*, vol. 153, no. 3, supplement 1, pp. 1041–1042, 1995.

[48] A. Irie, M. Iwamura, K. Kadowaki, A. Ohkawa, T. Uchida, and S. Baba, "Intravesical instillation of bacille Calmette-Guérin for carcinoma in situ of the urothelium involving the upper urinary tract using vesicoureteral reflux created by a double-pigtail catheter," *Urology*, vol. 59, no. 1, pp. 53–57, 2002.

[49] A. R. Rastinehad, A. El-Hakim, B. R. Lee, and A. D. Smith, "BCG topical immunotherapy reduces the rate of upper tract transitional cell carcinoma (UTTCC) tumor progression in patients treated by endoscopic resection—a single institution—long term experience," in *Proceedings of the Annual Meeting of the American Urological Association (AUA '07)*, Anaheim, Calif, USA, May 2007.

Hindawi Publishing Corporation
Advances in Urology
Volume 2009, Article ID 472831, 6 pages
doi:10.1155/2009/472831

Review Article

Review of Topical Treatment of Upper Tract Urothelial Carcinoma

Kenneth G. Nepple, Fadi N. Joudi, and Michael A. O'Donnell

Department of Urology, University of Iowa, 200 Hawkins Dr., 3 RCP, Iowa City, IA 52242-1089, USA

Correspondence should be addressed to Michael A. O'Donnell, michael-odonnell@uiowa.edu

Received 30 April 2008; Accepted 15 September 2008

Recommended by Norm D. Smith

A select group of patients with upper tract urothelial carcinoma may be appropriate candidates for minimally invasive management. Organ-preserving endoscopic procedures may be appropriate for patients with an inability to tolerate major surgery, solitary kidney, bilateral disease, poor renal function, small tumor burden, low-grade disease, or carcinoma in situ. We review the published literature on the use of topical treatment for upper tract urothelial carcinoma and provide our approach to treatment in the office setting.

1. Introduction

Nephroureterectomy with open excision of bladder cuff remains the standard of care for organ-confined upper tract urothelial cancer in patients with a normal contralateral kidney. Laparoscopic surgery has broadened the population of patients who are able to tolerate this surgery; however, due to concerns for preservation of renal function or inability to tolerate surgery, a selected group of patients may be suitable candidates for less-invasive management with endoscopic approach. Organ-preserving endoscopic procedures may be appropriate for patients with a solitary kidney, bilateral disease, poor renal function, or inability to tolerate major surgery [1, 2]. In addition, the indications for minimally invasive therapy have evolved to include small tumor burden, low-grade disease, or carcinoma in situ in patients with normal contralateral renal function [3]. Patients with high-grade disease, multifocal tumors, or history of recurrent tumor are not ideal candidates for topical therapy because of risk of recurrent or progressive disease. Patients managed with less invasive treatment must be made aware of the concern for progressive or recurrent disease. In addition, patients must be compliant with both the treatment regimen and the required subsequent follow-up.

The role of intravesical immunotherapy in non-muscle-invasive urothelial cancer of the bladder has been firmly established [4, 5]. A variety of agents have been utilized (Table 1), with BCG showing the greatest efficacy [4]. In the treatment of upper tract urothelial carcinoma, instillation of topical immunotherapy has been used as primary or adjuvant treatment, but upper tract treatment can be problematic because agents must be delivered to the renal pelvis and ureter to be effective. A challenge to the practicing urologist is finding a way to implement this treatment in the busy office setting. We review the published literature on topical treatment of upper tract urothelial cancer, and provide our approach to treatment in the office setting.

2. Upper Tract Evaluation

Patients must be properly selected for topical upper tract treatment. Upper tract abnormalities are often identified as a filling defect on delayed images of a CT urogram or IVP done for hematuria work-up or during selective upper tract washings for a positive bladder cytology in the absence of any bladder pathology. Our operative evaluation for positive cytology includes evaluation of both the bladder and upper tract for source of positive cytology. Initially, a rigid cystoscope is introduced and the bladder is inspected. The bladder is drained and a bladder wash with normal saline is obtained for cytology by rinsing the bladder several times. Cytology from the first kidney is obtained using normal saline washes through a 5 french open-ended ureteral catheter. To reduce the chance of bladder contamination, positive pressure saline is infused through the catheter up

Table 1: Mechanism of immunotherapy agents.

BCG	Inflammatory host response Release of cytokines
Interferon	Lymphocyte activation Cytokine release Phagocyte stimulation Antiproliferative actions Antiangiogenic
Thiotepa	Alkylating agent Crosslinks nucleic acids
Mitomycin C	Inhibits DNA synthesis
Gemcitabine	Deoxyctidine analog Inhibits DNA synthesis

until the point in which it is introduced into the ureter The catheter is advanced up into the renal pelvis (~25 cm) and two 5–7 cc saline washes are obtained followed by additional washes at 20, 15, and 10 cm. The catheter is then readvanced up into the renal pelvis where the remaining fluid is aspirated and pooled together with the other washes. A retrograde pyelogram is then performed from the renal pelvis downwards as the catheter is removed. The same procedure is then performed on the contralateral upper tract. It should be noted that special care must be taken to avoid contamination of specimens by using different ureteral catheters for each side. If any abnormality is seen on retrograde pyelogram, then the upper tract should be evaluated with ureteroscopy with subsequent upper tract wash, brush biopsy, or tissue biopsy as deemed appropriate. The bladder should be inspected and five random bladder biopsies taken in a stellate manner (trigone, base, dome, and both lateral side walls). An essential component of a complete evaluation is to obtain a separately labeled biopsy from the prostatic urethra, which can serve as a sanctuary site for urothelial carcinoma.

Patients treated with topical infusion therapy typically have either carcinoma in situ or lesions that have been resected endoscopically. A mass in the collecting system or ureter identified on retrograde pyelogram or CT urogram prompts a focused operative evaluation. Small lesions may be amenable to endoscopic treatment (ureteroscopic or percutaneous) as discussed elsewhere in this special issue. It is highly unlikely that topical treatment by itself would eradicate radiographically visible disease. After primary treatment or the presence of hematuria, BCG treatment should be delayed 2 to 4 weeks to allow the urothelium to heal and decrease the likelihood of systemic side effects. Of note, in patients with positive cytology from both the bladder and upper tract with no mass lesion, the status of the upper tract should be considered inconclusive. In these cases, we generally start with intravesical treatment as the positive upper tract cytology could be due to contamination from the bladder. Restaging after intravesical therapy is prudent to reevaluate the upper tracts. If the bladder is disease-free and the upper tract cytology continues to be positive, then this rules out the possibility of contamination and should be treated accordingly.

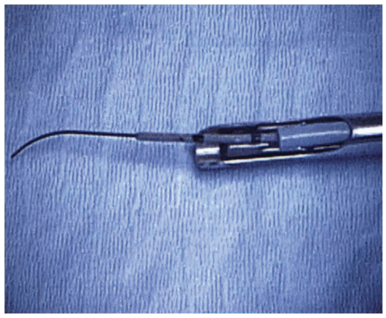

Figure 1

3. Office-Based Approach for Upper Tract Treatment

We use an office-based approach for placement of ureteral catheter(s) for upper tract therapy. Flexible cystoscopy is performed, sometimes with oral narcotic/benzodiazapine premedication or intravenous sedation (morphine, versed) based on patient preference. The ureteral orifice is visualized and cannulated with a 0.018 inch angled glidewire that is passed to the renal pelvis. A 4 F whistle-tip catheter is then passed over the glidewire (Figure 1). Under direct vision, the catheter is slid over the wire into the ureter and a second ureteral catheter with the tip cut off is used as a pusher to further advance the catheter. Using the catheter markings as a guide, the catheter is typically advanced to 25 cm to place it in the renal pelvis. The flexible scope is then carefully backed out leaving the catheter in the mid renal pelvis. The guidewire is subsequently removed once proper positioning is established. It is very helpful to use fluoroscopy, at least for the first session, to establish proper catheter position and rule out unexpected anatomical difficulties. Free flow of urine from the catheter or retrograde injection of contrast verifies proper position in the collecting system. Ureteral catheters are secured via silk ties to a foley catheter placed to drain the bladder and brought to rest at the bladder neck (Figure 2). The Foley catheter is either left to straight drainage or elevated over the bedrail to allow some collection into the bladder depending on whether simultaneous bladder exposure is desired. It may also be capped during treatment if formal intravesical instillation is performed at the same time. This particular technique of using a small caliber ureteral catheter over a small slippery wire is usually very atraumatic and allows free fluid flow around and out the splinted ureter. If trauma or bleeding is encountered, then treatment may need to be deferred in the case of BCG. In patients who have previously undergone cystectomy with urinary diversion, treatment is usually performed with percutaneous nephrostomy tube as retrograde access to the ureter is difficult.

We use a treatment regimen of low-dose BCG (one-third to one-tenth standard dose) plus interferon-alpha-2b

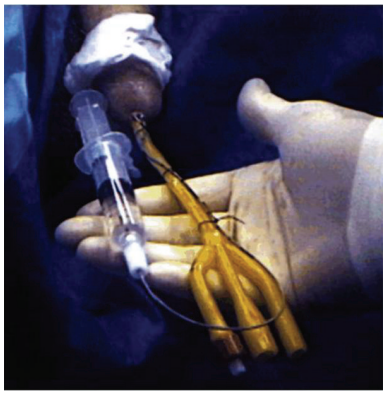

Figure 2

(50–100 million units) in 50 cc normal saline based on the effectiveness of this combination in non-muscle-invasive bladder cancer [5]. The viscosity of the full-dose BCG suspension is such that it will not spontaneously drip under gravity instillation through such a small 4 french catheter. The patient is positioned supine. The medication is suspended in an IV bag no more than 30 cm above the kidney level. Medication is instilled via microdrip tubing at the rate of 1 drop per 2 seconds, corresponding to a rate of approximately 30 cc/h. Medication is only instilled via gravity and should never be placed on a pump due to concern for increased intrarenal pressure. At the conclusion of treatment, the foley catheter is drained and then removed, bringing the attached ureteral catheters out with it. If treatments are not able to be administered via ureteral catheters, then a percutaneous nephrostomy tube can be placed at the beginning of treatment and medicine can be instilled via nephrostomy tube, with the tube capped between weekly treatments.

Patients receive weekly treatment for 6 sessions over 6 weeks. Then, 6 weeks following the last treatment, patients are restaged with bilateral upper tract washings and retrograde pyelograms, bladder washing, and random bladder biopsies along with prostatic urethral biopsy. If the results are negative, consideration is given to 3 future maintenance treatments starting 6 weeks later. While there have been no published results on the efficacy of maintenance treatment, the addition of 3 weekly maintenance treatments is well established for bladder CIS [6].

4. Literature Review

The true benefit of topical therapy, either as a primary treatment for carcinoma in situ or as an adjuvant for endoscopically treated tumors, is difficult to assess based on the variance in the reported literature. In contrast to bladder cancer, which is relatively common, upper tract urothelial cancer is uncommon and, therefore, a single center is not able to accrue significant numbers of patients for a prospective study. Additionally, heterogeneous groups of patients receive such therapy (solitary versus multifocal disease, primary versus recurrent, low- versus high-grade). Retrospective case reviews can also have methodological flaws. The goal is to maximize the effectiveness of treatment while minimizing side effects and complications. Multiple different treatment regimens have been utilized with BCG being used most commonly (Table 2). No randomized studies have been performed to evaluate such therapy, and most studies have set the number of instillations empirically based on expert opinion or extrapolating from intravesical treatment regimens.

5. BCG

In 1996, Yokogi et al. analyzed therapeutic outcomes of BCG perfusion therapy for upper urinary tract CIS in 8 renal units—5 through a percutaneous nephrostomy tube and 3 through a retrograde ureteral catheter [7]. Follow-up cystoscopy, retrograde pyelography, and selective urinary cytology were obtained 4 weeks after the last treatment and every 3 months thereafter. In 5 of 8 renal units, the cytology remained negative for 10 to 46 months after treatment, while the other 3 renal units had persistently positive cytology. Of 2 patients treated through a ureteral catheter, 1 developed a ureteral stricture and the other developed renal tuberculosis, which emphasizes that urologists must be mindful of the development of complications.

In contrast, Nishino et al. used BCG perfusion treatment (instilled weekly for 4 or 8 weeks) to treat upper tract CIS via retrograde catheterization with either a 6 French ureteral catheter or an 8 French indwelling double J ureteral stent [8]. At a mean follow-up of 22 months (range 9–38 months), all 8 renal units had negative cytology, and cytology became negative after 1 or 2 instillations of BCG. However, 1 patient had recurrent CIS in the prostatic urethra treated with intravesical BCG instillation. Complications included ureteral stenosis in 2 patients and self-limited irritative symptoms occurred in all patients.

An indwelling ureteral stent was used to treat 11 patients with upper tract CIS as reported by Nonomura et al. in 2000 [9]. Reflux up the ureteral stent was confirmed using contrast at the time of initial ureteral stent placement. BCG was instilled into the bladder weekly, 6 times in total as 1 course. At the end of 1 course, 9 cases showed negative urinary cytology; however, 2 patients had recurrence in the upper urinary tract after 4 and 8 months, and repeat BCG therapy was not effective. Two patients never normalized their cytology. The mean recurrence-free time was 19.6 months. As side effects, 8 cases (72.7%) developed bladder symptoms, and 4 presented with fever higher than 38°C, but the authors reported that no patient needed antitubercular treatment.

The efficacy of retrograde flow to the upper tract via an indwelling double J ureteral stent has been questioned. Yossepowitch et al. used performed cystograms with an indwelling stent in place and reported that retrograde flow occurred in only 56% of patients. Additionally, the mean minimal intravesical volume to obtain reflux was 170 mL, which is higher than the typically instilled treatment volume [10].

Table 2: Topical therapy of upper tract urothelial cancer.

Study	Indication	No. patients/no. renal units	Therapy	Mean follow-up, months	Comments
Jarret et al. 1995[19]	Adjuvant to percutaneous treatment	17 patients/19 renal units	BCG	55	No significant improvement in survival with BCG
Elliott et al. 1996[18]	Adjuvant to endoscopy	18 patients	BCG, thiotepa, MMC	NA	No difference in outcome between treated and untreated
Yokogi et al. 1996[7]	CIS	5 patients/8 renal units	BCG	10–46	NED in 5/8 renal units
Martinez-Pineiro et al. 1996[17]	Adjuvant to endoscopy	26 patients	BCG, MMC, thiotepa	31	12.5% recurrence with BCG, 14% with MMC, 60% with thiotepa
Keeley and Bagley, 1997[1]	Adjuvant to ureteroscopy	19 patients/21 renal units	MMC	30	35% complete response, 27% partial response, 38% no response
Patel and Fuchs, 1998[12]	Adjuvant to ureteroscopy	13 patients/17 renal units	BCG	15	NED in 15/17 renal units
Nishino et al. 2000[8]	CIS	6 patients/8 renal units	BCG	22	NED in 8/8 renal units
Nonomura et al. 2000[9]	CIS	11 patients	BCG	NA	NED in 7/11 patients
Burns et al. 2001[14]	CIS, adjuvant to endoscopy	15 patients/23 renal units	BCG-IFN	15	70% response rate
Thalmann et al. 2002[13]	Not eligible for open surgery	37 patients/41 renal units	BCG	42	87% recurred or progressed; 32% CIS were disease-free
Miyake et al. 2002[11]	CIS	15 patients/16 renal units	BCG	30	NED in 14/16 renal units
Palou et al. 2004[20]	Adjuvant to percutaneous treatment	19 patients	BCG in 14, MMC in 5	51	60% recurrence in treated patients vs 27% in untreated patients
Katz et al. 2007[16]	CIS, adjuvant to endoscopy	10 patients/11 renal units	BCG-IFN	24	80% complete response, 20% partial response

*BCG - bacillus Calmette-Guerin; MMC - mitomycin C; CIS - carcinoma in situ; IFN - interferon; NED - no evidence of disease; NA - not applicable.

Miyake et al. evaluated the efficacy of intrarenal BCG instillation for the treatment of CIS of the upper urinary tract [11]. Sixteen patients (17 renal units) were treated with BCG administered once weekly, 6 times in total using percutaneous nephrostomy tube in 5 patients, and a retrograde ureteral catheter in 11. During the median follow-up period of 30 months (range 9–90 months), 13 patients (14 renal units) remained cytologically negative. However, 1 of these 13 patients had CIS in the bladder and prostatic urethra 34 months after the BCG therapy and underwent radical cystectomy. Bladder irritability and fever higher than 38°C was observed in 12 and 9 patients, respectively; however, no patient received antitubercular treatment.

In the adjuvant setting after ureteroscopic tumor ablation, Patel and Fuchs in 1998 reported on the use of topical BCG therapy (indwelling stent and intravesical BCG in 3 renal units, and ureteral catheter instillation passed through a suprapubic stab incision in 14 which allowed the avoidance of weekly cystoscopy) [12]. At a mean follow-up of 15 months, 15 of 17 renal units were preserved and remained tumor-free. Patients in this series were followed with regular flexible ureteroscopy along with cytology washings in the clinic using topical anesthesia. The authors attributed the favorable outcome in preserving renal units to improved resections made possible by the development of small caliber ureteroscopes, improved optics, and new ablative energy sources such as the holmium:YAG laser.

In one of the largest series of topical upper tract treatment, Thalmann et al. (2002) retrospectively evaluated the results of BCG therapy for upper urinary tract disease in patients not eligible for nephroureterectomy [13]. Thirty-seven patients (22 with CIS, 15 with Ta or higher after endoscopic resection) were treated with 6 weekly perfusions of BCG via a 10 French nephrostomy tube. At a median follow-up of 42 months (range 8–137 months), 14 patients (38%) died of urothelial cancer, 11 (29%) of other causes, and 12 (33%) were alive. Other adverse outcomes included severe septicemia in 2 patients. There was no seeding of the nephrostomy tube tract and dialysis was avoided. Overall median survival was 42 months (range 1–137 months) with median recurrence-free survival of 21 months (range 1–137 months). The authors noted that this was a patient population with a poor prognosis and while BCG extended survival for some patients, it did not provide cure except for some patients with CIS. Of the patients treated in the adjuvant setting for papillary disease, only 13% remained

without recurrent or progressive disease with a median time of recurrence of 10 months. In contrast, treatment of CIS resulted in 32% of renal units remaining disease-free for a median follow-up of 51 months.

6. BCG Plus Interferon

The data regarding supplemental interferon is not firmly established, validated, or widely used for bladder cancer and certainly not for upper tract transitional cell carcinoma. However, there have been two reports of its use in treating upper tract urothelial carcinoma. We have reported on 15 patients (23 renal units) with upper tract urothelial cancer after endoscopic resection who received 6 weekly adjuvant low-dose BCG (one-tenth standard dose) and interferon-α (100 million units) [14, 15]. Nineteen of the renal units had CIS, 2 had Ta grade 1, one had Ta grade 3, and one had T1 grade 3. Sixteen were treated with ureteral catheters while seven were treated with percutaneous nephrostomy tubes. At a mean follow-up of 15.3 months (range 3–44 months), the response rate was 70% (16 of 23 renal units). The highest response rate was in patients with CIS (14 of 19; 74%). One patient had BCG sepsis that required 6 months of antitubercular therapy.

In 2007, Katz et al. published their initial experience with upper tract BCG-IFN [16]. A series of 10 patients (11 renal units) received 6 weekly courses of BCG (half strength) plus IFN-α2b (50 million units) via ureteral catheter. With a median follow-up of 24 months, 80% demonstrated a complete response, while 20% had a partial response (decrease in tumor size, number, or both). The authors reported that the treatment was well tolerated in the office setting and did not note any complications.

7. Other Agents

Less information is available on the use of mitomycin C topical treatment. In 1997, Keeley and Bagley reported on adjuvant mitomycin C (40 mg in 3 divided doses via ureteral catheter) in 19 patients (21 renal units) for high volume, recurrent, or multifocal urothelial carcinoma [1]. No systemic side effects occurred during or after treatment with mitomycin C which was attributed to the high molecular weight of mitomycin and limited systemic absorption. Thirty-five percent had a complete response, 27% had a partial response (reduction in tumor size > 50%), and 38% had no response. Tumors with a complete response were of similar size and grade as those that did not respond as well. With a mean follow-up of 30 months, none of the patients suffered local disease progression or died of disease; however, nearly all of the patients required repeat ureteroscopic treatment for residual or recurrent disease.

Due to confounding variables and heterogeneous treatment groups, direct comparisons between treatment groups in a study can be difficult. One study in 1996 from Martínez-Piñeiro et al. reported on a series of upper tract carcinoma in which 26 patients received adjuvant supplemental topical therapy, and attempted to make comparisons between different treatments [17]. BCG and mitomycin C seemed to be most effective at preventing recurrences, with recurrence rates of 12.5% and 14.2%, respectively, compared to 60% for thiotepa. Fatal aplastic anemia from systemic absorption of MMC was reported in 1 patient. In 1996, Elliott et al. reported the Mayo Clinic experience with endoscopic treatment of upper tract urothelial carcinoma in which 18 of 44 patients received some form of topical therapy (BCG in 9, MMC in 5, thiotepa in 4) [18]. Their methods did not report mode of delivery. In their sample, a difference was not found in recurrence between those who did and did not receive adjuvant topical therapy. Similarly, Jarrett et al. reported that BCG therapy showed no significant improvement in survival in 19 of 30 renal units [19].

Similarly, comparisons between treatment and nontreatment groups may be complicated by selection bias. In 2004, Palou et al. presented results of the percutaneous approach to resection of upper urinary tract urothelial carcinoma in which 14 and 5 patients received BCG and MMC instillations, respectively [20]. Median time to recurrence was 24 months and the rate of kidney preservation was 74%. The authors reported a recurrence rate of 58% in those who received topical therapy compared to 27% in those who did not; however, the topical therapy group was higher risk with higher grade disease and comprised more patients with multiple tumors. There was a trend of recurrence in patients with multifocal tumors, history of bladder carcinoma in situ, and tumor in renal pelvis. The authors concluded that the percutaneous approach to renal urothelial tumor should be considered a valid option with a good long-term outcome; however, there was an obligation to a long-lasting, strict surveillance.

An alternative experimental treatment regimen in refractory patients is sequential gemcitabine and mitomycin C. Medication dosage is 1 gm gemcitabine in 50 cc phosphate-buffered normal saline, then 40 mg mitomycin C in 40 cc sterile water. The gemcitabine is instilled followed by the mitomycin immediately afterward. We reported in 2006 on a group of patients with treatment refractory non-muscle-invasive bladder cancer (8 of 37 had upper tract involvement [21]. Gemcitabine alone was effective in only 1 of 14 patients (7%) while sequential treatment with gemcitabine followed by mitomycin was successful in 13 of 23 patients (57%). The rationale for sequential treatment is that gemcitabine is too acidic and affects mitomycin activity if given together. Additionally, gemcitabine primarily kills cells undergoing DNA synthesis (S-phase) while mitomycin is non-cell phase-specific and leads to cell cycle arrest. Gemcitabine is given first followed by mitomycin to maximize therapeutic efficacy.

8. Conclusions

Without large prospective or randomized data, the topical treatment of upper tract urothelial cancer is to some extent anecdotal. Topical treatment of upper tract urothelial cancer has a role in selected patients, who must be committed to close follow-up because of the risk of recurrence and more concerning progression. The goal of treatment is to provide noninvasive, nephron-sparing treatment without compromising oncologic outcomes. Treatment can be successfully

performed in the setting of a busy urologist's office. Further study is needed to identify the best candidates for this treatment approach and to determine which agents and schedule are most optimal. Our office-based approach to upper tract urothelial carcinoma provides the clinician with the framework to implement this treatment in practice.

References

[1] F. X. Keeley Jr. and D. H. Bagley, "Adjuvant mitomycin C following endoscopic treatment of upper tract transitional cell carcinoma," *The Journal of Urology*, vol. 158, no. 6, pp. 2074–2077, 1997.

[2] F. N. Joudi, C. N. Crane, and M. A. O'Donnell, "Minimally invasive management of upper tract urothelial carcinoma," *Current Urology Reports*, vol. 7, no. 1, pp. 23–30, 2006.

[3] D. S. Elliott, J. W. Segura, D. Lightner, D. E. Patterson, and M. L. Blute, "Is nephroureterectomy necessary in all cases of upper tract transitional cell carcinoma? Long-term results of conservative endourologic management of upper tract transitional cell carcinoma in individuals with a normal contralateral kidney," *Urology*, vol. 58, no. 2, pp. 174–178, 2001.

[4] M. C. Hall, S. S. Chang, G. Dalbagni, et al., "Guideline for the management of nonmuscle invasive bladder cancer (stages Ta, T1, and Tis): 2007 update," *The Journal of Urology*, vol. 178, no. 6, pp. 2314–2330, 2007.

[5] F. N. Joudi, B. J. Smith, and M. A. O'Donnell, "Final results from a national multicenter phase II trial of combination bacillus Calmette-Guérin plus interferon α-2B for reducing recurrence of superficial bladder cancer," *Urologic Oncology*, vol. 24, no. 4, pp. 344–348, 2006.

[6] D. L. Lamm, B. A. Blumenstein, J. D. Crissman, et al., "Maintenance bacillus Calmette-Guérin immunotherapy for recurrent Ta, T1 and carcinoma *in situ* transitional cell carcinoma of the bladder: a randomized Southwest Oncology Group study," *The Journal of Urology*, vol. 163, no. 4, pp. 1124–1129, 2000.

[7] H. Yokogi, Y. Wada, M. Mizutani, M. Igawa, and T. Ishibe, "Bacillus Calmette-Guérin perfusion therapy for carcinoma *in situ* of the upper urinary tract," *British Journal of Urology*, vol. 77, no. 5, pp. 676–679, 1996.

[8] Y. Nishino, N. Yamamoto, H. Komeda, Y. Takahashi, and T. Deguchi, "Bacillus Calmette-Guérin instillation treatment for carcinoma *in situ* of the upper urinary tract," *BJU International*, vol. 85, no. 7, pp. 799–801, 2000.

[9] N. Nonomura, Y. Ono, M. Nozawa, et al., "Bacillus Calmette-Guérin perfusion therapy for the treatment of transitional cell carcinoma *in situ* of the upper urinary tract," *European Urology*, vol. 38, no. 6, pp. 701–705, 2000.

[10] O. Yossepowitch, D. A. Lifshitz, Y. Dekel, et al., "Assessment of vesicoureteral reflux in patients with self-retaining ureteral stents: implications for upper urinary tract instillation," *The Journal of Urology*, vol. 173, no. 3, pp. 890–893, 2005.

[11] H. Miyake, H. Eto, S. Hara, H. Okada, S. Kamidono, and I. Hara, "Clinical outcome of bacillus Calmette-Guérin perfusion therapy for carcinoma *in situ* of the upper urinary tract," *International Journal of Urology*, vol. 9, no. 12, pp. 677–680, 2003.

[12] A. Patel and G. J. Fuchs, "New techniques for the administration of topical adjuvant therapy after endoscopic ablation of upper urinary tract transitional cell carcinoma," *The Journal of Urology*, vol. 159, no. 1, pp. 71–75, 1998.

[13] G. N. Thalmann, R. Markwalder, B. Walter, and U. E. Studer, "Long-term experience with bacillus Calmette-Guérin therapy of upper urinary tract transitional cell carcinoma in patients not eligible for surgery," *The Journal of Urology*, vol. 168, no. 4, part 1, pp. 1381–1385, 2002.

[14] J. A. Burns, R. D. Williams, S. P. Hedican, and M. A. O'Donnell, "The treatment of upper tract transitional cell carcinoma with BCG plus interferon-alpha," in *Proceedings of the North Central Section of the American Urological Association Annual Meeting*, Cancun, Mexico, October 2001.

[15] X. Chen, Y. Luo, H. Yamada, and M. A. O'Donnell, "BCG potentiates human chemokine induction in vivo and in vitro," *The Journal of Urology*, vol. 165, supplement 4, p. 114, abstract no. 465, 2001.

[16] M. H. Katz, M. W. Lee, and M. Gupta, "Setting a new standard for topical therapy of upper-tract transitional-cell carcinoma: BCG and interferon-α2B," *Journal of Endourology*, vol. 21, no. 4, pp. 374–377, 2007.

[17] J. A. Martínez-Piñeiro, Ma. J. García Matres, and L. Martínez-Piñeiro, "Endourological treatment of upper tract urothelial carcinomas: analysis of a series of 59 tumors," *The Journal of Urology*, vol. 156, no. 2, pp. 377–385, 1996.

[18] D. S. Elliott, M. L. Blute, D. E. Patterson, E. J. Bergstralh, and J. W. Segura, "Long-term follow-up of endoscopically treated upper urinary tract transitional cell carcinoma," *Urology*, vol. 47, no. 6, pp. 819–825, 1996.

[19] T. W. Jarrett, P. M. Sweetser, G. H. Weiss, and A. D. Smith, "Percutaneous management of transitional cell carcinoma of the renal collecting system: 9-year experience," *The Journal of Urology*, vol. 154, no. 5, pp. 1629–1635, 1995.

[20] J. Palou, L. F. Piovesan, J. Huguet, J. Salvador, J. Vicente, and H. Villavicencio, "Percutaneous nephroscopic management of upper urinary tract transitional cell carcinoma: recurrence and long-term followup," *The Journal of Urology*, vol. 172, no. 1, pp. 66–69, 2004.

[21] J. L. Maymi, N. Saltsgaver, and M. A. O'Donnell, "Intravesical sequential gemcitabine-mitomycin chemotherapy as salvage treatment for patients with refractory superficial bladder cancer," *The Journal of Urology*, vol. 175, supplement 4, p. 271, abstract no. 840, 2006.

Hindawi Publishing Corporation
Advances in Urology
Volume 2009, Article ID 826725, 4 pages
doi:10.1155/2009/826725

Review Article

Laparoscopic Nephroureterectomy: Oncologic Outcomes and Management of Distal Ureter; Review of the Literature

Andre Berger and Amr Fergany

Section of Laparoscopic and Robotic Surgery, Cleveland Clinic Foundation, Glickman Urological Institute, Cleveland, OH 44195, USA

Correspondence should be addressed to Amr Fergany, fergana@ccf.org

Received 6 May 2008; Revised 7 August 2008; Accepted 15 September 2008

Recommended by Norm D. Smith

Introduction. Laparoscopic radical nephroureterectomy (LNU) is being increasingly performed at several centers across the world. We review oncologic outcomes after LNU procedure and the techniques for the management of distal ureter. *Materials and Methods*. A comprehensive review of the literature was performed on the oncological outcomes and management of distal ureter associated with LNU for upper tract transitional cell carcinoma (TCC). *Results and Discussion*. LNU for upper tract TCC is performed pure laparoscopically (LNU) or hand-assisted (HALNU). The management of the distal ureter is still debated. LNU appears to have superior perioperative outcomes when compared to open surgery. Intermediate term oncologic outcomes after LNU are comparable to open nephroureterectomy (ONU). *Conclusions*. Excision of the distal ureter and bladder cuff during nephroureterectomy remains controversial. Intermediate term oncologic outcomes for LNU compare well with ONU. Initial long-term oncologic outcomes are encouraging. Prospective randomized comparison between LNU and open surgery is needed to define the role of these modalities in the current context.

1. Introduction

Upper tract TCC accounts for 5% of all urothelial tumors [1]. It usually occurs in patients older than 60. Compared to bladder cancer, upper tract TCC is diagnosed more frequently at advanced stages. In most series, in almost half the patients, tumor stages at diagnosis have been described as pT2 or higher. Stage is the main predictor for survival. Delay in diagnosis and treatment is related to worse prognosis. Standard management consists of open radical nephroureterectomy (ONU), which usually requires one large or two separate abdominal incisions. Since LNU was first reported by the Washington University Group in 1991 [2], the benefits of this procedure regarding perioperative morbidity, cosmesis, and convalescence have been established [3–5]. Mainly, there are 2 laparoscopic approaches: pure laparoscopic nephroureterectomy (LNU) and hand-assisted nephroureterectomy (HALNU). Despite the perioperative advantages, some oncological issues remain unclear, mainly management of the distal ureter and the role of lymphadenectomy.

2. Materials and Methods

We performed an extensive National Library of Medicine database search with no date restriction using the keywords upper tract transitional cell carcinoma, nephroureterectomy, and laparoscopic nephroureterectomy. Of the over 100 papers identified, 25 of each were selected for this review on the basis of their contribution in advancing the field with regards to (1) evolution of concepts (2) development and refinement of techniques, and (3) intermediate oncological outcomes.

3. Results and Discussion

3.1. Management of Distal Ureter. The management of the distal ureter is still controversial. The open extravesical or transvesical approach is accepted as the most oncologically safe. However, patient factors as obesity and previous history of pelvic surgery or radiotherapy can make ureteral excision more difficult. In 1952, McDonald et al. first reported an endoscopic method to handle the distal ureter [6]. In the

laparoscopic era, many attempts have been made to avoid the open approach to the distal ureter, which is still commonly used. Shalhav et al. [4] described the laparoscopic stapling of the distal ureter and bladder cuff and positive margins were associated with the method. Matin et al. compared the outcomes (median follow-up 23 months) using the two different techniques of en bloc excision of bladder cuff: 36 patients underwent technique of cystoscopic intravesical secured detachment of en bloc bladder cuff and juxtavesical ureter using needlescopic instruments percutaneouslly [7] and 12 underwent laparoscopic extravesical stapling. The stapling technique was associated with a decreased overall survival, decreased recurrence free survival, and higher positive surgical margin rate. Kurzer et al. (2006) evaluated 49 patients on a mean follow-up of 10.6 months and reported their results after cystoscopic circumferential excision of the distal ureter without primary closure of the bladder cuff with simultaneous ureteral ligation during HALNU [8]. No cases of local pelvic or peritoneal recurrences were reported. Vardi et al. (2006) reported a new technique to manage the distal ureter [9]. They proposed an en bloc excision of the bladder cuff and juxtavesical ureter during HALNU using a flexible cystoscope and a 5F electrode without repositioning the patient. Mean follow-up was 31 months (range 5–44) and none of the 6 patients presented with local recurrence. Recently, Nanigan et al. (2006) reported using robotic assistance in an attempt to decrease the technical challenge of excision of distal ureter in 11 patients [10]. As part of the procedure, they filled the bladder with a saline solution before opening it and aspirated all the fluid to avoid dissemination of cancer cells. In addition to the disadvantage of increased cost, the 6-month follow-up is not enough to evaluate local recurrence. Agarwall et al. (2008) modified the Cleveland Clinic technique. They performed a circumscribed incision in the ureteric orifice with a bladder cuff using a Collins knife. The ureter stump was ligated with an endoloop via cystoscope to avoid urine leak from the upper tract. Complete excision was achieved in all 13 patients. Five patients had bladder recurrence, 2 close to the ureteral scar [11].

Since most studies do not show any difference between different methods of handling the distal ureter, the best option is to follow individual surgeon's preference as long as the fundamental oncological concepts are preserved: having a complete resection of the distal ureter with bladder cuff and avoiding tumor spillage.

3.2. Oncological Outcomes after LNU. Laparoscopic nephroureterectomy is performed utilizing the same surgical principles as laparoscopic radical nephrectomy. A transperitoneal or retroperitoneal approach can be chosen. Most surgeons are familiar with the transperitoneal approach, which has the advantage of allowing dissection of the ureter all the way to the bladder. This is essential if endoscopic management of the distal ureter (as previously described) is planned. Surgeons familiar with the retroperitoneal approach to radical nephrectomy can perform the renal part of the operation retroperitoneally, although access to the distal ureter is difficult with this approach. This is best suited to cases where the distal ureter will be managed through an open approach. In either case the ureter is not divided and left in continuity. A clip placed on the ureter will minimize the risk of tumor seeding resulting from manipulation of the kidney. In cases of ureteric tumors, careful attention to wide dissection of the ureter is essential to avoid a positive margin or entry into the ureter with tumor spillage.

Long-term follow-up after ONU is well documented in some large series. Charbit et al. (1991) reported the first big follow-up series with upper tract TCC in 108 patients [17]. Survival rates after 5 and 10 years were 67% and 65%, respectively. Hall et al. (1998) reviewed 252 patients after ONU (median follow-up 64 months). Recurrence occurred in 67 (27%) patients and urothelial recurrences represented 69% of total [18]. Median time to recurrence was 12 months. Actuarial 5-year cancer-specific survival rates by primary tumor stage were 100% for Ta/Cis, 92% for T1, 73% for T2, and 41% for T3. Median survival for pT4 patients was 6 months. On multivariate analysis, tumor stage was a significant predictor for recurrence, whereas patient age and stage were significant predictors for survival. In contrast, a multicenter study by Ozsahin et al. (1999) evaluated 126 patients with upper tract TCC (median follow-up 39 months) and reported poor oncological outcomes of ONU [19]. In a median period of 9 months, 66% of the patients recurred. The 5- and 10-year overall survivals were 29% and 19%, respectively. Multivariate analysis revealed that independent prognostic factors influencing outcome were T staging, positive surgical margin, and tumor in the ureter. Lower survival rates in this study may be explained by high proportions of high grade (76%), nonorgan confined disease (59%), and positive surgical margin (26%).

Long-term follow-up studies after LNU are still sparse. El Fettouh et al. (2002) reported the results of 116 patients who underwent LNU on a multicenter basis with a median follow-up of 25 months [12]. Positive margins were identified in 4.5% of patients, local recurrence in 1.7%, bladder recurrence in 24%, and mean time to recurrence was 13.9 months. Distant metastasis rate was 9%; mean time to metastasis was 13 months. Two-year cancer-specific survival was 87%. According to T stage, 2-year cancer specific survival was 89% for pT1, 86% for pT2, 77% for pT3, and 0% for pT4. Muntener et al. (2007) reported the outcomes of 39 patients after LNU (median follow-up 74 months). Five-year cancer specific survival was 68%. Tumor stage was the only factor related to cancer death and ureteral tumor was the only factor associated with recurrence [13].

Cohorts comparing perioperative and short/intermediate oncological outcomes between ONU and LNU have been published. Bariol et al. (2004) evaluated 25 patients who underwent LNU and 42 who underwent ONU for TCC in a median follow-up of 101 and 96 months, respectively [14]. Local and bladder recurrence rates were 28% (7 patients) for LNU and 42% (15 patients) for ONU, while more ureteral tumors were described in ONU. One and 5-year metastases-free survivals were 80% and 72% for LNU and 87% and 82% for ONU, while no statistical difference between the two surgical treatments was found. Rouprêt et al. (2007) compared 20 patients who underwent LNU (median follow-up

Table 1: LNU series and comparative studies.

	Patients (n) LNU/ONU	Median follow-up (mo)	Recurrence (%)	Local recurrence (%)	Bladder recurrence (%)	Distant metastasis (%)	Overall survival (%)	Cancer-specific survival (%)	Risk factor associated to survival (%)
LNU X Series									
El Fettouh (2002) [12]	116	25	Not stated	Not stated	24	9	Not stated	87 (2 year)	Not stated
Muntner (2007) [13]	39	74	46	5	Not stated	18	59 (5 year)	68 (5 year)	Tumor stage
LNU versus open surgery									
Bariol (2004) [14]	58 26/22	101/96	Not stated	8/15	28/ 42	28/18	56/59	72/82 (5 year)	Not stated
Rouprêt (2006) [15]	46 20/ 26	68/ 78	19 (urothelial)	Not stated	Not stated	10/35	Not stated	90/61 (5 year)	Tumor stage and grade
Manabe (2007) [16]	224 58/166	14/ 28 (mean)	33/38	1 case port/ 2 cases	Not stated	17/20	84/84 (2 year)	85/82 (2 year)	Tumor stage and grade

68.5 months) to 26 who underwent ONU (median follow-up 78 months). Recurrence occurred in 20% of cases of LNU and 53% of ONU [15]. Median time to recurrence was 15 and 18 months, respectively. Five-year cancer-specific survival was 90% and 61% and 5-year recurrence-free survival was 71% and 51%, respectively. Okegawa et al. (2006) compared 25 LNU (mean follow-up 24 months) and 23 ONU (mean follow-up 29 months). In LNU and ONU groups, recurrence rates were 20% and 17% and mean time to recurrence were 9.5 and 23.4 months [20]. Distant metastasis rate was 8% for LNUX and 13% for ONUX. Two-year cancer-specific survival was 91% for LNU and 89% for ONU. No significant difference was detected in recurrence-free survival and cancer-specific survival. Manabe et al. (2007) evaluated 58 patients after LNU (mean follow-up 13.6 months) and 166 after ONU (mean follow-up 28 months). Bladder recurrence was reported in 33% of patients after LNU and in 38% after ONU [16]. Distant metastases were reported in 17% and 20% of the patients, respectively. The 2-year recurrence-free survivals were 76% and 82%. No difference was found in cancer-specific survival.

Some recent series report results after hand-assisted LNU (HALNU), but oncologic outcomes are limited. Wolf et al. evaluated 54 patients who underwent HALNU with median follow-up of 25 months [21]. Urothelial recurrences occurred in 66% patients. History of bladder tumors was associated with urothelial recurrence. Nonurothelial recurrences were found in 25% of the patients at a mean 10.4 months follow-up. Age and grade correlated with nonurothelial recurrence. The 2 and 3-year cancer-specific survival were 86% and 80%, respectively. Organ-confined disease and nonorgan-confined disease were associated with a 3-year survival of 100% and 36%, respectively. High-grade disease correlated with poorer 3-year cancer-specific survival. Chung et al. (2007) also described comparable recurrence free, 3-year cancer-specific and overall survivals in 39 patients after HALNU (median follow-up 48 months) and 41 patients after ONU (median follow-up 62 months) [22].

The propensity for dissemination of high-grade TCC is well known. An important concern with laparoscopic approach is port site metastasis. Seven cases have been published so far. No surgical bag was used in six cases and the surgical bag was torn during retrieval of the specimen in one case [22].

Recently, the importance of extended lymph node dissection for bladder cancer regarding staging and prognosis has been established. Given the histological similarity between bladder cancer and upper tract TCC, lymphadenectomy should also be important for the management of upper tract TCC. Kondo et al. (2007) evaluated 169 patients that underwent open nephroureterectomy divided in 3 different groups: complete lymphadenectomy, incomplete lymphadenectomy, and no lymphadenectomy [23]. Extended lymphadenectomy improved survival in patients with pT3 stage or higher. On multivariate analysis, complete lymphadenectomy, T stage and grade were significant prognostic factors for cancer-specific survival. Brausi et al. (2007) reported retroperitoneal lymph node dissection and T stage as the only independent significant prognostic factors on overall survival [24]. Busby et al. (2006) found no difference between ONU and LNU concerning number of lymph nodes retrieved, median number of positive nodes retrieved, and median density of positive nodes, showing that lymphadenectomy can be performed in the laparoscopic approach as adequately as in open approach [25].

Intermediate oncological outcomes after LNU are similar to ONU. Series combining long follow-up and large number of patients are lacking. Finally, to confirm these previous encouraging findings, prospective randomized trials are still needed Table 1 summarizes the oncological outcomes after LNU.

4. Conclusion

Many centers worldwide are now performing LNU. Contemporary series have demonstrated technical feasibility and safety. The management of distal ureter is still debated. Although large series of 5-year oncologic data are not yet available in the LNU literature, reports indicate that intermediate and long-term oncological outcomes are similar to ORC. Carefully designed prospective randomized trials comparing LNU and ONU are necessary to define the role of these modalities in the current and future management of upper tract TCC.

References

[1] E. R. Tawfiek and D. H. Bagley, "Upper-tract transitional cell carcinoma," *Urology*, vol. 50, no. 3, pp. 321–329, 1997.

[2] R. V. Clayman, L. R. Kavoussi, R. S. Figenshau, P. S. Chandhoke, and D. M. Albala, "Laparoscopic nephroureterectomy: initial clinical case report," *Journal of Laparoendoscopic Surgery*, vol. 1, no. 6, pp. 343–349, 1991.

[3] I. S. Gill, G. T. Sung, M. G. Hobart, et al., "Laparoscopic radical nephroureterectomy for upper tract transitional cell carcinoma: the Cleveland clinic experience," *The Journal of Urology*, vol. 164, no. 5, pp. 1513–1522, 2000.

[4] A. L. Shalhav, M. D. Dunn, A. J. Portis, A. M. Elbahnasy, E. M. McDougall, and R. V. Clayman, "Laparoscopic nephroureterectomy for upper tract transitional cell cancer: the Washington University experience," *The Journal of Urology*, vol. 163, no. 4, pp. 1100–1104, 2000.

[5] M. Tsujihata, N. Nonomura, A. Tsujimura, K. Yoshimura, Y. Miyagawa, and A. Okuyama, "Laparoscopic nephroureterectomy for upper tract transitional cell carcinoma: comparison of laparoscopic and open surgery," *European Urology*, vol. 49, no. 2, pp. 332–336, 2006.

[6] H. P. McDonald, W. E. Upchurch, and C. E. Sturdevant, "Nephro-ureterectomy: a new technique," *The Journal of Urology*, vol. 67, no. 6, pp. 804–809, 1952.

[7] S. F. Matin and I. S. Gill, "Recurrence and survival following laparoscopic radical nephroureterectomy with various forms of bladder cuff control," *The Journal of Urology*, vol. 173, no. 2, pp. 395–400, 2005.

[8] E. Kurzer, R. J. Leveillee, and V. G. Bird, "Combining hand assisted laparoscopic nephroureterectomy with cystoscopic circumferential excision of the distal ureter without primary closure of the bladder cuff—is it safe?" *The Journal of Urology*, vol. 175, no. 1, pp. 63–67, 2006.

[9] I. Y. Vardi, J. A. Stern, C. M. Gonzalez, S. Y. Kimm, and R. B. Nadler, "Novel technique for management of distal ureter and en block resection of bladder cuff during hand-assisted laparoscopic nephroureterectomy," *Urology*, vol. 67, no. 1, pp. 89–92, 2006.

[10] D. K. Nanigian, W. Smith, and L. M. Ellison, "Robot-assisted laparoscopic nephroureterectomy," *Journal of Endourology*, vol. 20, no. 7, pp. 463–465, 2006.

[11] D. K. Agarwal, H. S. Khaira, D. Clarke, and R. Tong, "Modified transurethral technique for the management of distal ureter during laparoscopic assisted nephroureterectomy," *Urology*, vol. 71, no. 4, pp. 740–743, 2008.

[12] H. A. El Fettouh, J. J. Rassweiler, M. Schulze, et al., "Laparoscopic radical nephroureterectomy: results of an international multicenter study," *European Urology*, vol. 42, no. 5, pp. 447–452, 2002.

[13] M. Muntener, M. E. Nielsen, F. R. Romero, et al., "Long-term oncologic outcome after laparoscopic radical nephroureterectomy for upper tract transitional cell carcinoma," *European Urology*, vol. 51, no. 6, pp. 1639–1644, 2007.

[14] S. V. Bariol, G. D. Stewart, S. A. McNeill, and D. A. Tolley, "Oncological control following laparoscopic nephroureterectomy: 7-year outcome," *The Journal of Urology*, vol. 172, no. 5, part 1, pp. 1805–1808, 2004.

[15] M. Rouprêt, V. Hupertan, K. M. Sanderson, et al., "Oncologic control after open or laparoscopic nephroureterectomy for upper urinary tract transitional cell carcinoma: a single center experience," *Urology*, vol. 69, no. 4, pp. 656–661, 2007.

[16] D. Manabe, T. Saika, S. Ebara, et al., "Comparative study of oncologic outcome of laparoscopic nephroureterectomy and standard nephroureterectomy for upper urinary tract transitional cell carcinoma," *Urology*, vol. 69, no. 3, pp. 457–461, 2007.

[17] L. Charbit, M.-C. Gendreau, S. Mee, and J. Cukier, "Tumors of the upper urinary tract: 10 years of experience," *The Journal of Urology*, vol. 146, no. 5, pp. 1243–1246, 1991.

[18] M. C. Hall, S. Womack, A. I. Sagalowsky, T. Carmody, M. D. Erickstad, and C. G. Roehrborn, "Prognostic factors, recurrence, and survival in transitional cell carcinoma of the upper urinary tract: a 30-year experience in 252 patients," *Urology*, vol. 52, no. 4, pp. 594–601, 1998.

[19] M. Ozsahin, A. Zouhair, S. Villà, et al., "Prognostic factors in urothelial renal pelvis and ureter tumours: a multicentre rare cancer network study," *European Journal of Cancer*, vol. 35, no. 5, pp. 738–743, 1999.

[20] T. Okegawa, A. Odagane, H. Ide, S. Horie, K. Nutahara, and E. Higashihara, "Oncological outcome of retroperitoneoscopic nephroureterectomy for upper urinary tract transitional cell carcinoma," *International Journal of Urology*, vol. 13, no. 5, pp. 493–497, 2006.

[21] J. S. Wolf Jr., A. Dash, B. K. Hollenbeck, W. K. Johnston III, R. Madii, and J. S. Montgomery, "Intermediate followup of hand assisted laparoscopic nephroureterectomy for urothelial carcinoma: factors associated with outcomes," *The Journal of Urology*, vol. 173, no. 4, pp. 1102–1107, 2005.

[22] S.-D. Chung, S.-C. Chueh, M.-K. Lai, et al., "Long-term outcome of hand-assisted laparoscopic radical nephroureterectomy for upper-tract urothelial carcinoma: comparison with open surgery," *Journal of Endourology*, vol. 21, no. 6, pp. 595–599, 2007.

[23] T. Kondo, H. Nakazawa, F. Ito, Y. Hashimoto, H. Toma, and K. Tanabe, "Impact of the extent of regional lymphadenectomy on the survival of patients with urothelial carcinoma of the upper urinary tract," *The Journal of Urology*, vol. 178, no. 4, part 1, pp. 1212–1217, 2007.

[24] M. A. Brausi, M. Gavioli, G. De Luca, et al., "Retroperitoneal lymph node dissection (RPLD) in conjunction with nephroureterectomy in the treatment of infiltrative transitional cell carcinoma (TCC) of the upper urinary tract: impact on survival," *European Urology*, vol. 52, no. 5, pp. 1414–1420, 2007.

[25] J. Busby, G. Brown, and S. Matin, "Efficacy of lymphadenectomy during laparoscopic radical nephroureterectomy: comparison to the open approach," *The Journal of Urology*, vol. 175, no. 4S, p. 344, 2006.

Hindawi Publishing Corporation
Advances in Urology
Volume 2009, Article ID 316807, 9 pages
doi:10.1155/2009/316807

Review Article

Laparoscopic Nephroureterectomy: The Distal Ureteral Dilemma

Shalom J. Srirangam,[1] Ben van Cleynenbreugel,[2] and Hein van Poppel[2]

[1] *Department of Urology, Royal Blackburn Hospital, Blackburn, BB2 3HH, UK*
[2] *Department of Urology, University Hospital KU Leuven, Herestraat 49, 3000 Leuven, Belgium*

Correspondence should be addressed to Shalom J. Srirangam, sjsrirangam@yahoo.co.uk

Received 26 May 2008; Accepted 22 September 2008

Recommended by Norm D. Smith

Transitional cell carcinoma affecting the upper urinary tract, though uncommon, constitutes a serious urologic disease. Radical nephroureterectomy remains the treatment of choice but has undergone numerous modifications over the years. Although the standard technique has not been defined, the laparoscopic approach has gained in popularity in the last two decades. The most appropriate oncological management of the distal ureteral and bladder cuff has been a subject of much debate. The aim of the nephroureterectomy procedure is to remove the entire ipsilateral upper tract in continuity while avoiding extravesical transfer of tumor-containing urine during bladder surgery. A myriad of technical modifications have been described. In this article, we review the literature and present an overview of the options for dealing with the lower ureter during radical nephroureterectomy.

Primary urothelial carcinoma of the upper urinary tract accounts for about 5% of all renal and urothelial malignancies. Though relatively uncommon, the incidence of upper tract transitional cell carcinoma (TCC) appears to be slowly increasing [1–3]. While alternative therapies, such as endoscopic ablation/resection and segmental ureteral resection, have been adopted, radical nephroureterectomy is considered the ideal treatment for upper tract TCC.

Le Dentu and Albarran performed the first complete open nephroureterectomy (ONU) for upper tract TCC in 1898 [4], but it was Kimball and Ferris in 1934 who established the need for complete removal of the ipsilateral renal tract on finding a high incidence of tumor in the remaining ureter after simple nephrectomy for upper tract TCC [5]. Upper tract TCC is frequently multifocal, has a higher rate of ipsilateral ureteral recurrence, is often associated with higher grade disease (42–47% grade 3; 18–48% grade 2) and, therefore, carries a poorer prognosis compared to bladder TCC [6, 7]. Thus in the presence of a normal contralateral upper tract, complete removal of the ipsilateral kidney, ureter, and bladder cuff remains the gold standard treatment for large, high-grade, or invasive TCC.

The procedure may be undertaken open or laparoscopically. The "standard" laparoscopic nephroureterectomy (LNU) technique has not been defined and continues to evolve. Variations include utilization of a pure laparoscopic technique versus a hand-assisted technique; transperitoneal versus retroperitoneal; and a myriad of approaches to deal with the lower ureter [8]. Indeed, the issue of the most appropriate oncological management of the lower ureter and bladder cuff has been the most debated and controversial aspect of this operation since McDonald et al. attempted to lessen surgical morbidity by advocating endoscopic resection of the distal ureter in 1952 [9]. Many approaches, varying in technique and results, have been described in [8]. Irrespective of the adopted technique, the challenge is to ensure adherence to principles of reproducibility of results, patient safety, and oncological outcomes. TCC is multifocal and even with a negative cystoscopy, up to a third of patients may have viable persistent tumor within the bladder. Some patients will have vesical or para-vesical recurrence due to urine spillage and the primary focus of the nephroureterectomy procedure remains to avoid extravesical transfer of tumor-containing urine during bladder surgery. This is the key feature of improvements in the surgical technique. In this paper, we aim to discuss the dilemma of the distal ureter and present an overview of the diverse modifications employed in managing the distal ureter.

1. Management of the Distal Ureter

The risk of tumor recurrence within the residual ureteral stump/periureteral meatal region in cases of incomplete upper tract removal is often cited as between 30 and 64% [10–12]. Total excision of the entire ureter, including the distal ureter with its intramural portion, the ipsilateral ureteral orifice and bladder cuff is mandatory and represents a distinct portion of the case, whether an open or laparoscopic approach to the kidney is used. Ideally, this is achieved by removal of an *en bloc*, "closed system" specimen following controlled occlusion of the ureteral orifice. Continuity of the specimen, though desirable, may be conceded to aid ease of extraction as long as the distal ureter is ligated and divided at tumor-free location. The key issue is to avoid extravesical urine contact and adherence to these principles will reduce risk of spillage or seeding of tumor cells.

The following techniques, along with some minor variations, have been advocated in order to accomplish distal ureteral removal:

(i) "pluck" technique,

(ii) intussusception technique,

(iii) pure laparoscopy,

(iv) open resection.

2. Transurethral Resection of Ureteral Orifice ("Pluck" Technique)

This involves the transurethral disarticulation of the intramural ureter along with the ureteral orifice (UO) using a standard resectoscope loop or Collin's knife, usually prior to performing the laparoscopic nephrectomy. The UO is resected deep into extravesical fat allowing subsequent "plucking" of the entire ureter from above. Though the original intention was to decrease morbidity by avoiding a second lower abdominal incision during open surgery, this is a less compelling argument with laparoscopic surgery as specimen extraction mandates a larger incision.

Following UO resection, the patient is put in the flank position for LNU. The kidney is mobilized along with the ureter down to the level of the pelvic brim. Gentle traction on the ureter should result in the removal of the entire length of ureter down to the level of the detached distal ureter. An indwelling Foley catheter is left in the bladder for at least 7 days. The major concern related to this technique is the risk of tumor cell spillage into the retroperitoneum with subsequent seeding and local recurrence.

A number of authors have published small retrospective series employing the pluck technique and report no local disease recurrences [13–15]. Palou et al. reported no local recurrences after an average followup of 20 months in 31 patients with mainly high grade upper tract TCC [13]. In a large multicenter, five-institution study comprising 116 patients who underwent LNU, no difference in local recurrence was noted between the various techniques of distal ureteral removal at a median followup time of 25 months [14]. Geavlete et al. recently reported on 100 ONU patients from a single center, the majority of whom (72 cases) had undergone a pluck transurethral detachment with coagulation of the resected area [16]. The remainder (28 cases) were managed by ureteral stripping. No local recurrences were reported after a mean followup of 44 months.

Nevertheless, the propensity for urological malignancies, including TCC, to seed is well recognized [17]. Not surprisingly, therefore, local recurrence following a pluck nephroureterectomy has been noted on many occasions, often occurring early and with tragic consequences [18–22]. Ko et al. reported on 51 patients undergoing LNU with the distal ureter being managed by either the open ($n = 30$) or the pluck technique ($n = 20$) [23]. The transurethral pluck was restricted to TCC located in the calices, renal pelvis, and ureter proximal to the pelvic brim and produced recurrence rates similar to those in an open fashion. Of note, however, is that five patients had an unplanned incomplete ureterectomy and four had tumor recurrences (three in the form of metastatic disease).

Furthermore, utilizing the pluck technique is likely to permit continued urine extravasation from the cancer-bearing ureter [24, 25]. Additionally, due to the absence of an identifiable marker within the detached distal ureter, confirmation of complete specimen removal is not possible, raising the theoretical possibility of local recurrence in any remaining portion of ureter [24].

2.1. Pluck Technique Modifications. Various modifications on the pluck theme have been described in an attempt to minimize tumor spillage. Tan et al. advocated completion of the laparoscopic nephrectomy first with the clipping of the ureter to prevent distal migration, followed by transurethral Collin's knife mobilization of the distal ureter and bladder cuff [8]. Recently, a novel technique has been described involving an initial partial circumscribing of the bladder cuff with a Collin's knife with a 1 cm margin around the ipsilateral ureteral orifice [26]. A preformed PDS Endoloop *(Ethicon, Sommerville, NJ, USA)* is then passed through the cystoscope to ligate and occlude the ureteral orifice. The bladder cuff is then completely circumscribed down to perivesical fat and subsequently removed *en bloc* following kidney mobilization. The Endoloop also acts as a marker ensuring complete specimen removal. A similar procedure has been described using a transurethrally placed 5-mm laparoscopic hem-o-lok clip on the ureteral stump, as an alternative to the Endoloop, to ensure a closed system [27]. Both these studies report no pelvic tumor recurrences in the short term [26, 27].

2.2. Ureteral Unroofing. The ureteral *unroofing technique* has been described and popularized by the Washington University group [28]. This can only be employed in transperitoneal LNU and briefly comprises cystoscopic incision of the entire anterior length of the intramural ureter; electrocautery to the cut edges and floor of the intramural ureter; placement of a 7.5 F occlusion ureteral balloon catheter in the renal pelvis to prevent urine spillage; laparoscopic dissection of the kidney and ipsilateral ureter down to the level of the

bladder and specimen detachment following placement of an Endo-GIA stapler on the bladder cuff. This technique has the theoretical advantage of minimizing urine leakage while maintaining a truly minimally invasive approach and promoting ureteral identification intraoperatively. It is contraindicated in the presence of active ureteral or bladder TCC. Other potential disadvantages include requirement of fluoroscopy, risk of injury to the contralateral ureteral orifice as the stapler is applied "blindly" and longer operating times [8]. Employment of the stapler device has produced hypothetical concerns relating to stone formation, tumor recurrence within urothelium trapped in the staple line, and the inability to visualize this area satisfactorily during subsequent surveillance cystoscopic inspections. These complications have not been reported to be a clinical problem. The same investigators compared LNU in 25 patients (using the unroofing technique) and ONU performed in 17 cases with a mean followup of 24 months and 43 months, respectively [29]. LNU took twice as long as ONU, but was associated with less pain, fewer complications, a shorter hospital stay, and quicker convalescence. Although there was no statistically significant difference in the disease-specific survival rate and proportion of bladder tumor recurrences, concerningly, there were 3 retroperitoneal recurrences in the LNU group. Whether this is due to surgical technique or the high tumor grade in these patients in unclear from the study.

2.3. Pluck Technique in HALNU. HALNU offers distinct advantages when considering how best to manage the distal ureter. Firstly, the requirement of a longer incision to facilitate a hand port will allow improved access to the bladder and distal ureter, offering the surgeon the option of either an extravesical approach, open transvesical cystotomy, or detaching the ureter using a transurethral technique [30]. In addition, the operator can facilitate dissection and resection by providing gentle countertraction on the distal ureter. Tumor spillage can be prevented by occlusion of the distal ureter by a clip or the surgeon's hand. Alternatives to the endoscopic management of the distal ureter during HALNU have been reported. Gonzalez et al. described a technique implementing insertion of a laparoscopic trochar, followed by introduction of a 24 F nephroscope allowing an endoscopic Collin's knife incision of the bladder cuff [31]. This is performed subsequent to dissection of the kidney and ureter, and after clips have been placed on the lower ureter. Alternatively, a similar technique may be performed without the need for a bladder port or patient repositioning [32]. Placement of the patient in a modified dorsal lithotomy position will permit introduction of a transurethral resectoscope to perform the bladder cuff incision. The oncological sequalae of this same group of patients was recently published, and none of the 49 patients had developed a pelvic recurrence after a mean followup period of 10.6 months [33]. Notably, the authors emphasized early ligation of ureter but did not routinely close the bladder. Vardi et al. reported a novel modification to this technique by inserting a flexible cystoscope per urethra and a 5 F electrode (ACMI, Norwalk, Conn, USA) to incise a circumferential 2-cm cuff of bladder around the UO using cutting and coagulating current [34]. Patient repositioning after the nephrectomy is avoided and the bladder opening is not closed. No pelvic recurrences were noted in their small group of patients after a mean followup of 31 months.

In summary, therefore, pluck techniques are contraindicated in the presence of lower ureteral tumor and widespread urinary tract carcinoma in situ. Coexistent bladder TCC should preclude the situation, where the bladder is left "open" with potential exposure of the perivesical tissues to malignant-cell laden urine. Patients with previous pelvic irradiation and active inflammatory conditions of the bladder are probably not ideal candidates for endoscopic procedures. Blind pulling of the ureter is discouraged to minimize ureteral tearing and the possibility of residual tissue. While retrospective studies have not confirmed the superiority of the open over the pluck method, the oncologically safe practice of maintaining a "closed" system is preferred and retroperitoneal exposure to potentially tumor cell-laden urine for any duration of time, in our opinion, is best avoided.

3. Intussusception Technique

This technique, first described by McDonald in 1953, has undergone various subsequent modifications around a central theme of ureteral ligation and removal either by stripping or intussusception [35]. Principles of this technique include initial catheterization of the ureter using either a ureteral catheter or a stone basket ligation and division of the ureter as part of the renal mobilization, securing of the distal ureter to the ureteral catheter/stone basket, transurethral incision of the bladder cuff, followed by removal of the distal ureter by gentle traction on the catheter via the urethra [8, 18]. The distal ureter intussuscepts into the bladder and can either be removed transurethrally or via a small lower midline incision and anterior cystotomy. A variety of technical devices, including sutures, vein stripper, balloon catheter, and double ligation, have been described in an attempt to improve ureteral excision of the ureter [18, 36–38].

Though its long-term safety during LNU has not been investigated, even after 5 years' followup, Clayman et al. reported no pelvic tumor recurrences in 14 patients undergoing ureteral stripping during ONU [36]. This is confirmed in a literature review by Laguna and de la Rosette, who compared the stripping and pluck techniques [18]. While there were no reports of local disease recurrence in the stripping group, this technique was associated with a 10% complication rate (including retained ureters and catheter breakage) resulting in an open conversion rate of between 9.5 and 12.5% in patients after difficult extraction.

Since the ureter is transected, it is contraindicated for ureteral tumors and primarily confined to low-grade renal pelvic tumors. Additionally, any cause for pelvic fibrosis, such as previous surgery or irradiation and retroperitoneal fibrosis, may further increase the risk of retention of ureteral remnant. Bladder mucosa is exposed to ureteral mucosa with the potential for seeding. Its main drawback is its failure

to guarantee adequate excision of the intramural ureter and bladder cuff, potentially resulting in tumor recurrence, and is thus unlikely to gain universal acceptance following LNU.

4. Pure Laparoscopic

A completely laparoscopic approach offers distinct advantages in terms of blood loss, postoperative pain, recovery times, and equivalent short- and intermediate-term oncologic efficacy. The kidney and ureter are mobilized in the standard fashion and the distal ureter may be secured by one of 2 main techniques:

(i) laparoscopic extravesical stapling of the distal ureter [28, 39];

(ii) transvesical laparoscopic detachment and ligation (Cleveland approach) [40, 41].

4.1. Laparoscopic Stapling. This method is usually combined with a ureteral unroofing procedure. The ureter is clipped early and dissected caudally until it diverges to merge with the detrusor muscle fibers at the ureterovesical junction (UVJ). Gentle traction on the ureter will tent up the wall of the bladder at the UVJ enabling placement of a 12-mm laparoscopic GIA tissue stapler (Endo-GIA; Auto-Suture, Norwalk, Conn, USA) or a large hem-o-lok clip. If desired, an ontable bladder fill with saline/indigo carmine solution may be performed to exclude extravasation and/or a delayed cystogram is obtained before catheter removal. A more recent trend has been to perform stapling of the bladder cuff as the initial step, followed by a transurethral resection of the ipsilateral UO till the staple line is reached [8].

Laparoscopic stapling has manifest advantages. It may help reduce operative time and facilitates a minimally invasive procedure while maintaining a "closed" urinary tract, thus preventing tumor spillage. There are, however, numerous concerns related to staple usage. Deployment of the stapler may prove awkward in the restricted pelvic space. An error in judgment may result in either part of the intramural ureter being left behind or inadvertent injury to the contralateral UO. In addition, the stapled margin cannot be assessed histologically. The Nagoya group reported stone formation at the staple line in 3 (5.7%) of 53 patients at an average of 20 months postoperatively [42]. Using a porcine model, Venkatesh et al. investigated the viability of bladder cells using 4 types of laparoscopic vascular and tissue stapler devices [43]. Viable cells were noted within the staple line in all cases and this could represent a potential risk for tumor recurrence in patients.

Romero et al. compared long-term safety and oncologic efficacy of extravesical laparoscopic stapling ($n = 12$) with the traditional transvesical open excision ($n = 12$) at nearly 4 years followup [44]. An increased positive margin rate (3 versus 0 patients) and local recurrence rate (2 versus 0 patients), and decreased recurrence-free interval were noted in the laparoscopic stapled group compared to the open group. However, none of these results was statistically significant probably owing to the small numbers. A number of authors have compared the various methods to distal ureteral excision and reported a higher incidence of positive surgical margins (up to 25%) and local recurrence (up to 15%) in the pure LNU with laparoscopic stapling cohort [25, 29, 45]. This highlights the need for meticulous removal of the whole ureter, UO, and bladder cuff. Contraindications include presence of mid/lower ureteral and bladder TCC.

More recently, Tsivian et al. described a variation on the laparoscopic stapling technique, using a 10-mm LigaSure Atlas (Valleylab, Tyco Healthcare UK Ltd, Gosport, UK) [46]. The bladder cuff was excised laparoscopically in an extravesical fashion using the LigaSure, without the need for staples. There were 2 bladder recurrences distant from the site of surgery but no reports of local recurrence in 13 patients followed up for nearly a year. Suturing of the bladder following LNU may be performed by those skilled in this technique.

4.2. Transvesical Laparoscopic Detachment and Ligation. This novel technique of securing the distal ureter and bladder cuff using transvesically placed laparoscopic ports was described by Gill et al. and is almost exclusively employed by the Cleveland clinic group [40, 41]. In this modified "pluck" procedure, a transurethral Collin's knife incision of the bladder cuff is performed after placement of a catheter into the affected ureter. Simultaneously, two 5-mm balloon-tipped ports are inserted suprapubically into the bladder. The incised UO is tightly snared using a 5-mm Endoloop (Ethicon, Cincinnati, Ohio, USA), preventing urine leakage from the ureter. Traction on the incised bladder cuff enables the mobilization of 3-4 cm of distal ureter into the bladder. The entire ureter can then be pulled through cephalad after radical nephrectomy and ureteral dissection. A bladder catheter is left in situ for 1 week.

The authors claim that the transvesical technique adheres to general oncological principles of complete and controlled en bloc specimen extraction. The ureteral catheter and Endoloop occlude the ureter, thereby reducing urine leakage. An indwelling ureteral catheter may aid identification and mobilization of the ureter during the laparoscopic procedure. Complete retrieval is confirmed by visualization of the Endoloop. However, this may be a difficult technique to master for most urologists and operating time is usually lengthened by 60–90 minutes [24, 47]. Other criticism of this approach includes the potential for irrigation fluid extravasation resulting in dilutional hyponatremia, the need for patient repositioning, and the possibility of port-site metastases. Contraindications include the presence of distal ureteral TCC or concomitant bladder tumors, prior pelvic surgery or irradiation and obesity [45].

LNU with the transvesical technique has been evaluated against ONU in a retrospective series [41]. Gill et al. reported that 27 patients who had undergone the former procedure had statistically significant superior results compared to the latter (35 patents) technique with regards to surgical time, blood loss, narcotic analgesia requirements, hospital stay, convalescence, and complication rates. Bladder recurrence rates and cancer specific survival were similar in both groups

and no local retroperitoneal or port-site recurrence were diagnosed in any patients. The same group reviewed their outcomes in 60 patients following LNU, who had either had a laparoscopic stapling ($n = 12$) or transvesical laparoscopic detachment of the distal ureter ($n = 36$) [45]. Following a mean followup period of 23 months, positive margins were more common in the former group (25 versus 2.8%) as were the rates of bladder recurrences at the ipsilateral ureteral scar/orifice (41.7 versus 13.9%), retroperitoneal recurrence (8.3 versus 5.6%), and distant metastasis (25 versus 8.3%). None of these differences was statistically significant and definitive conclusions are difficult to derive from such small retrospective series.

Recently, Cheng et al. described a similar technique utilizing a pneumovesicum to secure the UO and bladder cuff [48]. Following initial cystoscopy to exclude bladder tumors, three 5-mm PediPorts (Tyco) are inserted suprapubically into the bladder. Following the establishment of a carbon dioxide pneumovesicum, the ipsilateral UO is closed using a stitch and the bladder cuff is incised down to fat using diathermy scissors. The bladder defect is closed using Polysorb sutures before completion of a standard 5-port laparoscopic nephroureterectomy. The authors report on a single case and propose that gas insufflation minimizes tumor spillage/seeding and permits a superior endoscopic view, even in the presence of bleeding, compared to liquid endoscopy as in the Cleveland method.

5. Open Removal

The open technique (either 2-incision or extended single incision) forms the standard against which all techniques are measured. Typically performed after nephrectomy, it can be performed through a lower midline, modified Pfannenstiel, or Gibson incision. The lower ureter is clipped, dissected free, and removed in continuity with the bladder cuff. The bladder cuff may be secured extravesically (using a right angle clamp) or via an anterior cystotomy. The en bloc specimen is delivered through the same incision.

In the review of 252 patients performed by Hall et al., 194 patients had undergone ONU with open bladder cuff excision for TCC and showed excellent long-term local control [6]. Klingler et al. reported outcomes at a mean followup period of 22 months in 19 patients who had an LNU with open bladder cuff excision versus 15 patients with a standard ONU [49]. Only 1 patient in the LNU group, with a high-grade, locally infiltrative, lymph node positive final histology (pT3b pN2 G3 TCC) had local recurrence. There was no significant difference in local recurrence rates between the laparoscopic and open group.

A recent multicenter retrospective Belgian study analyzed 100 patients following LNU for TCC [50]. Of these, 55 patients had an open excision of the distal ureter while the rest (45 patients) underwent a laparoscopic technique. Local recurrence was noted in 13 out of 100 cases of which 6 of 55 cases (11%) had open distal ureter management and 7 of 45 (16%) laparoscopic handling of the distal ureter. The investigators attribute the higher local recurrence rate to the larger proportion of high grade disease being operated on.

The open technique is not without its pitfalls. The "blind" extravesical clamping may compromise the contralateral UO and does not inevitably guarantee adequate bladder cuff retrieval [51]. An anterior cystotomy must be avoided in the presence of active bladder TCC as it retains the potential to seed tumor into the extravesical space. Furthermore early ligation/clipping of the ureter during the nephrectomy part is advisable. Additionally, prior pelvic surgery or irradiation and obesity may render the open procedure more challenging. Notwithstanding these potential concerns, the open approach to distal ureteral removal is oncologically sound and minimizes tumor spillage and therefore has withstood the test of time [52]. An open incision is often required for specimen extraction and adds little to overall morbidity, while providing visual confirmation of complete upper tract resection. It also enables accurate histological examination and reporting by the pathologist. Patient repositioning is usually required but not always mandatory. At our institution, this is the preferred method of dealing with the distal ureter following LNU. Table 1 summarizes the data from some of the studies (all retrospective in design) comparing the different techniques of distal ureteral management and associated outcomes.

6. Open or Laparoscopic?

Given the uncommon nature of upper tract TCC, there is a scarcity of prospective randomized studies with long-term followup comparing both modalities of nephroureterectomy. The "gold standard" open surgery offers excellent access but at the expense of increased patient morbidity. Since being first described in 1991 by Clayman et al., increasing surgical experience and equipment quality has seen LNU emerge as a viable option with the express intention of minimizing surgical morbidity without compromising oncology outcomes.

Rassweiler et al. performed a meta-analysis comparing ONU and LNU, which included 1365 patients from 85 studies [55]. LNU was associated with a slightly longer operating time (276.6 versus 220.1 minutes); significantly lower blood loss (240.9 versus 462.9 mL); decreased analgesia requirements and shorter hospital stay (not statistically significant in all included studies). There appeared to be no significant difference in complication rates, both minor (12.9 versus 14.1%) and major (5.6 versus 8.3%) between LNU and ONU, respectively. In addition, bladder recurrence, local recurrence, distant metastases, and actual disease-free two-year survival rates (75.2 versus 76.2%) were similar. It is worth noting that caution is suggested in interpreting the data from this meta-analysis as the majority of studies were retrospective, nonrandomized, and limited by short followup periods and variable outcome measures.

Further, recent smaller retrospective comparisons by McNeill et al. ($n = 67$) [56], Tsujihata et al. ($n = 49$) [53], Taweemonkongsap et al. ($n = 60$) [54], Rouprêt et al. ($n = 46$) [57], and Manabe et al. ($n = 224$) [58] have demonstrated parity between ONU and LNU when comparing oncological parameters over a shorter followup period (1–3 years). In a similar study, but with 7-year outcome data, LNU was noted to have a similar local recurrence rate (8 versus

Table 1: Summary of perioperative results and oncological outcomes for the different distal ureteral management techniques from selected larger studies. (ND: no data; LOS: length of stay; f/u: mean followup).

	f/u	*n*	Procedure type	Number of complications of distal ureter technique	Median LOS (days)	Positive margins	Bladder recurrence (%)	Pelvic recurrence (no)	No. of cancer-specific deaths
Pluck technique									
Palou et al., 1995 [13]	20	31	ONU	1	ND	ND	35	0	2
Ubrig et al., 2004 [15]	44	18	ONU	1	11	ND	50	0	5
Geavlete et al., 2007 [16]	44	72	ONU	2	10	ND	24	0	9
Laguna and de la Rosette, 2001 (meta-analysis) [18]	n/a	129	ONU/LNU	3	ND	ND	24	4	ND
Ko et al., 2007 [23]	22	19	ONU/LNU	0	7.3	0	26	1	1
Modification of Pluck technique									
Agarwal et al., 2008 [26]	15	13	LNU	0	7.3	0	38	0	1
Ureteral deroofing									
Shalhav et al., 2000 [29]	24	24	LNU	2	6.1	ND	23	3	ND
Pluck in HALNU									
Wong and Leveillee, 2002 [32]	8	14	HALNU	ND	2	ND	14	ND	ND
Laparoscopic extravesical ureteral stapling									
Jarrett et al., 2001 [39]	24	25	LNU	0	4	1	48	0	2
Laparoscopic transvesical ureteral ligation									
Gill et al., 2000 [41]	11	42	LNU	1	2.3	3	24	0	2
Open distal ureteral excision									
Klingler et al., 2003 [49]	22	19	LNU	0	8.1	0	ND	0	ND
Tsujihata et al., 2006 [53]	ND	49	ONU/LNU	0	4	ND	31	0	2
Taweemonkongsap et al., 2008 [54]	27	60	ONU/LNU	0	9	ND	37	3	8

15.4%), bladder recurrence rate (28 versus 42%), and 5-year metastases free survival rate (87.2 and 82.1%) compared to ONU [59].

Port-site seeding following LNU remains a concern but is fortunately rare if appropriate surgical techniques are adopted and have been mainly confined to individual case reports [60, 61].

Hand-assisted laparoscopic nephroureterectomy referred to as (HALNU) is often seen as a compromise between the open and laparoscopic technique. Arguments in its favor include a shorter learning curve, facilitates tactile feedback and the eventual requirement of a longer incision following LNU for specimen extraction. In a prospective, but nonrandomized study with 27 subjects, patients undergoing an HALNU could expect a quicker discharge from hospital, faster recovery, and fewer complications with an equivalent intermediate-term oncologic outcome compared to the open approach [62]. On the other hand, HALNU took longer and was more expensive. Other studies evaluating ONU and HALNU have confirmed an overall equivalence with regards to cancer control in the short term [30, 63].

Clearly, in the absence of prospective, randomized studies comparing ONU, LNU, and HALNU, it is injudicious to draw robust conclusions regarding the superiority of one technique over the other. Nevertheless, though radical ONU still represents the gold standard for upper tract TCC, laparoscopic nephroureterectomy appears to offer the advantages of minimally invasive surgery without deteriorating the oncological outcome in most cases.

7. Conclusion

TCC of the upper urinary tract, though rare, constitutes a serious urological disease. Even though it is curable in its early stages, there has been little improvement in disease-specific survival in high-risk patients over the last three decades. Radical nephroureterectomy, with en bloc removal of the entire ureteral length and cuff of bladder, remains the procedure of choice, and the technique has undergone numerous modifications in recent years. The integration of laparoscopy into urological practice has seen LNU emerge as a viable option for the management of upper tract TCC.

Given the relative rarity of the disease and a lack of robust multicenter effort, it is unlikely that the issue of LNU versus ONU for upper tract TCC will be resolved in a prospective randomized manner. Nevertheless, a multitude

of small prospective studies with intermediate followup have clearly demonstrated the benefits of minimally invasive surgery (lesser morbidity, quicker recovery, better cosmesis) associated with LNU, along with comparable oncological efficacy in the hands of appropriately trained and experienced laparoscopic urologists. Long-term data from these studies would be beneficial.

The issue of the distal ureteral remains unresolved, and number and complexity of available techniques will undoubtedly continue to evolve. The existing data does not confirm the overwhelming superiority of one technique over the other. Each method has its distinct advantages and disadvantages and it is essential that the responsible surgeon adopts a meticulous, safe, reproducible, and oncologically sound technique.

References

[1] A. Jemal, R. C. Tiwari, T. Murray, et al., "Cancer statistics, 2004," *CA-A: Cancer Journal for Clinicians*, vol. 54, no. 1, pp. 8–29, 2004.

[2] J. J. Munoz and L. M. Ellison, "Upper tract urothelial neoplasms: incidence and survival during the last 2 decades," *The Journal of Urology*, vol. 164, no. 5, pp. 1523–1525, 2000.

[3] A. Mellemgaard, B. Carstensen, N. Norgaard, J. B. Knudsen, and J. H. Olsen, "Trends in the incidence of cancer of the kidney, pelvis, ureter and bladder in Denmark 1943–1988," *Scandinavian Journal of Urology and Nephrology*, vol. 27, no. 3, pp. 327–332, 1993.

[4] G. Haupt, "Transitional-cell carcinoma of the ureter," *Journal of Endourology*, vol. 15, no. 4, p. 409, 2001.

[5] F. N. Kimball and H. W. Ferris, "Papillomatous tumor of the renal pelvis associated with similar tumors of the ureter and bladder: review of literature and report of two cases," *The Journal of Urology*, vol. 31, p. 257, 1934.

[6] M. C. Hall, S. Womack, A. I. Sagalowsky, T. Carmody, M. D. Erickstad, and C. G. Roehrborn, "Prognostic factors, recurrence, and survival in transitional cell carcinoma of the upper urinary tract: a 30-year experience in 252 patients," *Urology*, vol. 52, no. 4, pp. 594–601, 1998.

[7] C. D. Auld, K. M. Grigor, and J. W. Fowler, "Histopathological review of transitional cell carcinoma of the upper urinary tract," *British Journal of Urology*, vol. 56, no. 5, pp. 485–489, 1984.

[8] B. J. Tan, M. C. Ost, and B. R. Lee, "Laparoscopic nephroureterectomy with bladder-cuff resection: techniques and outcomes," *Journal of Endourology*, vol. 19, no. 6, pp. 664–676, 2005.

[9] H. P. McDonald, W. E. Upchurch, and C. E. Surdevant, "Nephroureterectomy: a new technique," *The Journal of Urology*, vol. 67, p. 804, 1952.

[10] D. W. Strong and H. D. Pearse, "Recurrent urothelial tumors following surgery for transitional cell carcinoma of the upper urinary tract," *Cancer*, vol. 38, no. 5, pp. 2178–2183, 1976.

[11] T. Kakizoe, J. Fujita, T. Murase, K. Matsumoto, and K. Kishi, "Transitional cell carcinoma of the bladder in patients with renal pelvic and ureteral cancer," *The Journal of Urology*, vol. 124, no. 1, pp. 17–19, 1980.

[12] D. M. Murphy, H. Zincke, and W. L. Furlow, "Management of high grade transitional cell cancer of the upper urinary tract," *The Journal of Urology*, vol. 125, no. 1, pp. 25–29, 1981.

[13] J. Palou, J. Caparrós, A. Orsola, B. Xavier, and J. Vicente, "Transurethral resection of the intramural ureter as the first step of nephroureterectomy," *The Journal of Urology*, vol. 154, no. 1, pp. 43–44, 1995.

[14] H. A. El Fettouh, J. J. Rassweiler, M. Schulze, et al., "Laparoscopic radical nephroureterectomy: results of an international multicenter study," *European Urology*, vol. 42, no. 5, pp. 447–452, 2002.

[15] B. Ubrig, M. Boenig, M. Waldner, and S. Roth, "Transurethral approach to the distal ureter in nephroureterectomy: transurethral extraction vs. "pluck" technique with long-term follow-up," *European Urology*, vol. 46, no. 6, pp. 741–747, 2004.

[16] P. Geavlete, D. Georgescu, Ş. Bancu, and V. Mirciulescu, "Endoscopic ureteral procedures for one-step nephroureterectomy: experience in 100 cases," *Journal of Endourology*, vol. 21, no. 9, pp. 1019–1024, 2007.

[17] S. Micali, A. Celia, P. Bove, et al., "Tumor seeding in urological laparoscopy: an international survey," *The Journal of Urology*, vol. 171, no. 6, part 1, pp. 2151–2154, 2004.

[18] M. P. Laguna and J. J. M. C. H. de la Rosette, "The endoscopic approach to the distal ureter in nephroureterectomy for upper urinary tract tumor," *The Journal of Urology*, vol. 166, no. 6, pp. 2017–2022, 2001.

[19] J. W. Hetherington, R. Ewing, and N. H. Philip, "Modified nephroureterectomy: a risk of tumor implantation," *British Journal of Urology*, vol. 58, no. 4, pp. 368–370, 1986.

[20] D. R. Jones and C. U. Moisey, "A cautionary tale of the modified 'pluck' nephroureterectomy," *British Journal of Urology*, vol. 71, no. 4, p. 486, 1993.

[21] O. Arango, O. Bielsa, J. Carles, and A. Gelabert-Mas, "Massive tumor implantation in the endoscopic resected area in modified nephroureterectomy," *The Journal of Urology*, vol. 157, no. 5, p. 1839, 1997.

[22] D. Pascual Regueiro, A. García de Jalón Martínez, C. Sanch Serrano, E. Mallén Mateo, M. Blas Marín, and L. A. Rioja Sanz, "Tumor recurrence in the resected area of the ureteral meatus after endoscopic disinsertion during radical nephroureterectomy," *Actas Urologicas Españolas*, vol. 27, no. 4, pp. 308–311, 2003 (Spanish).

[23] R. Ko, B. H. Chew, D. R. Hickling, et al., "Transitional-cell carcinoma recurrence rate after nephroureterectomy in patients who undergo open excision of bladder cuff ν transurethral incision of the ureteral orifice," *Journal of Endourology*, vol. 21, no. 7, pp. 730–734, 2007.

[24] J. H. Kaouk, S. J. Savage, and I. S. Gill, "Retroperitoneal laparoscopic nephroureterectomy and management options for the distal ureter," *Journal of Endourology*, vol. 15, no. 4, pp. 385–390, 2001.

[25] J. A. Brown, S. E. Strup, E. Chenven, D. Bagley, and L. G. Gomella, "Hand-assisted laparoscopic nephroureterectomy: analysis of distal ureterectomy technique, margin status, and surgical outcomes," *Urology*, vol. 66, no. 6, pp. 1192–1196, 2005.

[26] D. K. Agarwal, H. S. Khaira, D. Clarke, and R. Tong, "Modified transurethral technique for the management of distal ureter during laparoscopic assisted nephroureterectomy," *Urology*, vol. 71, no. 4, pp. 740–743, 2008.

[27] S. Pathak, V. Lavin, T. Watcyn-Jones, D. Doyle, and N. Oakley, "Laparoscopic nephroureterectomy for upper tract urothelial cancer: a novel closed system pluck," *European Urology Supplements*, vol. 7, no. 3, p. 330, 2008.

[28] A. L. Shalhav, A. M. Elbahnasy, E. M. McDougall, and R. V. Clayman, "Laparoscopic nephroureterectomy for upper tract transitional-cell cancer: technical aspects," *Journal of Endourology*, vol. 12, no. 4, pp. 345–353, 1998.

[29] A. L. Shalhav, M. D. Dunn, A. J. Portis, A. M. Elbahnasy, E. M. McDougall, and R. V. Clayman, "Laparoscopic nephroureterectomy for upper tract transitional cell cancer: the Washington University experience," *The Journal of Urology*, vol. 163, no. 4, pp. 1100–1104, 2000.

[30] J. D. Raman, M. A. Palese, C. K. Ng, et al., "Hand-assisted laparoscopic nephroureterectomy for upper urinary tract transitional cell carcinoma," *JSLS: Journal of the Society of Laparoendoscopic Surgeons*, vol. 10, no. 4, pp. 432–438, 2006.

[31] C. M. Gonzalez, R. A. Batler, R. A. Schoor, J. C. Hairston, and R. B. Nadler, "A novel endoscopic approach towards resection of the distal ureter with surrounding bladder cuff during hand assisted laparoscopic nephroureterectomy," *The Journal of Urology*, vol. 165, no. 2, pp. 483–485, 2001.

[32] C. Wong and R. J. Leveillee, "Hand-assisted laparoscopic nephroureterectomy with cystoscopic en bloc excision of the distal ureter and bladder cuff," *Journal of Endourology*, vol. 16, no. 6, pp. 329–332, 2002.

[33] E. Kurzer, R. J. Leveillee, and V. G. Bird, "Combining hand assisted laparoscopic nephroureterectomy with cystoscopic circumferential excision of the distal ureter without primary closure of the bladder cuff—is it safe?" *The Journal of Urology*, vol. 175, no. 1, pp. 63–67, 2006.

[34] I. Y. Vardi, J. A. Stern, C. M. Gonzalez, S. Y. Kimm, and R. B. Nadler, "Novel technique for management of distal ureter and en block resection of bladder cuff during hand-assisted laparoscopic nephroureterectomy," *Urology*, vol. 67, no. 1, pp. 89–92, 2006.

[35] D. F. McDonald, "Intussusception ureterectomy: a method of removal of the ureteral stump at time of nephrectomy without an additional incision," *Surgery, Gynecology & Obstetrics*, vol. 97, no. 5, pp. 565–568, 1953.

[36] R. V. Clayman, G. L. Garske, and P. H. Lange, "Total nephroureterectomy with ureteral intussusception and transurethral ureteral detachment and pull-through," *Urology*, vol. 21, no. 5, pp. 482–486, 1983.

[37] J. C. Angulo, J. Hontoria, and M. Sanchez-Chapado, "One-incision nephroureterectomy endoscopically assisted by transurethral ureteral stripping," *Urology*, vol. 52, no. 2, pp. 203–207, 1998.

[38] S. Roth, H. van Ahlen, A. Semjonow, and L. Hertle, "Modified ureteral stripping as an alternative to open surgical ureterectomy," *The Journal of Urology*, vol. 155, no. 5, pp. 1568–1571, 1996.

[39] T. W. Jarrett, D. Y. Chan, J. A. Cadeddu, and L. R. Kavoussi, "Laparoscopic nephroureterectomy for the treatment of transitional cell carcinoma of the upper urinary tract," *Urology*, vol. 57, no. 3, pp. 448–453, 2001.

[40] I. S. Gill, J. J. Soble, S. D. Miller, and G. T. Sung, "A novel technique for management of the en bloc bladder cuff and distal ureter during laparoscopic nephroureterectomy," *The Journal of Urology*, vol. 161, no. 2, pp. 430–434, 1999.

[41] I. S. Gill, G. T. Sung, M. G. Hobart, et al., "Laparoscopic radical nephroureterectomy for upper tract transitional cell carcinoma: the Cleveland Clinic experience," *The Journal of Urology*, vol. 164, no. 5, pp. 1513–1522, 2000.

[42] R. Hattori, Y. Yoshino, M. Gotoh, M. Katoh, O. Kamihira, and Y. Ono, "Laparoscopic nephroureterectomy for transitional cell carcinoma of renal pelvis and ureter: Nagoya experience," *Urology*, vol. 67, no. 4, pp. 701–705, 2006.

[43] R. Venkatesh, J. Rehman, J. Landman, et al., "Determination of cell viability after laparoscopic tissue stapling in a porcine model," *Journal of Endourology*, vol. 19, no. 6, pp. 744–747, 2005.

[44] F. R. Romero, E. M. Schaeffer, M. Muntener, B. Trock, L. R. Kavoussi, and T. W. Jarrett, "Oncologic outcomes of extravesical stapling of distal ureter in laparoscopic nephroureterectomy," *Journal of Endourology*, vol. 21, no. 9, pp. 1025–1027, 2007.

[45] S. F. Matin and I. S. Gill, "Recurrence and survival following laparoscopic radical nephroureterectomy with various forms of bladder cuff control," *The Journal of Urology*, vol. 173, no. 2, pp. 395–400, 2005.

[46] A. Tsivian, S. Benjamin, and A. A. Sidi, "A sealed laparoscopic nephroureterectomy: a new technique," *European Urology*, vol. 52, no. 4, pp. 1015–1019, 2007.

[47] J. R. Steinberg and S. F. Matin, "Laparoscopic radical nephroureterectomy: dilemma of the distal ureter," *Current Opinion in Urology*, vol. 14, no. 2, pp. 61–65, 2004.

[48] C. W. Cheng, C. F. Ng, S. K. Mak, et al., "Pneumovesicum method in *en-Bloc* laparoscopic nephroureterectomy with bladder cuff resection for upper-tract urothelial cancer," *Journal of Endourology*, vol. 21, no. 4, pp. 359–363, 2007.

[49] H. C. Klingler, M. Lodde, A. Pycha, M. Remzi, G. Janetschek, and M. Marberger, "Modified laparoscopic nephroureterectomy for treatment of upper urinary tract transitional cell cancer is not associated with an increased risk of tumour recurrence," *European Urology*, vol. 44, no. 4, pp. 442–447, 2003.

[50] P. Schatteman, C. Chatzopoulos, C. Assenmacher, et al., "Laparoscopic nephroureterectomy for upper urinary tract transitional cell carcinoma: results of a Belgian retrospective nulticentre survey," *European Urology*, vol. 51, no. 6, pp. 1633–1638, 2007.

[51] D. W. Strong, H. D. Pearse, E. S. Tank Jr., and C. V. Hodges, "The ureteral stump after nephroureterectomy," *The Journal of Urology*, vol. 115, no. 6, pp. 654–655, 1976.

[52] R. Zigeuner and K. Pummer, "Urothelial carcinoma of the upper urinary tract: surgical approach and prognostic factors," *European Urology*, vol. 53, no. 4, pp. 720–731, 2008.

[53] M. Tsujihata, N. Nonomura, A. Tsujimura, K. Yoshimura, Y. Miyagawa, and A. Okuyama, "Laparoscopic nephroureterectomy for upper tract transitional cell carcinoma: comparison of laparoscopic and open surgery," *European Urology*, vol. 49, no. 2, pp. 332–336, 2006.

[54] T. Taweemonkongsap, C. Nualyong, T. Amornvesukit, et al., "Outcomes of surgical treatment for upper urinary tract transitional cell carcinoma: comparison of retroperitoneoscopic and open nephroureterectomy," *World Journal of Surgical Oncology*, vol. 6, article 3, pp. 3–10, 2008.

[55] J. J. Rassweiler, M. Schulze, R. Marrero, T. Frede, J. Palou Redorta, and P. Bassi, "Laparoscopic nephroureterectomy for upper urinary tract transitional cell carcinoma: is it better than open surgery?" *European Urology*, vol. 46, no. 6, pp. 690–697, 2004.

[56] S. A. McNeill, M. Chrisofos, and D. A. Tolley, "The long-term outcome after laparoscopic nephroureterectomy: a comparison with open nephroureterectomy," *BJU International*, vol. 86, no. 6, pp. 619–623, 2000.

[57] M. Rouprêt, V. Hupertan, K. M. Sanderson, et al., "Oncologic control after open or laparoscopic nephroureterectomy for

upper urinary tract transitional cell carcinoma: a single center experience," *Urology*, vol. 69, no. 4, pp. 656–661, 2007.

[58] D. Manabe, T. Saika, S. Ebara, et al., "Comparative study of oncologic outcome of laparoscopic nephroureterectomy and standard nephroureterectomy for upper urinary tract transitional cell carcinoma ," *Urology*, vol. 69, no. 3, pp. 457–461, 2007.

[59] S. V. Bariol, G. D. Stewart, S. A. McNeill, and D. A. Tolley, "Oncological control following laparoscopic nephroureterectomy: 7-year outcome," *The Journal of Urology*, vol. 172, no. 5, part 1, pp. 1805–1808, 2004.

[60] A. M. Ong, S. B. Bhayani, and C. P. Pavlovich, "Trocar site recurrence after laparoscopic nephroureterectomy," *The Journal of Urology*, vol. 170, no. 4, part 1, p. 1301, 2003.

[61] Y. Matsui, H. Ohara, K. Ichioka, N. Terada, K. Yoshimura, and A. Terai, "Abdominal wall metastasis after retroperitoneoscopic assisted total nephroureterectomy for renal pelvic cancer," *The Journal of Urology*, vol. 171, no. 2, part 1, p. 793, 2004.

[62] B. D. Seifman, J. E. Montie, and J. S. Wolf Jr., "Prospective comparison between hand-assisted laparoscopic and open surgical nephroureterectomy for urothelial cell carcinoma," *Urology*, vol. 57, no. 1, pp. 133–137, 2001.

[63] S.-D. Chung, C.-Y. Huang, S.-C. Chueh, et al., "Intermediate follow-up of hand-assisted retroperitoneoscopic nephroureterectomy for management of upper urinary tract urothelial carcinoma: comparison with open nephroureterectomy," *Urology*, vol. 69, no. 6, pp. 1030–1034, 2007.

Hindawi Publishing Corporation
Advances in Urology
Volume 2009, Article ID 721371, 8 pages
doi:10.1155/2009/721371

Review Article

Laparoscopic Nephroureterectomy and Management of the Distal Ureter: A Review of Current Techniques and Outcomes

Davis P. Viprakasit, Amanda M. Macejko, and Robert B. Nadler

Department of Urology, Feinberg School of Medicine, Northwestern University, Chicago, IL 60208, USA

Correspondence should be addressed to Robert B. Nadler, r-nadler@northwestern.edu

Received 27 May 2008; Accepted 3 November 2008

Recommended by Norm D. Smith

Laparoscopic nephroureterectomy (LNU) is becoming an increasingly common alternative treatment for transitional cell carcinoma (TCC) of the renal pelvis and ureter due to decreased perioperative morbidity, shorter hospitalization, and comparable oncologic control with open nephroureterectomy (ONU). Mobilization of the kidney and proximal ureter may be performed through a transperitoneal, retroperitoneal, or hand-assisted approach. Each technique is associated with its own benefits and limitations, and the optimal approach is often dictated by surgeon preference. Our analysis of the literature reflects equivalent cancer control between LPN and OPN at intermediate follow-up with significantly improved perioperative morbidity following LPN. Several methods for bladder cuff excision have been advocated, however, no individual technique for management of the distal ureter proved superior. Overall, complete en-bloc resection with minimal disruption of the urinary tract should be optimized to maintain oncologic outcomes. Longer follow-up and prospective studies are needed to fully evaluate these techniques.

1. Introduction

Transitional cell carcinoma (TCC) of the renal pelvis and ureter is a disease associated with high propensity for tumor recurrence and progression. Open radical nephroureterectomy (ONU) with bladder cuff excision is the traditional standard treatment for most localized diseases of the upper urinary tract because of its aggressive nature, as well as the difficulty encountered with surveillance of the upper tract urothelium [1]. To obtain adequate exposure, open excision of the distal ureter and bladder cuff requires either two skin incisions or an extended flank incision. This is associated with increased perioperative morbidity and recovery time. First described by Clayman et al. in 1991 [2], laparoscopic radical nephroureterectomy (LNU) has shown significant advantages in terms of blood loss, postoperative pain and recovery time, as well as comparable short and intermediate-term oncologic outcomes with the open treatment [3]. As more urologists are gaining increased comfort with minimally invasive techniques, LNU exhibits a large growth in worldwide popularity [4]. However, the optimal laparoscopic approach for nephroureterectomy as well as the technique for addressing the bladder cuff is unclear. We present a review of the most recent literature detailing the perioperative and cancer control outcomes observed with the various methods of LNU and discuss the reported variations on bladder cuff excision.

2. Laparoscopic Nephroureterectomy

2.1. Approach. A variety of techniques have been utilized to perform mobilization of the kidney and proximal ureter. These include conventional transperitoneal, conventional retroperitoneal, hand-assisted transperitoneal, and hand-assisted retroperitoneal approaches. The choice of laparoscopic approach is most dependent on the comfort level and training of the surgeon. However, each technique has its own potential advantages. Transperitoneal exposure offers the largest working area and may be beneficial for extensive tumors or lymphadenopathy. The retroperitoneal approach, however, involves decreased bowel manipulation and potentially allows for earlier recovery of bowel function. Additionally, this method may be favored in morbidly obese patients with an obstructing pannus or in patients with

a history of previous transperitoneal surgeries [5]. Hand-assistance techniques allow for continued tactile sensation and may lessen the learning curve required in laparoscopy [6]. Most of the experiences with LNU are primarily reported as single-institutional retrospective series. To date, there have been no prospective randomized studies that compare the different techniques for LNU. However, data published in the laparoscopic radical nephrectomy literature may be applicable. For example, a randomized, prospective study comparing conventional transperitoneal, retroperitoneal, and hand-assisted transperitoneal laparoscopic radical nephrectomy was recently published [7]. The hand-assisted technique resulted in a significantly shorter operative time but an increased risk of hernia formation; conversely, conventional transperitoneal surgery was associated with significantly improved perioperative morbidity. Desai et al. reported shorter operative times and faster control of the renal vasculature with retroperitoneal approaches in a prospective randomized comparison of conventional transperitoneal and retroperitoneal laparoscopic radical nephrectomy but no significant differences in other perioperative measures [5].

2.2. Perioperative Outcomes. Rassweiler et al. performed a literature review of published studies between 1991 and 2004 of LNU and ONU, including nine comparative studies and 1365 overall patients [3]. As compared to ONU, LNU was associated with a slightly longer operative time (277 versus 220 minutes), significantly lower blood loss (241 versus 463 mL), and shorter hospital stays, but showed similar complication rates (18% versus 21%).

Table 1 summarizes the perioperative outcomes of 12 LNU studies published since 2005. The mean operating time ranged from 165 to 395 minutes (mean 271) in the laparoscopic group ($n = 465$ patients), and 155 to 313 minutes (mean 237) in the open group ($n = 268$ patients). Significantly increased operative time with laparoscopy was noted in three of eight comparative studies, all of which involved the retroperitoneal approach. The blood loss averaged between 183 to 497 mL (mean 279) in the laparoscopic group as compared to a range of 296 to 558 mL (mean 402) in the open group. Significantly less blood loss after laparoscopy was noted in four of eight comparative studies with a similar trend in three of the remaining studies. The overall complication rate ranged from 0 to 37% (mean 18%) in the laparoscopy group and from 0 to 15% (mean 7%) in the open group. The open conversion rate associated with laparoscopy ranged from 0 to 10%. The absolute duration of hospital stays varied between institutions. Out of eight comparative studies, hospitalization following laparoscopy was shorter in seven series with a significant difference in five.

2.3. Oncologic Outcomes. The highly aggressive natural history of upper tract TCC, particularly with high-grade and high-stage disease, likely contributes to its increased potential for recurrence and poor prognosis irrespective of the surgical technique. However, there are many concerns that technical aspects of LNU, particularly with regard to management of the distal ureter and bladder cuff, may affect recurrence risks in the bladder, locally, or as port-site metastases secondary to tumor seeding. Rassweiler et al. noted no significant difference in bladder recurrence (24% versus 25%), local recurrence (4% versus 6%) and distant metastases (15.5% versus 15.2%) in eight LNU series and 11 ONU series [3]. The 2-year cancer specific survival rates were also similar (75% versus 76%).

Table 2 summarizes the short and intermediate oncologic outcomes of 14 LNU studies published since 2005. The most common method for bladder cuff excision was an open approach. At a minimum median follow-up of at least 2 years, bladder recurrence after LNU ($n = 488$ patients) ranged from 10 to 55% (mean 30%) as compared to 15 to 55% (mean 33%) in the ONU series ($n = 512$ patients). Local recurrence in the retroperitoneum was documented as 0 to 13% (mean 3.3%) in the laparoscopic ($n = 588$ patients) and 0 to 8% (mean 2.5%) in the open series ($n = 512$ patients). Distant metastases occurred in 0 to 18% (mean 9.5%) of patients undergoing LNU ($n = 588$ patients) as compared to 5 to 35% (mean 14.5%) in the open series ($n = 512$ patients). In six series reporting 2-year disease-specific survival, the rates ranged from 64 to 91% (mean 83%) in the laparoscopic series ($n = 274$ patients) and between 58 to 93% (mean 83.6%) after ONU ($n = 242$ patients). In the five series reporting 5-year survival rates, the outcomes ranged from 68 to 90% (mean 85%) after LNU ($n = 202$ patients) and 62 to 86% (mean 75%) in the ONU groups ($n = 191$ patients). There was no significant difference between LNU and ONU survival rates in the 10 comparative studies. However, absolute comparisons between the surgical approaches are difficult as the percentage of patients with high-grade disease and the follow-up period varied considerably, reflecting a large limitation with the retrospective nature of these studies. In addition, the inclusion of patients with a prior or concomitant history of bladder cancer may affect the oncologic outcome of treating upper tract TCC. In the 14 LNU studies, only 7 addressed this parameter in defining their patient characteristics. The 4 comparative studies including such patients and the 1 study which excluded patients with bladder TCC did not show a significant difference between ONU and LNU groups. However, it is unclear if the underlying biology and tumor aggressiveness in patients with both upper and lower tract TCC differ from patients with isolated upper tract TCC; inclusion of such patients in studies with already relatively low numbers further complicates comparisons of treatment approach.

2.4. Port-Site Metastases. One unique concern reported following laparoscopic surgery is the occurrence of recurrent malignant disease at the port-site [22]. To the best of our knowledge, there have been 18 cases published in the literature of port-site metastases of upper tract TCC after laparoscopy (Table 3). In seven cases, the diagnosis of TCC was not suspected preoperatively which influenced the surgical technique. Metastases occurred 3 to 15 months post-operatively (mean 6.8). These overall experiences emphasize that general preventive measures should be undertaken at

Table 1: Perioperative characteristics of LPN versus ONU cases. CR, conventional retroperitoneal; CT, conventional transperitoneal; HAT, hand-assisted transperitoneal; NL, not listed; ONU, open nephroureterectomy.

Author	Surgery	Number	High grade (%)	OR duration (min)	Blood loss (min)	Conversion (%)	Complication (%)	Hospital days
Muntener et al. [8]	CT	39	31 (80)	312	300	4 (10)	12 (31)	4
Schatteman et al. [9]	CT	100	48 (48)	192	234	7 (7)	19 (19)	10
Rouprêt et al. [10]	CT	20	8 (40)	165	275	1 (5)	3 (15)	4
	ONU	26	19 (73)	155	338	—	4 (15)	9
Okegawa et al. [11]	CR	25	6 (24)	299	258	1 (4)	4 (16)	11
	ONU	23	7 (30)	313	403	—	3 (13)	13
Tsujihata et al. [12]	CR	25	5 (20)	306	322	0 (0)	0 (0)	2
	ONU	24	12 (50)	271	558	—	0 (0)	4
Taweemonkongsap et al. [13]	CR	31	13 (42)	259	289	0 (0)	2 (6)	9.3
	ONU	29	19 (66)	191	314	—	2 (7)	8.7
Chung et al. [14]	HAT	39	16 (41)	233	183	0 (0)	5 (13)	7
	ONU	36	15 (42)	220	422	—	3 (8)	9
Raman et al. [15]	HAT	38	15 (40)	244	191	0 (0)	4 (11)	5
	ONU	52	19 (37)	243	478	—	2 (4)	7
Wolf et al. [16]	HAT	53	26 (49)	279	330	1 (2)	20 (37)	4
Cannon et al. [17]	HAT	34	NL	317	252	0 (0)	9 (26)	8
Chung et al. [18]	HAR	25	11 (44)	252	212	0 (0)	3 (12)	6.5
	ONU	41	17 (41)	212	408	—	3 (7)	9
Nakashima et al. [19]	HAR	36	18 (50)	395	497	1 (3)	11 (31)	18.8
	ONU	37	13 (35)	289	296	—	2 (5)	19.1

the conclusion of the surgery including the use of an impermeable organ bag, minimal tissue handling, and the avoidance of gross violation of the urinary system until the specimen has been removed en bloc.

3. Bladder Cuff Excision

There is no consensus as to the optimal technique to excise the distal ureter and ipsilateral bladder cuff [1]. Definitive steps to minimize tumor seeding and complete excision of the ureter are mandatory given the 30% to 64% tumor recurrence rate reported following inadequate distal resections [31, 32]. As noted in Table 2, one of the most utilized approaches involves an open approach. This may be accomplished transvesically or extravesically via a lower midline, Pfannenstiel, or Gibson incision, or by incorporation of the hand port incision following hand-assisted LNU. This technique is similarly employed during ONU and offers the surgeon familiarity, direct visualization, and a simultaneous site for en bloc specimen extraction. Awareness of the contralateral trigone and ureteral orifice location should be undertaken as potential injury may occur during ipsilateral dissection or bladder cuff closure [33].

Alternatively, numerous endoscopic approaches have been promoted. In 1952, McDonald et al. described the first endoscopic method of bladder cuff excision, the "pluck" technique, via transurethral resection of the ureteral orifice (TURUO) at the onset of surgery [34]. Resection of the orifice and intramural ureter, however, may require patient repositioning and when performed at the onset of the procedure can expose the extravesical space to potential tumor seeding. Several modifications have been described to this technique in contemporary series, including delaying resection until after kidney mobilization, performing transvesical endoscopy [35] or using transurethral cystoscopy with a Bugbee electrode [36] or Collins knife for excision [37]. Ko et al. reviewed their experience comparing open dissection ($n = 27$ patients) with modified TURUO using a Collins knife ($n = 19$ patients) following nephroureterectomy [38]. At a mean follow-up of over 22 months, they noted similar bladder recurrence rates (22.2% versus 26.3%) without evidence of pelvic recurrence.

The technique of ureteral intussusception has also been described and involves endoscopic extraction of the ligated ureter using a "stripping" method with the assistance of a ureteral catheter [39]. However, this approach is contraindicated with concomitant bladder or ureteral tumors and was noted to have an incomplete excision rate of 18.7% in a large single institutional series of 32 patients [40].

Gill et al. described the method of cystoscopic detachment and ligation which incorporates intramural ureteral dissection with a Collins knife aided by two transvesical laparoscopic ports and an endoloop to ligate the ureteral lumen and minimize potential tumor spillage [41]. While this method most closely echoes the intentions of ONU, it

Table 2: Oncologic outcomes of LPN versus ONU cases. CR, conventional retroperitoneal; CT, conventional transperitoneal; HAR, hand-assisted retroperitoneal; HAT, hand-assisted transperitoneal; LND, lymph node dissection; LS, laparoscopic stapling; NL, not listed; ONU, open nephroureterectomy; SD, surgeon discretion; TURUO, transurethral resection; TV, transvesical.

Author	Surgery	N	Follow up (mo)	History of bladder tumor specified	Bladder cuff surgery	Path stage (Ta,Tis,T1/T2, T3,T4)	Path grade (1/2/3)	LND	Urothelial recurrence (%)	Local recurrence (%)	Port-site recurrence (%)	Distal recurrence (%)	Disease-specific survival (@ year)
Muntener et al. [8]	CT	39	74	Yes	Open (19), LS (13), other (5)	22/15/2NL	8LG/ 31HG	No	16 (41)	2 (5)	0 (0)	7 (18)	68 (5)
Schatteman et al. [9]	CT/CR	95/5	20	No	Open (55), Other (45)	54/46	24/28/48	20% of cases	NL	13 (13)	3 (3)	16 (16)	88 (2)
Rouprêt et al. [10]	CT	20	69	No	Open	15/511/15	12LG/8HG	SD	2 (10)	0 (0)	0 (0)	2 (10)	90 (5)
	ONU	26	78				7LG/19HG		4 (15)	0 (0)		9 (35)	62 (5)
Okegawa et al. [11]	CR	25	24	Yes	Open	14/119/14	2/17/6	No	5 (20)	0 (0)	0 (0)	2 (8)	91 (2)
	ONU	23	29				1/15/7		4 (17)	0 (0)		3 (13)	89 (2)
Tsujihata et al. [12]	CR	25	22	No	Open	12/1315/6	5/15/5	No	7 (28)	0 (0)	0 (0)	0 (0)	64 (2)
	ONU	24	22				0/11/12		8 (33)	0 (0)		2 (8)	58 (2)
Manabe et al. [20]	CR	58	14	Excluded	Open	28/3070/96	4/31/23	No	19 (33)	1 (2)	1 (2)	10 (17)	85 (2)
	ONU	166	28				15/87/64		63 (38)	2 (1)		33 (20)	87 (2)
Taweemonkongsap et al. [13]	CR	31	26	Yes	Open	16/15	18LG/13HG	SD	9 (29)	2 (6)	0 (0)	3 (10)	86 (2)
	ONU	29	28			13/16	10LG/19HG		13 (45)	1 (3)		2 (7)	93 (2)
Chung et al. [14]	HAT	39	48	No	Open	18/21	1/22/16	SD	17 (44)	1 (3)	0 (0)	6 (15)	90 (5)
	ONU	36	60			17/19	1/20/15		13 (36)	3 (8)		4 (11)	86 (5)
Raman et al. [15]	HAT	38	32	Yes	Open (30),	27/9	23LG/15HG	No	11 (29)	1 (3)	0 (0)	2 (6)	81 (5)
	ONU	52	51		TURUO (8)	41/11	33LG/19HG		18 (35)	0 (0)		6 (11)	77 (5)
Wolf et al. [16]	HAT	53	25	Yes	TURUO (23), TV (22), Open (6), LS (2)	38/15	18/9/26	SD	(55)	(8)	0 (0)	(16)	80 (3)
Cannon et al. [17]	HAT	34	14	No	Open	17/18	NL	No	8 (24)	0 (0)	0 (0)	2 (6)	NL
Hsueh et al. [21]	HAR	66	38	No	Open	35/31	1/25/38	No	13 (20)	2 (3)	0 (0)	6 (9)	80 (5)
	ONU	77	54			43/33	3/39/34		19 (25)	2 (3)		12 (16)	75 (5)
Chung et al. [18]	HAR	25	32	No	Open	13/12	1/13/11	No	9 (36)	3 (12)	0 (0)	2 (8)	92 (3)
	ONU	41	62			18/23	1/23/17		13 (32)	3 (7)		5 (12)	92 (3)
Nakashima et al. [19]	HAR	35	23	Yes	Open	22 ≤ T2,13T3	17 ≤ G2,18G3	No	12 (34)	1 (3)	0 (0)	3 (9)	89 (2)
	ONU	38	56			26 ≤ T2,11T3	24 ≤ G2,13G3		21 (55)	1 (3)		2 (5)	91 (2)

Table 3: Port-site metastasis following LNU. CR, conventional retroperitoneal; CT, conventional transperitoneal; HAT, hand-assisted transperitoneal; LNU, laparoscopic nephroureterectomy; NL, not listed; TCC, transitional cell carcinoma; TURBT, transurethral resection of bladder tumor.

Author	Surgery	Stage	Retrieval bag	Metastases location	Time to metastasis (mo)	Comments
Ahmed et al. [23]	CT	pT3	No	Widespread	8	
Barrett et al. [24]	CT	pT1	No	Widespread	NL	
Otani et al. [25]	CT	pT3	Yes	Trocar	3	Bag torn; preoperative diagnosis of TCC not known
Ong et al. [26]	CR	pT1	Yes	Trocar	12	Stent perforation in proximal ureter noted at time of LNU
Chueh et al. [27]	HAT	pT2	NL	Trocar	8	Bilateral LNU and TURBT performed in renal transplant patient
Micali et al. [28]	CT	pT3	Yes	NL	3	
Micali et al. [28]	CR	pT3	Yes	NL	15	
Micali et al. [28]	HAT	pT3	Yes	NL	3	
Micali et al. [28]	CR	pT1	No	Trocar	3	Preoperative diagnosis of TCC not known
Micali et al. [28]	CR	pT1	Yes	Trocar	NL	Preoperative diagnosis of TCC not known
Micali et al. [28]	CR	pT2	Yes	Trocar	NL	Preoperative diagnosis of TCC not known
Micali et al. [28]	CR	NL	Yes	Trocar	NL	Preoperative diagnosis of TCC not known
Matsui et al. [29]	CR	pT3	No	Trocar	6	Squamous cell carcinoma
Naderi et al. [30]	CT	pT2	No	Trocar, subcostal wound	3	Required conversion to open surgery secondary to renal vein bleeding
Manabe et al. [20]	CR	NL	NL	Widespread	NL	Urine extravasation secondary to urinary tract obstruction noted preop
Schatteman et al. [9]	CT	pT4	No	Widespread	5	Preoperative diagnosis of TCC not known
Schatteman et al. [9]	CT	pT3	No	Widespread	8	Preoperative diagnosis of TCC not known
Schatteman et al. [9]	CT	pT1	Yes	Widespread	11	

is associated with a steep learning curve and long procedural time [42].

Laparoscopic stapling of the distal ureter and bladder cuff with either cystoscopic unroofing or a pure extravesical approach has also been utilized [43]. This technique, however, has been associated with the potential risk of stone formation [44] or viable tumor cells within the incorporated staple line [45]. A comparison of laparoscopic stapling (20% of cohort) with cystoscopic detachment and ligation (60% of cohort) by Matin and Gill was notable for a positive surgical margin rate of 25% versus 2.8% [46]. Hattori et al. reported their experience between laparoscopic stapling and open bladder cuff excision [44]. They noted a significantly decreased operative time with laparoscopic stapling with no significant difference in bladder and extravesical recurrence-free rates and disease-specific survival at 3-year follow-up. Tsivian et al. detailed a modified technique for excising the periurethral bladder cuff en bloc using a LigaSure Atlas device instead of a stapler [47]. Similarly, excision via harmonic scalpel has also been utilized [48]. Division of the bladder cuff using hemostatic diathermy devices may address the potential concerns of viable tumor cells and stone formation associated with laparoscopic stapling although further study is needed.

While there have been no randomized prospective trials comparing the management of the distal ureter, several groups have reported their retrospective results with several different approaches. In a large multicenter American and European study, Abou El Fettouh et al. noted that the local recurrence rates and the development of metastases depended on pathologic tumor stage and was irrespective of bladder cuff approach (open, TURUO, cystoscopic detachment and ligation, laparoscopic stapling) [49]. In a series of 55 patients undergoing hand-assisted transperitoneal LNU, Brown et al. noted increased perioperative morbidity and complications with TURUO. However, higher positive surgical margins were observed following laparoscopic stapling (29%) or extravesical harmonic scalpel excision

(10%) as compared to TURUO or open techniques [50]. Additionally, in patients without active or recent lower tract TCC, concerns exist regarding the increased potential risk of local recurrence when the cystotomy is not primarily closed following excision of the ureteral orifice and bladder neck as with many of the endoscopic approaches. Brown et al. noted their sole pelvic recurrence occurred in 1 of 7 patients without cystotomy closure, leading the authors to also advocate routine bladder defect closure [50]. However, Kurzer et al. reported no local recurrences in 49 patients treated with a modified TURUO technique and no cystotomy closure at a median follow-up of 10 months [51].

4. Role of Lymphadenectomy

Given its aggressive nature, the presence of nodal involvement in TCC of the renal pelvis and ureter is a poor prognostic factor and has shown limited response to adjuvant therapies [52]. However, the role and utilization of routine lymph node dissection (LND) in conjunction with either LNU or ONU is not well established. This contrasts lower urinary tract TCC in which extended pelvic LND is well supported in the literature for improved staging and survival benefits [53]. One reason for the variable use of LND (Table 2) is that the standard template for regional lymph node involvement in upper tract TCC has not been well delineated. In a recent review of 42 of 181 patients with upper tract TCC metastases, Kondo et al. noted that the location of lymph node metastases depended on the laterality and level of the primary tumor [54]. Based on their findings, the authors advocated a relatively wide LND template, particularly on the right side to include the paracaval, retrocaval, and interaortocaval nodes. In a follow-up study, the authors noted an improved cancer-specific survival in patients with advanced disease (stage pT3 or higher) undergoing LND although no difference was noted when all pathologic stages were considered [55]. Brausi et al. similarly reported an improved disease-specific survival benefit in patients treated with ONU and LND (81.6%) as compared to ONU alone (44.8%) [56]. However, the retrospective study may have been influenced by a potential bias in patient selection for LND [57]. Additionally, regardless of the benefits of LND, concerns remain regarding the technical challenge of laparoscopic lymphadenectomy. Hattori et al. reported a significantly decreased number of lymph nodes removed following LNU (8.2–11.6) as compared to ONU (16.5) [44]. Busby and Matin, however, reported their experience that removal of an equivalent number of nodes could be performed with both laparoscopic and open approaches [58].

5. Future Developments

With the increased popularity in robotic-assisted laparoscopy in urology, individual case reports and small case series have recently described robotic-assisted LNU with either retroperitoneal or transperitoneal approaches [59–62]. The improved dexterity, precision, and control of robotic assistance may better facilitate handling of the distal ureter and bladder cuff [60]. However, concerns with cost and the potential need for patient repositioning and robot redocking may influence the widespread utilization of robotics in treating upper tract TCC.

6. Conclusions

Following the increased popularity of laparoscopy in urologic surgery, LNU has become a common treatment for TCC of the renal pelvis and ureter with decreased perioperative morbidity, shorter hospitalization, as well as comparable oncologic outcomes and survival rates as with ONU. The optimal technique for mobilization of the kidney and proximal ureter, as well as excision of the distal ureter and bladder cuff, is still evolving and largely based on surgeon preference. The classic open approach for distal ureter removal is most comparable to the established principles of open oncologic surgery and simultaneously allows for intact en bloc specimen removal. Regardless of technique used, minimal disruption of the urinary tract should be maintained to decrease the risk of recurrences and port-site metastases. The role of routine lymphadenectomy and the utilization of robotic assistance in upper urinary tract TCC are still to be determined. Long-term studies with prospective, randomized trials are necessary to fully evaluate the outcomes of LNU in the management of this aggressive disease.

References

[1] W. Oosterlinck, E. Solsona, A. P. M. van der Meijden, et al., "EAU guidelines on diagnosis and treatment of upper urinary tract transitional cell carcinoma," *European Urology*, vol. 46, no. 2, pp. 147–154, 2004.

[2] R. V. Clayman, L. R. Kavoussi, R. S. Figenshau, P. S. Chandhoke, and D. M. Albala, "Laparoscopic nephroureterectomy: initial clinical case report," *Journal of Laparoendoscopic Surgery*, vol. 1, no. 6, pp. 343–349, 1991.

[3] J. J. Rassweiler, M. Schulze, R. Marrero, T. Frede, J. Palou Redorta, and P. Bassi, "Laparoscopic nephroureterectomy for upper urinary tract transitional cell carcinoma: is it better than open surgery?" *European Urology*, vol. 46, no. 6, pp. 690–697, 2004.

[4] G. S. Gerber and B. R. Stockton, "Update on laparoscopic nephrectomy and nephroureterectomy," *Journal of Endourology*, vol. 19, no. 10, pp. 1151–1153, 2005.

[5] M. M. Desai, B. Strzempkowski, S. F. Matin, et al., "Prospective randomized comparison of transperitoneal versus retroperitoneal laparoscopic radical nephrectomy," *The Journal of Urology*, vol. 173, no. 1, pp. 38–41, 2005.

[6] J. Landman, R. Y. Lev, S. Bhayani, et al., "Comparison of hand assisted and standard laparoscopic radical nephroureterectomy for the management of localized transitional cell carcinoma," *The Journal of Urology*, vol. 167, no. 6, pp. 2387–2391, 2002.

[7] R. B. Nadler, S. Loeb, J. Q. Clemens, R. A. Batler, C. M. Gonzalez, and I. Y. Vardi, "A prospective study of laparoscopic radical nephrectomy for T1 tumors—is transperitoneal, retroperitoneal or hand assisted the best approach?" *The Journal of Urology*, vol. 175, no. 4, pp. 1230–1234, 2006.

[8] M. Muntener, M. E. Nielsen, F. R. Romero, et al., "Long-term oncologic outcome after laparoscopic radical nephroureterectomy for upper tract transitional cell carcinoma," *European Urology*, vol. 51, no. 6, pp. 1639–1644, 2007.

[9] P. Schatteman, C. Chatzopoulos, C. Assenmacher, et al., "Laparoscopic nephroureterectomy for upper urinary tract transitional cell carcinoma: results of a Belgian retrospective multicentre survey," *European Urology*, vol. 51, no. 6, pp. 1633–1638, 2007.

[10] M. Rouprêt, V. Hupertan, K. M. Sanderson, et al., "Oncologic control after open or laparoscopic nephroureterectomy for upper urinary tract transitional cell carcinoma: a single center experience," *Urology*, vol. 69, no. 4, pp. 656–661, 2007.

[11] T. Okegawa, A. Odagane, H. Ide, S. Horie, K. Nutahara, and E. Higashihara, "Oncological outcome of retroperitoneoscopic nephroureterectomy for upper urinary tract transitional cell carcinoma," *International Journal of Urology*, vol. 13, no. 5, pp. 493–497, 2006.

[12] M. Tsujihata, N. Nonomura, A. Tsujimura, K. Yoshimura, Y. Miyagawa, and A. Okuyama, "Laparoscopic nephroureterectomy for upper tract transitional cell carcinoma: comparison of laparoscopic and open surgery," *European Urology*, vol. 49, no. 2, pp. 332–336, 2006.

[13] T. Taweemonkongsap, C. Nualyong, T. Amornvesukit, et al., "Outcomes of surgical treatment for upper urinary tract transitional cell carcinoma: comparison of retroperitoneoscopic and open nephroureterectomy," *World Journal of Surgical Oncology*, vol. 6, article 3, pp. 1–7, 2008.

[14] S.-D. Chung, S.-C. Chueh, M.-K. Lai, et al., "Long-term outcome of hand-assisted laparoscopic radical nephroureterectomy for upper-tract urothelial carcinoma: comparison with open surgery," *Journal of Endourology*, vol. 21, no. 6, pp. 595–599, 2007.

[15] J. D. Raman, M. A. Palese, C. K. Ng, et al., "Hand-assisted laparoscopic nephroureterectomy for upper urinary tract transitional cell carcinoma," *Journal of the Society of Laparoendoscopic Surgeons*, vol. 10, no. 4, pp. 432–438, 2006.

[16] J. S. Wolf Jr., A. Dash, B. K. Hollenbeck, W. K. Johnston III, R. Madii, and J. S. Montgomery, "Intermediate followup of hand assisted laparoscopic nephroureterectomy for urothelial carcinoma: factors associated with outcomes," *The Journal of Urology*, vol. 173, no. 4, pp. 1102–1107, 2005.

[17] G. M. Cannon Jr., T. Averch, J. Colen, S. Morrisroe, O. Durrani, and R. L. Hrebinko Jr., "Hand-assisted laparoscopic nephroureterectomy with open cystotomy for removal of the distal ureter and bladder cuff," *Journal of Endourology*, vol. 19, no. 8, pp. 973–975, 2005.

[18] S.-D. Chung, C.-Y. Huang, S.-C. Chueh, et al., "Intermediate follow-up of hand-assisted retroperitoneoscopic nephroureterectomy for management of upper urinary tract urothelial carcinoma: comparison with open nephroureterectomy," *Urology*, vol. 69, no. 6, pp. 1030–1034, 2007.

[19] K. Nakashima, C. Fujiyama, Y. Tokuda, et al., "Oncologic assessment of hand-assisted retroperitoneoscopic nephroureterectomy for urothelial tumors of the upper tract: comparison with conventional open nephroureterectomy," *Journal of Endourology*, vol. 21, no. 6, pp. 583–588, 2007.

[20] D. Manabe, T. Saika, S. Ebara, et al., "Comparative study of oncologic outcome of laparoscopic nephroureterectomy and standard nephroureterectomy for upper urinary tract transitional cell carcinoma," *Urology*, vol. 69, no. 3, pp. 457–461, 2007.

[21] T. Y. Hsueh, Y.-H. Huang, A. W. Chiu, S. K. Huan, and Y.-H. Lee, "Survival analysis in patients with upper urinary tract transitional cell carcinoma: a comparison between open and hand-assisted laparoscopic nephroureterectomy," *BJU International*, vol. 99, no. 3, pp. 632–636, 2007.

[22] V. Paolucci, B. Schaeff, M. Schneider, and C. Gutt, "Tumor seeding following laparoscopy: international survey," *World Journal of Surgery*, vol. 23, no. 10, pp. 989–997, 1999.

[23] I. Ahmed, N. A. Shaikh, and C. R. Kapadia, "Track recurrence of renal pelvic transitional cell carcinoma after laparoscopic nephrectomy," *British Journal of Urology*, vol. 81, no. 2, p. 319, 1998.

[24] P. Barrett, D. D. Fentie, L. A. Taranger, et al., "Laparoscopic assisted nephroureterectomy (TCC)," *Journal of Endourology*, vol. 12, p. S103, 1998.

[25] M. Otani, S. Irie, and Y. Tsuji, "Port site metastasis after laparoscopic nephrectomy: unsuspected transitional cell carcinoma within a tuberculous atrophic kidney," *The Journal of Urology*, vol. 162, no. 2, pp. 486–487, 1999.

[26] A. M. Ong, S. B. Bhayani, and C. P. Pavlovich, "Trocar site recurrence after laparoscopic nephroureterectomy," *The Journal of Urology*, vol. 170, no. 4, part 1, p. 1301, 2003.

[27] S.-C. J. Chueh, I.-D. Tsaia, and M.-K. Laia, "Solitary port-site metastasis after laparoscopic bilateral nephroureterctomy for transitional cell carcinoma in a renal transplant recipient," *Transplantation Proceedings*, vol. 36, no. 9, pp. 2697–2698, 2004.

[28] S. Micali, A. Celia, P. Bove, et al., "Tumor seeding in urological laparoscopy: an international survey," *The Journal of Urology*, vol. 171, no. 6, part 1, pp. 2151–2154, 2004.

[29] Y. Matsui, H. Ohara, K. Ichioka, N. Terada, K. Yoshimura, and A. Terai, "Abdominal wall metastasis after retroperitoneoscopic assisted total nephroureterectomy for renal pelvic cancer," *The Journal of Urology*, vol. 171, no. 2, part 1, p. 793, 2004.

[30] N. Naderi, J. A. Nieuwenhuijzen, A. Bex, A. Kooistra, and S. Horenblas, "Port site metastasis after laparoscopic nephroureterectomy for transitional cell carcinoma," *European Urology*, vol. 46, no. 4, pp. 440–441, 2004.

[31] D. W. Strong and H. D. Pearse, "Recurrent urothelial tumors following surgery for transitional cell carcinoma of the upper urinary tract," *Cancer*, vol. 38, no. 5, pp. 2178–2183, 1976.

[32] T. Kakizoe, J. Fujita, T. Murase, K. Matsumoto, and K. Kishi, "Transitional cell carcinoma of the bladder in patients with renal pelvic and ureteral cancer," *The Journal of Urology*, vol. 124, no. 1, pp. 17–19, 1980.

[33] J. R. Steinberg and S. F. Matin, "Laparoscopic radical nephroureterectomy: dilemma of the distal ureter," *Current Opinion in Urology*, vol. 14, no. 2, pp. 61–65, 2004.

[34] H. McDonald, W. E. Upchurch, and C. E. Sturdevant, "Nephro-ureterectomy: a new technique," *The Journal of Urology*, vol. 67, pp. 804–809, 1952.

[35] C. M. Gonzalez, R. A. Batler, R. A. Schoor, J. C. Hairston, and R. B. Nadler, "A novel endoscopic approach towards resection of the distal ureter with surrounding bladder cuff during hand assisted laparoscopic nephroureterectomy," *The Journal of Urology*, vol. 165, no. 2, pp. 483–485, 2001.

[36] I. Y. Vardi, J. A. Stern, C. M. Gonzalez, S. Y. Kimm, and R. B. Nadler, "Novel technique for management of distal ureter and en block resection of bladder cuff during hand-assisted laparoscopic nephroureterectomy," *Urology*, vol. 67, no. 1, pp. 89–92, 2006.

[37] C. Wong and R. J. Leveillee, "Hand-assisted laparoscopic nephroureterectomy with cystoscopic en bloc excision of the distal ureter and bladder cuff," *Journal of Endourology*, vol. 16, no. 6, pp. 329–332, 2002.

[38] R. Ko, B. H. Chew, D. R. Hickling, et al., "Transitional-cell carcinoma recurrence rate after nephroureterectomy in patients who undergo open excision of bladder cuff *v* transurethral incision of the ureteral orifice," *Journal of Endourology*, vol. 21, no. 7, pp. 730–734, 2007.

[39] D. McDonald, "Intussusception ureterectomy: a method of removal of the ureteral stump at time of nephrectomy without an additional incision," *Surgery, Gynecology & Obstetrics*, vol. 97, pp. 565–568, 1953.

[40] B. Giovansili, M. Peyromaure, D. Saïghi, T. Dayma, M. Zerbib, and B. Debré, "Stripping technique for endoscopic management of distal ureter during nephroureterectomy: experience of 32 procedures," *Urology*, vol. 64, no. 3, pp. 448–452, 2004.

[41] I. S. Gill, J. J. Soble, S. D. Miller, and G. T. Sung, "A novel technique for management of the en bloc bladder cuff and distal ureter during laparoscopic nephroureterectomy," *The Journal of Urology*, vol. 161, no. 2, pp. 430–434, 1999.

[42] I. S. Gill, G. T. Sung, and M. G. Hobart, "Laparoscopic radical nephroureterectomy for upper tract transitional cell carcinoma: the Cleveland clinic experience," *The Journal of Urology*, vol. 164, no. 5, pp. 1513–1522, 2000.

[43] A. L. Shalhav, M. D. Dunn, A. J. Portis, A. M. Elbahnasy, E. M. McDougall, and R. V. Clayman, "Laparoscopic nephroureterectomy for upper tract transitional cell cancer: the Washington University experience," *The Journal of Urology*, vol. 163, no. 4, pp. 1100–1104, 2000.

[44] R. Hattori, Y. Yoshino, M. Gotoh, M. Katoh, O. Kamihira, and Y. Ono, "Laparoscopic nephroureterectomy for transitional cell carcinoma of renal pelvis and ureter: Nagoya experience," *Urology*, vol. 67, no. 4, pp. 701–705, 2006.

[45] R. Venkatesh, J. Rehman, J. Landman, et al., "Determination of cell viability after laparoscopic tissue stapling in a porcine model," *Journal of Endourology*, vol. 19, no. 6, pp. 744–747, 2005.

[46] S. F. Matin and I. S. Gill, "Recurrence and survival following laparoscopic radical nephroureterectomy with various forms of bladder cuff control," *The Journal of Urology*, vol. 173, no. 2, pp. 395–400, 2005.

[47] A. Tsivian, S. Benjamin, and A. A. Sidi, "A sealed laparoscopic nephroureterectomy: a new technique," *European Urology*, vol. 52, no. 4, pp. 1015–1019, 2007.

[48] D. E. McGinnis, E. J. Trabulsi, L. G. Gomella, and S. E. Strup, "Hand-assisted laparoscopic nephroureterectomy: description of technique," *Techniques in Urology*, vol. 7, no. 1, pp. 7–11, 2001.

[49] H. Abou El Fettouh, J. J. Rassweiler, M. Schulze, et al., "Laparoscopic radical nephroureterectomy: results of an international multicenter study," *European Urology*, vol. 42, no. 5, pp. 447–452, 2002.

[50] J. A. Brown, S. E. Strup, E. Chenven, D. Bagley, and L. G. Gomella, "Hand-assisted laparoscopic nephroureterectomy: analysis of distal ureterectomy technique, margin status, and surgical outcomes," *Urology*, vol. 66, no. 6, pp. 1192–1196, 2005.

[51] E. Kurzer, R. J. Leveillee, and V. G. Bird, "Combining hand assisted laparoscopic nephroureterectomy with cystoscopic circumferential excision of the distal ureter without primary closure of the bladder cuff—is it safe?" *The Journal of Urology*, vol. 175, no. 1, pp. 63–67, 2006.

[52] M. Ozsahin, A. Zouhair, S. Villà, et al., "Prognostic factors in urothelial renal pelvis and ureter tumours: a multicentre rare cancer network study," *European Journal of Cancer*, vol. 35, no. 5, pp. 738–743, 1999.

[53] K. Steven and A. L. Poulsen, "Radical cystectomy and extended pelvic lymphadenectomy: survival of patients with lymph node metastasis above the bifurcation of the common iliac vessels treated with surgery only," *The Journal of Urology*, vol. 178, no. 4, pp. 1218–1224, 2007.

[54] T. Kondo, H. Nakazawa, F. Ito, Y. Hashimoto, H. Toma, and K. Tanabe, "Primary site and incidence of lymph node metastases in urothelial carcinoma of upper urinary tract," *Urology*, vol. 69, no. 2, pp. 265–269, 2007.

[55] T. Kondo, H. Nakazawa, F. Ito, Y. Hashimoto, H. Toma, and K. Tanabe, "Impact of the extent of regional lymphadenectomy on the survival of patients with urothelial carcinoma of the upper urinary tract," *The Journal of Urology*, vol. 178, no. 4, pp. 1212–1217, 2007.

[56] M. A. Brausi, M. Gavioli, G. De Luca, et al., "Retroperitoneal lymph node dissection (RPLD) in conjunction with nephroureterectomy in the treatment of infiltrative transitional cell carcinoma (TCC) of the upper urinary tract: impact on survival," *European Urology*, vol. 52, no. 5, pp. 1414–1420, 2007.

[57] I. Cagiannos, "Editorial comment on: retroperitoneal lymph node dissection (RPLD) in conjunction with nephroureterectomy in the treatment of infiltrative transitional cell carcinoma (TCC) of the upper urinary tract: impact on survival," *European Urology*, vol. 52, no. 5, pp. 1419–1420, 2007.

[58] J. E. Busby and S. F. Matin, "Laparoscopic radical nephroureterectomy for transitional cell carcinoma: where are we in 2007?" *Current Opinion in Urology*, vol. 17, no. 2, pp. 83–87, 2007.

[59] K. Rose, S. Khan, H. Godbole, J. Olsburgh, and P. Dasgupta, "Robotic assisted retroperitoneoscopic nephroureterectomy—first experience and the hybrid port technique," *International Journal of Clinical Practice*, vol. 60, no. 1, pp. 12–14, 2006.

[60] D. K. Nanigian, W. Smith, and L. M. Ellison, "Robot-assisted laparoscopic nephroureterectomy," *Journal of Endourology*, vol. 20, no. 7, pp. 463–465, 2006.

[61] D. S. Finley, O. Melamud, and D. K. Ornstein, "Combined robot-assisted laparoscopic nephroureterectomy and radical prostatectomy," *Journal of Endourology*, vol. 21, no. 4, pp. 411–414, 2007.

[62] D. Eun, A. Bhandari, R. Boris, C. Rogers, M. Bhandari, and M. Menon, "Concurrent upper and lower urinary tract robotic surgery: strategies for success," *BJU International*, vol. 100, no. 5, pp. 1121–1125, 2007.

Hindawi Publishing Corporation
Advances in Urology
Volume 2009, Article ID 181927, 6 pages
doi:10.1155/2009/181927

Review Article

Retroperitoneal Lymph Nodes in Transitional Cell Carcinoma of the Kidney and Ureter

Shilajit D. Kundu[1] and Scott E. Eggener[2]

[1] *Department of Surgery, Memorial Sloan-Kettering Cancer Center, New York, NY 10065, USA*
[2] *Section of Urology, The University of Chicago Medical Center, Chicago, IL 60637, USA*

Correspondence should be addressed to Scott E. Eggener, seggener@surgery.bsd.uchicago.edu

Received 10 July 2008; Accepted 3 November 2008

Recommended by Norm D. Smith

The incidence of transitional cell carcinoma of the kidney and ureter is low and for that reason limited data exists regarding the appropriate management of regional retroperitoneal lymph nodes. Lymph node metastases have consistently been associated with an adverse prognosis. However, five-year cancer-specific survival following nephroureterectomy and lymphadenectomy for patients with lymph node involvement ranges from 0–39%, suggesting a therapeutic benefit. This review covers the primary tumor characteristics associated with lymph node involvement, imaging of the lymph nodes, as well as the rationale, role, patient selection, suggested anatomic templates, and technical considerations for lymphadenectomy.

1. Introduction

Transitional cell carcinoma (TCC) of the kidney and ureter, alternatively referred to as upper tract TCC (UT-TCC), represents approximately 10% of malignancies arising from the kidney and less than 5% of all urothelial malignancies, which primarily occur in the bladder. In 2007, about 3000 cases of UT-TCC were diagnosed in the United States compared to approximately 67 000 cases of bladder cancer [1, 2]. Within the upper urinary tract, TCC of the ureter is less common than TCC of the renal pelvis by a ratio of 1:4 [3]. There are a variety of treatment options available for UT-TCC including endoscopic excision or fulguration, segmental resection, and radical surgery. The management strategy selected primarily depends on the grade, stage, location, presence of multifocality, renal functional reserve, and the patient's comorbid conditions. Largely due to the infrequent disease incidence and variable lymph node templates, the role of lymphadenectomy for UT-TCC is not well defined. Since TCC of the bladder can be cured in approximately 25% of patients with regional nodal spread following an extended lymph node dissection (LND) and radical cystectomy, there is biologic plausibility to a therapeutic role for lymphadenectomy in patients with UT-TCC [4, 5]. This review will focus on the assessment and surgical treatment of lymph nodes in UT-TCC.

2. Relationship of Stage and Nodal Status with Outcome

Stage and grade of UT-TCC are independently associated with recurrence and survival. The five-year actuarial survival rates by primary tumor stage have been reported as 92%, 78%, 56%, and 0% for pathologic Ta-T1, T2, T3, and T4, respectively. Patients with stage T4 disease have a dismal median survival of 6 months [6, 7]. Tumor stage has consistently been shown to be the most powerful predictor of disease-specific survival [8–10]. However, other factors like higher grade, multifocality, lymphovascular invasion, and previous cystectomy have also been associated with inferior cancer-specific survival [10–12]. Transmural tumor growth (pT3 or pT4) is less common in distal ureteral tumors (33%) compared to midureteral (44%), proximal ureteral (75%), or renal pelvis tumors (41%). There are several plausible explanations for this observation. First, tumors in the proximal ureter may be less likely to cause obstructive

symptoms compared to distal ureteral tumors due to greater distensibility of the proximal ureter and therefore present at more advanced stages than tumors in the distal ureter. Another proposed mechanism relates in part to the differences in muscular layers between the proximal and distal ureters. The distal ureter is encased by 3 layers of muscle in comparison to the proximal ureter which only contains 2 relatively thin interlacing layers [13]. This difference could explain the 2-fold higher incidence of transmural growth of proximally located tumors as compared to more distally located tumors [8].

Recent series show that up to 30% of patients with UT-TCC have regional nodal involvement [7, 14]. All the tumor characteristics that are associated with a poor prognosis are associated with an increasing likelihood of lymph node involvement. The likelihood of lymph node involvement is associated with increasing stage and ranges from 4% in noninvasive TCC of the upper tract to as high as 60% in patients with pT4 disease [10]. Hall et al. reported on 139 patients with pTa, pT1, or pCIS followed for a median of 64 months and not a single patient exhibited lymph node involvement at surgery or on follow-up [6]. Similarly, Kondo et al. reported on 42 patients with pTa, pT1, and pCIS, and there were no instances of lymph node metastases [14]. The five-year cancer-specific survival among patients with lymph node involvement varies widely and ranges from 0–39% [7, 14–17] (Table 1). Another study showed lymph node involvement to be independently associated with a three-fold increased risk of death at five years [7]. To our knowledge, no study definitively demonstrates a survival benefit for patients undergoing lymphadenectomy. Interpretations of studies including an LND are challenging for a number of reasons: (a) indications for an LND are not standardized, (b) templates are highly variable, (c) often only clinically suspicious lymph nodes are removed, and (d) in many series LND is applied for staging purposes and not therapeutic intent. Survival data from UT-TCC series is also confounded by 50% of patients having a history of bladder cancer and a significant number having cardiopulmonary morbidities, leading to competing risks of mortality [7]. However, Rabbani et al. compared Surveillance Epidemiology and End Results (SEER) outcomes for 657 patients who had UT-TCC diagnosed after bladder cancer to 7 839 patients who had de novo UT-TCC and found that patients with de novo UT-TCC had a 1.7-fold increased risk of cancer-related death [18]. Taken together, these data suggest that stage, grade, lymphovascular invasion, and tumor location are important factors that impact survival and should be addressed when considering treatment of UT-TCC and lymph node dissection.

Table 1: Five-year cancer-specific survival for node-positive disease following nephroureterectomy and lymph node dissection.

	Number of node-positive patients	Five-year cancer-specific survival
Johansson and Wahlqvist [19]	N/A	0%
Secin et al. [15]	28	0%
Miyake et al. [17]	13	0%
Novara et al. [7]	27	12%
Kondo et al. [14]	42	15%
Park et al. [20]	11	27%
Roscigno et al. [16]	26	39%

3. Anatomic Distribution of Lymph Node Metastases

Anatomic lymph node mapping studies of the upper tract are rare due to multiple factors, including relative rarity of the disease, inconsistent dissection templates, and conflicting data on the role of lymphadenectomy in UT-CC. Tumors of the renal pelvis and upper ureter drain into the retroperitoneal lymph nodes, whereas tumors of the lower ureter drain predominantly into the pelvic lymph nodes. Work from Batata et al. in 1975 showed that node-positive tumors of the renal pelvis can involve upper retroperitoneal nodes (retrocrural, suprahilar, paracaval, paraaortic, and interaortocaval) and extend caudally to the external iliac lymph nodes [21]. Node-positive tumors of the middle and lower third of the ureter can also involve both the retroperitoneal and pelvic lymph nodes. Based on these findings, this group advocated an extensive LND encompassing both regions. Involvement of more than one lymph node has also been associated with an inferior 3-year cancer-specific survival compared to only one node involved (58% versus 16%) [22]. Kondo et al. recently reported the lymph node drainage sites of 42 patients based on pathologic or radiographic evidence of lymph node involvement. Tumors of the lower ureter demonstrated an approximately 10% rate of lymph node positivity, whereas tumors in the mid to upper ureters demonstrated an increased likelihood of positive lymph nodes (up to 42%). This was dependent on tumor stage and very few tumors that were pathologic T1 or less had lymph node involvement. Tumors of the right renal collecting system can metastasize to hilar, paracaval, retrocaval, interaortocaval lymph nodes, and right common iliac lymph nodes [23]. Rarely, in the setting of significant nodal disease, right-sided tumors will also metastasize to preaortic or paraaortic nodes. [14]. Tumors of the left renal collecting system may involve hilar, paraaortic, interaortocaval, and left common iliac lymph nodes [23]. Upper and midureteral tumors may also involve the same side-specific nodal regions as tumors of the renal pelvis, with midureteral tumors harboring the potential to spread to lymph node regions caudal to the inferior mesenteric artery extending along the common iliac nodal chain [14]. The nodal basins for tumors of the distal ureter include the external iliac, obturator, and hypogastric regions. Although constrained by limited lymph node dissections, these studies provide updated information on the lymph node drainage of the upper tracts in the current era.

4. Imaging of Lymph Nodes

Since staging of TCC plays an important role in dictating the course of therapy, accurate pretreatment imaging is of utmost importance. Computed tomography (CT) and magneticresonance (MR) imaging are the primary cross-sectional imaging modalities by which the regional lymph nodes are assessed. The rarity of UT-TCC has limited studies addressing imaging of these lymph nodes. However, imaging studies relating to TCC of the bladder can provide valuable insight. CT imaging can correctly stage lymph node involvement in over 70% of patients with muscle invasive bladder cancer. However, almost 25% of patients are understaged with clinically normal nodes on CT scan. CT has shown 28% sensitivity, 93% specificity, 68% positive predictive value, and 72% negative predictive value as relates to lymph node involvement in bladder cancer [24]. Jager et al. showed that MRI demonstrated a sensitivity, specificity, and accuracy of 83, 98, 92%, respectively, when lymph nodes were larger than 8–10 mm in patients with TCC of the bladder [25]. A common theme in most studies of CT or MRI in the staging of TCC is the relative understaging of lymph node involvement in radiographically "normal" nodes. The role of Fluorodeoxyglucose- (FDG-) positron emission tomography (PET) in the imaging of TCC of the urinary tract has been limited because it is excreted into the urine and hard to distinguish from tumor activity in the bladder or nearby lymph nodes. FDG-PET has helped to identify distant lymph node involvement and metastases for patients with TCC of the bladder but not well studied in UT-TCC [26]. However, with the advent and utilization of other radiotracer agents not excreted in the urine, such as ^{11}C-choline, the future of PET imaging for UT-TCC is promising. ^{11}C-choline PET-CT has shown encouraging preliminary data in detecting nodal spread of TCC of the bladder with pathologic confirmation of nodes as small as 5 mm [27]. While it seems intuitive that imaging studies of TCC of the bladder can be extrapolated to UT-TCC, this is not proven. Given the limitations of preoperative nodal imaging and the risk of understaging, LND remains the only way to definitively assess lymph node involvement in UT-TCC.

5. Role of Lymphadenectomy

As previously mentioned, sparse data exist to establish a well-defined role or optimal extent of LND. Virtually every study addressing LND for UT-TCC has been retrospective and severely limited by nonuniform application of LND, variable anatomic boundaries, and inconsistent selection for adjuvant therapy [6, 9, 14–16, 20, 28]. Therefore, determining whether LND provides a potential therapeutic benefit or simply offers more accurate surgical and pathologic staging is largely unknown. Nevertheless, the pertinent observations detailed above regarding lymph node metastases incidence, location, and prognostic significance have been made, subsequently reproduced, and help inform contemporary patient counseling and surgical management.

6. Staging

Intuitively, retroperitoneal LND should improve the accuracy of pathologic staging and allow for more accurate prognostic assessment. Therefore, complete surgical staging consists of a radical nephroureterectomy (NU) and regional LND. While no consensus has been established regarding the appropriate and necessary extent of a regional LND, multiple authors suggest patient-specific templates based on laterality of the primary tumor, location of the primary tumor (renal pelvis, upper/mid/lower ureter), and presence of radiographic or intraoperative retroperitoneal lymphadenopathy [14, 28, 29].

7. Therapeutic

While basic tenets of surgical oncology make it easy to proclaim that LND improves pathologic staging, it is largely unclear whether the time, effort, or potential morbidity of an LND is worthwhile from a therapeutic perspective. There are currently three lines of evidence suggesting that LND offers the potential for increasing the probability of cancer-specific survival. First, a proportion of patients with nodal metastases, up to 39%, exhibit intermediate-term cancer-free survival (Table 1) and highlight that regional nodal involvement is compatible with the possibility of durable cure. Second, multiple retrospective series, albeit with substantial limitations such as selection bias and the Will Rogers phenomenon [30], have shown that LND is associated with improved cancer-specific outcome [9, 16, 17, 28]. In a Japanese study by Kondo et al. of 169 patients with localized UT-TCC, a complete regional LND was associated with a 50% decreased risk cancer-specific death [28]. Roscigno et al. analyzed 132 patients undergoing NU for UT-TCC and five-year cancer-specific survival was 67% versus 40%, in favor of those having an LND [16]. Whether a patient underwent an LND in these series was surgeon determined and not prespecified. Therefore, factors such as patient age, clinical characteristics of the cancer, preoperative imaging features, comorbid diseases, and patient performance status undoubtedly influenced the decision of whether an LND was performed. We are unaware of any study that has randomized patients based on preoperative characteristics to inclusion or extent of LND. Until such a formal, prospective analysis is performed we will continue to debate the merits, value, and proper extent of an LND for UT-TCC. Third, since TCC of the UT and bladder originate from the same urothelial cells, it can be loosely extrapolated that patients with regional nodal involvement may respond similarly to surgical excision. Since the incidence of bladder TCC is much higher than UT-TCC, a richer experience with accompanying data has been established regarding the natural history of surgically treated node-positive patients. Approximately 25% of patients with bladder TCC and pelvic lymph node metastases will experience a durable recurrence-free survival [31], and up to 35–40% of patients with limited node involvement will experience low lymph node density or an organ-confined primary tumor [32, 33]. This attests to the curative potential of surgery for a subset of patients with

lymph-node metastases in TCC of the bladder and suggests a similar possibility for those with node-positive UT-TCC.

8. Patient Selection

Without prospective studies utilizing standardized anatomic templates, the selection of patients for LND at time of treatment for UT-TCC remains uncertain. While other urologic malignancies such as prostate, bladder, and testicular cancer lack formal randomized data regarding the impact of LND, much has been gleaned from the outcomes of a uniformly applied, extensive LND consisting of similar anatomic boundaries for each patient [32, 34, 35]. This has not been done in a systematic manner for patients with UT-TCC, therefore decisions regarding the application or extent of LND must be drawn from weaker lines of evidence.

Among patients undergoing NU for UT-TCC, 16–23% will experience a local recurrence, typically in the regional lymph nodes [20, 36]. For patients with ureteral tumors, Park et al. reported a 37% versus 7% local recurrence rate based on the absence or presence of an LND, respectively [20]. Whether an LND may have prevented these recurrences, decreased progression to systemic metastases, or improved disease-free survival is not known. However, with local recurrence rates so high and their nearly universal association with subsequent metastases and disease-specific mortality, the benefit of an LND appears to outweigh the risks.

The incidence of nodal metastases has been strongly associated with primary tumor stage and multiple series have reported that lymph node metastases in the setting of low stage UT-TCC ($\leq$pT1) are rare at surgery or on follow-up [6, 14]. This data initially suggests that LND may be excluded for patients with low-stage disease however the gross limitations of preoperative clinical staging preclude an accurate and reliable prediction of ultimate pathologic stage. Therefore, it is our belief that all patients undergoing treatment for UT-TCC regardless of surgical approach (laparoscopic or open) or type of surgery (segmental ureterectomy, partial nephrectomy, or radical NU) should have a concomitantly thorough regional LND.

9. Technical Considerations for Lymph Node Dissection

As UT-TCC may originate from either the renal or ureteral urothelium, the regional lymph nodes may vary and the anatomic regions of LND should be planned accordingly.

Based on the regional anatomic drainage detailed above and presuming that the surgeon prefers an extensive rather than a suboptimal LND, recommendations regarding LND anatomic boundaries can be offered. The anatomic borders of dissection for a left-sided renal pelvis, upper ureteral, or midureteral tumor should, at the minimum, encompass the paraaortic, preaortic, and interaortocaval nodes from the level of the renal hilum to the aortic bifurcation. For a right-sided renal pelvis, upper ureteral, or midureteral tumor the removed node regions should include the paracaval, precaval, and interaortocaval areas from the renal hilum to the aortic bifurcation. For most midureteral tumors and all distal ureteral tumors, regardless of side of origin, a common iliac, external iliac, obturator, and hypogastric lymphadenectomy should be performed.

The method of LND, either open or laparoscopic, is a secondary concern compared to the primary intent, which is a thorough and safe removal of regional lymph nodes. Between 43–72% of patients undergoing open NU have a simultaneous LND and it is our impression that patients undergoing laparoscopic NU do so even less frequently [15, 16, 20, 28]. Busby et al. have recently compared patients undergoing open and laparoscopic NU with LND and noted a slightly higher lymph node yield for patients undergoing the laparoscopic approach (median: 6 versus 3) [37]. The authors do not state what proportion of patients requiring NU had an LND. Both groups appear to have an inadequately low yield and surgeon template preference can easily, and likely did, account for the differences rather than surgical approach.

The surgeon's goals are to optimize pathologic staging, minimize local recurrences, and potentially improve disease-free survival. General technical concerns for retroperitoneal LND include "split and roll" of the inferior vena cava and/or aorta, meticulous hemostasis and lymphostasis, and readiness to control and ligate lumbar vessels when necessary. For left-sided templates, the left renal vein is positioned as the superior border unless suprahilar adenopathy is present, in such case the surgeon should consider a more cranial dissection. If bulky retroperitoneal metastases are bilateral and resectable, ejaculatory function may be of concern. However, since the median age at diagnosis of UT-TCC is typically in the late 70s [38], this situation should be rare. Since the sympathetic trunks, ganglia, and postsympathetic efferents are collectively responsible for antegrade ejaculation, their preservation, either by nerve-sparing or a modified template dissection [39], is essential to maintain normal ejaculatory function.

10. Future

Given the aforementioned limitations in retroperitoneal imaging, preoperative staging, and the devastating impact of local recurrences, we feel that an LND using a standardized template should be considered for all patients undergoing NU. However, if more accurate imaging with novel modalities such as lymphotrophic tracers, molecular agents, or PET scans becomes available, the treatment paradigm for patients with UT-TCC would be appropriately altered.

Neoadjuvant chemotherapy for patients with muscle-invasive bladder TCC results in improved disease-specific outcomes [40] and, given the parallels between bladder and UT-TCC, may be ideally suited for patients with high-risk UT-TCC. For UT-TCC, neoadjuvant chemotherapy has not been adequately studied and may never, given its relative rarity. Beside the potential for improving cancer control, other benefits may include optimizing renal function at the time of administration, allowing for maximum doses of the most active agents, and eliminating the possibility of surgical complications delaying adjuvant therapy. Since the

gemcitabine and cisplatin doublet provides similar efficacy to traditional MVAC (methotrexate, vinblastine, doxorubicin, and cisplatin) regimens in patients with bladder TCC, with an improved safety profile, neoadjuvant therapy for patients with UT-TCC becomes even more attractive [41].

References

[1] American Cancer Society, *Cancer Facts & Figures 2007*, American Cancer Society, Atlanta, Ga, USA, 2007.

[2] A. Jemal, T. Murray, E. Ward, et al., "Cancer statistics, 2005," *CA: A Cancer Journal for Clinicians*, vol. 55, no. 1, pp. 10–30, 2005.

[3] R. P. Huben, A. M. Mounzer, and G. P. Murphy, "Tumor grade and stage as prognostic variables in upper tract urothelial tumors," *Cancer*, vol. 62, no. 9, pp. 2016–2020, 1988.

[4] H. W. Herr and S. M. Donat, "Outcome of patients with grossly node positive bladder cancer after pelvic lymph node dissection and radical cystectomy," *The Journal of Urology*, vol. 165, no. 1, pp. 62–64, 2001.

[5] S. P. Lerner, D. G. Skinner, G. Lieskovsky, et al., "The rationale for en bloc pelvic lymph node dissection for bladder cancer patients with nodal metastases: long-term results," *The Journal of Urology*, vol. 149, no. 4, pp. 758–765, 1993.

[6] M. C. Hall, S. Womack, A. I. Sagalowsky, T. Carmody, M. D. Erickstad, and C. G. Roehrborn, "Prognostic factors, recurrence, and survival in transitional cell carcinoma of the upper urinary tract: a 30-year experience in 252 patients," *Urology*, vol. 52, no. 4, pp. 594–601, 1998.

[7] G. Novara, V. De Marco, F. Gottardo, et al., "Independent predictors of cancer-specific survival in transitional cell carcinoma of the upper urinary tract: multi-institutional dataset from 3 European centers," *Cancer*, vol. 110, no. 8, pp. 1715–1722, 2007.

[8] H. G. van der Poel, N. Antonini, H. van Tinteren, and S. Horenblas, "Upper urinary tract cancer: location is correlated with prognosis," *European Urology*, vol. 48, no. 3, pp. 438–444, 2005.

[9] M. A. Brausi, M. Gavioli, G. De Luca, et al., "Retroperitoneal lymph node dissection (RPLD) in conjunction with nephroureterectomy in the treatment of infiltrative transitional cell carcinoma (TCC) of the upper urinary tract: impact on survival," *European Urology*, vol. 52, no. 5, pp. 1414–1420, 2007.

[10] G. A. Brown, J. E. Busby, C. G. Wood, et al., "Nephroureterectomy for treating upper urinary tract transitional cell carcinoma: time to change the treatment paradigm?" *BJU International*, vol. 98, no. 6, pp. 1176–1180, 2006.

[11] B. Hong, S. Park, J. H. Hong, C.-S. Kim, J. Y. Ro, and H. Ahn, "Prognostic value of lymphovascular invasion in transitional cell carcinoma of upper urinary tract," *Urology*, vol. 65, no. 4, pp. 692–696, 2005.

[12] K. Saito, S. Kawakami, Y. Fujii, M. Sakura, H. Masuda, and K. Kihara, "Lymphovascular invasion is independently associated with poor prognosis in patients with localized upper urinary tract urothelial carcinoma treated surgically," *The Journal of Urology*, vol. 178, no. 6, pp. 2291–2296, 2007.

[13] M. K. Hanna, R. D. Jeffs, J. M. Sturgess, and M. Barkin, "Ureteral structure and ultrastructure. Part I. The normal human ureter," *The Journal of Urology*, vol. 116, no. 6, pp. 718–724, 1976.

[14] T. Kondo, H. Nakazawa, F. Ito, Y. Hashimoto, H. Toma, and K. Tanabe, "Primary site and incidence of lymph node metastases in urothelial carcinoma of upper urinary tract," *Urology*, vol. 69, no. 2, pp. 265–269, 2007.

[15] F. P. Secin, T. M. Koppie, J. I. M. Salamanca, et al., "Evaluation of regional lymph node dissection in patients with upper urinary tract urothelial cancer," *International Journal of Urology*, vol. 14, no. 1, pp. 26–32, 2007.

[16] M. Roscigno, C. Cozzarini, R. Bertini, et al., "Prognostic value of lymph node dissection in patients with muscle-invasive transitional cell carcinoma of the upper urinary tract," *European Urology*, vol. 53, no. 4, pp. 794–802, 2008.

[17] H. Miyake, I. Hara, K. Gohji, S. Arakawa, and S. Kamidono, "The significance of lymphadenectomy in transitional cell carcinoma of the upper urinary tract," *British Journal of Urology*, vol. 82, no. 4, pp. 494–498, 1998.

[18] F. Rabbani, M. Perrotti, P. Russo, and H. W. Herr, "Upper-tract tumors after an initial diagnosis of bladder cancer: argument for long-term surveillance," *Journal of Clinical Oncology*, vol. 19, no. 1, pp. 94–100, 2001.

[19] S. Johansson and L. Wahlqvist, "A prognostic study of urothelial renal pelvic tumors: comparison between the prognosis of patients treated with intrafascial nephrectomy and perifascial nephroureterectomy," *Cancer*, vol. 43, no. 6, pp. 2525–2531, 1979.

[20] S. Park, B. Hong, C.-S. Kim, and H. Ahn, "The impact of tumor location on prognosis of transitional cell carcinoma of the upper urinary tract," *The Journal of Urology*, vol. 171, no. 2, part 1, pp. 621–625, 2004.

[21] M. A. Batata, W. F. Whitmore Jr., B. S. Hilaris, N. Tokita, and H. Grabstald, "Primary carcinoma of the ureter: a prognostic study," *Cancer*, vol. 35, no. 6, pp. 1626–1632, 1975.

[22] H. Akaza, K. Koiso, and T. Niijima, "Clinical evaluation of urothelial tumors of the renal pelvis and ureter based on a new classification system," *Cancer*, vol. 59, no. 7, pp. 1369–1375, 1987.

[23] H. Komatsu, N. Tanabe, S. Kubodera, H. Maezawa, and A. Ueno, "The role of lymphadenectomy in the treatment of transitional cell carcinoma of the upper urinary tract," *The Journal of Urology*, vol. 157, no. 5, pp. 1622–1624, 1997.

[24] A. Blanco Díez, M. Ruibal Moldes, G. Suárez Pascual, et al., "Staging of infiltrating bladder cancer. Role of C.T. scan," *Archivos Españoles de Urología*, vol. 56, no. 1, pp. 23–29, 2003 (Spanish).

[25] G. J. Jager, J. O. Barentsz, G. O. Oosterhof, J. A. Witjes, and S. J. H. Ruijs, "Pelvic adenopathy in prostatic and urinary bladder carcinoma: MR imaging with a three-dimensional T1-weighted magnetization-prepared-rapid gradient-echo sequence," *American Journal of Roentgenology*, vol. 167, no. 6, pp. 1503–1507, 1996.

[26] S. Jana and M. D. Blaufox, "Nuclear medicine studies of the prostate, testes, and bladder," *Seminars in Nuclear Medicine*, vol. 36, no. 1, pp. 51–72, 2006.

[27] O. N. Gofrit, E. Mishani, M. Orevi, et al., "Contribution of ^{11}C-choline positron emission tomography/computerized tomography to preoperative staging of advanced transitional cell carcinoma," *The Journal of Urology*, vol. 176, no. 3, pp. 940–944, 2006.

[28] T. Kondo, H. Nakazawa, F. Ito, Y. Hashimoto, H. Toma, and K. Tanabe, "Impact of the extent of regional lymphadenectomy on the survival of patients with urothelial carcinoma of the upper urinary tract," *The Journal of Urology*, vol. 178, no. 4, pp. 1212–1217, 2007.

[29] J. D. Raman and D. S. Scherr, "Management of patients with upper urinary tract transitional cell carcinoma," *Nature Clinical Practice Urology*, vol. 4, no. 8, pp. 432–443, 2007.

[30] O. N. Gofrit, K. C. Zorn, G. D. Steinberg, G. P. Zagaja, and A. L. Shalhav, "The will rogers phenomenon in urological oncology," *The Journal of Urology*, vol. 179, no. 1, pp. 28–33, 2008.

[31] B. H. Bochner, G. Dalbagni, M. W. Kattan, et al., "Postoperative nomogram predicting risk of recurrence after radical cystectomy for bladder cancer," *Journal of Clinical Oncology*, vol. 24, no. 24, pp. 3967–3972, 2006.

[32] N. B. Dhar, E. A. Klein, A. M. Reuther, G. N. Thalmann, S. Madersbacher, and U. E. Studer, "Outcome after radical cystectomy with limited or extended pelvic lymph node dissection," *The Journal of Urology*, vol. 179, no. 3, pp. 873–878, 2008.

[33] J. P. Stein, J. Cai, S. Groshen, and D. G. Skinner, "Risk factors for patients with pelvic lymph node metastases following radical cystectomy with en bloc pelvic lymphadenectomy: the concept of lymph node density," *The Journal of Urology*, vol. 170, no. 1, pp. 35–41, 2003.

[34] P. Bader, F. C. Burkhard, R. Markwalder, and U. E. Studer, "Disease progression and survival of patients with positive lymph nodes after radical prostatectomy. Is there a chance of cure?" *The Journal of Urology*, vol. 169, no. 3, pp. 849–854, 2003.

[35] S. E. Eggener, B. S. Carver, D. S. Sharp, R. J. Motzer, G. J. Bosl, and J. Sheinfeld, "Incidence of disease outside modified retroperitoneal lymph node dissection templates in clinical stage I or IIA nonseminomatous germ cell testicular cancer," *The Journal of Urology*, vol. 177, no. 3, pp. 937–943, 2007.

[36] S. C. Cozad, S. R. Smalley, M. Austenfeld, M. Noble, S. Jennings, and R. Raymond, "Transitional cell carcinoma of the renal pelvis or ureter: patterns of failure," *Urology*, vol. 46, no. 6, pp. 796–800, 1995.

[37] J. E. Busby, G. A. Brown, and S. F. Matin, "Comparing lymphadenectomy during radical nephroureterectomy: open versus laparoscopic," *Urology*, vol. 71, no. 3, pp. 413–416, 2008.

[38] R. Flanigan, *Campbell-Walsh Urology*, Saunders, Philadelphia, Pa, USA, 9th edition, 2007.

[39] J. P. Donohue and R. S. Foster, "Retroperitoneal lymphadenectomy in staging and treatment: the development of nerve-sparing techniques," *Urologic Clinics of North America*, vol. 25, no. 3, pp. 461–468, 1998.

[40] H. B. Grossman, R. B. Natale, C. M. Tangen, et al., "Neoadjuvant chemotherapy plus cystectomy compared with cystectomy alone for locally advanced bladder cancer," *The New England Journal of Medicine*, vol. 349, no. 9, pp. 859–866, 2003.

[41] H. von der Maase, L. Sengelov, J. T. Roberts, et al., "Long-term survival results of a randomized trial comparing gemcitabine plus cisplatin, with methotrexate, vinblastine, doxorubicin, plus cisplatin in patients with bladder cancer," *Journal of Clinical Oncology*, vol. 23, no. 21, pp. 4602–4608, 2005.

Hindawi Publishing Corporation
Advances in Urology
Volume 2009, Article ID 419028, 4 pages
doi:10.1155/2009/419028

Review Article

The Role of Chemotherapy in Upper Tract Urothelial Carcinoma

Peter H. O'Donnell and Walter M. Stadler

Section of Hematology/Oncology, Department of Medicine, University of Chicago, Maryland Avenue, MC2115, Chicago, IL 60637, USA

Correspondence should be addressed to Walter M. Stadler, wstadler@medicine.bsd.uchicago.edu

Received 23 July 2008; Accepted 3 November 2008

Recommended by Norm D. Smith

Locally advanced upper tract urothelial carcinoma has a poor prognosis. While surgery represents the only potentially curable therapeutic intervention, recurrences are common and typically systemic in nature. It is thus reasonable to consider perioperative chemotherapy in an effort to decrease the risk of recurrence. There are very little direct data providing clinical guidance in this scenario. For urothelial cancer of the bladder, there are randomized phase III data demonstrating a survival advantage with neoadjuvant cisplatin-based combination chemotherapy. Although arguments favoring adjuvant chemotherapy could be made for upper tract urothelial cancer, the loss of renal function that occurs with nephrectomy can complicate administration of appropriate perioperative treatment. Therefore, by analogy to urothelial carcinoma of the lower tract, it is argued that cisplatin-based neoadjuvant chemotherapy should be the standard of care for patients with locally advanced upper tract urothelial cancer.

1. Introduction

Locally advanced upper tract urothelial carcinoma has a poor prognosis. Surgical series suggest that, notwithstanding nodal status, the disease-specific five-year survival rates for stages T2 and T3 disease are 73% and 40%, respectively, while the median survival for T4 patients is approximately 6 months [1]. Importantly, the vast majority of patients with invasive upper tract urothelial carcinoma have stage T3 or greater disease at the time of surgery [2, 3], and, if investigated, at least 20–25% will have lymph node involvement at the time of surgery [4–6]. The poor prognosis is furthermore reflected by mortality estimates in which the mortality to incidence ratio for upper tract disease is approximately 0.34 [7], whereas for lower tract urothelial cancer it is 0.20 [8]. This may be due in part to the notorious difficulty of diagnosing earlier-stage urothelial cancer of the upper tract.

The most common presenting symptom of upper tract urothelial carcinoma, like its bladder counterpart, is hematuria [1]. Unfortunately, urine cytology is not particularly sensitive for diagnosing urothelial carcinoma of any location [9, 10]. Anterior grade and retrograde pyelogram, or ureteroscopy with visualization of the renal pelvices, are technically challenging and not routinely performed in the evaluation of hematuria. Computed tomography (CT) imaging is also not very sensitive for early stage disease [11, 12].

While surgery represents the only potentially curable therapeutic intervention for upper tract urothelial cancer, systemic recurrences are common [1, 3, 13]. It is thus reasonable to consider perioperative chemotherapy in an effort to decrease the risk of recurrence. Unfortunately, with only approximately 2000 cases annually in the United States [7, 14], and with the historical difficulties in accruing urothelial carcinoma patients to clinical trials, there are very little direct data providing clinical guidance in this scenario. Using analogy to urothelial carcinoma of the lower tract, we believe that cisplatin-based neoadjuvant chemotherapy should be the standard of care for patients with locally advanced upper tract urothelial cancer.

2. Is Urothelial Cancer of the Upper Tract Different?

Bladder and upper tract urothelial carcinomas have traditionally been considered separate diseases in the urologic and surgical literature mainly because the surgical approach

to these diseases is so different. Yet, recent evidence has suggested that the anatomic location of disease has no bearing on tumor behavior, in that recurrence and mortality rates from upper and lower tract carcinomas are similar when adjusted for tumor stage and grade [15]. Additionally, from a biologic prospective, there is very little difference between urothelial carcinomas that arise from these different sites. First of all, the most important epidemiologic risk factor for urothelial cancer remains exposure to tobacco products [16, 17], and this is true regardless of the site of origin. Secondly, the urothelial tissue itself is histologically indistinguishable by site [18]. Certainly, there are differences in the underlying stroma and supportive tissue, but the importance of these differences in the treatment of systemic disease, including the microscopic systemic disease that is being targeted in perioperative therapy, is debatable. Thirdly, the molecular oncogenic events appear to be the same between upper and lower tract urothelial cancers. For example, for both origins, chromosome 9 deletions are the most common genetic abnormality [19, 20], and chromosome 9 and p53 alterations appear to be present at similar frequencies in upper and lower tract lesions [20, 21]. Fourth, it has been the practice of the medical oncology community to include urothelial carcinoma patients in trials of metastatic disease, regardless of the site of origin. A number of large studies have thus included at least a fraction of patients whose initial tumor began in the upper tract [22–28]. In none of those studies was the site of origin an important prognostic factor in the context of systemic chemotherapy. Finally, the high incidence of secondary (40–50%), or, less commonly, synchronous (8%) lower tract disease in patients with upper tract disease [1, 29] also supports the notion that these cancers actually represent one disease process in such patients. It is thus reasonable to consider systemic and perioperative chemotherapy for locally advanced upper tract urothelial cancer by analogy to urothelial cancer of the bladder.

For urothelial cancer of the bladder, there are randomized phase III data demonstrating a survival advantage with neoadjuvant cisplatin-based combination chemotherapy. The two largest trials were conducted by an international collaboration [30] and by Grossman et al. [31]. A meta-analysis including all neoadjuvant chemotherapy trials confirms the conclusion [32]. Others have argued that the absolute benefit of neoadjuvant chemotherapy is modest [33], and that the more accurate clinical staging afforded by surgery [34] allows better patient selection on the basis of prognostic factors [35]. Under the assumption of equivalent benefit irrespective of underlying prognosis, the absolute benefit of perioperative chemotherapy for poor prognosis patients is certainly going to be greater than that for good prognosis patients. Nevertheless, the randomized studies of adjuvant chemotherapy in urothelial cancer of the bladder have been undersized and underpowered for detecting a clinically significant benefit [36–40].

Although similar arguments favoring adjuvant chemotherapy could be made for upper tract urothelial cancer, the loss of renal function that occurs with nephrectomy can further complicate administration of appropriate perioperative treatment. In this regard, the above noted meta-analysis [32] demonstrated survival benefits with neoadjuvant therapy only when cisplatin-based combination chemotherapy was utilized, and two randomized studies in the metastatic setting have strongly suggested that carboplatin, which is typically substituted for cisplatin in patients with renal dysfunction, is an inferior agent [41, 42]. Furthermore, the decrement in renal function associated with nephrectomy is not inconsequential, as evidenced by studies in renal cancer patients undergoing nephrectomy [43, 44]. This may be even more important in urothelial cancer patients who are often smokers and have other smoking-related comorbidities. Finally, anecdotal experience and early evidence [45, 46] suggest that even among patients in whom neoadjuvant chemotherapy is indicated, only a minority actually receive chemotherapy. This raises concerns about a lack of adherence to chemotherapy recommendations [47] in the urologic community, or perhaps an unwillingness by patients to be treated. Even if some urologists forgo neoadjuvant chemotherapy referral in favor of future adjuvant administration, adherence percentages in the postoperative setting are likely to be even lower, because of both patient and surgeon factors [48, 49]. Furthermore, despite hypothetical concerns about the potential for increased surgical morbidity after neoadjuvant chemotherapy, the data in bladder cancer patients have strongly demonstrated that this does not occur [49, 50], so we anticipate that the same would be true for neoadjuvant chemotherapy in upper tract disease.

3. Conclusions

Upper tract urothelial carcinoma, when not metastatic, typically presents with locally advanced disease. Such disease has a poor prognosis because of the high risk of systemic recurrence. Although the surgical approach to upper tract and lower tract urothelial cancers is markedly different, the biology of these diseases is for the most part indistinguishable. Certainly, the response to therapy appears to be the same. Given the rarity of upper tract urothelial cancer and the difficulty of accruing to clinical trials, recommendations for perioperative chemotherapy must currently be based on similarities to its lower tract counterpart. In this regard, neoadjuvant chemotherapy is the standard of care based on improvements in survival in well-conducted phase III trials. Such data does not exist with adjuvant therapy in bladder cancer, and adjuvant therapy for upper tract disease is further complicated by the difficulty of administering cisplatin-based regimens to patients who may suffer a decrement in renal function following nephrectomy. Therefore, until and unless specific trials are conducted, the most reasonable standard for locally advanced upper tract urothelial cancer is neoadjuvant, cisplatin-based combination chemotherapy prior to nephrectomy and surgical resection.

References

[1] M. C. Hall, S. Womack, A. I. Sagalowsky, T. Carmody, M. D. Erickstad, and C. G. Roehrborn, "Prognostic factors, recurrence, and survival in transitional cell carcinoma of the

upper urinary tract: a 30-year experience in 252 patients," *Urology*, vol. 52, no. 4, pp. 594–601, 1998.

[2] S. Holmäng and S. L. Johansson, "Urothelial carcinoma of the upper urinary tract: comparison between the WHO/ISUP 1998 consensus classification and WHO 1999 classification system," *Urology*, vol. 66, no. 2, pp. 274–278, 2005.

[3] S. A. Mcneill, M. Chrisofos, and D. A. Tolley, "The long-term outcome after laparoscopic nephroureterectomy: a comparison with open nephroureterectomy," *BJU International*, vol. 86, no. 6, pp. 619–623, 2000.

[4] H. Miyake, I. Kara, K. Gohji, S. Arakawa, and S. Kamidono, "The significance of lymphadenectomy in transitional cell carcinoma of the upper urinary tract," *British Journal of Urology*, vol. 82, no. 4, pp. 494–498, 1998.

[5] L. Charbit, M.-C. Gendreau, S. Mee, and J. Cukier, "Tumors of the upper urinary tract: 10 years of experience," *The Journal of Urology*, vol. 146, no. 5, pp. 1243–1246, 1991.

[6] T. Kondo, H. Nakazawa, F. Ito, Y. Hashimoto, H. Toma, and K. Tanabe, "Primary site and incidence of lymph node metastases in urothelial carcinoma of upper urinary tract," *Urology*, vol. 69, no. 2, pp. 265–269, 2007.

[7] A. Jemal, R. Siegel, E. Ward, T. Murray, J. Xu, and M. J. Thun, "Cancer statistics, 2007," *CA: A Cancer Journal for Clinicians*, vol. 57, no. 1, pp. 43–66, 2007.

[8] Surveillance Epidemiology and End Results (SEER) Database, Cancer of the Urinary Bladder Fact Sheet, Surveillance Research Program, National Cancer Institute, June 2008, http://seer.cancer.gov.

[9] R. Chahal, N. K. Gogoi, and S. K. Sundaram, "Is it necessary to perform urine cytology in screening patients with haematuria?" *European Urology*, vol. 39, no. 3, pp. 283–286, 2001.

[10] S. Viswanath, B. Zelhof, E. Ho, K. Sethia, and R. Mills, "Is routine urine cytology useful in the haematuria clinic?" *Annals of the Royal College of Surgeons of England*, vol. 90, no. 2, pp. 153–155, 2008.

[11] M. J. Scolieri, M. L. Paik, S. L. Brown, and M. I. Resnick, "Limitations of computed tomography in the preoperative staging of upper tract urothelial carcinoma," *Urology*, vol. 56, no. 6, pp. 930–934, 2000.

[12] E. M. Caoili, R. H. Cohan, P. Inampudi, et al., "MDCT urography of upper tract urothelial neoplasms," *American Journal of Roentgenology*, vol. 184, no. 6, pp. 1873–1881, 2005.

[13] J. J. Rassweiler, M. Schulze, R. Marrero, T. Frede, J. P. Redorta, and P. Bassi, "Laparoscopic nephroureterectomy for upper urinary tract transitional cell carcinoma: is it better than open surgery?" *European Urology*, vol. 46, no. 6, pp. 690–697, 2004.

[14] J. J. Munoz and L. M. Ellison, "Upper tract urothelial neoplasms: incidence and survival during the last 2 decades," *The Journal of Urology*, vol. 164, no. 5, pp. 1523–1525, 2000.

[15] J. W. F. Catto, D. R. Yates, I. Rehman, et al., "Behavior of urothelial carcinoma with respect to anatomical location," *The Journal of Urology*, vol. 177, no. 5, pp. 1715–1720, 2007.

[16] P. Brennan, O. Bogillot, S. Cordier, et al., "Cigarette smoking and bladder cancer in men: a pooled analysis of 11 case-control studies," *International Journal of Cancer*, vol. 86, no. 2, pp. 289–294, 2000.

[17] F. Korkes, T. S. Silveira, M. G. Castro, G. Cuck, R. C. Fernandes, and M. D. Perez, "Carcinoma of the renal pelvis and ureter," *International Brazil Journal of Urology*, vol. 32, no. 6, pp. 648–655, 2006.

[18] R. Gupta, G. P. Paner, and M. B. Amin, "Neoplasms of the upper urinary tract: a review with focus on urothelial carcinoma of the pelvicalyceal system and aspects related to its diagnosis and reporting," *Advances in Anatomic Pathology*, vol. 15, no. 3, pp. 127–139, 2008.

[19] T.-S. Tzai, H. H.-W. Chen, S.-H. Chan, et al., "Clinical significance of allelotype profiling for urothelial carcinoma," *Urology*, vol. 62, no. 2, pp. 378–384, 2003.

[20] C. Hafner, R. Knuechel, L. Zanardo, et al., "Evidence for oligoclonality and tumor spread by intraluminal seeding in multifocal urothelial carcinomas of the upper and lower urinary tract," *Oncogene*, vol. 20, no. 35, pp. 4910–4915, 2001.

[21] T. D. Jones, M. Wang, J. N. Eble, et al., "Molecular evidence supporting field effect in urothelial carcinogenesis," *Clinical Cancer Research*, vol. 11, no. 18, pp. 6512–6519, 2005.

[22] D. S. Kaufman, M. A. Carducci, T. M. Kuzel, et al., "A multi-institutional phase II trial of gemcitabine plus paclitaxel in patients with locally advanced or metastatic urothelial cancer," *Urologic Oncology: Seminars and Original Investigations*, vol. 22, no. 5, pp. 393–397, 2004.

[23] H. von der Maase, S. W. Hansen, J. T. Roberts, et al., "Gemcitabine and cisplatin versus methotrexate, vinblastine, doxorubicin, and cisplatin in advanced or metastatic bladder cancer: results of a large, randomized, multinational, multicenter, phase III study," *Journal of Clinical Oncology*, vol. 18, no. 17, pp. 3068–3077, 2000.

[24] C. N. Sternberg, P. H. M. de Mulder, J. H. Schornagel, et al., "Randomized phase III trial of high-dose-intensity methotrexate, vinblastine, doxorubicin, and cisplatin (MVAC) chemotherapy and recombinant human granulocyte colony-stimulating factor versus classic MVAC in advanced urothelial tract tumors: European Organization for Research and Treatment of Cancer Protocol no. 30924," *Journal of Clinical Oncology*, vol. 19, no. 10, pp. 2638–2646, 2001.

[25] A. Bamias, G. Aravantinos, C. Deliveliotis, et al., "Docetaxel and cisplatin with granulocytecolony-stimulating factor (G-CSF) versus MVAC with G-CSF in advanced urothelial carcinoma: a multicenter, randomized, phase III study from the Hellenic Cooperative Oncology Group," *Journal of Clinical Oncology*, vol. 22, no. 2, pp. 220–228, 2004.

[26] A. Bamias, G. Aravantinos, C. Deliveliotis, et al., "Erratum: docetaxel and cisplatin with granulocyte colony-stimulating factor (G-CSF) versus MVAC with G-CSF in advanced urothelial carcinoma: a multicenter, randomized, phase III study from the Hellenic Cooperative Oncology Group," *Journal of Clinical Oncology*, vol. 22, no. 9, p. 1771, 2004.

[27] D. Kaufman, D. Raghavan, M. Carducci, et al., "Phase II trial of gemcitabine plus cisplatin in patients with metastatic urothelial cancer," *Journal of Clinical Oncology*, vol. 18, no. 9, pp. 1921–1927, 2000.

[28] R. Dreicer, J. Manola, B. J. Roth, et al., "Phase III trial of methotrexate, vinblastine, doxorubicin, and cisplatin versus carboplatin and paclitaxel in patients with advanced carcinoma of the urothelium: a trial of the Eastern Cooperative Oncology Group," *Cancer*, vol. 100, no. 8, pp. 1639–1645, 2004.

[29] J. D. Raman, R. E. Sosa, E. D. Vaughan Jr., and D. S. Scherr, "Pathologic features of bladder tumors after nephroureterectomy or segmental ureterectomy for upper urinary tract transitional cell carcinoma," *Urology*, vol. 69, no. 2, pp. 251–254, 2007.

[30] International Collaboration of Trialists, "Neoadjuvant cisplatin, methotrexate, and vinblastine chemotherapy for muscle-invasive bladder cancer: a randomised controlled trial," *The Lancet*, vol. 354, no. 9178, pp. 533–540, 1999.

[31] H. B. Grossman, R. B. Natale, C. M. Tangen, et al., "Neoadjuvant chemotherapy plus cystectomy compared with

cystectomy alone for locally advanced bladder cancer," *The New England Journal of Medicine*, vol. 349, no. 9, pp. 859–866, 2003.

[32] Advanced Bladder Cancer Meta-Analysis Collaboration and C. Vale, "Neoadjuvant chemotherapy in invasive bladder cancer: a systematic review and meta-analysis," *The Lancet*, vol. 361, no. 9373, pp. 1927–1934, 2003.

[33] M. R. Feneley and S. Harland, "Neoadjuvant chemotherapy for muscle-invasive bladder cancer: a new standard of care?" *BJU International*, vol. 92, no. 9, pp. 877–878, 2003.

[34] H. I. Scher, A. Yagoda, H. W. Herr, et al., "Neoadjuvant M-VAC (methotrexate, vinblastine, doxorubicin and cisplatin) effect on the primary bladder lesion," *The Journal of Urology*, vol. 139, no. 3, pp. 470–474, 1988.

[35] P. C. Black, G. A. Brown, H. B. Grossman, and C. P. Dinney, "Neoadjuvant chemotherapy for bladder cancer," *World Journal of Urology*, vol. 24, no. 5, pp. 531–542, 2006.

[36] A. V. Bono, C. Benvenuti, L. Reali, et al., "Adjuvant chemotherapy in advanced bladder cancer. Italian Uro-Oncologic Cooperative Group," *Progress in Clinical and Biological Research*, vol. 303, pp. 533–540, 1989.

[37] D. G. Skinner, J. R. Daniels, C. A. Russell, et al., "The role of adjuvant chemotherapy following cystectomy for invasive bladder cancer: a prospective comparative trial," *The Journal of Urology*, vol. 145, no. 3, pp. 459–467, 1991.

[38] M. Stöckle, W. Meyenburg, S. Wellek, et al., "Advanced bladder cancer (stages pT3b, pT4a, pN1 and pN2): improved survival after radical cystectomy and 3 adjuvant cycles of chemotherapy. Results of a controlled prospective study," *The Journal of Urology*, vol. 148, no. 2, part 1, pp. 302–307, 1992.

[39] U. E. Studer, M. Bacchi, C. Biedermann, et al., "Adjuvant cisplatin chemotherapy following cystectomy for bladder cancer: results of a prospective randomized trial," *The Journal of Urology*, vol. 152, no. 1, pp. 81–84, 1994.

[40] F. Freiha, J. Reese, and F. M. Torti, "A randomized trial of radical cystectomy versus radical cystectomy plus cisplatin, vinblastine and methotrexate chemotherapy for muscle invasive bladder cancer," *The Journal of Urology*, vol. 155, no. 2, pp. 495–500, 1996.

[41] L. Dogliotti, G. Cartenì, S. Siena, et al., "Gemcitabine plus cisplatin versus gemcitabine plus carboplatin as first-line chemotherapy in advanced transitional cell carcinoma of the urothelium: results of a randomized phase 2 trial," *European Urology*, vol. 52, no. 1, pp. 134–141, 2007.

[42] J. Bellmunt, A. Ribas, N. Eres, et al., "Carboplatin-based versus cisplatin-based chemotherapy in the treatment of surgically incurable advanced bladder carcinoma," *Cancer*, vol. 80, no. 10, pp. 1966–1972, 1997.

[43] W. K. O. Lau, M. L. Blute, A. L. Weaver, V. E. Torres, and H. Zincke, "Matched comparison of radical nephrectomy vs nephron-sparing surgery in patients with unilateral renal cell carcinoma and a normal contralateral kidney," *Mayo Clinic Proceedings*, vol. 75, no. 12, pp. 1236–1242, 2000.

[44] J. McKiernan, R. Simmons, J. Katz, and P. Russo, "Natural history of chronic renal insufficiency after partial and radical nephrectomy," *Urology*, vol. 59, no. 6, pp. 816–820, 2002.

[45] K. A. David, M. I. Milowsky, J. Ritchey, P. R. Carroll, and D. M. Nanus, "Low incidence of perioperative chemotherapy for stage III bladder cancer 1998 to 2003: a report from the National Cancer Data Base," *The Journal of Urology*, vol. 178, no. 2, pp. 451–454, 2007.

[46] D. Schrag, N. Mitra, F. Xu, et al., "Cystectomy for muscle-invasive bladder cancer: patterns and outcomes of care in the medicare population," *Urology*, vol. 65, no. 6, pp. 1118–1125, 2005.

[47] C. N. Sternberg, S. M. Donat, J. Bellmunt, et al., "Chemotherapy for bladder cancer: treatment guidelines for neoadjuvant chemotherapy, bladder preservation, adjuvant chemotherapy, and metastatic cancer," *Urology*, vol. 69, supplement 1, pp. 62–79, 2007.

[48] S. M. Donat, A. Shabsigh, C. Savage, et al., "Potential impact of postoperative earlycomplications on the timing of adjuvant chemotherapy in patients undergoing radical cystectomy: a high volume tertiary cancer center experience," *European Urology*, vol. 55, no. 1, pp. 177–186, 2008.

[49] R. Millikan, C. Dinney, D. Swanson, et al., "Integrated therapy for locally advanced bladder cancer: final report of a randomized trial of cystectomy plus adjuvant M-VAC versus cystectomy with both preoperative and postoperative M-VAC," *Journal of Clinical Oncology*, vol. 19, no. 20, pp. 4005–4013, 2001.

[50] M. C. Hall, D. A. Swanson, and C. P. N. Dinney, "Complications of radical cystectomy: impact of the timing of perioperative chemotherapy," *Urology*, vol. 47, no. 6, pp. 826–830, 1996.

Hindawi Publishing Corporation
Advances in Urology
Volume 2009, Article ID 656521, 14 pages
doi:10.1155/2009/656521

Review Article

Comprehensive Management of Upper Tract Urothelial Carcinoma

Georgios Koukourakis,[1] Georgios Zacharias,[2] Michael Koukourakis,[3] Kiriaki Pistevou-Gobaki,[4] Christos Papaloukas,[4] Athanasios Kostakopoulos,[5] and Vassilios Kouloulias[1]

[1] *Radiation Therapy Unit, 2nd Department of Radiology, Athens University Medical School, Attikon University Hospital, Rimini 1 Street, Haidari, 12462 Athens, Greece*
[2] *Section of Pathology, Policlinic of Athens, Piraeus 5 Street, 11474 Athens, Greece*
[3] *Radiation Therapy Unit, University Hospital of Thrace, 68100 Alexandroupolis, Greece*
[4] *Radiation-Oncology Department, AHEPA University Hospital of Thessalonica, 54301 Thessalonica, Greece*
[5] *Section of Urology, University Hospital of Athens, 10029 Athens, Greece*

Correspondence should be addressed to Georgios Koukourakis, gkoyokoyrakis@yahoo.gr

Received 30 April 2008; Revised 4 August 2008; Accepted 15 September 2008

Recommended by Norm D. Smith

Urothelial carcinoma of the upper urinary tract represents only 5% of all urothelial cancers. The 5-year cancer-specific survival in the United States is roughly 75% with grade and stage being the most powerful predictors of survival. Nephroureterectomy with excision of the ipsilateral ureteral orifice and bladder cuff en bloc remains the gold standard treatment of the upper urinary tract urothelial cancers, while endoscopic and laparoscopic approaches are rapidly evolving as reasonable alternatives of care depending on grade and stage of disease. Several controversies remain in their management, including a selection of endoscopic versus laparoscopic approaches, management strategies on the distal ureter, the role of lymphadenectomy, and the value of chemotherapy in upper tract disease. Aims of this paper are to critically review the management of such tumors, including endoscopic management, laparoscopic nephroureterectomy and management of the distal ureter, the role of lymphadenectomy, and the emerging role of chemotherapy in their treatment.

1. Introduction

Primary urothelial carcinoma of the upper tract is a rare urological disease and has a propensity for multifocality, local recurrence, and development of metastases. Almost 5% of all urothelial neoplasms occur in the kidney and ureters. The vast majority of upper tract tumors arise in the kidney, comprising 4% to 15% of all primary kidney neoplasms in the United States, whereas ureteral tumors represent only 1% [1].

As a result, urothelial carcinoma of the bladder has been examined to a greater extent than urothelial tumors elsewhere.

The main treatment for patients with upper tract urothelial neoplasms and a normal contralateral kidney is a complete nephroureterectomy with removal of a cuff of urinary bladder. Due to the high rate of ureteral stump recurrence, which has been reported to be between 30% and 75%, it is important to complete the nephroureterectomy with a cuff of urinary bladder [2–10]. Hall et al. [11] reported in one of the largest series in the literature on 252 patients who were treated for upper tract urothelial tumors with a median follow-up of 64 months. One hundred ninety-four (76.6%) patients underwent open radical nephroureterectomy with removal of bladder cuff, 42 (16.7%) patients underwent parenchymal-sparing surgery, 14 (5.6%) patients underwent nephrectomy alone, and 2 (0.8%) had exploration only for nonresectable disease. Overall, patients undergoing parenchymal-sparing surgery had a lower actuarial 5-year disease-free survival rate than those treated with initial

Table 1: Studies that compare laparoscopic nephroureterectomy with open surgery.

Study	No. of patients	Tumor grade	Follow-up	Outcomes
Gill et al. [12]	42 in LT, 35 in OS	34 patients in LT arm and 28 in OS arm III tumors	11.1 months in LT,34.4 in OS	LT significantly decreasing morbidity with comparable oncological and survival data to OS
Shalhav et al. [13]	25 in LT 17 in OS	21 patients in LT arm and 14 in OS arm grade II	2 years in both arms	LT has longer operating time but the same efficacy and is better tolerated

LT: laparoscopic treatment, OS: open surgery.

aggressive surgical resection (23% versus 45%, $P < .0009$). Patients with grades 1 and 2 tumors were equally distributed in these 2 groups. This study supported the use of aggressive open surgical resection for initial treatment of upper tract urothelial tumors, with a 5-year disease-free survival rate of 45%.

Nevertheless, the gold standard of open radical nephroureterectomy with resection of a bladder cuff is being challenged by minimally invasive approaches to the managing of upper tract transitional cell carcinoma (TCC). For upper tract urothelial carcinoma, laparoscopic nephroureterectomy has been used as an alternative to an open procedure. Since the first laparoscopic nephroureterectomy, performed by Clayman in May 1991 at Washington University (St. Louis, Mo, USA), numerous reports regarding the safety and efficacy of that procedure have been published [12, 14–23]. This paper will cover the therapeutic approaches to upper tract TCC, including laparoscopic nephroureterectomy, endoscopic approaches, and the prognostic value of lymphadenectomy in patients with muscle invasion. Topical immunotherapy, adjuvant chemotherapy, and adjuvant radiation therapy will also be discussed.

2. Surgical Treatment

2.1. Laparoscopic Treatment. Recently, Gill et al. published on their experience of 42 patients who underwent laparoscopic retroperitoneal nephroureterectomy with a mean follow-up of 11.1 months [12]. The distal ureter was treated with a combination of laparoscopic and endoscopic transvesical approaches [23]. A comparable research was performed between those patients and another 35, who underwent open nephroureterectomy at their department. In the laparoscopic group, the blood lost was significantly less (242 versus 696 mL). Postsurgically, patients in the laparoscopic group had a significantly more rapid recommencement of ambulation (1.4 versus 2.5 days), oral intake (1.6 versus 3.2 days), shorter hospital stay (2.3 versus 6.6 days), decreased analgesic necessities (26 mg morphine sulfate equivalent versus 228 mg), and a more rapid period of recovery (8 versus 14.1 weeks). Complications occurred in 5 (12%) and 10 (29%) patients in the laparoscopic and open groups, respectively. These complications integrated 1 renal vein injury, 1 patient with fluid extravasations from mobilization of the bladder cuff, and 3 patients with atelectasis in the laparoscopic group. The open group had 4 patients with atelectasis, 5 patients with postoperative ileus, and 1 patient with a pneumothorax. Two cases required an open conversion because of a renal injury and an elective conversion secondary to local tumor infiltration with obliteration of tissue planes near the hilum.

The mean pathologic grade was 2.3 for both of the groups, with the laparoscopic group having 9, 10, and 23 patients with grades 1, 2, and 3 tumors and the open group having 6, 10, and 16 patients with grades 1, 2, and 3 tumors, respectively. Surgical margins were positive in 3 (7%) patients in the laparoscopic group and 5 (15%) patients in the open group. All 3 patients in the laparoscopic group received systemic chemotherapy postoperatively, and pulmonary metastases developed in 1 patient during follow-up. For comparable stage and grade of primary tumor, the negative surgical margin rate was similar between the 2 groups. The two groups of laparoscopic and open surgeries have no difference as regarding the bladder recurrence (23 versus 37%), retroperitoneal or port site/incisional recurrence (0 versus 0%), or distant metastases (8,6 versus 13%). There was no difference in either cancer-specific survival (97% versus 87%) or crude survival (97% versus 94%) after adjusting for the shorter follow-up period (11 versus 34 months) between the laparoscopic and open groups, respectively, during follow-up. Mortality occurred in 2 patients (6%) of the laparoscopic group and in 6 of the open group (30%). The authors cannot estimate whether these mortality rates are significantly different or equivalent [12]. The results of the trails that compare laparoscopic treatment with open surgery are summarized in Table 1. The techniques of laparoscopic retroperitoneal nephroureterectomy and partial nephrectomy are shown in Figures 1(a), 1(b), and 1(c) and in Figure 2, respectively. Patients are placed in the full flank position. Usually, the operating table is flexed and the kidney rest is elevated, thereby increasing the space between the iliac crest and the lower ribs. Retroperitoneal access is obtained through a small 10- to 15-mm incision just below and medial to the tip of the 12th rib (Figure 1(a)). The muscle and fascia are separated using a blunt instrument that allows one finger to develop a working space posterior to the kidney above the psoas muscle (Figure 1(b)). Often the lower pole of the kidney is immediately palpated. The colon is separated away from the anterolateral abdominal wall with the index

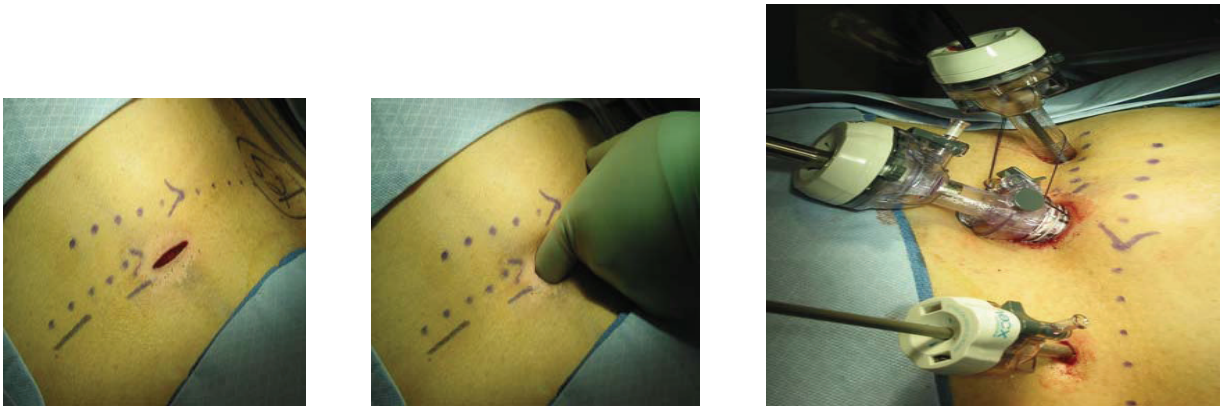

(a) (b) (c)

Figure 1: (a) Access for a right retroperitoneal laparoscopic radical nephrectomy (LRN). A 10- to 15-mm incision is made below and medial to the tip of the 12th rib. (b) The flank muscles are pierced with a blunt-tipped instrument followed by finger dissection and development of the retroperitoneum space to permit trocar placement. (c) Trocar placement for a right retroperitoneal LRN.

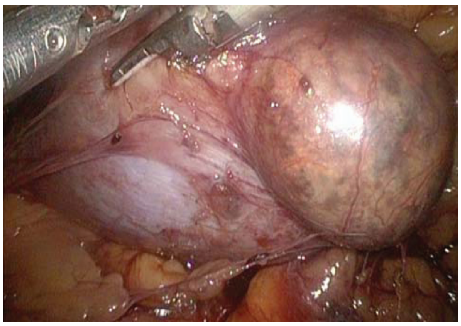

Figure 2: Retroperitoneal laparoscopic left partial nephrectomy.

finger. Additional trocars are placed below the 12th rib just above the psoas muscle posteriorly, and then more anteriorly through the lateral abdominal wall under direct vision using the laparoscope (Figure 1(c)). Laparoscopic partial nephrectomy is ideal for a patient with an exophytic, small, and peripherally located renal tumor (Figure 2).

The literature research discovered similar effects in transperitoneal laparoscopic nephroureterectomy [13, 24]. The familiarity with anatomic landmarks and a larger working space are some advantages of transperitoneal approach compared to retroperitoneal one. The retroperitoneal approach, however, has distinct advantages, for example, permittance of early control of the renal artery and vein, no manipulation of the bowel leading to less incidence of ileus and possibly a shorter hospital stay, and confinement of possible urinomas or seromas to the retroperitoneal space [12, 25].

2.2. Hand-Assisted Laparoscopic Nephroureterectomy. Apart from standard laparoscopic nephroureterectomy among urologists, hand-assisted laparoscopic nephroureterectomy is also an acceptable technique [18, 20]. Patient preparation and positioning is identical to that described for transperitoneal LRN (laparoscopic nephroureterectomy). The hand-assisted LRN technique usually begins with a 6 cm to 8 cm incision for hand-port placement through a lower quadrant Gibson-type incision (Figure 3(a)) or through the lower midline abdomen (Figure 3(b)). The Kawauchi et al.'s [18] experience was described in 34 consecutive patients who underwent hand-assisted laparoscopic nephroureterectomy using a Lap Disc (Hakko Shoji, Tokyo, Japan). Those 34 patients were compared with the previous group of 34 patients who underwent open nephroureterectomy. Mean follow-up was 13.1 months in the hand-assisted group and 48.8 months in the open group [18]. In the hand-assisted group, there was observed a similar operative time (233 versus 236 minutes), decreased analgesia frequency (2.1 versus 4.1 days), decreased blood loss (236 versus 427 mL), quicker return to ambulation (1.5 versus 2.5 days), and shorter hospital stay (13 versus 21.1 days). In the Japanese series compared with the American ones, the lengthy stay is a social issue and not reflective of actual patient recovery. There were 4 (12%) complications in both groups, with 1 open conversion in the hand-assisted group. The 4 complications in the hand-assisted group include 1 conversion due to bleeding from the left adrenal gland, 2 wound infections, and 1 pulmonary infarction in a patient who recovered with conservative treatment [18]. As regarding the histological tumor grade, the pathologic studies have revealed that in the hand-assisted group there were 5, 20, and 9 patients with grades 1, 2, and 3 tumors, whereas in the open group there were 4, 17, and 13 patients with grades 1, 2, and 3 tumors, respectively. Recurrence rate was 12% (4 patients) in the hand-assisted group, with a mean time to recurrence of 9.5 months. Patients in the open group had a longer mean time to recurrence at 14.4 months, with a 47% (16 patients) recurrence rate [18].

Seifman et al. [26] completed a prospective study comparing 16 patients (mean follow-up, 19 months) who underwent hand-assisted laparoscopic nephroureterectomy

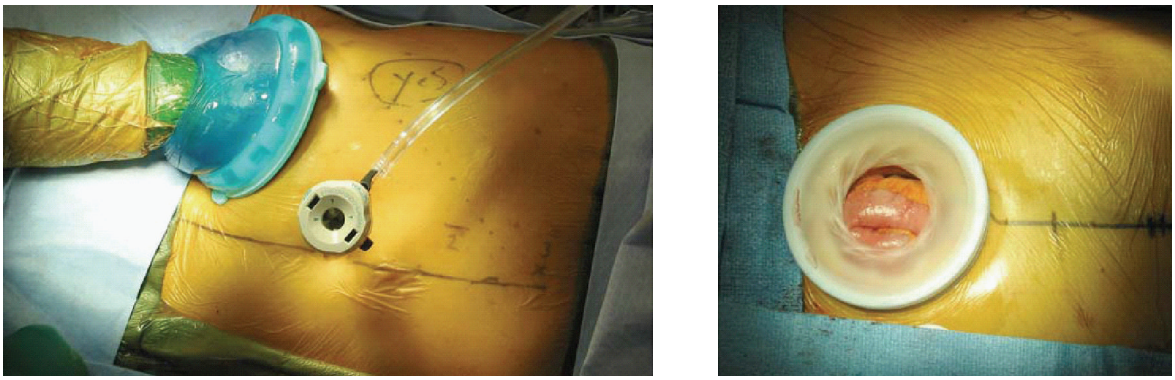

(a) (b)

Figure 3: (a) Right lower quadrant hand-port placement for hand-assisted right radical nephrectomy, and (b) Lower midline hand-port placement for hand-assisted right radical nephrectomy.

to 11 patients (mean follow-up 16 months) who underwent the open technique. Despite the fact that the operative time was longer in the hand-assisted group (320 versus 199 minutes), there was a decrease in the length of hospital stay (3.9 versus 5.2 days), time to oral intake (33 versus 38 hours), analgesic requirements (20 versus 31 tablets), and return to normal activity (18 versus 38 days). Tumor recurrence appeared in 3 of 16 laparoscopic cases and in 7 of 11 open cases. However, the open series had a higher number of patients with grade 3 (6 of 11) and T3 disease (5 of 11) compared with the laparoscopic group (5 of 16 with grade 3, 3 of 16 with T3 disease).

Landman et al. [20] compared 16 patients who underwent hand-assisted laparoscopic nephroureterectomy to 11 patients who underwent a standard one. In the standard group, the mean follow-up was 27.4 months, whereas in the hand-assisted group it was 9.6 months. Compared with the standard technique, patients who underwent the hand-assisted technique had a decreased operative time (4.4 versus 5.3 hours), similar blood loss (201 versus 190 mL), longer time to oral intake (20 versus 13 hours), similar analgesic use (33 versus 29.3 mg of morphine), longer hospital stay (4.5 versus 3.3 days), and longer time to complete recovery (8 versus 5.2 weeks).

Complications occurred in 5 patients in both groups, with 1 open conversion in the hand-assisted group due to failure to progress. Myocardial infarction and respiratory failure was the cause of death postoperatively for a patient in the hand-assisted group. Pathologic stage and grade were similar in the 2 groups, with the majority of patients having low-grade and low-stage tumors. Metastatic disease developed in 3 out of 15 hand-assisted cases and in 2 patients of the standard group [20].

The results of the trails that compare hand-assisted laparoscopic nephroureterectomy with other techniques are summarized in Table 2. Thereafter, these studies sustain the utility of both hand-assisted and pure laparoscopic techniques for nephroureterectomy. The hand-assisted technique has the advantage of the tactile sensation and blunt-manual dissection. The probability of cancer control is similar to open techniques. However, due to the fact that most of the studies were current, long-term action—a five-year period—is required for definitive results.

2.3. Robotic-Assisted Laparoscopic Management of Upper Urothelial Tract TCC. The daVinci robotic surgical system has revolutionized minimally invasive urologic laparoscopy as applied to prostatectomy. By providing a three-dimensional operating environment and instrumentation with two additional degrees of freedom, the daVinci surgical system appears to have dramatically reduced the learning curve for complex-laparoscopic procedures. Even laparoscopically inexperienced open surgeons can become remarkably talented in a technically challenging procedure such as robotic radical prostatectomy in as few as 12 patients [27].

Since there are not any studies regarding the robotic-assisted laparoscopic management of upper urothelial tract carcinoma, we analyze the papers of robot-assisted laparoscopic partial nephrectomy and we believe that the technique will be soon applicable for small lesions of renal pelvis and upper ureter.

The first series of robot-assisted laparoscopic partial nephrectomy (RLPN) for small renal masses was reported by Gettman et al. [28]. Since then, there have been five other reports, three of which detail the New York University experience [29–33]. The results of the last trail conducted by Deane et al. [33] as regarding the mean tumor size, the mean total procedure time, the mean estimated blood loss, and the mean warm ischemia time are similar to those analyzed in the previously reported series, and by comparing them with laparoscopic partial nephrectomy (LPN), there were no differences. Moreover, in this cohort there were no conversions, while in the New York University series, among 12 patients, there were two conversions: one to a hand-assisted approach and one to an open approach [30]. In the series of Kaul et al. [32], like in that of Deane et al. [33], there were no conversions; however, a patient had urgent re-exploration and nephrectomy. These studies are summarized in Table 3.

Table 2: Studies that compare hand-assisted laparoscopic nephroureterectomy with other techniques.

Study	No. of patients	Tumor grade	Follow-up	Outcomes
Kawauchi et al. [18]	34 in HALN 34 in OS	24 patients in HALN arm and 25 in OS arm grade II	13.1 months in HALN,48.8 in OS	TTR for HALN 9.5 months with RR 12% TTR for OS 14.4 months with RR 47%
Seifman et al. [26]	16 in HALN 11 in OS	12 patients in HALN arm and 9 in OS grade II tumors	19 months in HALN,16 in OS	TR for HALN in 3 patients and for OS in 7 patients
Landman et al. [20]	16 in HALN 11 in LN	13 patients in HALN arm and 8 in LN arm grade III tumors	9.6 months in HALN,27.4 in LN	HALN decreases operative time without significantly altering short-term parameters of convalescence

HALN: hand-assisted laparoscopic nephroureterectomy, LN: laparoscopic nephroureterectomy, OS: open surgery, TTR: time to recurrence, RR: recurrence rate, TR: tumor recurrence.

RLPN using the daVinci surgical system can be performed by a fellowship of trained urologic oncologists with extensive experience in robotic radical prostatectomy; early results mirror those achieved by experienced laparoscopic surgeons performing standard LPN. These results can further support the assumption of introducing a robotic interface which provides surgeons with extensive experience in open and other robotic procedures (in this instance, open partial nephrectomy and robot-assisted radical prostatectomy), with the successful incorporation of advanced robotic procedures, such as partial nephrectomy, into their clinical practice.

2.4. Management of Distal Ureter and Bladder Cuff. While there is a negligible disagreement about the role of laparoscopic nephroureterectomy, the management of the distal ureter and bladder cuff with laparoscopy varies among the surgeons. Techniques include (1) open excision, (2) transvesical laparoscopic detachment and ligation technique, (3) laparoscopic stapling of the distal ureter and bladder, and (4) the "pluck" technique. Steinberg and Matin have recently reviewed these techniques [21].

2.4.1. Open Technique. An open technique involves initial dissection of the renal unit laparoscopically. After its completion, the ureter is clipped but not ligated to avert potential downstream seeding of tumor cells. Once the laparoscopic ports are separated, either a midline, Gibson, or Pfannenstiel incision is performed. The distal ureter is identified and dissected towards the bladder. The specimen is then isolated en bloc with a border of bladder cuff. The bladder may be opened and the ureter dissected intravesically and extravesically, or secured and the full dissection performed extravesically.

Matsui et al. [22] reported their results in 17 patients who underwent laparoscopic nephroureterectomy using an open technique to remove the distal ureter and bladder cuff. A comparison with another 17-patient group who underwent standard nephroureterectomy was performed. The mean follow-up was 8.8 months in the laparoscopic group and 23.0 months in the standard group. Patients who were in high risk and had good performance status had received adjuvant chemotherapy postoperatively. In the laparoscopic group, 1, 6, and 10 patients had grades 1, 2, and 3 diseases on final pathologic examination. The standard group had 0, 6, and 11 patients with grades 1, 2, and 3 diseases on final pathologic examination. T3 disease was found in 5 patients in both groups with the rest of patients having T2 or lower disease. Three patients in the laparoscopic group and four in the standard group, respectively, had received adjuvant chemotherapy. The recurrence was observed only in a patient in the laparoscopic group, in comparison to six in the standard group, but that could be attributed to the shorter follow-up of the laparoscopic group. After adjusting to that difference in follow-up, there were no significant differences in the disease-free survival rate between the 2 groups [22].

Klingler et al. [16] also reported on 19 patients who underwent laparoscopic nephroureterectomy; mean follow-up 22.1 months, with an open approach to remove the distal ureter and bladder cuff. The comparison was made to 15 patients who underwent standard nephroureterectomy, mean follow-up 23.1 months. According to the T stage, there were 12 patients with T1 versus 10, 2 patients with T2 versus 2, and 5 with T3 versus 3 in the laparoscopic and standard groups, respectively. Tumor recurrence was observed in a patient in both groups who had grade 3 and T3 disease. This study also concluded that the risk for tumor recurrence and cancer control rates was similar between the standard technique and the laparoscopic group with an open technique of handling the distal ureter and bladder cuff.

2.4.2. Transvesical Laparoscopic Technique. Gill et al. [23] have used a transvesical laparoscopic technique to remove the distal ureter and bladder cuff. That was performed by using 2 needlescopic ports placed suprapubically into the bladder under cystoscopic guidance. The patient was repositioned into the dorsal lithotomy position before placing the bladder ports. A ureteral catheter was then placed in the ipsilateral orifice through an endoloop that was passed through the laparoscopic bladder ports. A grasper was used to tent the

Table 3: Studies for robotic-assisted laparoscopic nephrectomy.

Study	No. of patients	Conversions	Follow-up	Outcomes
Gettman et al. [28]	13	1 to LN	13 months	RALN is feasible and safely performed
Phillips et al. [30]	12	2 one to HALN and 1 to OS	12 months	RALN is safe, feasible, and reproducible
Caruso et al. [31]	10	1 to LN	12 months	RALN safe and feasible procedure in patients with small exophytic masses
Kaul et al. [32]	10	No conversions	15 months	RALN is a viable alternative to LN for patients with small exophytic masses
Deane et al. [33]	10	No conversions	16 months	No difference between RALN and LN as regarding PT,IBL and MWIT

RALN: robotic-assisted laparoscopic nephrectomy, LN: laparoscopic nephrectomy, OS: open surgery, PT: procedure time, IBL: intraoperative blood loss, MWIT: mean warm ischemia time.

ureter anteriorly and a Collins knife to dissect the bladder cuff and ureter. The intramural ureter and bladder cuff were completely detached en bloc from the bladder. The dissection continued with the Collins knife into the pelvic extraperitoneal fatty tissues.

Gill et al. [12] compared 42 patients who underwent that technique to 35 patients who underwent the standard open nephroureterectomy. That study-case was discussed earlier in this study and as a conclusion the patients had comparable cancer-specific survival and tumor recurrence. The follow-up, however, was shorter for patients who underwent the transvesical laparoscopic technique.

Stifelman et al. [34] have also reported using a combined transvesical laparoscopic and endourologic technique on 22 patients with an average follow-up of 13 months. The pathologic examination has revealed that 3, 10, and 9 patients had grades 1, 2, and 3 tumors. Five lesions were Ta, 8 were T1, 2 were T2, and 7 were T3 disease. In all cases, the margins were negative. Disease recurrence was observed in six patients: four with low grade, low-stage bladder tumors, not involving the resection site, and two with grade III T3 tumors who presented later with metastatic lesions. All patients were alive at 18 months. This technique simulates established open principles for upper tract urothelial tumors. Potential criticisms of this technique are the risk of fluid extravasation and subsequent potential tumor seeding. This is minimized, however, by continuous suction from the transvesical ports. Furthermore, a meta-analysis of the literature reveals no reports of tumor seeding in over 50 patients to date [12, 21, 23, 34, 35]. In cases in which tumor is presented in the distal and intramural ureter, active bladder disease exists, and in patients who have received prior pelvic radiation therapy this technique is contraindicated.

2.4.3. Laparoscopic Stapling Technique. Laparoscopic stapling of the distal ureter and bladder cuff has been combined with cystoscopic unroofing [13, 21]. With this procedure, ureteral unroofing is performed initially via cystoscopy and placement of a balloon catheter in the intramural ureter. The distal ureter and bladder cuff are then stapled laparoscopically during the distal dissection, using an Endo-GIA (US Surgical, Norwalk, Conn, USA) stapler.

Shalhav et al. [13] reported their experience using the laparoscopic stapling technique in 25 patients who underwent laparoscopic nephroureterectomy and compared them with 17 patients who underwent open radical nephroureterectomy. A patient in the laparoscopic group underwent the "pluck" technique, which will be discussed later in this review. Mean follow-up was shorter in the laparoscopic group (24 versus 43 months). Thirteen patients in both groups had grade 2 disease or greater. Distal metastases developed in 4 patients (31%) in the laparoscopic group and 3 patients (23%) in the open group. In the laparoscopic group, local recurrence rate was lower, 3 versus 7, but this could be attributed to a shorter follow-up. All patients with recurrence in the laparoscopic group had tumors that recurred in the bladder and were treated with transurethral resection. The authors argue in this series that the stapling technique minimizes the risk of tumor spillage, since the bladder cuff just caudal to the ureter is secured and occluded with six rows of titanium staples before it is incised.

Yoshino et al. [37] also reported their experience with 23 patients using flexible endoscopic gastrointestinal automatic stapler (Ethicon Endosurgery, Cincinnati, Ohio, USA) in their laparoscopic series. At a mean follow-up period of 15 months, 4 patients had bladder recurrence which was successfully treated by transurethral resection. Three of those patients had no evidence of disease at greater than a 20-month-follow-up, whereas 1 died of other medical comorbidities.

While the previous studies support the use of the stapling technique for distal ureteral and bladder cuff management, Matin and Gill [35] evaluated outcome and patterns of recurrence based on the form of bladder cuff control. They concluded that positive margins were higher with a

Table 4: Studies that compare techniques for the management of distal ureter end bladder cuff with other methods of treatment.

Study	No. of patients	Tumor grade	Follow-up	Outcomes
Open technique				
Matsui et al. [22]	17 in OT 17 in SN	14 patients OT arm and 13 in SN arm grade III	8.8 months in OT and 23 months in SN	No difference in DFS
Klingler et al. [16]	19 in OT 15 in SN	15 patients in OT and 13 in SN arm grade II	21.1 months in OT and 23.1 months in SN	CCR and RTR similar in both arms
Transvesical laparoscopic technique				
Gill et al. [12]	42 in LT 35 in SN	34 patients in LT arm and 28 in OS arm III tumors	11.1 in LT and 34.4 months in SN	CSS and TR comparable in both arms
Laparoscopic stapling technique				
Shalhav et al. [13]	25 in LT 17 in SN	21 patients in LT arm and 14 in OS arm grade II	24 months LT 43 months SN	RTR lower in LT
The "pluck" technique				
McNeill et al. [36]	25 in PT 42 in SN	18 patients in PT arm grade II and 36 patients in SN arm grade III	32.9 months PT 42.3 months SN	No difference in TR

SN: standard nephroureterectomy, OT: open technique, CCR: cancer control rate, RTR: risk of tumor recurrence, CSS: cancer specific survival, TR: tumor recurrence, ORN: open radical nephroureterectomy, PT: "pluck" technique.

laparoscopic stapling approach than either the open or the transvesical technique. Additionally, the stabling technique was associated with poorer recurrence-free survival.

The theoretical risk of stone formation, secondary to the migration of staples into the bladder mucosa, could be an additional animadversion of this technique. Chandhoke et al. [38] reported that there was neither stone formation nor visible staples in the bladder after using the stapling technique. A recent case report revealed the presence of a nearly complete intravesical titanium staple line on surveillance cystoscopy at a follow-up of 6 months [39]. However, there was no identifiable encrustation in that patient, and a successful transurethral resection of the staple line was performed without sequela.

2.4.4. The "Pluck" Technique. The "pluck" technique involves an aggressive transurethral resection of the ipsilateral ureteral orifice with a simultaneous "plucking" of the distal ureteral during the laparoscopic procedure. Before the resection of the renal unit and ureter, this resection is performed initially via a resectoscope. McNeil et al. [36] treated 25 patients using that technique and compared them with 42 patients who underwent open nephroureterectomy. In the laparoscopic group, the follow-up was shorter mean 32.9 versus 42.3 months. According to tumor grade, in the laparoscopic group, there were 4, 6, and 9 patients with grades 1 and 2, while in the open group there were 2, 8, and 6 patients with grade 3. Pathologic examination also revealed T1, T2, and T3 diseases in 0, 1, and 9 patients in the laparoscopic group and 0, 3, and 6 patients in the open group. Four deaths in the laparoscopic group and nine in the open group were observed. The authors concluded that there was no increase in local recurrence within the laparoscopic group during the follow-up, but the exact incidence of recurrence was not reported. The studies that compare the techniques of the management of distal ureter and bladder cuff with other methods of treatment are summarized in Table 4.

The major criticism of that technique is tumor seeding and the potential to leave behind a segment of an incompletely resected ureter [21, 40–42]. Arango et al. [40] described a case of a fatal recurrence at the resection site after endoscopic resection of the intramural ureter. The patient had stage 1 grade 2 transitional cell carcinoma with a normal lower ureter and bladder. Nevertheless, seven months later, the patient presented with pelvic pain and urgency. Computed tomography revealed a large vesical mass at the site of the resected lower ureter. The biopsy showed a grade 3 tumor stage IV and the patient underwent salvage cystectomy with adjuvant chemotherapy. Three months after cystectomy the patient died. The exact incidence of tumor seeding is unknown and difficult to assess. On the other hand, the theoretical potential combined with the above reports has led some authors to abandon this technique [40–42].

To summarize, laparoscopic nephroureterectomy with open distal ureterectomy is a safe and acceptable alternative to open nephroureterectomy. Cancer control rates seem to be similar with superior convalescence. In terms of managing the distal ureter and bladder cuff, the open technique is the most efficacious so as to achieve negative margins and decreased risk of cancer seeding. However, because of the relatively small series in the literature (due to the low incidence and prevalence of the disease) and because most

literature is fairly recent (due to recent advances), long-term follow-up and larger series are necessary to assess cancer-specific survival and recurrence rates.

3. Endoscopic Management

Generally, recommendations for endoscopic management of upper-tract TCC include patients with anatomic or functional solitary kidneys, bilateral upper-tract TCC, base line renal insufficiency, or significant comorbid diseases that preclude abdominal surgery [43]. Patients with a normal contralateral kidney who have small, low-grade lesions can also be reasonable candidates for conservative management [44]. Endoscopic treatment of the upper urinary tract can be performed via either a retrograde ureteroscopic or a percutaneous antegrade approach.

As regarding the retrograde ureteroscopic, an approach can be used for low-volume ureteral and renal pelvic tumors. Proximal ureter and renal pelvic lesions require flexible ureteroscopes, while tumors localized in the intramural and distal ureter are best managed by rigid ureteroscopy [45]. Low morbidity in association with maintenance of urothelial integrity is the principal advantage of retrograde endoscopy [43, 45, 46]. This technique is limited, however, by the size of instruments that can be accommodated in the ureter, which in turn limits the size of tumor that can be adequately treated. Some portions of the upper urinary tract, such as the lower pole calyces, are less accessible by a retrograde approach. Furthermore, retrograde ureteroscopy differs in patients who have undergone a prior urinary diversion.

An initial biopsy of the lesion is required for the ureteroscopic method followed by a debulkment to its base using cold-cup forceps (3 Fr or 5 Fr) or a stone basket (1.9 Fr or 2.4 Fr) [45]. Due to the fact that the wall of the proximal ureter and renal pelvis is thin, no attempt should be made to resect these regions deeply. The base of the lesion is subsequently addressed by monopolar electrocautery or laser ablation (neodymium: yttriumaluminum-garnet [Nd:YAG] or holmium [Ho]: YAG laser) [47]. With a tissue penetration of less than 0.5 mm, the Ho:YAG laser is well suited for use in the ureter, allowing for excellent hemostasis with minimal transmural thermal damage. Conversely, the Nd:YAG laser has a deeper penetration (5-6 mm) making it better suited for coagulative necrosis of large lesions, particularly in the renal pelvis [46].

Ureteral perforation and postoperative strictures are the principal complications associated with retrograde ureteroscopy. The incidence of perforation in most series is below 10% and is readily managed by ureteral stenting or percutaneous nephrostomy drainage [48, 49]. The reported stricture rate following retrograde management of upper-tract TCC ranges from 4.9% to 13.6% [48–50]. Literature data indicate that a lower incidence of strictures is associated with lesions managed by laser ablation, rather than with electrocoagulation [51]. Most postoperative strictures are successfully managed by endoscopic stenting, laser incision, or balloon dilatation. Ultimately, all ureteroscopic interventions should be followed with short-term ureteral stenting to prevent postoperative obstructive sequelae.

Nevertheless, being more invasive than retrograde ureteroscopy, the percutaneous antegrade approach is preferred in larger tumors of the renal pelvis and proximal ureter. Antegrade nephroscopy offers better visualization of the renal pelvis whereas accommodating larger caliber working instruments, being able to handle a larger tumor burden. The percutaneous approach also allows for superior access to the lower pole calyces, as well as to renal units with complicated calyceal anatomy. The principal disadvantage of this approach is violation of urothelial integrity with reports of tumor seeding of nonurothelial surfaces around the kidney or in the nephrostomy tract [52, 53]. Larger series, however, fail to note such tract recurrences, confirming that this phenomenon is uncommon [54–56].

After a percutaneous tract that can accommodate a 30 Fr access sheath is subsequently established, the lesion is initially biopsied and consequently debulked. Due to the larger access tract, antegrade techniques permit the use of cold-cup biopsy forceps through a standard nephroscope or a cutting loop from a resectoscope. The base of the lesion is resected and sent separately for staging purposes, and haemostasis is achieved by electrocautery or laser ablation as previously described. The established nephrostomy tract can be maintained, allowing for repeated treatment or administration of topical adjuvant therapy [45, 46].

Away from tumor tract seeding, complications of percutaneous management of upper-tract TCC are similar to those of percutaneous stone procedures and include bleeding, infection, electrolyte abnormalities, adjacent organ injury, and pleural injury [45, 46].

The safety and efficacy of ureteroscopic management of upper-tract TCC are confirmed by multiple studies. In 1997, Tawfiek and Bagley reported on the outcomes of 205 patients summarized from 14 modern series and found a recurrence rate of 33% for 61 renal pelvic tumors and 31% for 144 ureteral tumors [57]. More recent reviews demonstrate similar findings, with recurrence rates ranging from 31% to 65% and disease-free rates of 35% to 86% [47, 49, 58–62]. The bladder was the most frequent site of recurrence in these series. Tumor recurrence was most dependent upon pathologic grade with recurrence rates of 25% for grade I tumors and almost 50% for higher-grade lesions [48]. It is important to note that initial endoscopic management does not predict a worse outcome if disease progression occurs. Boorjian and colleagues reported that ureteroscopic tumor ablation before nephroureterectomy did not adversely affect postoperative disease status [63].

As regarding the percutaneous approaches, they have promising results when taking into consideration that these lesions are more substantial than those managed by retrograde ureteroscopy. Okada et al. performed a review in 84 patients and found an overall recurrence rate of 27%, with tumor grade strongly predicting outcomes [64]. Additionally, Rouprêt et al. reported a similar recurrence rate of approximately 30%, with 5-year disease specific survival of almost 80% [65]. Moreover, Lee et al. reviewed their 13-year experience with percutaneous management of upper-tract TCC patients and found no significant differences in overall survival compared with those patients who underwent a

nephroureterectomy [66]. Regardless of treatment modality, patients with low-grade lesions did well, while those with high-grade tumors were predisposed to tumor recurrence and progression.

The recommended follow-up of patients treated for upper-tract TCC should consist of interval history and physical examination, urinary cytology, and surveillance cystoscopy every 3 months for the first 2 years after treatment, every 6 months for the next 2 years and yearly thereafter if the patient is free from disease recurrence [46, 67]. Radiographic studies including chest X-ray and abdominopelvic CT should be performed every 6 months for the first 2 years and yearly thereafter. Ipsilateral endoscopy for patients who undergo organ-sparing treatment should occur every 6 months for the first 2-3 years and yearly thereafter, provided that the patient is disease free. Bone scans should only be performed for symptoms of bone pain or for an elevated alkaline phosphatase level.

4. The Prognostic Value of Lymphadenectomy in Patients with Muscle Invasion

Patients with muscle-invasive transitional cell carcinoma of the upper urinary tract are at high risk of nodal metastasis, and the prognosis may be extremely poor in the case of nodal involvement [68, 69].

The impact of lymph node dissection on clinical outcomes is reported only in few papers. Komatsu et al. [68] evaluated a limited cohort of 36 patients and suggested that lymph node dissection may provide a therapeutic benefit by selecting patients with lymph node metastasis as candidates for adjuvant therapy. Miyake et al. [70] reported on 72 patients with transitional cell carcinoma of the upper urinary tract. 35 of those had undergone total nephroureterectomy and regional lymphadenectomy. Lymph node dissection was associated with an increased cancer-specific survival in patients with no evidence of lymph-vascular invasion. On the other hand, in patients with evidence of lymph-vascular invasion who were considered at higher risk of micrometastatic disease, no additional prognostic advantages were provided by lymph node dissection.

In contrast, no data is available on the extent of lymph node dissection in patients with invasive transitional cell carcinoma of the upper urinary tract.

Recently, Brausi et al. [71] showed that in patients with muscle-invasive transitional cell carcinoma of the upper urinary tract, disease-free survival and cancer-specific survival were significantly higher in patients who had retroperitoneal lymph node dissection in conjunction with nephroureterectomy than in patients who did not undergo lymph node dissection. They recommended that an accurate and extended lymph node dissection can be curative in patients with advanced transitional cell carcinoma of the upper urinary tract. Nevertheless, they did not analyze the impact of the number of removed lymph nodes on clinical outcome.

Roscigno et al. [72] first tested the role of lymph node dissection on disease-free survival and cancer-specific survival. They observed 132 consecutive patients with muscle-invasive transitional cell carcinoma of the upper urinary tract who underwent radical surgery. Lymph node dissection was performed in 95 cases. Patients were stratified according to the presence of lymph node dissection and lymph node status.

They concluded that patients undergoing lymph node dissection at the time of radical surgery had a significantly better prognosis, contrary to those managed with tumor excision only, even though, in the group of patients undergoing lymph node dissection, about 1/4 (26 patients) had nodal metastases. Then, they analyzed the clinical outcome, according to nodal status. They observed that the prognosis of patients who did not receive lymph node dissection (pNx) was significantly worse than that of pN0 patients, whereas, interestingly, both disease-free survival (DFS) and cancer-specific survival (CSS) of pNx patients were comparable to those of pN+ patients. This was confirmed at multivariable analysis, where lymph node status emerged as a significant predictor of DFS and CSS after accounting for age at diagnosis, T stage, G grade, CIS (cancer in situ), LVI (lymph-vascular invasion), year of surgery and postoperative chemotherapy.

These data are in contrast with those presented by a recent paper of Brown et al. [73], showing that survival of Nx and N0 patients is similar and significantly higher than N+ patients. On the other hand, the M. D. Anderson series evaluated superficial tumor also, whereas in this series only muscle-invasive transitional cell carcinomas were considered. Probably in their population a higher percentage of pNx patients could have had positive nodes if lymph node dissections were performed.

Finally, these results suggest for the first time that the number of lymph nodes removed and examined, related to the extent of lymph node dissection, seems to play a significant role in predicting clinical outcome after radical surgery. In fact, even when only the subset of patients managed with lymph node dissection was analyzed, the number of lymph nodes removed and examined emerged, both in invariable and multivariable analyses, as a significant predictor of DFS and CSS, independently from the evidence of nodal metastases. A better clinical outcome was observed in those patients in whom at least six lymph nodes had been removed and examined [74].

5. Adjuvant Therapy

5.1. Immunotherapy. More than one third of the patients with endoscopically treated upper tract TCC will develop tumor recurrence [46]. In order to reduce recurrence rates, adjuvant topical immunotherapy or chemotherapy can be used. There are several methods to perform an instillation: by infusion through a percutaneous nephrostomy tube, via a retrograde ureteral catheter, or by retrograde reflux from the bladder with an indwelling double-J stent, or by surgical creation of ureteral reflux. The aim of the treatment is a continued exposure of the urothelium to the topical agent while maintaining a low-pressure system that is free of infection. These approaches minimize major complications

such as sepsis, although granulomatous changes in the kidney and systemic adverse effects relating to bacillus Calmette-Guerin (BCG) infection can occur [75, 76].

The same agents used to treat urothelial carcinoma of the bladder can be used to treat tumorsof the upper tracts. The most common agents instilled are BCG or mitomycin-C.

As regarding the specific role of upper tract immunotherapy and topical chemotherapy, there are few reports in the literature. Thalmann et al. [77] reported on 41 renal units treated in 37 patients with BCG (Bacillus Chalmette-Guerin) via percutaneous nephrostomy tube with a mean follow-up of 44 months. For carcinoma in situ (CIS), there were treated 25 renal units and another 16 received adjuvant BCG therapy for superficial tumors in 15 patients. In this study no tumor seeding occurred along the nephrostomy tract. Indications for treatment in this study included solitary renal units, renal insufficiency, bilateral disease, and inoperable disease. Among the patients with CIS, 9 died of disease (41%), 6 died of other causes (27%), and 7 are alive at a median follow-up of 50 months (32%). Median overall survival and time to recurrence were 44 and 25 months, respectively. Fifteen patients with papillary disease of the urinary tract in 16 renal units were treated (TaG1 in 2, TaG2 in 6, TaG3 in 2, T1G3 in 2, and Tx in 4). Overall survival was 40 months (range of 1–59). Thirteen patients (87%) had recurrence after a median interval of 10 months (range of 1–69) and progression after a median interval of 11 months (range of 5–27). Among the 15 patients, 4 are alive, 6 died of disease, and 5 died of other causes with tumor present in the upper urinary tract.

The authors concluded that papillary and solid tumor recurrences of the upper urinary tract could not be prevented with BCG therapy. However, BCG therapy did provide cure in approximately 50% of renal units with CIS. Several other studies also support the use of BCG for upper tract CIS [78–83].

Vasavada et al. [84] also reported on the use of BCG in the adjuvant setting for upper tract urothelial tumor. After surgical resection for upper tract transitional cell carcinoma in eight patients, they received adjuvant BCG therapy. Grades 1, 2, and 3 diseases were present in 2, 5, and 1 patients, and Ta, T1, and T2 diseases occurred in 5, 2, and 1 patients in this cohort. At a mean follow-up of 23.8 months, 5 out of 8 patients (62.5%) were disease free, 2 out of 8 patients (25%) died of disease, and 1 out of 8 (12.5%) was alive with metastatic disease and receiving systemic chemotherapy.

Although the study number was small, the authors concluded that the application of BCG after definitive resection of the primary tumor may result in a decreased incidence of local tumor recurrence.

To our knowledge, there has not been any randomized, prospective, placebo-controlled trial specifically addressing the effectiveness of topical immunotherapy or chemotherapy for adjuvant treatment of upper tract urothelial tumors [77–85]. Until such studies become available, adjuvant therapy may be used in patients undergoing nephron-sparing management of upper tract transitional cell carcinoma with their consent and the addition of a strict surveillance protocol.

5.2. Radiation Therapy and Systemic Chemotherapy. The fact that the transitional cell carcinoma of the upper urinary tract is relatively rare has led to a scarcity of studies that analyze adjuvant radiation therapy and chemotherapy for locally advanced but completely resected upper tract urothelial tumors. When the tumor extents beyond the muscular, the 5-year-survival rates will be between 0% and 34% [5, 9, 86, 87]. The loco-regional recurrence at 5 years after treatment with definitive surgery, when no adjuvant chemotherapy was given, has been reported at several studies between 45% and 60% [88–90]. This high recurrence rate has been a strong argument for adjuvant therapy for all patients with locally advanced disease even after complete resection.

However, all recent studies count on limited numbers of patients because of the rarity of this disease. Some researches have supported [88, 89, 91] the role of adjuvant radiation treatment on upper tract urothelial malignancies and others have rejected it [92, 93]. The role of adjuvant chemotherapy alone for transitional cell carcinoma also remains controversial [94].

Maulard-Durdux et al. [92] reported their experience on postsurgical irradiation in 26 patients with upper tract tumors after complete resection. 11 patients had stage B disease (muscular invasion) 42% and 15 patients had stage C disease (periureteral fat invasion) 58%. According to tumor grade, 10 patients had grade 2, 40%, 15 had grade 3, 60%, and it was unknown in a patient. The radiation therapy dose was 45 Gy in all patients. After a mean follow-up of 45 months, 13 patients (50%) were alive, with 11 patients being disease free. Disease metastasized in 14 patients to the bone, liver, and lungs. The overall 5-year-survival rates and 5-year survival with no evidence of disease were 49% and 30%, respectively. The authors concluded that adjuvant radiation therapy did not improve long-term survival and is only recommended for prospective randomized studies.

A recent review of selected series of surgery with or without adjuvant radiation therapy for carcinoma of the upper urinary tract revealed some improvement in percent loco-regional failure [88–90, 92–94]. Six series of patients who received adjuvant radiation revealed a failure rate between 9% and 38%. The number of patients ranged from 9 to 45, with 1 series having 86 patients. The 5-year-survival rate was 21% to 49%. The series of patients who had surgery only (the number of patients in these series ranged from 11 to 81) without adjuvant treatment had a crude loco-regional failure rate of 45% to 65% and a 5-year-survival rate of 17% to 33%. These studies might conclude that with radiation, there seems to be some improvement in the failure and survival rate, but large studies need to be performed.

The urothelial tumors of the upper urinary tract are considered to be chemosensitive tumors [43–45]. Most of the data regarding the clinical efficacy of chemotherapy in the neoadjuvant and adjuvant settings are based on experience from bladder TCC. Advantages of neoadjuvant chemotherapy include eradication of subclinical metastatic disease, better tolerability before surgical extirpation, and ability to deliver higher doses than in the adjuvant setting [45]. Both the Advanced Bladder Cancer Meta-analysis

Collaboration and the Southwest Oncology group have presented compelling data for the use of neoadjuvant platinum-based chemotherapy regimens before radical cystectomy [95, 96]. Regimens comprised of gemcitabine and cisplatin that provide a similar survival advantage to methotrexate-vinblastine-doxorubicin-cisplatin (MVAC), with a better safety profile and tolerability, increase the attractiveness of neoadjuvant chemotherapy [97]. Similar management strategies are likely to be beneficial for upper-tract TCC, particularly in the setting of large, bulky tumors.

The role of adjuvant systemic chemotherapy to patients with locally advanced upper urinary tract tumors is not well defined, because of the scarcity of controlled trials due to the low prevalence and incidence of disease. Nevertheless, a recent study by Brown et al. [73] reported on their experience with both adjuvant radiation therapy and concurrent chemotherapy for locally advanced disease. After surgery, 31 patients have received adjuvant radiation therapy. All patients had grade 2 and even 84% of the group were found to have a pathologic stage of T3 or higher. Nine patients received methotrexate, cisplatin, and vinblastine chemotherapy for 2 to 4 cycles. Univariate analysis revealed that patients had improved 5-year actuarial overall and disease-specific survival with the administration of concurrent chemotherapy when compared with patients receiving adjuvant radiation alone (27% versus 67%, $P = .01$; 41% versus 76%, $P = .06$, resp.).

6. Conclusions

Treatment of upper-tract urothelial carcinoma has developed and changed with advances in technology. Treatment has evolved from open radical nephroureterectomy to percutaneous resection to ureteroscopic treatment. Adjuvant treatments are also evolving with topical immunotherapy, radiation, and chemotherapy. Before any decision for optimal treatment, the specifics of each individual patient with regard to renal function, medical comorbidities, location of disease, tumor stage, and tumor grade must be taken into account.

Due to the fact that the incidence and prevalence of this tumor is low, the majority of series in the literature are of limited number. What is clear from the literature with regard to surgical outcomes for upper-tract TCC is that this is a potentially lethal disease if not treated appropriately. Due to its relative rarity, many decisions regarding treatment are extrapolated from our experience in managing bladder urothelial carcinoma (such as node dissections, topical chemotherapies, immunotherapies, and adjuvant treatments). The problem about the studies utilizing minimally invasive techniques is that they lack long-term follow-up. Almost all of the studies are retrospective in nature and therefore flawed with selection biases.

As a result, the standard way still remains to be surgical removal with radical nephroureterectomy, and for selected patients segmental ureterectomy may be performed. Endoscopic management is also reasonable in patients with low-grade and low-stage disease as long as they adhere to a strict follow-up protocol that includes frequent cytology and endoscopy. The benefits of adjuvant radiation and chemotherapy are still debated, but the literature does reveal some improvement in disease-specific survival using both forms of treatment.

References

[1] C. R. Porter, K. C. Latchamsetty, and E. M. Genega, "Urothelial neoplasms of the kidney and ureter: an epidemiologic, pathological and clinical review," *AUA Update Series*, vol. 24, pp. 77–84, 2005.

[2] H. Grabstald, W. F. Whitmore, and M. R. Melamed, "Renal pelvic tumors," *The Journal of the American Medical Association*, vol. 218, no. 6, pp. 845–854, 1971.

[3] D. G. Wagle, R. H. Moore, and G. P. Murphy, "Primary carcinoma of the renal pelvis," *Cancer*, vol. 33, no. 6, pp. 1642–1648, 1974.

[4] C. C. Say and J. M. Hori, "Transitional cell carcinoma of the renal pelvis: experience from 1940 to 1972 and literature review," *The Journal of Urology*, vol. 112, no. 4, pp. 438–442, 1974.

[5] B. N. Nocks, N. M. Heney, J. J. Dally, T. A. Perrone, P. P. Griffin, and G. R. Prout Jr., "Transitional cell carcinoma of renal pelvis," *Urology*, vol. 19, no. 5, pp. 472–477, 1982.

[6] D. A. Grace, W. N. Taylor, J. N. Taylor, and C. C. Winter, "Carcinoma of the renal pelvis: a 15-year review," *The Journal of Urology*, vol. 98, no. 5, pp. 566–569, 1967.

[7] K. B. Cummings, R. J. Correa, R. P. Gibbons, H. M. Stoll, R. F. Wheelis, and J. T. Mason, "Renal pelvic tumors," *The Journal of Urology*, vol. 113, no. 2, pp. 158–162, 1975.

[8] M. A. Rubenstein, B. J. Walz, and J. G. Bucy, "Transitional cell carcinoma of the kidney: 25-year experience," *The Journal of Urology*, vol. 119, no. 5, pp. 594–597, 1978.

[9] N. M. Heney, B. N. Nocks, J. J. Daly, P. H. Blitzer, and E. C. Parkhurst, "Prognostic factors in carcinoma of the ureter," *The Journal of Urology*, vol. 125, no. 5, pp. 632–636, 1981.

[10] E. Mazeman, "Tumours of the upper urinary tract calyces, renal pelvis and ureter," *European Urology*, vol. 2, no. 3, pp. 120–126, 1976.

[11] M. C. Hall, S. Womack, A. I. Sagalowsky, T. Carmody, M. D. Erickstad, and C. G. Roehrborn, "Prognostic factors, recurrence, and survival in transitional cell carcinoma of the upper urinary tract: a 30-year experience in 252 patients," *Urology*, vol. 52, no. 4, pp. 594–601, 1998.

[12] I. S. Gill, G. T. Sung, M. G. Hobart, et al., "Laparoscopic radical nephroureterectomy for upper tract transitional cell carcinoma: the Cleveland Clinic experience," *The Journal of Urology*, vol. 164, no. 5, pp. 1513–1522, 2000.

[13] A. L. Shalhav, M. D. Dunn, A. J. Portis, A. M. Elbahnasy, E. M. McDougall, and R. V. Clayman, "Laparoscopic nephroureterectomy for upper tract transitional cell cancer: the Washington University experience," *The Journal of Urology*, vol. 163, no. 4, pp. 1100–1104, 2000.

[14] R. V. Clayman, L. R. Kavoussi, R. S. Figenshau, P. S. Chandhoke, and D. M. Albala, "Laparoscopic nephroureterectomy: initial clinical case report," *Journal of Laparoendoscopic Surgery*, vol. 1, no. 6, pp. 343–349, 1991.

[15] A. Goel, A. K. Hemal, and N. P. Gupta, "Retroperitoneal laparoscopic radical nephrectomy and nephroureterectomy and comparison with open surgery," *World Journal of Urology*, vol. 20, no. 4, pp. 219–223, 2002.

[16] H. C. Klingler, M. Lodde, A. Pycha, M. Remzi, G. Janetschek, and M. Marberger, "Modified laparoscopic nephroureterectomy for treatment of upper urinary tract transitional cell cancer is not associated with an increased risk of tumour recurrence," *European Urology*, vol. 44, no. 4, pp. 442–447, 2003.

[17] E. M. McDougall, R. V. Clayman, and O. Elashry, "Laparoscopic nephroureterectomy for upper tract transitional cell cancer: the Washington University experience," *The Journal of Urology*, vol. 154, no. 3, pp. 975–980, 1995.

[18] A. Kawauchi, A. Fujito, O. Ukimura, K. Yoneda, Y. Mizutani, and T. Miki, "Hand assisted retroperitoneoscopic nephroureterectomy: comparison with the open procedure," *The Journal of Urology*, vol. 169, no. 3, pp. 890–894, 2003.

[19] M. D. Stifelman, M. J. Hyman, S. Shichman, and R. E. Sosa, "Hand-assisted laparoscopic nephroureterectomy versus open nephroureterectomy for the treatment of transitional-cell carcinoma of the upper urinary tract," *Journal of Endourology*, vol. 15, no. 4, pp. 391–395, 2001.

[20] J. Landman, R. Y. Lev, S. Bhayani, et al., "Comparison of hand assisted and standard laparoscopic radical nephroureterectomy for the management of localized transitional cell carcinoma," *The Journal of Urology*, vol. 167, no. 6, pp. 2387–2391, 2002.

[21] J. R. Steinberg and S. F. Matin, "Laparoscopic radical nephroureterectomy: dilemma of the distal ureter," *Current Opinion in Urology*, vol. 14, no. 2, pp. 61–65, 2004.

[22] Y. Matsui, H. Ohara, K. Ichioka, et al., "Retroperitoneoscopy-assisted total nephroureterectomy for upper urinary tract transitional cell carcinoma," *Urology*, vol. 60, no. 6, pp. 1010–1015, 2002.

[23] I. S. Gill, J. J. Soble, S. D. Miller, and G. T. Sung, "A novel technique for management of the en bloc bladder cuff and distal ureter during laparoscopic nephroureterectomy," *The Journal of Urology*, vol. 161, no. 2, pp. 430–434, 1999.

[24] F. X. Keeley Jr. and D. A. Tolley, "Laparoscopic nephroureterectomy: making management of upper-tract transitional-cell carcinoma entirely minimally invasive," *Journal of Endourology*, vol. 12, no. 2, pp. 139–141, 1998.

[25] I. S. Gill and J. J. Rassweiler, "Retroperitoneoscopic renal surgery: our approach," *Urology*, vol. 54, no. 4, pp. 734–738, 1999.

[26] B. D. Seifman, J. E. Montie, and J. S. Wolf Jr., "Prospective comparison between hand-assisted laparoscopic and open surgical nephroureterectomy for urothelial cell carcinoma," *Urology*, vol. 57, no. 1, pp. 133–137, 2001.

[27] T. E. Ahlering, D. Skarecky, D. Lee, and R. V. Clayman, "Successful transfer of open surgical skills to a laparoscopic environment using a robotic interface: initial experience with laparoscopic radical prostatectomy," *The Journal of Urology*, vol. 170, no. 5, pp. 1738–1741, 2003.

[28] M. T. Gettman, M. L. Blute, G. K. Chow, R. Neururer, G. Bartsch, and R. Peschel, "Robotic-assisted laparoscopic partial nephrectomy: technique and initial clinical experience with daVinci robotic system," *Urology*, vol. 64, no. 5, pp. 914–918, 2004.

[29] M. D. Stifelman, R. P. Caruso, A. M. Nieder, and S. S. Taneja, "Robot-assisted laparoscopic partial nephrectomy," *JSLS*, vol. 9, no. 1, pp. 83–86, 2005.

[30] C. K. Phillips, S. S. Taneja, and M. D. Stifelman, "Robot-assisted laparoscopic partial nephrectomy: the NYU technique," *Journal of Endourology*, vol. 19, no. 4, pp. 441–445, 2005.

[31] R. P. Caruso, C. K. Phillips, E. Kau, S. S. Taneja, and M. D. Stifelman, "Robot assisted laparoscopic partial nephrectomy: initial experience," *The Journal of Urology*, vol. 176, no. 1, pp. 36–39, 2006.

[32] S. Kaul, R. Laungani, R. Sarle, et al., "da Vinci-assisted robotic partial nephrectomy: technique and results at a mean of 15 months of follow-up," *European Urology*, vol. 51, no. 1, pp. 186–192, 2007.

[33] L. A. Deane, H. J. Lee, G. N. Box, et al., "Robotic versus standard laparoscopic partial/wedge nephrectomy: a comparison of intraoperative and perioperative results from a single institution," *Journal of Endourology*, vol. 22, no. 5, pp. 947–952, 2008.

[34] M. D. Stifelman, R. E. Sosa, A. Andrade, A. Tarantino, and S. J. Shichman, "Hand-assisted laparoscopic nephroureterectomy for the treatment of transitional cell carcinoma of the upper urinary tract," *Urology*, vol. 56, no. 5, pp. 741–747, 2000.

[35] S. Matin and I. S. Gill, "Laparoscopic radical nephrectomy with various forms of bladder cuff control II: patterns of survival," *J Endourol*, vol. 17, supplement 1, p. A74, 2003.

[36] S. A. McNeill, M. Chrisofos, and D. A. Tolley, "The long-term outcome after laparoscopic nephroureterectomy: a comparison with open nephroureterectomy," *BJU International*, vol. 86, no. 6, pp. 619–623, 2000.

[37] Y. Yoshino, Y. Ono, R. Hattori, M. Gotoh, O. Kamihira, and S. Ohshima, "Retroperitoneoscopic nephroureterectomy for transitional cell carcinoma of the renal pelvis and ureter: Nagoya experience," *Urology*, vol. 61, no. 3, pp. 533–538, 2003.

[38] P. S. Chandhoke, R. V. Clayman, K. Kerbl, et al., "Laparoscopic ureterectomy: initial clinical experience," *The Journal of Urology*, vol. 149, no. 5, pp. 992–997, 1993.

[39] S. M. Baughman, W. Sexton, and J. T. Bishoff, "Multiple intravesical linear staples identified during surveillance cystoscopy after laparoscopic nephroureterectomy," *Urology*, vol. 62, no. 2, p. 351, 2003.

[40] O. Arango, O. Bielsa, J. Carles, and A. Gelabert-Mas, "Massive tumor implantation in the endoscopic resected area in modified nephroureterectomy," *The Journal of Urology*, vol. 157, no. 5, p. 1839, 1997.

[41] J. W. Hetherington, R. Ewing, and N. H. Philp, "Modified nephroureterectomy: a risk of tumour implantation," *British Journal of Urology*, vol. 58, no. 4, pp. 368–370, 1986.

[42] D. R. Jones and C. U. Moisey, "A cautionary tale of the modified "pluck" nephroureterectomy," *British Journal of Urology*, vol. 71, no. 4, p. 486, 1993.

[43] R. C. Flanigan, "Urothelial tumors of the upper urinary tract," in *Campbell-Walsh Urology*, A. J. Wein, L. R. Kavoussi, A. C. Novick, A. W. Partin, and C. A. Peters, Eds., vol. 2, pp. 1638–1652, WB Saunders, Philadelphia, Pa, USA, 9th edition, 2007.

[44] G. S. Gerber and G. D. Steinberg, "Endourologic treatment of renal pelvic and ureteral transitional cell carcinoma," *Techniques in Urology*, vol. 5, no. 2, pp. 77–80, 1999.

[45] R. H. Houston and B. C. Leibovich, "Management of upper tract tumors," in *Comprehensive Textbook of Genitourinary Oncology*, N. J. Vogelzang, P. T. Scardino, W. U. Shipley, and D. S. Coffey, Eds., vol. 1, pp. 435–442, Lippincott Williams & Wilkins, Philadelphia, Pa, USA, 3rd edition, 2005.

[46] A. Sagalowsky, "Management of urothelial tumors of the renal pelvis and ureter," in *Campbell- Walsh Urology*, A. J. Wein, L. R. Kavoussi, A. C. Novick, A. W. Partin, and C. A. Peters, Eds., vol. 2, pp. 1653–1687, WB Saunders, Philadelphia, Pa, USA, 9th edition, 2007.

[47] S. Daneshmand, M. L. Quek, and J. L. Huffman, "Endoscopic management of upper urinary tract transitional cell carcinoma: long-term experience," *Cancer*, vol. 98, no. 1, pp. 55–60, 2003.

[48] F. X. Keeley Jr., M. Bibbo, and D. H. Bagley, "Ureteroscopic treatment and surveillance of upper urinary tract transitional cell carcinoma," *The Journal of Urology*, vol. 157, no. 5, pp. 1560–1565, 1997.

[49] J. A. Martinez-Pineiro, M. J. Garcia Matres, and L. Martinez-Pineiro, "Endourological treatment of upper tract urothelial carcinomas: analysis of a series of 59 tumors," *The Journal of Urology*, vol. 156, no. 2, pp. 377–385, 1996.

[50] D. S. Elliott, M. L. Blute, D. E. Patterson, E. J. Bergstralh, and J. W. Segura, "Long-term follow-up of endoscopically treated upper urinary tract transitional cell carcinoma," *Urology*, vol. 47, no. 6, pp. 819–825, 1996.

[51] J. A. Smith Jr., "Review: tissue effects of laser energy," *Journal of Endourology*, vol. 7, no. 5, pp. 389–390, 1993.

[52] A. Huang, R. K. Low, and R. D. White, "Nephrostomy tract tumor seeding following percutaneous manipulation of a ureteral carcinoma," *The Journal of Urology*, vol. 153, no. 3, Supplement 1, pp. 1041–1042, 1995.

[53] Y. Yamada, Y. Kobayashi, A. Yao, K. Yamanaka, Y. Takechi, and K. Umezu, "Nephrostomy tract tumor seeding following percutaneous manipulation of a renal pelvic carcinoma," *Acta Urologica Japonica*, vol. 48, no. 7, pp. 415–418, 2002.

[54] T. W. Jarrett, P. M. Sweetser, G. H. Weiss, and A. D. Smith, "Percutaneous management of transitional cell carcinoma of the renal collecting system: 9-year experience," *The Journal of Urology*, vol. 154, no. 5, pp. 1629–1635, 1995.

[55] P. E. Clark, S. B. Streem, and M. A. Geisinger, "13-year experience with percutaneous management of upper tract transitional cell carcinoma," *The Journal of Urology*, vol. 161, no. 3, pp. 772–776, 1999.

[56] A. Patel, P. Soonawalla, S. F. Shepherd, D. P. Dearnaley, M. J. Kellett, and C. R. J. Woodhouse, "Long-term outcome after percutaneous treatment of transitional cell carcinoma of the renal pelvis," *The Journal of Urology*, vol. 155, no. 3, pp. 868–874, 1996.

[57] E. R. Tawfiek and D. H. Bagley, "Upper-tract transitional cell carcinoma," *Urology*, vol. 50, no. 3, pp. 321–329, 1997.

[58] G. L. Chen and D. H. Bagley, "Ureteroscopic management of upper tract transitional cell carcinoma in patients with normal contralateral kidneys," *The Journal of Urology*, vol. 164, no. 4, pp. 1173–1176, 2000.

[59] D. S. Elliott, J. W. Segura, D. Lightner, D. E. Patterson, and M. L. Blute, "Is nephroureterectomy necessary in all cases of upper tract transitional cell carcinoma? Long-term results of conservative endourologic management of upper tract transitional cell carcinoma in individuals with a normal contralateral kidney," *Urology*, vol. 58, no. 2, pp. 174–178, 2001.

[60] M. Grasso, M. Fraiman, and M. Levine, "Ureteropyeloscopic diagnosis and treatment of upper urinary tract urothelial malignancies," *Urology*, vol. 54, no. 2, pp. 240–246, 1999.

[61] A. Patel and G. J. Fuchs, "New techniques for the administration of topical adjuvant therapy after endoscopic ablation of upper urinary tract transitional cell carcinoma," *The Journal of Urology*, vol. 159, no. 1, pp. 71–75, 1998.

[62] D. W. Soderdahl, M. D. Fabrizio, N. U. Rahman, T. W. Jarrett, and D. H. Bagley, "Endoscopic treatment of upper tract transitional cell carcinoma," *Urologic Oncology*, vol. 23, no. 2, pp. 114–122, 2005.

[63] S. Boorjian, C. Ng, R. Munver, et al., "Impact of delay to nephroureterectomy for patients undergoing ureteroscopic biopsy and laser tumor ablation of upper tract transitional cell carcinoma," *Urology*, vol. 66, no. 2, pp. 283–287, 2005.

[64] H. Okada, H. Eto, I. Hara, et al., "Percutaneous treatment of transitional cell carcinoma of the upper urinary tract," *International Journal of Urology*, vol. 4, no. 2, pp. 130–133, 1997.

[65] M. Rouprêt, O. Traxer, M. Tligui, et al., "Upper urinary tract transitional cell carcinoma: recurrence rate after percutaneous endoscopic resection," *European Urology*, vol. 51, no. 3, pp. 709–714, 2007.

[66] B. R. Lee, M. E. Jabbour, F. F. Marshall, A. D. Smith, and T. W. Jarrett, "13-year survival comparison of percutaneous and open nephroureterectomy approaches for management of transitional cell carcinoma of renal collecting system: Equivalent outcomes," *Journal of Endourology*, vol. 13, no. 4, pp. 289–294, 1999.

[67] S. E. Canfield, C. P. N. Dinney, and M. J. Droller, "Surveillance and management of recurrence for upper tract transitional cell carcinoma," *Urologic Clinics of North America*, vol. 30, no. 4, pp. 791–802, 2003.

[68] H. Komatsu, N. Tanabe, S. Kubodera, H. Maezawa, and A. Ueno, "The role of lymphadenectomy in the treatment of transitional cell carcinoma of the upper urinary tract," *The Journal of Urology*, vol. 157, no. 5, pp. 1622–1624, 1997.

[69] M. Abdel-Latif, H. Abol-Enein, M. El-Baz, and M. A. Ghoneim, "Nodal involvement in bladder cancer cases treated with radical cystectomy: incidence and prognosis," *The Journal of Urology*, vol. 172, no. 1, pp. 85–89, 2004.

[70] H. Miyake, I. Kara, K. Gohji, S. Arakawa, and S. Kamidono, "The significance of lymphadenectomy in transitional cell carcinoma of the upper urinary tract," *British Journal of Urology*, vol. 82, no. 4, pp. 494–498, 1998.

[71] M. A. Brausi, M. Gavioli, G. De Luca, et al., "Retroperitoneal lymph node dissection (RPLD) in conjunction with nephroureterectomy in the treatment of infiltrative transitional cell carcinoma (TCC) of the upper urinary tract: impact on survival," *European Urology*, vol. 52, no. 5, pp. 1414–1420, 2007.

[72] M. Roscigno, C. Cozzarini, R. Bertini, et al., "Prognostic value of lymph node dissection in patients with muscle-invasive transitional cell carcinoma of the upper urinary tract," *European Urology*, vol. 53, no. 4, pp. 794–802, 2008.

[73] G. A. Brown, J. E. Busby, C. G. Wood, et al., "Nephroureterectomy for treating upper urinary tract transitional cell carcinoma: time to change the treatment paradigm?" *BJU International*, vol. 98, no. 6, pp. 1176–1180, 2006.

[74] M. Roscigno, C. Cozzarini, R. Bertini, et al., "Prognostic value of lymph node dissection in patients with muscle-invasive transitional cell carcinoma of the upper urinary tract," *European Urology*, vol. 53, no. 4, pp. 794–802, 2008.

[75] E. Mukamel, E. Vilkovsky, H. Hadar, D. Engelstein, B. Nussbaum, and C. Servadio, "The effect of intravesical bacillus Calmette-Guérin therapy on the upper urinary tract," *The Journal of Urology*, vol. 146, no. 4, pp. 980–981, 1991.

[76] G. C. Bellman, P. Sweetser, and A. D. Smith, "Complications of intracavitary bacillus Calmette-Guérin after percutaneous resection of upper tract transitional cell carcinoma," *The Journal of Urology*, vol. 151, no. 1, pp. 13–15, 1994.

[77] G. N. Thalmann, R. Markwalder, B. Walter, and U. E. Studer, "Long-term experience with bacillus Calmette-Guérin therapy of upper urinary tract transitional cell carcinoma in patients

not eligible for surgery," *The Journal of Urology*, vol. 168, no. 4, part 1, pp. 1381–1385, 2002.

[78] J. R. Sharpe, G. Duffy, and J. L. Chin, "Intrarenal bacillus Calmette-Guérin therapy for upper urinary tract carcinoma in situ," *The Journal of Urology*, vol. 149, no. 3, pp. 457–460, 1993.

[79] N. Nonomura, Y. Ono, M. Nozawa, et al., "Bacillus Calmette-Guérin perfusion therapy for the treatment of transitional cell carcinoma in situ of the upper urinary tract," *European Urology*, vol. 38, no. 6, pp. 701–705, 2000.

[80] H. Yokogi, Y. Wada, M. Mizutani, M. Igawa, and T. Ishibe, "Bacillus Calmette-Guérin perfusion therapy for carcinoma in situ of the upper urinary tract," *British Journal of Urology*, vol. 77, no. 5, pp. 676–679, 1996.

[81] K. Okubo, K. Ichioka, N. Terada, Y. Matsuta, K. Yoshimura, and Y. Arai, "Intrarenal bacillus Calmette-Guérin therapy for carcinoma in situ of the upper urinary tract: long-term follow-up and natural course in cases of failure," *BJU International*, vol. 88, no. 4, pp. 343–347, 2001.

[82] Y. Nishino, N. Yamamoto, H. Komeda, Y. Takahashi, and T. Deguchi, "Bacillus Calmette-Guérin instillation treatment for carcinoma in situ of the upper urinary tract," *BJU International*, vol. 85, no. 7, pp. 799–801, 2000.

[83] H. W. Herr, "Durable response of a carcinoma in situ of the renal pelvis to topical bacillus Calmette-Guérin," *The Journal of Urology*, vol. 134, no. 3, pp. 531–532, 1985.

[84] S. P. Vasavada, S. B. Streem, and A. C. Novick, "Definitive tumor resection and percutaneous Bacille Calmette Calmette-Guérin for management of renal pelvictransitional cell carcinoma in solitary kidneys," *Urology*, vol. 45, no. 3, pp. 381–386, 1995.

[85] J. C. Ramsey and M. S. Soloway, "Instillation of bacillus Calmette-Guérin into the renal pelvis of a solitary kidney of the treatment of transitional cell carcinoma," *The Journal of Urology*, vol. 143, no. 6, pp. 1220–1222, 1990.

[86] M. A. Batata, W. F. Whitmore Jr., B. S. Hilaris, H. Grabstald, and N. Tokita, "Primary carcinoma of the ureter: a prognostic study," *Cancer*, vol. 35, no. 6, pp. 1626–1632, 1975.

[87] C. Reitelman, I. S. Sawczuk, C. A. Olsson, P. J. Puchner, and M. C. Benson, "Prognostic variables in patients with transitional cell carcinoma of the renal pelvis and proximal ureter," *The Journal of Urology*, vol. 138, no. 5, pp. 1144–1145, 1987.

[88] S. C. Cozad, S. R. Smalley, M. Austenfeld, M. Noble, S. Jennings, and R. Raymond, "Transitional cell carcinoma of the renal pelvis or ureter: patterns of failure," *Urology*, vol. 46, no. 6, pp. 796–800, 1995.

[89] R. K. Brookland and M. P. Richter, "The postoperative irradiation of transitional cell carcinoma of the renal pelvis and ureter," *The Journal of Urology*, vol. 133, no. 6, pp. 952–955, 1985.

[90] M. Ozsahin, A. Zouhair, S. Villà, et al., "Prognostic factors in urothelial renal pelvis and ureter tumours: a multicentre rare cancer network study," *European Journal of Cancer*, vol. 35, no. 5, pp. 738–743, 1999.

[91] R. J. Babaian and D. E. Johnson, "Primary carcinoma of the ureter," *The Journal of Urology*, vol. 123, no. 3, pp. 357–359, 1980.

[92] C. Maulard-Durdux, B. Dufour, C. Hennequin, et al., "Postoperative radiation therapy in 26 patients with invasive transitional cell carcinoma of the upper urinary tract: no impact on survival?" *The Journal of Urology*, vol. 155, no. 1, pp. 115–117, 1996.

[93] C. N. Catton, P. Warde, M. K. Gospodarowicz, et al., "Transitional cell carcinoma of the renal pelvis and ureter: outcome and patterns of relapse in patients treated with postoperative radiation," *Urologic Oncology*, vol. 2, no. 6, pp. 171–176, 1996.

[94] B. Czito, A. Zietman, D. Kaufman, U. Skowronski, and W. Shipley, "Adjuvant radiotherapy with and without concurrent chemotherapy for locally advanced transitional cell carcinoma of the renal pelvis and ureter," *The Journal of Urology*, vol. 172, no. 4, part 1, pp. 1271–1275, 2004.

[95] H. B. Grossman, R. B. Natale, C. M. Tangen, et al., "Neoadjuvant chemotherapy plus cystectomy compared with cystectomy alone for locally advanced bladder cancer," *The New England Journal of Medicine*, vol. 349, no. 9, pp. 859–866, 2003.

[96] International Collaboration of Trialists, "Neoadjuvant cisplatin, methotrexate, and vinblastine chemotherapy for muscle-invasive bladder cancer: a randomised controlled trial," *The Lancet*, vol. 354, no. 9178, pp. 533–540, 1999.

[97] J. T. Roberts, H. von der Maase, L. Sengeløv, et al., "Long-term survival results of a randomized trial comparing gemcitabine/cisplatin and methotrexate/vinblastine/doxorubicin/cisplatin in patients with locally advanced and metastatic bladder cancer," *Annals of Oncology*, vol. 17, supplement 5, pp. v118–v122, 2006.