Future Trend in Minimally Invasive Surgery: Single Port, Minilaparoscopy, and NOTES

Guest Editors: Luigi Boni, Paul G. Curcillo, and Silvana Perretta

Future Trend in Minimally Invasive Surgery: Single Port, Minilaparoscopy, and NOTES

Future Trend in Minimally Invasive Surgery: Single Port, Minilaparoscopy, and NOTES

Guest Editors: Luigi Boni, Paul G. Curcillo, and Silvana Perretta

Editorial Board

Contents

Hindawi Publishing Corporation
Minimally Invasive Surgery
Volume 2012, Article ID 575301, 1 page
doi:10.1155/2012/575301

Editorial

Future Trend in Minimally Invasive Surgery: Single Port, Minilaparoscopy, and NOTES

Luigi Boni,[1] Paul G. Curcillo,[2] and Silvana Perretta[3]

[1] *Minimally Invasive Surgery Center, University of Insubria, 20100 Varese, Italy*
[2] *Minimally Invasive Surgical Initiatives and Development, Fox Chase Cancer Center, Philadelphia, PA 19111, USA*
[3] *IRCAD, 67000 Strasbourg, France*

Correspondence should be addressed to Luigi Boni, luigi.boni@uninsubria.it

Received 11 December 2012; Accepted 11 December 2012

Over the last few years, we assisted to an unstoppable quest for technical improvements in order to reduce even more the surgical trauma in the field of minimally invasive surgery. natural orifice transluminal endoscopic surgery (NOTES), single port surgery, and minilaparoscopy seem to answer the needs for reducing the trauma related to the "access" to the human body.

Among these techniques NOTES is, by no means, the most appealing and promising in terms of minimizing the access to the abdominal cavity; nevertheless, while single port and even more minilaparoscopy are currently applied worldwide in the routine clinical setting, for NOTES there are still several limitations, and it is often used only in clinical trials or experimental models, and, for most of the cases, it is performed under laparoscopic control.

On the other hand, there is no doubt that the current scientific literature is lacking robust data, and all these new technologies are still under evaluation to demonstrate that the reduction of surgical trauma in comparison to standard laparoscopy can justify the extra costs as well and the increase of operative difficulties.

In this special issue, ten original articles, reviews, and case reports have been selected because they described different experiences and modalities for what could be called "ultra" minimally invasive surgery.

As for NOTES not only a comprehensive review on current "state of the art" of NOTES in humans is published but also a paper describing results of a survey regarding patinets' perception on NOTES. As for specific clinical applications of NOTES three articles are focused on the approach to the spine and the role of transesophageal and transanal surgeries.

Readers will also find different papers regarding technique and results of single port surgery for colorectal, pancreatic, ileal resection as well as for cholecystectomy.

Finally, a well-documented technical note on applications of minilaparoscopy during colorectal resection is also presented.

Luigi Boni
Paul G. Curcillo
Silvana Perretta

Hindawi Publishing Corporation
Minimally Invasive Surgery
Volume 2012, Article ID 189296, 8 pages
doi:10.1155/2012/189296

Review Article

Natural Orifice Translumenal Endoscopic Surgery in Humans: A Review

Michelle P. Clark,[1] Emad S. Qayed,[1] David A. Kooby,[2] Shishir K. Maithel,[2] and Field F. Willingham[1]

[1] *Division of Digestive Diseases, Department of Medicine, School of Medicine, Emory University, Atlanta, GA 30322, USA*
[2] *Department of Surgery, School of Medicine, Emory University, Atlanta, GA 30322, USA*

Correspondence should be addressed to Field F. Willingham, field.willingham@emoryhealthcare.org

Received 9 January 2012; Accepted 6 March 2012

Academic Editor: Silvana Perretta

Natural orifice translumenal endoscopic surgery (NOTES) had its origins in numerous small animal studies primarily examining safety and feasibility. In human trials, safety and feasibility remain at the forefront; however, additional logistic, practical, and regulatory requirements must be addressed. The purpose of this paper is to evaluate and summarize published studies to date of NOTES in humans. The literature review was performed using PUBMED and MEDLINE databases. Articles published in human populations between 2007 and 2011 were evaluated. A review of this time period resulted in 48 studies describing procedures in 916 patients. Transcolonic and transvesicular procedures were excluded. The most common procedure was cholecystectomy (682, 75%). The most common approach was transvaginal (721, 79%). 424 procedures (46%) were pure NOTES and 491 (54%) were hybrid NOTES cases. 127 (14%) were performed in the United States of America and 789 (86%) were performed internationally. Since 2007, there has been major development in NOTES in human populations. A preponderance of published NOTES procedures were performed internationally. With further development, NOTES may make less invasive surgery available to a larger human population.

1. Introduction

An open laparotomy is employed for many surgical procedures; however, the laparoscopic approach and minimally invasive techniques have become more common and are now preferred for certain procedures. Surgery without a cutaneous incision utilizing flexible endoscopes passed through internal organs has been termed natural orifice translumenal endoscopic surgery (NOTES). NOTES is felt to represent a logical evolution in minimally invasive surgery. NOTES is performed via a natural orifice (mouth, anus, vagina, and urethra), in some cases without requiring an abdominal wall incision. Some studies have suggested superiority over a conventional approach. NOTES had its origins in numerous small animal studies primarily examining safety and feasibility. In human trials, safety and feasibility remain at the forefront; however, additional logistic, practical, and regulatory requirements must be addressed. The purpose of this paper is to summarize and describe the progress in NOTES in humans to date.

Historical Perspective. Long before the term NOTES was coined, variations of the approach have been discussed in the medical literature. In 1813, the first colpotomy with a transvaginal approach to abdominal viscera was described for hysterectomy [1]. In the 1940s, gynecological procedures were performed using an endoscope passed through the recto-uterine pouch to view the pelvic organs and perform sterilization procedures [2]. Pancreatic necrosectomy was first described in 2000 and involved a controlled endoscopic perforation of the gastric wall to access the retrogastric space [3]. The concept of NOTES gained greater attention in 2004 when purposeful transgastric peritoneoscopy was performed in a porcine model [4]. The pig model was also used for tubal ligation, cholecystectomy, splenectomy, gastrojejunostomy,

distal pancreatectomy, and oophorectomy with tubectomy [2, 5]. Many studies have focused on intraabdominal applications; however, intrathoracic procedures have been performed as well including mediastinoscopy, thorascopy [6, 7], and lymph node dissection [8, 9].

In 2005 a meeting occurred between members of the Society of American Gastrointestinal Endoscopic Surgeons (SAGES) and members of the American Society for Gastrointestinal Endoscopy (ASGE) to evaluate NOTES research to date and to consider challenges in NOTES development moving forward [10]. This meeting would lead to the development of the Natural Orifice Surgery Consortium for Assessment and Research [NOSCAR]. The goal of the meeting was to create a white paper setting forth concerns regarding skills and safety, research challenges, and results reporting in moving NOTES towards human populations. In 2006 the White Paper was published outlining ten critical areas that would impact the safety and appropriate usage of NOTES and the need for increased research and analysis of data. The paper identified challenges to be addressed including the physiologic implications of the procedure, safe access to the peritoneum, advancing technology and evaluating the risk of infection following NOTES [10].

Methodology. The review period included studies published between 2007 and 2011. These included pure and hybrid NOTES. A pure NOTES approach was defined as a procedure using flexible endoscopy without any abdominal incisions. Transvaginal NOTES was defined as a procedure where the approach involved a transvaginal conduit, often performed via a colpotomy with or without port placement. Hybrid studies were defined as surgeries utilizing flexible endoscopy combined with additional placement of one or more trocars involving flexible or rigid endoscopes [11–13]. The studies were performed in the United States of America and internationally. The transvaginal route was considered to involve incisions made near the cervix with entry into the peritoneal cavity. The transgastric route was considered to involve an endoscope passed through the mouth and esophagus and brought through a gastrotomy to enter the peritoneal cavity. Transcolonic and transvesicular approaches were not included. The literature review was completed using PUBMED and MEDLINE databases using the terms: NOTES, natural orifice translumenal endoscopic surgery, natural orifice translumenal endoscopy, human, minimally invasive surgery, NOTES in humans, and history of NOTES. Additional studies were identified in the references sections from publications located in the database search.

2. Results

2.1. Early NOTES in Humans. Pancreatic necrosectomy and pancreatic pseudocyst gastrostomy are considered by some reviewers to be the first NOTES procedures. Early reports of transgastric pancreatic procedures appeared in 2000 [3]. Recently a large multicenter retrospective study reported on the experience with pancreatic necrosectomy for walled off pancreatic necrosis [14]. In this retrospective chart review, 95 of 104 patients (91%) achieved successful resolution with a 14% complication rate. The first NOTES procedure in humans is often considered to be a transgastric appendectomy performed in India in 2006 which was presented but not reported in manuscript form [15]. This was followed by two cases of transvaginal cholecystectomy in 2006 [16] and 2007 [17]. In 2008 the first cases of transvaginal appendectomy in humans were published [18]. The results of the first pilot study for natural orifice transgastric endoscopic peritoneoscopy in humans were published in 2008 in the United States of America [19] and included ten patients with pancreatic masses who underwent diagnostic laparoscopic evaluation. These patients then underwent transgastric peritoneoscopy by surgeons blinded to the laparoscopic findings. The authors concluded that the translumenal endoscopic method is feasible, safe, and could be applied to other procedures such as appendectomy and cholecystectomy. In a more recent trial, an additional 10 patients were tested in the same manner and added to the previous cohort of 10 patients [20]. The extension of the study found a 7-minute decrease in operative time for the second cohort without significant complications related to the endoscopic approach.

2.2. NOTES Human Studies to Date. A compendium of published reports of NOTES in humans is presented in Table 1, grouped by procedure. Almost all these reports describe NOTES with elective indications, most commonly transvaginal cholecystectomy. Only one series describes NOTES as an emergent procedure with acute intraabdominal infection [21]. A more recent report highlights the first use of a hybrid approach for a malignant tumor of the foregut and describes a series in which the hybrid approach may have been superior to conventional approaches, beyond cosmesis and postoperative pain [22]. The literature review focused on 916 NOTES procedures published between 2007 and 2011 (Table 1). In 2007, 6 (1%) were published followed by 57 (6%) in 2008, 176 (19%) in 2009, 517 (56%) in 2010, and 160 to date (18%) in 2011. There were 721 transvaginal procedures (79%) and 195 transgastric procedures (21%). The most common procedures were cholecystectomy (682, 74%), peritoneoscopy (82,9%), and appendectomy (60,7%). Of the cholecystectomies, 612 were transvaginal (90%) and 70 were transgastric (10%). Of the peritoneoscopies, 79 were transgastric (96%) and 3 were transvaginal (4%). Of the appendectomies, 42 were transvaginal (70%) and 18 were transgastric (30%).

The most common procedures by orifice were the transvaginal cholecystectomy 4 (0.4%) in 2007, 37 (4%) in 2008, 127 (14%) in 2009, 370 (40%) in 2010, and 74 (8%) in 2011 for a total of 612 procedures (67%). This was followed by transgastric peritoneoscopy 1 (0.1%) in 2007, 20 (2%) in 2008, and 58 (6%) in 2010 for a total of 79 procedures (9%). Transgastric cholecystectomy accounted for 36 of the procedures (4%) in 2009 and 34 (4%) in 2010 for a total of 70 procedures (8%). This was followed by transvaginal appendectomy: 2 (0.2%) in 2008, 1 (0.1%) in 2009, 37 (4%) in 2010, and 2 (0.2%) in 2011 for a total of 42 (5%) of the 916 procedures. There were 424 published pure NOTES

Table 1: Published NOTES studies in human populations between 2007 and 2011, grouped by procedure.

Procedure	Year	Route	*N* (range and total)	Complication rate (Range)
Cholecystectomy [16, 17, 21, 23, 49–66]	2007–2011	TV	1–240 Total = 612	1.5%–25% (Abscess, hematuria, subhepatic collection, sepsis, hematoma, laceration, perforation, biliary leakage)
Cholecystectomy [23, 62, 67–69]	2009-2010	TG	4–29 Total = 70	18% (sepsis, hematoma, laceration, perforation, biliary leakage)
Peritoneoscopy [19, 20, 31, 45, 70]	2007, 2008, 2010, 2011	TG	1–40 Total = 79	12.5% (infection, bleeding, wound dehiscence)
Peritoneoscopy [21, 32]	2008, 2011	TV	1-2 Total = 3	0%
Appendectomy [18, 34]	2008–2011	TV	1–37 Total = 42	0%
Appendectomy [23, 60, 71]	2009-2010	TG	1–14 Total = 18	33.3% (pneumothorax)
Gastrectomy (partial) [9, 23, 33, 37, 42]	2011	TG	14	0%
Gastrectomy [23, 33, 37, 42]	2008–2010	TV	Sleeve = 1–5 Partial = 2 Total = 12	0%
Nephrectomy [23, 40, 41]	2009-2010	TV	1–5 Total = 10	0%
Colectomy [35, 36, 38]	2008–2010	TV	1–12 Total = 16	0%
Gastric mass resection [22]	2011	TG	7	0% No recurrence to date
Gastric banding [72]	2010	TV	3	33.3% (ureter damage)
Cancer staging [23]	2010	TV	8	
Stapled cystogastrostomy [44]	2011	TG	6	0%
Gynecologic surgery [23]	2010	TV	11	
Splenectomy [39]	2009	TV	1	0%
Incisional hernia repair [43]	2010	TV	1	0%
Hepatic cystectomy [23]	2010	TV	1	
PEG rescue [31]	2007	TG	1	0%
Liver, ovary biopsy [32]	2008	TV	1	0%

TV: transvaginal, TG: transgastric.

procedures (46%) and 491 hybrid NOTES procedures (54%). With regard to geography, 127 (14%) of the procedures occurred in the United States of America and 789 (86%) internationally.

Overall complication rates varied by procedure type and access site. The complication rate was 0% for the following procedures: transvaginal peritoneoscopy, transvaginal appendectomy, transgastric and transvaginal gastrectomy, transvaginal nephrectomy, transvaginal colectomy, transgastric gastric mass resection, transgastric stapled cystogastrostomy, transvaginal splenectomy, transvaginal incisional hernia repair, transgastric PEG rescue, and transvaginal liver and ovarian biopsy and may reflect the small sample size reported to date. The complication rate for transvaginal cholecystectomy ranged from 1.5% to 25% while that for transgastric peritoneoscopy was 12.5%. The rate for transgastric cholecystectomy was 18% and in both transgastric appendectomy and gastric banding was 33.3%.

2.3. International Multicenter Trial on Clinical Natural Orifice Surgery. The international multicenter trial on clinical natural orifice surgery or NOTES IMTN study analyzed data on NOTES procedures from July 2007 to June 20, 2009 [23].

A total of 362 NOTES patients were followed. The study was conducted in 16 centers in 9 countries including Brazil, Peru, Ecuador, Chile, Italy, Germany, Mexico, India, and Cuba. General surgeons performed most of the procedures. The most common procedures were transvaginal cholecystectomy (66%) and transvaginal appendectomy (10%). Four of the centers performed transgastric procedures, accounting for 12% of the total. The overall complication rate was 8.8% (6.9% for transvaginal and 23.2% for transgastric procedures). All 43 procedures involving the transgastric approach were hybrid procedures. There were no mortalities.

2.4. German National Registry. The German Registry for NOTES is a privately funded registry that was started in March of 2008 [24]. It collects data voluntarily and directly from surgeons performing NOTES at their respective facilities. Data collected include patient demographics, target organs, therapy, and postoperative outcome. The results of the first 14 months of the registry were published [24]. The operations were documented between March 2008 and April 2009. General surgeons performed 97% of the procedures with a small number utilizing a gynecologist. Of the 551 patients, 534 used rigid endoscopes and 99% were hybrid procedures and all were transvaginal. As in the IMTN Study, cholecystectomy was the most common, accounting for 85% of the procedures. The complication rate was 3% and conversions to open or laparoscopic surgery occurred in 5%. There was no reported mortality. Advanced patient age and obesity were associated with increased conversion rates but were not associated with an increase in complication rates. The authors also concluded that transvaginal hybrid NOTES cholecystectomy is a practicable and safe alternative to laparoscopic cholecystectomy [24].

2.5. Patient Acceptance. There were 3 studies reviewed regarding patient opinions about NOTES. In a study published in 2009, a survey about NOTES and laparoscopic surgery was distributed to 192 presurgical patients [25]. They rated the importance of different potential benefits of NOTES versus laparoscopic surgery for cholecystectomy. It was found that risk of postoperative complication, recovery time, and postoperative pain was more important to patients than cost, visual scar, length of hospital stay, or anesthesia type ($P < 0.001$). When the patients were asked which method of surgery they preferred, 56% reported NOTES and 44% reported laparoscopic surgery. Patients felt they could have less pain, cost, risk of complication, and recovery time than with open or laparoscopic surgery. They also felt that more skill and training were required for NOTES than for other surgical methods ($P < 0.04$). Patients who had completed some college preferred NOTES. Patients who were 70 years of age and older, as well as patients who had previously undergone flexible endoscopy preferred laparoscopic surgery to NOTES ($P < 0.04$). In a study published in 2008, a hundred patients with an intact gallbladder who were undergoing EUS or ERCP for evaluation for abdominal complaints were asked about their preference between a laparoscopic or a NOTES cholecystectomy [26]. The patients were given a questionnaire about laparoscopic cholecystectomy and were then given a detailed description of the NOTES procedures using oral, rectal, and vaginal conduits. 78% of patients preferred NOTES over the traditional laparoscopic approach. Patients with age less than or equal to 50 years (odds ratio [OR] 1.3, $P = .61$), female sex (OR 2.1, $P = .14$), and prior endoscopy experience (OR 2.2, $P = .19$) preferred NOTES to laparoscopic surgery. As was seen previously when the laparoscopic approach was compared to open surgery, patients similarly may prefer NOTES to laparoscopy provided that the complication rates were comparable. The oral orifice appeared to be the preferred conduit [26]. In a study that reported on transvaginal NOTES procedures in a group of 100 women, 87% preferred transumbilical laparoendoscopic single-site surgery, while 8% preferred laparoscopy and only 4% preferred a transvaginal approach. Reasons cited included postoperative fear of complications with fertility and sexuality. Postoperative abstinence from intercourse following a transvaginal NOTES procedure was a concern in 76% of women who believed this could make them feel less feminine, less attractive, and could cause tension with their partners [27].

3. Discussion

NOTES is evolving as a feasible and acceptable alternative to more traditional surgical approaches, and the experience continues to grow. In this paper, published reports of NOTES in humans increased from 6 in 2007 to 517 in 2010. Despite studies suggesting that patients prefer an oral route [26], the transvaginal approach is by far the most common NOTES approach (79%) for both pure and hybrid procedures. The gallbladder remains the most common target organ in pure and hybrid NOTES (75%). Patients appear to prefer NOTES to laparoscopic surgery provided that a similar complication rate is achieved. Hybrid NOTES is common in humans, comprising 54% of reported cases. Human NOTES procedures were reported internationally in 27 countries. The preponderance of NOTES procedures were performed internationally with 86% of reported NOTES cases abroad and 14% in the United States.

3.1. The Transvaginal Approach. A transvaginal approach has been the most frequently utilized despite a number of challenges. This is in likelihood due to the ease and ready availability of a standard closure method for the transvisceral incision, frequently the colpotomy. In this paper the transvaginal approach was utilized in 79% of reports and was the most frequent approach for both pure and hybrid NOTES procedures. Gynecologists have been performing colpotomies for many years, providing ample experience with this surgical technique and the subsequent closure. Nevertheless, patients do not tend to prefer the transvaginal approach. In one study reviewed here, only 4% preferred a transvaginal approach when compared to single site or a laparoscopy. Patients express concern for decreased fertility and sexuality. Additionally, a transvaginal approach is only possible in half the population. As NOTES continues to

evolve, enabling technologies may make closure of alternative visceral incisions more feasible.

3.2. Hybrid NOTES. Hybrid NOTES is common in humans, comprising 54% of reported cases in this paper. A hybrid approach is felt to be safer given the presence of standard transabdominal instruments to address potential complications. Hybrid approaches also enable standard-of-care closures of visceral incisions, leak testing, and additional visibility. Furthermore, the combination of laparoscopic and endoscopic techniques may enable more novel surgeries and may allow movement beyond cholecystectomy. Hybrid procedure and NOTES may have the potential to move beyond the recapitulation of standard and safe surgeries such as cholecystectomy, enabling more novel techniques with greater potential benefits over the traditional approach [28, 29].

3.3. Complications. Multiple potential benefits have been suggested for NOTES procedures including decreased postoperative wound infection, faster recovery, less intraabdominal adhesions, less postoperative ileus, decreased incidence of incisional hernias, less postoperative pain, and better cosmesis. Surgical wound infections are not an uncommon complication after traditional open or laparoscopic surgeries, occurring in up to 20% of patients undergoing intraabdominal surgery [30]. NOTES could also prove useful when transabdominal routes are not optimal or are difficult, such as in morbidly obese patients, patients with abdominal wall infections, or in the critically ill patients with contraindications to general anesthesia [28]. Many of the studies reviewed here reported no complications [9, 18, 21–23, 31–44]. The most common reported complications were sepsis, hematoma, laceration, perforation, and biliary leakage (Table 1). For the most common procedure, transvaginal cholecystectomy, the complication rate ranged from 1.5–25%. The main limitation presently is the lack of comparative data from trials comparing one approach with another in a prospective manner [45, 46].

3.4. NOTES Technology. Technology remains a challenge; much of the equipment and device technology used to date has been repurposed from other applications. Equipment typically employed in NOTES was not designed for use intraperitoneally [11]. The tools are not designed to manipulate the intraabdominal organs and they often have insufficient angulation and push force via small accessory channels [47]. There are also questions about safety, particularly with the gastric closure, for management of complications and regarding compression syndromes [10]. Endoscope design, conduit access, assist devices, and systems for closure require reengineering and redesign for optimal function in the NOTES setting [46]. This requires industry activity, investment, and interest. Following an initial flurry of interest, active development by industry has fluctuated but remains a critical component to progress.

3.5. Regulations. Multiple regulatory requirements will contribute to the penetrance of NOTES into the general human population. Transitioning to human studies requires IRB oversight and justification in utilizing a NOTES approach over a traditional standard. The risk of a novel procedure must be justified against a presumed potential benefit with a new approach. Similarly, device development is associated with rigorous regulatory requirements. A substantial contribution to the technology needed for NOTES procedures comes from small startup companies [48]. Devices of the past were often approved with the FDA 510 K pathway, and physicians have used devices in nontraditional ways. This system is changing and newer devices are going through the longer, more expensive premarket approval application (PMA) process. Following the PMA process, a procedure or device must pass through the current procedural terminology (CPT) coding pathway, third-party-payer process, and hospital and purchasing requirements [48]. Presently, NOSCAR is encouraging dialogue between the multiple parties. If NOTES continues to show that it is a safe, minimally invasive procedure with faster recovery times and more patient acceptance it may be advantageous to payers and third parties to work towards wider acceptance [48].

3.6. Training. There is considerable debate about who should be trained to perform NOTES among general surgeons, thoracic surgeons, gynecologists, and gastroenterologists. In this paper, the majority of human NOTES procedures were performed by general surgeons. Regardless of the specialty, the operator should have expertise with intra-and extralumenal anatomy, flexible endoscopy, and/or laparoscopy, and undergo specialized training to learn the techniques. As techniques move in and out of the operating room, in and out of the endoscopy suite, and away from or towards the patient's bedside, it becomes less certain which specialist should perform or train in which procedure [29].

4. Conclusion

Natural orifice translumenal endoscopic surgery has progressed to human populations and is evolving for certain indications. Due to practical concerns, much of the initial work has focused on elective procedures. Many NOTES surgeries have redemonstrated laparoscopic procedures which have a high degree of safety and little morbidity. More recent studies have raised the possibility that NOTES may come to offer more substantial improvements over the current standard, going beyond cosmesis and reduced pain medication usage [22]. The studies reviewed here suggest a high degree of safety and feasibility with low rates of infection. As the field progresses, rigorous, prospective, controlled studies will become more important in defining the exact benefits versus a traditional approach [73]. With greater experience in redemonstrating standard procedures, it is hoped that the field will continue to evolve, enabling novel approaches that distinguish the potential for more unique contributions.

Acknowledgment

This work supported by departmental funding.

References

[1] P. Nau, E. C. Ellison, P. Muscarella Jr. et al., "A review of 130 humans enrolled in transgastric NOTES protocols at a single institution," *Surgical Endoscopy*, vol. 25, no. 4, pp. 1004–1011, 2011.

[2] J. Moreira-Pinto, E. Lima, J. Correia-Pinto, and C. Rolanda, "Natural orifice transluminal endoscopy surgery: a review," *World Journal of Gastroenterology*, vol. 17, no. 33, pp. 3795–3801, 2011.

[3] H. Seifert, T. Wehrmann, T. Schmitt, S. Zeuzem, and W. F. Caspary, "Retroperitoneal endoscopic debridement for infected peripancreatic necrosis," *The Lancet*, vol. 356, no. 9230, pp. 653–655, 2000.

[4] A. N. Kalloo, V. K. Singh, S. B. Jagannath et al., "Flexible transgastric peritoneoscopy: a novel approach to diagnostic and therapeutic interventions in the peritoneal cavity," *Gastrointestinal Endoscopy*, vol. 60, no. 1, pp. 114–117, 2004.

[5] B. F. Merrifield, M. S. Wagh, and C. C. Thompson, "Peroral transgastric organ resection: a feasibility study in pigs," *Gastrointestinal Endoscopy*, vol. 63, no. 4, pp. 693–697, 2006.

[6] K. I. Makris, E. Rieder, and L. L. Swanstrom, "Natural orifice trans-luminal endoscopic surgery (NOTES) in thoracic surgery," *Seminars in Thoracic and Cardiovascular Surgery*, vol. 22, no. 4, pp. 302–309, 2010.

[7] F. F. Willingham, D. W. Gee, G. Y. Lauwers, W. R. Brugge, and D. W. Rattner, "Natural orifice transesophageal mediastinoscopy and thoracoscopy," *Surgical Endoscopy*, vol. 22, no. 4, pp. 1042–1047, 2008.

[8] A. M. Donatsky, P. Vilmann, S. Meisner, L. N. Jorgensen, and J. Rosenberg, "Transgastric pure-NOTES peritoneoscopy and endoscopic ultrasonography for staging of gastrointestinal cancers: a survival and feasibility study," *Surgical Endoscopy*. In press.

[9] W. Y. Cho, Y. J. Kim, J. Y. Cho et al., "Hybrid natural orifice transluminal endoscopic surgery: endoscopic full-thickness resection of early gastric cancer and laparoscopic regional lymph node dissection—14 human cases," *Endoscopy*, vol. 43, no. 2, pp. 134–139, 2011.

[10] E. B. Deborah, "ASGE/SAGES Working Group on Natural Orifice Translumenal Endoscopic Surgery: white paper October 2005," *Gastrointestinal Endoscopy*, vol. 63, no. 2, pp. 199–203, 2006.

[11] P. N. Nesargikar and S. S. Jaunoo, "Natural orifice translumenal endoscopic surgery (NOTES)," *International Journal of Surgery*, vol. 7, no. 3, pp. 232–236, 2009.

[12] J. P. Pearl, R. P. Onders, J. M. Marks et al., "Transgastric endoscopic peritoneoscopy in humans under laparoscopic visualization: a bridge to NOTES," *Gastrointestinal Endoscopy*, vol. 65, no. 5, Article ID AB292, 2007.

[13] I. Tarantino, G. R. Linke, J. Lange, I. Siercks, R. Warschkow, and A. Zerz, "Transvaginal rigid-hybrid natural orifice transluminal endoscopic surgery technique for anterior resection treatment of diverticulitis: a feasibility study," *Surgical Endoscopy*, vol. 25, no. 9, pp. 3034–3042, 2011.

[14] T. B. Gardner, N. Coelho-Prabhu, S. R. Gordon et al., "Direct endoscopic necrosectomy for the treatment of walled-off pancreatic necrosis: results from a multicenter U.S. series," *Gastrointestinal Endoscopy*, vol. 73, no. 4, pp. 718–726, 2011.

[15] G. V. Rao and N. Reddy, "Transgastric appendectomy in humans," in *Proceedings of the American Gastrointestinal and Endoscopic Surgeons (SAGES) Conference*, Dallas, Tex, USA, 2006.

[16] R. Zorron, M. Filgueiras, L. C. Maggioni, L. Pombo, G. C. Lopes, and A. O. Lacerda, "NOTES transvaginal cholecystectomy: report of the first case," *Surgical Innovation*, vol. 14, no. 4, pp. 279–283, 2007.

[17] J. Marescaux, B. Dallemagne, S. Perretta, A. Wattiez, D. Mutter, and D. Coumaros, "Surgery without scars: report of transluminal cholecystectomy in a human being," *Archives of Surgery*, vol. 142, no. 9, pp. 823–826, 2007.

[18] C. Palanivelu, P. S. Rajan, M. Rangarajan, R. Parthasarathi, P. Senthilnathan, and M. Prasad, "Transvaginal endoscopic appendectomy in humans: a unique approach to NOTES—world's first report," *Surgical Endoscopy*, vol. 22, no. 5, pp. 1343–1347, 2008.

[19] J. W. Hazey, V. K. Narula, D. B. Renton et al., "Natural-orifice transgastric endoscopic peritoneoscopy in humans: initial clinical trial," *Surgical Endoscopy*, vol. 22, no. 1, pp. 16–20, 2008.

[20] P. Nau, J. Anderson, B. Yuh et al., "Diagnostic transgastric endoscopic peritoneoscopy: extension of the initial human trial for staging of pancreatic head masses," *Surgical Endoscopy*, vol. 24, no. 6, pp. 1440–1446, 2010.

[21] J. F. Noguera, A. Cuadrado, F. M. Sanchez-Margallo et al., "Emergency transvaginal hybrid natural orifice transluminal endoscopic surgery," *Endoscopy*, vol. 43, no. 5, pp. 442–444, 2011.

[22] F. F. Willingham, S. S. Garud, S. S. Davis et al., "Human hybrid endoscopic and laparoscopic management of mass lesions of the foregut(with video)," *Gastrointestinal Endoscopy*, vol. 75, no. 4, pp. 905–912, 2012.

[23] R. Zorron, C. Palanivelu, M. P. Galvao Neto et al., "International multicenter trial on clinical natural orifice surgery-Notes IMTN study: preliminary results of 362 patients," *Surgical Innovation*, vol. 17, no. 2, pp. 142–158, 2010.

[24] K. S. Lehmann, J. P. Ritz, A. Wibmer et al., "The German registry for natural orifice translumenal endoscopic surgery: report of the first 551 patients," *Annals of Surgery*, vol. 252, no. 2, pp. 263–270, 2010.

[25] L. L. Swanstrom, E. Volckmann, E. Hungness, and N. J. Soper, "Patient attitudes and expectations regarding natural orifice translumenal endoscopic surgery," *Surgical Endoscopy*, vol. 23, no. 7, pp. 1519–1525, 2009.

[26] S. Varadarajulu, A. Tamhane, and E. R. Drelichman, "Patient perception of natural orifice transluminal endoscopic surgery as a technique for cholecystectomy," *Gastrointestinal Endoscopy*, vol. 67, no. 6, pp. 854–860, 2008.

[27] P. Bucher, S. Osterman, F. Pugin et al., "Female population peception of conventional laparoscopy, transumbilical LESS, and transvaginal NOTES for cholecystectomy," *Surgical Endoscopy*, vol. 25, no. 7, pp. 2308–2315, 2011.

[28] A. K. Tsao and T. D. Averch, "The history of NOTES," *Journal of Endourology*, vol. 23, no. 5, pp. 727–731, 2009.

[29] B. J. Dunkin, "Natural orifice transluminal endoscopic surgery: educational challenge," *World Journal of Gastrointestinal Surgery*, vol. 2, no. 6, pp. 224–230, 2010.

[30] D. W. Bratzler and P. M. Houck, "Antimicrobial prophylaxis for surgery: an advisory statement from the National Surgical Infection Prevention Project," *The American Journal of Surgery*, vol. 189, no. 4, pp. 395–404, 2005.

[31] J. M. Marks, J. L. Ponsky, J. P. Pearl, and M. F. McGee, "PEG "rescue": a practical NOTES technique," *Surgical Endoscopy*, vol. 21, no. 5, pp. 816–819, 2007.

[32] R. Zorron, M. Soldan, M. Filgueiras, C. L. Maggioni, L. Pombo, and A. L. Oliveira, "NOTES: transvaginal for cancer

diagnostic staging: preliminary clinical application," *Surgical Innovation*, vol. 15, no. 3, pp. 161–165, 2008.

[33] A. C. Ramos, N. Zundel, M. G. Neto, and M. Maalouf, "Human hybrid NOTES transvaginal sleeve gastrectomy: initial experience," *Surgery for Obesity and Related Diseases*, vol. 4, no. 5, pp. 660–663, 2008.

[34] J. Bernhardt, B. Gerber, H. C. Schober, G. Kahler, and K. Ludwig, "NOTES—case report of a unidirectional flexible appendectomy," *International Journal of Colorectal Disease*, vol. 23, no. 5, pp. 547–550, 2008.

[35] A. M. Lacy, S. Delgado, O. A. Rojas, R. Almenara, A. Blasi, and J. Llach, "MA-NOS radical sigmoidectomy: report of a transvaginal resection in the human," *Surgical Endoscopy*, vol. 22, no. 7, pp. 1717–1723, 2008.

[36] J. Burghardt, M. Federlein, V. Muller, T. Benhidjeb, D. Elling, and K. Gellert, "Minimal invasive transvaginal right hemicolectomy: report of the first complex NOS (natural orifice surgery) Bowels operation using a hybrid approach," *Zentralblatt fur Chirurgie*, vol. 133, no. 6, pp. 574–576, 2008.

[37] L. J. Fischer, G. Jacobsen, B. Wong et al., "NOTES laparoscopic-assisted transvaginal sleeve gastrectomy in humans-description of preliminary experience in the United States," *Surgery for Obesity and Related Diseases*, vol. 5, no. 5, pp. 633–636, 2009.

[38] J. E. Sanchez, S. H. Rasheid, B. R. Krieger, J. C. Frattini, and J. E. Marcet, "Laparoscopic-assisted transvaginal approach for sigmoidectomy and rectocolpopexy," *Journal of the Society of Laparoendoscopic Surgeons*, vol. 13, no. 2, pp. 217–220, 2009.

[39] E. M. Targarona, C. Gomez, R. Rovira et al., "NOTES-assisted transvaginal splenectomy: the next step in the minimally invasive approach to the spleen," *Surgical Innovation*, vol. 16, no. 3, pp. 218–222, 2009.

[40] J. H. Kaouk, W. M. White, R. K. Goel et al., "NOTES transvaginal nephrectomy: first human experience," *Urology*, vol. 74, no. 1, pp. 5–8, 2009.

[41] J. H. Kaouk, G. P. Haber, R. K. Goel et al., "Pure natural orifice translumenal endoscopic surgery (NOTES) transvaginal nephrectomy," *European Urology*, vol. 57, no. 4, pp. 723–726, 2010.

[42] K. Nakajima, T. Nishida, T. Takahashi et al., "Partial gastrectomy using natural orifice translumenal endoscopic surgery (NOTES) for gastric submucosal tumors: early experience in humans," *Surgical Endoscopy*, vol. 23, no. 12, pp. 2650–2655, 2009.

[43] G. R. Jacobsen, K. Thompson, A. Spivack et al., "Initial experience with transvaginal incisional hernia repair," *Hernia*, vol. 14, no. 1, pp. 89–91, 2010.

[44] R. Pallapothu, D. B. Earle, D. J. Desilets, and J. R. Romanelli, "NOTES stapled cystgastrostomy: a novel approach for surgical management of pancreatic pseudocysts," *Surgical Endoscopy*, vol. 25, no. 3, pp. 883–889, 2011.

[45] V. C. Memark, J. B. Anderson, P. N. Nau et al., "Transgastric endoscopic peritoneoscopy does not lead to increased risk of infectious complications," *Surgical Endoscopy*, vol. 25, no. 7, pp. 2186–2191, 2011.

[46] V. K. Narula, L. C. Happel, K. Volt et al., "Transgastric endoscopic peritoneoscopy does not require decontamination of the stomach in humans," *Surgical Endoscopy*, vol. 23, no. 6, pp. 1331–1336, 2009.

[47] G. V. Rao, D. N. Reddy, and R. Banerjee, "NOTES: human Experience," *Gastrointestinal Endoscopy Clinics of North America*, vol. 18, no. 2, pp. 361–370, 2008.

[48] D. W. Rattner, R. Hawes, S. Schwaitzberg, M. Kochman, and L. Swanstrom, "The second SAGES/ASGE white paper on natural orifice transluminal endoscopic surgery: 5 years of progress," *Surgical Endoscopy*, vol. 25, no. 8, pp. 2441–2448, 2011.

[49] A. A. Gumbs, D. Fowler, L. Milone et al., "Transvaginal natural orifice translumenal endoscopic surgery cholecystectomy: early evolution of the technique," *Annals of Surgery*, vol. 249, no. 6, pp. 908–912, 2009.

[50] M. Bessler, P. D. Stevens, L. Milone, M. Parikh, and D. Fowler, "Transvaginal laparoscopically assisted endoscopic cholecystectomy: a hybrid approach to natural orifice surgery," *Gastrointestinal Endoscopy*, vol. 66, no. 6, pp. 1243–1245, 2007.

[51] A. J. Branco Filho, R. W. Noda, W. Kondo, N. Kawahara, M. Rangel, and A. W. Branco, "Initial experience with hybrid transvaginal cholecystectomy," *Gastrointestinal Endoscopy*, vol. 66, no. 6, pp. 1245–1248, 2007.

[52] C. Zornig, A. Emmermann, H. A. von Waldenfels, and H. Mofid, "Laparoscopic cholecystectomy without visible scar: combined transvaginal and transumbilical approach," *Endoscopy*, vol. 39, no. 10, pp. 913–915, 2007.

[53] R. Zorron, L. C. Maggioni, L. Pombo, A. L. Oliveira, G. L. Carvalho, and M. Filgueiras, "NOTES transvaginal cholecystectomy: preliminary clinical application," *Surgical Endoscopy*, vol. 22, no. 2, pp. 542–547, 2008.

[54] L. DeCarli, R. Zorron, A. Branco et al., "Natural orifice translumenal endoscopic surgery (NOTES) transvaginal cholecystectomy in a morbidly obese patient," *Obesity Surgery*, vol. 18, no. 7, pp. 886–889, 2008.

[55] A. C. Ramos, A. H. F. Murakami, M. Galvao Neto et al., "NOTES transvaginal video-assisted cholecystectomy: first series," *Endoscopy*, vol. 40, no. 7, pp. 572–575, 2008.

[56] C. Palanivelu, P. S. Rajan, M. Rangarajan et al., "NOTES: transvaginal endoscopic cholecystectomy in humans—preliminary report of a case series," *American Journal of Gastroenterology*, vol. 104, no. 4, pp. 843–847, 2009.

[57] J. Noguera, C. Dolz, A. Cuadrado, J. Olea, A. Vilella, and R. Morales, "Hybrid transvaginal cholecystectomy, NOTES, and minilaparoscopy: analysis of a prospective clinical series," *Surgical Endoscopy*, vol. 23, no. 4, pp. 876–881, 2009.

[58] A. L. Decarli, R. Zorron, A. Branco et al., "New hybrid approach for NOTES transvaginal cholecystectomy: preliminary clinical experience," *Surgical Innovation*, vol. 16, no. 2, pp. 181–186, 2009.

[59] F. Davila, D. A. Tsin, G. Dominguez, U. Davila, R. Jesus, and A. G. de Arteche, "Transvaginal cholecystectomy without abdominal ports," *Journal of the Society of Laparoendoscopic Surgeons*, vol. 13, no. 2, pp. 213–216, 2009.

[60] S. Horgan, J. P. Cullen, M. A. Talamini et al., "Natural orifice surgery: initial clinical experience," *Surgical Endoscopy*, vol. 23, no. 7, pp. 1512–1518, 2009.

[61] C. Zornig, H. Mofid, L. Siemssen et al., "Transvaginal NOTES hybrid cholecystectomy: feasibility results in 68 cases with mid-term follow-up," *Endoscopy*, vol. 41, no. 5, pp. 391–394, 2009.

[62] G. Salinas, L. Saavedra, H. Agurto et al., "Early experience in human hybrid transgastric and transvaginal endoscopic cholecystectomy," *Surgical Endoscopy*, vol. 24, no. 5, pp. 1092–1098, 2010.

[63] M. Federlein, D. Borchert, V. Muller et al., "Transvaginal video-assisted cholecystectomy in clinical practice," *Surgical Endoscopy*, vol. 24, no. 10, pp. 2444–2452, 2010.

[64] M. Kilian, W. Raue, C. Menenakos, B. Wassersleben, and J. Hartmann, "Transvaginal-hybrid vs. single-port-access vs. "conventional" laparoscopic cholecystectomy: a prospective

observational study," *Langenbeck's Archives of Surgery*, vol. 396, no. 5, pp. 709–715, 2011.

[65] J. Niu, W. Song, M. Yan et al., "Transvaginal laparoscopically assisted endoscopic cholecystectomy: preliminary clinical results for a series of 43 cases in China," *Surgical Endoscopy*, vol. 25, no. 4, pp. 1281–1286, 2011.

[66] A. Cuadrado-Garcia, J. F. Noguera, J. M. Olea-Martinez et al., "Hybrid natural orifice transluminal endoscopic cholecystectomy: prospective human series," *Surgical Endoscopy*, vol. 25, no. 1, pp. 19–22, 2011.

[67] B. Dallemagne, S. Perretta, P. Allemann, M. Asakuma, and J. Marescaux, "Transgastric hybrid cholecystectomy," *British Journal of Surgery*, vol. 96, no. 10, pp. 1162–1166, 2009.

[68] E. D. Auyang, E. S. Hungness, K. Vaziri, J. A. Martin, and N. J. Soper, "Human notes cholecystectomy: transgastric hybrid technique," *Journal of Gastrointestinal Surgery*, vol. 13, no. 6, pp. 1149–1150, 2009.

[69] M. B. Ujiki, D. V. Martinec, T. S. Diwan, P. M. Denk, C. M. Dunst, and L. L. Swanstrom, "Natural orifice translumenal endoscopic surgery (NOTES): creation of a gastric valve for safe and effective transgastric surgery in humans," *Surgical Endoscopy*, vol. 24, no. 1, article 220, 2010.

[70] M. Nikfarjam, M. F. McGee, J. A. Trunzo et al., "Transgastric natural-orifice transluminal endoscopic surgery peritoneoscopy in humans: a pilot study in efficacy and gastrotomy site selection by using a hybrid technique," *Gastrointestinal Endoscopy*, vol. 72, no. 2, pp. 279–283, 2010.

[71] P. O. Park and M. Bergstrom, "Transgastric peritoneoscopy and appendectomy: thoughts on our first experience in humans," *Endoscopy*, vol. 42, no. 1, pp. 81–84, 2010.

[72] M. Michalik, M. Orlowski, M. Bobowicz, A. Frask, and A. Trybull, "The first report on hybrid NOTES adjustable gastric banding in human," *Obesity Surgery*, vol. 21, no. 4, pp. 524–527, 2011.

[73] F. F. Willingham and W. R. Brugge, "Taking NOTES: translumenal flexible endoscopy and endoscopic surgery," *Current Opinion in Gastroenterology*, vol. 23, no. 5, pp. 550–555, 2007.

Hindawi Publishing Corporation
Minimally Invasive Surgery
Volume 2012, Article ID 365814, 6 pages
doi:10.1155/2012/365814

Research Article

Natural Orifice Translumenal Endoscopic Surgery for Anterior Spinal Procedures

Priscilla Magno,[1,2] Mouen A. Khashab,[2] Manuel Mas,[3] Samuel A. Giday,[2] Jonathan M. Buscaglia,[2] Eun Ji Shin,[2] Xavier Dray,[4] and Anthony N. Kalloo[2]

[1] *Division of Gastroenterology and Hepatology, University of Puerto Rico School of Medicine, San Juan, PR 00936, USA*
[2] *Division of Gastroenterology and Hepatology, Johns Hopkins Hospital, 600 N. Wolfe Street, Blalock 465, Baltimore, MD 21287, USA*
[3] *Department of Surgery, University of Puerto Rico School of Medicine, San Juan, PR 00936, USA*
[4] *Department of Digestive Diseases, Lariboisière Hospital, AP-HP, Paris, France*

Correspondence should be addressed to Anthony N. Kalloo, akalloo@jhmi.edu

Received 16 October 2011; Revised 26 December 2011; Accepted 27 March 2012

Academic Editor: Silvana Perretta

Background. NOTES techniques allow transesophageal access to the mediastinum. The aim of this study was to assess the feasibility of transesophageal biopsy of thoracic vertebrae. *Methods*. Nonsurvival experiments on four 50-kg porcine animals were performed. Transesophageal access to the mediastinum was attained using submucosal tunneling technique. *Results*. The posterior mediastinum was successfully accessed and navigated in all animals. Vertebral bodies and intervertebral spaces were easily approached while avoiding damage to adjacent vessels. Bone biopsy was successfully performed without complications, but the hardness of bone tissue resulted in small and fragmented samples. *Conclusions*. Peroral transesophageal access into the posterior mediastinum and thoracic vertebral bone biopsy was feasible and safe. The proximity of the esophagus to the vertebral column provides close and direct access to the thoracic spine and opens up new ground for the performance of multilevel anterior spine procedures using NOTES techniques.

1. Introduction

Natural orifice transluminal endoscopic surgery (NOTES) has gained a great deal of attention from gastroenterologists and surgeons all over the world since its introduction in 2000 [1]. Interest in NOTES procedures within the thoracic cavity is gaining momentum [2–7].

Transesophageal approach into the mediastinum has been successfully performed in animal and cadaveric models via endoscopic full thickness incision of the esophageal wall, submucosal endoscopy techniques or assisted by endoscopic ultrasound (EUS) [7, 8]. Transesophageal NOTES enables access into the posterior mediastinum with visualization of the descending thoracic aorta, esophagus, trachea, pleura, lung, vagus nerves, and hilar lymph nodes [9]. The excellent visualization of these structures has allowed for a variety of transesophageal mediastinal NOTES interventions including mediastinal lymph node resection, vagotomy, thoracic duct ligation, thymectomy, biopsy of the lung and pleura, epicardial coagulation, saline injection into the myocardium, and pericardial fenestration [4, 5, 7].

Transesophageal NOTES is still in its infancy. However, its potential clinical applications deserve commitment from NOTES researchers to further investigate potential novel applications for transesophageal NOTES. The proximity of the esophagus to the vertebral column provides a closer and direct access to the thoracic spine and opens a new ground for multilevel anterior spine procedures using NOTES techniques. Furthermore, a NOTES approach to the spine could potentially avoid complications of conventional surgical techniques such as postsurgical neuralgia, rib resections, muscular atrophy, and trauma [10]. The aim of this study is to assess the feasibility of transesophageal thoracic spine interventions in a porcine model. We report the first transesophageal anterior spinal approach of multiple thoracic vertebrae using NOTES techniques.

2. Methods

This study was approved by the University of Puerto Rico Animal Care Institutional Review Board. Acute nonsurvival experiments were performed on four 50 kg pigs (*Sus scrofus domesticus*) under 1.5% to 2% isoflurane general anesthesia with 7.0 mm endotracheal intubation (Mallinckrodt Co, C.D. Juarez, Chihuahua, Mexico). Prior to endoscopy, all pigs were fasted overnight with unrestricted access to water. Pre-anesthesia medications consisted of an intramuscular injection of 100 mg/mL Telazol (tiletamine HCL + zolazepam HCL; Lederle Parenterals, Inc, Carolina, PR) reconstituted with 100 mg/mL ketamine HCL and 100 mg/mL xylazine at a total dose of approximately 0.05 cc/kg. An intravenous (IV) line (18 g Gelco IV catheter, Medex Inc., Carlsbad, CA) was placed in the marginal ear vein, and 1 g thiopental sodium was injected at a dose of 6.6 to 8.8 mg/kg IV.

A forward-viewing double-channel upper endoscope (GIF-2T160; Olympus Optical Co. Ltd., Tokyo, Japan) was passed perorally and advanced to the esophagus. In pigs, the aortic arch is typically visualized at about 35 cm from the snout and the submucosal tunnel was created starting at approximately 25 cm to facilitate forward viewing of the posterior mediastinum [8]. An initial mucosal incision was created in the right esophageal wall using a Huibregtse single-lumen needle knife (Wilson-Cook Medical Inc., Winston-Salem, NC, USA) with a combination of 20 joules coagulation and 30 joules cutting current (Valleylab SSE2L, Boulder, Col). A submucosal tunnel was created using blunt dissection through the mucosal incision with the tip of a needle knife catheter. The endoscope was introduced into the submucosal space and the channel was extended 5–7 centimeters distally toward the gastroesophageal junction where a full-thickness incision through the muscular layers was completed with a needle knife. The endoscope was passed into the posterior mediastinum and the pig was changed into prone position. Air insufflation was turned off upon entrance into the mediastinum to avoid tension pneumothorax and tension pneumomediastinum while lung ventilation, capnography, pulse oximetry, and heart rate were closely monitored throughout the experiments [3].

The mediastinal compartment, pleura, lung, and the exterior surface of the esophagus were identified immediately after passing the endoscope through the completed myotomy. The anterior thoracic spine, descending aorta, azygous vein, esophagus, chest wall, and superior diaphragmatic surface were examined after placing the pig in prone position and advancing the endoscope in both the forward and retroflexed positions. A lateral decubitus position was evaluated in the process of changing the animals into prone position. However, the fall of the dorsal regions of the lung (lung from the opposite side of decubitus) still interfered with visualization and navigation in the thoracic cavity. Therefore, mediastinoscopy was performed while animals were in prone position. Using the needle knife, small incisions were made through the anterior longitudinal ligament at the level of the proximal, middle, and distal thoracic spine. Vertebral bodies, intervertebral space, and vessels were examined. Vertebral bone biopsy was performed using a 19 gauge needle (Cook Medical, Winston-Salem, NC) or endoscopic biopsy forceps. The needle was advanced into three vertebral bodies (T4, T8, T12) and intervertebral spaces under fluoroscopic monitoring (GE Medical Systems, Milwaukee, WI).

The endoscope was withdrawn from the mediastinum into the esophagus through the submucosal tunnel. The mucosal flap sealed the submucosal tunnel and the mucosal incision was closed with two T-bars (Cook Medical, Winston-Salem, NC). The animals were sacrificed at the end of the procedure for immediate post-mortem examination.

3. Results

We performed acute experiments in four porcine models. Submucosal tunnel was successfully performed in all four pigs as described above and successful access to the mediastinum was attained without injury to any surrounding structures. After passing the endoscope through the completed myotomy, immediate and excellent visualization of lungs, pleura, and margins of the adventitial side of the esophagus were obtained (Figures 1(a)–1(c)). The mediastinal pleura was visualized on each side of the posterior mediastinum overlying the lungs and was not breached. The median time for completion of the transesophageal access was 12 minutes (range, 8–16 minutes).

The posterior mediastinum was evaluated in all animals with no immediate complications. Changing the pig position from supine to prone allowed for spectacular visualization of the entire anterior thoracic spine, descending thoracic aorta, ribs, and the esophagus (Figures 2(a)-2(b)). Further changes in the pigs' position or manipulation of single-lung ventilation were not required to maintain adequate endoscopic visualization during spinal interventions.

Transesophageal interventions in the thoracic spine were successful in all animals. The incision through the anterior longitudinal ligament and subsequent exposure of vertebral bone tissue and intervertebral spaces at the level of the proximal, middle, and distal thoracic spine were successfully completed while avoiding damage to the adjacent vessels. Bone biopsies were successfully obtained from selected thoracic vertebral bodies (T4, T8, T12). Fluoroscopy was used to confirm precise vertebral location. However, the hardness of cortical bone tissue resulted in fragmented bone samples using both forceps and needles, and limited the insertion of the 19 gauge needle to approximately one centimeter into the vertebra as seen under fluoroscopy (Figures 3(a)–3(c)). After 4-5 attempts, the 19 gauge needle was inserted under fluoroscopy guidance approximately one centimeter into the vertebra. Once inserted within the vertebral body and visualized in place under fluoroscopy, the 19 g needle was withdrawn and flushed with water to obtain the specimen. The specimen consisted of fragmented particles (1–3 fragments). These particles were visually inspected and palpated to confirm the presence of bone particles as a measure of sample adequacy (the purpose was to assess the presence or absence of bone material). The median time for entire procedure was 77 minutes (range, 52–93 minutes).

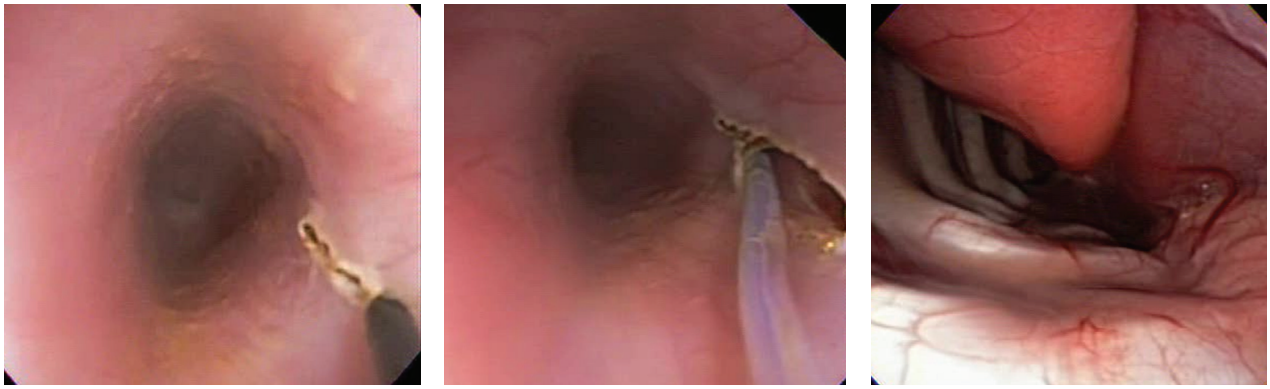

(a) (b) (c)

Figure 1: Transesophageal access. (a) Esophageal wall incision. (b) Submucosal tunnel. (c) Visualization of the lung, pleural, aorta, thoracic spine, and esophagus in forward scope position.

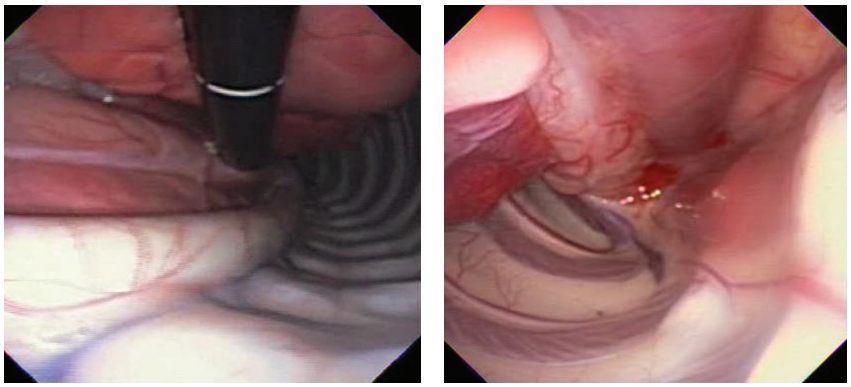

(a) (b)

Figure 2: Mediastinoscopy. Retroflexed endoscopic views at (a) distal and (b) proximal thoracic spine.

There were no hemodynamic complications during transesophageal access and interventions in the thoracic spine. All animals remained stable throughout the experiment and displayed no changes in hemodynamic parameters or oxygen saturation while completing incisions in the anterior longitudinal ligaments or vertebral bone biopsies. Necropsy revealed no injury to mediastinal organs or vessels resulting from mediastinoscopy, bone biopsy or esophagotomy closure with T-bars. Harvesting of bone fragments was not performed.

4. Discussion

Transesophageal NOTES has not garnered as much interest as other approaches for NOTES. There is much more to learn about this technique and its potential applications. The use of a transesophageal NOTES approach for anterior spinal procedures is an innovative technique with the potential for clinical application. Prior experience with submucosal tunneling [8] and peroral endoscopic myotomy (POEM) has suggested safety of such an approach [11, 12]. Access strategies for surgical interventions in the thoracic spine most commonly include thoracotomy, costovertebral, posterolateral, and transpedicular percutaneous approaches [13–16]. Open surgical techniques to expose the spine require the separation of musculoskeletal structures and traction of nerve roots to create an access large enough to accommodate surgical tools. The morbidities associated with these strategies include postsurgical neuralgia resulting from traction injuries to nerve roots, lacerations of the dura mater, scars from skin incisions, wound infection, and muscular atrophy or trauma [16, 17].

Minimally invasive approaches to the thoracic and thoracolumbar spine, such as video-assisted thoracoscopic surgery (VATS), allow the performance of anterior approaches to the spine with small transthoracic incisions or portals [17, 18]. These portals have reduced the size of percutaneous incisions with less muscular dissection and chest wall disruption, all of which contribute to a faster recovery from surgery. Nevertheless, the consequences of a percutaneous access are not totally avoided and patients often require hospital stay following the procedure. Lung atelectasis, empyema, and retropleural effusions are additional morbidities often reported after VATS procedures [18, 19].

The proximity of the esophagus to the vertebral column provides close and direct access to the thoracic spine and

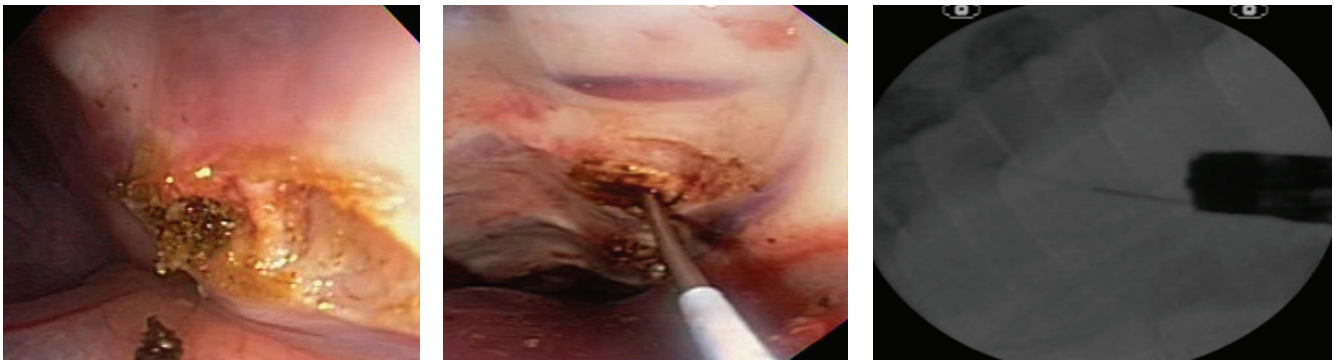

(a) (b) (c)

Figure 3: Transesophageal approach to the anterior thoracic spine. (a) Incision over the anterior longitudinal ligament and exposure of the intravertebral space and vertebral bone. (b) Insertion of the 19 gauge needle in the thoracic vertebrae. (c) Fluoroscopic view of vertebral bone biopsy.

opens up new ground for the performance of multilevel anterior spine procedures through NOTES techniques. In this study, the esophageal submucosal endoscopy technique was used to access the posterior mediastinum and to prevent mediastinal soiling in all animals. Although submucosal saline injections or endoscopic mucosal resection (EMR) caps were not utilized, a careful superficial incision in the mucosa followed by blunt dissection of the submucosal layer resulted in a safe entry into the mediastinum with no resulting complications. Selection of the entry site in the right esophageal wall of the proximal to mid esophagus was determined by following known anatomical structures around the esophagus in order to avoid puncture of the aorta or the heart located behind the left or left posterior esophageal wall or the azygous vein behind the right-posterior wall.

Navigation within the thoracic cavity was performed under mechanically-assisted lung ventilation with the endoscopy air pump off. Given that intramediastinal pressures were not monitored, avoiding inadvertent room air insufflation into the thoracic cavity prevented potential complications from positive intramediastinal pressures such as an acute lung or hemodynamic collapse. The gasless approach did not limit access and navigation of the mediastinum or approach to the thoracic spine. It is uncertain if a low-pressure or pressure limited pneumomediastinum could improve exposure even in supine position. This technique could be evaluated in future experiments. More importantly, the use of laparoscopic insufflators for pressure control (intrathoracic pressure monitoring) is an additional safety parameter that must be used in future transesophageal NOTES experiments. None of the animals required intraoperative chest tube placement or suffered cardiovascular complications during the experiment. However, in agreement with other investigators [7, 8], further studies should monitor intrathoracic pressures, ventilation volumes and pressures or insufflation of CO2 as safety parameters while performing transesophageal NOTES interventions in the mediastinum.

Changing the pig position from supine to prone facilitated the visualization of the entire anterior thoracic spine and surrounding structures. Prone position resulted in the fall of the dorsal regions of the lungs into a dependent position away from the vertebral column while keeping both lungs under assisted mechanical ventilation. Adequate visualization was maintained without need for further position changes or single-lung ventilation. In contrast, accessing other areas in the thoracic cavity, such as a left-sided approach to the heart, would still require single-lung ventilation for optimal visualization [7].

In this study, the anterior vertebral bodies and intervertebral spaces were easily approached at different levels of the thoracic spine without injury to the adjacent vessels. Incisions in the anterior longitudinal ligament and vertebral bone biopsy were safely performed under direct endoscopic observation. However, some technical challenges were encountered during vertebral bone biopsy. First, the hardness of the cortical bone of vertebral bodies limited the introduction of the 19-gauge needle to approximately one centimeter into the vertebral bone as observed under fluoroscopy. In addition, the hardness of the cortical bone resulted in small and fragmented tissue samples obtained through both endoscopic forceps and needles. Future development of endoscopic accessories dedicated to bone tissue interventions will be necessary to facilitate sampling or extraction of bone tissue via NOTES techniques. Second, retroflexed position of the endoscope in the posterior mediastinum resulted in a tangential orientation to the spine, which made needle insertion into the vertebral bodies more technically demanding. A side-viewing endoscope can potentially allow an en-face approach to the spine, but this endoscope was not evaluated in the study. In the future, a steerable overtube with variable stiffness technology or a multibending endoscope may reduce tangential orientations and avoid the use of multiple endoscopes in mediastinal NOTES procedures.

A transesophageal approach to the vertebral column has the potential for the development of novel interventions in the anterior thoracic spine under direct endoscopic observation. Examples of these innovative procedures include endoscopic aspiration and biopsy of vertebral bodies when infection or malignant infiltration is suspected and the

source of infection or metastasis is unknown; vertebroplasty and kyphoplasty for vertebral compression fractures due to osteoporosis or malignancy; intradiscal therapies such as electrothermal annuloplasty or pulsed radiofrequency ablations for chronic low back pain; and release of the anterior longitudinal ligament at different levels of the vertebral column for severe scoliosis.

The advantages of NOTES for spinal interventions are similar to those of anterior laparoscopic spinal surgery but without the limitations of rigid instrumentation. These benefits include maintenance and ease of restoration of intervertebral disc height, avoidance of removal of bone from the spine, which is an integral component of posterior spinal surgery, and preservation of normal spinal anatomy since this approach takes advantage of normal tissue planes with no removal of bone tissue. In addition, the complications of posterior spinal surgery, such as nerve injury due to manipulation, retraction, and hematoma formation around nerves, and which may cause scarring and chronic pain, can be avoided [20]. Potential disadvantages of transesophageal NOTES include risk of mediastinitis and iatrogenic injury to major vessels and pleura resulting in massive hemorrhage, and tension pneumomediastinum, respectively. Contamination protocols and cultures are a major consideration in spine surgery. Given that the purpose of these nonsurvival experiments was only to assess the feasibility of a transesophageal biopsy of the thoracic vertebrae, infection prevention measures were not followed. Contamination protocols and cultures will be paramount in future survival NOTES experiments in spine surgery.

This initial *in vivo* nonsurvival study reports the first transesophageal intervention in the thoracic spine and proves the feasibility of this novel approach. Esophageal submucosal endoscopy and prone positioning allowed for safe access to the mediastinum and excellent visualization of the vertebral column. The release of the anterior longitudinal ligament, biopsy of multiple vertebral bodies, and exposure intervertebral spaces via NOTES techniques were feasible and safe. The proximity of the esophagus to the vertebral column is favorable for developing novel NOTES spinal interventions.

Disclosure

A. Kalloo is a Founding member, Equity Holder, and Consultant for Apollo Endosurgery. M. Khashab is a consultant for Boston Scientific.

Conflict of Interests

All authors have no conflict of interests to disclose.

References

[1] A. N. Kalloo, S. V. Kantsevoy, V. K. Singh et al., "Flexible transgastric peritoneoscopy: a novel approach to diagnostic and therapeutic interventions in the peritoneal cavity," *Gastrointestinal Endoscopy*, vol. 118, p. A1039, 2000.

[2] T. Woodward, D. McCluskey 3rd, M. B. Wallace, M. Raimondo, J. Mannone, and C. D. Smith, "Pilot study of transesophageal endoscopic surgery: NOTES esophagomyotomy, vagotomy, lymphadenectomy," *Journal of Laparoendoscopic and Advanced Surgical Techniques*, vol. 18, no. 5, pp. 743–745, 2008.

[3] D. W. Gee, F. F. Willingham, G. Y. Lauwers, W. R. Brugge, and D. W. Rattner, "Natural orifice transesophageal mediastinoscopy and thoracoscopy: a survival series in swine," *Surgical Endoscopy and Other Interventional Techniques A*, vol. 22, no. 10, pp. 2117–2122, 2008.

[4] F. F. Willingham, D. W. Gee, G. Y. Lauwers, W. R. Brugge, and D. W. Rattner, "Natural orifice transesophageal mediastinoscopy and thoracoscopy," *Surgical Endoscopy and Other Interventional Techniques*, vol. 22, no. 4, pp. 1042–1047, 2008.

[5] A. Fritscher-Ravens, K. Patel, A. Ghanbari et al., "Natural orifice transluminal endoscopic surgery (NOTES) in the mediastinum: long-term survival animal experiments in transesophageal access, including minor surgical procedures," *Endoscopy*, vol. 39, no. 10, pp. 870–875, 2007.

[6] B. G. Turner, D. W. Gee, S. Cizginer et al., "Endoscopic transesophageal mediastinal lymph node dissection and en bloc resection by using mediastinal and thoracic approaches (with video)," *Gastrointestinal Endoscopy*, vol. 72, no. 4, pp. 831–835, 2010.

[7] K. Sumiyama, C. J. Gostout, E. Rajan et al., "Pilot study of transesophageal endoscopic epicardial coagulation by submucosal endoscopy with the mucosal flap safety valve technique (with videos)," *Gastrointestinal Endoscopy*, vol. 67, no. 3, pp. 497–501, 2008.

[8] K. Sumiyama, C. J. Gostout, E. Rajan, T. A. Bakken, M. A. Knipschield, and R. J. Marler, "Submucosal endoscopy with mucosal flap safety valve," *Gastrointestinal Endoscopy*, vol. 65, no. 4, pp. 688–694, 2007.

[9] T. A. Woodward, L. H. Jamil, and M. B. Wallace, "Natural orifice trans-luminal endoscopic surgery in the esophagus," *Gastrointestinal Endoscopy Clinics of North America*, vol. 20, no. 1, pp. 123–138, 2010.

[10] I. Nagahiro, A. Andou, M. Aoe, Y. Sano, H. Date, an N. Shimizu, "Pulmonary function, postoperative pain, and serum cytokine level after lobectomy: a comparison of VATS and conventional procedure," *Annals of Thoracic Surgery*, vol. 72, no. 2, pp. 362–365, 2001.

[11] P. Pasricha, R. Hawari, I. Ahmed et al., "Submucosal endoscopic esophageal myotomy: a novel experimental approach for the treatment of achalasia," *Gastrointestinal Endoscopy*, vol. 65, no. 5, p. AB92, 2007.

[12] H. Inoue, H. Minami, Y. Kobayashi et al., "Peroral endoscopic myotomy (POEM) for esophageal achalasia," *Endoscopy*, vol. 42, no. 4, pp. 265–271, 2010.

[13] K. Das, A. Rawanduzy, and W. T. Couldwell, "Posterolateral approach for decompression with anterior and posterior fusion: a less invasive surgical technique for stabilization of the thoracic spine. Case report," *Neurosurgical Focus*, vol. 4, no. 2, p. e3, 1998.

[14] M. H. Bilsky, "Transpedicular approach for thoracic disc herniations," *Neurosurgical Focus*, vol. 9, no. 4, p. e3, 2000.

[15] S. Mulier and V. Debois, "Thoracic disc herniations: transthoracic, lateral, or posterolateral approach? A review," *Surgical Neurology*, vol. 49, no. 6, pp. 599–608, 1998.

[16] W. E. McCormick, S. F. Will, and E. C. Benzel, "Surgery for thoracic disc disease. Complication avoidance: overview and management," *Neurosurgical Focus*, vol. 9, no. 4, p. e13, 2000.

[17] R. A. Lehman Jr., A. R. Vaccaro, R. Bertagnoli, and T. R. Kuklo, "Standard and minimally invasive approaches to the spine," *Orthopedic Clinics of North America*, vol. 36, no. 3, pp. 281–292, 2005.

[18] J. E. O'Toole, K. M. Eichholz, and R. G. Fessler, "Minimally invasive approaches to vertebral column and spinal cord tumors," *Neurosurgery Clinics of North America*, vol. 17, no. 4, pp. 491–506, 2006.

[19] R. Levin, D. Matusz, A. Hasharoni, C. Schaarf, B. Lonner, and T. Errico, "Mini-open thoracoscopically assisted thoracotomy versus video-assisted thoracoscopic surgery for anterior release in thoracic scoliosis and kyphosis: a comparison of operative and radiographic results," *Spine Journal*, vol. 5, no. 6, pp. 632–638, 2005.

[20] J. Inamasu and B. H. Guiot, "Laparoscopic anterior lumbar interbody fusion: a review of outcome studies," *Minimally Invasive Neurosurgery*, vol. 48, no. 6, pp. 340–347, 2005.

Hindawi Publishing Corporation
Minimally Invasive Surgery
Volume 2012, Article ID 287613, 6 pages
doi:10.1155/2012/287613

Research Article

Update on Transanal NOTES for Rectal Cancer: Transitioning to Human Trials

Dana A. Telem, David L. Berger, Liliana G. Bordeianou, David W. Rattner, and Patricia Sylla

Division of Gastrointestinal Surgery, Massachusetts General Hospital, 15 Parkman Street, Wang 460, Boston, MA 02114, USA

Correspondence should be addressed to Patricia Sylla, psylla@partners.org

Received 13 January 2012; Accepted 21 March 2012

Academic Editor: Silvana Perretta

The feasibility of natural orifice translumenal endoscopic surgery (NOTES) resection for rectal cancer has been demonstrated in both survival swine and fresh human cadaveric models. In preparation for transitioning to human application, our group has performed transanal NOTES rectal resection in a large series of human cadavers. This experience both solidified the feasibility of resection and allowed optimization of technique prior to clinical application. Improvement in specimen length and operative time was demonstrated with increased experience and newer platforms. This extensive laboratory experience has paved the way for successful clinical translation resulting in an ongoing clinical trial. To date, based on published reports, 4 human subjects have undergone successful hybrid transanal NOTES resection of rectal cancer. While promising, instrument limitations continue to hinder a pure transanal approach. Careful patient selection and continued development of new endoscopic and flexible-tip instruments are imperative prior to pure NOTES clinical application.

1. Introduction

Just as laparoscopy resulted in a major paradigm shift in the field of gastrointestinal surgery, NOTES has the potential to be equally as ground breaking and likely represents the next step in the evolution of minimally invasive surgery [1]. Proposed advantages of NOTES include faster recovery time, shorter hospital stays, improved pain control, and avoidance of potential abdominal wall complications including wound infection and hernia [2]. The range of operations under investigation is rapidly increasing. Currently, transvaginal, transgastric, transesophageal, and transanal approaches have been described. The international and national experience now counts several thousand cases of successfully performed hybrid transvaginal NOTES procedures including but not limited to cholecystectomy, nephrectomy, and vertical sleeve gastrectomy [3–9]. Progress however, continues to be hampered by instrument limitations as well as safety concerns regarding NOTES translumenal access, particularly regarding access closure.

Transanal access for colon resection has been proven safe and feasible in both swine and fresh human cadaveric models [10, 11]. The advantages of transanal access for colorectal resection are multiple. First, the availability of well-established platforms such as transanal endoscopic microsurgery (TEM) to gain access to the peritoneal cavity facilitates performance of endorectal and transrectal procedures [12]. Second, creation of the enterotomy though the organ to be resected rather than an otherwise healthy organ obviates concerns regarding safe, reproducible closure associated with other NOTES access points. In 2007, Whiteford et al. described the first transanal NOTES radical sigmoidectomy in human cadavers [13]. Although colon and mesenteric dissection could be technically achieved with use of the TEM platform, difficulties were encountered with mobilization of adequate specimen length secondary to instrument inability to overcome anatomic constraints. While instrument limitations continue to be a barrier to pure application of transanal NOTES resection, this approach has since been optimized in both a swine and fresh human

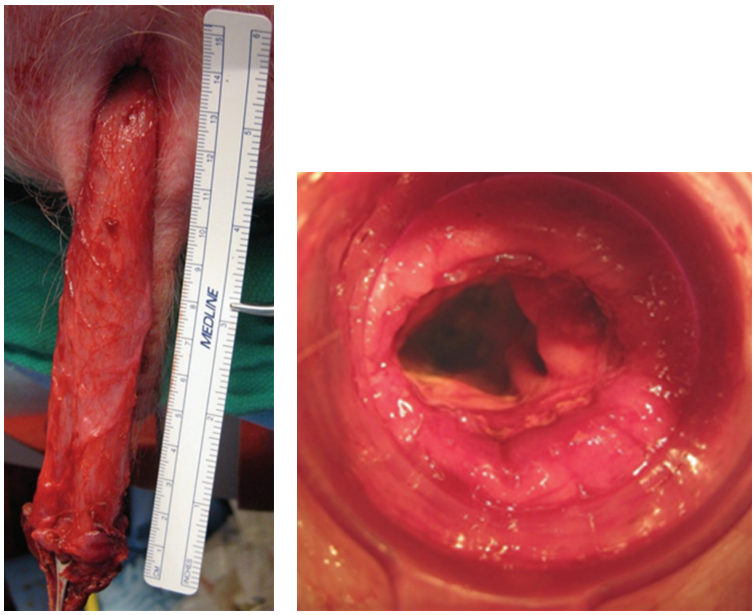

(a) (b)

Figure 1: (a) Tranasanal extraction of specimen following completely NOTES in a swine survival model. (b) Intact stapled coloanal anastomosis following specimen transection.

cadaveric model. Based on this work, human clinical trials are currently underway worldwide [14–16].

The aim of this paper is to provide a review of our experience with transanal NOTES colorectal resection as well as an update on the current status of human clinical trials worldwide.

2. Technique Development

To determine the feasibility of transanal NOTES rectosigmoid resection, a pilot study using a nonsurvival porcine model was performed [11]. Rectosigmoid resection using the TEM platform was replicated in this model. A purse-string suture was placed in the distal rectum to prevent fecal outflow and contamination. Following this, full-thickness incision of the rectal wall was performed. Upon entry into the presacral space, en-bloc resection of the rectosigmoid colon and its mesentery could be performed endoscopically. Once the peritoneal reflection was reached, the peritoneal cavity was entered and dissection of the sigmoid colon continued proximally until anatomic and instrument limitations were encountered. The colon was then pulled out through the anus, transected and a stapled colorectal anastomosis performed. Figures 1(a) and 1(b).

From this nonsurvival model, several key limitations were identified and addressed. First, the sharp angle of the sacral promontory and narrow swine pelvis hindered proximal dissection. In an attempt to overcome these anatomic limitations, a combined transgastric and transanal approach was attempted. While prolonging operative time, dual transanal and transgastric approach improved visualization, retraction, and ultimately mobilization of the proximal colon yielding additional specimen length. The addition of transgastric endoscopic access resulted in an average gain of 5.8 cm in colon length [11]. Other anatomic constraints included the flaccid swine bladder which obscures the rectosigmoid, spiral colon configuration, and lack of a true splenic flexure making proximal colonic mobilization more challenging. To overcome these anatomic challenges, exposure was improved by positioning animals in the Trendelenburg and right lateral decubitus position.

A second impediment centered on technical optimization of the colorectal anastomosis. A stapled colorectal anastomosis was performed in all animals in this series. Following anastomotic inspection the staple line was noted to be incomplete in 2 out of 9 (22%) animals. A small posterior anastomotic defect was identified in each case and believed to be secondary to an incomplete purse-string suture on the open distal rectum. This discovery led to technique modification. A transanal purse string was placed under direct vision using anal retractors, rather than through the proctoscope, with improved results [11].

Despite technical and anatomic limitations, all resected specimens were intact with respect to colon wall and attached mesentery. Given the promising results regarding the feasibility of this approach, the next step involved determining safety of application. A two-week survival study using 20 swines was initiated [10]. This study compared outcomes of pure transanal endoscopic resection versus combined transanal and transgastric rectosigmoid resection as described in the pilot study. All procedures were performed successfully without transabdominal assistance and all specimens were grossly intact with respect to integrity of colonic wall and attached mesentery. The use of transgastric assistance again

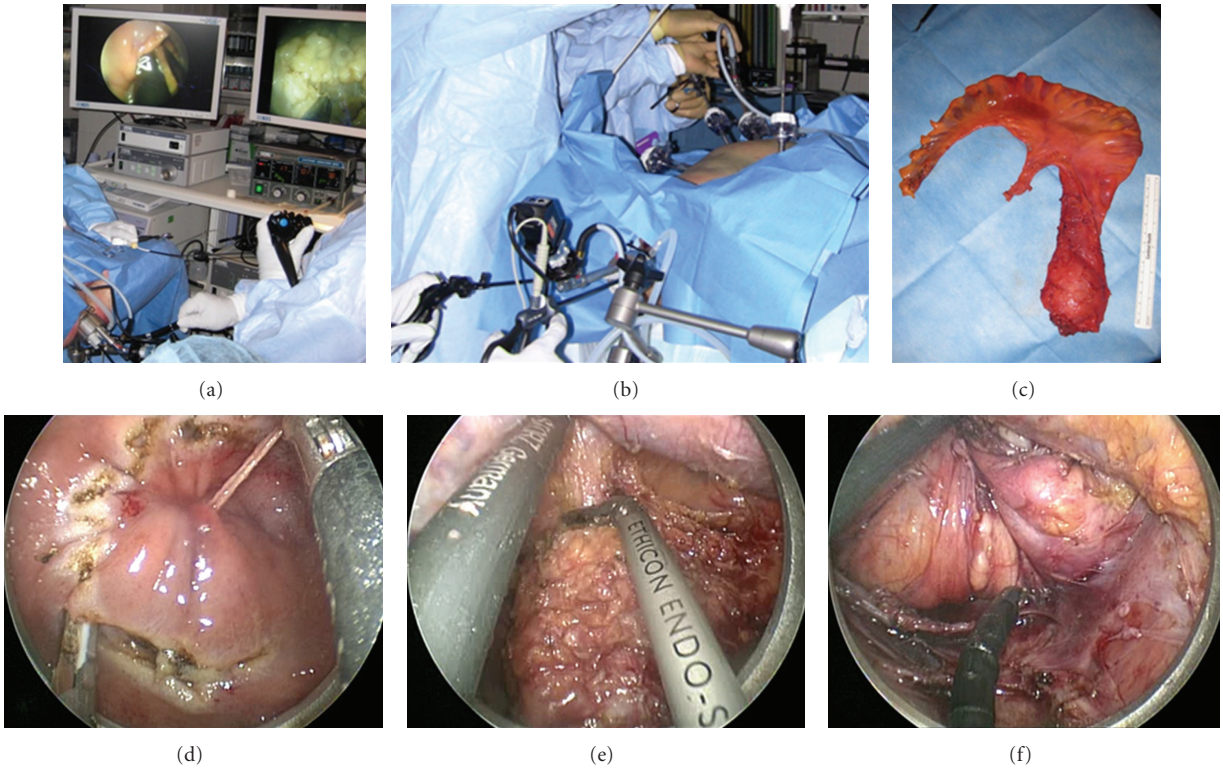

Figure 2: (a) Set up for pure NOTES transanal rectosigmoid resection via TEM using standard instruments and endoscopic tools in cadavers using a colonoscope for visualization. (b) Set up for transanal NOTES rectosigmoid resection with laparoscopic assistance in cadavers. (c) Transanal circumferential and full-thickness rectal dissection through the TEM platform, starting just below the purse-string suture, in a female patient with an upper rectal cancer. (d) Transanal posterior mesorectal dissection using laparoscopic instruments through the TEM platform in a female patient. (e) Transanal mobilization of the anterior rectal wall and peritoneal entry through the TEM platform in a female patient. (f) Intact rectosigmoid specimen and mesorectum following transanal NOTES procedures.

demonstrated a significant increase in the length of specimen able to be mobilized and resected. No mortalities occurred in either group. Two morbidities, one intraabdominal abscess and one abdominal wall hematoma, occurred in the dual transgastric and transanal group identified at necropsy. Experimental evidence from both the nonsurvival and survival swine studies demonstrated both the feasibility and safety of transanal NOTES rectosigmoid resection using TEM with or without transgastric endoscopic assistance. This work served as the foundation for transitioning to human application.

2.1. Technique Optimization and Transitioning to Clinical Application. In preparation for human application, fresh human cadaveric models were utilized to optimize this technique. The purpose of this model was to both determine the technical and oncologic feasibility of this technique and eventually optimize this procedure for human clinical trials. Since initiation of this protocol, transanal NOTES rectosigmoid resection has been successfully performed in 32 fresh human cadavers [17]. NOTES transanal endoscopic rectosigmoid resection was performed using transanal dissection alone ($n = 19$), with transgastric endoscopic assistance ($n = 5$) or with laparoscopic assistance ($n = 8$). Of the 19 cadaveric operations performed via a pure transanal approach, 2 were performed using laparoscopic and TEO instruments through the TEO platform, 8 using endoscopic assistance with a gastroscope (Pentax) inserted through the TEO platform, and 9 utilized endoscopic assistance through a novel rigid endoscopic platform inserted through the TEO platform (ISSA, Storz). The purpose of this novel platform was to provide additional rigidity to the gastroscope.

2.2. Technique. As in swine, the rectum was occluded transanally with a 2-0 vicryl purse-string suture approximately 3-4 cm from the anal verge, above the sphincter complex. The 7.5 cm TEO proctoscope (Storz, Tuttlingen, Germany) was then inserted transanally and sealed with a faceplate. Circumferential dissection of the rectum was initiated above the anal sphincter complex using electrocautery and TEO dissecting instruments (Figure 2(c)). Low pressure CO_2 insufflation (9 mm Hg) was used to facilitate dissection (Figures 2(a) and 2(b)). Posterior entry into the presacral space was facilitated by CO_2 insufflation and flexible-tip instruments. The mesorectum was mobilized sharply, with or without electrocautery or a bipolar device (Autosonix ultrashears, Covidien, Norwalk, CT), and mesorectal dissection proceeded cephalad along the avascular presacral plane (Figure 2(d)). This plane of dissection was extended medially, laterally, and anteriorly to achieve circumferential

rectal mobilization and TME. The shorter proctoscope was replaced with the 15 cm proctoscope to improve exposure. The peritoneal reflection was visualized and divided anteriorly after carefully mobilizing the vagina or prostate from the anterior rectal wall, and the peritoneal cavity was entered (Figure 2(e)). The peritoneal attachments of the rectosigmoid were divided using electrocautery and a bipolar device (Autosonix). Proximal dissection was continued either via transanal endoscopic dissection alone or with transgastric endoscopic or laparoscopic assistance. The inferior mesenteric pedicle was taken in all cadavers using a bipolar device or a linear endoscopic stapler (EndoGIA, Covidien) inserted transanally through the TEO platform.

In cadavers undergoing sole transanal rectosigmoid resection, dissection into the peritoneal cavity was extended as cephalad as possible using TEO and laparoscopic instruments, with or without transanal endoscopic assistance using a gastroscope (Pentax Medocal Incl, Montvale, NJ, USA). When dissection could not be extended any further, the proctoscope was removed, and the specimen was exteriorized in preparation for specimen extraction.

Transgastric assistance, when utilized, was performed as previously described [10]. In brief, following maximal transanal rectosigmoid mobilization, peroral transgastric peritoneal access was obtained using a 12.8 mm colonoscope (Pentax). A 4 mm gastrostomy was then made using a needle knife (Cook Medical Inc., Winsont-Salem, NC, USA) and dilated. Once access was established, the colonoscope was advanced into the peritoneal cavity. In 2 cases, transgastric access and dissection were performed using a novel endoscopic platform (Anubiscope, Storz). The lateral peritoneal attachments of the rectosigmoid, sigmoid, and descending colon was then divided using the needle knife. Transanal and transgastric mobilization were combined until no further mobilization could be safely achieved. For operations performed with laparoscopic assistance, 1–3 abdominal trocars were inserted to improve visualization and/or facilitate colon retraction. This permitted more proximal dissection of the rectosigmoid junction.

Regardless of operative approach, once the rectosigmoid specimen had been fully mobilized, it was exteriorized transanally, measured and subsequently transected (Figure 2(f)). A Lone Star retractor (Cooper Surgical, Trumbull, CT, USA) was then positioned and a handsewn coloanal anastomosis performed between the proximal sigmoid colon and distal anorectal cuff as previously described.

2.3. Technical Feasibility and Optimization. In this series of 32 fresh human cadavers, 21 were male and 11 female with mean BMI of 24 kg/m^2. Mean operative time was 5.1 hours and mean specimen length 53 cm (range 15 to 91.5 cm). A significant improvement in both specimen length and operative time was demonstrated with increased experience [17]. In addition, comparison by operative approach demonstrated significantly improved specimen length with addition of laparoscopic assistance. Cases that employed a hybrid transgastric and transanal approach initially resulted in increased specimen length; however, this became less pronounced with increasing experience in transanal dissection alone. In 8 (25%) cadavers, an enteric perforation was identified in the sigmoid ($n = 2$), rectum ($n = 3$), or proximal colon ($n = 2$). Factors associated with complication included obesity, poor cadaver quality, pelvic adhesions, and a redundant sigmoid colon. In addition, all enteric perforations occurred in cadavers undergoing pure NOTES rectosigmoid resection during attempted mobilization of the proximal descending colon. Limitations in dissecting instruments, current platforms, and proximal visualization are likely responsible for the rate of enteric perforation. While the feasibility of pure NOTES colorectal resection could be replicated in fresh human male and female cadavers, the complication rate highlights that clinical application is not yet possible and a hybrid laparoscopic approach is essential. In addition to serving as an experimental platform, this model also enabled standardization of a hybrid laparoscopic procedure prior to clinical trials. It allowed for the capability of trouble shooting and overcoming the procedural learning curve prior to human application.

2.4. Oncologic Feasibility. Another question that needed to be addressed prior to transitioning to human trials pertained to the adequacy of oncologic resection. Both cadaveric work done by our group as well as the one by Whiteford et al. [13] illustrate that this operation is oncologically appropriate. As total mesorectal excision (TME) remains the gold standard in the treatment of rectal cancer, we evaluated oncologic adequacy in our cadaveric model by specimen assessment following procedure. In our series of 32 cadavers, the mesorectum was intact in 100% of specimens following TME. The capability of performing an adequate oncologic operation was corroborated in 2011 by Rieder et al. [18]. This paper randomized male cadavers to either laparoscopic or transanal sigmoid resection for a lesion simulated at 25 cm. Lymph node yield as well as adequate resection margins were evaluated. This study demonstrated similar lymph node yield following transanal rectosigmoidectomy when compared to the laparoscopic approach. Given the distance of the simulated lesion however, laparoscopic assistance was necessary in the transanal group to achieve adequate proximal resection margin. Nonetheless, results from this study support the feasibility of this technique as an adequate oncologic procedure.

3. Clinical Trials

Success in animal and cadaveric models has led to worldwide human clinical trials [14–16]. In 2010, our group reported the first hybrid NOTES transanal total mesorectal excision (TME) in a 76-year-old female with a T2N1 rectal cancer treated preoperatively with neoadjuvant therapy [16]. Visualization and assistance during the procedure were aided with a transabdominal 5 mm port that later became the stoma site and 2 mm needle ports of which one was used as a drain site. The TME was performed entirely transanally through the TEO platform (Storz, Tuttlingen, Germany)

with mobilization of the splenic flexure and proximal intra-abdominal colon performed laparoscopically. The specimen was then transected transanally and a handsewn coloanal anastomosis with diverting loop ileostomy was performed. The operative time was 4 hours and 30 minutes. The patient did well postoperatively and was discharged home on postoperative day four. The final pathology demonstrated a ypT1N0 tumor with intact mesorectum that included 23 negative lymph nodes and negative proximal, distal and radial margins. The patient later underwent ileostomy reversal with good function and has remained free of disease.

Since this report, 3 additional cases have been reported in the literature. Zorron et al. published a series of 2 patients who underwent successful hybrid NOTES TME for rectal cancer [14]. In this series, mesorectal dissection is described with both an endoscope and with a transrectal rigid single port device. The first case was that of a 54-year-old male who presented with an adenocarcinoma 8 cm from the rectal verge causing 90% stenosis of the lumen. Secondary to the obstructing nature of his tumor, the patient did not undergo neoadjuvant therapy. Hybrid transcolonic NOTES TME was performed using a colonoscope. Following identification of the anal verge, a 2.5 cm posterior incision was performed in the planned line of rectal resection. The colonoscope was then inserted directly into the perirectal retroperitoneal space and dissection was performed by directing the endoscope via CO_2 insufflation through a working channel. Once dissection reached the level of the peritoneal cavity, pneumoretroperitoneum was lost and dissection was then facilitated by laparoscopic assistance via 3 transabdominal trocars. Once dissection was complete, the specimen was removed transanally and a stapled anastomosis and right transverse diverting colostomy were performed. Operative time was 350 minutes. Both the intra- and postoperative courses were uncomplicated and the patient was discharged home on postoperative day 6. Pathology revealed an intact mesorectum with 3 out of 12 retrieved lymph nodes positive for tumor (pT3N1). Margins were free of tumor.

The second patient reported in this series was a 73-year-old female with a diagnosis of rectal adenocarcinoma 6 cm from the anal verge who underwent neoadjuvant therapy. In contrast to the first patient, this patient underwent a hybrid NOTES TME using a transanally inserted rigid, single port device. The single port access device has 3 channels for instrumentation, with 2 additional channels for CO_2 insufflation. Using a 10 mm 45-degree laparoscopic camera, in lieu of a flexible colonoscope, the TME dissection was then carried out transanally with laparoscopic assistance as previously described. Operative time was 360 minutes. This patient also recovered uneventfully and was discharged home on postoperative day 6. Pathology revealed tumor-free margins and intact mesorectum with 2 of 11 lymph nodes positive for tumor (pT3N1).

The third case was reported by Tuech et al. in 2011 [15]. This report describes a 45-year-old woman with a reported T1sm3 rectal adenocarcinoma 3 cm above the dentate line. For this procedure a single port access device, endorec trocar (Aspide, France), was also used. This trocar consists of a rigid port with 40 mm outer diameter, three 5 mm, and one 10 mm access channel and an air inlet tube through which CO_2 can be inflated. The extraperitoneal rectum was completely mobilized using this device. Once the lateral rectal attachments were divided, the rectovaginal peritoneal reflection was identified and perforated to gain access to the abdominal cavity. A second endorec trocar (Aspide, France) was then placed through the proposed ileostomy site and laparoscopic assistance with proximal colonic mobilization ensued. The procedure was performed successfully without complication. Operative time was 5 hours. The patient did well postoperatively without complication. Pathology revealed a pT1sm3N0 tumor. Fifteen lymph nodes were retrieved with the specimen.

While the principles of NOTES transanal rectal cancer resection remain the same, the methodology, particularly with respect to transanal dissection, varies between clinical trials. The consensus is that the majority of the rectal and mesorectal dissection can be achieved transanally while laparoscopic assistance is needed for proximal colon mobilization and tissue retraction. It is the preference of our group at this time to use the rigid TEO platform for transanal endoscopic rectal dissection rather than a flexible single port device. The TEO platform comes in 2 lengths, provides rigid stabilization for instrument manipulation, and is an established cost effective, reusable platform readily available at our institution. Nonetheless, the published reports thus far demonstrate that adequate hybrid NOTES TME can be achieved using flexible or rigid platforms and highlight the importance of continued work and development in this field.

As part of our effort to further this work, we are currently enrolling patients into an ongoing United States based Institutional Review Board (IRB) approved prospective clinical trial [19]. Patients selected for this approach include those with biopsy proven resectable adenocarcinoma of rectum located 4–12 cm from anal verge who are otherwise eligible to undergo standard open or laparoscopic low anterior resection with temporary diverting stoma. Tumors must be preoperatively staged as node negative, T1 (high risk features), T2 or T3 based on pelvic MRI with no evidence of metastasis on staging CT scans. For preoperatively staged T3N0 tumors, patients must have completed full-course neoadjuvant treatment. Procedures are performed following the same steps as described in cadavers, using an abdominal and perineal team working simultaneously. Transanal dissection is performed via the TEM platform with laparoscopic assistance through 1–4 abdominal trocars. The right lower quadrant trocar is later used as the ileostomy site. Following transanal specimen retrieval, a handsewn coloanal anastomosis with diverting ileostomy is performed. For this protocol, a diverting ileostomy is standard given performance of a low-lying anastomosis in patients who likely will require either neoadjuvant or adjuvant chemoradiation.

4. Conclusion

Transanal NOTES rectosigmoid resection is feasible and safe as demonstrated in both a swine and fresh human cadaveric model. Clinical application has been promising, with several

hybrid laparoscopic and transanal procedures for rectal cancers published to date. While encouraging, instrument limitations continue to hinder a pure transanal approach. Continued development of new flexible endoscopic platforms and flexible-tip instruments are imperative prior to pure NOTES clinical application in humans. In addition, the success of clinical application will ultimately rely on careful patient selection and strict adherence to oncologic principles of resection with all planned procedures done in the setting of IRB-approved clinical trials.

References

[1] M. H. Sodergreen, J. Clarck, T. Athanasiou, J. Teare, G. Z. Yang, and A. Darzi, "Natural orifice translumenal endoscopic surgery: critical appraisal of applications in clinical practice," *Surgical Endoscopy*, vol. 23, pp. 680–687, 2009.

[2] D. Rattner and A. Kalloo, "ASGE/SAGES working group on natural orifice translumenal endoscopic surgery," *Surgical Endoscopy and Other Interventional Techniques*, vol. 20, no. 2, pp. 329–333, 2006.

[3] D. W. Rattner, R. Hawes, S. Schwaitzberg, M. Kochman, and L. Swanstrom, "The second SAGES/ASGE white paper on natural orifice transluminal endoscopic surgery: 5 years of progress," *Surgical Endoscopy*, vol. 25, no. 8, pp. 2441–2448, 2011.

[4] G. V. Rao, D. N. Reddy, and R. Banerjee, "NOTES: human experience," *Gastrointestinal Endoscopy Clinics of North America* , vol. 18, pp. 361–370, 2008.

[5] C. Zornig, H. Mofid, A. Emmermann, M. Alm, H. A. Von Waldenfels, and C. Felixmüller, "Scarless cholecystectomy with combined transvaginal and transumbilical approach in a series of 20 patients," *Surgical Endoscopy and Other Interventional Techniques*, vol. 22, no. 6, pp. 1427–1429, 2008.

[6] D. W. Gee, F. F. Willingham, G. Y. Lauwers, W. R. Brugge, and D. W. Rattner, "Natural orifice transesophageal mediastinoscopy and thoracoscopy: a survival series in swine," *Surgical Endoscopy and Other Interventional Techniques*, vol. 22, no. 10, pp. 2117–2122, 2008.

[7] D. W. Gee and D. W. Rattner, "Transmediastinal Endoscopic Intervention," *Journal of Gastrointestinal Surgery*, vol. 15, no. 8, pp. 1303–1305, 2011.

[8] W. M. Bazzi, O. Wagner, S. P. Stroup et al., "Transrectal hybrid natural orifice transluminal endoscopic surgery (NOTES) nephrectomy in a porcine model," *Urology*, vol. 77, no. 3, pp. 518–523, 2011.

[9] L. J. Fischer, G. Jacobsen, B. Wong et al., "NOTES laparoscopic-assisted transvaginal sleeve gastrectomy in humans-description of preliminary experience in the United States," *Surgery for Obesity and Related Diseases*, vol. 5, no. 5, pp. 633–636, 2009.

[10] P. Sylla, D. K. Sohn, S. Cizginer et al., "Survival study of natural orifice translumenal endoscopic surgery for rectosigmoid resection using transanal endoscopic microsurgery with or without transgastric endoscopic assistance in a swine model," *Surgical Endoscopy and Other Interventional Techniques*, vol. 24, no. 8, pp. 2022–2030, 2010.

[11] P. Sylla, F. F. Willingham, D. K. Sohn, D. Gee, W. R. Brugge, and D. W. Rattner, "NOTES rectosigmoid resection using transanal endoscopic microsurgery (TEM) with transgastric endoscopic assistance: a pilot study in swine," *Journal of Gastrointestinal Surgery*, vol. 12, no. 10, pp. 1717–1723, 2008.

[12] P. M. Denk, L. L. Swanström, and M. H. Whiteford, "Transanal endoscopic microsurgical platform for natural orifice surgery," *Gastrointestinal Endoscopy*, vol. 68, no. 5, pp. 954–959, 2008.

[13] M. H. Whiteford, P. M. Denk, and L. L. Swanström, "Feasibility of radical sigmoid colectomy performed as natural orifice translumenal endoscopic surgery (NOTES) using transanal endoscopic microsurgery," *Surgical Endoscopy and Other Interventional Techniques*, vol. 21, no. 10, pp. 1870–1874, 2007.

[14] R. Zorron, H. N. Phillips, D. Coelho, L. Flach, F. B. Lemos, and R. C. Vassallo, "Perirectal NOTES access: "down-to-up" total mesorectal excision for rectal cancer," *Surgical Innovation*. In press.

[15] J. J. Tuech, V. Bridoux, B. Kianifard et al., "Natural orifice total mesorectal excision using transanal port and laparoscopic assistance," *European Journal of Surgical Oncology*, vol. 37, no. 4, pp. 334–335, 2011.

[16] P. Sylla, D. W. Rattner, S. Delgado, and A. M. Lacy, "NOTES transanal rectal cancer resection using transanal endoscopic microsurgery and laparoscopic assistance," *Surgical Endoscopy and Other Interventional Techniques*, vol. 24, no. 5, pp. 1205–1210, 2010.

[17] D. A. Telem, D. W. Rattner, and P. Sylla, "NOTES transanal rectosigmoid resection with total mesorectal excision in a large human cadaver series," in *Proceedings of the Scientific Session of the 15th World Congress of Endoscopic Surgery*, Diego, Calif, USA, March 2012.

[18] E. Rieder, G. O. Spaun, Y. S. Khajanchee et al., "A natural orifice transrectal approach for oncologic resection of the rectosigmoid: an experimental study and comparison with conventional laparoscopy," *Surgical Endoscopy*, vol. 25, no. 10, pp. 3357–3363, 2011.

[19] 2012, http://clinicaltrial.gov/ct2/show/NCT01340755?term=sylla&rank=1.

Hindawi Publishing Corporation
Minimally Invasive Surgery
Volume 2012, Article ID 874172, 4 pages
doi:10.1155/2012/874172

Clinical Study

Improving the Advantages of Single Port in Right Hemicolectomy: Analysis of the Results of Pure Transumbilical Approach with Intracorporeal Anastomosis

Salvador Morales-Conde, Antonio Barranco, María Socas, Cristina Méndez, Isaias Alarcón, Jesús Cañete, and Francisco J. Padillo

Unit of Innovation in Minimally Invasive Surgery, University Hospital "Virgen del Rocío", 41010 Sevilla, Spain

Correspondence should be addressed to Salvador Morales-Conde, smoralesc@gmail.com

Received 15 January 2012; Accepted 7 February 2012

Academic Editor: Luigi Boni

Background. Single-port laparoscopic surgery has recently emerged as a method to improve patient recovery and cosmetic benefits of laparoscopic surgery. The evolution of our technique has led us to move from a periumbilical incision to a transumbilical one, avoiding the use of drain and maintaining a pure single-port approach with intracorporeal anastomosis in order to maintain the incision as smaller as possible. *Method*. We report a prospective clinical analysis of our first 38 patients. Oncological surgical steps were followed as during the standard laparoscopic approach, performing the anastomosis intracorporeally in all cases. *Results*. Mean age of 68,39 years old and an average BMI of 27,88%. (range 19,81–41,5). Most lesions were adenocarcinoma (65,8%), while the remaining were polyps (31,5%) and one a mucocele of the appendix. We moved from a periumbilical incision, initial 14 cases, into a transumbilical one, (medium size of the incision 3,25 cm). Average surgical time was 117,42 minutes. Drains was only used in our first 3 cases. Mean hospital stay was 5,2 days, (86,5% stayed less than 5 days). Total morbidity was 13%. Histological exams of the specimens showed that the oncological criteria were preserved. *Conclusions*. Single-port right hemicolectomy with intracorporeal anastomosis is feasible and safe. The advantages of a total intracorporeal anastomosis include that there is no need to enlarge the umbilical incision and avoid traction of the pedicle of the mesenterium of the transverse colon during the extracorporeal anastomosis. A transumbilical incision offers better cosmetic results, and the use of drains can be avoided, which increase, patient's satisfaction.

1. Introduction

Laparoscopic surgery for carcinoma of the colon is a feasible technique as short- and long-term results show. This technique is as safe and effective as the open approach [1, 2]. The development of minimally invasive surgical techniques tries to search for new methods and approaches to improve cosmetic results, reduce postoperative pain, and minimize possible complications associated to laparoscopic approach, trying at the same time to preserve the oncological results so far obtained with the standard laparoscopic procedures. New approaches, such as NOTES and single-port access surgery, are being developed in the field of minimally invasive surgery. In fact, single-port access surgery is becoming accepted in some laparoscopic procedures such as cholecystectomy [3, 4], nephrectomy [5], appendectomies [6], adrenalectomies [7], splenectomies [8], bariatric procedures [9], and colonic surgery [10]. Even that this approach has demonstrated to be feasible in colonic surgery, further efforts are necessary to prove if surgeons may obtain similar results, in terms of morbidity and oncological results, to those obtained by standard laparoscopic approach.

On the other hand, we have to keep analyzing our results in order to determine the best way of performing these procedures. There is still a great debate in order to determine where to place the single-port devices, the way of performing the incision in the umbilicus, transumbilical versus periumbilical, the instruments to be used, straight versus curve

versus Roticulator instruments, and, in case of right colonic resections, how to perform the anastomosis, extracorporeal versus intracorporeal.

2. Patients and Methods

2.1. Case Series. We report a prospective clinical analysis of our first 38 pure single-port right colonic resection performed between June of 2009 and November of 2011. We analyse the evolution of our technique as well as the morbidity and the oncological results of our series.

2.2. Surgical Technique. The procedure was originally performed through a periumbilical incision, in our first 14 cases, moving into a transumbilical one in the latest 24 cases, what increases patient's satisfaction in term of cosmetic results. No additional trocars were used in any of our cases in order to decrease the trauma of the abdominal wall. We used in all cases a single-port device with two orifices of 5 mm and one of 12 mm (SILS port. Covidien Ltd., Norwalk, CT, USA), a 5 mm 30° scope (Olympus Ltd., Hamburg, Germany), a roticulator grasper (Roticulator Endo Dissect, Covidien Ltd, Norwalk, CT, USA) in the left hand through one of the 5 mm orifice, using the 12 mm orifice to introduce different instruments such as the endoscopic scissors with electrocautery (Roticulator Endo mini-shears, Covidien Ltd., Norwalk, CT, USA), the LigaSure Atlas (Covidien Ltd., Norwalk, CT, USA), originally, while the latest cases has been performed using the LigaSure Advance (Covidien Ltd., Norwalk, CT, USA), the flexible endo-stapler (EndoGIA Roticulator, Covidien Ltd., Norwalk, CT, USA), and the Endo Stitch suture system (Covidien Ltd., Norwalk, CT, USA). Surgery was performed according the standard oncological criteria, following a medial-to-lateral approach with section of ileo-colic vessels close to their origin with the LigaSure (Covidien Ltd., Norwalk, CT, USA). For the exposition of the mesenterium of the right colon, tension was maintained using a suture introduced through the abdominal wall with a straight needle which crossed the abdominal cavity through two distal points between the entry (right lumbar area) and exit sites (suprapubic). This suture was passed through the mesentery close to the ileocecal valve, and it was fixed to the tissue with clips to avoid the suture to slide through the fatty tissue, which allows moving the colon from one side to another by pulling from each side of the suture. This suture allowed the right exposition of the colon during the different phases of the surgery by pulling of the two ends of the suture. Once the main vessels have been divided and the resections of the transverse colon and ileum have been done, a side-to-side intracorporeal anastomosis is performed using a 60 mm Endo Stapler with blue cartridge (Figure 1). The orifice of the anastomosis was closed with a running suture by using the Endo Stitch (Figure 2). The specimen was removed from the abdominal cavity in a 15 mm bag through the same umbilical incision, which was closed with a running absorbable suture under a proper direct vision.

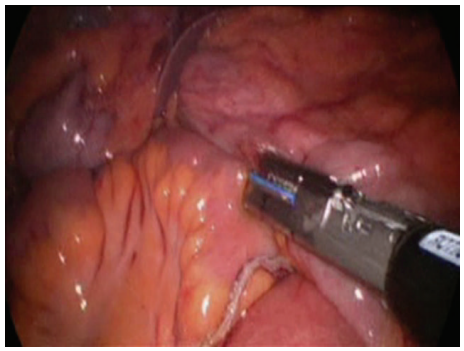

Figure 1: Intracorporeal anastomosis using an Endo Stapler with a blue cartridge.

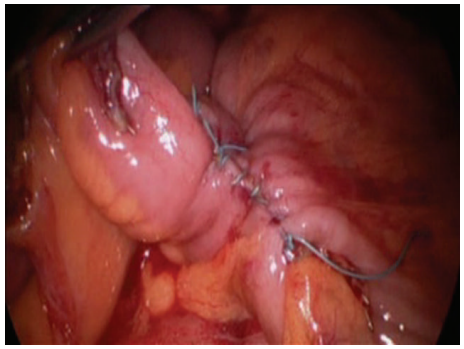

Figure 2: Total intracorporeal anastomosis performed.

3. Results

Twenty-two patients were males (57,9%) and 16 females (42,1%), with an average age of 68,39 years old (range 45–84). Previous clinical history of the patients revealed that 12 of them had previous abdominal surgery. Mean ASA score was 2,71, and the average BMI was 27,88 (range 19,81–41,5).

Lesions were located preoperatively in the cecum in 15 cases (39,5%), in ascending colon in 8 (21,1%), in hepatic flexure in 12 (31,5%), and in transverse colon in 3 (7,9%). Most lesions were adenocarcinoma (25 cases, 65,8%), while the remaining were polyps (12 cases, 31,5%), and one case was due to a previous mucocele of the appendix. Only 17 of these lesions (44,7%) could be detected by the CT scan, while the remaining ones were very small and could not be identified by this imaging technique.

All patients were operated following the same technique, although in 5 of them it was necessary to perform an adhesiolysis due to previous surgery. An extended right hemicolectomy was performed in 17 cases (44,7%), including the transverse colon left to the round ligament, while in the rest of the cases the technique was a standard right colonic resection.

Regarding the incision, a periumbilical incision was performed in our initial 14 cases (36,8%), while the rest of the cases a transumbilical incision was used (Figure 3). Patient satisfaction increases with the changes in the way that the incision was performed, due to better cosmetic results

Figure 3: Transumbilical incision one month after surgery.

Figure 4: Drain through a periumbilical incision.

obtained. Medium size of the incision was 3,25 cm (range 2,5–5,2).

Mean surgical time was 117,42 minutes (range 75–190), while the average blood loss during surgery was 118,48 cc. Drain was only used in our first 3 cases, and it was placed through the same periumbilical incision (Figure 4). Drains were not used in the rest of the cases.

Mean hospital stay was 5,2 days, although most of the patients (86,5%) stayed less than 5 days: one patient stayed one day (2,7%), 14 patients 3 days (37,8%), 10 patients 4 days (7%), 7 patients 5 days (19%), 2 patients 6 days (5,4%), and only 3 patients stayed more than 7 days (8,1%).

Regarding complications, we have had one conversion into open surgery, due to a tear of the inferior mesenteric vein. Reoperation rate was 5,2% (2 patients), one due to a bowel obstruction, being performed by conventional laparoscopy, identifying the drain as the cause of this problem, since it entraps the small bowel. The other case was performed by open approach, and it was due to a leak of the anastomosis.

Total morbidity was 13%: there were one leak (2,6%), one bowel occlusion (2,6%), one paralytic ileus (2,6%), and 2 wound infections (5,2%). Long-term follow up showed one incisional hernia (2,6%).

Histological exams of the specimens showed that the oncological criteria, related to number of lymph node (100% patients more of 12 lymph nodes, ranges 12–27) and resection margin (more than 5 cm), were preserved.

4. Discussion

We report our initial series of single-port access right hemicolectomy with total intracorporeal anastomosis without any additional trocars. Single-port access surgery is the result of the continuous search for increasing less invasive approaches. This technique has been possible thanks to the development of flexible instruments and trocars which enables the introduction of several instruments [11].

The main goal of this novel approach is to follow the same steps and principles of standard laparoscopic right hemicolectomy achieving the same oncological results. In fact this laparoscopic approach has been demonstrated to be as effective as conventional surgery for the treatment of carcinoma of colon [1, 2]. Single-port access surgery tries to obtain certain additional benefits in comparison to laparoscopic approach, such as better cosmetic results and potential minimization of postoperative pain, apart from the advantages associated to less traumatism to the abdominal wall, avoiding possible complications associated to the use of additional trocars, such as abdominal wall bleeding or hernias at the site of these additional lateral trocars. But these theoretical advantages still have to be demonstrated in prospective randomized trials.

A review of the literature starts showing different series on single-port right hemicolectomy [12–18]. All series and cases reported were performed with extracorporeal anastomosis, but in our series both the resection of the specimen and subsequent anastomosis were intracorporeal, what could add different advantages to the procedure. In fact, the specimen was removed from the abdominal cavity in a 15 mm bag, avoiding the necessity to enlarge the incision, to carry out the extracorporeal anastomosis, and also possible unnecessary tractions of the pedicle of the transverse colon, where the anastomosis was performed.

Intracorporeal ileocolic anastomosis can be performed safely and effectively, although this technique needs to be performed by expert surgeons with experience in this type of anastomosis and with skills in single-port approach, what could increase the learning curve. On the other hand, this anastomosis could be considered more expensive than the extracorporeal anastomosis, since this last one could be performed manually. Further studies need to analyse if this intracorporeal anastomosis is more cost effective than the extracorporeal ones.

This type of anastomosis has already been described for standard laparoscopic right hemicolectomy in the literature by Bergamaschi et al. [19]. More recently, Bucher et al. [20] have also described an intracorporeal anastomosis in a report of a single-port access gastrojejunostomy, but an additional trocar was added to perform the anastomosis, closing the orifice left by the endostappler with a new special device. However, we defend the use of a running suture to close this orifice, the endostitch being very useful for such purpose as it allows to perform the suture with few wrist movements, avoiding interferences with the scope, since a standard needle

holder requires more wrist movements. From a technical point of view, the use of a flexible grasper with the left hand is also important as it allows the exposition of the operation field. However, using straight instruments with the right hand requires a 30° scope to obtain a correct visualization of the tip of them. On the other hand, the suture through the mesentery allows the exposition of the operation field, specially the ileocecal pedicle, replacing standard assistant trocars needed during this procedure.

On the other hand, the use of drain in right colonic resection has been demonstrated not to be necessary, which increases patient satisfaction and decreases postoperative pain. We have moved from the use of drain in our first 3 cases to avoid them. In fact the drain was the cause of one of the reoperations, since it entraps the ileum producing a bowel occlusion. The use of a transumbilical incision, better than a periumbilical one, has increased the cosmetic results of our series.

5. Conclusion

Single-port access right hemicolectomy follows the basic principles of conventional right hemicolectomy in term of morbidity and oncological results, although longer followup is necessary to determine the survival. This technique with intracorporeal anastomosis is a safe and feasible approach when performed by experienced laparoscopic surgeons, offering more potential advantages than the extracorporeal anastomosis. The use of transumbilical incision and avoiding additional trocars and drains could increase patient's satisfaction, since it could reduce pain and increase cosmetic results.

Nevertheless, further series and prospective studies must be conducted to prove the effectiveness of this technique in relation to less postoperative pain and less abdominal wall complications while preserving the same oncological results.

References

[1] E. Kuhry, W. F. Schwenk, R. Gaupset, U. Romild, and H. J. Bonjer, "Long-term results of laparoscopic colorectal cancer resection," *Cochrane Database of Systematic Reviews*, no. 2, Article ID CD003432, 2008.

[2] A. M. Lacy, J. C. García-Valdecasas, S. Delgado et al., "Laparoscopy-assisted colectomy versus open colectomy for treatment of non-metastatic colon cancer: a randomised trial," *The Lancet*, vol. 359, no. 9325, pp. 2224–2229, 2002.

[3] N. T. Nguyen, K. M. Reavis, M. W. Hinojosa, B. R. Smith, and S. E. Wilson, "Laparoscopic transumbilical cholecystectomy without visible abdominal scars," *Journal of Gastrointestinal Surgery*, vol. 13, no. 6, pp. 1125–1128, 2009.

[4] R. Raakow and D. A. Jacob, "Single-Incision Cholecystectomy in about 200 Patients," *Minimally Invasive Surgery*, vol. 2011, Article ID 915735, 5 pages, 2011.

[5] A. Rané, P. Rao, and P. Rao, "Single port acces nephrectomy and other laparoscopic urologic procedures using a novel laparoscopic port (R-port)," *Urology*, vol. 72, no. 2, pp. 260–263, 2008.

[6] J. Park, H. Kwak, S. G. Kim, and S. Lee, "Single-port laparoscopic appendectomy: comparison with conventional laparoscopic appendectomy," *Journal of Laparoendoscopic & Advanced Surgical Techniques*, vol. 22, no. 2, pp. 142–145, 2012.

[7] A. Miyajima, S. Hattori, T. Maeda et al., "Transumbilical approach for laparo-endoscopic single-site adrenalectomy: initial experience and short-term outcome," *International Journal of Urology*, vol. 19, no. 4, pp. 331–335, 2012.

[8] E. M. Targarona, M. B. Lima, C. Balague, and M. Trias, "Single-port splenectomy: current update and controversies," *Journal of Minimal Access Surgery*, vol. 7, no. 1, pp. 61–64, 2011.

[9] S. Morales-Conde, G. Dominguez, G. J Cañete et al., "Magnetic-assisted single-port sleeve gastrectomy," *Surgical Innovation*. In press.

[10] S. Morales-Conde, J. García Moreno, J. Cañete Gómez et al., "Total intracorporeal anastomosis during single-port laparoscopic right hemicolectomy for carcinoma of colon: a new step forward," *Surgical Innovation*, vol. 17, no. 3, pp. 226–228, 2010.

[11] J. R. Romanelli and D. B. Earle, "Single-port laparoscopic surgery: an overview," *Surgical Endoscopy and Other Interventional Techniques*, vol. 23, no. 7, pp. 1419–1427, 2009.

[12] J. A. Waters, B. M. Rapp, M. J Guzman et al., "Single-port laparoscopic right hemicolectomy: the first 100 resections," *Diseases of the Colon & Rectum*, vol. 55, no. 2, pp. 134–139, 2012.

[13] C. Lai, T. Edwards, D. Clements, and M. Coleman, "Single port laparoscopic right colonic resection using a "vessel-first" approach," *Colorectal Disease*. In press.

[14] C. B. Patel, D. I. Ramos-Valadez, M. Ragupathi, and E. M. Haas, "Single incision laparoscopic-assisted right hemicolectomy: technique and application (with video)," *Surgical Laparoscopy, Endoscopy and Percutaneous Techniques*, vol. 20, no. 5, pp. e146–e149, 2010.

[15] J. A. Waters, M. J. Guzman, A. D. Fajardo et al., "Single-port laparoscopic right hemicolectomy: a safe alternative to conventional laparoscopy," *Diseases of the Colon and Rectum*, vol. 53, no. 11, pp. 1467–1472, 2010.

[16] F. H. Remzi, H. T. Kirat, J. H. Kaouk, and D. P. Geisler, "Single-port laparoscopy in colorectal surgery," *Colorectal Disease*, vol. 10, no. 8, pp. 823–826, 2008.

[17] P. Bucher, F. Pugin, and P. Morel, "Single port access laparoscopic right hemicolectomy," *International Journal of Colorectal Disease*, vol. 23, no. 10, pp. 1013–1016, 2008.

[18] L. Boni, G. Dionigi, E. Cassinotti et al., "Single incision laparoscopic right colectomy," *Surgical Endoscopy and Other Interventional Techniques*, vol. 24, no. 12, pp. 3233–3236, 2010.

[19] R. Bergamaschi, E. Schochet, C. Haughn, M. Burke, J. F. Reed, and J. P. Arnaud, "Standardized laparoscopic intracorporeal right colectomy for cancer: Short-term outcome in 111 unselected patients," *Diseases of the Colon and Rectum*, vol. 51, no. 9, pp. 1350–1355, 2008.

[20] P. Bucher, F. Pugin, and P. Morel, "Transumbilical single-incision laparoscopic intracorporeal anastomosis for gastrojejunostomy: case report," *Surgical Endoscopy and Other Interventional Techniques*, vol. 23, no. 7, pp. 1667–1670, 2009.

Hindawi Publishing Corporation
Minimally Invasive Surgery
Volume 2012, Article ID 896952, 7 pages
doi:10.1155/2012/896952

Review Article

Natural Orifice Transesophageal Endoscopic Surgery: State of the Art

João Moreira-Pinto,[1,2,3] Aníbal Ferreira,[1,2,4] Carla Rolanda,[1,2,4] and Jorge Correia-Pinto[1,2,5]

[1] *Life and Health Sciences Research Institute (ICVS), School of Health Sciences, University of Minho, 4709-057 Braga, Portugal*
[2] *ICVS/3B's, PT Government Associate Laboratory, 4709-057 Braga/Guimarães, Portugal*
[3] *Department of Pediatric Surgery, Centro Hospitalar do Porto, 4099-001 Porto, Portugal*
[4] *Department of Gastroenterology, Hospital de Braga, 4710-243 Braga, Portugal*
[5] *Department of Pediatric Surgery, Hospital de Braga, 4710-243 Braga, Portugal*

Correspondence should be addressed to Jorge Correia-Pinto, jcp@ecsaude.uminho.pt

Received 9 December 2011; Accepted 9 February 2012

Academic Editor: Luigi Boni

The main goal of Natural Orifice Transluminal Endoscopic Surgery (NOTES) is performing surgery avoiding skin incisions. Theoretical advantages of NOTES include decreased postoperative pain, reduction/elimination of general anesthesia, improved cosmetic outcomes, elimination of skin incision-related complications such as wound infections and hernias, and increased overall patient satisfaction. Although various forms of port creation to accomplish thoracic NOTES procedures have been proposed, transesophageal NOTES has been shown to be the most reliable one. The evolution of endoscopic submucosal transesophageal access resulted in the development of per-oral endoscopic myotomy (POEM), which had a fast transition to clinical practice. The authors present a review of the current state of the art concerning transesophageal NOTES, looking at its potential for diagnostic and therapeutic interventions as well as the hurdles yet to be overcome.

1. Introduction

Natural Orifice Transluminal Endoscopic Surgery (NOTES) is the name given to novel endoscopic interventions on internal organs performed through natural orifices. In this new approach, endoscopes enter the abdominal and thoracic cavities via any single or combination of natural orifices—mouth, urethra, vagina, and anus [1]. In fact, NOTES dates back to 1940s, when Decker performed the first culdoscopy using an endoscope passed through the rectouterine pouch to view pelvic organs and perform sterilization procedures [2]. These procedures were superseded by noninvasive ultrasound imaging for diagnostic purposes and laparoscopy for surgical purposes. Later, NOTES was to be reborn when Rao and Reddy presented the video of the first transgastric appendectomy at the 2004 Annual Conference of the Society of Gastrointestinal Endoscopy of India [3]. In a severely burnt patient, whose skin they could not incise, they used a therapeutic flexible gastroscope to reach his stomach. Then, they performed an inside-out gastrostomy and pushed the gastroscope through the gastric wall into the abdominal cavity. They looked for the appendix and performed the first ever transgastric appendectomy.

The first description of transgastric peritoneoscopy in porcine model published in paper was by Kallo et al. in 2004 [4]. Soon, other natural orifices were presented as good access points for NOTES. Pai et al. published transcolonic peritoneoscopy followed by a series of transcolonic procedures [5]. The access from below gives a good, direct view of the upper abdominal cavity. Having this in mind, Lima et al. presented transvesical endoscopic peritoneoscopy [6]. To accomplish NOTES procedures in the thorax and the mediastinum, Sumiyama et al. proposed a transesophageal access [7]. Transvesical-transdiaphragmatic [8], transgastric-transdiaphragmatic [9], and transtracheal [10] access have been suggested too. Even though, the transesophageal has been preferred as a direct entry to the thorax and permited several procedures in porcine model (Table 1) [11–19].

Table 1: Transesophageal NOTES procedures in animal studies.

Mediastinoscopy	Cardiomyotomy
Thoracoscopy	Esophagomyotomy
Lymphadenectomy	Vagotomy
Pleural biopsy	Sympathectomy
Myocardial and left atrium injection	Esophagectomy and end-to-end anastomosis*
Pericardial fenestration	Pulmonary lobectomy*
Epicardial ablation	Left atrial appendage ligation*

* With single transthoracic trocar assistance.

The main goal of NOTES is to avoid skin incisions and its associated complications, such as wound infections and hernias. Theoretical advantages of NOTES include reduction in hospital stay, faster return to bowel function, decreased post-operative pain, reduction/elimination of general anesthesia, performance of procedures in an outpatient or even office setting, possibly cost reduction, improved cosmetic outcomes, and increased overall patient satisfaction [1].

2. Transesophageal Approach

When Sumyiama et al. presented transesophageal access to the thorax and mediastinum, they used submucosal endoscopy with mucosal flap (SEMF) [7]. The authors injected saline into the esophageal submucosal layer creating a bleb and high-pressure carbon dioxide was used to perform a submucosal dissection. A biliary retrieval balloon was then inserted into the submucosal layer and was distended to enlarge the mucosal hole and create a 10 cm long submucosa tunnel. Subsequently, they used an endoscopic mucosal resection (EMR) cap (Olympus, Tokyo, Japan) to create a defect in the muscularis propria and the mediastinum was entered. The key of the method is the overlying mucosa which serves as a sealant flap minimizing the risk of soiling a body cavity with lumenal contents and the ease by which the entry point into the submucosal working space can be closed [20].

Several modifications have been described to SEMF (Figure 1). Mucosa can be incised using either needle knife, a prototype flexible CO_2 laser fiber (OmniGuide Inc., Cambridge, MA, USA), or a Duette Multiband mucosectomy device (Cook Medical, Winston-Salem, NC, USA) [12]. Besides biliary retrieval balloons, the creation of the submucosal tunnel has been achieved with air and blunt dissection using snare tips, closed forceps, EMR caps [12–15]. Division of the muscular layer has been described using needle knife, although the aspiration method of the EMR cap may reduce the risk of injury to any adjacent mediastinal structure [13]. The SEMF procedure has also been applied in the stomach to safely perform NOTES in the abdominal cavity [21].

According to *von Renteln* et al. working with the endoscope through a dissection tunnel limits endoscope movements and degrees of freedom, and major procedures tend to stretch open the submucosal tunnel resulting in a major defect or laceration [22]. On the other hand, Moyer et al. tested durability of submucosal endoscopic tunnel in the stomach and concluded that it tolerates the mechanical forces of peroral transgastric procedures provided that the organ resected is small to moderate in size ($<8 \times 3$ cm) [23].

With or without submucosal tunneling, transesophageal approach to the thoracic cavity is highly risky because of possible mechanical abrasion and trauma of surrounding structures [13, 22]. For that, Fritscher-Ravens et al. proposed endosonographically EUS-assisted transesophageal access. In a comparative study of NOTES alone against EUS-assisted NOTES procedures, the authors found that the last was superior in gaining access, identifying structures, and therefore avoiding major complications [24].

A different alternative was presented by Rolanda et al. single transthoracic trocar assistance for transesophageal NOTES [18]. As most thoracic procedures imply some time of postoperative tube drainage, a 12 mm incision was made in the thoracic wall and a 10 mm trocar was inserted before esophagotomy was performed. Using a 10 mm thoracoscope with a 5 mm working channel (Karl Storz, Tuttlingen, Germany) inserted through the transthoracic trocar, transesophageal port was safety created with thoracoscopic visual control. Moreover, other well-known problems of NOTES, such as tissue manipulation, suturing, and anastomosis establishment, were overlapped, because triangulation and countertraction were achieved using flexible instruments inserted through the gastroscope and rigid instruments inserted through the thoracoscope. Therefore, transesophageal NOTES with the assistance of a single transthoracic trocar can be used for highly complex thoracic procedures.

Recently, our group has presented transesophageal pulmonary lobectomy with survival assessment in porcine model, using this single transthoracic port assistance [19]. Besides using flexible instruments inserted through the gastroscope, we introduced several rigid instruments through an oroesophageal overtube: endstaplers (EndoPath, Ethicon Endo-Surgery, Cincinnati, OH, USA), SILS-Stich (SILS stitch, Covidien, Mansfield, MA, USA), and knot-pusher. Coordinating the movement of a rigid instruments through the mouth with the image provided by the thoracoscope made ligation of the right upper bronchus and its vessels possible and reliable. The 12 mm thoracic incision was crucial for acute air and liquid drainage. All the four animals in the survival group subsisted for 15 days [19].

Transesophageal NOTES with the assistance of a single transthoracic trocar might be the key to incisionless cardiac procedures. Our group has performed left atrial appendage (LAA) ligation in 4 acute and 6 survival porcine models (unpublished results). The instruments entering both through the gastroscope and the thoracoscope made triangulation very similar to the one experienced on exclusive thoracoscopic approach. The flexible endoscope had a good access to all aspects of the heart—using direct position to reach the base of the heart and retroflexion for its apex. Moreover, flexible gastroscope was useful to show some parts of the thoracic cavity that could not be visualized with the 0° optic of the operative thoracoscope, namely, lateral thoracic wall and the entire diaphragm. With exception of the one acute

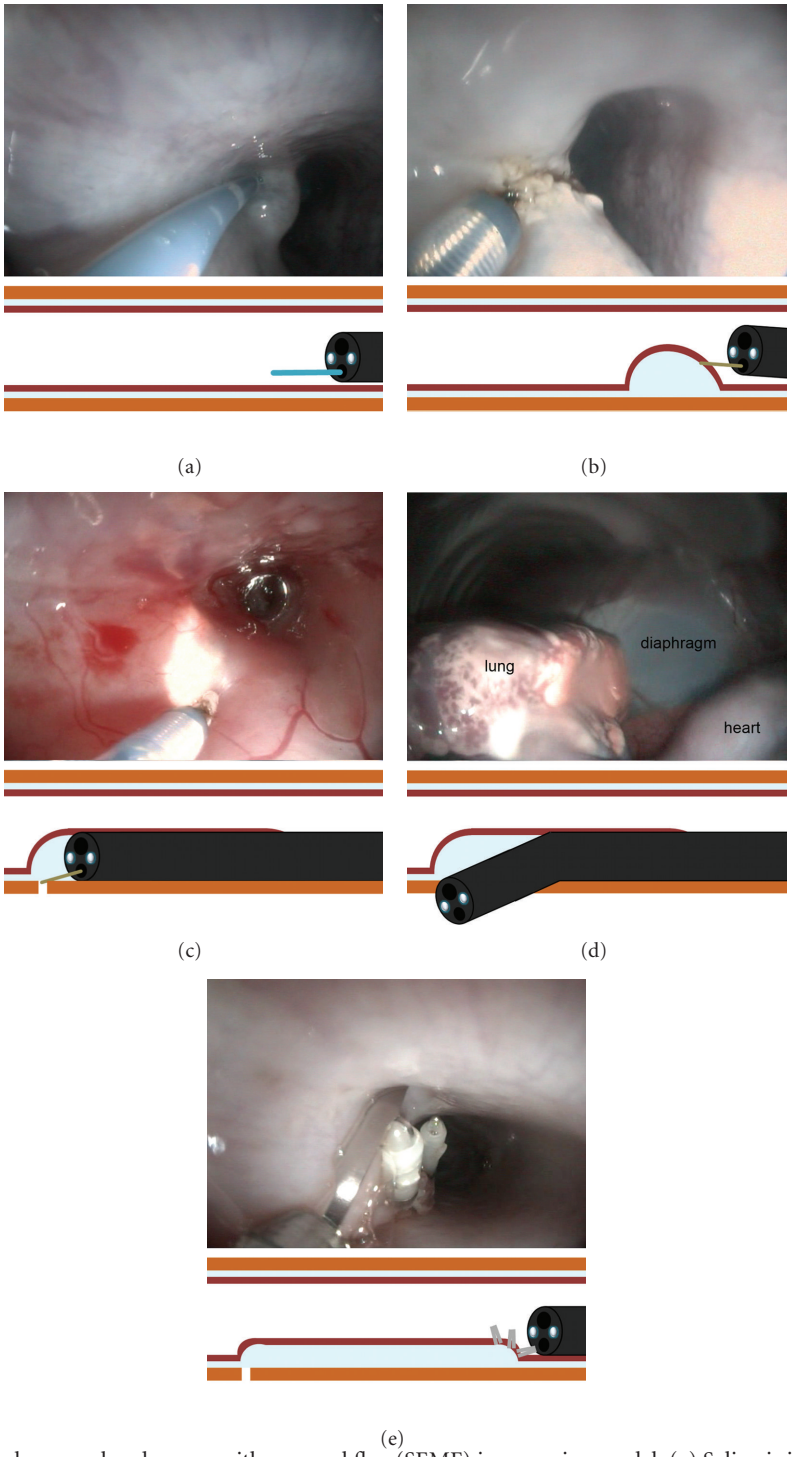

Figure 1: Transesophageal submucosal endoscopy with mucosal flap (SEMF) in a porcine model. (a) Saline is injected into the submucosal layer of the esophagus. (b) The mucosa of the bleb is incised using a needle knife. (c) A 10 cm tunnel is created using air and blunt dissection. The muscularis propria is incised at the distal end of the esophageal submucosal tunnel. (d) The endoscope is passed through the esophagotomy and the thoracic cavity is inspected. (e) Esophagotomy closure is achieved by mucosal flap adhesion. The mucosal defect is sutured using endoclips.

experiment which was terminated because of LAA rupture, all the other animals were kept alive until the end of the experiment. No adverse event occurred during the survival period. Complete LAA ligation was verified on necropsy, as LAA was fibrotic with the nylon endo-loop in place.

The NOTES revolution permitted evolution of the different natural orifices approaches themselves. The performance of endoscopic submucosal transesophageal myotomy is a perfect example of this. Pasricha et al. used SEMF to perform peroral endoscopic myotomy (POEM) in an experimental

setting [25]. Soon after this, Inoue et al. reported the first clinical experience of POEM for the treatment of achalasia [26]. In 17 consecutive patients, there were no intraoperative or postoperative complications, and the occasions of inadvertent entry into the cardiac mucosa (2 patients) and the exposure of mediastinal tissue (4 patients) were without incident. Although POEM might not be considered a true NOTES procedure because it does not divide all the layers of the esophagus, it does use readily available endoscopic equipment and techniques and directly competes with a laparoscopic procedure [27].

3. Esophagotomy Closure

When SEMF is used to create transesophageal access, esophagotomy closure is easy, as the overlying mucosa serves as a sealant flap. Most authors use endoclips to close the defect of the mucosa, but in the early studies the mucosa was left open with good clinical outcomes [7, 12–14]. Turner et al. published a study comparing esophageal submucosal tunnel closure with a stent versus no closure [28]. In this study, the unstented group achieved endoscopic and histologic evidence of complete reepithelialization and healing (100%) at the mucosectomy site compared with the stented group (20%, $P = .048$). So, it seems that the placement of a covered esophageal stent prejudices healing of the mucosectomy site.

When direct incision esophagotomy is performed, a full-thickness healing of the mucosal and muscular layer must be achieved. Fritscher-Raves et al. compared endoscopic clip-closure (ECC) versus endoscopic suturing (ECS) versus thoracoscopic (TC) repair of a 2–2.5 cm esophageal incision [29]. ECS was achieved using a prototype suturing system that deploys a metal anchor with a nonabsorbable polypropylene thread (T-bar) on each side of the esophageal defect (CR Bard, Murray Hill, NJ; Ethicon Endosurgery, Cincinnati, OH, USA). The two threads were joined together using a small cylindrical suture-locking device, approximating both sides of the incision. Three to 5 pairs of T-bars were used to close the defect. Thoracoscopic repair took the longest time because of trocar placement and dissection of the periesophageal tissue for localization of the defect in the esophagus. Although ECC was the fastest technique, it could not achieve full-thickness repair of the esophageal wall. Moreover, larger gaping defects could not be bridged by the jaws of the clips. In contrast, ECS anchors were deployed across the entire esophageal wall and showed well-healed scares with the smallest remaining gaps. One of the disadvantages of T-bars is that placing them beyond the gastrointestinal wall cannot be performed under direct vision. So, the needle tip may harm or inadvertedly place a T-bar into an unwanted structure as reported in a previous study [30].

The novel over-the-scope clip (OTSC) system showed promising results for gastrostomy closure [31] and has been used in for closure of postoperative leaks following gastrectomy and primary repair after spontaneous acute esophageal perforation [32]. Cardiac septal occluders might be a valuable alternative. Repici et al. have recently reported the first human case of esophagus-tracheal fistula closure by using a cardiac septal occluder with good results [33]. Other prototype suturing/apposition devices might be of future use in esophagotomy closure, namely, Padlock-G clips (Aponos Medical, Kingston, NH, USA) [34], NDO Plicator (NDO Surgical Inc., Mansfield, MA, USA) [35], g-Cath/g-Prox (Usgi Medical Inc, San Clemente, CA, USA) [36], flexible Endostich (Covidien, North Haven, Conneticut, USA) [37], OverStich (Apollo Endosurgery, Austin, TX, USA) [38], Direct Drive Endoscopic System (DDES Boston Scientific, Natick, MA, USA) [39], Anubis-scope (Karl Storz, Tuttlingen, Germany) [40],and Endo-Samurai (Olympus, Tokyo, Japan) [41].

Von Reitein et al. presented a prototype self-expanding metal stent (SX-ELLA stent, ELLA-CS, Hradec Kralove, Czech Republic) for direct incision esophagotomy closure without any suture [22]. Fifteen-millimeter direct incision esophagotomies were created in 12 domestic pigs using a prototype endoscopic Maryland dissector (Ethicon Endosurgery, Cincinnati, OH, USA). Six animals were randomly assigned to open surgical repair and six animals to endoscopic closure using the self-expanding, covered, nitinol stent in a nonsurvival setting. Pressurized leak test results were not different for stent compared to surgical closures. Six animals underwent transesophageal endoscopic mediastinal interventions and survived for 17 days. Stents were extracted at day 10. All survival animals were found to have complete closure and adequate healing of the esophagotomies, without leakage or infectious complications.

Finally, the hybrid approach presented by Rolanda et al. might be useful for safe esophagotomy closure. Using a thoracoscope with a 5 mm working channel, the authors inserted a needle-holder and performed an end-to-end esophageal anastomosis with gastroscopic intruments assistance [18].

4. Mediastinum and Pneumothorax Management

Injecting air or carbon dioxide (CO_2) is a key component for adequate exposure and visualization, especially in thoracic NOTES. Air insufflated in an uncontrolled manner through the endoscope results in wide fluctuations in intrathoracic and intraperitoneal pressures, overdistension of the gastrointestinal tract, and adverse hemodynamic effects. Von Delius et al. studied the potentional cardiopulmonary effects of transesophageal mediastinoscopy in a porcine model, using a conventional gastroscope [42]. Air insufflation was manually performed and the pressure was monitored through the working port of the gastroscope. In 3 of the 8 pigs, there was pleural injury with tension pneumothorax, resulting in hemodynamic instability. In the remaining 5 pigs, median mediastinal pressure maintained was 4.5 mm Hg (mean 5.4 $\pm$ 2.2 mm Hg). In this uncomplicated mediastinoscopies, peak inspiratory pressures, pH, partial pressure of CO_2, and partial pressure of O_2 were not influenced.

Inadvertent high-pressure pneumomediastinum and pneumothorax have been major complications since the begining of thoracic NOTES [7, 12, 16]. Most authors use thoracic tube drainage for pressure relief. As CO_2 pressure control is also a main concern in abdominal endoscopic

surgery, new insufflators have been adapted to both deliver and monitor CO_2 through the endoscope [43]. These may be of some use in transesophageal NOTES. Meanwhile, using a Veress needle or a transthoracic trocar may be a secure way to achieve good pneumothorax pressure control [18].

There is a great debate whether CO_2 or room air should be used for transesophageal NOTES. CO_2 is far more soluble in blood than air and fatal CO_2 embolism is rare. The effect of CO_2 with respect to laparoscopy has suggested an overall attenuated inflammatory response that may provide a further immunologic benefit. Conversely, room air laparoscopy has been shown to generate a greater inflammatory response, but a recent case-control study did not find a significant difference between the peritoneal inflammatory response of NOTES versus laparoscopy with CO_2 and air pneumoperitoneum [44].

Even for intraesophageal endoscopic surgery, the question if either air or CO_2-insufflation should be used is relevant. A study by Uemura et al. found a decreased need for midazolam in patients undergoing esophageal endoscopic submucosal dissection with CO_2-insufflation when compared to air-insufflation. The authors attributed this decreased need for midazolam to decreased procedural pain [45]. In human POEM procedures, only CO_2-insufflation has been used [26, 46]. Inoue et al. reported that none of the 17 patients in their series had postoperative subcutaneous emphysema, but CT scan just after procedure revealed a small amount of CO_2 deposition in the paraesophageal mediastinum. The authors suggest that positive pressure ventilation with intratracheal intubation should be maintained at higher pressures than those generated by endoscopic CO_2-insufflation in order not only to reduce mediastinal emphysema but also to reduce the risk of air embolization [26].

In their series of 5 patients undergoing POEM, Swaanström et al. observed the development of pneumoperitoneum in 3 patients and placement of a Veress needle was necessary to decompress it [46]. According to the authors, Inoue described this occurrence as well in 10% of this most recent series of more than 100 patients (personal communication) and theorized that it might occur due to gas permeation through the remarkably thin longitudinal muscle fibers of the esophagus [46].

5. Infection Prevention

Since the beginning of NOTES procedures, sterility has been a hurdle. Infection must be prevented by using a clean access site. Most transesophageal protocols follow a 12–24-hour liquid formula diet, intravenous antibiotics and esophageal and stomach irrigation with saline or iodopovidone solution. Despite these precautions, even a sterile overtube used to protect the endoscope from oral contamination becomes contaminated on oral insertion and can transport bacteria to the esophagus, the mediastinum, and the thorax.

Several infectious complications have been reported. In a study by Fritscher et al. two out of 12 pigs had reflux of gastric contents into the esophagus that resulted in spillage through the esophagotomy [28]. The study protocol included 12-hour fasting period before surgery and a 3-day antibiotherapy with enrofloxacin. Despite this, one animal died of severe mediastinitis, whereas the other one developed a subclinical mediastinal abscess found on necropsy. The authors suggested that careful aspiration of gastric contents at the beginning of the procedure should always be performed. Also, the authors concluded that 12 hours of fasting may be too short time to clear the stomach of the animals well enough. In a previous study by Gee et al., one out of four animals developed submucosal abscess, despite 24 h liquid diet, esophagus and stomach lavage with iodopovidone solution and cefazolin injection preoperatively [14].

There is also some controversy about the need for endoscope sterilization. In a recent literature review, Spaun et al. concluded that, although difficult, it is possible to terminally sterilize flexible endoscopes. Steris System 1TM that uses 0.2% peracetic acid was the cheapest and fastest sterilization method and scored second in the risk of recontamination. Ethylene oxide gas (ETO) sterilization has the lowest risk of recontamination but is the slowest and most expensive method. The authors recommend sterile instrumentation for clinical NOTES until well-designed and randomized clinical trials are available and guidelines are published [47].

When transferring the results from animal experiments to human settings, one should keep in mind that anatomy and physiology of the esophagus and the mediastinum in humans are somewhat different from those of the pig, especially with regard to wall structure, motility, and infection pathophysiology of the mediastinum. In humans, a perforation of the esophagus causes severe complications or even death in at least 30–50% of cases [48]. In human POEM, patients are placed on a clear liquid diet 24 hours and given a single preoperative dose of a first generation cephalosporin [46]. Although published series account for a short number of patients, no infectious complications were reported. Neither studies specify if the flexible endoscope was either completely sterilized or conventionally disinfected.

6. Conclusions

Transesophageal NOTES offers new possibilities in less invasive access to mediastinal and thoracic cavities. Ongoing NOTES revolution permitted the development of esophageal submucosal endoscopic techniques with almost immediate human application. POEM is a perfect example of this. Theoretical advantages of transesophageal NOTES warrant the continuation of research, although some hurdles are to be overcome. The critical nature of the organs that involve the esophagus, the risk of hemodynamic instability related to pressure pneumomediastinum and pneumothorax, and potential infectious complications call for caution when transition to human practice.

A hybrid NOTES approach, adding transthoracic assistance, might be the key to safe human translation, as it gives visual control of transesophageal port creation (Figure 2), it may improve esophagotomy closure, it permits triangulation and countertraction using flexible instruments inserted

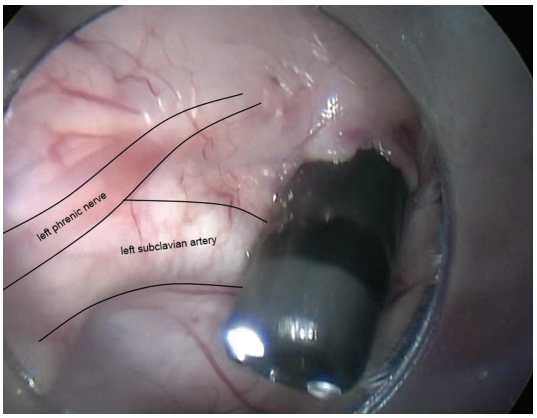

Figure 2: Transthoracic visual control of transesophageal port creation in the upper third of the esophagus (porcine model).

through the gastroscope and rigid instruments inserted through the thoracoscope, and it gives a good intrathoracic pressure control and pneumothorax drainage.

References

[1] J. Moreira-Pinto, E. Lima, J. Correia-Pinto, and C. Rolanda, "Natural orifice transluminal endoscopy surgery: a review," *World Journal of Gastroenterology*, vol. 17, no. 33, pp. 3795–3801, 2011.

[2] A. Decker and T. H. Cherry, "Culdoscopy: a new method in the diagnosis of pelvic disease—Preliminary report," *The American Journal of Surgery*, vol. 64, no. 1, pp. 40–44, 1944.

[3] N. Reddy and P. Rao, "Per oral transgastric endoscopic appendectomy in human," in *Proceedings of the 45th Annual Conference of the Society of Gastrointestinal Endoscopy of India*, pp. 28–29, Jaipur, India, 2004.

[4] A. N. Kalloo, V. K. Singh, S. B. Jagannath et al., "Flexible transgastric peritoneoscopy: a novel approach to diagnostic and therapeutic interventions in the peritoneal cavity," *Gastrointestinal Endoscopy*, vol. 60, no. 1, pp. 114–117, 2004.

[5] R. D. Pai, D. G. Fong, M. E. Bundga, R. D. Odze, D. W. Rattner, and C. C. Thompson, "Transcolonic endoscopic cholecystectomy: a NOTES survival study in a porcine model (with video)," *Gastrointestinal Endoscopy*, vol. 64, no. 3, pp. 428–434, 2006.

[6] E. Lima, C. Rolanda, J. M. Pêgo et al., "Transvesical endoscopic peritoneoscopy: a novel 5 mm port for intra-abdominal scarless surgery," *Journal of Urology*, vol. 176, no. 2, pp. 802–805, 2006.

[7] K. Sumiyama, C. J. Gostout, E. Rajan, T. A. Bakken, and M. A. Knipschield, "Transesophageal mediastinoscopy by submucosal endoscopy with mucosal flap safety valve technique," *Gastrointestinal Endoscopy*, vol. 65, no. 4, pp. 679–683, 2007.

[8] E. Lima, T. Henriques-Coelho, C. Rolanda et al., "Transvesical thoracoscopy: a natural orifice translumenal endoscopic approach for thoracic surgery," *Surgical Endoscopy and Other Interventional Techniques*, vol. 21, no. 6, pp. 854–858, 2007.

[9] G. D. de Palma, S. Siciliano, P. Addeo et al., "A NOTES approach for thoracic surgery: transgastric thoracoscopy via a diaphragmatic incision in a survival porcine model," *Minerva Chirurgica*, vol. 65, no. 1, pp. 11–15, 2010.

[10] Y. H. Liu, H. P. Liu, Y. C. Wu, and P. J. Ko, "Feasibility of transtracheal surgical lung biopsy in a canine animal model," *European Journal of Cardio-thoracic Surgery*, vol. 37, no. 5, pp. 1235–1236, 2010.

[11] A. Fritscher-Ravens, K. Patel, A. Ghanbari et al., "Natural orifice transluminal endoscopic surgery (NOTES) in the mediastinum: long-term survival animal experiments in transesophageal access, including minor surgical procedures," *Endoscopy*, vol. 39, no. 10, pp. 870–875, 2007.

[12] F. F. Willingham, D. W. Gee, G. Y. Lauwers, W. R. Brugge, and D. W. Rattner, "Natural orifice transesophageal mediastinoscopy and thoracoscopy," *Surgical Endoscopy and Other Interventional Techniques*, vol. 22, no. 4, pp. 1042–1047, 2008.

[13] K. Sumiyama, C. J. Gostout, E. Rajan et al., "Pilot study of transesophageal endoscopic epicardial coagulation by submucosal endoscopy with the mucosal flap safety valve technique (with videos)," *Gastrointestinal Endoscopy*, vol. 67, no. 3, pp. 497–501, 2008.

[14] D. W. Gee, F. F. Willingham, G. Y. Lauwers, W. R. Brugge, and D. W. Rattner, "Natural orifice transesophageal mediastinoscopy and thoracoscopy: a survival series in swine," *Surgical Endoscopy and Other Interventional Techniques*, vol. 22, no. 10, pp. 2117–2122, 2008.

[15] T. Woodward, D. McCluskey III, M. B. Wallace, M. Raimondo, J. Mannone, and C. D. Smith, "Pilot study of transesophageal endoscopic surgery: NOTES esophagomyotomy, vagotomy, lymphadenectomy," *Journal of Laparoendoscopic and Advanced Surgical Techniques*, vol. 18, no. 5, pp. 743–745, 2008.

[16] A. Fritscher-Ravens, T. Cuming, B. Jacobsen et al., "Feasibility and safety of endoscopic full-thickness esophageal wall resection and defect closure: a prospective long-term survival animal study," *Gastrointestinal Endoscopy*, vol. 69, no. 7, pp. 1314–1320, 2009.

[17] B. G. Turner, D. W. Gee, S. Cizginer et al., "Feasibility of endoscopic transesophageal thoracic sympathectomy (with video)," *Gastrointestinal Endoscopy*, vol. 71, no. 1, pp. 171–175, 2010.

[18] C. Rolanda, D. Silva, C. Branco, I. Moreira, G. Macedo, and J. Correia-Pinto, "Peroral esophageal segmentectomy and anastomosis with single transthoracic trocar assistance: a step forward in thoracic NOTES," *Endoscopy*, vol. 43, no. 1, pp. 14–20, 2011.

[19] J. Moreira-Pinto, A. Ferreira, A. Miranda, C. Rolanda, and J. Correia-Pinto, "Transesophageal pulmonary lobectomy with single transthoracic port assistance: study with survival assessment in porcine model," *Endoscopy*, vol. 44, no. 4, pp. 354–361, 2012.

[20] K. Sumiyama and C. J. Gostout, "Clinical applications of submucosal endoscopy," *Current Opinion in Gastroenterology*, vol. 27, no. 5, pp. 412–417, 2011.

[21] K. Sumiyama, C. J. Gostout, E. Rajan et al., "Transgastric cholecystectomy: transgastric accessibility to the gallbladder improved with the SEMF method and a novel multibending therapeutic endoscope," *Gastrointestinal Endoscopy*, vol. 65, no. 7, pp. 1028–1034, 2007.

[22] D. von Renteln, M. C. Vassiliou, K. Caca, A. Schmidt, and R. I. Rothstein, "Feasibility and safety of endoscopic transesophageal access and closure using a Maryland dissector and a self-expanding metal stent," *Surgical Endoscopy and Other Interventional Techniques*, vol. 25, no. 7, pp. 2350–2357, 2011.

[23] M. T. Moyer, E. M. Pauli, J. Gopal, A. Mathew, and R. S. Haluck, "Durability of the self-approximating translumenal access technique (STAT) for potential use in natural orifice

translumenal surgery (NOTES)," *Surgical Endoscopy*, vol. 25, no. 1, pp. 315–322, 2011.

[24] A. Fritscher-Ravens, A. Ghanbari, T. Cuming et al., "Comparative study of NOTES alone vs. EUS-guided NOTES procedures," *Endoscopy*, vol. 40, no. 11, pp. 925–930, 2008.

[25] P. J. Pasricha, R. Hawarl, I. Ahmed et al., "Submucosal endoscopic esophageal myotomy: a novel experimental approach for the treatment of achalasia," *Endoscopy*, vol. 39, no. 9, pp. 761–764, 2007.

[26] H. Inoue, H. Minami, Y. Kobayashi et al., "Peroral endoscopic myotomy (POEM) for esophageal achalasia," *Endoscopy*, vol. 42, no. 4, pp. 265–271, 2010.

[27] K. I. Makris, E. Rieder, and L. L. Swanstrom, "Natural orifice trans-luminal endoscopic surgery (NOTES) in thoracic surgery," *Seminars in Thoracic and Cardiovascular Surgery*, vol. 22, no. 4, pp. 302–309, 2010.

[28] B. G. Turner, M. C. Kim, D. W. Gee et al., "A prospective, randomized trial of esophageal submucosal tunnel closure with a stent versus no closure to secure a transesophageal natural orifice transluminal endoscopic surgery access site," *Gastrointestinal Endoscopy*, vol. 73, no. 4, pp. 785–790, 2011.

[29] A. Fritscher-Ravens, J. Hampe, P. Grange et al., "Clip closure versus endoscopic suturing versus thoracoscopic repair of an iatrogenic esophageal perforation: a randomized, comparative, long-term survival study in a porcine model (with videos)," *Gastrointestinal Endoscopy*, vol. 72, no. 5, pp. 1020–1026, 2010.

[30] G. S. Raju, A. Fritscher-Ravens, R. I. Rothstein et al., "Endoscopic closure of colon perforation compared to surgery in a porcine model: a randomized controlled trial (with videos)," *Gastrointestinal Endoscopy*, vol. 68, no. 2, pp. 324–332, 2008.

[31] C. Rolanda, E. Lima, D. Silva et al., "In vivo assessment of gastrotomy closure with over-the-scope clips in an experimental model for varicocelectomy (with video)," *Gastrointestinal Endoscopy*, vol. 70, no. 6, pp. 1137–1145, 2009.

[32] J. Pohl, M. Borgulya, D. Lorenz, and C. Ell, "Endoscopic closure of postoperative esophageal leaks with a novel over-the-scope clip system," *Endoscopy*, vol. 42, no. 9, pp. 757–759, 2010.

[33] A. Repici, P. Presbitero, A. Carlino et al., "First human case of esophagus-tracheal fistula closure by using a cardiac septal occluder (with video)," *Gastrointestinal Endoscopy*, vol. 71, no. 4, pp. 867–869, 2010.

[34] D. J. Desilets, J. R. Romanelli, D. B. Earle, and C. N. Chapman, "Gastrotomy closure with the lock-it system and the padlock-G clip: a survival study in a porcine model," *Journal of Laparoendoscopic and Advanced Surgical Techniques*, vol. 20, no. 8, pp. 671–676, 2010.

[35] M. F. McGee, J. M. Marks, R. P. Onders et al., "Complete endoscopic closure of gastrotomy after natural orifice translumenal endoscopic surgery using the NDO Plicator," *Surgical Endoscopy and Other Interventional Techniques*, vol. 22, no. 1, pp. 214–220, 2008.

[36] D. L. Seaman, C. J. Gostout, J. G. de la Mora Levy, and M. A. Knipschield, "Tissue anchors for transmural gut-wall apposition," *Gastrointestinal Endoscopy*, vol. 64, no. 4, pp. 577–581, 2006.

[37] R. P. Voermans, A. M. Worm, M. I. van Berge Henegouwen, P. Breedveld, W. A. Bemelman, and P. Fockens, "In vitro comparison and evaluation of seven gastric closure modalities for natural orifice transluminal endoscopic surgery (NOTES)," *Endoscopy*, vol. 40, no. 7, pp. 595–601, 2008.

[38] S. V. Kantsevoy and P. J. Thuluvath, "Successful closure of a chronic refractory gastrocutaneous fistula with a new endoscopic suturing device (with video)," *Gastrointestinal Endoscopy*, vol. 75, no. 3, pp. 688–690, 2012.

[39] C. C. Thompson, M. Ryou, N. J. Soper, E. S. Hungess, R. I. Rothstein, and L. L. Swanstrom, "Evaluation of a manually driven, multitasking platform for complex endoluminal and natural orifice transluminal endoscopic surgery applications (with video)," *Gastrointestinal Endoscopy*, vol. 70, no. 1, pp. 121–125, 2009.

[40] B. Dallemagne and J. Marescaux, "The ANUBIS project," *Minimally Invasive Therapy and Allied Technologies*, vol. 19, no. 5, pp. 257–261, 2010.

[41] G. O. Spaun, B. Zheng, and L. L. Swanström, "A multitasking platform for natural orifice translumenal endoscopic surgery (NOTES): A benchtop comparison of a new device for flexible endoscopic surgery and a standard dual-channel endoscope," *Surgical Endoscopy and Other Interventional Techniques*, vol. 23, no. 12, pp. 2720–2727, 2009.

[42] S. von Delius, D. Wilhelm, H. Feussner et al., "Natural orifice transluminal endoscopic surgery: cardiopulmonary safety of transesophageal mediastinoscopy," *Endoscopy*, vol. 42, no. 5, pp. 405–412, 2010.

[43] M. Bergström, P. Swain, and P. O. Park, "Measurements of intraperitoneal pressure and the development of a feedback control valve for regulating pressure during flexible transgastric surgery (NOTES)," *Gastrointestinal Endoscopy*, vol. 66, no. 1, pp. 174–178, 2007.

[44] J. A. Trunzo, M. F. McGee, L. T. Cavazzola et al., "Peritoneal inflammatory response of natural orifice translumenal endoscopic surgery (NOTES) versus laparoscopy with carbon dioxide and air pneumoperitoneum," *Surgical Endoscopy and Other Interventional Techniques*, vol. 24, no. 7, pp. 1727–1736, 2010.

[45] M. Uemura, N. Ishii, T. Itoh, K. Suzuki, and Y. Fujita, "Effects of carbon dioxide insufflation in esophageal endoscopic submucosal dissection," *Hepatogastroenterology*, vol. 59, pp. 115–116, 2011.

[46] L. L. Swanström, E. Rieder, and C. M. Dunst, "A stepwise approach and early clinical experience in peroral endoscopic myotomy for the treatment of achalasia and esophageal motility disorders," *Journal of the American College of Surgeons*, vol. 213, no. 6, pp. 751–756, 2011.

[47] G. O. Spaun, T. A. Goers, R. A. Pierce, M. A. Cassera, S. Scovil, and L. L. Swanstrom, "Use of flexible endoscopes for NOTES: sterilization or high-level disinfection?" *Surgical Endoscopy and Other Interventional Techniques*, vol. 24, no. 7, pp. 1581–1588, 2010.

[48] K. E. Grund and T. G. Lehmann, "Transesophageal NOTES a critical analysis of relevant problems," *Minimally Invasive Therapy and Allied Technologies*, vol. 19, no. 5, pp. 252–256, 2010.

Hindawi Publishing Corporation
Minimally Invasive Surgery
Volume 2012, Article ID 415430, 4 pages
doi:10.1155/2012/415430

Clinical Study

Glove Technique in Single-Port Access Laparoscopic Surgery: Results of an Initial Experience

Lorenzo Livraghi, Mattia Berselli, Veronica Bianchi, Lorenzo Latham, Luca Farassino, and Eugenio Cocozza

Dipartimento di Chirurgia, Azienda Ospedaliera, Ospedale di Circolo e Fondazione Macchi, 21100 Varese, Italy

Correspondence should be addressed to Eugenio Cocozza, eugenio.cocozza@ospedale.varese.it

Received 19 December 2011; Revised 18 January 2012; Accepted 18 January 2012

Academic Editor: Luigi Boni

Introduction. Single-incision laparoscopic surgery (SILS) is a virtually "scarless" technique. A retrospective analysis is performed to evaluate an initial experience of this surgical approach. *Materials and Methods*. From January 2010 to October 2011, SILS was considered as a minimally invasive approach to abdominal disease. The access was made by a standard wound protector and a size 6 glove. A series of little accesses were made on the tips of the glove-fingers to induce pneumoperitoneum and to create a working channel for the laparoscopic instruments. An analysis of costs of this technique was made too. *Results*. SILS was successfully completed with low cost in 34 patients: 20 appendectomy, 12 cholecystectomy, and 2 right colectomy were performed with a median operative time of 35, 45, and 67.5 minutes, respectively. In no patient any conversion to standard laparoscopy or to open surgery was needed. The postoperative course was uneventful in all patients. In right hemicolectomy, the oncological parameters were respected. *Conclusions*. In this paper the glove-port technique showed multiple advantages. The SILS is a feasible approach for some pathologies in selected patients. The glove-port is a simple, low-cost, reproducible, and sure method to perform SILS in a high-experienced laparoscopic surgical centre.

1. Introduction

Laparoscopic surgery is a well-established surgical technique for a variety of procedures. In recent years, multiple attempts to decrease parietal trauma and visible scars have been proposed. These efforts include the reduction of the diameter of the port size, the reduction in the number of the laparoscopic access [1–5], and the introduction of natural orifice transluminal endoscopic surgery (NOTES) [6–8] and of single incision laparoscopic surgery (SILS) [9–12]. SILS is a virtually "scarless" technique; the single port is hidden in the umbilicus. It is a rapidly evolving field: this approach is recently under investigation in some laparoscopic surgical centres to achieve less postoperative pain, less discomfort, and fewer surgical scares.

In a laparoscopic centre, a retrospective analysis is performed to evaluate an initial experience in laparoscopic surgery with the single-port technique and a periumbilical access; a detailed description of the SILS approach as a simple, safe, and cheap technique is done.

2. Patients and Methods

2.1. Patients. In a surgical centre from January 2010 to October 2011 SILS was considered for minimally invasive approach for abdominal disease. All patients underwent surgery after obtaining an informed consent. A Patients selection was made before deciding the proper surgical approach. Exclusion criteria for minimally invasive approach were the same of traditional laparoscopic surgery.

Clinical or radiological signs of complicated appendix or gallbladder disease (masses and abscesses) and of voluminous neoplasms, the presence of liver cirrhosis, peritonitis, previous upper abdominal surgery, or severe obesity were exclusion criteria for SILS.

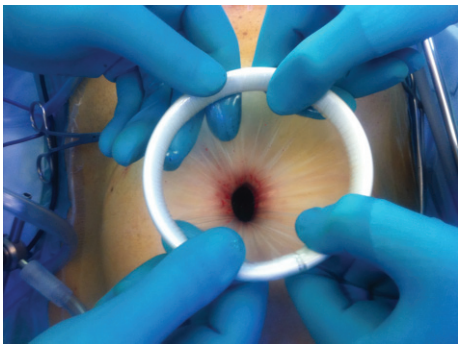

Figure 1: Placement of wound protector.

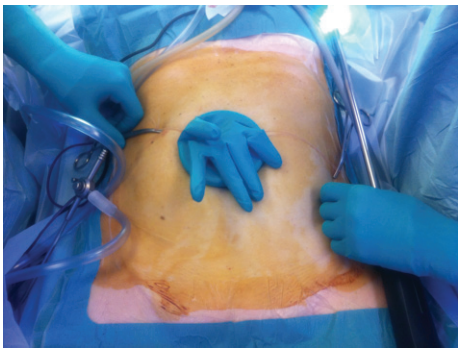

Figure 2: Placement of surgical glove.

Figure 3: Induction of pneumoperitoneum.

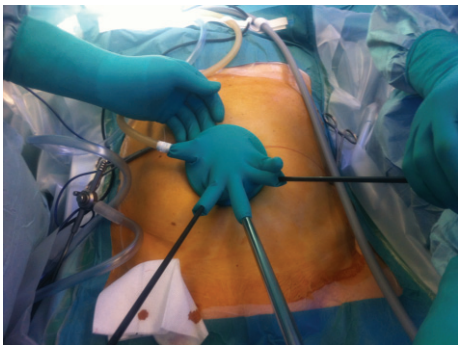

Figure 4: Placement of instruments.

2.2. Single-Port Access Technique: Surgical Glove Port Construction. An access device was made by a standard wound protector (a small size or extra small size ALEXIS wound retractor; Applied Medical, CA, USA) (Figure 1) and size 6, nonlatex sterile glove. The wound retractor was introduced through the small umbilical incision. The surgical glove was fixed to the outer ring of the wound retractor (Figure 2). A little access was made on the tip of one finger, and the CO2 pipe was connected to induce pneumoperitoneum (Figure 3). Other accesses were made on the others fingers to create a working channel for the laparoscopic instruments (Figure 4). Five- or three-millimeter traditional or curved laparoscopic instruments were used.

3. Results

SILS was successfully completed in 34 patients: 20 appendectomy was performed in female patients (median age 15, range 9–32 years), cholecystectomy in 12 patients (11 female and 1 male, median age 35, range 17–83 years), and right hemicolectomy in 2 female patients (55 and 64 years old).

In no patient conversion to standard laparoscopy or to open surgery was needed.

The median operative time for appendectomy, cholecistectomy and right hemicolectomy was 35, 45, and 67.5 minutes, respectively.

Blood loss was minimal in all cases. No wound complication occurred; a picture of the scare at the end of a procedure is showed in the Figure 5.

The postoperative course was uneventful in all patients. The median postoperative in-hospital stay was 2 days for appendectomy and cholecistectomy and 6 days for right hemicolectomy.

The characteristics of patients and the perioperative results are resumed in Table 1.

An analytical analysis of postoperative pain was not performed; however, no patient needed any opiates drugs and no discharged was conditioned by sorrow.

In right hemicolectomy, the resection margins were oncologically correct and the number of regional limphonodes was adequate: in the surgical specimen of the first patient, 17 limphonodes were found with 2 micrometastases; in the second patient, 14 limphonodes were found without any sign of disease. An adequate preoperative staging was performed: thoracic and abdominal CT with contrast enhancement and colonoscopy excluded, respectively distant metastases and other cancer colonic localization.

An analysis of costs of this technique was made too. The prices of wound protector and of glove are respectively 50 and 0,51 euro (IVA 21% Excluded).

4. Discussion

A series of 34 patients underwent SILS with "Glove Technique" in a General Surgery Unit: postoperative complication rate was nil, oncological requires were respected in

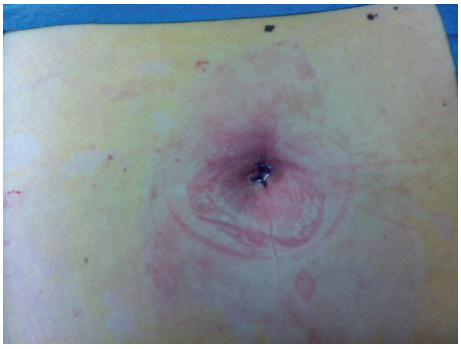

Figure 5: The umbilical scare at the end of a procedure.

Table 1: Patients and perioperative results.

	Cholecistectomy	Appendectomy	Right colectomy
Number of patients	12	20	2
Median age	26	15	59,5
Conversion to standard laparoscopy or to open	NO	NO	NO
Median operative time	45	35	67,5
Postoperative complications	NONE	NONE	NONE
Median postoperative in-hospital stay	2	2	6

approaching to right colon neoplasms, and, furthermore, this technique is cheaper.

The procedures did not seem to take longer than expected for traditional laparoscopic approaches. Each intraoperative step was accomplished with confidence, similar to standard multiport laparoscopy. These results are in accordance with those reported in the literature: the use of the "glove-port" has been reported previously in general surgery [13–15] studies as in others specialities; in some papers it is moving from single-case descriptions to case series [16, 17].

In this paper the glove-port technique showed multiple advantages. It is easy to use and can be simply accommodated to the abdominal wall even in overweight patients. The glove-port allows simultaneous passage of several laparoscopic instruments through one small incision, and this fact can have several merits: the effect of the two rings of the wound retractor can prevent subcutaneous emphysema, port-site infection and bleeding. The umbilical incision is minimized; this advantage can decrease the postoperative pain and the rate of surgical site hernia development.

Many devices have three or four ports, whereas the glove-port allows to use simultaneously up to five instruments without any size limit. A wide axis of movements is possible with the glove-port technique: the instruments inside the abdomen can be used apart, easily crossed or rotated as required in any situation.

The cost of technique is very low, and this can be an advantage compared to the prices of some commercial dedicated devices.

The glove is not certified for this use, and the single-port access needs to be considered as advanced operative technique. The use of surgical glove obviates issues of devices cost but of course not operative skills. Intra-abdominal smoke that may slow the procedure somewhat is another problem because there is no separate venting channel.

A significant coordination between the surgeon and the camera holder is needed. The surgeon also has to be adapted to counterintuitive movements due to frequent crossing of the instrument shafts at the point of entry into the abdominal cavity.

Finally, if the lack of a fixed axis for instruments can be an advantage for movements as above discussed, it can cause in some conditions a further difficulty for the surgeon: the glove cannot always give just the same stability of a traditional trocar or single-incision device.

5. Conclusions

The SILS is a feasible approach for some pathologies in selected patients. The glove-port is a simple, reproducible and sure method to perform SILS in a high-experienced laparoscopic surgical centre. Further studies are necessary to demonstrate the advantages in terms of pain control, patient satisfaction, and surgical-related morbidity.

References

[1] K. W. Lee, C. M. Poon, K. F. Leung, D. W. H. Lee, and C. W. Ko, "Two-port needlescopic cholecystectomy: prospective study of 100 cases," *Hong Kong Medical Journal*, vol. 11, no. 1, pp. 30–35, 2005.

[2] D. A. Osborne, G. Alexander, B. Boe, and E. E. Zervos, "Laparoscopic cholecystectomy: past, present, and future," *Surgical Technology International*, vol. 15, pp. 81–85, 2006.

[3] N. Tagaya, K. Rokkaku, and K. Kubota, "Needlescopic cholecistectomy versus needlescope-assisted laparoscopic cholecistectomy," *Surgical Laparoscopy Endoscopy & Percutaneous Techniques*, vol. 17, pp. 375–379, 2007.

[4] P. L. Legget, R. Churchman-Winn, and G. Miller, "Minimizing ports to improve laparoscopic cholecistectomy," *Surgical Endoscopy*, vol. 14, pp. 32–36, 2000.

[5] T. Bisgaard, B. Klarskov, R. Trap, H. Kehlet, and J. Rosenberg, "Microlaparoscopic vs conventional laparoscopic cholecystectomy: a prospective randomized double-blind trial," *Surgical Endoscopy and Other Interventional Techniques*, vol. 16, no. 3, pp. 458–464, 2002.

[6] D. J. Scott, S. J. Tang, R. Fernandez et al., "Completely transvaginal NOTES cholecystectomy using magnetically anchored instruments," *Surgical Endoscopy and Other Interventional Techniques*, vol. 21, no. 12, pp. 2308–2316, 2007.

[7] C. Zornig, H. Mofid, A. Emmermann, M. Alm, H. A. Von Waldenfels, and C. Felixmüller, "Scarless cholecystectomy with combined transvaginal and transumbilical approach in a series of 20 patients," *Surgical Endoscopy and Other Interventional Techniques*, vol. 22, no. 6, pp. 1427–1429, 2008.

[8] J. P. Pearl and J. L. Ponsky, "Natural orifice translumenal endoscopic surgery: a critical review," *Journal of Gastrointestinal Surgery*, vol. 12, no. 7, pp. 1293–1300, 2008.

[9] J. F. Zhu, H. Hu, Y. Z. Ma, M. Z. Xu, and F. Li, "Transumbilical endoscopic surgery: a preliminary clinical report," *Surgical Endoscopy and Other Interventional Techniques*, vol. 23, no. 4, pp. 813–817, 2009.

[10] P. Bucher, F. Pugin, and P. Morel, "Single port access laparoscopic right hemicolectomy," *International Journal of Colorectal Disease*, vol. 23, no. 10, pp. 1013–1016, 2008.

[11] J. H. Kaouk, G. P. Haber, R. K. Goel et al., "Single-port laparoscopic surgery in urology: initial experience," *Urology*, vol. 71, no. 1, pp. 3–6, 2008.

[12] F. H. Remzi, H. T. Kirat, J. H. Kaouk, and D. P. Geisler, "Single-port laparoscopy in colorectal surgery," *Colorectal Disease*, vol. 10, no. 8, pp. 823–826, 2008.

[13] J. Leroy, F. Costantino, R. A. Cahill et al., "Fully laparoscopic colorectal anastomosis involving percutaneous endoluminal colonic anvil control (PECAC)," *Surgical Innovation*, vol. 17, no. 2, pp. 79–84, 2010.

[14] D. Uematsu, G. Akiyama, M. Matsuura, and K. Hotta, "Single-access laparoscopic colectomy with a novel multiport device in sigmoid colectomy for colon cancer," *Diseases of the Colon and Rectum*, vol. 53, no. 4, pp. 496–501, 2010.

[15] H. Ishida, N. Okada, K. Ishibashi, T. Ohsawa, K. Kumamoto, and N. Haga, "Single-incision laparoscopic-assisted surgery for colon cancer via a periumbilical approach using a surgical glove: initial experience with 9 cases," *International Journal of Surgery*, vol. 9, pp. 150–154, 2011.

[16] T. H. Hong, Y. K. You, and K. H. Lee, "Transumbelical single-port laparoscopic cholecistectomy," *Surgical Endoscopy*, vol. 23, pp. 1393–1397, 2009.

[17] M. Hayashi, M. Asakuma, K. Komeda, Y. Miyamoto, F. Hirokawa, and N. Tanigawa, "Effectiveness of a surgical glove port for single port surgery," *World Journal of Surgery*, vol. 34, no. 10, pp. 2487–2489, 2010.

Hindawi Publishing Corporation
Minimally Invasive Surgery
Volume 2012, Article ID 482079, 7 pages
doi:10.1155/2012/482079

Research Article

Minilaparoscopic Colorectal Resections: Technical Note

S. Bona, M. Molteni, and M. Montorsi

Department of General Surgery, IRCCS Istituto Clinico Humanitas, University of Milan School of Medicine, Via Manzoni 56, 20089 Rozzano, Milano, Italy

Correspondence should be addressed to M. Molteni, mattia.molteni@humanitas.it

Received 18 January 2012; Accepted 23 January 2012

Academic Editor: Luigi Boni

Laparoscopic colorectal resections have been shown to provide short-term advantages in terms of postoperative pain, general morbidity, recovery, and quality of life. To date, long-term results have been proved to be comparable to open surgery irrefutably only for colon cancer. Recently, new trends keep arising in the direction of minimal invasiveness to reduce surgical trauma after colorectal surgery in order to improve morbidity and cosmetic results. The few reports available in the literature on single-port technique show promising results. Natural orifices endoscopic techniques still have very limited application. We focused our efforts in standardising a minilaparoscopic technique (using 3 to 5 mm instruments) for colorectal resections since it can provide excellent cosmetic results without changing the laparoscopic approach significantly. Thus, there is no need for a new learning curve as minilaparoscopy maintains the principle of instrument triangulation. This determines an undoubted advantage in terms of feasibility and reproducibility of the procedure without increasing operative time. Some preliminary experiences confirm that minilaparoscopic colorectal surgery provides acceptable results, comparable to those reported for laparoscopic surgery with regard to operative time, morbidity, and hospital stay. Randomized controlled studies should be conducted to confirm these early encouraging results.

1. Introduction

Laparoscopic surgery (LS) for both benign and neoplastic colonic disease has become a standard procedure worldwide [1–8], although its distribution is currently limited [9]. Many authors reported adequacy and short-term benefits also for laparoscopic rectal procedures [10–13]; nevertheless, large randomized studies and oncologic results are still lacking. In recent years, innovative endoscopic procedures such as single-port laparoscopic surgery (SILS) [14], natural orifices transluminal endoscopic surgery (NOTES) [15], and needlescopic surgery (NS) [16] have been introduced to further reduce surgical invasiveness and abdominal wall trauma. This goal has been achieved by reducing the number of ports (SILS), avoiding transabdominal incisions (NOTES), or reducing port size (NS). This should possibly reduce postoperative pain and lower the incidence of wound infections and port site hernias, besides improving cosmetic results. NOTES has been performed mainly on experimental models [17, 18], and its application in clinical environment is very limited [19, 20]. Several attempts with single-port technique have been made for various procedures, including appendectomy [21], cholecystectomy [22], splenectomy [23], inguinal hernia repair [24], and in paediatric [25], gynaecologic [26], and urologic [27] surgery; few preliminary experiences are available also for colorectal surgery [28–46]. Likewise, NS has been gradually introduced in the aforementioned surgical fields, with some preliminary results also in colorectal surgery [47–55]. The main drawback of SILS is the loss of triangulation of surgical instruments in the operative field, which despite recent development of curved instruments and flexible endoscopes enhances technical difficulty and requires a long learning curve. Needlescopic technique keeps port positioning unchanged compared to standard laparoscopic procedures and therefore has minimal impact on the surgeon. Nevertheless, few technical aspects need to be considered when approaching needlescopic colorectal surgery. Since reports are limited in this field, we aim to review technical points such as instrumentation and its use in the different steps of the operation.

Figure 1: Minilaparoscopic 3 mm instrumentation available to date.

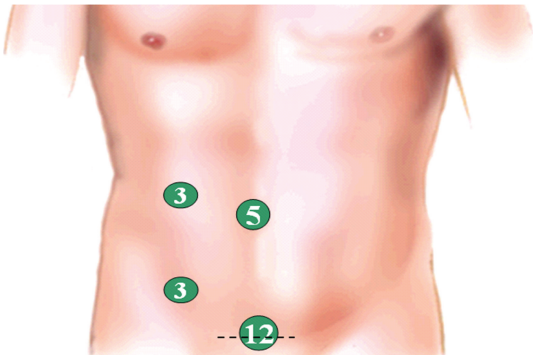

Figure 2: Trocar placement for left-side resection.

2. Instrumentation

In our practice, laparoscopic colorectal resections are currently performed with a 3- to 5-port (5–12 mm size) technique, intracorporeal anastomosis whenever possible, and specimen extraction through a suprapubic transverse incision. Laparoscopic instrumentation consists of 30° scope, atraumatic graspers, coagulating hook, bipolar grasper, clip applier, ultrasonic dissector (optional), suction device, retractor, needle holder, and linear stapler. Apart from the clip applier, the ultrasonic dissector, and the stapler, all instruments are available in 3 mm size (Figure 1) still keeping a high standard of quality and performance. Only 3 mm laparoscopes, although providing a good vision, are still less performant than 5 mm HD scopes which may be preferable in advanced laparoscopic procedures. Since a minilaparotomy is always planned, open access with a Hasson port may be performed at the suprapubic site allowing introduction of 10–12 mm devices. Further trocars ranging from 3 to 5 mm size are placed after insufflation under direct vision.

3. Left Colectomy and Rectal Resection

Port positioning for minilaparoscopic left colectomy is shown in Figure 2. After placement of the 12 mm Hasson port at the site of the planned minilaparotomy, one 5 mm port is inserted through the umbilicus for the scope, and two 3 mm ports are placed in the right hypochondrium on the midclavicular line and in the right lower quadrant. Such position allows good triangulation in order to work between the left hypochondrium and the pelvis. An additional 3 mm port may be placed in the left lower quadrant for the surgeon to switch hands and improve triangulation during mobilization of the splenic flexure or dissection of the lower rectum. When in place, this port may be used by the assistant for additional grasping or to expose the operative field with a retractor when working in the pelvis. A standard medial to lateral approach is used starting with vascular ligation followed by Toldt's fascia dissection. Clips for vascular ligation are inserted through the 12 mm suprapubic port (Figure 3). Mobilization of the splenic flexure may be performed indifferently as a first step or before bowel section. Dissection is performed with the 3 mm coagulating hook; should the ultrasonic dissector be used, the 3 mm port in the right and/or left lower quadrant is to be replaced with a 5 mm port. Three mm instruments allow fine grasping of elements such as vessels and peritoneum, but care must be taken during lifting of the mesocolon as the small contact surface may result in the tearing of the vessels which need to be preserved; it is therefore advisable to interpone a sponge (inserted through the 12 mm port) between the grasper and the tissue to be handled. Similarly, since mesorectal integrity is of utmost importance during total mesorectal excision in rectal cancer surgery, grasping of the mesorectal fascia with small instruments is to be avoided, and a wad of gauze held by the grasper should be used to expose the "holy plane" (Figure 4). If a stronger retraction is needed to achieve dissection of the lower rectum or in case of bulky tumours in obese patients, a 10 mm retractor may be introduced through the 12 mm suprapubic port. The same port is used to place the linear stapler and transect the rectum at any level down to the pelvic floor (Figure 5). After specimen retrieval, the suprapubic minilaparotomy is closed leaving in place the 12 mm port which may be useful for extraction of the staple trocar, anterior retraction during confection of low colorectal anastomosis, and introduction of sutures if the peritoneum is to be closed. Alternatively, the suprapubic minilaparotomy may be performed as a first step of the operation and sealed temporarily with a device which allows air-tight placement

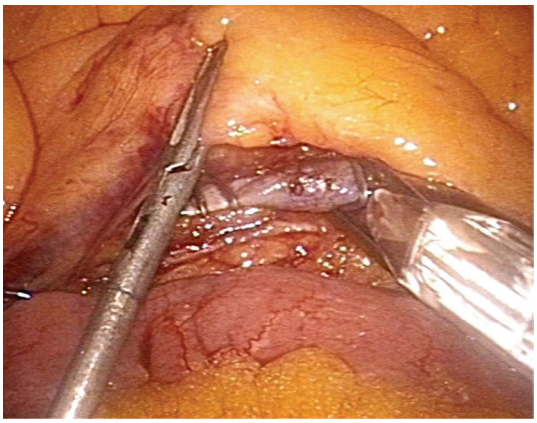

Figure 3: Three-millimeter grasper exposes IMV (3 mm port in the right hypochondrium, left hand) while 12 mm device places clips for vessel division (12 mm port above the pubis, right hand).

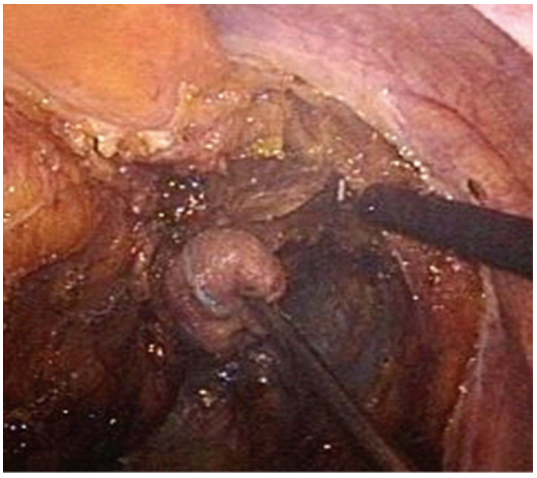

Figure 4: Dissection of the mesorectal right side.

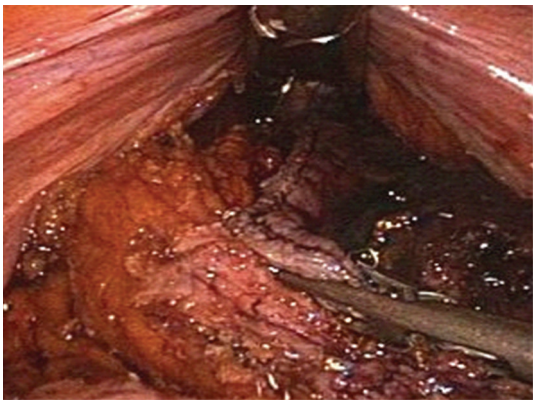

Figure 5: Rectal transection performed by linear stapler introduced by the suprapubic 12 mm port.

Figure 6: Trocar placement for right–side resection.

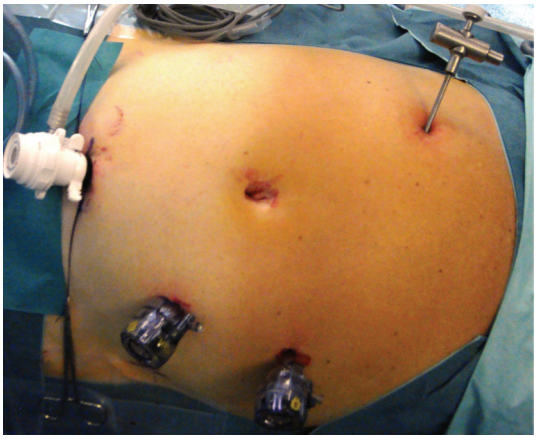

Figure 7: Trocar placement for right–side resection.

of a 12 mm port. At the end of the procedure, the ports are removed under vision to check eventual bleeding, and the 12 mm port is extracted at last.

4. Right Colectomy

The 12 mm Hasson port is inserted above the pubis using the open technique, and two additional ports are placed under vision: one 5 mm port is placed in the left lower quadrant for the introduction of the scope and one 3 mm port in the left hypochondrium on the midclavicular line. Such position allows good triangulation when working in the right abdomen and on the middle transverse colon. The use of the ultrasonic dissector requires a 5 mm port in the left upper quadrant. An optional 3 mm port may be placed in the right hypochondrium to allow grasping and retraction by the assistant (Figures 6 and 7). Dissection is carried on with the same principles described above. The clip applier and linear stapler are introduced through the 12 mm port. After completing the mobilization and the bowel transaction, the specimen is pushed in the right hypochondrium. A double enterotomy is performed in the distal ileum and transverse colon, and a stapled side-to-side isoperistaltic anastomosis is performed. Due to the direction of the linear stapler introduced through the suprapubic port, the visceral stumps must be correctly oriented using one or two traction sutures held by graspers. The anastomosis is completed with a running suture, and the ileal mesentery and transverse mesocolon are approximated. Five and 3 mm ports are retrieved under vision, and the specimen is extracted via a suprapubic incision.

5. Discussion

Laparoscopy has been widely proven to be a feasible, safe, and effective technique to perform colorectal resections [1, 2, 56–61] leading to clinically relevant advantages in selected patients such as reduction of postoperative pain [1, 62] and complications, shortening hospital stay and improving recovery [1, 58, 63], wound healing [1, 64], and cosmesis [65, 66]. Moreover, minimally invasive surgery has facilitated the application of enhanced recovery programs in colorectal surgery [67–69]. Long-term outcome of laparoscopic colonic resection for cancer is not different from what has been achieved by open surgery procedures [2]. Therefore, some authors suggest that laparoscopy should be the preferred

technique to perform colectomy in patients suitable for this approach [1]. New trends have been developed in order to further reduce the impact of surgical procedure in patients undergoing colorectal resections. Three main directions have been undertaken in specialized centres: SILS, which aims to the reduction of port number, NOTES, in which surgical instruments are inserted in hollow organs trough natural openings, and minilaparoscopic colorectal surgery, based on reduction of port size.

SILS was first described by Piskun and Rajpal for cholecystectomy as early as 1999 [14]; this term currently identifies surgical procedures that provide the placement of one port having three or more working channels within the umbilicus. Surgeons who perform single-port colorectal surgery seem to agree that this technique, though should be suitable for the resection of colon cancer with respect to oncologic principles, is demanding because of the difficulties of exposure of the operative field and because of the risk of "crowding" while maneuvering laparoscopic instruments, although specially designed for this purpose [44].

NOTES was first described by Kalloo et al. in 2004 [15]: this term currently identifies surgical procedures that provide the placement of flexible endoscopic systems through natural orifices (per-oral, transvaginal, transanal, transumbilical, or transvesical routes) entering the peritoneal cavity through an incision of hollow organs and approaching target organs to perform intra-abdominal procedures. Many procedures ranging in complexity from cholecystectomy to colorectal resections may be theoretically performed entirely endoscopically without the need for abdominal incisions [70, 71]. The advantages of such an approach include absence of incisional pain and wound complications (including infection and hernias), improved cosmetic results, and faster recovery. Although studies have shown the feasibility of an NOTES approach, significant constraints have been identified with the use of a flexible endoscopy platform, including a relative inability to apply off-axis forces, mechanical stability, inadequate triangulation, and limits in passing multiple instruments simultaneously into the peritoneal cavity. Concerns have also been expressed about the risk of postoperative leak and infections: with the intestinal closure systems currently adopted for NOTES access sites, it is doubtful that 100% safety can be achieved [72].

At present, the need for improved technology remains a major limitation for SILS and NOTES.

The use of smaller ports to perform laparoscopic procedures is defined with different terms such as "minilaparoscopy," "microlaparoscopy," "miniendoscopic" or "microendoscopic surgery," and "microinvasive surgery" [16]. In general, NS is the term used to describe LS with instruments with an external diameter of 2-3 mm, as defined by Gagner and Garcia-Ruiz [16]. Santoro et al. have defined "miniendoscopic surgery" as any procedure that uses endoscopic instruments and optics 5 mm in diameter or smaller [55].

Needlescopic colorectal surgery is feasible, effective, and easy to perform since no specific training is required [55]. Surgeons who experienced NS in the aforementioned surgical fields [47–55] report several advantages over standard LS. In general, reduction of laparoscopic port size is associated with limited trauma on the abdominal wall. Smaller incisions result in decreased incisional pain and reduced risk of complications such as port-site bleeding, infection, and herniation. Moreover, minimal scarring allows better cosmetic results [73]. On the other hand, narrow operative field, lower image quality due to lack of definition and reduced light transmission [16, 74], and blurred vision with the use of electrocautery [75] are almost unanimously reported to be the "Achilles' heel" of this technique and cause more stress for the surgeon especially when using 3 mm scopes. The use of modern 5 mm optics with high-definition cameras and powerful light sources is much more comfortable in performing advanced laparoscopic procedures, though a 3 mm optic inserted through an ancillary port may be useful if the 5 mm port is to be used for a larger instrument such as the clip applier.

As for smaller instruments, they may show a weaker grasping capability and a lack of tensile strength due to increased flexibility, particularly in the presence of fibrosis or inflammation. Manipulation of tiny laparoscopic instruments may result in an increased risk of tissue damage during dissection [16, 74, 76–79].

Apart from these precautions, moving from standard laparoscopic technique to needlescopic colorectal resections is not to be considered as approaching a new technique but simply an adaptation of a well-established practice and does not require a long learning curve. None of the steps of the operation has shown difficulties resulting from the use of miniaturized instruments. A good exposition of the surgical field has been always achieved during vessel ligation and viscera dissection, transection, and anastomosis. Building on the experience gained from needlescopic procedures such as cholecystectomy and appendectomy, we decided not to give up the greater definition provided by 5 mm scopes, since the 3 mm optics are still less performant for more advanced and complex procedures.

The 3 mm grasper has been shown to provide good traction, also during gentle dissection. We used a simple trick to overcome its aforementioned limits: a wad of gauze held within the jaws of the instrument itself was used for lifting and retracting viscera in order to increase its strength and decrease the risk of injury of other organs.

One aspect that has been reconsidered performing needlescopic colorectal surgery is the position of trocars: we thought it would be logical to incorporate the only 12 mm port that must necessarily be placed for the introduction of the stapler in the minilaparotomy which is generally a transverse suprapubic incision; we therefore started introducing the stapler from a suprapubic port not only for low rectal resection but also to transect the upper rectum and transverse colon. The use of the stapler from the suprapubic port did not result in substantial differences in bowel transection. Nevertheless, performing an intracorporeal side-to-side mechanical ileocolic anastomosis from the suprapubic port requires wider mobilization of the transverse colon in order to place it parallel to the stapler. Approximation and orientation of the ileal and colonic stumps is best achieved by pulling on two stitches placed at each end of the anastomosis, the proximal one being held by the 3 mm grasper in the right

hypochondrium and the distal one passing through the 12 mm suprapubic port. The 3 mm grasper in the right hypochondrium is also useful during hand suturing of the enterotomies.

Finally, attention must be paid when maneuvering 3 mm instruments, which must be done under direct vision throughout the operation.

Our experience suggests that in well-trained hands and for properly selected patients, ports can be reduced in size safely without a negative impact on the surgeon's ability to perform laparoscopic colorectal resections. These findings should promote a larger prospective randomized comparison with conventional laparoscopy to determine whether this refinement of laparoscopic colorectal surgery confers concrete and incontrovertible benefits to the patients.

References

[1] W. Schwenk, O. Haase, J. Neudecker, and J. M. Müller, "Short term benefits for laparoscopic colorectal resection," *Cochrane Database of Systematic Reviews*, no. 3, Article ID CD003145, 2005.

[2] E. Kuhry, W. F. Schwenk, R. Gaupset, U. Romild, and H. J. Bonjer, "Long-term results of laparoscopic colorectal cancer resection," *Cochrane Database of Systematic Reviews*, no. 2, Article ID CD003432, 2008.

[3] P. J. Guillou, P. Quirke, H. Thorpe et al., "Short-term endpoints of conventional versus laparoscopic-assisted surgery in patients with colorectal cancer (MRC CLASICC trial): multicentre, randomised controlled trial," *Lancet*, vol. 365, no. 9472, pp. 1718–1726, 2005.

[4] M. Buunen, R. Veldkamp, W. C. Hop et al., "Survival after laparoscopic surgery versus open surgery for colon cancer: long-term outcome of a randomised clinical trial," *The Lancet Oncology*, vol. 10, no. 1, pp. 44–52, 2009.

[5] K. Umanskiy, G. Malhotra, A. Chase, M. A. Rubin, R. D. Hurst, and A. Fichera, "Laparoscopic colectomy for crohn's colitis. A large prospective comparative study," *Journal of Gastrointestinal Surgery*, vol. 14, no. 4, pp. 658–663, 2010.

[6] E. J. Eshuis, J. F. M. Slors, P. C. F. Stokkers et al., "Long-term outcomes following laparoscopically assisted versus open ileocolic resection for Crohn's disease," *British Journal of Surgery*, vol. 97, no. 4, pp. 563–568, 2010.

[7] X. J. Wu, X. S. He, X. Y. Zhou, J. Ke, and P. Lan, "The role of laparoscopic surgery for ulcerative colitis: systematic review with meta-analysis," *International Journal of Colorectal Disease*, vol. 25, no. 8, pp. 949–957, 2010.

[8] U. A. Ali, F. Keus, J. T. Heikens et al., "Open versus laparoscopic (assisted) ileo pouch anal anastomosis for ulcerative colitis and familial adenomatous polyposis," *Cochrane Database of Systematic Reviews*, no. 1, Article ID CD006267, 2009.

[9] J. C. Carmichael, H. Masoomi, S. Mills, M. J. Stamos, and N. T. Nguyen, "Utilization of laparoscopy in colorectal surgery for cancer at academic medical centers: does site of surgery affect rate of laparoscopy?" *American Surgeon*, vol. 77, no. 10, pp. 1300–1304, 2011.

[10] G. D. McKay, M. J. Morgan, S. K. Wong et al., "The South Western Sydney Colorectal Tumor Group. Improved short-term outcomes of laparoscopic versus open resection for colon and rectal cancer in an area health service: a multicenter study," *Diseases of the Colon & Rectum*, vol. 55, no. 1, pp. 42–50, 2012.

[11] S. H. Baik, M. Gincherman, M. G. Mutch, E. H. Birnbaum, and J. W. Fleshman, "Laparoscopic vs open resection for patients with rectal cancer: comparison of perioperative outcomes and long-term survival," *Diseases of the Colon and Rectum*, vol. 54, no. 1, pp. 6–14, 2011.

[12] S. Breukink, J. Pierie, and T. Wiggers, "Laparoscopic versus open total mesorectal excision for rectal cancer," *Cochrane Database of Systematic Reviews*, no. 4, Article ID CD005200, 2006.

[13] J. T. C. Poon and W. L. Law, "Laparoscopic resection for rectal cancer: a review," *Annals of Surgical Oncology*, vol. 16, no. 11, pp. 3038–3047, 2009.

[14] G. Piskun and S. Rajpal, "Transumbilical laparoscopic cholecystectomy utilizes no incisions outside the umbilicus," *Journal of Laparoendoscopic and Advanced Surgical Techniques Part A*, vol. 9, no. 4, pp. 361–364, 1999.

[15] A. N. Kalloo, V. K. Singh, S. B. Jagannath et al., "Flexible transgastric peritoneoscopy: a novel approach to diagnostic and therapeutic interventions in the peritoneal cavity," *Gastrointestinal Endoscopy*, vol. 60, no. 1, pp. 114–117, 2004.

[16] M. Gagner and A. Garcia-Ruiz, "Technical aspects of minimally invasive abdominal surgery performed with needlescopic instruments," *Surgical Laparoscopy, Endoscopy and Percutaneous Techniques*, vol. 8, no. 3, pp. 171–179, 1998.

[17] J. Leroy, R. A. Cahill, S. Perretta, A. Forgione, B. Dallemagne, and J. Marescaux, "Natural orifice translumenal endoscopic surgery (NOTES) applied totally to sigmoidectomy: an original technique with survival in a porcine model," *Surgical Endoscopy and Other Interventional Techniques*, vol. 23, no. 1, pp. 24–30, 2009.

[18] M. H. Whiteford, P. M. Denk, and L. L. Swanström, "Feasibility of radical sigmoid colectomy performed as natural orifice translumenal endoscopic surgery (NOTES) using transanal endoscopic microsurgery," *Surgical Endoscopy and Other Interventional Techniques*, vol. 21, no. 10, pp. 1870–1874, 2007.

[19] A. M. Lacy, S. Delgado, O. A. Rojas, R. Almenara, A. Blasi, and J. Llach, "MA-NOS radical sigmoidectomy: report of a transvaginal resection in the human," *Surgical Endoscopy and Other Interventional Techniques*, vol. 22, no. 7, pp. 1717–1723, 2008.

[20] J. P. Pearl and J. L. Ponsky, "Natural orifice translumenal endoscopic surgery: a critical review," *Journal of Gastrointestinal Surgery*, vol. 12, no. 7, pp. 1293–1300, 2008.

[21] N. T. Nguyen, K. M. Reavis, M. W. Hinojosa, B. R. Smith, and M. J. Stamos, "A single-port technique for laparoscopic extended stapled appendectomy," *Surgical Innovation*, vol. 16, no. 1, pp. 78–81, 2009.

[22] N. T. Nguyen, K. M. Reavis, M. W. Hinojosa, B. R. Smith, and S. E. Wilson, "Laparoscopic transumbilical cholecystectomy without visible abdominal scars," *Journal of Gastrointestinal Surgery*, vol. 13, no. 6, pp. 1125–1128, 2009.

[23] U. Barbaros and A. Dinççağ, "Single incision laparoscopic splenectomy: the first two cases," *Journal of Gastrointestinal Surgery*, vol. 13, no. 8, pp. 1520–1523, 2009.

[24] J. Filipovic-Cugura, I. Kirac, T. Kulis, J. Jankovic, and M. Bekavac-Beslin, "Single-incision laparoscopic surgery (SILS) for totally extraperitoneal (TEP) inguinal hernia repair: first case," *Surgical Endoscopy and Other Interventional Techniques*, vol. 23, no. 4, pp. 920–921, 2009.

[25] T. A. Ponsky, J. Diluciano, W. Chwals, R. Parry, and S. Boulanger, "Early experience with single-port laparoscopic surgery in children," *Journal of Laparoendoscopic and Advanced Surgical Techniques*, vol. 19, no. 4, pp. 551–553, 2009.

[26] A. N. Fader and P. F. Escobar, "Laparoendoscopic single-site surgery (LESS) in gynecologic oncology: technique and initial report," *Gynecologic Oncology*, vol. 114, no. 2, pp. 157–161, 2009.

[27] J. D. Raman, J. A. Cadeddu, P. Rao, and A. Rane, "Single-incision laparoscopic surgery: initial urological experience and comparison with natural-orifice transluminal endoscopic surgery," *British Journal of Urology International*, vol. 101, no. 12, pp. 1493–1496, 2008.

[28] P. Bucher, F. Pugin, and P. Morel, "Single port access laparoscopic right hemicolectomy," *International Journal of Colorectal Disease*, vol. 23, no. 10, pp. 1013–1016, 2008.

[29] P. Bucher, F. Pugin, and P. Morel, "Transumbilical single incision laparoscopic sigmoidectomy for benign disease," *Colorectal Disease*, vol. 12, no. 1, pp. 61–65, 2010.

[30] M. B. Ostrowitz, D. Eschete, H. Zemon, and G. DeNoto, "Robotic-assisted single-incision right colectomy: early experience," *International Journal of Medical Robotics and Computer Assisted Surgery*, vol. 5, no. 4, pp. 465–470, 2009.

[31] F. H. Remzi, H. T. Kirat, J. H. Kaouk, and D. P. Geisler, "Single-port laparoscopy in colorectal surgery," *Colorectal Disease*, vol. 10, no. 8, pp. 823–826, 2008.

[32] A. M. Merchant and E. Lin, "Single-incision laparoscopic right hemicolectomy for a colon mass," *Diseases of the Colon and Rectum*, vol. 52, no. 5, pp. 1021–1024, 2009.

[33] J. Leroy, R. A. Cahill, M. Asakuma, B. Dallemagne, and J. Marescaux, "Single-access laparoscopic sigmoidectomy as definitive surgical management of prior diverticulitis in a human patient," *Archives of Surgery*, vol. 144, no. 2, pp. 173–179, 2009.

[34] N. A. Rieger and F. F. Lam, "Single-incision laparoscopically assisted colectomy using standard laparoscopic instrumentation," *Surgical Endoscopy and Other Interventional Techniques*, vol. 24, no. 4, pp. 888–890, 2010.

[35] P. Bucher, F. Pugin, and P. Morel, "Single-port access laparoscopic radical left colectomy in humans," *Diseases of the Colon and Rectum*, vol. 52, no. 10, pp. 1797–1801, 2009.

[36] D. P. Geisler, E. T. Condon, and F. H. Remzi, "Single incision laparoscopic total proctocolectomy with ileopouch anal anastomosis," *Colorectal Disease*, vol. 12, no. 9, pp. 941–943, 2010.

[37] W. L. Law, J. K. M. Fan, and J. T. C. Poon, "Single incision laparoscopic left colectomy for carcinoma of distal transverse colon," *Colorectal Disease*, vol. 12, no. 7, pp. 698–701, 2010.

[38] F. H. Remzi, H. T. Kirat, and D. P. Geisler, "Laparoscopic single-port colectomy for sigmoid cancer," *Techniques in Coloproctology*, vol. 14, no. 3, pp. 253–255, 2010.

[39] W. L. Law, J. K. M. Fan, and J. T. C. Poon, "Single-incision laparoscopic colectomy: early experience," *Diseases of the Colon and Rectum*, vol. 53, no. 3, pp. 284–288, 2010.

[40] W. M. Chambers, M. Bicsak, M. Lamparelli, and A. R. Dixon, "Single-incision laparoscopic surgery (SILS) in complex colorectal surgery: a technique offering potential and not just cosmesis," *Colorectal Disease*, vol. 13, no. 4, pp. 393–398, 2011.

[41] V. W. Fazio, D. Geisler, and T. Garrett, "Single incision laparoscopic colorectal surgery: a single surgeon experience of 102 consecutive cases," *Techniques in Coloproctology*, vol. 15, no. 4, p. 403, 2011.

[42] C. C. Lu, S. E. Lin, K. C. Chung, and K. M. Rau, "Comparison of clinical outcome of single incision laparoscopic surgery using a simplified access system with conventional laparoscopic surgery for malignant colorectal disease," *Colorectal Disease*, vol. 14, no. 4, pp. e171–e176, 2012.

[43] M. E. McNally, B. Todd Moore, and K. M. Brown, "Single-incision laparoscopic colectomy for malignant disease," *Surgical Endoscopy and Other Interventional Techniques*, vol. 25, no. 11, pp. 3559–3565, 2011.

[44] S. Gaujoux, F. Bretagnol, M. Ferron, and Y. Panis, "Single-incision laparoscopic colonic surgery," *Colorectal Disease*, vol. 13, no. 9, pp. 1066–1071, 2011.

[45] D. Uematsu, G. Akiyama, M. Narita, and A. Magishi, "Single-access laparoscopic low anterior resection with vertical suspension of the rectum," *Diseases of the Colon and Rectum*, vol. 54, no. 5, pp. 632–637, 2011.

[46] L. Boni, G. Dionigi, E. Cassinotti et al., "Single incision laparoscopic right colectomy," *Surgical Endoscopy and Other Interventional Techniques*, vol. 24, no. 12, pp. 3233–3236, 2010.

[47] M. S. Sajid, M. A. Khan, E. Cheek, and M. K. Baig, "Needlescopic versus laparoscopic appendectomy: a systematic review," *Canadian Journal of Surgery*, vol. 52, no. 2, pp. 129–134, 2009.

[48] R. McCloy, D. Randall, S. A. Schug et al., "Is smaller necessarily better? A systematic review comparing the effects of minilaparoscopic and conventional laparoscopic cholecystectomy on patient outcomes," *Surgical Endoscopy and Other Interventional Techniques*, vol. 22, no. 12, pp. 2541–2553, 2008.

[49] M. Gagner, "Needlescopic splenectomy: a safer alternative to single incision laparoscopic splenectomy (SILS)," *Journal of Gastrointestinal Surgery*, vol. 14, no. 9, p. 1473, 2010.

[50] W.-H. She, O. S.-H. Lo, J. K.-M. Fan, J. T.-C. Poon, and W.-L. Law, "Needlescopic totally extraperitoneal hernioplasty for unilateral inguinal hernia in adult patients," *Asian Journal of Surgery*, vol. 34, no. 1, pp. 23–27, 2011.

[51] R. Shalaby, A. Moniem Shams, S. Mohamed, M. El-Leathy, M. Ibrahem, and G. Alsaed, "Two-trocar needlescopic approach to incarcerated inguinal hernia in children," *Journal of Pediatric Surgery*, vol. 42, no. 7, pp. 1259–1262, 2007.

[52] F. Ghezzi, A. Cromi, G. Siesto et al., "Minilaparoscopic versus conventional laparoscopic hysterectomy: results of a randomized trial," *Journal of Minimally Invasive Gynecology*, vol. 18, no. 4, pp. 455–461, 2011.

[53] I. S. Gill, "Needlescopic urology: current status," *Urologic Clinics of North America*, vol. 28, no. 1, pp. 71–83, 2001.

[54] P. M. Chiasson, D. E. Pace, R. A. Mustard, J. Mamazza, E. C. Poulin, and C. M. Schlachta, ""Needlescopic" sigmoid resection," *Surgical endoscopy*, vol. 16, no. 4, p. 715, 2002.

[55] E. Santoro, F. Agresta, S. Veltri, G. Mulieri, N. Bedin, and M. Mulieri, "Minilaparoscopic colorectal resection: a preliminary experience and an outcomes comparison with classical laparoscopic colon procedures," *Surgical Endoscopy and Other Interventional Techniques*, vol. 22, no. 5, pp. 1248–1254, 2008.

[56] S. B. Lim, H. S. Choi, S. Y. Jeong, and J. G. Park, "Feasibility of laparoscopic techniques as the surgical approach of choice for primary colorectal cancer: an analysis of 570 consecutive cases," *Surgical Endoscopy and Other Interventional Techniques*, vol. 22, no. 12, pp. 2588–2595, 2008.

[57] H. Nelson, "Laparoscopically assisted colectomy is as safe and effective as open colectomy in people with colon cancer," *Cancer Treatment Reviews*, vol. 30, no. 8, pp. 707–709, 2004.

[58] H. Nelson, D. J. Sargent, H. S. Wieand et al., "A comparison of laparoscopically assisted and open colectomy for colon cancer," *New England Journal of Medicine*, vol. 350, no. 20, pp. 2050–2114, 2004.

[59] R. Veldkamp, E. Kuhry, W. C. Hop et al., "Laparoscopic surgery versus open surgery for colon cancer: short-term outcomes of a randomised trial," *Lancet Oncology*, vol. 6, no. 7, pp. 477–484, 2005.

[60] H. J. Bonjer, W. C.J. Hop, H. Nelson et al., "Laparoscopically assisted vs open colectomy for colon cancer: a meta-analysis," *Archives of Surgery*, vol. 142, no. 3, pp. 298–303, 2007.

[61] A. Murray, T. Lourenco, R. de Verteuil et al., "Clinical effectiveness and cost-effectiveness of laparoscopic surgery for colorectal cancer: systematic reviews and economic evaluation," *Health Technology Assessment*, vol. 10, no. 45, pp. 1–141, 2006.

[62] J. C. Weeks, H. Nelson, S. Gelber, D. Sargent, and G. Schroeder, "Short-term quality-of-life outcomes following laparoscopic-assisted colectomy vs open colectomy for colon cancer: a randomized trial," *Journal of the American Medical Association*, vol. 287, no. 3, pp. 321–328, 2002.

[63] A. M. Lacy, J. C. García-Valdecasas, S. Delgado et al., "Laparoscopy-assisted colectomy versus open colectomy for treatment of non-metastatic colon cancer: a randomised trial," *Lancet*, vol. 359, no. 9325, pp. 2224–2229, 2002.

[64] C. Laurent, F. Leblanc, F. Bretagnol, M. Capdepont, and E. Rullier, "Long-term wound advantages of the laparoscopic approach in rectal cancer," *British Journal of Surgery*, vol. 95, no. 7, pp. 903–908, 2008.

[65] M. Scarpa, F. Erroi, C. Ruffolo et al., "Minimally invasive surgery for colorectal cancer: quality of life, body image, cosmesis, and functional results," *Surgical Endoscopy and Other Interventional Techniques*, vol. 23, no. 3, pp. 577–582, 2009.

[66] E. J. Eshuis, S. W. Polle, J. F. Slors et al., "Long-term surgical recurrence, morbidity, quality of life, and body image of laparoscopic-assisted vs. open ileocolic resection for Crohn's disease: a comparative study," *Diseases of the Colon and Rectum*, vol. 51, no. 6, pp. 858–867, 2008.

[67] W. R. Spanjersberg, J. Reurings, and C. H. J. M. Van Laarhoven, "Fast track surgery versus conventional recovery strategies for colorectal surgery," *Cochrane Database of Systematic Reviews*, no. 1, Article ID CD007635, 2009.

[68] C. J. Walter, J. T. Watson, R. D. Pullan, N. J. Kenefick, S. J. Mitchell, and D. J. DeFriend, "Enhanced recovery in major colorectal surgery: safety and efficacy in an unselected surgical population at a UK district general hospital," *Surgeon*, vol. 9, no. 5, pp. 259–264, 2011.

[69] M. S. Vlug, J. Wind, M. W. Hollmann et al., "Laparoscopy in combination with fast track multimodal management is the best perioperative strategy in patients undergoing colonic surgery: a randomized clinical trial (LAFA-study)," *Annals of Surgery*, vol. 254, no. 6, pp. 868–875, 2011.

[70] D. Rattner and A. Kalloo, "ASGE/SAGES Working Group on natural orifice translumenal endoscopic surgery: October 2005," *Surgical Endoscopy and Other Interventional Techniques*, vol. 20, no. 2, pp. 329–333, 2006.

[71] "ASGE; SAGES. ASGE/SAGES Working Group on natural orifice translumenal endoscopic surgery white paper October 2005," *Gastrointestinal Endoscopy*, vol. 63, no. 2, pp. 199–203, 2006.

[72] G. G. Ginsber, M. L. Kochman, I. D. Norton, and C. J. Gostout, "Clinical gastrointestinal endoscopy," in *Surgical Perspectives on Natural Orifice Translumenal Endoscopic Surgery (NOTES)*, Section 4, Chapter 55, Saunders, 2011.

[73] N. Tagaya and K. Kubota, "Reevaluation of needlescopic surgery," *Surgical Endoscopy*, vol. 26, no. 1, pp. 137–143, 2011.

[74] R. H. Yuan, W. J. Lee, and S. C. Yu, "Mini-laparoscopic cholecystectomy: a cosmetically better, almost scarless procedure," *Journal of Laparoendoscopic and Advanced Surgical Techniques Part A*, vol. 7, no. 4, pp. 205–211, 1997.

[75] Y. Watanabe, M. Sato, S. Ueda et al., "Microlaparoscopic cholecystectomy—the first 20 cases: is it an alternative to conventional LC?" *European Journal of Surgery*, vol. 164, no. 8, pp. 623–625, 1998.

[76] P. R. Reardon, J. I. Kamelgard, B. A. Applebaum, and F. C. Brunicardi, "Mini-laparoscopic cholecystectomy: validating a new approach," *Journal of Laparoendoscopic and Advanced Surgical Techniques - Part A*, vol. 9, no. 3, pp. 227–233, 1999.

[77] N. Tagaya, A. Abe, and K. Kubota, "Needlescopic surgery for liver, gallbladder and spleen diseases," *Journal of Hepato-Biliary-Pancreatic Sciences*, vol. 18, no. 4, pp. 516–524, 2011.

[78] C. K. Yeung, "Needlescopic operation: surgery of the future?" *Hong Kong Medical Journal*, vol. 9, no. 4, pp. 236–237, 2003.

[79] P. Rajan and B. Turna, "New trends in minimally invasive urological surgery," *Brazilian Journal of Urology*, vol. 35, no. 5, pp. 514–520, 2009.

Hindawi Publishing Corporation
Minimally Invasive Surgery
Volume 2012, Article ID 317249, 7 pages
doi:10.1155/2012/317249

Research Article

Patient Perceptions of Natural Orifice Translumenal Surgery

Melanie E. Tsang,[1,2] Kirstin Theman,[2] Dale Mercer,[1,2] Wilma M. Hopman,[3,4] and Lawrence Hookey[1,5]

[1] *Gastrointestinal Diseases Research Unit, Queen's University, Kingston, ON, Canada K7L 2V7*
[2] *Department of General Surgery, Queen's University, Kingston, ON, Canada K7L 2V7*
[3] *Clinical Research Centre, Kingston General Hospital, Kingston, ON, Canada K7L 2V7*
[4] *Department of Community Health and Epidemiology, Queen's University, Kingston, ON, Canada K7L 2V7*
[5] *Division of Gastroenterology, Hotel Dieu Hospital, Queen's University, Sydenham 4, Kingston, ON, Canada K7L 5G2*

Correspondence should be addressed to Lawrence Hookey, hookeyl@hdh.kari.net

Received 28 November 2011; Accepted 18 December 2011

Academic Editor: Luigi Boni

Natural orifice translumenal endoscopic surgery (NOTES) is on the forefront of surgical technique, but existing research has produced mixed results regarding factors associated with interest in the procedure. Our objective was to ascertain patient opinions at a Canadian centre regarding scarless surgery. A survey comprising demographic data (gender, age, body mass index [BMI]), interest in NOTES, impact of increased risk, as well as importance of further research and shorter recovery time was administered to volunteer patients at outpatient general surgery clinics. Nonparametric tests were utilized to examine difference in response by age, sex, BMI, and preexisting scars. Of the 335 participants (57% female, mean age of 54.5 ± 15.9 years, mean BMI of 28.7 ± 6.9), the majority (83%) showed some interest, but this dropped to 38% when additional risk was factored in. Generally, women, those under 50 years of age and those of healthy weight, were more interested than male, older, and/or heavier patients. Most felt that research into NOTES and reduced length of inpatient stay were important (80% and 95%, respectively). Further investigation into objective NOTES outcomes are needed to provide patients adequate data to make an informed choice regarding surgical route.

1. Introduction

Natural orifice translumenal endoscopic surgery (NOTES) is on the forefront of surgical technique and is pushing the perceptions and boundaries of abdominal surgery, as laparoscopy did when first introduced. Research continues to progress in this field in both animal and human trials. However, in spite of enthusiasm on behalf of researchers for the technical aspects of NOTES, what will truly lead to its wider implementation will be improved patient outcomes and acceptance. While better patient outcomes (less postoperative pain, fewer—if any—scars, and decreased length of hospital stay) are touted to be the main goal of this technique, it will be some time before hard data are available to assess these. However, patient acceptance of the procedure and its risks can be assessed through surveys in advance of outcomes data.

Though multiple studies have addressed attitudes towards this developing technique, the ability to interpret these variable study results is challenging. Firstly, there is heterogeneity in the questions asked and survey techniques. Secondly, the larger scale studies have come mainly from Europe, thus making direct inferences to a North American population potentially incorrect. Finally, these surveys have emphasized gender and age as variables in assessing interest in NOTES but have not assessed whether previous surgery affects patients perceptions of scars and postsurgical pain. Obesity, surprisingly, has also not been examined previously. It is known that obese patients are at higher risk for developing postoperative hernias and wound infections [1–4] and thus may be a group that could derive significant benefit from NOTES. In this paper, we surveyed a large number of patients at a Canadian centre to assess opinions regarding scarless surgical procedures and whether increased risks would affect their choices. A large sample also allowed for subgroup analyses based on gender, age, and body mass index.

2. Methods

The survey instrument was developed by a team of general surgeons, gastroenterologists, and a statistician. Approval for the study was obtained from the Queen's University Health Sciences & Affiliated Teaching Hospitals Research Ethics Board. A pilot study was performed with 10 people and feedback incorporated into the survey tool. The final survey was comprised of demographic data (age, gender, self-reported height and weight), as well as questions regarding previous surgery and presence and location of scars. Patients were then asked about the importance of scars, bother from scars, interest in scarless surgery, interest in scarless surgery if there were increased complications, acceptable complication rate (from 0% to ≥20%), importance of research into the field, and importance of shorter recovery from surgery. These were all graded on a five-point scale (see the appendix).

All patients attending general surgery outpatient clinics (excluding breast clinics) at Hotel Dieu Hospital—an ambulatory based hospital providing secondary and tertiary care to residents of Kingston, Ontario, and the surrounding area—were invited to fill out a short questionnaire regarding NOTES over a 6-month period in 2008-2009. Surveys were distributed and collected by study hospital staff and deposited in a collection box, which was emptied on a weekly basis to avoid any chance of patient identification. The actual response rate could not be calculated, as the surveys were anonymous and clinic staff did not track the number of patients who were uninterested in responding. However, anecdotal evidence suggests that the patients were generally happy to complete the short survey while they waited. In the event that several appointments were scheduled, patients were asked to complete the survey only once.

2.1. Statistics. Data were entered into an Excel spreadsheet designed for the study and entered into SPSS (version 17.0 for Windows, 2009, Chicago, IL) for statistical analysis. Body mass index (BMI) was calculated according to the standard formula of weight (kg) divided by height (metres) squared. BMI was then classified using the standard cutpoints of 18.5–24.9 (healthy weight), 25–29.9 (overweight), 30–34.9 (Obese I), 35–39.9 (Obese II), and ≥35 (Obese III) [5]. Two who were just below the 18.5 threshold were included with the healthy weight group. The three obese groups were also combined for a 3-level analysis. Age was similarly classified as ≤29, 30–49, and ≥50 years.

Data were initially assessed descriptively (mean, standard deviation and range for continuous and ordinal data, frequency and percent for categorical data) and graphed to assess the underlying distribution. Responses to the 5-level Likert scales (1 = no importance, bother, or interest and 5 = extremely important, bothered, or interested) were quantified so that means and standard deviations could be generated. Although the data are ordinal in nature and the use of inferential statistics is not optimal in this situation, they were used for several reasons. First, this was considered preferable to a large volume of chi-square tests. A comparison of medians was also considered but while groups often had similar median values, subtle differences emerged when means were used. Finally, the sample size for the majority of the comparisons was sufficiently substantial to allow the use of inferential statistics in this situation [6]. However, the more conservative nonparametric tests were used to assess all associations.

Table 1: Patient demographics.

Characteristic	Mean (standard deviation) [range]
Age	54.5 (15.9) [17–88]
Height (cm)	168.5 (10.4) [127–198]
Weight (kg)	82.1 (22.8) [38.1–199.6]
BMI	28.7 (6.9) [17.9–64.3]
	Frequency (Percent)
Male	144 (43.0)
Existing abdominal scar	209 (62.4)
Other major nonabdominal scar	158 (47.2)

The associations of age and body mass index with the seven questions were assessed by means of the nonparametric Spearman's correlation. The association of gender and presence of a previous surgical scar (abdominal or nonabdominal) with the seven questions was assessed by means of the Mann-Whitney U test, while the association for the three levels of age and BMI were assessed by means of the Kruskal-Wallis test. In order to provide an adequate sample to allow for subgroup analysis, enrolment was aimed at approximately 300 patients. For all analyses, the significance level was set at $P < 0.05$ (two-sided), although results that fell short of statistical significance were noted if they were deemed to be of clinical interest.

3. Results

Three hundred thirty-five patients completed the survey. Demographic and physical characteristics are summarized in Table 1. Nine percent were ≤29 years of age, 26% were 30–49 years, and 64% were ≥50 years; for BMI, 29.9% were at a healthy weight, 34.9% were overweight, and 29.6% were obese (6% were missing height and/or weight). As this was a voluntary, anonymous survey, there were very few missing data (see Table 2). For the few items that were missing, analyses were completed on the subset without missing data, as the type of detailed information typically required for imputation was not collected.

3.1. Attitudes towards Scars. Younger respondents (<50 years of age), females, and those of a healthy weight indicated that cosmetic issues such as scars were more important, as compared to older, male, and heavier respondents ($P \leq 0.001$ for all three comparisons) (Table 3). Amongst all surveyed, 87% of respondents had some type of scar. Of these, 58% indicated that it did not bother them at all, but 9.9% indicated that they were bothered quite a bit or extremely by their scar(s). Women placed significantly greater importance on abdominal scars than men and

Table 2: Missing data ($n = 335$).

Variable	Missing N (%)
Age	1 (0.3)
Gender	1 (0.3)
BMI	20 (6.0)
Previous abdominal scar	3 (0.9)
Major non-abdominal scars	11 (3.3)
Importance of scars	2 (0.6)
Impact of current scars	1 (0.3)
Interest in no scar surgery	2 (0.6)
Interest if increased complications	8 (2.4)
Reasonable risk	18 (5.4)
Importance of research	12 (3.6)
Importance of shorter stay	9 (2.7)

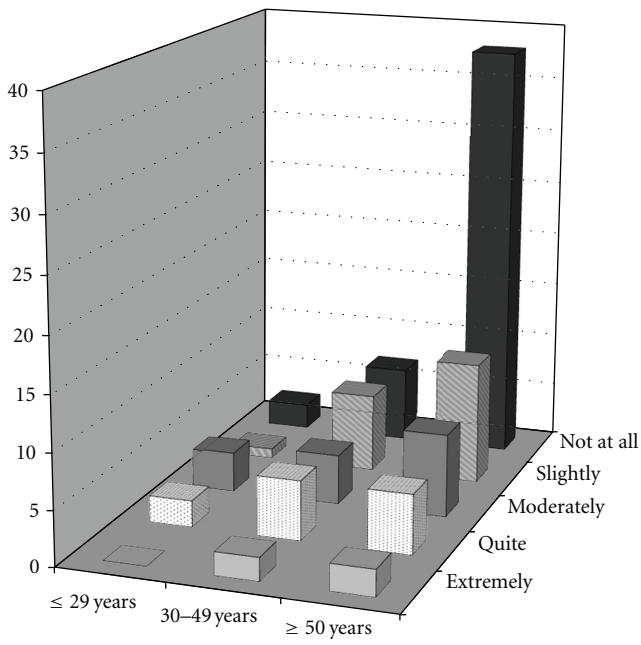

Figure 1: Importance of scars by age category. Percentages are within total sample.

were more greatly impacted by them; fifty-six percent of women were bothered by some degree by their current scars as compared with 23% of men ($P < 0.001$). Age (as a continuous variable) was negatively correlated with the importance and impact of abdominal scars; in other words, as age increased, the importance and impact of abdominal scars decreased ($P < 0.001$, see Figure 1 for importance). Similarly, as BMI increased, the importance of abdominal scars significantly decreased ($P < 0.001$, Figure 2.)

3.2. Interest in Scarless Surgery and Acceptance of Complication Rates. The majority (83%) had at least some interest in a surgery that would leave no scars. The two younger groups were more interested than those over 50 years ($P = 0.001$),

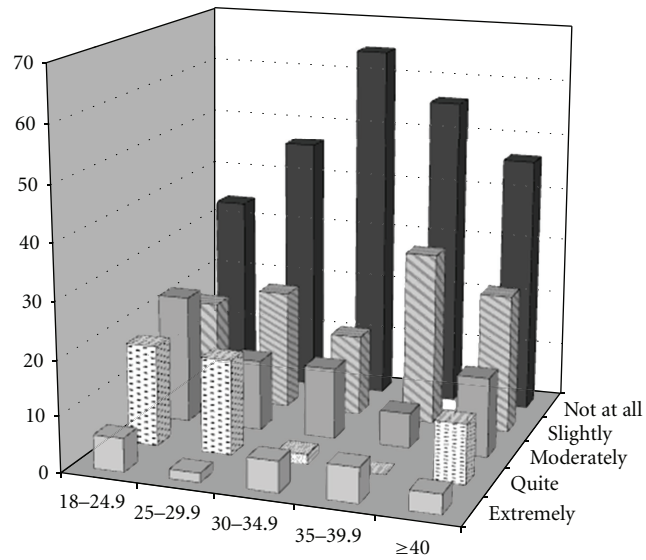

Figure 2: Importance of scars by body mass index category. Percentages are within weight category.

with those between 30 and 49 years remaining the most interested in the face of increased risk ($P = 0.036$). The two younger groups were comfortable with a risk up to 10%, while the older group was more conservative and was more comfortable with a risk close to 5% ($P = 0.003$). There were also gender differences in the level of interest, with women expressing more interest than men ($P = 0.021$). This difference disappeared when the question of risk was added ($P = 0.192$), although the women tended to accept an increased risk of close to 10%, while the men were closer to 5% ($P = 0.059$).

Level of interest in NOTES was not significantly related to BMI, nor was acceptance of increased rate of complication, or the amount of acceptable risk. However, for all three questions, those at a healthy weight had the highest scores, suggesting more interest and less concern about risk. Those without previous abdominal scars were more interested in NOTES than those with scars ($P = 0.049$), but both groups lost interest when presented with increased risk. The presence of other scars had little association with the responses to the three questions.

3.3. Research into NOTES. Over 80% of respondents felt that research into scarless surgery was of some importance, with 30.4% rating it as quite or extremely important. With age as a continuous variable, the Spearman correlation suggested a negative but significant association (rho $= -.205$, $P < 0.001$); using the categorical variable, those in the age group of 30–49 years rated research as more important than the younger or older groups ($P = 0.040$). BMI was also negatively and significantly associated with importance when using the continuous variable (rho $= -.149$, $P = 0.009$), but fell just short of significance when using the categorical variable ($P = 0.066$), although it was the healthy weight group that was more likely to rate it as important. Women

Table 3: Associations between patient characteristics and opinions. Please see the appendix for detailed responses. Scales are scored from 1–5, with 1 representing no importance, bother, interest, or no increased acceptable risk; 5 = extremely important, bothered, interested, and a 20% increased risk. Values represent means and standard deviations, but *P* values are based on the Mann-Whitney U or the Kruskal-Wallis as appropriate.

Characteristic	Importance	Feel about current scars*	Interest in surgery with no scars	Even if increased risk of infection	How much additional risk	Importance of research	Importance of shorter recovery time
Age in years							
≤29	2.7 (1.1)	1.9 (1.1)	3.3 (1.4)	1.6 (0.9)	1.9 (0.9)	2.9 (1.3)	3.9 (1.1)
30–49	2.6 (1.3)	2.1 (1.2)	3.3 (1.2)	1.9 (1.1)	2.0 (1.1)	3.1 (1.2)	3.9 (1.1)
50+	1.8 (1.2)	1.6 (1.0)	2.8 (1.3)	1.6 (1.0)	1.6 (1.0)	2.7 (1.3)	3.7 (1.2)
P value	<0.001	<0.001	0.001	0.036	0.003	0.040	0.537
Sex							
Female	2.4 (1.3)	2.1 (1.2)	3.1 (1.3)	1.8 (1.1)	1.9 (1.1)	2.9 (1.3)	3.8 (1.1)
Male	1.7 (1.1)	1.4 (0.8)	2.8 (1.3)	1.6 (0.9)	1.6 (0.8)	2.7 (1.2)	3.7 (1.2)
P value	<0.001	<0.001	0.021	0.192	0.059	0.084	0.363
BMI Category							
Healthy	2.4 (1.3)	1.8 (1.0)	3.1 (1.3)	1.8 (1.1)	2.0 (1.2)	3.0 (1.2)	3.8 (1.1)
Overweight	2.1 (1.2)	1.9 (1.2)	2.9 (1.3)	1.6 (0.9)	1.7 (0.9)	2.8 (1.3)	3.7 (1.0)
Obese	1.8 (1.1)	1.6 (1.0)	2.9 (1.2)	1.6 (1.0)	1.6 (0.9)	2.6 (1.3)	3.7 (1.3)
P value	0.001	0.123	0.297	0.272	0.253	0.066	0.786
Abdominal Scar							
No	2.3 (1.3)	—	3.1 (1.3)	1.7 (0.9)	1.8 (0.9)	3.0 (1.2)	3.9 (1.1)
Yes	2.0 (1.2)	1.8 (1.1)	2.8 (1.3)	1.7 (1.1)	1.7 (1.1)	2.8 (1.3)	3.7 (1.1)
P value	0.071	—	0.049	0.431	0.203	0.222	0.104
Other Scar							
No	2.0 (1.2)	—	2.9 (1.3)	1.7 (1.0)	1.7 (0.9)	2.8 (1.3)	3.8 (1.1)
Yes	2.1 (1.3)	1.9 (1.2)	3.0 (1.3)	1.7 (1.1)	1.8 (1.1)	2.9 (1.3)	3.8 (1.2)
P value	0.527	—	0.416	0.964	0.939	0.275	0.740

*Responses are based on the subset with scars.

rated it as more important than men, although it fell short of significance ($P = 0.084$). Presence of abdominal or other scars had little association with the ratings of importance.

3.4. Shorter Hospital Stay. One of the key proposed benefits of NOTES is a decreased length of stay in the hospital. Very few (only 5.1%) indicated that a shorter hospital stay was not important, with 64.8% indicating that it was quite or extremely important. There was a weak, negative association with age using the Spearman correlation (rho $= -.109$, $P = 0.049$), but this was no longer significant when using the categorical data ($P = 0.537$). Sex, BMI, and presence of scars also had little association with the importance of shorter in-hospital recovery time.

4. Discussion

Here, we captured the opinions of 335 North American patients to obtain their views on this developing technique. Several patient surveys have attempted to characterize those who would be most interested in this new method. Studies published to date have variable results, perhaps related to the population surveyed and questions asked. Some surveys have shown that patients prefer NOTES to laparoscopic surgery due to its improved cosmetic result with the potential for decreased pain also holding appeal in some studies [7–10]. However, patients consistently had decreased interest as the potential rate of complication increased [7, 9]. Single port surgery (SPS) is a minimally invasive form of laparoscopic surgery and a large-scale British study ($n = 750$) comparing patient views on it and NOTES showed that SPS was significantly preferred over open surgery and NOTES [11]. Although experts often point to women as being a target group who would be interested in NOTES [12], studies looking at the effect of gender on opinions of NOTES have led to conflicting results. Varadarajulu et al. did not find a significant preference by women for NOTES compared to men [9]. Further to this, surveys targeted at women in the context of transvaginal NOTES have had variable results. Sixty-eight percent of women were interested in NOTES in a study by Peterson et al. [8]. However, in an Australian study, three quarters of surveyed women were neutral or unhappy about transvaginal NOTES compared with standard laparoscopic surgery [13].

In keeping with the results of previous surveys, women were significantly more concerned with the cosmetic results

of surgery and were more bothered by current scars. NOTES, being a "scarless" method, would allay this concern. In addition, female patients are anatomically more versatile candidates for NOTES, with the potential for a transvaginal approach. Our study did support the theory that women would be more interested in NOTES than men, but this association was lost when additional risk was factored into the equation. Those under 50 years of age rated a scarless method as being more important and expressed more interest, even in the face of increased risk.

Although there was a high interest in the concept of NOTES (83% showed at least slight interest), this dropped to 38% when an increased complication risk was proposed compared to traditional techniques. However, this remains a significant proportion of the surveyed population, and provides impetus to further research and development in this field to make it a safe alternative to laparoscopic and open surgery. This is borne out in our data where 81% of patients felt that research into NOTES held some level of importance.

One of the groups in the position to benefit the most from NOTES is obese patients, though our data show that level of interest in the technique is significantly and *negatively* associated with BMI, such that those of healthy weight expressed greater interest. Obese patients are especially at risk for hernias after transabdominal surgery [4–6] and NOTES could mitigate this risk. The lack of abdominal wall incisions could also lead to earlier postoperative mobilization, better lung ventilation, decreased wound infections, all of which would lead to decreased length of hospital stay [12]. Furthermore, NOTES-assisted bariatric surgery has now been successfully attempted [14] and in the authors' opinion is one of the prime areas for NOTES development. Hence, further objective data and education will be necessary to garner the interest and support of this population in this new technique.

Though the capital investment required for the development and adoption of any new technique is significant, the potential for cost savings in projected shorter hospital stays could offset the cost. Ninety-five percent of patients indicated that a shorter in-hospital stay was important to them, adding to the attractiveness of this aspect of NOTES. The reasons behind patient interest in shorter length of hospital stay were not explored further but could include less time away from home and increased awareness of hospital acquired infections. Third party payers (insurance companies and governments) would certainly also be interested in a technique that reduces hospital stay. In addition, it has been proposed that once further developed NOTES would not require a traditional operating room, thus altering hospital utilization further [15].

The current study has some limitations. By dint of the survey population being from surgical clinics, a large proportion already had scars, which may have skewed the results. While the self-administered survey prevented any bias that might have stemmed from a personal interview, patients were unable to ask for any more detail regarding the technique and complications than was included in the survey. For example, when presented with potential complications such as dyspareunia and infertility, women may in fact be less interested in the transvaginal approach of NOTES. Qualitative data collection may provide more insight into the subtleties of patient concerns. This could also be extended to multiple centres to capture regional differences in opinion as the present study was performed in a single centre.

Our results show that there is significant Canadian patient interest in NOTES. The technique is still in its early stage of acceptance, but our data lend support to this endeavour. Clearly, once techniques are further refined, hard data including complication rates, length of stay, and post-operative pain will be necessary to assess its utility and give patients adequate information for an informed choice.

Appendix

Survey Instrument

Survey of Opinions Regarding a New Surgical Technique.

Age: . . . . . years

Sex:

Male ( )
Female ( )

Height: . . . (in feet and inches) or . . .(in centimetres)

Weight: . . . . . (in pounds) or . . . . . (in kilograms)

Do you have an abdominal scar from a previous surgery?

Yes ( )
No ( )

Do you have any other major scars?

Yes ( )
No ( )

If yes, where? . . . . . .

For the following questions, please place a check mark in the box that corresponds best with what you think

(1) How important are cosmetic issues, like scars, to you in abdominal surgery?

Not at all important ( )
Slightly important ( )
Moderately important ( )
Quite important ( )
Extremely important ( )

(2) How do you feel about the scars you have?

Not applicable, no scars ( )
Do not bother me at all ( )
Bother me slightly ( )
Bother me moderately ( )

Bother me quite a bit ( )
Extremely bothered ( )

(3) Would you be interested in a surgery that would leave no scars?

Not interested ( )
Slightly interested ( )
Moderately interested ( )
Quite interested ( )
Extremely interested ( )

(4) Would you be interested in a surgery that would leave no scars even if there was an increased risk of complications such as infection inside your abdomen?

Not interested ( )
Slightly interested ( )
Moderately interested ( )
Quite interested ( )
Extremely interested ( )

(5) How much increased risk would you be comfortable with if the surgery would leave no scar? For example, if you pick 5%, you are indicating that you'd be comfortable with a 5 in 100 chance of having a complication such as infection just to have a scarless surgery.

None, would not have scarless surgery ( )
5% ( )
10% ( )
15% ( )
20% or more ( )

(6) How would you rate the importance of further research and investment into scarless surgery?

Not important at all ( )
Slightly important ( )
Moderately important ( )
Quite important ( )
Extremely important ( )

(7) How important is a shorter recovery time (time spent in hospital recuperating from surgery) to you?

Not important at all ( )
Slightly important ( )
Moderately important ( )
Quite important ( )
Extremely important ( )

Acknowledgment

Funding for this study was provided by the Clinical Teachers' Association of Queen's University. The authors do not have any conflict of interests to declare.

References

[1] C. H. Yap, A. Zimmet, M. Mohajeri, and M. Yii, "Effect of obesity on early morbidity and mortality following cardiac surgery," *Heart Lung and Circulation*, vol. 16, no. 1, pp. 31–36, 2007.

[2] A. O. Sadr, R. Bellocco, K. Eriksson, and J. Adami, "The impact of tobacco use and body mass index on the length of stay in hospital and the risk of post-operative complications among patients undergoing total hip replacement," *Journal of Bone and Joint Surgery. Series B*, vol. 88, no. 10, pp. 1316–1320, 2006.

[3] R. J. De, G. Delvaux, P. Haentjens, and Y. van Nieuwenhove, "Waist circumference is an independent risk factor for the development of parastomal hernia after permanent colostomy," *Diseases of the Colon and Rectum*, vol. 51, no. 12, pp. 1806–1809, 2008.

[4] H. J. Sugerman, J. M. Kellum Jr., H. D. Reines, E. J. DeMaria, H. H. Newsome, and J. W. Lowry, "Greater risk of incisional hernia with morbidly obese than steroid-dependent patients and low recurrence with prefascial polypropylene mesh," *American Journal of Surgery*, vol. 171, no. 1, pp. 80–84, 1996.

[5] T. E. Bucknall, P. J. Cox, and H. Ellis, "Burst abdomen and incisional hernia: a prospective study of 1129 major laparotomies," *British Medical Journal*, vol. 284, no. 6320, pp. 931–933, 1982.

[6] V. J. Hesselink, R. W. Luijendijk, J. H. W. De Wilt, R. Heide, and J. Jeekel, "An evaluation of risk factors in incisional hernia recurrence," *Surgery Gynecology and Obstetrics*, vol. 176, no. 3, pp. 228–234, 1993.

[7] M. E. Hagen, O. J. Wagner, D. Christen, and P. Morel, "Cosmetic issues of abdominal surgery: results of an enquiry into possible grounds for a natural orifice transluminal endoscopic surgery (NOTES) approach," *Endoscopy*, vol. 40, no. 7, pp. 581–583, 2008.

[8] C. Y. Peterson, S. Ramamoorthy, B. Andrews, S. Horgan, M. Talamini, and A. Chock, "Women's positive perception of transvaginal NOTES surgery," *Surgical Endoscopy*, vol. 23, no. 8, pp. 1770–1774, 2009.

[9] S. Varadarajulu, A. Tamhane, and E. R. Drelichman, "Patient perception of natural orifice transluminal endoscopic surgery as a technique for cholecystectomy," *Gastrointestinal Endoscopy*, vol. 67, no. 6, pp. 854–860, 2008.

[10] D. Gero, P. Lukovich, B. Hulesch, T. Palhazy, B. Kecskedi, and P. Kupcsulik, "Inpatients and specialists' opinions about natural orifice translumenal endoscopic surgery," *Surgical Technology International*, vol. 19, pp. 79–84, 2010.

[11] A. Rao, J. Kynaston, E. R. MacDonald, and I. Ahmed, "Patient preferences for surgical techniques: should we invest in new approaches?" *Surgical Endoscopy*, vol. 24, no. 12, pp. 3016–3025, 2010.

[12] P. Swain, "A justification for NOTES—natural orifice translumenal endosurgery," *Gastrointestinal Endoscopy*, vol. 65, no. 3, pp. 514–516, 2007.

[13] A. D. Strickland, M. G. A. Norwood, F. Behnia-Willison, S. A. Olakkengil, and P. J. Hewett, "Transvaginal natural orifice translumenal endoscopic surgery (NOTES): a survey of women's views on a new technique," *Surgical Endoscopy*, vol. 24, no. 10, pp. 2424–2431, 2010.

[14] A. C. Ramos, N. Zundel, M. G. Neto, and M. Maalouf, "Human hybrid NOTES transvaginal sleeve gastrectomy: initial experience," *Surgery for Obesity and Related Diseases*, vol. 4, no. 5, pp. 660–663, 2008.

[15] M. F. McGee, M. J. Rosen, J. Marks et al., "A primer on natural orifice transluminal endoscopic surgery: building a new paradigm," *Surgical Innovation*, vol. 13, no. 2, pp. 86–93, 2006.

Hindawi Publishing Corporation
Minimally Invasive Surgery
Volume 2012, Article ID 697142, 7 pages
doi:10.1155/2012/697142

Clinical Study

Single-Access Laparoscopic Surgery for Ileal Disease

Mohamed Moftah, John Burke, Aaditya Narendra, and Ronan A. Cahill

Department of Colorectal Surgery, Beaumont Hospital, Beaumont Road, Dublin 9, Ireland

Correspondence should be addressed to Ronan A. Cahill, cahillra@gmail.com

Received 10 December 2011; Accepted 12 December 2011

Academic Editor: Luigi Boni

Aim. Single-access laparoscopic surgery (SALS) can be effective for benign and malignant diseases of the ileum in both the elective and urgent setting. *Methods*. Ten consecutive, nonselected patients with ileal disease requiring surgery over a twelve month period were included. All had a preoperative abdominopelvic computerized tomogram. Peritoneal access was achieved via a single transumbilical incision and a "surgical glove port" utilized as our preferred access device. With the pneumoperitoneum established, the relevant ileal loop was located using standard rigid instruments. For ileal resection, anastomosis, or enterotomy, the site of pathology was delivered and addressed extracorporeally. *Result*. The median (range) age of the patients was 42.5 (22–78) years, and the median body mass index was 22 (20.2–28) kg/m^2. Procedures included tru-cut biopsy of an ileal mesenteric mass, loop ileostomy and ileotomy for impacted gallstone extraction as well as ileal ($n = 3$) and ileocaecal resection ($n = 4$). Mean (range) incision length was 2.5 (2–5) cm. All convalescences were uncomplicated. *Conclusions*. These preliminary results show that SALS is an efficient and safe modality for the surgical management of ileal disease with all the advantages of minimal access surgery and without requiring a significant increase in theatre resource or cost or incurring extra patient morbidity.

1. Introduction

There has been a recent shift in the paradigm of operative access toward minimally invasive approaches for the majority of surgical specialities. This has occurred due to the proven benefits of faster recovery times, reduced hospital stay, less wound-related complications, and better cosmesis. The recent development of single access laparoscopic surgery (SALS) represents a natural evolution in progressive practices in order to further improve patient outcomes by minimising operative wounding and reducing access-related complications and the number of ports used.

Many elective general and specialized operations for both benign and malignant diseases have now been performed using SALS techniques. The evidence from the literature to date shows it is a safe and efficient approach that, in the case of malignancy, provides adequate oncologic resection [1–3]. SALS has also been advocated as an important step in promoting safe live donor organ harvest [2, 4].

Nonetheless, compared to standard laparoscopic surgery, this approach necessitates crowding of instruments within one single incision which results in loss of triangulation. This makes the procedure challenging even for the experienced laparoscopic surgeon especially early in a department's learning curve. Moreover, the longer distance from insertion to operative site and lack of manoeuvrability present additional challenges. These challenges have discouraged many surgeons from adopting this technique [5]. This prejudice has been reinforced by the expense of current commercial devices.

To date, there has only been limited experience published regarding the usefulness of SALS for diseases of the small bowel particularly in the emergency setting. The fact that the small bowel is predominantly a mobile organ (or in the case of the terminal ileum, one that can be mobilized easily), however, makes it ideal for this approach as the focus of the operation can be controlled in its position relative to the operating instruments. This is especially the case where enterotomy or resection is required as the operating surgeon can readily exteriorize the affected segment through the single incision and perform the intended bowel procedure as in open surgery. Operative planning is also greatly helped by computerised tomography (CT) to localise and, usually,

define the disease process and any locoregional effects. SALS for ileal disease therefore should allow avoidance of many of the above disadvantages.

In this cohort of consecutive, nonselected patients presenting electively and emergently for surgery over a twelve-month period, a SALS approach was used to locate and surgically manage the presenting small bowel pathology. To obviate expense (and the associated pressures of case selection) and to ensure maximum recruitment for procedural familiarity, we elected to use the "surgical glove port," as our access device [6]. This experience is detailed herein and the advantages and considerations of this approach in this setting are discussed.

2. Materials and Methods

All patients presenting with ileal disease requiring surgery between October 2010 and October 2011 were considered for the SALS approach. Operations for both benign or malignant pathology of the ileum were included whether elective or urgent, and there were no exclusion criteria regarding previous surgery, body habitus, or comorbidity (once the patient was fit for laparoscopy). All patients had a CT scan of the abdomen and pelvis as the most pertinent diagnostic modality prior to surgery. Informed written consent was obtained from all patients following discussion of the potential risks and benefits of the SALS approach, and all were assured of early conversion to either a multiport or open approach in the event of this being prudent. Patient and pathology characteristics, in-hospital and 30-day postdischarge complications, length of stay, readmissions, and followup were recorded and reviewed retrospectively. Patients were contacted by telephone interview to determine the most recent outcome.

2.1. Preoperative Procedure. Standard perioperative management measures (including thromboembolic prophylaxis) were employed in all cases. No bowel preparation was given before surgery. Patients presenting with bowel obstruction had a nasogastric tube inserted at the time of admission.

2.2. Operative Procedure. After the induction of general anaesthesia, prophylactic antibiotic (1.2 g co-amoxiclav in the absence of allergies) was given and the patient placed onto a bean-bag in a Trendelenburg position with both arms tucked to the side. Epidural anaesthesia was not used. After standard skin preparation (povidone-iodine) and draping, a vertical 2-3 cm skin and fascial incision centred on the patient's umbilicus was used to access the abdominal cavity. The incision was later extended if necessary to deliver the bowel and perform the resection and anastomosis. The abdominal cavity was entered carefully under direct vision. A "surgical glove port" was then constructed at the table as previously described [6]. In brief, the internal ring of a wound protector-retractor (Alexis O, Applied Medical, Rancho Santo Margarita, CA, USA) was inserted. The external ring was placed in traction and folded over itself until 2-3 cm from the abdominal surface. The surgical glove port itself was then made with one 10 mm and two 5 mm laparoscopic trocar sleeves inserted and secured in each glove finger. The glove was then stretched onto and around the outer ring which was then itself folded over again until it was in contact with the abdomen (Figure 1). The abdomen was insufflated with CO2 to a pressure of 12 mmHg. A 10 mm straight laparoscope with a 30° optic was used to visualize the abdominal cavity and standard rigid laparoscopic instrumentation used thereafter. Both surgeon and assistant stood to the patient's left side, with the camera stack to the right side. The operating table was then placed in a mild head up and right side-up position.

Careful inspection of abdominal cavity sometimes revealed an obvious pathology in the small bowel without further exploration (Figure 2(a)). If no pathology was seen, a thorough examination was commenced at the ileocaecal junction using two nontraumatic graspers until the pathology was located. Adhesions were divided when encountered especially in cases where they would interfere with small bowel examination or extraction. When the pathological loop of small bowel was identified, its mobility was assessed. Mobilization of right colon was only performed in cases of limited right hemicolectomy and distal ileal pathology to enable exteriorization of bowel. For exteriorisation, the bowel immediately adjacent to pathology was grasped with nontraumatic graspers. The abdomen was then deflated, the glove port disassembled, and the diseased bowel segment brought out directly through the wound protector (Figure 2(b)). Mesenteric division with Ligasure (Covidien, Dublin, Ireland) and bowel resection and functional side to side anastomosis with a straight gastrointestinal anastomosis stapler (Covidien) were performed in the usual fashion. After securing haemostasis, the bowel was reintroduced into the abdominal cavity and a second laparoscopic inspection performed after remounting the Glove port. The wound protector was then removed and fascial closure performed with interrupted monofilament suture. Skin closure was achieved with subcuticular absorbable suture. Local analgesia was then infiltrated around the wound and most often a specific infusional catheter (Painbuster, B-Braun) placed in the wound to allow continual infiltration with bupivacaine for the first 30 hours postoperatively (Figure 3).

3. Results

Over a ten month period, a total of ten patients (9 female and 1 male) underwent SALS for ileal disease on either an elective or urgent basis. This represents all such patients having laparoscopic surgery for this pathology over the study interval. Nine patients presented acutely with abdominal pain and/or symptoms of bowel obstruction while one presented to the clinic with iron defiency anaemia. Four patients were known already to have Crohn's disease and so were on immunosuppressive therapy. The median age of the patients was 42.5 years (range 22–78) and the median BMI was 22 kg/m^2 (range 20.2–28). The median length of hospital stay was 4.5 days (range 2–7 days). Seven had ileal resection while two had enterotomies fashioned (one for an ileostomy and the other an ileostomy for extraction of gallstone causing

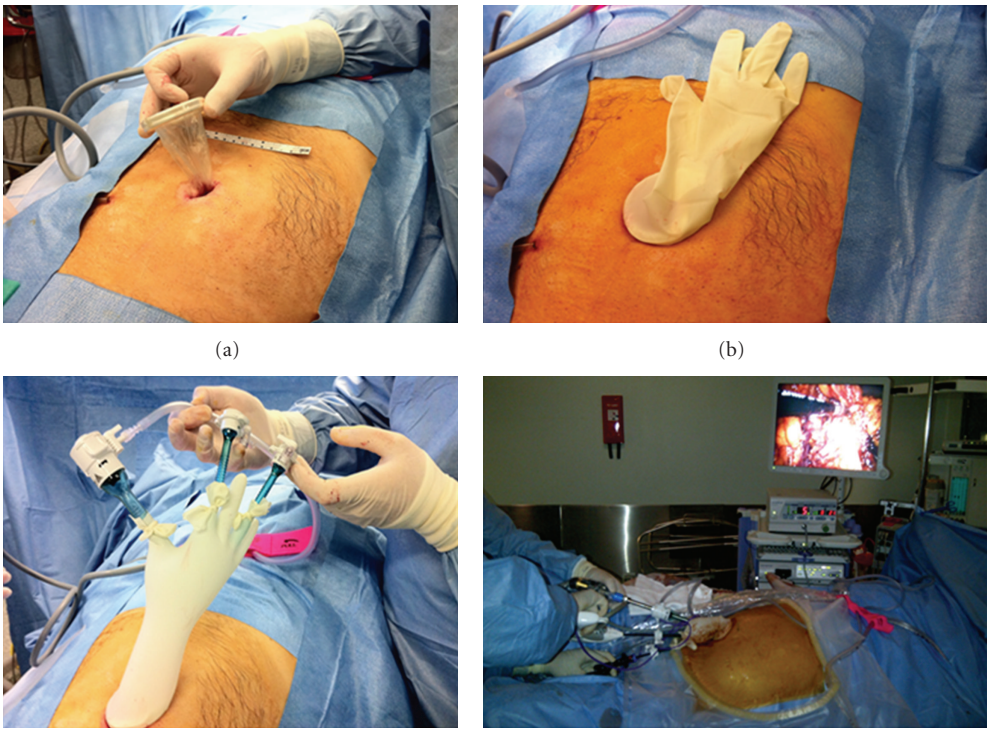

(a) (b) (c) (d)

Figure 1: The assembly of the surgical glove port. A wound protector-retractor is placed into a 3 cm transumbilical incisions. A standard sterile surgical glove is snapped on the outer ring of the wound protector. Standard trocar sleeves are inserted into three of the fingers of the glove and secured in position by tying cut fingers from the other surgical glove in the pair around the trocars. The entire intra-abdominal component of the operation is then performed via this device as the sole abdominal access.

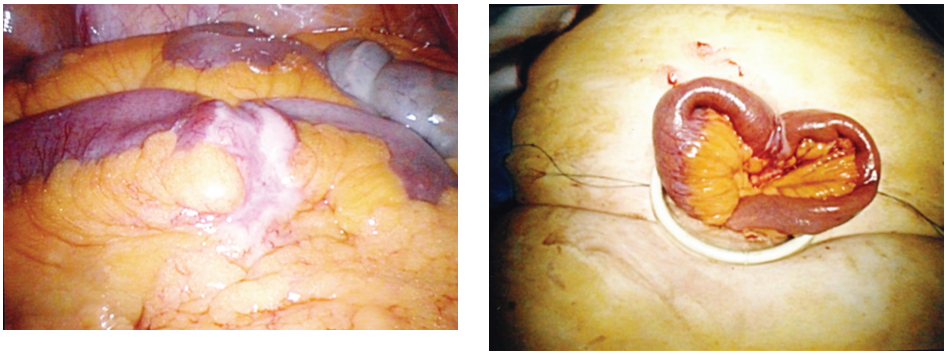

(a) (b)

Figure 2: (a) Obvious small bowel pathology seen at laparoscopy (in this case, histopathological of the excised specimen proved small bowel lymphoma). (b) The same loop of small bowel as shown in Figure 2 exteriorized via the single SALS incisions to allow formal wedge excision and reanastomosis to be performed extracorporeally.

ileus) and one had a mesenteric biopsy alone. Procedures included limited ileo-caecal resection ($n = 4$), ileal resection ($n = 3$), adhesiolysis ($n = 1$), enterotomy ($n = 1$), loop ileostomy ($n = 1$) and true cut biopsy ($n = 1$). Overall the mean incision length was 2.5 ± 1.0 cm (range 2.0–5.0). No patient required access modification or conversion. No intraoperative or postoperative complications were encountered. All patients tolerated normal diet within 2 days. All individual patients characteristics, presentation and perioperative data are summarized in Table 1 while their case summaries are presented next.

3.1. Case Summaries

Case 1. A 62-year-old woman (BMI 23 kg/m^2) with a past history of hysterectomy and bilateral salpingo-oophorectomy in addition to pelvic radiotherapy for ovarian cancer presented with mid-ileal obstruction. CT abdomen

Table 1: Patients characteristics, presentation and perioperative data.

Case No	Sex	Age (yrs)	BMI (kg/m^2)	Previous Open Abdominal Surgery	Presentation	SALS Operation	Pathology	Complications	Length of Postop Stay
1	F	62	23	Hyesterectomy & BSO	Small bowel obstruction	Adhesiolyis, enterotomy	Gallstone ileus	No	5
2	F	59	23.5	No	Abdominal pain, anaemia	Ileal resection	Crohn's Disease	No	5
3	F	78	25.2	No	Abdominal pain, vomiting	Ileal resection	Lymphoma	No	7
4	F	48	28	No	RIF pain	Trucut Biopsy	Carcinoid tumor	No	3
5	F	70	22	No	Faecaluria, recurrent UTI	Loop ileostomy	Metastatic Sigmoid cancer	No	2
6	M	22	20.2	No	Abdominal pain, weight loss	Small bowel resection	Ileal TB	No	4
7	F	37	20.8	No	RIF pain	Ileocaecal resection	Crohn's Disease	No	4
8	F	34	22	No	RIF pain	Ileocaecal resection	Crohn's Disease	No	6
9	F	27	21.5	No	RIF pain, vomiting	Ileocaecal resection	Crohn's Disease	No	3
10	F	27	21.5	No	RIF Pain with masss	Ileocaecal resection	Crohn's Disease	No	6

BMI: Body Mass Index; Postop: Postoperative; F: Female; M: Male; BSO: Bilateral Salphingo-oophorectomy; Abdo: Abdominal; RIF: Right iliac fossa; UTI: Urinary Tract Infection; TB: Tuberculosis.

Figure 3: Operative photograph illustrating patient wound appearances at procedure end. The subcuticularly opposed 3 cm transumbilical wound is seen as the sole site of transabdominal access. The "Painbuster" infusional catheter is seen cephalad on the abdominal wall; this tunnelled catheter provides local anaesthesia by continual bupivacaine infusion for the first thirty hours postoperatively.

demonstrated considerable distension of the proximal ileum with a clear transition point at the point of a radiopaque intraluminal focus. She underwent single-port laparoscopy which allowed adhesiolysis of considerable interloop adhesions before the obstructed loop could be determined. The obstruction was due to an intraluminal gallstone, held up in a mid-ileal loop caught by adhesions against the anterior abdominal wall. With further distal adhesiolysis, this loop was delivered up through the single-port access site allowing enterotomy, removal of the gallstone, and primary ileal closure. The patient made an uneventful recovery and was discharged home on the fifth postoperative day.

Case 2. A 59-year-old woman (BMI 23.5 kg/m^2) presented with fatigue and intermittent abdominal pain in addition to iron deficiency anaemia (haemoglobin 7.5 g/dL). As both upper and lower gastrointestinal endoscopy (including terminal ileal intubation) were normal, a CT of abdomen was performed and revealed a tight distal ileal stricture with appearances consistent with either Crohn's disease or possible lymphoma. After complete mobilisation of the right colon and distal ileum, the diseased loop of bowel was exteriorised and resected. Subsequent pathological examination confirmed the diagnosis of Crohn's disease.

Case 3. A 78-year-old woman (BMI 25.2 kg/m^2) presented with subacute small bowel obstruction on a background

of intermittent, recurrent episodes of abdominal pain with vomiting over the previous three months. She had had no previous abdominal surgery or abdominal wall herniae on physical examination. A CT scan of her abdomen showed dilated proximal ileum with a transition point at the level of the mid-ileum but no obvious mass. Single-port laparoscopy revealed an obstructing lesion around the circumference of the bowel with mesenteric extension at this location (see Figure 2). Surgical relief was achieved by its mobilization, exteriorisation, resection, and extracorporeal anastomosis. Subsequent histological examination revealed a B-cell lymphoma.

Case 4. A 48-year-old woman (BMI 28 kg/m^2) presented with a five-day history of right iliac fossa pain and tenderness. CT abdomen suggested an inflammatory focus related to her distal ileum. Single-port laparoscopy identified a cicatrising mesenteric lesion nearer to the base of her mesentery and allowed its biopsy by means of a tru-cut needle passed through a separate 2 mm stab incision. This biopsy revealed a diagnosis of a carcinoid tumor and allowed planning for its definitive resection at a subsequent operation.

Case 5. A 70-year-old woman (BMI 22 kg/m^2) presented with metastatic sigmoid cancer. Due to extensive liverand lung deposits, she was treated with palliative chemotherapy without resection of the primary tumour. During her treatment, she developed signs and symptoms (pneumaturia, fecaluria, and recurrent urinary tract infections) of a colovesical fistula. To alleviate this problem, she underwent a single-port laparoscopy via a right rectus sheath incision which allowed assessment of the peritoneum and sigmoid. As the primary was unresectable, she had a defunctioning loop ileostomy fashioned in the site of the single laparoscopic access site. She was discharged home well on the second postoperative day and was able to continue her chemotherapy two weeks later.

Case 6. A 22 year old man (BMI 20.2 kg/m^2) from the Middle East who presented with a three month history of recurrent abdominal pain and weight loss with night sweats having being diagnosed with pulmonary tuberculosis six months prior to presentation. CT and terminal ileoscopy revealzed an inflammatory stricture of the terminal ileum. Due to the degree of local symptoms, he went single port laparoscopic resection of the ileal loop with primary stapled extracorporeal anastomosis. Histological examination demonstrated ileocaecal tuberculosis and he was commenced on appropriate therapy.

Cases 7, 8, 9 and 10. All females (37 years (BMI 20.8 kg/m^2), 34 years (BMI kg/m^2), 27 years (BMI kg/m^2), 24 years (BMI 20.5 kg/m^2) with known Crohn's disease presented with increasingly frequent episodes of intermittent, crampy right iliac fossa pain with occasional postprandial vomiting despite maximal medical therapy. One patient had a palpable mass evident on palpation in her right iliac fossa. CT abdomen revealed distal ileal disease in all cases. Single port laparoscopy allowed the performance of a limited ileo-caecal resection with extracorporeal anastomosis in each case. All made uncomplicated postoperative recoveries and were discharged home on between postoperative day 4 ($n = 3$) and 6. Subsequent pathological examination confirmed the diagnosis of Crohn's disease.

4. Discussion

SALS provides the benefits of conventional laparoscopy while reducing the tissue trauma due to the reduction in size and number of ports used. The potential benefits of SALS include reduced postoperative pain, a shorter recovery period, lower morbidity, reduced cost, and superior cosmesis [1]. It also obviates trocar-related intra-abdominal injury and port site incisional hernia formation, and thus may ultimately prove superior. This approach is particularly compelling in cases where a 3 cm incision is required anyway for the purposes of specimen extraction or stoma formation and so this wound can be made at the commencement of the surgery and used as the sole site of transabdominal incision before being closed securely under direct vision at procedure end. The ability to focus local anaesthetic regimens towards one single wound is also intuitively advantageous over the more variable responses associated with broader regional techniques such as transversus abdominus preperitoneal plane (TAPPS) blocks.

To date, however, the published experience is limited with regard to followup beyond hospital discharge and lack of long-term clinical outcome data demonstrating superiority. Furthermore, many laparoscopic surgeons still raise concerns overthe ergonomics of the technique. This is because most believe that triangulation is necessary to create the traction and counter traction that permits efficient surgery by facilitating both dissection along normal anatomical planes and laparoscopic suturing. That is why great care is taken during multiport laparoscopic surgery to respect this physical principle by ensuring trocar placement permits ideal instrument axial alignment. In contrast, the principle of triangulation hardly exists in SALS making it somewhat challenging for the laparoscopic surgeon to achieve fluent two-handed choreography for instrument movement. Therefore, there has been great interest in modification of laparoscopic instruments by implementing angulated shafts, tip reticulation, and robotic platforms to compensate for the limits of constrained parallel access [7]. At present, therefore many surgeons perhaps consider SALS best as a needlessly expensive, difficult, and time-consuming variant of minimal access surgery.

In this pilot series, we have presented a cohort of consecutive, unselected patients requiring surgery for ileal disease where a SALS access device and technique was adopted that minimizes these disadvantages while preserving the advantages of the approach. The "surgical glove port" provides more flexibility and allows greater manoeuvrability than most of the commercially available ports. The proximity of instruments within the access device, which hinders ergonomics, tends to be less constraining as the glove can stretch to increase or decrease the distance between instruments

allowing greater horizontal, vertical, and rotational freedom as well as facilitate enhanced abduction and adduction of instrument tips. Furthermore, the flush positioning of the ring construct minimises the fulcrum bulk around which the instruments pivot in contrast to the majority of commercially available single-port devices which enforce parallel positioning of instrument shafts at least throughout the cylindrical component of the device. The glove port device is always readily available, thereby relieving the pressure of both preoperative selection and economic considerations and therefore means the modality can be employed with sufficient spontaneity and regularity (including its use during multiport laparoscopic colorectal resections such as to recapture the specimen extraction site to restore pneumoperitoneum and maintain full-port capacity) to ensure pan-departmental expertise [6]. Additionally a coaxial light cable instead of the tangential light cable on the laparoscope helps to overcome instrument clashing. For the novice SALS surgeon, utilizing this approach for ileal disease represents an ideal opportunity to ascend their learning curve. It is always possible to convert a SALS procedure standard laparoscopy by adding more trocars to complete the procedure (still using the single incision to extract the specimen at the end of the operation) or to extend the existing incision to convert to an open approach at no disadvantage to the patient and without significant added cost for the healthcare provider. An additional economic advantage is that, as only trocar sleeves are used with the Glove port, there is a cost-saving compared to the standard multiport approach which needs trocars with bladed obturators.

Laparoscopy is now considered an acceptable approach for initial assessment and possible management of small bowel obstruction with a conversion to a midline laparotomy rate of 29% [8]. Meta-analysis comparing laparoscopic and open approaches for the management of small bowel Crohn's disease has also demonstrated that laparoscopic surgery is associated with reduced wound infection, reduced length of stay, shorter time for recovery of enteric function, reduced reoperation rates for nondisease-related complications, and no difference in disease recurrence [9, 10]. Since the first report of SALS for the management of ileocolic Crohn's disease [11], there has been a further of four case reports [12–15] and seven case series with the number of patients ranging from one to fourteen [2, 16–21] demonstrating this approach is safe, feasible, and maintains all the advantages of traditional multiport approaches. The data presented herein further supports SALS for the management of small bowel Crohn's disease. Given the predominantly young age of patients presenting for surgery with Crohn's disease and their concerns regarding cosmesis [22] as well their potential for needing further surgery (and so the preservation of uninjured abdominal wall should facilitate reoperation), SALS may represent the optimal minimally invasive approach in this setting.

Finally, to the authors' knowledge, the usefulness and safety of this technique in the acute setting has been demonstrated for the first time. Patients presenting for urgent gastrointestinal operation have higher rates of infectious and other postoperative morbidity and greater wound complications both in the short and intermediate term [23]. If there is to be a category of patients in whom reducing the abdominal wound is important for reasons other than cosmesis, it is clearly this group of patients.

In conclusion, SALS for small bowel diseases is feasible and it can be performed without specialized instrumentation and at no extra cost. Further evaluation is required to optimise the technique; however, there are currently many available innovative, adapted techniques that can spur on the evolution of minimal access surgery by interested practitioners for the benefit of patients. While caution is needed to ensure judicious selection, ileal disease is often limited in its extent and most often specifically diagnosed by a preoperative CT. Moreover, the ileum tends to be mobile and therefore positionable both in terms of intraperitoneal quadrant and extraction via the access site.

References

[1] K. Ahmed, T. T. Wang, V. M. Patel et al., "The role of single-incision laparoscopic surgery in abdominal and pelvic surgery: a systematic review," *Surgical Endoscopy*, vol. 25, no. 2, pp. 378–396, 2011.

[2] D. Geisler and T. Garrett, "Single incision laparoscopic colorectal surgery: a single surgeon experience of 102 consecutive cases," *Techniques in Coloproctology*, vol. 15, no. 4, pp. 397–401, 2011.

[3] N. Baig, M. Moftah, J. Deasy, D. McNamara, and R. A. Cahill, "Implementation and usefulness of single access laparoscopic segmental and total colectomy," *Colorectal Disease*. In press.

[4] D. Canes, A. Berger, M. Aron et al., "Laparo-endoscopic single site (LESS) versus standard laparoscopic left donor nephrectomy: matched-pair comparison," *European Urology*, vol. 57, no. 1, pp. 95–101, 2010.

[5] A. van der Merwe, A. Bachmann, and C. F. Heyns, "Retroperitoneal LESS donor nephrectomy," *International Brazilian Journal of Urology*, vol. 36, no. 5, pp. 602–608, 2010.

[6] R. Hompes, I. Lindsey, O. M. Jones et al., "Stepwise integration of single port laparoscopic surgery into routine colorectal surgical practice by use of a surgical glove port," *Techniques in Coloproctology*, vol. 15, no. 2, pp. 165–171, 2011.

[7] M. Sugimoto, K. Tanaka, Y. Matsuoka et al., "da Vinci robotic single-incision cholecystectomy and hepatectomy using single-channel GelPort access," *Journal of Hepato-Biliary-Pancreatic Sciences*, vol. 18, no. 4, pp. 493–498, 2011.

[8] D. B. O'Connor and D. C. Winter, "The role of laparoscopy in the management of acute small-bowel obstruction: a review of over 2,000 cases," *Surgical Endoscopy*, vol. 26, no. 1, pp. 12–17, 2011.

[9] B. V. Dasari, D. McKay, and K. Gardiner, "Laparoscopic versus Open surgery for small bowel Crohn's disease," *Cochrane Database of Systematic Reviews*, no. 1, Article ID CD006956, 2011.

[10] H. S. Tilney, V. A. Constantinides, A. G. Heriot et al., "Comparison of laparoscopic and open ileocecal resection for Crohn's disease: a metaanalysis," *Surgical Endoscopy*, vol. 20, no. 7, pp. 1036–1044, 2006.

[11] A. Heeney, D. B. O'Connor, S. Martin, and D. C. Winter, "Single-port access laparoscopic surgery for complex Crohn's disease," *Inflammatory Bowel Diseases*, vol. 16, no. 8, pp. 1273–1274, 2010.

[12] T. Karahasanoglu, I. Hamzaoglu, E. Aytac, and B. Baca, "Transvaginal assisted totally laparoscopic single-port right colectomy," *Journal of Laparoendoscopic & Advanced Surgical Techniques*, vol. 21, no. 3, pp. 255–257, 2011.

[13] H. Kawahara, K. Watanabe, T. Ushigome, R. Noaki, S. Kobayashi, and K. Yanaga, "Single-incision laparoscopic right colectomy for recurrent Crohn's disease," *Hepato-Gastroenterology*, vol. 57, no. 102-103, pp. 1170–1172, 2010.

[14] S. Scaringi, F. Giudici, G. Liscia, C. Cenci, and F. Tonelli, "Single-port laparoscopic access for Crohn's disease complicated by enterocutaneous fistula," *Inflammatory Bowel Diseases*, vol. 17, no. 2, pp. E6–E7, 2011.

[15] G. S. Sica, S. Di Carlo, L. Biancone, P. Gentileschi, F. Pallone, and A. L. Gaspari, "Single access laparoscopic ileocecal resection in complicated Crohn's disease," *Surgical Innovation*, vol. 17, no. 4, pp. 359–360, 2010.

[16] C. A. Laituri, J. D. Fraser, C. L. Garey et al., "Laparoscopic ileocecectomy in pediatric patients with Crohn's disease," *Journal of Laparoendoscopic & Advanced Surgical Techniques*, vol. 21, no. 2, pp. 193–195, 2011.

[17] H. Ross, S. Steele, M. Whiteford et al., "Early multi-institution experience with single-incision laparoscopic colectomy," *Diseases of the Colon and Rectum*, vol. 54, no. 2, pp. 187–192, 2011.

[18] B. Chaudhary, D. Glancy, and A. R. Dixon, "Laparoscopic surgery for recurrent ileocolic Crohn's disease is as safe and effective as primary resection," *Colorectal Disease*, vol. 13, no. 12, pp. 1413–1416, 2011.

[19] B. J. Champagne, E. C. Lee, F. Leblanc, S. L. Stein, and C. P. Delaney, "Single-incision vs straight laparoscopic segmental colectomy: a case-controlled study," *Diseases of the Colon and Rectum*, vol. 54, no. 2, pp. 183–186, 2011.

[20] A. Keshava, C. J. Young, and S. MacKenzie, "Single-incision laparoscopic right hemicolectomy," *British Journal of Surgery*, vol. 97, no. 12, pp. 1881–1883, 2010.

[21] K. J. Gash, A. C. Goede, W. Chambers, G. L. Greenslade, and A. R. Dixon, "Laparoendoscopic single-site surgery is feasible in complex colorectal resections and could enable day case colectomy," *Surgical Endoscopy*, vol. 25, no. 3, pp. 835–840, 2011.

[22] E. J. Eshuis, S. W. Polle, J. F. Slors et al., "Long-term surgical recurrence, morbidity, quality of life, and body image of laparoscopic-assisted vs. open ileocolic resection for Crohn's disease: a comparative study," *Diseases of the Colon and Rectum*, vol. 51, no. 6, pp. 858–867, 2008.

[23] D. B. Hennessey, J. P. Burke, T. Ni-Dhonochu, C. Shields, D. C. Winter, and K. Mealy, "Preoperative hypoalbuminemia is an independent risk factor for the development of surgical site infection following gastrointestinal surgery: a multi-institutional study," *Annals of Surgery*, vol. 252, no. 2, pp. 325–329, 2010.

Hindawi Publishing Corporation
Minimally Invasive Surgery
Volume 2012, Article ID 197429, 4 pages
doi:10.1155/2012/197429

Clinical Study

Single-Port Laparoscopic Spleen Preserving Distal Pancreatectomy

Stephen K. Y. Chang,[1] Davide Lomanto,[2] and Maria Mayasari[1]

[1] *Division of Hepatobiliary and Pancreatic Surgery, Department of Surgery, University Surgical Cluster, National University Hospital, Singapore 119228*
[2] *Minimally Invasive Surgical Centre, Department of Surgery, National University Hospital, Singapore 119228*

Correspondence should be addressed to Stephen K. Y. Chang, cfscky@nus.edu.sg

Received 16 November 2011; Accepted 21 November 2011

Academic Editor: Luigi Boni

Single-port laparoscopic surgery has become increasingly popular, with widened indication to more types of surgery. This report will present our initial experience with spleen-preserving distal pancreatectomy technique through a small transumbilical incision using the single-port approach for a cystic tumor of pancreatic body. The surgery was done using specialized single-port instruments and normal laparoscopic instruments. The total operative time for this surgery is 233 minutes, and it was completed without drains. Patient was discharged from the hospital on the third day postoperatively in good condition.

1. Introduction

Distal pancreatectomy has been performed since early twentieth century [1].The first description of laparoscopic distal pancreatectomy was published by Soper et al. in 1994 [2] in animal model but since then many surgeons worldwide with better improvement of technologies, like ultrasonography, staplers, instrumentations, and so forth, have been applied safely in humans [3, 4]. In recent years, laparoscopic distal pancreatectomy had been performed for benign [5, 6], malignant [7], inflammatory lesion [8], and even for harvesting pancreatic donor for transplant [9]. Though technically feasible, this procedure is not frequently performed, probably due to the limited cases indicated for this procedure, the technical difficulty involved, and the high-tech devices required. Today indications for distal pancreatectomy include distal tumors (neuroendocrine and cystic lesions), chronic pancreatitis, and isolated pseudocysts.

In the past 10 years, minimal access surgery is increasingly popular and is moving towards further minimizing the surgical trauma by reducing numbers and size of the port. In the last few years, a novel technique called "Scar-less surgery" through a single-incision laparoscopic approach, has become one of the emerging technique. This technique is becoming popular especially for female patients due to the invaluable cosmetic results. In our institution, surgery using single port technique, such as appendicectomy, cholecystectomy, and hernia repair, is widely under investigation by randomized control trials. More complex operations with single-port technique are also being performed involving obesity surgeries, gastrectomies, liver resections, and so forth. Distal pancreatectomy may be another promising procedure that can be done through single-incision approach due to the wide range of instruments, energy sealing devices, and staplers available today.

This report will present our initial experience with spleen preserving distal pancreatectomy technique through a small transumbilical incision using the single-port approach.

2. Case Report

A 40-year-old female was found to have a 3.5 cm cyst at the body of the pancreas on ultrasound during a routine health screening. She had 2 previous laparoscopic procedures for pelvic inflammatory disease and excision of ovarian cyst.

A CT scan showed a complex cyst with septations measuring more than 3 cm and subsequent endoscopic

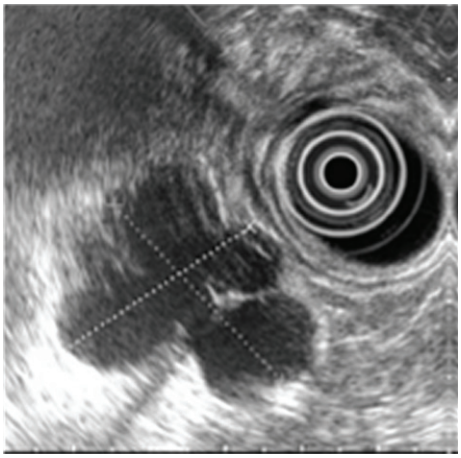

Figure 1: Endoscopic ultrasound image showing the cyst in pancreatic body.

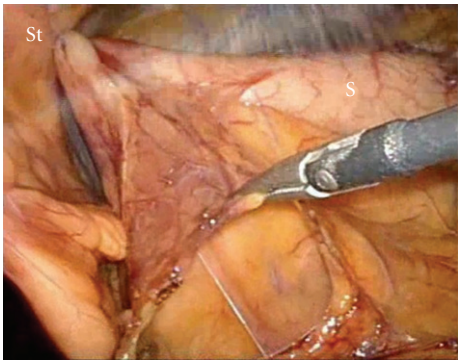

Figure 2: Opening of bursa omentalis. The stomach was retracted upwards with the help of stay sutures using prolene straight needle to the anterior abdominal wall. (St = Stay Sutures, S = Stomach.)

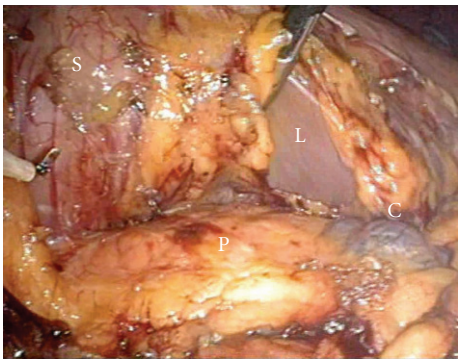

Figure 3: Exposure of pancreas. The lesion is seen at the right side of the picture. (C = cyst, P = pancreas, L = liver.)

ultrasound followed with fine-needle aspiration showed a multiloculated hypoechoic cystic lesion located at the body of pancreas with high Ca 19-9 of 148.2 U/mL (n.v. ≤ 37 U/mL), (Figure 1), suggestive of cystic mucin-producing neoplasm. She subsequently underwent spleen-preserving distal pancreatectomy via single-port approach.

3. Surgical Technique

Under general anesthesia, patient was placed in a French position with both arms tucked in. An SILS (Covidien USA) port was introduced through a 2 cm midline periumbilical incision, and three 5 mm ports were introduced into the SILS port.

Pneumoperitoneum was achieved, with pressure setting of 13 mmHg. A diagnostic laparoscopy was performed, using the 5 mm Endo-eye (Olympus, Japan) 30° telescope to confirm the absence of advance malignant disease. Out of the standard instrumentation, an Endograsp roticulator (Covidien AutoSuture, USA) was utilized during the surgery to avoid clashes and conflict between instruments and telescope and to improve triangulation.

The lesser sac was entered by opening the omentum along the greater curvature of the stomach using Ligasure (Covidien, USA), this allows the exposure of the pancreas as in standard technique. A total of three prolene straight needles stay sutures were placed superficially to the posterior gastric wall and slinged to the anterior abdominal wall to expose the pancreas (Figure 2). The cystic lesion was identified at the body of pancreas, measuring approximately 3 cm (Figure 3). Intraoperative laparoscopic ultrasound was used to confirm the lesion and that no other lesion was present.

After the lesion has been identified and assessed to be operable, the inferior edge of the pancreatic capsule is incised. Subsequently, a tunnel was created beneath the pancreatic neck from caudal to cephalad direction and freeing the pancreatic parenchyma from the splenic vessels. A cotton sling was passed through to lift the pancreas, and the pancreatic neck was then transected with the use of Ligasure (Figure 4) preserving the splenic vessels. A careful dissection of distal pancreas from medial to lateral approach was carried out with preservation of the main splenic artery and veins (Figure 5).

Short transverse branches of the splenic artery and vein were individually isolated and sealed using Ligasure and the distal pancreatectomy was carried out by dissecting the specimen off its retroperitoneal attachments. The pancreatic stump was reinforced with continuous suture using V-lock suture-needle (Covidien, USA, Figure 6) involving the pancreatic duct. Afterwards, the prolene lifting sutures were removed and the specimen retrieved using bag retrieval (Applied Medical, USA) and delivered out through the umbilical wound (Figure 7).

The umbilical fascia was closed using 2.0 PDS sutures (Ethicon, USA), and no drains were inserted. Total operative time was 233 minutes, total blood loss was less than 100cc.

Patient recovery was uneventful. Liquid diet was started on first postoperative day before progressing to normal diet on the second postoperative day. Independent ambulation was achieved on the first postoperative day. She was discharged on the third postoperative day. Postoperative histopathology report was macrocystic serous cyst adenoma with free margin of the tumor.

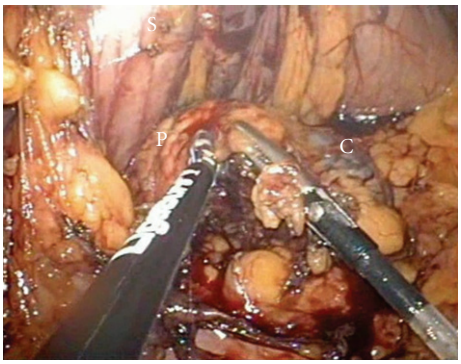

Figure 4: Transection of pancreatic neck using ligasure and roticulator endograsper.

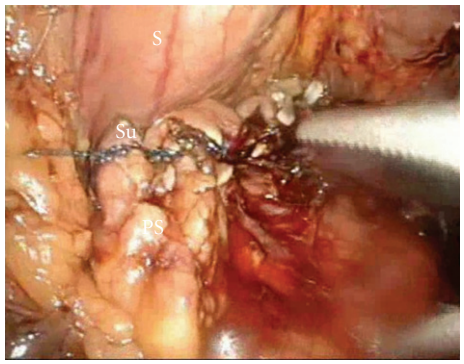

Figure 6: Pancreatic stump postsuturing (Su = sutures, P = pancreas).

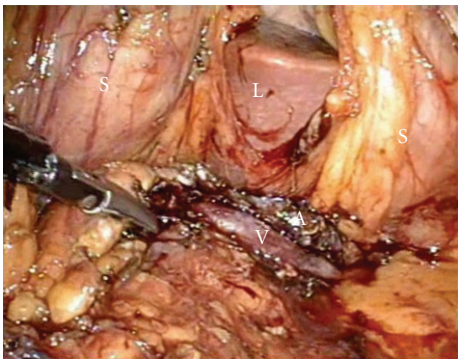

Figure 5: Tumor bed after resection. The splenic vessels (A = splenic artery, V= splenic veins) are seen intact in the horizontal manner.

Figure 7: Postoperative wound.

4. Discussion

Distal pancreatectomy is not commonly done in many centers due to lack of suitable cases for this procedure. However, when indicated, laparoscopic approach is preferred than open. A meta-analysis [10] in 2010 showed that the minimally invasive approach has less morbidity and shorter hospital stay than open approach. Therefore, a laparoscopic approach should be considered as the first approach for distal pancreatectomy.

Single-port laparoscopic surgery [11–15] has been an emerging technique implemented and offered in simple cases such as appendicectomy and cholecystectomy worldwide in our institution. This approach may take longer to complete and require advance skills and dedicated instrumentations to compensate the lack of the triangulation as in conventional laparoscopy. In our experience, a combination of articulated grasper or dissector, sealing device like Ligasure, and telescope like Endoeye is necessary to overcome the clashes of instrumentations during single-port laparoscopic surgery. This allows a good dissection, traction, sealing and prevents instrument clashes within or outside of the abdomen. The options of using Ligasure advance, in this operation, was based on its ability to sealed vessels up to 6 mm and to have a thin tip for dissection. This is particularly important in keeping a bloodless view when dissecting the pancreas because of the rich blood supply of the organ and the tiny transverse branch of the splenic vessels. The operative time was 233 minutes, comparable to the average time used for conventional laparoscopic distal pancreatectomy of other series [10, 16].

The size of the lesion was 3 cm and is within the accepted indication for laparoscopic approach [16]. Probably for larger lesion (>3-4 cm), the single-port approach would not be appropriate, because of the need of a larger the incision to deliver the specimen out of the abdomen.

In our spleen-preserving technique, we carefully preserve both splenic vessels; this method is our preferred technique, since it avoids the splenectomy with all related intra- and postoperative complications as described by Warshaw [17, 18], like delivering a large organ out through the small port site, the risk of postoperative splenic infarction, and the postsplenectomy morbidity.

The postoperative recovery of the patient was uneventful and rapid with independent ambulation occurring on first day after surgery in keeping with the claimed advantages of minimal invasive over open approach.

5. Conclusion

Distal pancreatectomy is a complex procedure that was associated with high risk of complications and morbidity. The laparoscopic approach used has been well received with the experience of less complications and shorter hospital stay. The single-port laparoscopic distal pancreatectomy with spleen-preserving technique is a feasible and safe technique that can be done in selected cases and in highly qualified surgical centres.

References

[1] W. J. Mayo, "The surgery of the pancreas," *Annals of Surgery*, vol. 58, pp. 145–150, 1913.

[2] N. J. Soper, L. M. Brunt, D. L. Dunnegan, and T. A. Meininger, "Laparoscopic distal pancreatectomy in the porcine model," *Surgical Endoscopy*, vol. 8, no. 1, pp. 57–61, 1994.

[3] M. Gagner, A. Pomp, M. F. Herrera et al., "Early experience with laparoscopic resections of islet cell tumors," *Surgery*, vol. 120, no. 6, pp. 1051–1054, 1996.

[4] S. A. Cuschieri and J. J. Jakimowicz, "Laparoscopic pancreatic resections," *Surgical Innovation*, vol. 5, no. 3, pp. 168–179, 1998.

[5] A. Marinis, G. Anastasopoulos, and G. Polymeneas, "A solid pseudopapillary tumor of the pancreas treated with laparoscopic distal pancreatectomy and splenectomy: a case report and review of the literature," *Journal of Medical Case Reports*, vol. 4, p. 387, 2010.

[6] S. C. Kim, K. T. Park, J. W. Hwang et al., "Comparative analysis of clinical outcomes for laparoscopic distal pancreatic resection and open distal pancreatic resection at a single institution," *Surgical Endoscopy and Other Interventional Techniques*, vol. 22, no. 10, pp. 2261–2268, 2008.

[7] D. A. Kooby and C. K. Chu, "Laparoscopic management of pancreatic malignancies," *Surgical Clinics of North America*, vol. 90, no. 2, pp. 427–446, 2010.

[8] P. M. Fisichella, V. Shankaran, and M. Shoup, "Laparoscopic distal pancreatectomy with or without splenectomy: how i do it," *Journal of Gastrointestinal Surgery*, vol. 15, no. 1, pp. 215–218, 2010.

[9] M. Maruyama, T. Kenmochi, N. Akutsu et al., "Laparoscopic-assisted distal pancreatectomy and nephrectomy from a live donor," *Journal of Hepato-Biliary-Pancreatic Sciences*, vol. 17, no. 2, pp. 193–196, 2010.

[10] G. R. Nigri, A. S. Rosman, N. Petrucciani et al., "Metaanalysis of trials comparing minimally invasive and open distal pancreatectomies," *Surgical Endoscopy*, vol. 25, no. 5, pp. 1642–1652, 2010.

[11] J. Ma, M. A. Cassera, G. O. Spaun, C. W. Hammill, P. D. Hansen, and S. Aliabadi-Wahle, "Randomized controlled trial comparing single-port laparoscopic cholecystectomy and four-port laparoscopic cholecystectomy," *Annals of Surgery*, vol. 254, no. 1, pp. 22–27, 2011.

[12] A. Fagotti, C. Bottoni, G. Vizzielli et al., "Postoperative pain after conventional laparoscopy and laparoendoscopic single site surgery (LESS) for benign adnexal disease: a randomized trial," *Fertility and Sterility*, vol. 96, no. 1, pp. 255–259, 2011.

[13] M. Zheng, M. Qin, and H. Zhao, "Laparoendoscopic single-site cholecystectomy: a randomized controlled study," *Minimally Invasive Therapy and Allied Technologies*. In press.

[14] A. Y. B. Teoh, P. W. Y. Chiu, T. C. L. Wong, S. K. H. Wong, P. B. S. Lai, and E. K. W. Ng, "A case-controlled comparison of single-site access versus conventional three-port laparoscopic appendectomy," *Surgical Endoscopy*, vol. 25, no. 5, pp. 1415–1419, 2010.

[15] S. K. Y. Chang, C. W. Tay, R. A. Bicol, Y. Y. Lee, and K. Madhavan, "A Case-control study of single-incision versus standard laparoscopic cholecystectomy," *World Journal of Surgery*, vol. 35, no. 2, pp. 289–293, 2010.

[16] B. J. Ammori and G. D. Ayiomamitis, "Laparoscopic pancreaticoduodenectomy and distal pancreatectomy: a UK experience and a systematic review of the literature," *Surgical Endoscopy*, vol. 25, no. 7, pp. 2084–2099, 2011.

[17] L. Fernández-Cruz, D. Orduña, G. Cesar-Borges, and M. A. López-Boado, "Distal pancreatectomy: En-bloc splenectomy vs spleen-preserving pancreatectomy," *Journal of the International Hepato Pancreato Biliary Association*, vol. 7, no. 2, pp. 93–98, 2005.

[18] S. E. Lee, J. Y. Jang, K. U. Lee, and S. W. Kim, "Clinical comparison of distal pancreatectomy with or without splenectomy," *Journal of Korean Medical Science*, vol. 23, no. 6, pp. 1011–1014, 2008.