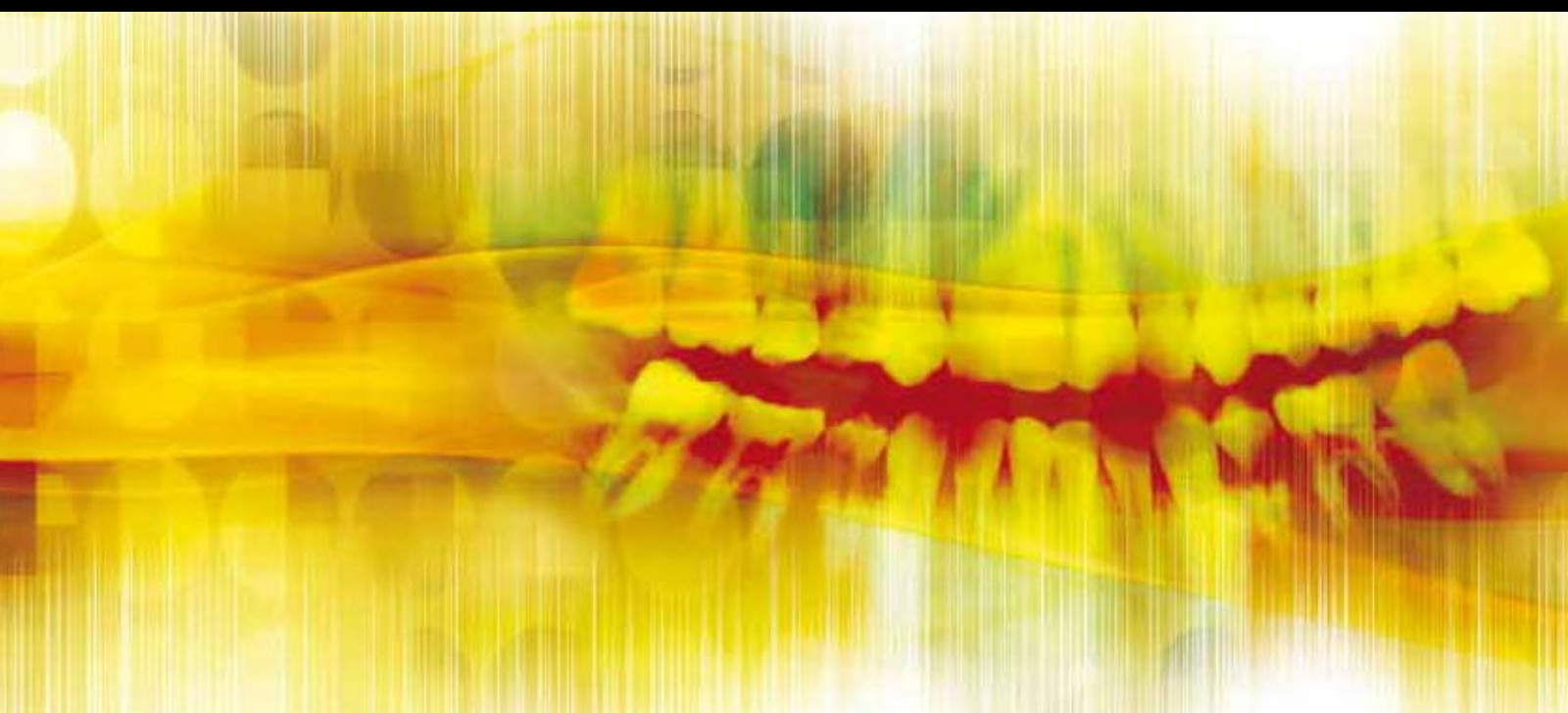

# MAXILLARY SINUS in RELATION TO MODERN ORAL AND MAXILLOFACIAL SURGERY

GUEST EDITORS: SILVIO TASCHIERI, MASSIMO DEL FABBRO, IGOR TSEIS,  
AND STEFANO CORBELLA





---

# **Maxillary Sinus in relation to Modern Oral and Maxillofacial Surgery**

International Journal of Dentistry

---

## **Maxillary Sinus in relation to Modern Oral and Maxillofacial Surgery**

Guest Editors: Silvio Taschieri, Massimo Del Fabbro,  
Igor Tsesis, and Stefano Corbella



---

Copyright © 2012 Hindawi Publishing Corporation. All rights reserved.

This is a special issue published in "International Journal of Dentistry." All articles are open access articles distributed under the Creative Commons Attribution License, which permits unrestricted use, distribution, and reproduction in any medium, provided the original work is properly cited.

## Editorial Board

Ali Abdalla, Egypt  
Yahya Açil, Germany  
Jasim M. Albandar, USA  
Eiichiro Arijii, Japan  
Manal Awad, UAE  
Ashraf F. Ayoub, UK  
Silvana Barros, USA  
Sema Belli, Turkey  
Marilia Buzalaf, Brazil  
Giuseppina Campisi, Italy  
Francesco Carinci, Italy  
Lim K. Cheung, Hong Kong  
Brian W. Darvell, Kuwait  
Hugo De Bruyn, Belgium  
Dong M. Deng, The Netherlands  
Shinn-Jyh Ding, Taiwan  
J. D. Eick, USA  
Annika Ekestubbe, Sweden  
Carla Evans, USA  
Vincent Everts, The Netherlands  
Stefano Fedele, UK  
G. Nogueira Filho, Canada  
Roland Frankenberger, Germany  
Gerald Glickman, USA  
Valeria V. Gordan, USA  
Rosa H. Grande, Brazil  
Yoshitaka Hara, Japan

James K. Hartsfield, USA  
Yumiko Hosoya, Japan  
Saso Ivanovski, Australia  
Chia-Tze Kao, Taiwan  
Elizabeth Kay, UK  
Heidrun Kjellberg, Sweden  
Kristin Klock, Norway  
Kee-Yeon Kum, Republic of Korea  
Manuel Lagravere, Canada  
Daniel M. Laskin, USA  
Claudio R. Leles, Brazil  
Louis M. Lin, USA  
A. D. Loguercio, Brazil  
Tommaso Lombardi, Switzerland  
Martin Lorenzoni, Austria  
Adriano Loyola, Brazil  
Maria Machado, Brazil  
Jukka H. Meurman, Finland  
Hendrik Meyer-Luckel, Germany  
Konstantinos Michalakis, Greece  
Masashi Miyazaki, Japan  
Yasuhiro Morimoto, Japan  
Carlos A. Munoz-Viveros, USA  
Hiroshi Murata, Japan  
Ravindra Nanda, USA  
Toru Nikaido, Japan  
Joseph Nissan, Israel

Chikahiro Ohkubo, Japan  
Athena Papas, USA  
Patricia Pereira, USA  
Roberta Pileggi, USA  
A. B. M. Rabie, Hong Kong  
Michael E. Razzoog, USA  
André Reis, Brazil  
Stephen Richmond, UK  
George E. Romanos, USA  
Kamran Safavi, USA  
Tuula Salo, Finland  
Gilberto Sammartino, Italy  
Robin Seymour, UK  
Timo Sorsa, Finland  
Gianrico Spagnuolo, Italy  
Andreas Stavropoulos, Denmark  
Dimitris N. Tatakis, USA  
Shigeru Uno, Japan  
Jacques Vanobbergen, Belgium  
Marcos Vargas, USA  
Ahmad Waseem, UK  
Izzet Yavuz, Turkey  
Cynthia Yiu, Hong Kong  
Li-wu Zheng, Hong Kong  
Qiang Zhu, USA  
Spiros Zinelis, Greece

# Contents

**Maxillary Sinus in relation to Modern Oral and Maxillofacial Surgery**, Silvio Taschieri, Massimo Del Fabbro, Igor Tsesis, and Stefano Corbella  
Volume 2012, Article ID 391012, 2 pages

**Tilted Implants for Full-Arch Rehabilitations in Completely Edentulous Maxilla: A Retrospective Study**, Nicolò Cavalli, Bruno Barbaro, Davide Spasari, Francesco Azzola, Alberto Ciatti, and Luca Francetti  
Volume 2012, Article ID 180379, 6 pages

**Prevention and Treatment of Postoperative Infections after Sinus Elevation Surgery: Clinical Consensus and Recommendations**, Tiziano Testori, Lorenzo Drago, Steven S. Wallace, Matteo Capelli, Fabio Galli, Francesco Zuffetti, Andrea Parenti, Matteo Deflorian, Luca Fumagalli, Roberto L. Weinstein, Carlo Maiorana, Danilo Di Stefano, Pascal Valentini, Aldo B. Gianni, Matteo Chiapasco, Raffaele Vinci, Lorenzo Pignataro, Mario Mantovani, Sara Torretta, Carlotta Pipolo, Giovanni Felisati, Giovanni Padoan, Paolo Castelnuovo, Roberto Mattina, and Massimo Del Fabbro  
Volume 2012, Article ID 365809, 5 pages

**Influence of Material Properties on Rate of Resorption of Two Bone Graft Materials after Sinus Lift Using Radiographic Assessment**, Fawzi Riachi, Nada Naaman, Carine Tabarani, Nayer Aboelsaad, Moustafa N. Aboushelib, Antoine Berberi, and Ziad Salameh  
Volume 2012, Article ID 737262, 7 pages

**Schneider Membrane Elevation in Presence of Sinus Septa: Anatomic Features and Surgical Management**, Mario Beretta, Marco Cicciù, Ennio Bramanti, and Carlo Maiorana  
Volume 2012, Article ID 261905, 6 pages

**Repair of a Perforated Sinus Membrane with a Subepithelial Palatal Conjunctive Flap: Technique Report and Evaluation**, S. A. Gehrke, S. Taschieri, M. Del Fabbro, and S. Corbella  
Volume 2012, Article ID 489762, 7 pages

**Osteotome-Mediated Sinus Lift without Grafting Material: A Review of Literature and a Technique Proposal**, Silvio Taschieri, Stefano Corbella, Massimo Saita, Igor Tsesis, and Massimo Del Fabbro  
Volume 2012, Article ID 849093, 9 pages

**Biological Principles and Physiology of Bone Regeneration under the Schneiderian Membrane after Sinus Lift Surgery: A Radiological Study in 14 Patients Treated with the Transcrestal Hydrodynamic Ultrasonic Cavitational Sinus Lift (Intralift)**, A. Troedhan, A. Kurrek, and M. Wainwright  
Volume 2012, Article ID 576238, 12 pages

## Editorial

# Maxillary Sinus in relation to Modern Oral and Maxillofacial Surgery

**Silvio Taschieri,<sup>1</sup> Massimo Del Fabbro,<sup>1</sup> Igor Tsesis,<sup>2</sup> and Stefano Corbella<sup>3</sup>**

<sup>1</sup>Oral Health Research Centre, Department of Biomedical, Surgical and Dental Sciences, Università degli Studi di Milano, IRCCS Istituto Ortopedico Galeazzi, Milan, Italy

<sup>2</sup>Department of Endodontology, Maurice and Gabriela Goldschleger School of Dental Medicine, Tel Aviv, Israel

<sup>3</sup>Oral Implantology Research Centre, Department of Biomedical, Surgical and Dental Sciences, Università degli Studi di Milano, IRCCS Istituto Ortopedico Galeazzi, Milan, Italy

Correspondence should be addressed to Silvio Taschieri, [silvio.taschieri@fastwebnet.it](mailto:silvio.taschieri@fastwebnet.it)

Received 26 November 2012; Accepted 26 November 2012

Copyright © 2012 Silvio Taschieri et al. This is an open access article distributed under the Creative Commons Attribution License, which permits unrestricted use, distribution, and reproduction in any medium, provided the original work is properly cited.

The maxillary sinus is a fundamental anatomical structure which is often involved in many oral and maxillofacial surgical procedures in the posterior maxilla, and whose integrity is important to preserve.

Infracture or invasion of maxillary sinus can occur during augmentation procedures and implant placement, especially when residual ridge height is reduced due to the process of bone loss after tooth extractions in the posterior maxilla. The invasion of maxillary sinus can hypothetically be considered a potential source of infection or irritation which can lead to inflammation of sinus membrane.

Because of these aspects, the placement of dental implants in the atrophic posterior maxilla is a challenging procedure in the presence of reduced maxillary bone height.

Various techniques have been proposed in order to obtain the adequate bone dimension for the insertion of implants. However, due to the improvement of surgical techniques and the progress of research in the field of biomaterials, excellent outcomes have been reported in the last years for implant-supported rehabilitations even in cases with severe atrophy.

Several types of complications may occur during and after the sinus elevation procedure with lateral approach. In fact, relatively frequent Schneiderian membrane perforations, nose bleeding, postoperative pain, and swelling could be considered as major drawbacks for this treatment alternative even though it was not described an important negative effect on implant success rates.

In this special issue, several aspects about implant placement in relation to interventions to augment posterior maxilla bone volume were discussed, and the reader can find a summary of the contents of the articles included.

The results of a clinical consensus of experts published in this issue (periodontists, implantologist, maxillofacial surgeons, ENT, and microbiology specialists) on several clinical questions and to give clinical recommendations on how to prevent, diagnose, and treat postoperative infections, can be useful for the clinician to make the right treatment choice and give guidelines for handling the intra-operative and post-operative complications. Moreover, the presented guidelines showed that a multidisciplinary approach can help in limiting the occurrence of complications and improving patients' quality of life.

S. A. Gehrke et al. showed a repair technique of a perforated sinus membrane with a subepithelial palatal conjunctive flap. Authors concluded that the use of conjunctive technique with collected palate flap for sealing the perforation of the membrane of the sinus may have predictable result. It could be hypothesized that repairing the sinus injury entrapping the bone graft in a safety and closed sinus cavity, and achieving a contact between this package and the vascularized sinus walls could be enough to favor angiogenesis and contextually the developing of newly formed vital bone.

M. Beretta et al. highlight the correct steps for doing sinus lift surgery in presence of anatomic variations such as sinus septa. Radiographic identification of these structures is

important in order to perform the right design of the lateral window during sinus lift and to avoid complications related to the sinus lift surgery. The correct steps in performing the surgical procedures can be an important aid in the sinus lifting procedure with lateral approach in presence of sinus septa.

N. Cavalli et al. in this issue presented an alternative technique in case of severe atrophic posterior maxilla. Patients received a maxillary full-arch fixed bridge supported by two axial implants and two distal tilted implants, without a sinus lift management. The overall follow-up range was 12 to 73 months (mean 38.8 months). The high cumulative implant survival rate indicates that this technique could be considered a viable treatment option. Authors underlined the relevance of an effective recall program in order to early intercept and correct prosthetic and biologic complications in order to avoid implant and prosthetic failures. It should be underlined that this procedure can be useful to avoid the management of maxillary sinus in cases of the presence of sinus pathology.

While autogenous bone has long been considered the gold standard grafting material because of its osteoinductive and osteoconductive properties, alternative materials have, in general, no osteoinductive potential but are considered to provide a scaffold for optimal bone growth. The efficacy of the graft material in promoting graft maturation and providing optimal long-term support to endosseous implants is one of the most critical factors for the success of the sinus augmentation procedure.

A. Troedhan et al. investigated the key role of the sinus-membrane in bone reformation in vivo. The results of this study proved the key role of the sinus-membrane as the main carrier of bone-reformation after sinuslift-procedures as multiple experimental studies suggested. Thus the importance of minimal invasive and rupture free sinuslift procedures is underlined and does not depend on the type of grafting material used.

F. Riachi et al. investigated the influence of material properties on rate of resorption of two bone graft materials after sinus lift using radiographic assessment showing that the chemical and physical properties of bone graft material significantly influence resorption rate of bone graft materials used for sinus augmentation.

The aim of the study presented by S. Taschieri et al. was to systematically review the existing literature on transalveolar maxillary sinus augmentation without grafting materials and to propose and describe an osteotome-mediated approach in postextraction sites in combination with platelet derivative.

While transcrestal approach is considered more conservative than a lateral approach, the main drawback is that the main part of the sinus lifting procedure must be performed blindly because of the impossibility to visualize the sinus floor. Considering this limitation, the systematic review showed that high implant survival rate (more than 96% after 5 years) can be achieved even without grafting the site, with a low rate of complications. Available alveolar bone height before surgery was not correlated to survival rate. The osteotome-mediated sinus lifting technique was performed with the use of platelet derivative (PRGF). The presented

technique might represent a viable alternative for the treatment of edentulous atrophic posterior maxilla, more than 5 mm of residual bone height, of the alveolar bone though it needs to be validated by studies with a large sample size.

In general, sinus lifting through a lateral approach is a viable technique when less than 4-5 mm of residual bone height is present. When more than 5 mm of residual bone height is available a transalveolar approach, with or without adding bone substitute, or the insertion of short implant could be indicated as alternatives techniques in order to reduce the morbidity and the invasiveness of the treatment protocol. The choice of the most suitable technique among the three ones above mentioned depends on the sinus physiology, the patient's desire to attempt a long and challenging rehabilitation with respect to a shorter one and the patient's financial status.

The analysis of the data of the literature suggested that short implants, osteotome-mediated sinus floor elevation (with or without bone substitute) and lateral approach sinus floor elevation had similar clinical outcomes and appeared to be comparable. A wider literature was available for lateral approach sinus floor elevation while short implants should be supported by more well-designed studies with a detailed description of implant demographics.

## Acknowledgments

The guest editors would like to thank and acknowledge all the contributors (authors and coauthors), the reviewers, and the members of the Editorial Office of Hindawi Publishing Corporation for their valuable cooperation and assistance while preparing this issue.

*Silvio Taschieri  
Massimo Del Fabbro  
Igor Tsesis  
Stefano Corbella*



## Clinical Study

# Tilted Implants for Full-Arch Rehabilitations in Completely Edentulous Maxilla: A Retrospective Study

**Nicolò Cavalli, Bruno Barbaro, Davide Spasari,  
Francesco Azzola, Alberto Ciatti, and Luca Francetti**

*Department of Biomedical, Surgical and Dental Sciences, Oral Implantology Research Center, Università degli Studi di Milano, IRCCS Istituto Ortopedico Galeazzi, 20161 Milan, Italy*

Correspondence should be addressed to Nicolò Cavalli, cavalli.nicolo@gmail.com

Received 26 June 2012; Revised 5 September 2012; Accepted 26 September 2012

Academic Editor: Silvio Taschieri

Copyright © 2012 Nicolò Cavalli et al. This is an open access article distributed under the Creative Commons Attribution License, which permits unrestricted use, distribution, and reproduction in any medium, provided the original work is properly cited.

**Purpose.** The aims of this study were to assess the treatment outcome of immediately loaded full-arch fixed bridges anchored to both tilted and axially placed implants in the edentulous maxilla and to evaluate the incidence of biological and prosthetic complications. **Materials and Methods.** Thirty-four patients (18 women and 16 men) were included in the study. Each patient received a maxillary full-arch fixed bridge supported by two axial implants and two distal tilted implants. A total of 136 implants were inserted. Loading was applied within 48 hours of surgery and definitive restorations were placed 4 to 6 months later. Patients were scheduled for followup at 6, 12, 18, and 24 months and annually up to 5 years. At each followup plaque level and bleeding scores were assessed and every complication was recorded. **Results.** The overall follow-up range was 12 to 73 months (mean 38.8 months). No implant failures were recorded to date, leading to a cumulative implant survival rate of 100%. Biological complications were recorded such as alveolar mucositis (11.8% patients), peri-implantitis (5.9% patients), and temporomandibular joint pain (5.9% patients). The most common prosthetic complications were the fracture or detachment of one or multiple acrylic teeth in both the temporary (20.6% patients) and definitive (17.7% patients) prosthesis and the minor acrylic fractures in the temporary (14.7% patients) and definitive (2.9% patients) prosthesis. Hygienic complications occurred in 38.2% patients. No patients' dissatisfactions were recorded. **Conclusions.** The high cumulative implant survival rate indicates that this technique could be considered a viable treatment option. An effective recall program is important to early intercept and correct prosthetic and biologic complications in order to avoid implant and prosthetic failures.

## 1. Introduction

Several long-term prospective and retrospective studies reported high survival and success rates for implant-supported prosthesis for full-arch rehabilitations of atrophic jaws [1–3]. The described full-arch rehabilitations were supported by implants placed in the median region of jaws, between the two mental foramina in the mandible and between the mesial walls of maxillary sinus. They supported a full prosthesis with distal cantilevers.

In the atrophic maxilla, even though sinus augmentation procedures were described as effective in creating conditions for implant placement [4, 5], the occurrence of several complications was reported in the literature [6].

Tilted implants were suggested to be useful in the treatment of edentulous jaws avoiding the bone augmentation procedures and the involvement of anatomical structures during surgery [7]. Furthermore, tilting of distal implants in full-arch rehabilitation allows to reduce cantilever length and to augment the anteroposterior distance between the most anterior implant emergence and the most posterior ones with several prosthetic advantages [8, 9].

The All-on-Four surgical and prosthetic procedure was proposed to rehabilitate edentulous arches without any bone augmentation procedures, using distal tilted implants to obtain prosthetic and surgical advantages as described before [10, 11]. Tilted implants should be placed mesially or in direct contact with the mesial walls of the maxillary sinus,

without invasion or rupture of the Schneiderian membrane [12].

This procedure was validated by scientific literature in terms of implant success of survival both in short and in medium term, demonstrating that the use of tilted implants was not related to an increased bone resorption [9, 11, 13, 14].

The aim of this retrospective study was to investigate and present data about prosthetic and biological complications occurred in patients treated with full-arch maxillary rehabilitations supported by a combination of tilted and upright implants. Also implant survival rates were discussed and retrieved from clinical databases.

## 2. Materials and Methods

The Inclusion Criteria were as follows.

- (1) 18 years or older of any race and gender.
- (2) Patients in general good health condition, able to undergo surgical treatment and restorative procedures (ASA-1/ASA-2).
- (3) Completely edentulous maxilla or presence of teeth with an unfavorable long-term prognosis.
- (4) Adequate bone height and thickness in the region between the first premolars for the placement of implants at least 10 mm long and 4 mm wide.
- (5) Presence of extremely resorbed maxilla that would have needed bone augmentation for placing implants in a region posterior to the first premolars.
- (6) Patients who refused any kind of bone augmentation procedure.

The Exclusion Criteria were as follows.

- (1) Presence of acute infection at the implant site; hematologic diseases; serious problems of coagulation; diseases of the immune system; uncontrolled diabetes; metabolic diseases affecting bone; pregnancy or lactation.
- (2) Inadequate oral hygiene level (full-mouth plaque score and full-mouth bleeding score greater than 20%) and poor motivation to maintain good oral hygiene throughout the study.
- (3) Irradiation of the head or neck region or chemotherapy within the past 60 months.
- (4) Severe bruxism or clenching.

Participants were informed about the nature of the study and signed an informed consent.

Preliminary screening was performed using a careful clinical examination of the patient, panoramic orthopantomographs, computerized tomographic scans, accurate blood tests, electrocardiography, and cardiological examination. All included patients were scheduled to be followed for up to 6 years after loading.

**2.1. Surgical Protocol.** Patients received the following presurgical prophylactic drug therapy:

- (i) antibiotics, amoxicillin and clavulanic acid 2 g 1 hour before surgery,
- (ii) chlorhexidine digluconate 0.2% mouthwash starting 3 days before surgery.

All surgeries were performed under local anesthesia with articaine chlorohydrate with adrenaline 1 : 100,000 and intravenous sedation with diazepam.

A crestal incision was made starting in the first molar position. All hopeless teeth, if present, were extracted and sockets were carefully debrided. Where necessary, a regularization of the edentulous bone ridge was performed with rotating instruments and/or bone forceps. Each patient received four implants (Brånemark System MKIV or Nobel-Speedy Groovy, Nobel Biocare AB, Göteborg, Sweden) according to a previously described protocol (All-on-Four, Nobel Biocare AB, Göteborg, Sweden), with the the two distal implants tilted by approximately 30 degrees with respect to the occlusal plane and the two anterior implants axially inserted. To allow an immediate rehabilitation, each implant was inserted with a final torque of 40 to 50 Ncm. Multi-Unit Abutments (MUA, Nobel Biocare AB) were connected to the implants. On distal implants, abutments angulated 17 or 30 degrees with respect to the long axis of the fixture were positioned to obtain an optimal orientation for the prosthetic screw access, while straight abutments were placed over the anterior implants. An impression was taken utilizing a silicon putty polyvinylsiloxane directly on the coping. Then, four healing caps were placed upon the multiunit abutments.

Patients were discharged with the following postsurgical drug therapy:

- (i) antibiotics, amoxicillin and clavulanic acid 1 g every 12 hours for six days after surgery;
- (ii) analgesics, naproxen sodium 550 mg for the first three days from surgery;
- (iii) chlorhexidine digluconate 0.2% mouthwash for 7 days following surgery.

**2.2. Prosthetic Phase.** Within 48 h from surgery an acrylic temporary prostheses with 10 teeth and no cantilever was placed over the abutments. Screws were tightened over the MUA with a torque of 10 Ncm, following the manufacturer's instructions (Figure 1). All centric and lateral contacts were assessed by a 40 mm articulating paper and adjusted if necessary until they were present only between 33 and 43, according to the Maló protocol [10]. The screw access was then covered with provisional resin cement. After 6 months of loading, in the absence of pain and inflammatory signs, the patients received the final prosthesis (Figure 2). The definitive prosthesis was composed by a titanium framework fabricated by means of the CAD-CAM Procera system (Nobel Biocare AB), acrylic pink resin, and composite resin teeth (Figures 3, 4, and 5).

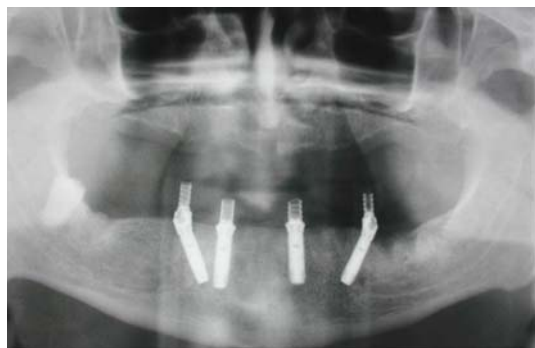

FIGURE 1: Pretreatment orthopantomography.

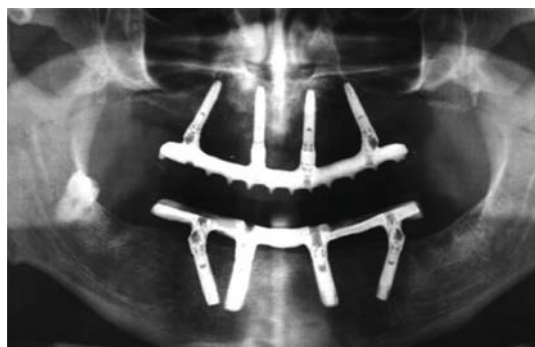

FIGURE 2: One year posttreatment orthopantomography.

**2.3. Followup and Data Collection.** The patients were scheduled for weekly control visits during the first month after surgery. During each visit, prosthetic functionality and tissue healing were evaluated. Every 3 months, oral hygiene level was evaluated. After definitive prosthesis delivery patients were scheduled for follow-up visit every 6 months for the first two years and yearly thereafter up to 6 years.

At each follow-up visit, mobility of the prosthetic structure and occlusion was checked, any prosthetic or biological complication was recorded, plaque level and bleeding score was assessed, and periapical radiographs using a paralleling technique and an individual X-ray holder were performed for evaluation of peri-implant bone level change over time.

### 3. Results

From April 2007 to April 2011, a total of 34 healthy patients (18 women and 16 men; mean age 58.7 years; range 44 to 84 years) were rehabilitated with an immediately loaded implant-supported fixed maxillary prosthesis supported by four implants. 19 patients were smokers (average daily consumption: 16.3 cigarettes per day), with 8 of them smoking 20 cigarettes per day or more.

A total of 136 implants were inserted (implants' length ranges from 10 mm to 15 mm; mean length 12.2 mm), of whom 68 with an axial inclination and 68 tilted by 30°. All implants had a diameter of 4 mm. All patients received the provisional prosthesis as planned within 48 hours of surgery.

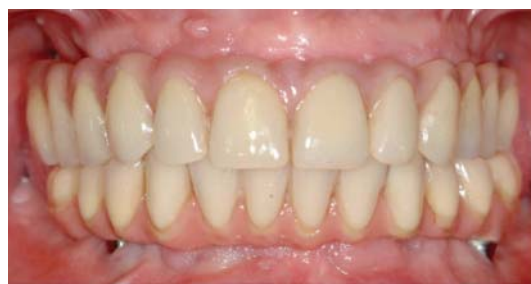

FIGURE 3: Frontal view of the definitive prosthesis.

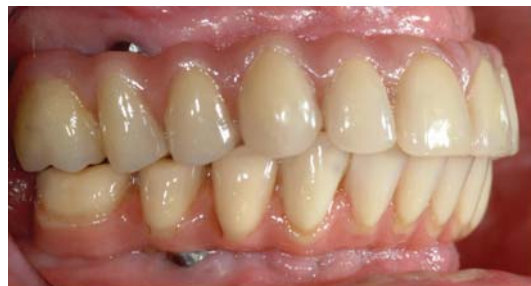

FIGURE 4: Lateral view of the definitive prosthesis.

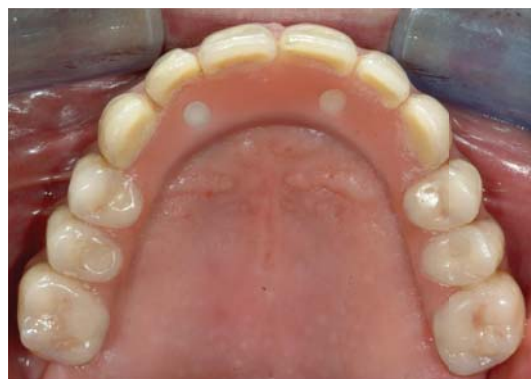

FIGURE 5: Occlusal view of the definitive prosthesis.

The follow-up range was from 12 to 73 months (mean 38.8 months).

Up to date no implant failures were recorded, so the cumulative implant survival rate was 100% (Table 1).

Complication incidence over time was showed in Table 2 and in Figure 6.

Biological complications were documented consisting in alveolar mucositis in 4 patients (11.76% patients), peri-implantitis in 2 patients (5.88% patients), and temporomandibular joint (TMJ) pain in 2 patients (5.88% patients). Both TMJ pain cases were solved after the adjustment of centric and lateral contacts.

The most common prosthetic complication was the fracture or detachment of one or more resin teeth that occurred in 10 patients (29.41% patients). In 7 patients it took place in the temporary prosthesis (20.59% patients) while in 6 patients in the definitive one (17.65% patients), in 3 of them happened in both. Minor acrylic resin fractures

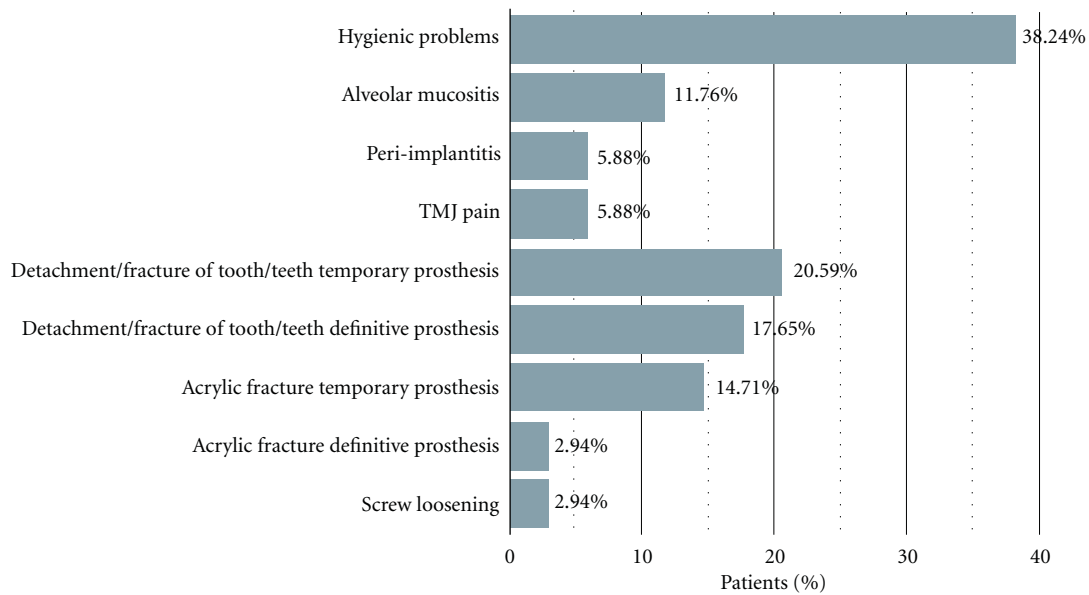


FIGURE 6: Graphical representation of the patient-related complication incidence.

TABLE 1: Cumulative survival rate.

Interval	Number of implants	Failed	CSR%
0–6 mo	136	0	100
6–12 mo	136	0	100
12–18 mo	132	0	100
18–24 mo	108	0	100
24–36 mo	108	0	100
36–48 mo	80	0	100
48–60 mo	36	0	100
60–72 mo	16	0	100

TABLE 2: Complication incidence over time.

Hygienic problems	38,24%
Al. mucositis	11,76%
Peri-implantitis	5,88%
TMJ pain	5,88%
Detachment/fracture of tooth/teeth in temporary prosthesis	20,59%
Detachment/fracture of tooth/teeth in definitive prosthesis	17,65%
Acrylic fracture in temporary prosthesis	14,71%
Acrylic fracture in definitive prosthesis	2,94%
Screw loosening	2,94%

of the temporary prosthesis occurred in 5 patients (14.72% patients) and in 1 of them also in the definitive prosthesis (2.94% patients).

Prosthetic screw loosening was recorded in one patient (2.94% patients). Twenty-one patients had no prosthetic complications (61.7% patients).

Hygienic problems were recorded in 13 patients (38.24% patients), but in most cases the patient was motivated to a better oral hygiene and the problem was solved without developing in alveolar mucositis or peri-implantitis. No patients' dissatisfaction was recorded.

#### 4. Discussion

In this study medium-term data about implant and prosthetic complications were reported from a cohort of patients treated following the All-on-Four protocol. All implants were functioning determining the 100% cumulative survival rate. However, some prosthetic or hygienic complication occurred in a relatively high number of patients (almost 30%).

In clinical records the most reported parameter to evaluate the effectiveness of an implant-supported rehabilitation is the survival rate, meaning whether the implant is still physically in the mouth or has been removed.

The commonly accepted criteria for the assessment of implant success were proposed by Albrektsson et al. [15].

Misch et al. in a consensus conference in 2007 [16] assessed as success parameters no pain in function, absence of observed clinical mobility, radiographic bone loss from surgery lower than 2 mm, and no exudates history.

In the present study the patient-related implant survival rated is 100%, while the patient-related implant success rate results were 94.22% because implants with peri-implantitis cannot be considered successful.

However those parameters seem no longer sufficient to assess the clinical efficiency of current implant prosthetic methodologies [17].

A number of studies reported implant survival rates for this type of rehabilitation in edentulous maxillas.

Recently some authors reported 98.96% of implant survival rate after 3 years from loading for 24 maxillary rehabilitations without any prosthetic complete failure [18].



Other authors reported good performances of this technique, in terms of implant survival rate and function in a large cohort of 276 patients, evaluated after 16 months from prosthesis placement [19].

A retrospective investigation performed by Babbush and coworkers described a 99.3% of implant survival rate for edentulous maxillas rehabilitated through the All-on-Four technique for up to 29 months of loading [14]. Also in this study the final prosthesis survival rate was 100%.

Another retrospective study, published by Malo et al. in 2011, reported data about 242 patients treated with a combination of two tilted and two upright implants [11]. Nineteen implants were lost in 17 patients, with a 5-year survival rate estimation of 93% and 98% at patient and implant level, respectively. Prosthesis survival rate was 100%.

Even though scientific literature reported, high survival rates for implants and prosthesis used in this type of rehabilitation, there is a lack of description of minor prosthetic and implant complications that may occur.

A recent review of the literature about rehabilitation of atrophic maxilla with tilted implants reported implant success rates varying from 91.3% to 100% for 666 axial implants and 92.1% to 100% for 782 tilted ones evaluating 319 patients [20]. Only few minor prosthetic complications were reported but there is a lack of description of such occurrence.

Fischer and Stenber reported a description of long-term complication for full-arch maxillary prosthesis supported by upright implants [21, 22]. No abutment or screw fractures were reported. Up to 82% of prosthesis experienced complications in the 10-year follow-up period, and the most common complication was tooth fracture (4.7 resin-related complications per prosthesis). Only 4% of metal frameworks fractured and 9% were remade after 10 years.

Other report on a large cohort of patients with mandibular rehabilitations reported that resin or veneer fractures were the most frequent complication after 15-year followup [23]. The same results were reported for maxillary restorations [24].

Considering prosthetic complications, other authors reported that the most common complications were prosthetic tooth fracture, tooth wear, maxillary hard relines, and screw complications in cases of mandibular restorations [25].

Also in the present study the most common prosthetic complication was the detachment of teeth, especially in the provisional restoration. In final restorations some resin-related complications were reported too. Such occurrences were easily solved within one week and did not cause major complications at implant level.

Hygienic complications were considered in the present study, because an early diagnosis of a problem in maintaining dental implant soft tissue health is necessary to reduce the prevalence of peri-implant diseases [26].

It has to be considered that the prevalence of peri-implant inflammatory disease has described to have a prevalence ranging from 50% to 90% of implants considering peri-implant mucositis (8–10 years) and from 12% to 43% of implants considering peri-implantitis (9–11 years) [27], and

so, a strict control of hygienic problems is mandatory in the long-term maintenance.

Another observation deriving from the results of the present report is that despite the relatively high rate of minor prosthetic or hygienic complication, all implants survived and no failures were reported. This confirmed that an effective recall program is important to individuate complications in the beginning avoiding the evolution of these in major complication that may lead to implant failure.

In conclusion, the present study showed that the use of angled implants to rehabilitate atrophic maxillas could be a viable alternative to bone augmentation procedures in the posterior area and allowed a good functional and aesthetic patients' satisfaction.

Prosthetic and biologic complication should be early intercepted and corrected to avoid implant and prosthetic failures.

## References

- [1] R. Adell, B. Eriksson, U. Lekholm, P. I. Brånemark, and T. Jemt, "Long-term follow-up study of osseointegrated implants in the treatment of totally edentulous jaws," *The International Journal of Oral & Maxillofacial Implants*, vol. 5, no. 4, pp. 347–359, 1990.
- [2] T. Jemt and J. Johansson, "Implant treatment in the edentulous maxillae: a 15-year follow-up study on 76 consecutive patients provided with fixed prostheses," *Clinical Implant Dentistry and Related Research*, vol. 8, no. 2, pp. 61–69, 2006.
- [3] P. Åstrand, J. Ahlqvist, J. Gunne, and H. Nilson, "Implant treatment of patients with edentulous jaws: a 20-year follow-up," *Clinical Implant Dentistry and Related Research*, vol. 10, no. 4, pp. 207–217, 2008.
- [4] S. S. Wallace and S. J. Froum, "Effect of maxillary sinus augmentation on the survival of endosseous dental implants. A systematic review," *Annals of Periodontology*, vol. 8, no. 1, pp. 328–343, 2003.
- [5] M. Del Fabbro, G. Rosano, and S. Taschieri, "Implant survival rates after maxillary sinus augmentation," *European Journal of Oral Sciences*, vol. 116, no. 6, pp. 497–506, 2008.
- [6] A. Katranji, P. Fotek, and H. L. Wang, "Sinus augmentation complications: etiology and treatment," *Implant Dentistry*, vol. 17, no. 3, pp. 339–349, 2008.
- [7] L. Krekmanov, M. Kahn, B. Rangert, and H. Lindström, "Tilting of posterior mandibular and maxillary implants for improved prosthesis support," *International Journal of Oral and Maxillofacial Implants*, vol. 15, no. 3, pp. 405–414, 2000.
- [8] C. M. Bellini, D. Romeo, F. Galbusera et al., "A finite element analysis of tilted versus nontilted implant configurations in the edentulous Maxilla," *International Journal of Prosthodontics*, vol. 22, no. 2, pp. 155–157, 2009.
- [9] L. Francetti, D. Romeo, S. Corbella, S. Taschieri, and M. Del Fabbro, "Bone level changes around axial and tilted implants in full-arch fixed immediate restorations. Interim results of a prospective study," *Clinical Implant Dentistry and Related Research*, vol. 14, no. 5, pp. 646–654, 2012.
- [10] P. Maló, B. Rangert, and M. Nobre, "All-on-4 immediate-function concept with Branemark system implants for completely edentulous maxillae: a 1-year retrospective clinical study," *Clinical Implant Dentistry and Related Research*, vol. 7, no. 1, supplement, pp. S88–S94, 2005.

- [11] P. Maló, M. de Araújo Nobre, A. Lopes, C. Francischone, and M. Rigolizzo, "All-on-4" immediate-function concept for completely edentulous maxillae: a clinical report on the medium (3 years) and long-term (5 years) outcomes," *Clinical Implant Dentistry and Related Research*, vol. 14, no. 1, pp. e139–e150, 2012.
- [12] O. T. Jensen, M. W. Adams, J. R. Cottam, S. M. Parel, and W. R. Phillips, "The all-on-4 shelf: maxilla," *Journal of Oral and Maxillofacial Surgery*, vol. 68, no. 10, pp. 2520–2527, 2010.
- [13] L. Francetti, E. Agliardi, T. Testori, D. Romeo, S. Taschieri, and M. D. Fabbro, "Immediate rehabilitation of the mandible with fixed full prosthesis supported by axial and tilted implants: interim results of a single cohort prospective study," *Clinical Implant Dentistry and Related Research*, vol. 10, no. 4, pp. 255–263, 2008.
- [14] C. A. Babbush, G. T. Kutsko, and J. Brokloff, "The all-on-four immediate function treatment concept with NobelActive implants: a retrospective study," *The Journal of Oral Implantology*, vol. 37, no. 4, pp. 431–445, 2011.
- [15] T. Albrektsson, G. Zarb, P. Worthington, and A. R. Eriksson, "The long-term efficacy of currently used dental implants: a review and proposed criteria of success," *The International Journal of Oral & Maxillofacial Implants*, vol. 1, no. 1, pp. 11–25, 1986.
- [16] C. E. Misch, M. L. Perel, H. L. Wang et al., "Implant success, survival, and failure: the International Congress of Oral Implantologists (ICOI) pisa consensus conference," *Implant Dentistry*, vol. 17, no. 1, pp. 5–15, 2008.
- [17] P. Papaspyridakos, C. J. Chen, M. Singh, H. P. Weber, and G. O. Gallucci, "Success criteria in implant dentistry: a systematic review," *Journal of Dental Research*, vol. 91, no. 3, pp. 242–248, 2012.
- [18] R. Crespi, R. Vinci, P. Capparé, G. E. Romanos, and E. Gherlone, "A clinical study of edentulous patients rehabilitated according to the "all on four" immediate function protocol," *The International Journal of Oral & Maxillofacial Implants*, vol. 27, no. 2, pp. 428–434, 2012.
- [19] S. Graves, B. A. Mahler, B. Javid, D. Armellini, and O. T. Jensen, "Maxillary all-on-four therapy using angled implants: a 16-month clinical study of 1110 implants in 276 jaws," *Dental Clinics of North America*, vol. 55, no. 4, pp. 779–794, 2011.
- [20] D. Penarrocha-Oltra, E. Candel-Marti, J. Ata-Ali, and M. Penarrocha, "Rehabilitation of the atrophic maxilla with tilted implants: review of the literature," *The Journal of Oral Implantology*. In press.
- [21] K. Fischer and T. Stenberg, "Prospective 10-year cohort study based on a Randomized Controlled Trial (RCT) on implant-supported full-arch maxillary prostheses—part 1: sandblasted and acid-etched implants and mucosal tissue," *Clinical Implant Dentistry and Related Research*. In press.
- [22] K. Fischer and T. Stenberg, "Prospective 10-year cohort study based on a Randomized Controlled Trial (RCT) on implant-supported full-arch maxillary prostheses—part 2: prosthetic outcomes and maintenance," *Clinical Implant Dentistry and Related Research*. In press.
- [23] A. Örtorp and T. Jemt, "Early laser-welded titanium frameworks supported by implants in the edentulous mandible: a 15-year comparative follow-up study," *Clinical Implant Dentistry and Related Research*, vol. 11, no. 4, pp. 311–322, 2009.
- [24] T. Jemt, B. Bergendal, K. Arvidson et al., "Implant-supported welded titanium frameworks in the edentulous maxilla: a 5-year prospective multicenter study," *International Journal of Prosthodontics*, vol. 15, no. 6, pp. 544–548, 2002.
- [25] B. A. Purcell, E. A. McGlumphy, J. A. Holloway, and F. M. Beck, "Prosthetic complications in mandibular metal-resin implant-fixed complete dental prostheses: a 5- to 9-year analysis," *International Journal of Oral and Maxillofacial Implants*, vol. 23, no. 5, pp. 847–857, 2008.
- [26] S. Corbella, M. Del Fabbro, S. Taschieri, F. De Siena, and L. Francetti, "Clinical evaluation of an implant maintenance protocol for the prevention of peri-implant diseases in patients treated with immediately loaded full-arch rehabilitations," *International Journal of Dental Hygiene*, vol. 9, no. 3, pp. 216–222, 2011.
- [27] N. U. Zitzmann and T. Berglundh, "Definition and prevalence of peri-implant diseases," *Journal of Clinical Periodontology*, vol. 35, no. 8, supplement, pp. 286–291, 2008.

## Research Article

# Prevention and Treatment of Postoperative Infections after Sinus Elevation Surgery: Clinical Consensus and Recommendations

**Tiziano Testori,<sup>1</sup> Lorenzo Drago,<sup>2</sup> Steven S. Wallace,<sup>3</sup> Matteo Capelli,<sup>1</sup> Fabio Galli,<sup>1</sup> Francesco Zuffetti,<sup>1</sup> Andrea Parenti,<sup>1</sup> Matteo Deflorian,<sup>1</sup> Luca Fumagalli,<sup>1</sup> Roberto L. Weinstein,<sup>4</sup> Carlo Maiorana,<sup>5</sup> Danilo Di Stefano,<sup>6</sup> Pascal Valentini,<sup>7</sup> Aldo B. Gianni,<sup>8</sup> Matteo Chiapasco,<sup>9</sup> Raffaele Vinci,<sup>10</sup> Lorenzo Pignataro,<sup>11</sup> Mario Mantovani,<sup>11</sup> Sara Torretta,<sup>11</sup> Carlotta Pipolo,<sup>12</sup> Giovanni Felisati,<sup>12</sup> Giovanni Padoan,<sup>13</sup> Paolo Castelnuovo,<sup>13</sup> Roberto Mattina,<sup>14</sup> and Massimo Del Fabbro<sup>15</sup>**

<sup>1</sup>Section of Implant Dentistry and Oral Rehabilitation, Department of Biomedical, Surgical and Dental Science, School of Dentistry, I.R.C.C.S. Galeazzi Institute, University of Milan, Via Riccardo Galeazzi 4, 20161 Milan, Italy

<sup>2</sup>Laboratory of Clinical Chemistry and Microbiology, I.R.C.C.S. Galeazzi Institute, University of Milan, Milan, Italy

<sup>3</sup>Department of Implantology, Columbia University, New York, NY, USA

<sup>4</sup>Department of Biomedical, Surgical and Dental Science, School of Dentistry, I.R.C.C.S. Galeazzi Institute, University of Milan, Milan, Italy

<sup>5</sup>Department of Oral Surgery, Dental Clinic, School of Dentistry, Istituti Clinici di Perfezionamento (ICP), University of Milan, Milan, Italy

<sup>6</sup>Oral Surgery, Department of Oral Science, University Vita-San Raffaele Salute, Milan, Italy

<sup>7</sup>Department of Oral Implantology, University of Corsica Pasquale Paoli, Corte, France

<sup>8</sup>Department of Maxillofacial Surgery, University of Milan and Fondazione IRCCS Cà Granda, Ospedale Maggiore Policlinico, Milan, Italy

<sup>9</sup>Department of Oral Surgery, School of Dental Medicine, Department of Medicine, Surgery and Dentistry, San Paolo Hospital, University of Milan, Milan, Italy

<sup>10</sup>Division of Advanced Oral Surgery, Department of Dental Medicine, University Vita-Salute, San Raffaele, Milan, Italy

<sup>11</sup>Otorhinolaryngology Clinic, Department of Otorhinolaryngoiatric Sciences, Fondazione IRCCS Cà Granda, Ospedale Maggiore Policlinico, Milan, Italy

<sup>12</sup>Head and Neck Department, San Paolo Hospital, University of Milan, Milan, Italy

<sup>13</sup>Department of Surgical Sciences, University of Insubria, Varese, Italy

<sup>14</sup>Department of Public Health, Microbiology and Virology, University of Milan, Milan, Italy

<sup>15</sup>Section of Oral Physiology, Department of Biomedical, Surgical and Dental Science, I.R.C.C.S. Galeazzi Institute, University of Milan, Milan, Italy

Correspondence should be addressed to Tiziano Testori, [tiziano.testori@unimi.it](mailto:tiziano.testori@unimi.it)

Received 7 May 2012; Accepted 6 June 2012

Academic Editor: Silvio Taschieri

Copyright © 2012 Tiziano Testori et al. This is an open access article distributed under the Creative Commons Attribution License, which permits unrestricted use, distribution, and reproduction in any medium, provided the original work is properly cited.

**Introduction.** Maxillary sinus surgery is a reliable and predictable treatment option for the prosthetic rehabilitation of the atrophic maxilla. Nevertheless, these interventions are not riskless of postoperative complications with respect to implant positioning in pristine bone. **Aim.** The aim of this paper is to report the results of a clinical consensus of experts (periodontists, implantologists, maxillofacial surgeons, ENT, and microbiology specialists) on several clinical questions and to give clinical recommendations on how to prevent, diagnose, and treat postoperative infections. **Materials and Methods.** A panel of experts in different fields of dentistry and medicine, after having reviewed the available literature on the topic and taking into account their long-standing clinical experience, gave their response to a series of clinical questions and reached a consensus. **Results and Conclusion.** The incidence of postop infections is relatively low (2%–5.6%). A multidisciplinary approach is advisable. A list of clinical recommendation are given.

## 1. Introduction

Maxillary sinus surgery can be defined as a routine and predictable procedure for the prosthetic rehabilitation in the atrophic maxilla [1–7].

In the past, implant treatment was applied to total edentulous patients [8, 9] and was later extended to partially edentulous patients; however, the resorption of the alveolar ridges in the maxilla often limits the available bone for positioning dental implants unless a reconstructive phase was performed and different classifications of bone atrophy and relative treatments protocols were proposed [10–12].

Management of patients undergoing sinus lift procedure often requires an interdisciplinary approach involving various specialists in the presurgical phase to optimize surgical results and reduce complications [13–15].

There are anatomic alterations and pathological conditions such as inflammatory-infective processes or sinus manifestations of systemic or cancer related diseases that represent contraindications and should be treated prior to maxillary sinus elevation [16, 17].

Complications are infrequent and can be easier managed if promptly diagnosed.

Postoperative infections are relatively infrequent, with infection rates reported between 2% and 5.6%, with no distinction being made between true sinus and sinus graft infections.

Infections after sinus elevation surgery can occur in two locations. Most commonly the infection is not a true sinus infection but an infected sinus graft. It should be realized that the sinus graft is not actually in the sinus but is located below the elevated sinus membrane, hence the term subantral augmentation. True sinus infections are less common but may have more widespread consequences such as a pansinusitis which can occur as a result of the interconnectivity of the sinus network [18–22].

The aim of this paper is to report the results of a clinical consensus of experts (periodontists, implantologist, maxillofacial surgeons, ENT, and microbiology specialists) on several clinical questions and to give clinical recommendations on how to prevent, diagnose and treat postoperative infections.

The clinical questions addressed by the panel of experts are as follows.

- (1) What is the normal postoperative patient response to sinus surgery?
- (2) What is the correct preop and postop pharmacological treatment after sinus surgery?
- (3) In case of persistence of signs and symptoms beyond 3 weeks, what are the proper clinical recommendations?
- (4) What is the difference between early and delayed complication?
- (5) (a) Which postop infections can be managed only with pharmacological treatment? (b) Which postop infections require a combined pharmacological and surgical approach?
- (6) What are the clinical indications for a microbiologic assay?
- (7) In case of surgical management of postoperative infections, is a reentry possible and how long should the surgeon wait?
- (8) What are the most appropriate clinical recommendations to reduce the incidence of postop complications?

## 2. Materials and Methods

A panel of experts in different fields of dentistry and medicine like periodontists, implantologists, maxillofacial surgeons, ENT, and microbiology specialists after having reviewed the available literature on the topic and taking into account their long standing clinical experience gave their response to the above mentioned questions and reached a clinical consensus.

## 3. Results

(1) *What Is the Normal Postoperative Patient Response to Sinus Surgery?* A normal postoperative patient's response could be swelling, ecchymosis, and mild-to-moderate discomfort that is rarely spontaneous within the first few days and usually resolves within three weeks. Minor nose bleed might be present.

The resolution of symptoms after three weeks suggest a normal postop period. Usually acute spontaneous pain is absent; however, if present it is a warning sign for the clinician to investigate promptly.

(2) *What Is the Correct Preop and Postop Pharmacological Treatment after Sinus Surgery?* Usually sinus surgery is a surgical procedure carried out under antibiotic prophylaxis and postoperative drug therapy as seen in Table 1. This pharmacological regimen is based on clinical experience and indirect evidence. In implant dentistry, there is a trend that favor the use of prophylactic antibiotics to reduce infections [23, 24].

With regard to preop or postoperative corticosteroid therapy, a common consensus was reached regarding the use of corticosteroid but not on the dosage due to the heterogeneity of the pharmacological regimens utilized by the different experts.

(3) *In Case of Persistence of Signs and Symptoms beyond 3 Weeks, What Are the Proper Clinical Recommendations?* The presence of signs and symptoms beyond three weeks calls for a careful examination and monitoring of the patient until total recovery.

If the patient has not fully recovered after 3 weeks, CT is suggested to evaluate maxillary sinuses, nasal, and sinus endoscopy can be added if necessary.

(4) *What Is the Difference between Early and Delayed Complication?* Early complication happens within 21 days following surgery.



TABLE 1: Prophylaxis and post-operative drug therapy in sinus lift patient.

	Prophylaxis	Post-operative therapy
Patient not allergic to penicillin	Amoxicillin/clavulanic acid 1 gr twice a day (BID) per os starting 24 hours before surgery	Amoxicillin/clavulanic acid 1 gr three times a day (TID) per os for 7 days
Patient allergic to penicillin	Clarithromycin 250 mg BID + Metronidazole 500 TID per os starting 24 hours before surgery	Clarithromycin 250 mg BID + Metronidazole 500 TID per os for 7 days

TABLE 2: Drug therapy for sinus lift complications.

Patient not allergic to penicillin	Amoxicillin/clavulanic acid 1 gr TID and Metronidazole 500 mg TID per os
Patient allergic to penicillin	Levofloxacin 400 mg BID per os until 72 hours to symptom remission
Usually these regimens are utilized for 7–10 days	

Delayed complication sets in more than 21 days after the surgery.

A clear distinction between early and delayed complications allows a time-related assessment of the complication. This classification is useful in communicating among clinicians and writing scientific papers.

(5a) *Which Postop Infection Can Be Managed Only with Pharmacological Treatment?* Graft infection well contained under the sinus membrane, as seen in the scan, with only a clean serum exudate from the surgical incision can be managed only with pharmacological treatment (Table 2).

A strict monitoring of the patient is needed until resolution of the complication.

(5b) *Which Postop Infection Require a Combined Pharmacological and Surgical Approach?* If the graft is well contained under the schneiderian membrane (as seen in the CT scans) but signs and symptoms still persist beyond 3 weeks associated with additional symptoms (like tenderness, nasal obstruction, pain, fistulization, purulent discharge from the nose and throat, flap dehiscence, and suppuration), partial or total removal of the bone graft by oral access combined to pharmacological therapy is recommended.

If the graft is not contained under the sinus membrane and a loss of graft material inside the sinus is present (as seen in the CT scans) a multidisciplinary approach to manage the complication is mandatory. Functional endoscopic sinus surgery (FESS) could be suggested along with the removal of bone graft and dental implants from an oral approach [25].

A quick and multidisciplinary approach to the patient with sinus complications is required in these clinical scenarios.

(6) *What Are the Clinical Indications for a Microbiologic Assay?* Microbiologic assay is always suggested but a negative result (bacteria absence) does not mean absence of infection. Usually during antibiotic therapy, bacterial cultures are negative.

If possible it is recommended to make a second test some days after the end of the pharmacological therapy.

The indications to request a microbiologic assay have to be evaluated in relation to the antibiotic response in term of days versus recovery speed, seriousness of the complication, and general patient condition. A close patient monitoring is always advised.

(7) *In Case of Surgical Management of a Postoperative Infection, Is a Reentry Possible and How Long Should the Surgeon Wait?* A sinus reentry is possible after a CT evaluation and preferably an ENT reevaluation to confirm a complete sinus healing (which on the average requires 6–9 months).

(8) *What Are the Most Appropriate Clinical Recommendations to Reduce the Incidence of Postop Complications?* The clinical recommendation are as follows:

- (i) careful assessment of the medical history of the patient,
- (ii) proper patient selection with healthy maxillary sinus,
- (iii) to take a pre-operative CT scan to evaluate sinus anatomy and identify preexisting pathology,
- (iv) a smoking cessation protocol is always recommended and, especially in case of heavy smokers ( $\geq 15$  cigarettes a day), evaluated with caution [26],
- (v) preventive resolution of periodontal and endodontic diseases,
- (vi) adequate antibiotic prophylaxis,
- (vii) to achieve full mouth plaque score (FMPS) and full mouth bleeding score (FMB5)  $< 15\%$ . In case of provisional crowns it is advisable to remove the temporary crowns and disinfect the abutments with antiseptic solution,
- (viii) preop disinfection of the skin with an antiseptic solution and mouth rinses with chlorhexidine,
- (ix) use of sterile draping and infection-control protocol,
- (x) to keep the incision distant from the antrotomy,
- (xi) salivary-contamination prevention for bone graft and/or other biomaterials,
- (xii) intra- and postoperative control of the hemostasis,
- (xiii) prevention of bone overheating,
- (xiv) use of two different surgical sets of instruments: one for the flap elevation phase and the other for the grafting phase,

- (xv) to rinse the surgical field with sterile saline solution,
- (xvi) to keep the surgical time as short as possible,
- (xvii) postoperative chlorhexidine rinses,
- (xviii) correct postoperative pharmacological therapy,
- (xix) preplanned patient controls: weekly for the first month and monthly for the following 3 months.

#### 4. Conclusion

The maxillary sinus elevation procedure using a lateral window approach has been shown to be the most successful bone augmentation procedure that is performed as a pre-prosthetic procedure before implant placement [5]. When success is measured by patient outcome (success of the grafting procedure), the excellent result rate achieved is due to the fact that complications are minimal and possibly further on prevented through proper case selection, good surgical technique, and proper and prompt handling of intraoperative and postoperative complications. Properly performed sinus grafting does not alter neither sinus function [13] nor the characteristics of the voice [25]. When measured by implant outcome (implant survival rate), it has been shown that implant survival rates in the high 90th percentile can be achieved through proper decision making with regard to implant surfaces (textured), graft materials (highest survival with xenografts), and the placement of a barrier membrane over the window. Complications are infrequent and those that occur after sinus grafting procedures are for the most part localized and readily resolved. Since prevention is better than treatment, the clinical recommendations given by the panel will help in reducing the incidence of the postop infections.

#### References

- [1] O. T. Jensen, L. B. Shulman, M. S. Block, and V. J. Lacono, "Report of the sinus consensus conference of 1996," *International Journal of Oral and Maxillofacial Implants*, vol. 13, supplement, pp. 11–34, 1998.
- [2] S. S. Wallace and S. J. Froum, "Effect of maxillary sinus augmentation on the survival of endosseous dental implants. A systematic review," *Annals of Periodontology*, vol. 8, no. 1, pp. 328–343, 2003.
- [3] M. Del Fabbro, T. Testori, L. Francetti, and R. Weinstein, "Systematic review of survival rates for implants placed in the grafted maxillary sinus," *International Journal of Periodontics and Restorative Dentistry*, vol. 24, no. 6, pp. 565–577, 2004.
- [4] M. Del Fabbro, G. Rosano, and S. Taschieri, "Implant survival rates after maxillary sinus augmentation," *European Journal of Oral Sciences*, vol. 116, no. 6, pp. 497–506, 2008.
- [5] T. L. Aghaloo and P. K. Moy, "Which hard tissue augmentation techniques are the most successful in furnishing bony support for implant placement?" *International Journal of Oral and Maxillofacial Implants*, vol. 22, supplement, pp. 49–70, 2007, Erratum in *International Journal of Oral and Maxillofacial Implants*, vol. 23, no. 1, article 56, 2008.
- [6] B. E. Pjetursson, W. C. Tan, M. Zwahlen, and N. P. Lang, "A systematic review of the success of sinus floor elevation and survival of implants inserted in combination with sinus floor elevation: part I: lateral approach," *Journal of Clinical Periodontology*, vol. 35, no. 8, pp. 216–240, 2008.
- [7] M. Chiapasco, P. Casentini, and M. Zaniboni, "Bone augmentation procedures in implant dentistry," *The International Journal of Oral & Maxillofacial Implants*, vol. 24, pp. 237–259, 2009.
- [8] P. I. Brånemark, B. O. Hansson, R. Adell et al., "Osseointegrated implants in the treatment of the edentulous jaw. Experience from a 10-year period," *Scandinavian Journal of Plastic and Reconstructive Surgery. Supplementum*, vol. 16, pp. 1–132, 1977.
- [9] R. Adell, U. Lekholm, B. Rockler, and P. I. Brånemark, "A 15-year study of osseointegrated implants in the treatment of the edentulous jaw," *International Journal of Oral Surgery*, vol. 10, no. 6, pp. 387–416, 1981.
- [10] T. Testori and S. S. Wallace, "Surgical procedures—lateral windows approach," in *Maxillary Sinus Surgery and Alternatives*, T. Testori, M. Del Fabbro, R. Weinstein, and S. Wallace, Eds., pp. 218–238, Quintessence Publishing, Chicago, Ill, USA, 2009.
- [11] M. Chiapasco, M. Zaniboni, and L. Rimondini, "Dental implants placed in grafted maxillary sinuses: a retrospective analysis of clinical outcome according to the initial clinical situation and a proposal of defect classification," *Clinical Oral Implants Research*, vol. 19, no. 4, pp. 416–428, 2008.
- [12] A. B. Gianni, R. Monteverdi, A. Baj, and F. Carlino, "Atrophy of the maxilla: classification and protocols," in *Maxillary Sinus Surgery and Alternatives*, T. Testori, M. Del Fabbro, R. Weinstein, and S. Wallace, Eds., pp. 114–156, Quintessence Publishing, Chicago, Ill, USA, 2009.
- [13] N. M. Timmenga, G. M. Raghoobar, G. Boering, and R. Van Weissenbruch, "Maxillary sinus function after sinus lifts for the insertion of dental implants," *Journal of Oral and Maxillofacial Surgery*, vol. 55, no. 9, pp. 936–940, 1997.
- [14] L. Pignataro, M. Mantovani, S. Torretta, G. Felisati, and G. Sambataro, "ENT assessment in the integrated management of candidate for (maxillary) sinus lift," *Acta Otorhinolaryngologica Italica*, vol. 28, no. 3, pp. 110–119, 2008.
- [15] S. Torretta, M. Mantovani, T. Testori, M. Cappadonna, and L. Pignataro, "Importance of ENT assessment in stratifying candidates for sinus floor elevation: a prospective clinical study," *Clinical Oral Implants Research*, 2011. In press.
- [16] M. Mantovani, "Otolaryngological contraindications in augmentation of the maxillary sinus," in *Maxillary Sinus Surgery and Alternatives*, T. Testori, M. Del Fabbro, R. Weinstein, and S. Wallace, Eds., pp. 42–52, Quintessence Publishing, Chicago, Ill, USA, 2009.
- [17] G. Padoan, T. Testori, F. Galli, A. Petrosino, S. Gallo, and P. Castelnovo, "Role of endoscopic rehabilitation of the ostio-meatal complex (FESS) in maxillary sinus surgery," *Italian Oral Surgery*, 2011.
- [18] V. B. Ziccardi and N. J. Betts, "Complications of maxillary sinus augmentation," in *The Sinus Bone Graft*, O. T. Jensen, Ed., pp. 201–208, Quintessence, Chicago, Ill, USA, 1999.
- [19] S. A. Zijdeveld, J. P. A. van den Bergh, E. A. J. M. Schulten, and C. M. ten Bruggenkate, "anatomical and surgical findings and complications in 100 consecutive maxillary sinus floor elevations," *Journal of Oral and Maxillofacial Surgery*, vol. 66, no. 7, pp. 1426–1438, 2008.
- [20] D. Schwartz-Arad, R. Herzberg, and E. Dolev, "The prevalence of surgical complications of the sinus graft procedure and their impact on implant survival," *Journal of Periodontology*, vol. 75, no. 4, pp. 511–516, 2004.

- [21] A. Barone, S. Santini, L. Sbordone, R. Crespi, and U. Covani, "A clinical study of the outcomes and complications associated with maxillary sinus augmentation," *International Journal of Oral and Maxillofacial Implants*, vol. 21, no. 1, pp. 81–85, 2006.
- [22] S. S. Wallace, "Complication in lateral window sinus elevation surgery," in *Dental Implant Complications*, S. J. Froum, Ed., pp. 284–309, Wiley-Blackwell, Oxford, UK, 2010.
- [23] M. Esposito, G. Cannizarro, P. Bozzoli et al., "Effectiveness of prophylactic antibiotics at placement of dental implants: a pragmatic multicentre placebo-controlled randomised clinical trial," *European Journal of Oral Implantology*, vol. 3, no. 2, pp. 135–143, 2010.
- [24] M. Esposito, M. G. Grusovin, V. Loli, P. Coulthard, and H. V. Worthington, "Does antibiotic prophylaxis at implant placement decrease early implant failures? A Cochrane systematic review," *European Journal of Oral Implantology*, vol. 3, no. 2, pp. 101–110, 2010.
- [25] M. Chiapasco, G. Felisati, A. Maccari, R. Borloni, F. Gatti, and F. Di Leo, "The management of complications following displacement of oral implants in the paranasal sinuses: a multicenter clinical report and proposed treatment protocols," *The International Journal of Oral and Maxillofacial Surgery*, vol. 38, no. 12, pp. 1273–1278, 2009.
- [26] T. Testori, T. Weinstein, F. Bianchi et al., "Analysis of risk factors in implant therapy following maxillary sinus augmentation: a retrospective multicenter study," *The International Journal of Oral & Maxillofacial Implants*, 2012. In press.

## Research Article

# Influence of Material Properties on Rate of Resorption of Two Bone Graft Materials after Sinus Lift Using Radiographic Assessment

Fawzi Riachi,<sup>1</sup> Nada Naaman,<sup>2</sup> Carine Tabarani,<sup>1</sup> Nayer Aboelsaad,<sup>3</sup>  
Moustafa N. Aboushelib,<sup>4</sup> Antoine Berberi,<sup>5</sup> and Ziad Salameh<sup>5</sup>

<sup>1</sup> Department of Oral Surgery, Faculty of Dental Medicine, Saint Joseph University, P.O. Box 17-5208, Beirut 1104-2020, Lebanon

<sup>2</sup> Department of Periodontology, Faculty of Dental Medicine, Saint Joseph University, P.O. Box 17-5208, Beirut 1104-2020, Lebanon

<sup>3</sup> Periodontology Department, Faculty of Dentistry, Beirut Arab University, P.O. Box 115020 Rial el Solh, 1107 Beirut, Lebanon

<sup>4</sup> Dental Biomaterials Department, Faculty of Dentistry, Alexandria University, Alexandria, Egypt

<sup>5</sup> Research Department, School of Dental Medicine, Lebanese University, P.O. Box 4 Hadath, Lebanon

Correspondence should be addressed to Ziad Salameh, drzsalameh@gmail.com

Received 25 May 2012; Accepted 24 June 2012

Academic Editor: Silvio Taschieri

Copyright © 2012 Fawzi Riachi et al. This is an open access article distributed under the Creative Commons Attribution License, which permits unrestricted use, distribution, and reproduction in any medium, provided the original work is properly cited.

**Purpose.** The aim of this study was to investigate the influence of chemical and physical properties of two graft materials on the rate of resorption. **Materials and Methods.** Direct sinus graft procedure was performed on 22 patients intended for implant placement. Two types of graft materials were used (Bio-Oss and Cerabone) and after 8 months healing time the implants were inserted. Radiographic assessment was performed over the period of four years. Particle size, rate of calcium release, and size and type of crystal structure of each graft were evaluated. **Results.** The average particle size of Bio-Oss (1 mm) was much smaller compared to Cerabone (2.7 mm). The amount of calcium release due to dissolution of material in water was much higher for Bio-oss compared to Cerabone. X-ray image analysis revealed that Bio-Oss demonstrated significantly higher volumetric loss ( $33.4 \pm 3.1\%$ ) of initial graft size compared to Cerabone ( $23.4 \pm 3.6\%$ ). The greatest amount of vertical loss of graft material volume was observed after one year of surgery. **Conclusion.** The chemical and physical properties of bone graft material significantly influence resorption rate of bone graft materials used for sinus augmentation.

## 1. Introduction

Maxillary sinus augmentation and placement of dental implants is a well-established technique for functional and esthetic rehabilitation of partially or completely edentulous patients with severe maxillary atrophy. Sinus pneumatization, together with poor bone quality, is one of the most challenging circumstances in implantology, a condition that will restrict implant placement in such areas. When this situation occurs, bone grafts can be used to correct bone deficits, allowing the placement of implants of adequate length and width [1]. The first report about maxillary sinus floor augmentation for placement of implants was published by Boyne and James [2], while Tatum [3] first described two techniques with a sinus approach from the alveolar crest and lateral wall in maxillary and sinus implant reconstruction.

There are diverse choices of graft materials available for replacing lost bone through atrophy, trauma, congenital or pathological processes. These graft materials include: intra or extraoral autologous bone, heterologous grafts, alloplastic grafts, xenografts or a combination of these [4]. In general, the success of a bone graft is measured in terms of its capacity to withstand the conditions of tension and mechanical deformation to which it is subjected. The interactions between graft material and healing processes at the host site have a direct influence on the pattern, rate, and quality of new bone formation. Successful grafts are those that undergo revascularization and substitution of the graft material by host bone, without suffering a significant loss of mechanical strength or graft volume [5, 6].

Clinical and histomorphometric studies done on autografts, bovine hydroxyapatite (Bio-Oss, Geistlich),



a xenograft and  $\beta$ -tricalciumphosphate (Cerasorb, Curasan), an alloplast, prove that all these grafting materials are bio-compatible, osseoconductive and can be used successfully in conjunction during implant rehabilitation [7, 8]. However, rate of resorption of these materials is dependent on their chemical and physical properties. Frenken et al. [9] evaluated the quantity and quality of bone formed in sinus augmentations using a synthetic material: biphasic calcium phosphate consisting of a combination of 60% hydroxyapatite and 40%  $\beta$ -tricalcium phosphate. Histological findings reported differences in the amount of newly formed bone used with each material.

The aim of this study was to evaluate the influence of chemical and physical properties of two types of bone graft materials on the rate of resorption after placement in sinus lift procedure over a period of four years.

## 2. Materials and Methods

This study was conducted in coherence with the Helsinki agreement for research on humans and the study design was approved by the Institutional Review Board and Independent Ethics Committee of the Faculty of Dental Medicine, Saint Joseph University, Beirut, Lebanon. Signed informed consent forms were obtained for all participants in the study.

Two xenograft materials prepared by deproteinizing technique (Bio-Oss, Geistlich Sons Ltd., Wolhusen, Switzerland) or high temperature decalcified freeze-dried (Cerabone, Botiss Dental, Berlin, Germany) were selected for this study.

**2.1. Characterization of the Graft Materials.** The particle size of each graft material was calculated using particle size analyzer (Partica LA-950V2, Horiba Scientific, Kyoto, Japan), and average particle size and distribution were calculated from 5 different batches for each material.

Crystal structure and size of crystals were calculated using X-ray diffraction (XRD) technique. 5 gram of each material was finely ground, dried, and homogenously dispersed on the measuring table of the machine (Bruker AXS, D8 Advance, Bruker AXS GmbH, Karlsruhe, Germany,  $10^\circ/\text{min}$ ,  $2\theta$  from  $5^\circ$  to  $60^\circ$ ). The phase composition was checked using Joint Committee on Powder Diffraction standards. Crystallite size analysis was calculated using the peak broadening of XRD reflection that is used to estimate the crystallite size (in a direction perpendicular to the crystallographic plane) using the following formula:

$$X_s = \frac{0.9\lambda}{(\text{FWHM} \times \cos \theta)}, \quad (1)$$

where  $X_s$  is the crystallite size in nanometer,  $\lambda$  is the wavelength of X-ray beam in nanometer ( $\lambda = 0.15406 \text{ nm}$  for standard detectors), and FWHM is the full width at half maximum for the diffraction angle ( $2\theta = 25.9^\circ$  peak was selected related to (002) Miller's plane family).

Solubility of graft material in demineralized water was evaluated using atomic absorption spectrophotometer

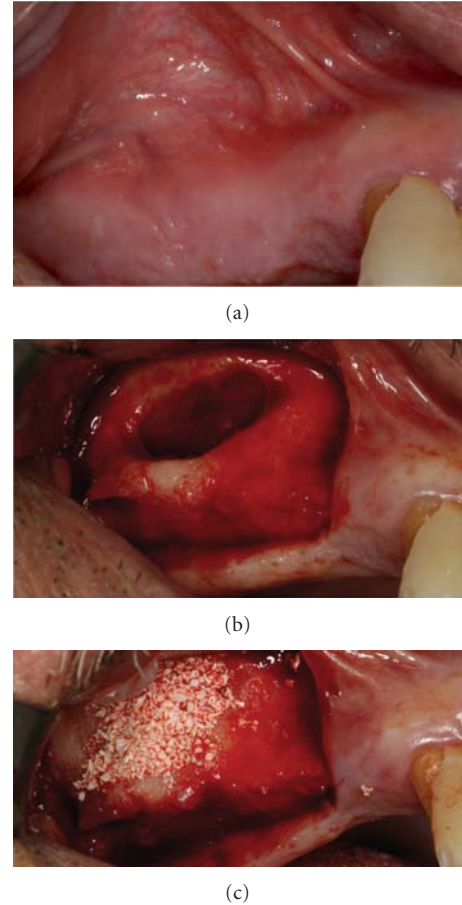


FIGURE 1: Site before exposure (a), direct exposure of lateral sinus wall (b), and filling of sinus with the selected grafting material (c).

(WFX-210, Rayleigh, BRAIC, China). Calcium and phosphorous detectors were calibrated in standard solution before each reading. 0.25 gram of each material was immersed in 100 mL of double purified water and the amount of calcium dissolution was measured every week for a period of six months.

Patients received detailed explanations of the difficulties and complications that could take place during the surgery and all patients agreed before the surgery. All of the 22 consenting patients were examined and medically compromised and uncooperative cases were excluded from the study.

**2.2. Sinus Lift Technique.** Local anesthesia was administered (2% lidocaine containing 1:100,000 epinephrine) and a horizontal incision was made along on the crestal bone in the edentulous area and then vertical incisions were made to elevate the mucoperiosteal flap. After elevation of a full-thickness mucoperiosteal flap, access was gained to the anterior bony wall of the sinus. The lateral bony wall of the sinus was cut by using a small diamond bur. All the cortical bone was removed up to the sinus membrane. After elevation of the membrane, the sinus cavity was then packed with either of the selected materials Figures 1(a), 1(b), and 1(c). An absorbable collagen membrane (Bio-Gide, Geistlich

Pharma AG, Wolhusen, Switzerland) was then placed on the graft to avoid migration of the graft and invasion of soft tissues. After the surgery, patients were prescribed 625 mg of antibiotic (Augmentin, GlaxoSmithKline, United Kingdom) twice a day for a week and advised to rinse their mouths daily with Chlorhexidine Gluconate Oral Rinse 0.12% (PerioGard, Colgate-Palmolive, United Kingdom) during healing period. The patients were examined 1 week after surgery when the sutures were removed. All patients were checked regularly to verify healing. After a healing period of 8 months, all implants (NobelReplace, Nobel Biocare, Kloten, Switzerland) were placed by one expert oral surgeon. The choice of the implant length was based on the postpanoramic X-rays after the sinus lift surgery.

**2.3. Measurement of Graft Height.** Height of graft material was measured at the following intervals:

- (i) 1st measurement: right after the implantation (baseline),
- (ii) 2nd measurement: after 8 month at time of implant placement,
- (iii) 3rd measurement: one year after implant placement,
- (iv) 4th measurement: four years after implant placement.

The implant length, alveolar crest, the original base line of the sinus floor, and the final graft height were traced by superimposition of the panoramic images. Two fixed measurement points were evaluated using image analysis software (Cell A, Olympus, Germany) to the accuracy of 1  $\mu$ m. [10]. Implant length was used to correct for any magnification errors.

**2.4. Statistical Analysis.** Data were analyzed using computer statistical program software (SPSS 18.0, SPSS Inc, Chicago, IL, USA) to evaluate the resorption rate of graft material with time and the differences between graft materials (means and standard deviations). Changes in graft volume at different time intervals were analyzed using Student's *t*-test ( $\alpha = 0.05$ ).

### 3. Results

The average particle size of Bio-Oss (1 mm) was much smaller compared to Cerabone (2.7 mm), Figures 2(a) and 2(b). X-ray diffraction analysis revealed typical structure of hydroxylapatite for both materials. The crystallite size was smaller for Bio-Oss (41.7 nm at 25.86 diffraction angle) compared to Cerabone (53.2 nm at 25.95 diffraction angle), Figure 3.

The amount of calcium release due to dissolution of the material in water was much higher for Bio-Oss compared to Cerabone. This observation was marked in the first 6 weeks after which dissolution rate of calcium ions reaches a fixed rate for both materials, Figure 4.

Four implants failed after 6 months from insertion time due to lack of adequate initial stability, these cases were

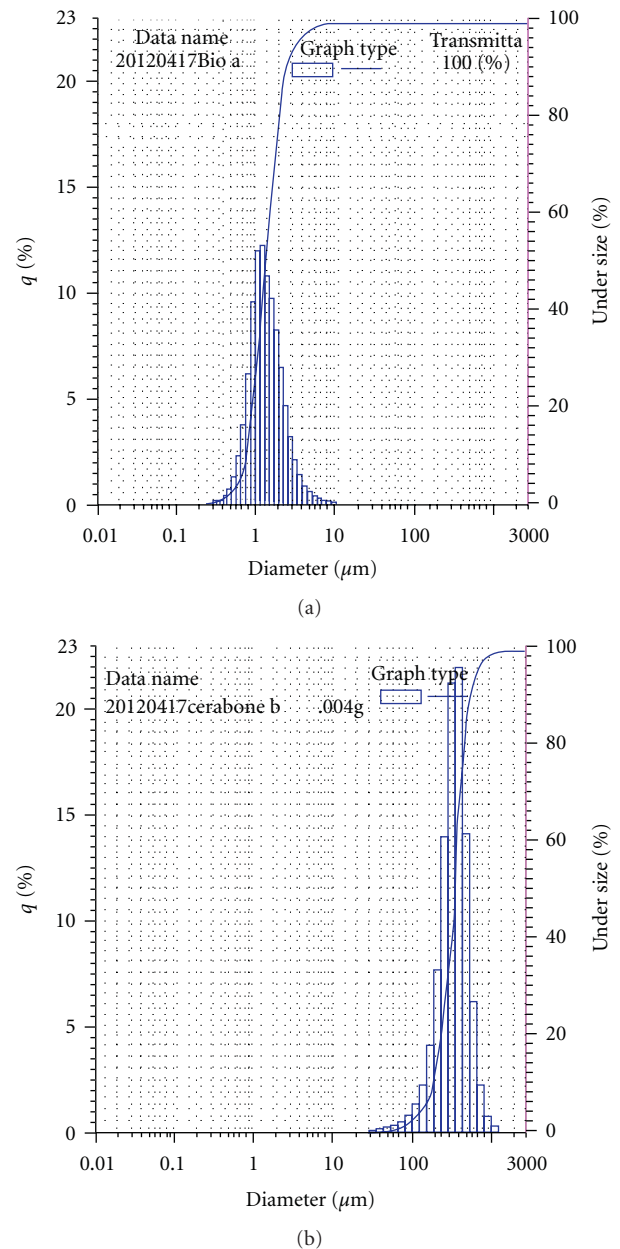


FIGURE 2: (a) Average particle size and distribution of Bio-Oss, (b) average particle size and distribution of Cerabone.

replaced with new cases. All patients demonstrated adequate healing after grafting surgery without complications. X-ray image analysis revealed that Bio-Oss demonstrated significantly higher ( $t = 7.25$ ,  $P < 0.001$ ) volumetric loss ( $33.4 \pm 3.1\%$ , volumetric loss of total graft height after 4 years) compared to Cerabone ( $23.4 \pm 3.6\%$ ). The greatest amount of vertical loss of graft volume was observed after one year of graft surgery (55–65% of total bone loss), which decreased almost to 10–12% per year later on for both materials ( $P < 0.06$ ), Figures 5 and 6. After four years from implant placement, it was observed that the height of Bio-Oss bone graft was located at level of implant apex while this finding was not reported for Cerabone.

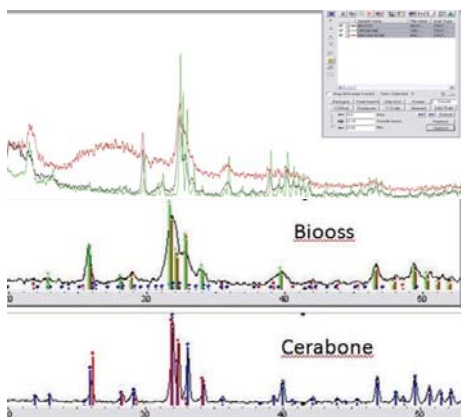


FIGURE 3: XRD analysis of Bio-Oss (red) and Cerabone (green) in relation to natural hydroxylapatite (black).

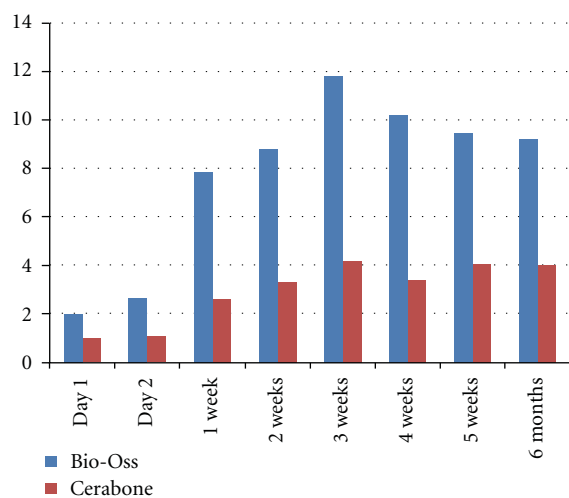
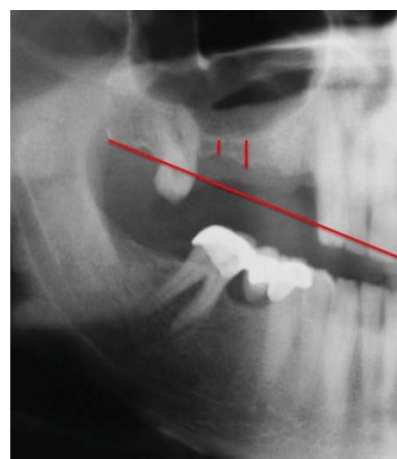


FIGURE 4: Calcium release (mg/g) at different time intervals. Release rate was almost constant after 2 months.

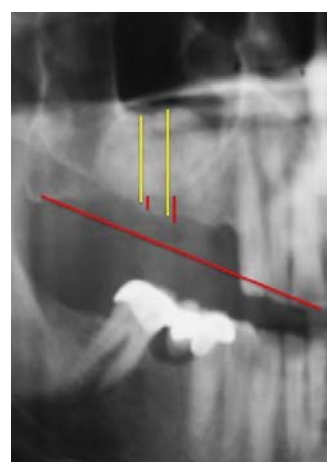
#### 4. Discussion

Numerous allogenic or alloplastic materials have been used alone or in combination with autogenous bone for sinus augmentation. Many researchers showed that these materials could be as effective as autologous bone [11–19]. Histologic evidence generated by studies of mature grafts and the excellent survival rates of implants inserted in them have led to the realization that these nonautogenous graft materials may be considered an excellent option [9, 13, 15, 20–23].

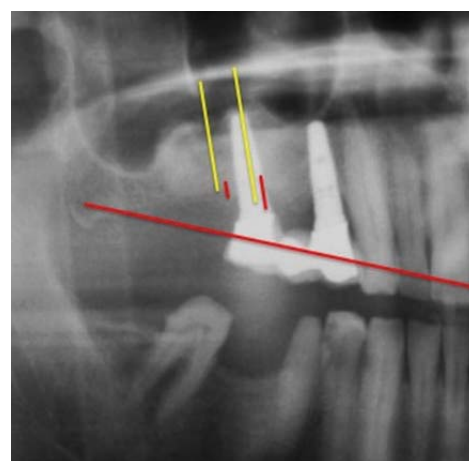
Moy et al. [24] reported  $59.4 \pm 18.0\%$  new bone formation and  $40.5 \pm 17.9\%$  connective tissue in the histomorphometric analysis of sinus augmented with chin bone after six-month healing time. The quality of newly formed bone was superior when compared to bovine hydroxyapatite and  $\beta$ -tricalciumphosphate, as it was composed of about 80% lamellar mature in nature. Another histomorphometric study [25] using Bio-Oss showed 28% mature bone, 44% connective tissue, and 28% bovine hydroxyapatite (BHA)



(a)



(b)



(c)

FIGURE 5: Panoramic X-ray with fixed measuring points at base line (a), after grafting procedure using Bio-Oss after 8-month healing time (b), and after four years of implant placement (c).

particles in a period of 6 months from 20 sinus lifts done in 15 patients.

A ten-year follow-up study [26] from 36 sinus grafts reported  $29.8 \pm 2.5\%$  new bone formation in the first 8

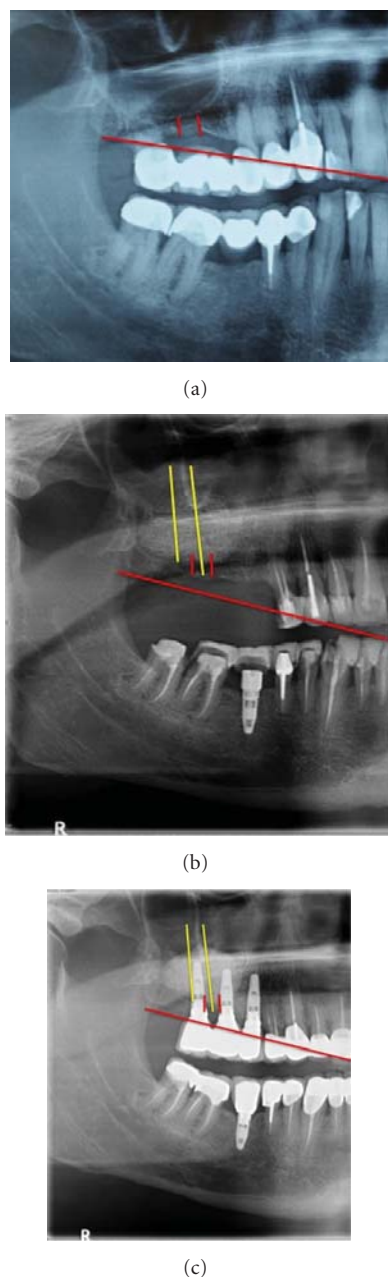


FIGURE 6: Panoramic X-ray with fixed measuring points at base line (a), after grafting procedure using Cerabone (b), and four years of implant placement (c).

months,  $69.7 \pm 2.6\%$  in the next one year, and by the end of the study it was  $86.7 \pm 2.84\%$ . The study proved that the rate of resorption of the graft material, BHA, was 3.55% per month in the initial 2 years and then the value reached a mean value of 0.58% per month in the next 8 years that is close to the findings of the present study. A total volume loss after 4 years was 34% for Bio-Oss and 22% for Cerabone accounting for an average monthly volume loss of 0.69% for Bio-Oss and 0.5% per month for Cerabone.

Although BHA is considered to be a resorbable material, it is not clear from the literature if the graft particles will

undergo resorption and will eventually be replaced with autogenous bone. Moreover the bone found in conjunction with the BHA particles was mainly woven [27]. Based on the data observed in the present study, Bio-Oss has smaller particle size (1 mm average particle size compared to 2.7 mm for Cerabone) resulting in significantly higher surface area, higher calcium release rate (9.8 mg/g), and smaller crystallite size (41.7 nm at 25.86 diffraction angle) compared to 53.2 nm at 25.95 diffraction angle for Cerabone. These minor differences were associated with significantly higher resorption rate of the initial graft volume observed for Bio-Oss material.

Studies [28, 29] using  $\beta$ -tricalciumphosphate ( $\beta$ -TCP) in sinus augmentation show around 29% new bone formation after 6 months healing time. When an osseoinductive factor like platelet rich plasma (PRP) was mixed with  $\beta$ -TCP, the osseous regenerating capacity was increased to 38%. Nevertheless, a resorption rate of 32–43% was reported; type and quality of crystal content of graft material is a dominant factor-controlling rate of resorption.

A very recent study [30] performed an ultrastructural study on bone-to-biomaterial interface and biomaterial mineral degradation in retrieved bone biopsies following maxillary sinus augmentation using bovine xenografts (Endobon). Scanning electron microscopy revealed that newly formed bone was closely attached to the xenograft. Elemental analysis showed a significantly high Ca/P ratio in the residual biomaterials ( $3.031 \pm 0.104$ ) compared with the interface ( $2.908 \pm 0.115$ ) and new bone ( $2.889 \pm 0.113$ ), which suggests that there may be a gradual diffusion of Ca ions from the biomaterial into the newly forming bone at the interface as part of the biomaterial's resorption process. These findings are in direct agreement with the calcium release rate observed in the present study. Under the influence of body fluids and with consideration to flow dynamics of blood, a higher calcium release rate is expected inside the sinus due to washing-off effect of the released ions, Figure 4.

Jensen et al. [31] reported that the types of graft materials influence the resorption rate of bone which was 1.8 mm in an autograft, 2.1 mm in a demineralized allograft, 0.9 mm in an alloplast, and 0.8 mm in an autograft mixed with alloplast. Histologic reviews of sinus lift procedures [32] with different types of graft material reported height reduction with all graft materials. Furthermore, in 90% of cases, the graft materials were positioned superior to the apex of the implant, which is in agreement with the findings of this study. The cases grafted with Bio-Oss ended with graft resorption ending at apex of integrated implants after four-year service time, meanwhile at least 3 mm of new bone remained on top of implants inserted in Cerabone graft. Hatano et al. [10] reported that graft materials were reduced with a statistically significant amount during 2 to 3 years after a sinus lift, while other study [33] observed that the force loading on dental implants caused graft height to be sustained at a consistent level.

These results should be interpreted cautiously considering the study's reduced sample size. Further in vitro and in vivo studies should be conducted to validate the results of the present study.



## 5. Conclusions

Within limitations of this study, the physical and chemical properties of bone graft material have significant influence on rate of resorption after sinus lift procedure intended for implant placement. Careful consideration of graft properties might enhance clinical performance.

## Acknowledgments

The authors like to thank the director and staff of the research platform of “Ecole Doctorale” at the Lebanese University, Hadath Campus, Lebanon, for their precious help.

## References

- [1] L. A. Aguirre Zorzano, M. J. Rodríguez Tojo, and J. M. Aguirre Urizar, “Maxillary sinus lift with intraoral autologous bone and B—tricalcium phosphate: histological and histomorphometric clinical study,” *Medicina Oral, Patología Oral y Cirugía Bucal*, vol. 12, no. 7, pp. E532–E536, 2007.
- [2] P. J. Boyne and R. A. James, “Grafting of the maxillary sinus floor with autogenous marrow and bone,” *Journal of Oral Surgery*, vol. 38, no. 8, pp. 613–616, 1980.
- [3] H. Tatum Jr., “Maxillary and sinus implant reconstructions,” *Dental Clinics of North America*, vol. 30, no. 2, pp. 207–229, 1986.
- [4] C. E. Misch and F. Dietsh, “Bone-grafting materials in implant dentistry,” *Implant Dentistry*, vol. 2, no. 3, pp. 158–167, 1993.
- [5] R. Guarnieri, R. Grassi, M. Ripari, and G. Pecora, “Maxillary sinus augmentation using granular calcium sulfate (Surgi-plaster Sinus): radiographic and histologic study at 2 years,” *International Journal of Periodontics and Restorative Dentistry*, vol. 26, no. 1, pp. 79–85, 2006.
- [6] J. B. Park, “Radiographic follow-up evaluation of sinus augmentation with deproteinized bovine bone and implant installation after loading,” *Indian Journal of Dental Research*, vol. 21, no. 4, pp. 603–605, 2010.
- [7] M. R. Norton, E. W. Odell, I. D. Thompson, and R. J. Cook, “Efficacy of bovine bone mineral for alveolar augmentation: a human histologic study,” *Clinical Oral Implants Research*, vol. 14, no. 6, pp. 775–783, 2003.
- [8] I. R. Zerbo, S. A. Zijderfeld, A. De Boer et al., “Histomorphometry of human sinus floor augmentation using a porous  $\beta$ -tricalcium phosphate: a prospective study,” *Clinical Oral Implants Research*, vol. 15, no. 6, pp. 724–732, 2004.
- [9] J. W. F. H. Frenken, W. F. Bouwman, N. Bravenboer, S. A. Zijderfeld, E. A. J. M. Schulten, and C. M. Ten Bruggenkate, “The use of Straumann Bone Ceramic in a maxillary sinus floor elevation procedure: a clinical, radiological, histological and histomorphometric evaluation with a 6-month healing period,” *Clinical Oral Implants Research*, vol. 21, no. 2, pp. 201–208, 2010.
- [10] N. Hatano, Y. Shimizu, and K. Ooya, “A clinical long-term radiographic evaluation of graft height changes after maxillary sinus floor augmentation with a 2:1 autogenous bone/xenograft mixture and simultaneous placement of dental implants,” *Clinical Oral Implants Research*, vol. 15, no. 3, pp. 339–345, 2004.
- [11] C. Blus, S. Szmukler-Moncler, M. Salama, H. Salama, and D. Garber, “Sinus bone grafting procedures using ultrasonic bone surgery: 5-Year experience,” *International Journal of Periodontics and Restorative Dentistry*, vol. 28, no. 3, pp. 221–229, 2008.
- [12] S. S. Wallace, S. J. Froum, S. C. Cho et al., “Sinus augmentation utilizing anorganic bovine bone (Bio-Oss) with absorbable and nonabsorbable membranes placed over the lateral window: histomorphometric and clinical analyses,” *International Journal of Periodontics and Restorative Dentistry*, vol. 25, no. 6, pp. 551–559, 2005.
- [13] Y. M. Lee, S. Y. Shin, J. Y. Kim, S. B. Kye, Y. Ku, and I. C. Rhyu, “Bone reaction to bovine hydroxyapatite for maxillary sinus floor augmentation: histologic results in humans,” *International Journal of Periodontics and Restorative Dentistry*, vol. 26, no. 5, pp. 471–481, 2006.
- [14] M. Simion, F. Fontana, G. Rasperini, and C. Maiorana, “Long-term evaluation of osseointegrated implants placed in sites augmented with sinus floor elevation associated with vertical ridge augmentation: a retrospective study of 38 consecutive implants with 1- to 7-year follow-up,” *International Journal of Periodontics and Restorative Dentistry*, vol. 24, no. 3, pp. 208–221, 2004.
- [15] U. Lekholm, K. Wannfors, S. Isaksson, and B. Adielsson, “Oral implants in combination with bone grafts: a 3-year retrospective multicenter study using the Brånemark implant system,” *International Journal of Oral and Maxillofacial Surgery*, vol. 28, no. 3, pp. 181–187, 1999.
- [16] J. H. Lee, U. W. Jung, C. S. Kim, S. H. Choi, and K. S. Cho, “Histologic and clinical evaluation for maxillary sinus augmentation using macroporous biphasic calcium phosphate in human,” *Clinical Oral Implants Research*, vol. 19, no. 8, pp. 767–771, 2008.
- [17] C. Maiorana, D. Sigurtà, A. Mirandola, G. Garlini, and F. Santoro, “Sinus elevation with alloplasts or xenogenic materials and implants: an up-to-4-year clinical and radiologic follow-up,” *International Journal of Oral and Maxillofacial Implants*, vol. 21, no. 3, pp. 426–432, 2006.
- [18] M. Chiapasco, M. Zaniboni, and L. Rimondini, “Dental implants placed in grafted maxillary sinuses: a retrospective analysis of clinical outcome according to the initial clinical situation and a proposal of defect classification,” *Clinical Oral Implants Research*, vol. 19, no. 4, pp. 416–428, 2008.
- [19] P. Martos Díaz, L. Naval Gías, J. Sastre Pérez et al., “Sinus elevation by in situ utilization of bone scrapers: technique and results,” *Medicina Oral, Patología Oral y Cirugía Bucal*, vol. 12, no. 7, pp. E537–541, 2007.
- [20] N. Yamamichi, T. Itose, R. Neiva, and H. L. Wang, “Long-term evaluation of implant survival in augmented sinuses: a case series,” *International Journal of Periodontics and Restorative Dentistry*, vol. 28, no. 2, pp. 163–169, 2008.
- [21] R. González García, L. Naval Gías, M. F. Muñoz Guerra, J. Sastre Pérez, F. J. Rodríguez Campo, and J. L. Gil-Díez Usandizaga, “Preprosthetic and implantological surgery in patients with severe maxillary atrophy,” *Medicina Oral, Patología Oral y Cirugía Bucal*, vol. 10, no. 4, pp. 343–354, 2005.
- [22] M. Hallman, L. Sennerby, and S. Lundgren, “A clinical and histologic evaluation of implant integration in the posterior maxilla after sinus floor augmentation with autogenous bone, bovine hydroxyapatite, or a 20:80 mixture,” *International Journal of Oral and Maxillofacial Implants*, vol. 17, no. 5, pp. 635–643, 2002.
- [23] K. E. Kahnberg and L. Vannas-Löfqvist, “Sinus lift procedure using a 2-stage surgical technique: i. Clinical and radiographic report up to 5 years,” *International Journal of Oral and Maxillofacial Implants*, vol. 23, no. 5, pp. 876–884, 2008.

- [24] P. K. Moy, S. Lundgren, and R. E. Holmes, "Maxillary sinus augmentation: histomorphometric analysis of graft materials for maxillary sinus floor augmentation," *Journal of Oral and Maxillofacial Surgery*, vol. 51, no. 8, pp. 857–862, 1993.
- [25] P. Valentini and D. Abensur, "Maxillary sinus floor elevation for implant placement with demineralised freeze-dried bone and bovine bone (Bio-Oss)," *International Journal of Periodontics and Restorative Dentistry*, vol. 17, no. 3, pp. 233–241, 1997.
- [26] S. Sartori, M. Silvestri, F. Forni, A. I. Cornaglia, P. Tesei, and V. Cattaneo, "Ten-year follow-up in a maxillary sinus augmentation using anorganic bovine bone (Bio-Oss). A case report with histomorphometric evaluation," *Clinical Oral Implants Research*, vol. 14, no. 3, pp. 369–372, 2003.
- [27] S. Schou, P. Holmstrup, T. Jørgensen et al., "Anorganic porous bovine-derived bone mineral (Bio-Oss®) and ePTFE membrane in the treatment of peri-implantitis in cynomolgus monkeys," *Clinical Oral Implants Research*, vol. 14, no. 5, pp. 535–547, 2003.
- [28] C. Reinhardt and B. Kreusser, "Retrospective study dental implantation with sinus lift and Cerasorb augmentation," *Dental Implantology*, vol. 14, pp. 18–26, 2000.
- [29] J. Cabezas-Mojón, C. Barona-Dorado, G. Gómez-Moreno, F. Fernández-Cáliz, and J.-M. Martínez-González, "Meta-analytic study of implant survival following sinus augmentation," *Medicina Oral, Patología Oral y Cirugía Bucal*, vol. 17, no. 1, pp. e135–e139, 2012.
- [30] M. P. Ramírez-Fernández, J. L. Calvo-Guirado, R. A. Delgado-Ruiz, J. E. Maté-Sánchez del Val, B. Negri, and M. Peñarrocha Diago, "Ultrastructural study by backscattered electron imaging and elemental microanalysis of biomaterial-to-bone interface and mineral degradation of bovine xenografts in maxillary sinus floor elevation," *Clinical Oral Implants Research*. In press.
- [31] O. T. Jensen, L. B. Shulman, M. S. Block, and V. J. Lacono, "Report of the sinus consensus conference of 1996," *International Journal of Oral and Maxillofacial Implants*, vol. 13, supplement, pp. 11–32, 1998.
- [32] E. Nyström, K. E. Kahnberg, and T. Albrektsson, "Treatment of the severely resorbed maxillae with bone graft and titanium implants: histologic review of autopsy specimens," *International Journal of Oral & Maxillofacial Implants*, vol. 8, no. 2, pp. 167–172, 1993.
- [33] R. D. Listrom and J. M. Symington, "Osseointegrated dental implants in conjunction with bone grafts," *International Journal of Oral & Maxillofacial Surgery*, vol. 17, no. 2, pp. 116–118, 1988.

## Research Article

# Schneider Membrane Elevation in Presence of Sinus Septa: Anatomic Features and Surgical Management

**Mario Beretta,<sup>1</sup> Marco Cicciù,<sup>2</sup> Ennio Bramanti,<sup>3</sup> and Carlo Maiorana<sup>4</sup>**

<sup>1</sup>Implantology Department, School of Dentistry, University of Milan, IRCSS Cà Grande, MI, Italy

<sup>2</sup>Human Pathology Department, Dental School, Messina University, Via Consolare Valeria 98100, Messina, Italy

<sup>3</sup>Odontostomatology Department, School of Dentistry, University of Messina, Via Consolare Valeria 98100, Messina, Italy

<sup>4</sup>Oral Surgery, Implantology Department, School of Dentistry, University of Milan, IRCSS Cà Grande, MI, Italy

Correspondence should be addressed to Marco Cicciù, [acromarco@yahoo.it](mailto:acromarco@yahoo.it)

Received 9 May 2012; Revised 20 June 2012; Accepted 20 June 2012

Academic Editor: Silvio Taschieri

Copyright © 2012 Mario Beretta et al. This is an open access article distributed under the Creative Commons Attribution License, which permits unrestricted use, distribution, and reproduction in any medium, provided the original work is properly cited.

Maxillary sinus floor elevation via a lateral approach is a predictable technique to increase bone volume of the edentulous posterior maxilla and consequently for dental implants placement. The sinus floor is elevated and it can be augmented with either autologous or xenogeneic bone grafts following an opening bone window created on the facial buccal wall. Maxillary septa are walls of cortical bone within the maxillary sinus. The septa shape has been described as an inverted gothic arch arising from the inferior or lateral walls of the sinus and may even divide the sinus into two or more cavities. Some authors have reported a higher prevalence of septa in atrophic edentulous areas than in nonatrophic ones. Radiographic identification of these structures is important in order to perform the right design of the lateral window during sinus lift. Aim of this investigation is to highlight the correct steps for doing sinus lift surgery in presence of those anatomic variations. Clinicians should always perform clinical and radiographic diagnosis in order to avoid complications related to the sinus lift surgery.

## 1. Introduction

The treatment of maxillary edentulous jaws with osseointegrated implants is often complex for the frequent pneumatization of the maxillary sinus and for the remaining low-bone density and volume. The bone resorption, consequent to the loss of the dental elements, determines atrophy in height and thickness, by reducing the amount of available bone to the implant placement. In the 1970s, Tatum Jr [1] and then Boyne and James [2] developed the surgical technique of the maxillary sinus augmentation. The proposed approach represents the most reliable procedure for the bone reconstruction of the maxillary sinus. Sinus augmentation has evolved into a predictable surgical modality for increasing the existing height with bone of sufficient quality to allow successful placement of dental implants [3]. Sinus floor augmentation can be today considered a relative safe procedure, but severe complications may occur as a result of incorrect

surgical plan or related to aggressive surgical manoeuvres [4]. Many different filling subantral materials have been used over the years [5]. Autologous bone represented for years the gold standard in bone grafting procedures for his osteoinductive, osteogenic, and osteoconductive abilities [6]. On the other hand, the pain deriving from the need of a double surgical site has prompted the researchers to develop alternative procedures using alloplastic, heterologous materials, and growth factors to support the bone regeneration [7–9].

Atrophy-related resorption of the alveolar process results in a vertical loss of bone volume, while progressive sinus pneumatization leads to an excavation of the alveolar process from the cranial aspect, which varies from one individual to another. Because atrophy-related resorption may occur differently in different areas of the alveolar process, bony septa can be considered residues between two such zones of resorption [10].

Knowledge of the maxilla anatomy, and moreover, of the blood supply of the maxillary sinus is mandatory to avoid unnecessary complications. [11–13].

All the surgical operations in the posterior maxillary region require detailed knowledge of maxillary sinus anatomy and possible anatomical variations. The aim of the present investigation is to underline how the presence of maxillary septa may influence the sinus floor augmentation surgical procedure. A complete knowledge of the patient's anatomical conditions is fundamental for exact planning of invasive surgery and helps to avoid complications.

## 2. Material and Methods

**2.1. Literature Search and Selection.** Several published paper underlined how dental implants positioned on posterior resorbed maxilla with extensive expanded sinus can be safely treated by a simultaneous sinus lift approach and implant insertion using the technical protocol and biomaterials studied with overall 10-years-long-term results [14, 15]. However, particular anatomical sinus features, like the presence of septa, can increase the percentage of complications of this safe technique.

The data from epidemiological studies on sinus septa prevalence on upper maxilla is not regular or predictable cause involving several additional topics. PUBMED research by “maxillary sinus septa” keywords evidences a total of sixty-one documents. However, only fifty-three manuscripts published and indexed in Medline assessing relation with “oral surgery diagnosis and therapy” and consequently published on related dentistry journal.

Fixot and Sorensens [16] dated on 1977 a document about retained root fragments along septa in the maxillary sinuses. Moreover, other fifteen manuscripts point out sinus septa prevalence, epidemiology, and anatomy.

A large number of studies (eighteen) involved radiological investigation on maxillary anatomy underlining how the volumetric analysis represents the more accurate way for performing sinus septa diagnosis. Nine published papers talk about sinus septa considering it on the sinus lift surgical procedure complications. Four animal studies and four cadaveric anatomy dissections and one systematic review complete the list of sinus-septa-related manuscript.

**2.2. Data Collection.** Referring about the full text data, the anatomical features and the surgical technique will be exposed thorough the paper in order to give clinicians complete information before performing sinus lift surgery.

In 1910, Underwood published a detailed description of maxillary sinus anatomy, evidencing antral septa of varying shape and size. Author divided sinus floor into three anatomic sections: a small anterior one over the premolar region a large median one descending between the roots of the first and second molars, and a small posterior one corresponding to the third molar region. These three sections of the floor of the sinus are usually underlined by ridges rising to distinct septa and connected to three defined

periods of tooth activity, separated by intervals of growth time [17].

For decades, these septa were considered clinically insignificant anatomical variations. However, new diagnostic methods for verification of sinus disorders, such as endoscopy, have led to a different attitude towards the maxillary sinus and its anatomical variations [18, 19].

Krennmair et al. [20] divided septa into primary and secondary on another Septa classification: primary septa corresponding to those first described by Underwood, arising from the development of the maxilla and secondary septa arising from irregular pneumatization of the sinus floor following tooth loss. Other authors [21–23] classified septa related to the presence/absence of maxillary teeth. Primary septa were located superior to a maxillary tooth; secondary septa were located on edentulous maxillae. However a combination of both types has been recorded too.

Furthermore, detailed knowledge of maxillary sinus anatomy has become increasingly important for sinus lift surgery [24].

The sinus lift technique, or internal maxillary sinus augmentation in the sense of sinus floor elevation, allows positioning of dental implants even when the posterior maxillary region has undergone severe bone resorption [25–27]. Before performing this kind of surgery, clinicians should suggest patients undergoing radiographic investigation for having a complete knowledge of the sinus extension [28–30]. Moreover, a CT dental scan of the upper jaw may give important information about the presence of septa and regarding the sinus three-dimensional limits (Figures 1, 2, 3 and 4).

In this surgical technique, a hinged window is made in the facial antral wall and inverted to create space for the grafting material. Either an autologous or a xenogenic bone graft is then placed between the former antral floor and the elevated sinus membrane, including or not inverted bone plate [31]. The presence of maxillary sinus septa can complicate both the luxation of the window into the sinus and the lifting of the membrane [20]. Boyne and James [2] advise cutting the septa with a chisel and removing them with haemostatic forceps, for placing the graft into the cavity without interruption. Sometimes, it is necessary to modify the buccal window design to avoid fracturing the septa: if the septa is high, it is advised to make two windows, one on each side [4, 32] or make one w-shaped window if the septa is lower [4] (Figures 5, 6, 7, and 8).

Although several modifications of this surgical technique have been proposed during the past few years, either with a supplementary or a simultaneous Le Fort I osteotomy, horseshoe osteotomy or nasal floor elevation [33], the original technique described by Boyne and James (1980) is still valid today [2].

After a period of 6/9 months, dental implants can be positioned in the newly formed bone (Figures 9 and 10).

## 3. Discussion

The surgery procedures of the posterior maxillary region require detailed knowledge of maxillary sinus anatomy and



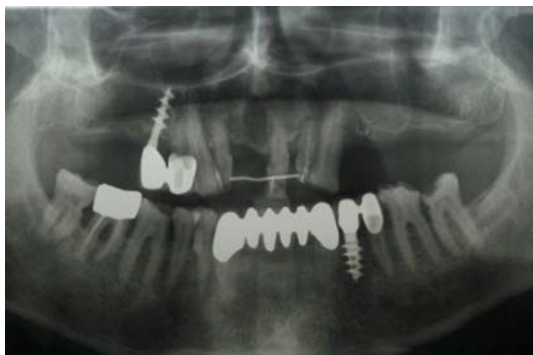


FIGURE 1: Panoramic rx shows the presence of possible septa in the left maxilla.

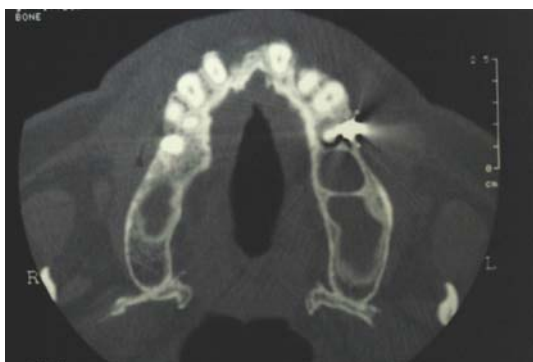

FIGURE 2: CT dental scan confirmed the presence of bone septa in the left maxilla.

possible anatomical variations. Detailed knowledge of the patient's morphological conditions allows exact planning of invasive surgery and helps to avoid complications. Several investigations analyzed the prevalence of sinus septa in the bone maxilla. Authors of those studies calculated the incidence number based on the number of sinus, which have septa, or on the number of subjects who have septa. The main results of those studies state how the antral septa are more commonly found in edentulous atrophic maxillae than in dentate maxillae. The septae in edentulous atrophic maxillae are usually shorter than those found in dentate maxillae. When present, maxillary sinus septae are more common anteriorly than posteriorly [23, 27, 30]. Additionally, the prevalence of septa has no relation with patient's sex or age, but there are variances based on the sorting of edentulism; some studies described a higher prevalence of septa in totally edentulous/atrophic areas than in partially edentulous/nonatrophic ones, with statistically significant differences [17, 21, 26]. Many authors contemplated the presence of septa if the height measured more than 2.5 mm [26, 30].

Despite the overall progress in dental implantology, dental implants positioning in the posterior atrophic maxilla are already considered to be a challenging procedure due to great levels of reduced bone volumes in many cases [34]. Grafting of the subantral space for augmentation is a prerequisite to overcome this deficiency [35]. Autogenous bone

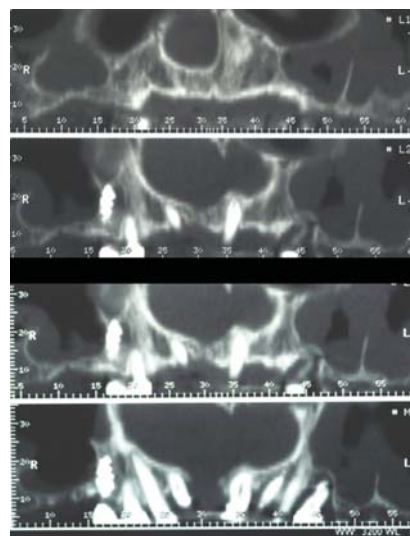


FIGURE 3: Axial view of the CT dental scan confirmed a deep septa in the left maxillary sinus.

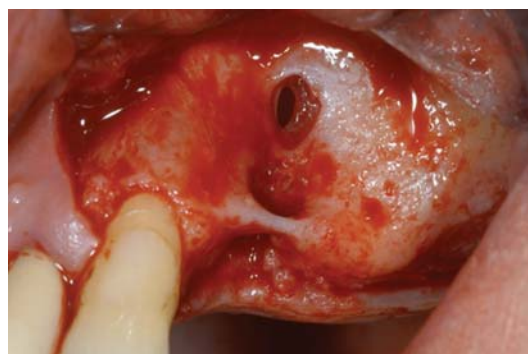

FIGURE 4: A mucoperiosteal flap is elevated. The buccal wall shows residual ridge with a perforation of the Schneider membrane related to previous tooth infection and fistula.

shows osteoinductive and osteoconductive properties and has, therefore, long been considered the material of choice for sinus augmentations. Because of its main disadvantages such as limited availability and donor site morbidity various allografts, xenografts and alloplastic materials are used to substitute autogenous bone. Though bone graft materials give only few osteoinductive potential, they may act as a scaffold for bone growth [36]. In a recent review [37], the overall implant survival rate using 100% autogenous bone grafts for sinus augmentations was lower (88.9%) compared to combined grafts (94.7%) and 100% bone substitutes (96.1%). However, several studies (60%) associated with autogenous bone grafts referred the use of implants with machined surfaces that, added together, achieved poorer survival rates (86.3%) than textured surfaces (96.7%). The authors concluded that grafts of bone substitutes alone or in combination with autogenous bone were at least as effective as those exclusively constituted by particulate autogenous bone [36].

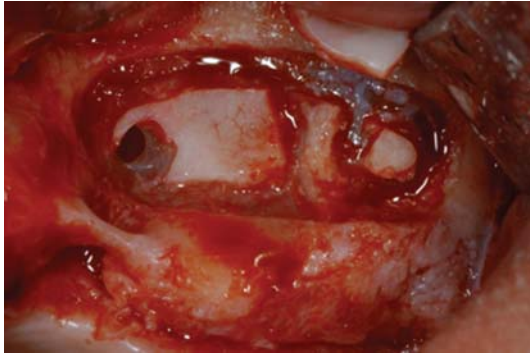


FIGURE 5: The buccal osteotomy is performed according to Boyne and James technique.

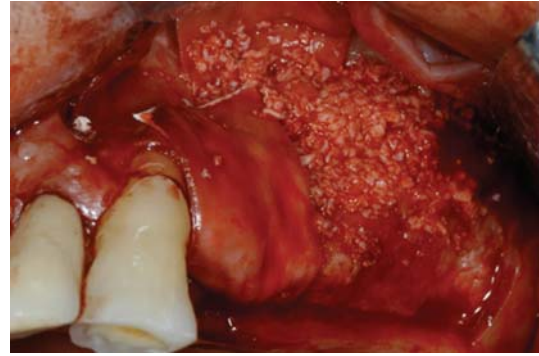


FIGURE 7: Deproteinized bovine bone has been used for covering the bone defect and for increasing the bone volume of the maxilla after the sinus lift.

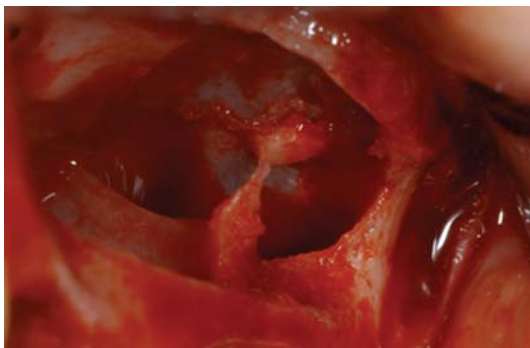


FIGURE 6: The presence of septa is well underlined after the sinus lift procedure performed. Two separate bone windows have been done.

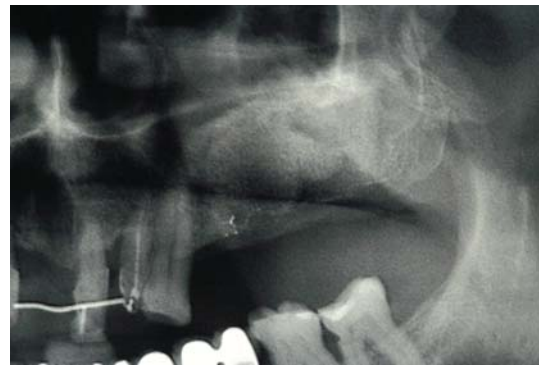

FIGURE 8: Panoramic rx control at 6 months after the surgery confirmed the newly bone formation.

Sinus lift procedure performed by using xenograft materials is today a common and predictable technique. Histological and immunohistochemical investigations of human and animal biopsies taken after implantation of those bone graft showed signs of osteoconduction as well as osteoinduction, a high biocompatibility and a angiogenic response [37–42]. Autologous bone has been considered the gold standard for years, but its use could be limited by the donor's morbidity, by its reduced availability, and by its variable resorption.

However, even if the surgeon may choose several kinds of materials for doing the graft, the problems related to the septa presence should be prevented and considered before doing the surgery.

Underwood observed the existence of another type of septa, indicating that it must have a different origin, as it seemed to be unrelated with teeth. Vinter et al. confirmed that resorption of maxillary alveolar process incomes irregularity in different regions, leaving bony crests on the sinus floor [3]. Consequently, incomplete septa on the sinus floor as known like “secondary septa” can be considered a result of tooth loss and bone resorption. Underwood was the first to study maxillary sinus septa and examined 45 dried skulls cut.

Ulm et al. [26] performed an observational study on the septa of 41 edentulous maxillae during sinus lift procedures underlining the anatomical features of the septa. Lugmayr et al. [23] observed the presence and morphology of maxillary sinus septa by observing the CTs of 100 adult

patients. This investigation pointed out how the view of the maxilla can be useful for underlining septa presence. Krennmair et al. [20] in 1997 performed another analysis about 194 posterior maxillary regions, which were divided, into 4 group: Group 1 clinical observation during sinus lift procedure with panoramic Radiograph evaluation, Group 2 skull for anatomic evaluation, Group 3 TC evaluation of edentulous alveolar ridge, and Group 4 TC evaluation of dentate maxillary ridge [26]. The study showed the presence of different anatomies related to the patients age and teeth presence on the mouth.

According to several investigations, the diagnosis of the septa presence is fundamental in order to avoid surgical complications. The elevate number of false diagnosis established using panoramic investigation remarks how this kind of method cannot be suitable to entirely evaluate the sinus anatomic extensions. Otherwise, CT Scan, 3D, and Cone Beam investigation are today the better diagnostic investigation to underline the real maxillary anatomy highlighting the presence of septa.

#### 4. Conclusion

The results of this study suggest how first-level radiographic investigation like orthopantomography or X ray are not

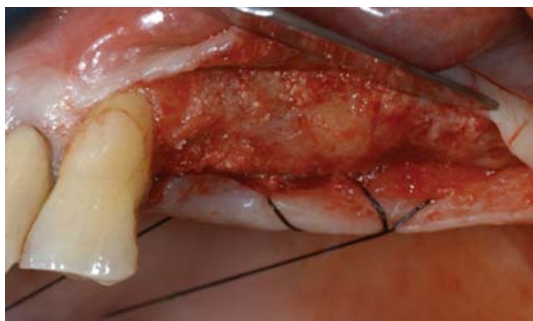

FIGURE 9: The new opened mucoperiosteal flap clearly shows a good amount of bone formation.

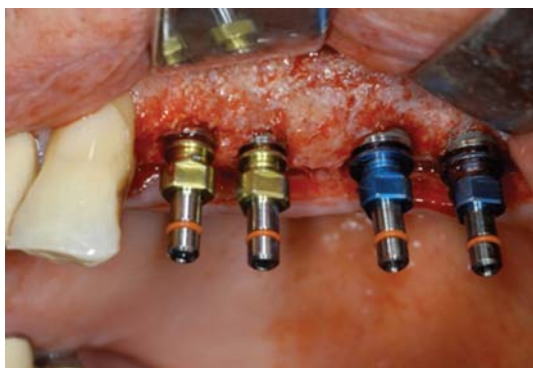

FIGURE 10: Four dental implants have been placed in order to perform prosthetic restoration of the previous edentulous area.

appropriate for thorough evaluation of the sinus floor and its anatomical variants. Otherwise, CT and subsequent reconstructions consent high-resolution imaging of anatomical bone structures and can be considered the method of choice for imagining and investigating sinus septa presence. Specially, the CT axial section may help clinicians on evaluating the septa orientation. Moreover, axial section is the ideal sectional plane to examine this bony structure.

## References

- [1] H. Tatum Jr., "Maxillary and sinus implant reconstructions," *Dental Clinics of North America*, vol. 30, no. 2, pp. 207–229, 1986.
- [2] P. J. Boyne and R. A. James, "Grafting of the maxillary sinus floor with autogenous marrow and bone," *Journal of Oral Surgery*, vol. 38, no. 8, pp. 613–616, 1980.
- [3] I. Vinter, J. Krmpotic-Nemanic, J. Hat, and D. Jalsovec, "Does the alveolar process of the maxilla always disappear after loss of teeth?" *Laryngorhinootologie*, vol. 72, no. 12, pp. 605–607, 1993.
- [4] H. F. Sailer, "A new method of inserting endosseous implants in totally atrophic maxillae," *Journal of Cranio-Maxillo-Facial Surgery*, vol. 17, no. 7, pp. 299–305, 1989.
- [5] R. G. Triplett, M. Nevins, R. E. Marx et al., "Pivotal, randomized, parallel evaluation of recombinant human bone morphogenetic protein-2/absorbable collagen sponge and autogenous bone graft for maxillary sinus floor augmentation," *Journal of Oral and Maxillofacial Surgery*, vol. 67, no. 9, pp. 1947–1960, 2009.
- [6] M. Chanavaz, "Maxillary sinus: anatomy, physiology, surgery, and bone grafting related to implantology—eleven years of surgical experience (1979–1990)," *The Journal of Oral Implantology*, vol. 16, no. 3, pp. 199–209, 1990.
- [7] G. M. Raghoobar, N. M. Timmenga, H. Reintsema, B. Stegenga and A. Vissink, "Maxillary bone grafting for insertion of endosseous implants: results after 12–124 months," *Clinical Oral Implants Research*, vol. 12, no. 3, pp. 279–286, 2001.
- [8] C. Karabuda, O. Ozdemir, T. Tosun, A. Anil, and V. Olgaç, "Histological and clinical evaluation of 3 different grafting materials for sinus lifting procedure based on 8 cases," *Journal of Periodontology*, vol. 72, no. 10, pp. 1436–1442, 2001.
- [9] H. Browaeys, P. Bouvry, and H. De Bruyn, "A literature review on biomaterials in sinus augmentation procedures," *Clinical Implant Dentistry and Related Research*, vol. 9, no. 3, pp. 166–177, 2007.
- [10] J. K. Tidwell, P. A. Blijdorp, P. J. Stoelinga, J. B. Brouns, and F. Hinderks, "Composite grafting of the maxillary sinus for placement of endosteal implants. A preliminary report of 48 patients," *International Journal of Oral and Maxillofacial Surgery*, vol. 21, no. 4, pp. 204–209, 1992.
- [11] N. Elia, S. Wallace, S. C. Cho, Z. N. Jalbout, and S. Froum, "Distribution of the maxillary artery as it relates to sinus floor augmentation," *International Journal of Oral and Maxillofacial Implants*, vol. 20, no. 5, pp. 784–787, 2005.
- [12] P. Solar, U. Geyerhofer, H. Traxler, A. Windisch, C. Ulm, and G. Watzek, "Blood supply to the maxillary sinus relevant to sinus floor elevation procedures," *Clinical Oral Implants Research*, vol. 10, no. 1, pp. 34–44, 1999.
- [13] H. Traxler, A. Windisch, U. Geyerhofer, R. Surd, P. Solar, and W. Firbas, "Arterial blood supply of the maxillary sinus," *Clinical Anatomy*, vol. 12, pp. 417–421, 1999.
- [14] M. C. Manso and T. Wassal, "Erratum: A 10-year longitudinal study of 160 implants simultaneously installed in severely atrophic posterior maxillas grafted with autogenous bone and a synthetic bioactive resorbable graft (Implant Dentistry (2010) 19(4) (351–360))," *Implant Dentistry*, vol. 19, no. 5, p. 364, 2010.
- [15] M. Esposito, M. G. Grusovin, J. Rees et al., "Effectiveness of sinus lift procedures for dental implant rehabilitation: a cochrane systematic review," *European Journal of Oral Implantology*, vol. 3, no. 1, pp. 7–26, 2010.
- [16] H. C. Fixot and F. M. Sorenson, "Retained root fragments along septa in the maxillary sinuses," *Oral Surgery, Oral Medicine, Oral Pathology*, vol. 43, no. 2, p. 320, 1977.
- [17] A. S. Underwood, "An inquiry into the anatomy and pathology of the maxillary sinus," *Journal of Anatomy and Physiology*, vol. 44, pp. 354–369, 1910.
- [18] M. E. Wigand, W. Steiner, and M. P. Jaumann, "Endonasal sinus surgery with endoscopic control: from radical operation to rehabilitation of the mucosa," *Endoscopy*, vol. 10, no. 4, pp. 255–260, 1978.
- [19] H. Stammberger, "Nasal and paranasal sinus endoscopy. A diagnostic and surgical approach to recurrent sinusitis," *Endoscopy*, vol. 18, no. 6, pp. 213–218, 1986.
- [20] G. Krennmair, C. Ulm, and H. Lugmayr, "Maxillary sinus septa: incidence, morphology and clinical implications," *Journal of Cranio-Maxillo-Facial Surgery*, vol. 25, no. 5, pp. 261–265, 1997.
- [21] I. Vinter, J. Krmpotic-Nemanic, and D. Jalsovec, "Verschwindet der Processus alveolaris des Oberkiefers immer



- nach dem Zahnausfall?" *Laryngorhinootologie*, vol. 72, pp. 606–607, 1993.
- [22] C. W. Ulm, P. Solar, G. Krennmair, M. Matejka, and G. Watzek, "Incidence and suggested surgical management of septa in sinus-lift procedures," *The International Journal of Oral & Maxillofacial Implants*, vol. 10, no. 4, pp. 462–465, 1995.
  - [23] H. Lugmayr, G. Krennmair, and H. Holzer, "The morphology and incidence of maxillary sinus septa," *RoFo*, vol. 165, no. 5, pp. 452–454, 1996.
  - [24] C. E. Misch, "Maxillary sinus augmentation for endosteal implants: organized alternative treatment plans," *The International Journal of Oral Implantology*, vol. 4, no. 2, pp. 49–58, 1987.
  - [25] J. A. Shibli, M. Faveri, D. S. Ferrari et al., "Prevalence of maxillary sinus septa in 1024 subjects with edentulous upper jaws: a retrospective study," *The Journal of Oral Implantology*, vol. 33, no. 5, pp. 293–296, 2007.
  - [26] C. W. Ulm, P. Solar, G. Krennmair, M. Matejka, and G. Watzek, "Incidence and suggested surgical management of septa in sinus-lift procedures," *The International Journal of Oral & Maxillofacial Implants*, vol. 10, no. 4, pp. 462–465, 1995.
  - [27] G. Krennmair, C. W. Ulm, H. Lugmayr, and P. Solar, "The incidence, location, and height of maxillary sinus septa in the edentulous and dentate maxilla," *Journal of Oral and Maxillofacial Surgery*, vol. 57, no. 6, pp. 667–671, 1999.
  - [28] S. Kasabah, R. Slezák, A. Simůnek, J. Krug, and M. C. Lecaro, "Evaluation of the accuracy of panoramic radiograph in the definition of maxillary sinus septa," *Acta Medica*, vol. 45, no. 4, pp. 173–175, 2002.
  - [29] D. Velásquez-Plata, L. R. Hovey, C. C. Peach, and M. E. Alder, "Maxillary sinus septa: a 3-dimensional computerized tomographic scan analysis," *International Journal of Oral and Maxillofacial Implants*, vol. 17, no. 6, pp. 854–860, 2002.
  - [30] H. González-Santana, M. Peñarrocha-Diogo, J. Guarinos-Carbó, and M. Sorní-Bröker, "A study of the septa in the maxillary sinuses and the subantral alveolar processes in 30 patients," *The Journal of Oral Implantology*, vol. 33, no. 6, pp. 340–343, 2007.
  - [31] S. V. Raja, "Management of the posterior maxilla with sinus lift: review of techniques," *Journal of Oral and Maxillofacial Surgery*, vol. 67, no. 8, pp. 1730–1734, 2009.
  - [32] N. J. Betts and M. Miloro, "Modification of the sinus lift procedure for septa in the maxillary antrum," *Journal of Oral and Maxillofacial Surgery*, vol. 52, no. 3, pp. 332–333, 1994.
  - [33] A. Stern and J. Green, "Sinus lift procedures: an overview of current techniques," *Dental Clinics of North America*, vol. 56, no. 1, pp. 219–233, 2012.
  - [34] M. Del Fabbro, G. Rosano, and S. Taschieri, "Implant survival rates after maxillary sinus augmentation," *European Journal of Oral Sciences*, vol. 116, no. 6, pp. 497–506, 2008.
  - [35] C. Karabuda, O. Ozdemir, T. Tosun, A. Anil, and V. Olgaç, "Histological and clinical evaluation of 3 different grafting materials for sinus lifting procedure based on 8 cases," *Journal of Periodontology*, vol. 72, no. 10, pp. 1436–1442, 2001.
  - [36] M. Hallman, L. Sennerby, and S. Lundgren, "A clinical and histologic evaluation of implant integration in the posterior maxilla after sinus floor augmentation with autogenous bone, bovine hydroxyapatite, or a 20:80 mixture," *International Journal of Oral and Maxillofacial Implants*, vol. 17, no. 5, pp. 635–643, 2002.
  - [37] H. Browaeys, P. Bouvry, and H. De Bruyn, "A literature review on biomaterials in sinus augmentation procedures," *Clinical Implant Dentistry and Related Research*, vol. 9, no. 3, pp. 166–177, 2007.
  - [38] P. Valentini and D. J. Abensur, "Maxillary sinus grafting with anorganic bovine bone: a clinical report of long-term results," *International Journal of Oral and Maxillofacial Implants*, vol. 18, no. 4, pp. 556–560, 2003.
  - [39] F. Heinemann, T. Mundt, R. Biffar, T. Gedrange, and W. Goetz, "A 3-year clinical and radiographic study of implants placed simultaneously with maxillary sinus floor augmentations using a new nanocrystalline hydroxyapatite," *Journal of Physiology and Pharmacology*, vol. 60, supplement 8, pp. 91–97, 2009.
  - [40] M. Sato, A. Aslani, M. A. Sambito, N. M. Kalkhoran, E. B. Slamovich, and T. J. Webster, "Nanocrystalline hydroxyapatite/titania coatings on titanium improves osteoblast adhesion," *Journal of Biomedical Materials Research A*, vol. 84, no. 1, pp. 265–272, 2008.
  - [41] M. Hallman, S. Lundgren, and L. Sennerby, "Histologic analysis of clinical biopsies taken 6 months and 3 years after maxillary sinus floor augmentation with 80% bovine hydroxyapatite and 20% autogenous bone mixed with fibrin glue," *Clinical Implant Dentistry and Related Research*, vol. 3, no. 2, pp. 87–96, 2001.
  - [42] G. Tawil and M. Mawla, "Sinus floor elevation using a bovine bone mineral (Bio-Oss) with or without the concomitant use of a bilayered collagen barrier (Bio-Gide): a clinical report of immediate and delayed implant placement," *International Journal of Oral and Maxillofacial Implants*, vol. 16, no. 5, pp. 713–721, 2001.



## Clinical Study

# Repair of a Perforated Sinus Membrane with a Subepithelial Palatal Conjunctive Flap: Technique Report and Evaluation

S. A. Gehrke,<sup>1</sup> S. Taschieri,<sup>2</sup> M. Del Fabbro,<sup>2</sup> and S. Corbella<sup>2</sup>

<sup>1</sup> Department of Research, Biotecnos, Rua Bozano, 571-97015-001 Santa Maria, RS, Brazil

<sup>2</sup> IRCCS Istituto Ortopedico Galeazzi, Università Degli Studi di Milano, Milan, Italy

Correspondence should be addressed to S. A. Gehrke, sergio.gehrke@hotmail.com

Received 10 April 2012; Revised 27 May 2012; Accepted 14 June 2012

Academic Editor: Igor Tsesis

Copyright © 2012 S. A. Gehrke et al. This is an open access article distributed under the Creative Commons Attribution License, which permits unrestricted use, distribution, and reproduction in any medium, provided the original work is properly cited.

The maxillary sinus grafting procedure has proven to be an acceptable modality for bone augmentation to provide a base for endosseous implants, routinely used for the rehabilitation of posterior maxilla. Perforation of the membrane is the most common complication in this type of procedure. This paper presents a technique for repairing a perforated Schneiderian membrane with a conjunctive connective tissue graft harvested from the palate and shows the histological and radiographic evaluation of the results. Ten consecutive cases with the occurrence of membrane perforation were included in this study. All were repaired with a flap of tissue removed from the palatine portion near to the surgical site. The technique is demonstrated through a clinical case. The results showed successful integration of 88.8% of the implants after 12 months from prosthesis installation. Histological evaluation of the samples showed that the use of nanocrystallized hydroxyapatite showed an adequate stimulation of bone neoformation within 6 months. Radiographic evaluation revealed a small apical implant bone loss, not compromising their anchorages and preservation. Thus, it can be concluded that the use of conjunctive technique with collected palate flap for sealing the perforation of the membrane of the sinus may have predictable result.

## 1. Introduction

The lateral window technique described in the mid 80s [1] was introduced as a method of increasing the amount of bone in atrophic posterior maxilla to allow implant placement. The lifting of the maxillary sinus floor is currently a widely used procedure for bone augmentation of the posterior maxilla in patients who underwent alveolar bone resorption and/or maxillary sinus pneumatization [2, 3], thus increasing the possibility of rehabilitative treatment of these areas with the placement of dental implants [4].

Schneiderian membrane perforation was the most common complication reported for lateral sinus lifting procedure [5, 6], and this can lead to loss of graft material and sometimes of the implants, as well as causing the loss of normal physiological function of the breast [7].

The knowledge of process for the management of the complications of implant surgery is very important in dental practice [8]. The suture of perforations of the membrane is

very difficult due to its characteristics, such as consistency [9]. However, sometimes the perforation of the membrane is not detected [10]. Various methods and techniques have been described to correct this problem, such as the use of collagen membranes, fibrin glue, or bone blades removed from donor areas [11].

The use of tissue removed from the palatal region has been used for correction and/or grafting of periodontal defects, because it is easily accessible and has a low morbidity, with excellent biological properties [12].

The purpose of this study is to describe the technique of using a subepithelial palatine flap for correction of medium-size perforations during the procedure for stabilizing the maxillary sinus graft material and for preventing its displacement into the maxillary sinus. Still, we present the results of the histologic analysis of the quality of new bone within these conditions and monitoring the behavior of these areas one year after prosthesis installation.

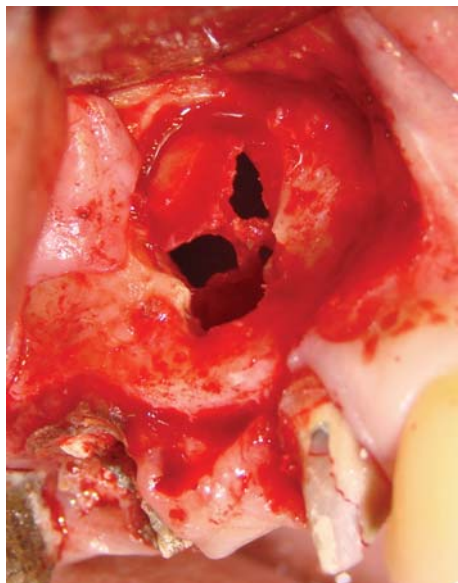


FIGURE 1: Image of the initial perforation.

## 2. Material and Methods

Ten cases of sinus floor elevations were included in this study conducted in Bioface Institut, Santa Maria (Brazil). Patients were treated, if they did not show any uncontrolled systemic disease and without history of maxillary sinus diseases. All patients signed an appropriate consent form for publication and monitoring of cases. After a careful planning of each case, the patients underwent maxillary sinus graft with lateral access without the simultaneous placement of implants, as indicated and planned. Before treatment, all patients were clinically and radiographically examined by panoramic radiograph and TC scans. Every two months, clinical evaluation was performed. Prophylactic oral antibiotics were used routinely for this procedure (amoxicillin 875 mg and metronidazole 400 mg) and an anti-inflammatory (Profenid 100 mg), beginning 2 h before the procedure and continued for 7 days every 12 h.

**2.1. Surgical Technique Report.** All the procedures were performed under light sedation and local anesthesia. The sinus augmentation procedure was followed the technique described by Tatum et al. [13]. A horizontal antero-posterior incision was made in the alveolar crest and supplemented by buccal releasing incisions at the anterior portion of the horizontal incision. A full-thickness mucoperiosteal flap was raised and the lateral wall of the sinus was exposed. An osteotomy was made with a round bur mounted on a high-speed handpiece device with copious sterile saline irrigation. The bony wall was carefully removed through abrasion, and the elevation of the membrane began with a series of curved curettes. At some point, we observed a small or medium size (<10 mm) Schneiderian membrane perforation (Figure 1). These occurrences were not considered a reason to abort the planned augmentation procedure, but the membrane surrounding the perforation was delicately dissected with a

blunt instrument, in an attempt not to increase the perforation size.

Then, a flap made only by connective tissue was removed from the palate portion, beginning the incision in the same site of the first incision of the flap prepared for the access of sinus wall, at the depth and size required to cover the perforation (Figure 2). The connective portion of the tissue was dissected from the epitelial one of the flap through the use of a 15C blade, used in an horizontal direction, parallel to the flap surface.

The tissue was placed and the maxillary sinus was filled by grafting material selected (Figure 3(a)). The posterior part of the cavity was grafted first, followed by the anterior portion, and finally the central area. Filling material consisted of hidroxiapatite (Nano Bone, Germany) (Figure 3(b)). This grafting protocol was used in all patients. After graft placement and compressing, the subepithelial flap was repositioned and sutured with continued sutures (Figure 3(c)).

**2.2. Postoperative Care.** Patients were advised not to blow their noses and to sneeze opening the mouth for 1 week after surgery. Patients were also instructed not to wear their dentures for 2-weeks postoperatively. Finally, sutures were removed after 7–10 days from surgery.

After 6 months, a total of 18 tapered dental implants were placed in the prepared sites 1 mm below the bone crest. The preparation of the fixture sites was undertaken using surgical guides based on wax-up models and according to the standard clinical procedures for the implant system (Implacil DeBortoli, São Paulo, Brazil).

**2.3. Histologic Evaluation.** Patients had the surgical bed initially prepared with a trephine of 2.8 mm external diameter and 2 mm internal diameter to collect the tissue sample for histological studies (Figure 4).

The processing and the histologic measurements were performed by an experienced and calibrated, blinded examiner. Samples were fixed in 4% buffered formalin for 24 hours, dehydrated using ascending grades of alcohol (80%, 90%, 100%) and xylol, and embedded in paraffin. Sections with 2  $\mu$ m thickness were made for each sample. The sections were treated with xylol and a series of decreasing concentrations of alcohol (100%, 90%, 80%), immersed in distilled water, stained in hematoxylin-eosin, and observed under a light microscope (E200—Nikon, Japan) to assess morphologic aspects. The histologic characteristics of bone formation were described.

**2.4. Radiographical Evaluation.** The sites were observed radiographically after implant placement, 4 months before the beginning of the prosthetic phase and 12 months after installation of the prosthesis. Radiographs were taken using a parallel technique and the use of individualized radiograph holder. The entity of bone-to-implant contact were made with the software Image Tool 3.0 for Windows (Figure 5). These assessments was made, blindly for patients characteristics, considering the chosen radiographs by a very experienced professional (ST). No magnification devices

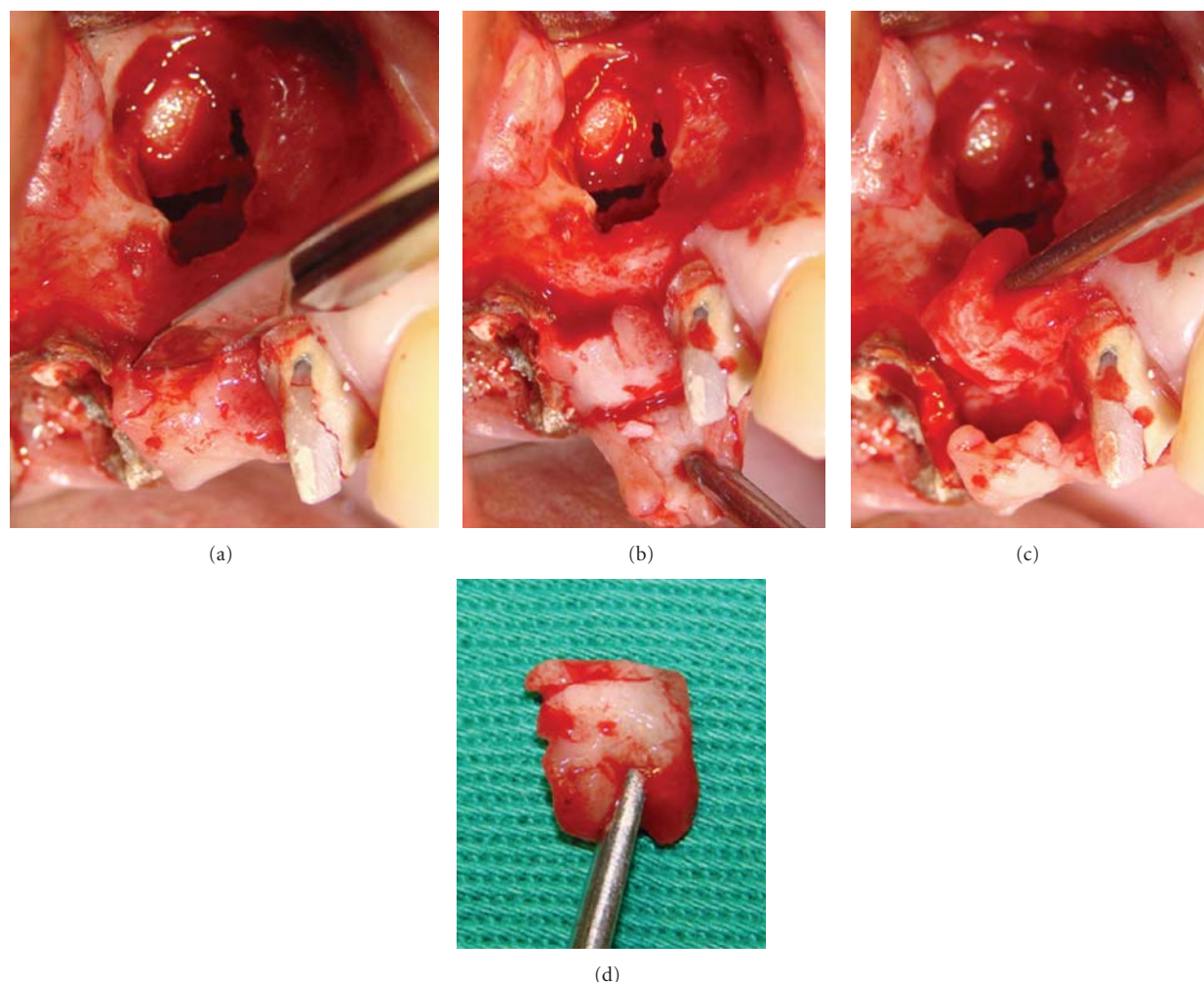


FIGURE 2: Images showing the sequence of removal of palatal tissue.

were used for the radiographs evaluation because the used software allowed a digital zoom of the image itself.

**2.5. Statistical Analysis.** The differences between 4 and 12 months in terms of presence of bone around implants were evaluated with a Students *t*-statistic ( $P < 0.05$ ).

### 3. Results

Sinus membrane perforations that occurred during surgical procedures were generally small with a mean diameter of 5 mm. All of them occurred during the detachment from the sinus walls.

After 6 months, two implants in one patient failed, because they were not osseointegrated and they were removed. Thus, the success rate was 88.8%. In other cases, the results showed an adequate new bone formation in patients treated with the described technique. No case had a postoperative complication in both the first and second surgical phase.

Histologically, the samples showed a new bone formation consistent with the period studied, demonstrating that the material used for grafting promoted good bone quality formation, although the amount of resorption of the material showed a very efficient integration (Figure 6).

Radiographically, the measures showed a good maintenance of bone formation, as shown in the graph of Figure 5, but in most cases there is a small loss of bone more frequently in the apical portion of the implants. The presence of bone tissue around implants installed in these areas was  $94.5 \pm 5.3\%$  after 4 months of implant placement and  $84.5 \pm 6.7\%$  after 12 months of installation of the prosthesis on the implants, showing no a significant loss even after receiving the implant loads ( $P = 0,087$ ) (Figure 7).

### 4. Discussion

The present study showed that the bone graft survival in the maxillary sinus after sinus membrane perforation can be obtained after correction with a flap of tissue removed portion of the palate.



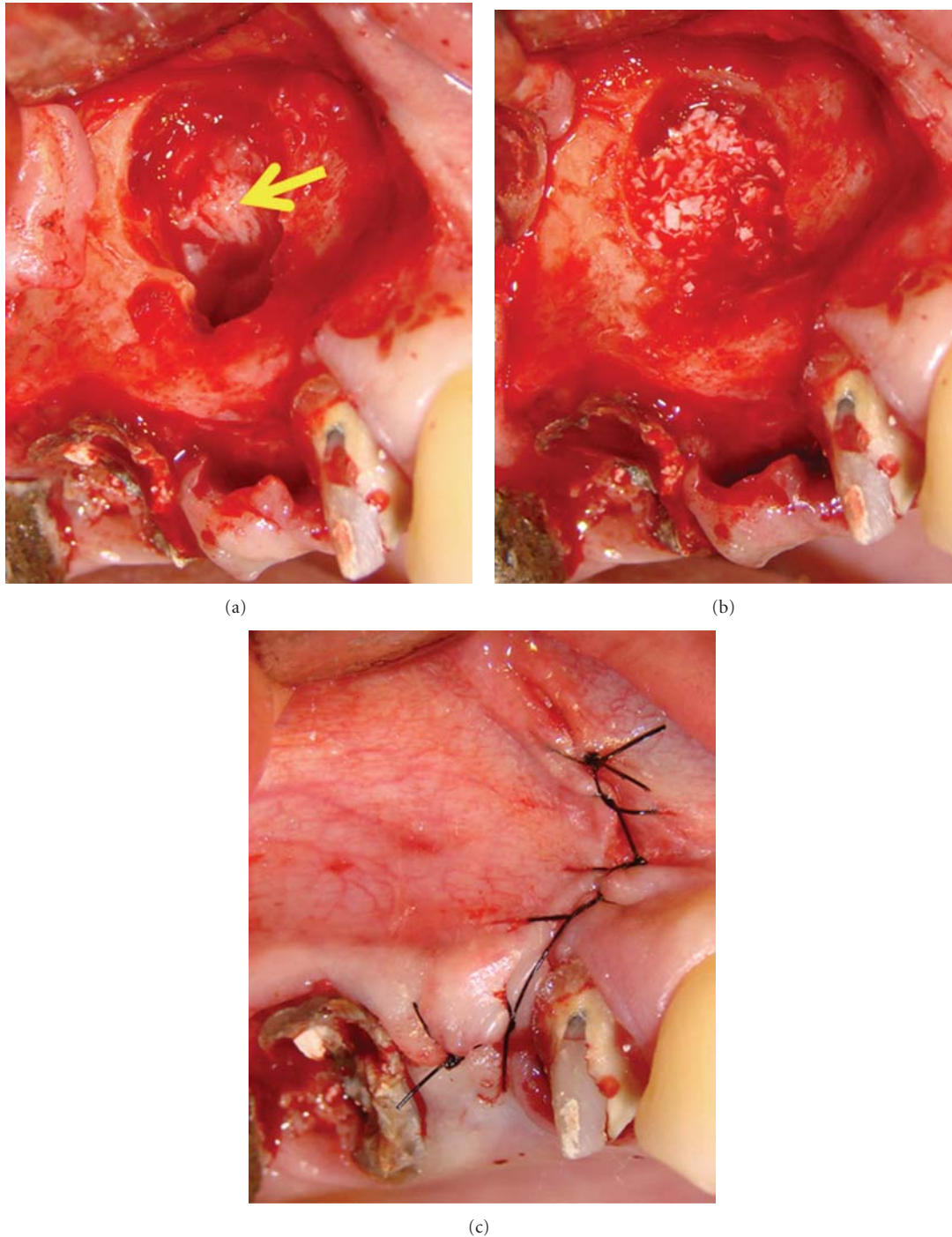


FIGURE 3: The placement of the autologous membrane, the bone graft, and the suture, respectively.

Grafting of the maxillary sinus is a method for reaching sufficient bone height for posterior maxillary implant placement and has proven to be a highly successful method and to give predictable results [14, 15]. Sinus floor elevation procedures are routinely performed, although the function of the maxillary sinus is not clearly understood. Some of its functions might be adding resonance to the voice and some

degrees of olfactory function, warming, and humidifying inspired air, as well as reducing the weight of the skull [5, 14].

The most commonly reported intraoperative complication of sinus augmentation is membrane perforation [15–18]. It has been reported to occur in 7–35% of sinus floor elevation procedures [14, 15, 18]. The presence of anatomic variations as well as technical factors in the region

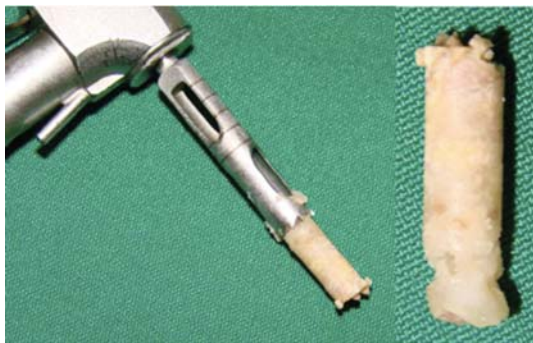

FIGURE 4: Picture of the bone fragments collected from the grafted areas for histological study.

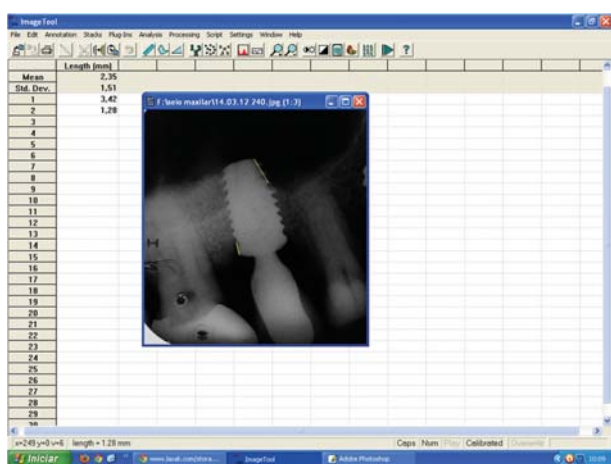
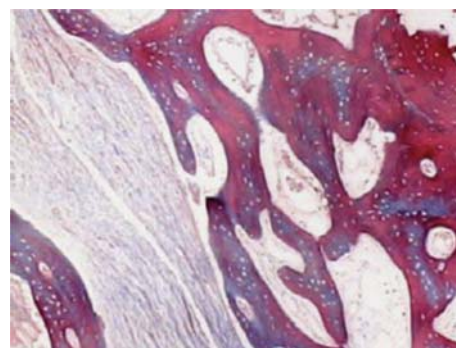


FIGURE 5: Image of the measurements being made with the review program Image Tool 3.0 for Windows.

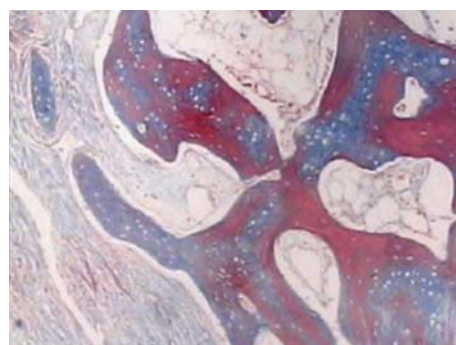
of the sinus floor can cause complications during such procedures [5, 19]. In the present study, ten cases were included where the perforation occurred during the surgical procedure.

It may be reasonable to assume that there is a correlation between implant failure and sinus membrane perforation. In 104 cases, sinus lift surgery was complicated by perforation of the sinus membrane, which was treated using different techniques and materials intended to act as a barrier between the sinus cavity and the site of graft placement [20].

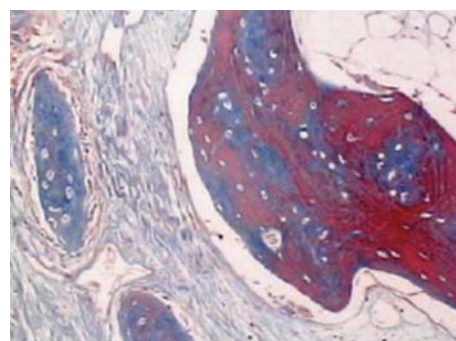
Several clinicians have recommended the use of a resorbable collagen membrane for repairing the perforated sinus membrane, and the reported implant success rate in nonperforated sites was 100%, while in perforated sites it was 69.56% [17]. Our study described an alternative for repairing of sinus membrane perforation with the use of a flap of tissue removed portion of the palate, which presented after one-year followup after prosthesis installation, an implant success rate of 88.8%. The use of an autologous connective tissue graft may be hypothesized to be more biocompatible and better tolerated by patients than other nonautologous materials. Furthermore, the autologous graft demonstrated a



(a)



(b)



(c)

FIGURE 6: Images showing bone growth in different areas of the sample, with 40x magnification ((a)-(b)) and a 100x magnification (c). We can see the formation of fibers surrounding the “islands” of ossification. Masson’s trichrome staining.

deep adherence to the sinus membrane tissue, and this could be useful during perforation management.

A classification for the perforated sinus membrane based on location and difficulty to repair can be described: class I perforation is a perforation that occurs at any point along the most apical wall of the prepared sinus window; class II perforations occur along the lateral or crestal aspects of the prepared sinus window and are further subdivided according to their position; class III perforations occur at any location within the body of the prepared sinus window [19, 21]. Pikos described sinus perforation by size: small (5 to 10 mm) and large (greater than 10 mm) [22]. As suggested by the results of the present study, minor membrane perforations, may not play a significant role in the clinical outcome. However, it

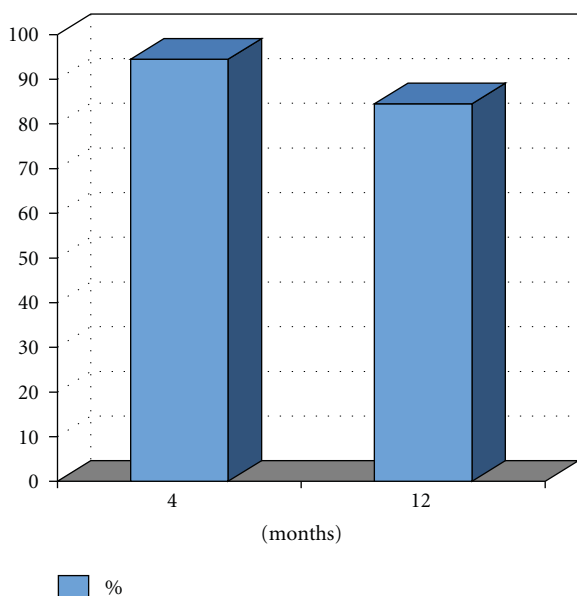


FIGURE 7: Percentage of implant portion included in bone 4 months after implantation and 12 months after prosthesis installation.

appears that the size of the membrane perforations is related to the prognosis of the implants placed.

Previous reports suggested that larger perforations represent an absolute contraindication to the continuation of surgery [10]. Schwartz-Arad et al. [18] found no relation between membrane perforations or postoperative complications and implant survival. In our study, cases with perforations bigger than 10mm were treated, and it was clinically observed that the grafted soft tissue promotes an easier and better stability at the site of perforation.

It has been proposed that the regenerative result of the bone-grafting procedure is inferior following sinus membrane perforations and that simultaneous implant placement should not be performed following repairing of severe perforations [15]. According to the results of the present study, membrane perforation should not be considered an absolute contraindication for simultaneous implant placement.

Various grafting materials have been used during sinus augmentation procedures, including autogenous bone, freeze-dried bone allografts, xenografts, hydroxyapatite, tricalcium phosphate, or a combination of these materials [15, 17, 23–26] and bone morphogenetic protein [5]. The quantity and quality of the bone graft available from the mandible seems to be sufficient and may avoid the need to harvest the bone from an extraoral site to permit sinus grafting and simultaneous implant placement [20]. In our series, a hidroxyapyatite nanocrystalized was used and has proved to be an adequate grafting material, and it was also confirmed by histological results.

## 5. Conclusion

The sinus membrane perforation is the most common intraoperative complication associated with the procedures

for maxillary sinus elevation and grafting. Sinus membrane perforations may be adequately reconstructed and covered, and therefore they are not an absolute contraindication to the continuation of surgery, provided that they do not allow the passage of graft material inside the maxillary sinus. The use of a connective flap grafted from the palate area is a good alternative. So, the overall survival rate of implants placed under reconstructed membranes was 88,8% after 12 months. A hidroxyapatite nanocrystalized (nano bone) constitutes a viable alternative as an augmentation material for this type of procedure. The maintenance bone around the implants placed in these areas was  $94.5 \pm 5.33\%$  after 4 months of implant placement and  $84,5 \pm 6.74\%$  after 12 months of installation of the prosthesis on implants.

More comparative clinical trials with wider sample size and adequate randomization may be necessary to validate this technique and to evaluate the advantages and disadvantages in comparison with other surgical procedures.

## References

- [1] P. J. Boyne and R. A. James, "Grafting of the maxillary sinus floor with autogenous marrow and bone," *Journal of Oral Surgery*, vol. 38, no. 8, pp. 613–616, 1980.
- [2] C. E. Misch, "Maxillary sinus augmentation for endosteal implants: organized alternative treatment plans," *The International Journal of Oral Implantology*, vol. 4, no. 2, pp. 49–58, 1987.
- [3] S. S. Wallace and S. J. Froum, "Effect of maxillary sinus augmentation on the survival of endosseous dental implants. A systematic review," *Annals of Periodontology*, vol. 8, no. 1, pp. 328–343, 2003.
- [4] E. Kaufman, "Maxillary sinus elevation surgery: an overview," *Journal of Esthetic and Restorative Dentistry*, vol. 5, no. 4, pp. 272–283, 2003.
- [5] J. P. Van Den Bergh, C. M. Ten Bruggenkate, F. J. Disch, and D. B. Tuinzing, "Anatomical aspects of sinus floor elevations," *Clinical Oral Implants Research*, vol. 11, no. 3, pp. 256–265, 2000.
- [6] A. Katranji, P. Foteck, and H. L. Wang, "Sinus augmentation complications: etiology and treatment," *Implant Dentistry*, vol. 17, no. 3, pp. 339–349, 2008.
- [7] P. Proussaefs and M. A. Maksoud, "Complications after maxillary sinus augmentation: a case report," *Implant Dentistry*, vol. 10, no. 3, pp. 168–171, 2001.
- [8] K. Misch and H. L. Wang, "Implant surgery complications: etiology and treatment," *Implant Dentistry*, vol. 17, no. 3, pp. 159–168, 2008.
- [9] B. H. Choi, S. J. Zhu, J. H. Jung, S. H. Lee, and J. Y. Huh, "The use of autologous fibrin glue for closing sinus membrane perforations during sinus lifts," *Oral Surgery, Oral Medicine, Oral Pathology, Oral Radiology and Endodontology*, vol. 101, no. 2, pp. 150–154, 2006.
- [10] M. Aimetti, R. Romagnoli, G. Ricci, and G. Massei, "Maxillary sinus elevation: the effect of macrolacerations and microlacerations of the sinus membrane as determined by endoscopy," *International Journal of Periodontics and Restorative Dentistry*, vol. 21, no. 6, pp. 581–589, 2001.
- [11] P. Proussaefs, J. Lozada, and J. Kim, "Effects of sealing the perforated sinus membrane with a resorbable collagen membrane: a pilot study in humans," *Journal of Oral Implantology*, vol. 29, no. 5, pp. 235–241, 2003.



- [12] L. A. Chambrone and L. Chambrone, "Subepithelial connective tissue grafts in the treatment of multiple recession-type defects," *Journal of Periodontology*, vol. 77, no. 5, pp. 909–916, 2006.
- [13] O. H. Tatum, "Maxillary and sinus implant reconstructions," *Dental Clinics of North America*, vol. 30, no. 2, pp. 207–229, 1986.
- [14] E. Nkenke, A. Schlegel, S. Schultze-Mosgau, F. W. Neukam, and J. Wiltfang, "The endoscopically controlled osteotome sinus floor elevation: a preliminary prospective study," *International Journal of Oral and Maxillofacial Implants*, vol. 17, no. 4, pp. 557–566, 2002.
- [15] B. Shlomi, I. Horowitz, A. Kahn, A. Dobriyan, and G. Chaushu, "The effect of sinus membrane perforation and repair with lambone on the outcome of maxillary sinus floor augmentation: a radiographic assessment," *International Journal of Oral and Maxillofacial Implants*, vol. 19, no. 4, pp. 559–562, 2004.
- [16] L. Levin, R. Herzberg, E. Dolev, and D. Schwartz-Arad, "Smoking and complications of onlay bone grafts and sinus lift operations," *International Journal of Oral and Maxillofacial Implants*, vol. 19, no. 3, pp. 369–373, 2004.
- [17] P. Proussaefs, J. Lozada, J. Kim, and M. D. Rohrer, "Repair of the perforated sinus membrane with a resorbable collagen membrane: a human study," *International Journal of Oral and Maxillofacial Implants*, vol. 19, no. 3, pp. 413–420, 2004.
- [18] D. Schwartz-Arad, R. Herzberg, and E. Dolev, "The prevalence of surgical complications of the sinus graft procedure and their impact on implant survival," *Journal of Periodontology*, vol. 75, no. 4, pp. 511–516, 2004.
- [19] J. M. Vlassis and P. A. Fugazzotto, "A classification system for sinus membrane perforations during augmentation procedures with options for repair," *Journal of Periodontology*, vol. 70, no. 6, pp. 692–699, 1999.
- [20] F. Khoury, "Augmentation of the sinus floor with mandibular bone block and simultaneous implantation: a 6-year clinical investigation," *International Journal of Oral and Maxillofacial Implants*, vol. 14, no. 4, pp. 557–564, 1999.
- [21] P. A. Fugazzotto and J. Vlassis, "A simplified classification and repair system for sinus membrane perforations," *Journal of Periodontology*, vol. 74, no. 10, pp. 1534–1541, 2003.
- [22] M. A. Pikos, "Maxillary sinus membrane repair: update on technique for large and complete perforations," *Implant Dentistry*, vol. 17, no. 1, pp. 24–31, 2008.
- [23] B. Johansson, K. Wannfors, J. Ekenbäck, J. I. Smedberg, and J. Hirsch, "Implants and sinus-inlay bone grafts in a 1-stage procedure on severely atrophied maxillae: surgical aspects of a 3-year follow-up study," *International Journal of Oral and Maxillofacial Implants*, vol. 14, no. 6, pp. 811–818, 1999.
- [24] R. Guarnieri and M. Bovi, "Maxillary sinus augmentation using prehardened calcium sulfate: a case report," *International Journal of Periodontics and Restorative Dentistry*, vol. 22, no. 5, pp. 503–508, 2002.
- [25] M. Hallman, L. Sennerby, and S. Lundgren, "A clinical and histologic evaluation of implant integration in the posterior maxilla after sinus floor augmentation with autogenous bone, bovine hydroxyapatite, or a 20:80 mixture," *International Journal of Oral & Maxillofacial Implants*, vol. 17, no. 5, pp. 635–643, 2002.
- [26] P. Valentini and D. Abensur, "Maxillary sinus grafting with anorganic bovine bone: a clinical report of long-term results," *International Journal of Oral and Maxillofacial Implants*, vol. 18, no. 4, pp. 556–560, 2003.

## Review Article

# Osteotome-Mediated Sinus Lift without Grafting Material: A Review of Literature and a Technique Proposal

**Silvio Taschieri,<sup>1</sup> Stefano Corbella,<sup>2</sup> Massimo Saita,<sup>1</sup> Igor Tsesis,<sup>3</sup> and Massimo Del Fabbro<sup>1,2</sup>**

<sup>1</sup> Centre for Research in Oral Health, Department of Biomedical, Surgical and Dental Sciences, Università degli Studi di Milano, IRCCS Istituto Ortopedico Galeazzi, Milan, Italy

<sup>2</sup> Centre for Research in Oral Implantology, Department of Biomedical, Surgical and Dental Sciences, Università degli Studi di Milano, IRCCS Istituto Ortopedico Galeazzi, Milan, Italy

<sup>3</sup> Section of Endodontology, The Maurice and Gabriela Goldschleger School of Dental Medicine, Tel Aviv University, Israel

Correspondence should be addressed to Stefano Corbella, stefano.corbella@gmail.com

Received 31 March 2012; Accepted 25 April 2012

Academic Editor: Stefano Corbella

Copyright © 2012 Silvio Taschieri et al. This is an open access article distributed under the Creative Commons Attribution License, which permits unrestricted use, distribution, and reproduction in any medium, provided the original work is properly cited.

Implant rehabilitation of the edentulous posterior maxilla may be a challenging procedure in the presence of insufficient bone volume for implant placement. Maxillary sinus augmentation with or without using grafting materials aims to provide adequate bone volume. The aim of the present study was to systematically review the existing literature on transalveolar maxillary sinus augmentation without grafting materials and to propose and describe an osteotome-mediated approach in postextraction sites in combination with platelet derivative. The systematic review showed that high implant survival rate (more than 96% after 5 years) can be achieved even without grafting the site, with a low rate of complications. Available alveolar bone height before surgery was not correlated to survival rate. In the described case report, three implants were placed in posterior maxilla after extraction of two teeth. An osteotome-mediated sinus lifting technique was performed with the use of platelet derivative (PRGF); a synthetic bone substitute was used to fill the gaps between implant and socket walls. No complications occurred, and implants were successfully in site after 1 year from prosthetic loading. The presented technique might represent a viable alternative for the treatment of edentulous posterior maxilla with atrophy of the alveolar bone though it needs to be validated by studies with a large sample size.

## 1. Introduction

Implant placement in the posterior maxilla is a challenging procedure when residual bone height is reduced. Maxillary sinus elevation technique is a common surgical procedure which allows to augment the available bone volume in posterior maxilla in order to place implants.

Residual bone height is considered fundamental in deciding which augmentation technique can be used to obtain an adequate bone volume. Generally, sinus lifting through a lateral approach is a viable technique when less than 4–5 mm of residual bone height is present [1–3]. When more than 5 mm of residual bone height is available, a transalveolar approach could be indicated in order to reduce the morbidity and the invasivity of the treatment protocol [4–6].

Osteotome-mediated transcrestal sinus lift approach was first proposed by Tatum in 1986 [7]. In the original approach, implants were placed after the controlled fracture of sinus floor and were submerged during the healing phase. In 1994, Summers described a modification of this technique [8]. The author proposed the preparation of implant site through the use of conical osteotomes which allows the compression, through lateral force application, of the bone in the posterior maxilla. The author stated that these maneuvers allow to increase the lateral bone density, preserving bone because drilling is avoided.

While the transcrestal approach is considered more conservative than the lateral approach, the main drawback is that the sinus lifting procedure must be performed blindly because of the impossibility to visualize the sinus floor



[5, 6]. In spite of this limitation, membrane perforation was reported to be less frequent in the osteotome-mediated procedure [6] than in the lateral approach, for which such complication was described in 25–44% of cases [9–11].

Transcrestal, osteotome-mediated sinus lift surgery may be performed with or without the use of bone grafting material as allograft, autogenous bone, or heterologous bone material [6]. No significant differences in terms of implant survival and success rates were observed comparing the two methods [6]. Also, the use of platelet derivatives without any bone substitute is described in literature [12, 13] with the aim of allowing a better control of forces during sinus floor elevation and reducing the incidence of complications.

The aim of this study was to perform a literature review regarding osteotome-mediated sinus lifting without bone grafting material and to present a technique to perform the procedure with the use of plasma rich in growth factors (PRGFs).

## 2. Literature Review

**2.1. Materials and Methods.** An electronic search was conducted via MEDLINE (PubMed) in the dental literature to select human clinical trials published from 1986 to January 2012. The search terms used were “sinus lift,” “sinus augmentation,” “sinus grafting,” “sinus elevation” alone or in combination with “osteotome,” “dental implants,” “crestal,” and “transalveolar” using boolean operator “AND” and were chosen accordingly with previously published reviews [1, 5, 6]. Bibliographies of the selected articles were also manually searched.

Inclusion criteria for the studies were

- (i) studies concerning osteotome-mediated sinus lifting procedure without using grafting materials;
- (ii) a minimum of 1-year followup after prosthetic rehabilitation;
- (iii) at least 20 patients treated;
- (iv) data on implant survival (SR) were reported.

Two authors (SC and MDF) independently screened abstracts and fulltext of the eligible articles for possible inclusion. In case of disagreement, a joint decision was taken by discussion.

Data from selected studies were extracted and recorded in a previously designed electronic form.

The fulltext of each included study was reviewed, and the following parameters were extracted:

- (i) demographics of treated patients (age, gender, sample size);
- (ii) bone height (distance between bone crest and floor of the sinus);
- (iii) implant length;
- (iv) Implant survival rate;
- (v) surgical or postsurgical complications;
- (vi) causes and occurrence of implant failure.

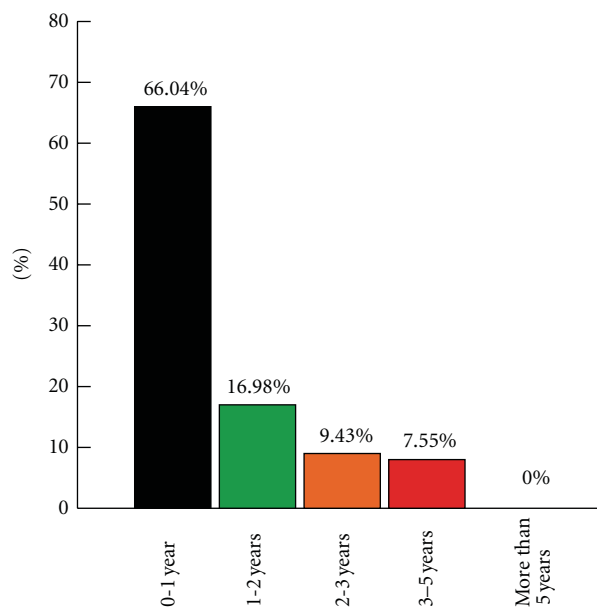


FIGURE 1: Failures distribution over time.

Weighted mean survival rate was calculated up to 5 years. The comparison between subgroups (follow-up duration, implant length, residual bone height) was made using Pearson's chi square test.

## 3. Results

The initial electronic search provided 438 items. After titles and abstracts screening, they are 361 articles were excluded because not pertinent with the aims of this paper. Of the 77 remaining articles, 62 were excluded because of not fulfilling the inclusion criteria. Fifteen articles were finally included in the analysis [12, 14–27].

Data about implant survival rates over time are presented in Table 1. It can be observed a great heterogeneity among studies regarding sample size (ranging from 20 to 983 patients) and study design. A total of 1767 implants were considered in this study. Survival rates were high in each considered follow-up time. The weighted mean survival was 98.02% one year after loading, 97.37% after 2 years, 97.47% after 3 years, and 96.77% after 5 years.

Two thirds (66.04%) of failures were recorded during the first year after loading as shown in Figure 1.

Implant length distribution in relation to implant survival at 1 year is shown in Table 2. Implant length varied among the studies, but it was greater than 10 mm in the majority of the considered studies. No correlation between implant length and survival rate could be demonstrated.

Alveolar bone height before and after surgical procedures is presented in Table 2. Mean residual bone height at baseline did not exceed 8.2 mm considering mean values. The higher mean bone height after surgery was 13.28 mm [27].

TABLE 1: Cumulative implant survival rates.

Study	N	n	1 y	n	2 y	n	3 y	n	5 y
Fermbergård and Åstrand [14]	53	53	96,23			50	94,30		
Tetsch et al. [15]	983	983	98,88	887	97,88	805	98,39	529	97,83
Bruschi et al. [16]	66	66	95,45	63	95,45	63	95,45	63	95,45
Gabbert et al. [17]	92	92	95,65	83	95,65	83	95,65		
Juriscic et al. [18]	40	40	100,00	40	100,00	40	100,00		
Nedir et al. [19]	25	25	100,00	25	100,00	25	100,00		
Nedir et al. [20]	54	54	100,00						
Cavicchia et al. [21]	97	97	89,69	87	89,69	87	89,69	86	88,65
Diss et al. [12]	35	35	97,14						
Schmidlin et al. [22]	24	24	100,00	24	100,00				
Leblebicioglu et al. [23]	75	75	97,33	73	97,33				
Fugazzotto [24]	114	114	98,25	83	98,25	40	98,25		
Volpe et al. [25]	20	20	100,00						
Bruschi et al. [27]	68	68	100,00	68	100,00	68	100,00	68	100,00
Fornell et al. [26]	21	21	100,00						
n Total	1767	1767	98,02	1433	97,37	1261	97,47	746	96,77

TABLE 2: Bone height before and after surgery.

Study	Mean implant length	Mean $\pm$ SD (range) before surgery	Mean $\pm$ SD after surgery
Fermbergård and Åstrand [14]	10,89	6,3 $\pm$ 0,3	10,7 $\pm$ 0,3
Tetsch et al. [15]	11,50	8,2	3,3
Bruschi et al. [16]	13,57	1–3	13,28 $\pm$ 1,23
Gabbert et al. [17]	10,29	NE	NE
Juriscic et al. [18]	10,72	NE	NE
Nedir et al. [19]	9,60	5,4 $\pm$ 2,3	10,3 $\pm$ 2,2
Nedir et al. [20]	8,37	2,5 $\pm$ 1,7	6,3 $\pm$ 1,5
Cavicchia et al. [21]	12,30	NE	NE
Diss et al. [12]	10,51	6,5 $\pm$ 1,7	9,8 $\pm$ 1,5
Schmidlin et al. [22]	8,60	5,0 $\pm$ 1,5	8,6 $\pm$ 1,3
Leblebicioglu et al. [23]	>11 mm	7 $\pm$ 1,3	10,9 $\pm$ 1,7
Fugazzotto [24]	9,16	NE	NE
Volpe et al. [25]	NR	7.2 $\pm$ 1.5	10.0 $\pm$ 1.0
Bruschi et al. [27]	13,50	6.02 $\pm$ 0,75	7.99 $\pm$ 1.16
Fornell et al. [26]	10,00	5.6 $\pm$ 2.1	8.6 $\pm$ 2.1

No correlation could be found between bone height and implant survival rate.

#### 4. Technique Description and Case Report

A 45-year-old male patient, in general good health (ASA 1), nonsmoker, presented with a first left maxillary molar (2.6) exhibiting a destructive caries and referring vague, nonspecific symptoms. Radiographic examination revealed the presence of periradicular lesion of strictly endodontic origin, and a suitable restoration was considered unfeasible. In the same quadrant, the maxillary second premolar and second molar (2.5 and 2.7) were missing. Moreover, a tilted wisdom teeth (2.8) showed a lateral and vertical mobility

associated with a pathological periodontal status (Figure 2).

An experienced surgeon (ST) performed the entire surgical procedure.

**4.1. Surgical Procedure.** Preoperatively all patients rinsed with a 0.2% chlorhexidine solution for a minute as an antiseptic treatment in order to reduce the contamination of the surgical field.

Patients' peripheral blood was collected using citrated tubes in order to prepare the platelet concentrate [28–30]. Briefly, the platelet concentrate is obtained by one-step centrifugation process (580 g for 8 minutes). The supernatant is then separated into two fractions paying care not to collect the leukocyte-rich layer: the deeper half is

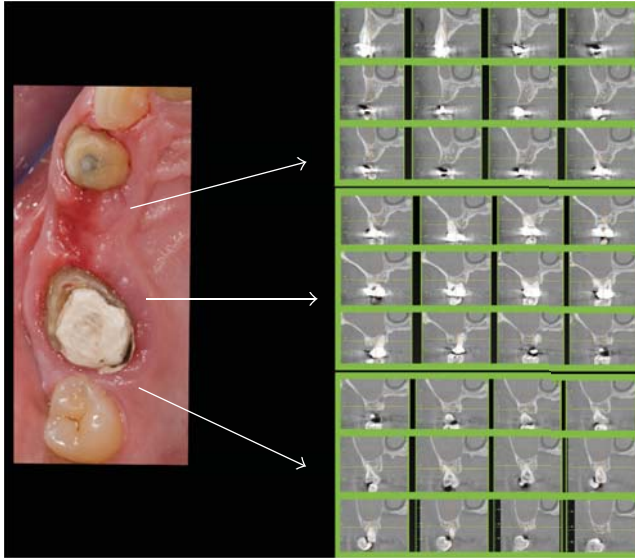


FIGURE 2: Clinical situation before surgery (clinical photo and TC sections).

plasma very rich in growth factors (PVRGFs), and the upper half is plasma rich in growth factors (PRGFs). Each fraction is activated with calcium chloride a few minutes before use.

Local anaesthesia was administered with the use of articaine 4% and epinephrine 1 : 100.000.

A full thickness mucosal flap was raised, and the extraction of the mobilized teeth 2.6 and 2.8 was made with forceps in order to minimize the mechanical trauma to the surrounding bone. Implant surgical procedure was immediately performed after extraction of the involved teeth and accurate removal of the granulation tissue, when present, from the socket.

Three implants (BTI Biotechnology Institute, Alava, Spain) were placed. One was placed in the edentulous 2.5 site (Figure 3(a)), and implant installation was performed according to the protocol provided by the manufacturers. The other two implants were placed, respectively, in 2.6 post extraction site and in the bone bridge between 2.6 site and 2.8 site. In both sites, implant installation was performed using a modified technique of osteotome sinus floor elevation (OSFE) procedure [13] (Figure 4).

Piezosurgical inserts (MB1, EMS, Nyon Switzerland) were used to prepare the implant sites until the Schneiderian membrane was reached (Figure 5). The sites depth was predetermined according to measurements obtained from the 3D radiographic examination. A Valsalva maneuver was done in order to detect the presence of an oroantral communication.

At this time, the sites were firstly embedded with liquid PVRGF (plasma very rich in growth factors) and subsequently a PRGF fibrin clot was gently pushed beyond the empty alveolus with the osteotome before raising the sinus floor (Figure 3(a)). The osteotome was used with minimal pressure and rotation and when necessary slight malleting to implode the sinus membrane in an apical

direction (Figure 3(b)). After removing the osteotome, a Valsalva maneuver was done again. The osteotomy was to be underprepared by 1 mm relative to the final implants diameter to improve primary implant stability. The clot placement and the insertion of the osteotome were repeated several times until the required membrane lift was achieved; finally, a membrane of cross-linked collagen was placed in both sites (COVA, Biom'Up, Saint-Priest, France) (Figure 3(b)). The implant was embedded with PVRGF and inserted with a torque of at least 30 Ncm (Figures 3(c) and 3(d)). Three implants were placed: one  $4.5 \times 11.5$  mm (2.5) and two  $4 \times 8.5$  mm (2.6 and 2.7). A clot of PRGF combined with a biphasic and synthetic bone substitute, made by hydroxyapatite, calcium phosphate, and porcine-acellular collagen (Matribone, Biom'Up, Saint-Priest, France), was used as a gapfiller of the postextraction sockets (Figures 6(a) and Figure 6(b)).

A cross-linked collagen membrane (COVA, Biom'Up, Saint-Priest, France) embedded with PVRGF was positioned over the cover screw (Figure 6(c)). The flaps were repositioned and secured with nonabsorbable silk 5-0 sutures (Ethicon Inc. Johnson & Johnson, Piscataway, NJ, USA). All implants were semisubmerged so that all parts of the defects were covered by mucosal tissue (Figure 6(d)).

After surgical phase, a standard pharmacological protocol was prescribed: amoxicillin 1 g every 8 hours for 5 days after surgery, nimesulide 100 mg twice daily for pain control if needed, and 0.2% chlorhexidine digluconate mouthwash twice daily for 1 week for plaque control. A soft diet was recommended, avoiding contact of the surgically involved zone with food for a few days if possible. Sutures were removed one week after surgery.

After 3 months of healing, a surgical reentry procedure was performed. Full thickness flaps were elevated to access the marginal portion of the implant sites (Figure 7). The cover screws were replaced with healing caps and subsequently with permanent abutments, and the implants were loaded with the final restoration. The prosthesis was cemented (Figures 8 and 9). Complications were recorded any time they occurred.

**4.2. Radiographic Evaluation.** A standardized intraoral radiograph followed by a CBCT scan was taken before surgery (Figure 1).

Other intraoral periapical radiographs was taken immediately after implant placement, at the prosthetic phase, and at each follow-up visit (scheduled after 6 and 12 months of prosthesis function and yearly thereafter).

Figure 9 is a radiograph taken at the 6-month followup. Radiographs were taken using a long cone paralleling technique and individual trays, in order to ensure reproducibility. Each periapical radiograph was scanned at 600 dpi with a scanner (Epson Expression 1680 Pro, Epson).

**4.3. Variables Assessed.** Primary variables were (a) prosthesis success: prosthesis in function, without mobility. Prosthesis stability was tested by means of two opposing instruments' pressure. Prosthesis was considered as failed if its function

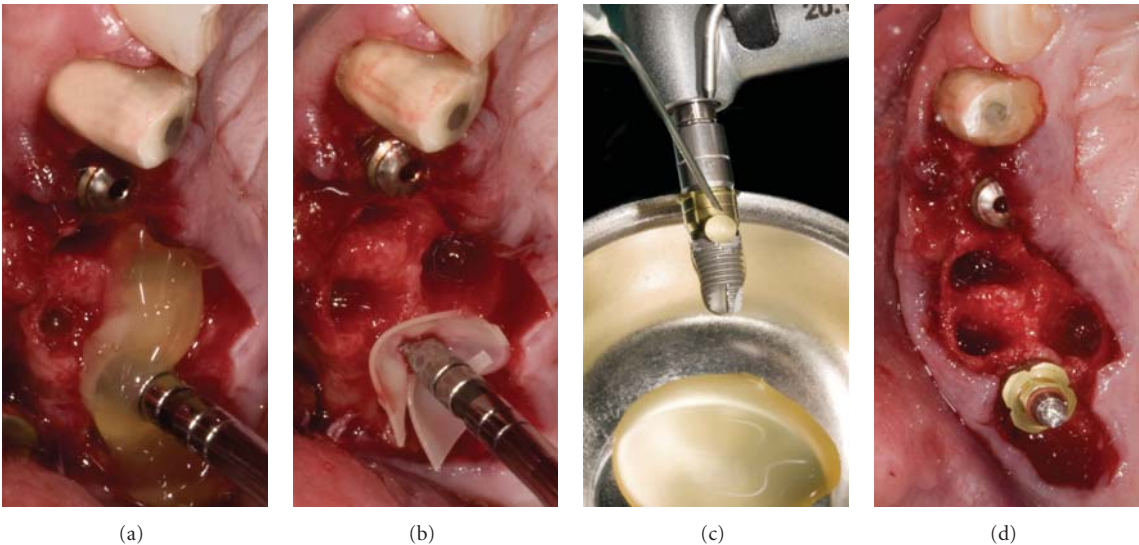


FIGURE 3: (a) Implant in site 1.5 was placed through standard protocol; a PRFG clot was positioned in the prepared socket before sinus floor elevation. (b) A membrane was placed apically in the so prepared site. (c) Before implant positioning, the fixture surface was bioactivated with liquid PRGF. (d) 2.5 and 2.7 implants in position.

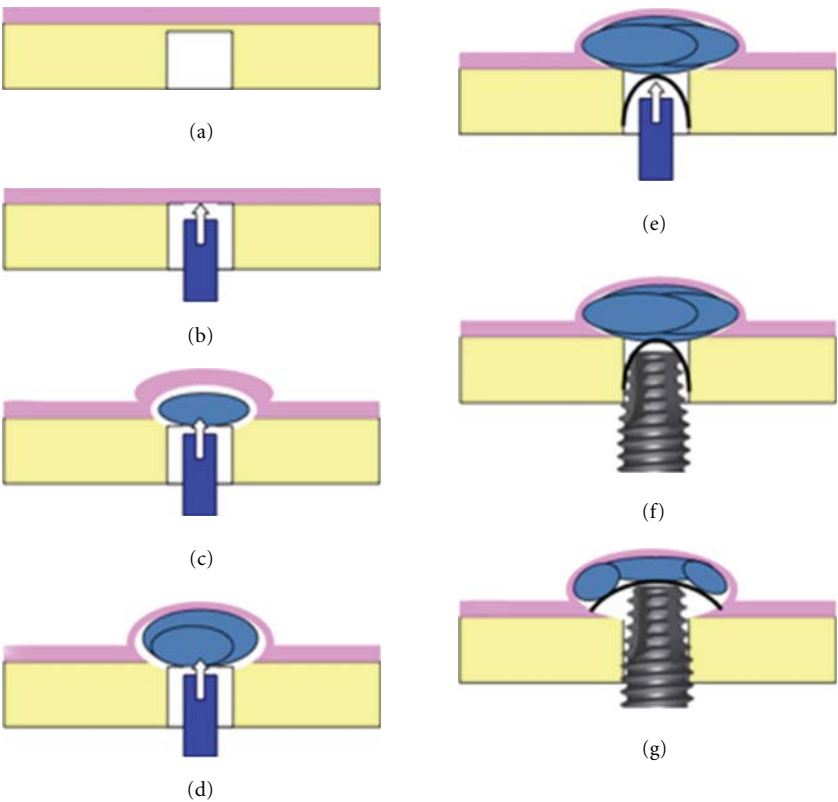


FIGURE 4: Schematic representation of osteotome-mediated sinus lift technique with the use of PRGF.

was compromised for any reason; (b) implant success according to conventional criteria [31]; (c) postoperative quality of life based on the assessment of pain, swelling, general discomfort in the first week after surgery; (d) patient satisfaction for mastication function, phonetics, and

aesthetics. The latter two variables were evaluated by means of questionnaires based on a five-point Likert scale [32]. Secondary variables were implant survival, the number and type of complications, mesial and distal changes of marginal bone level.



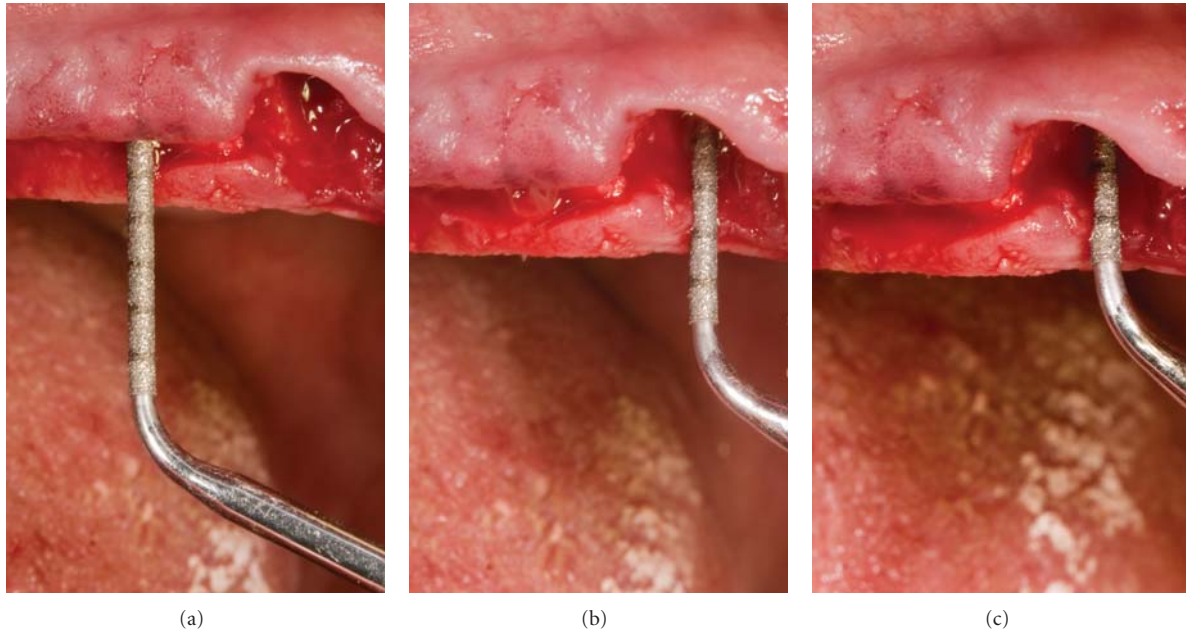


FIGURE 5: Use of piezoelectric inserts to prepare implant site.

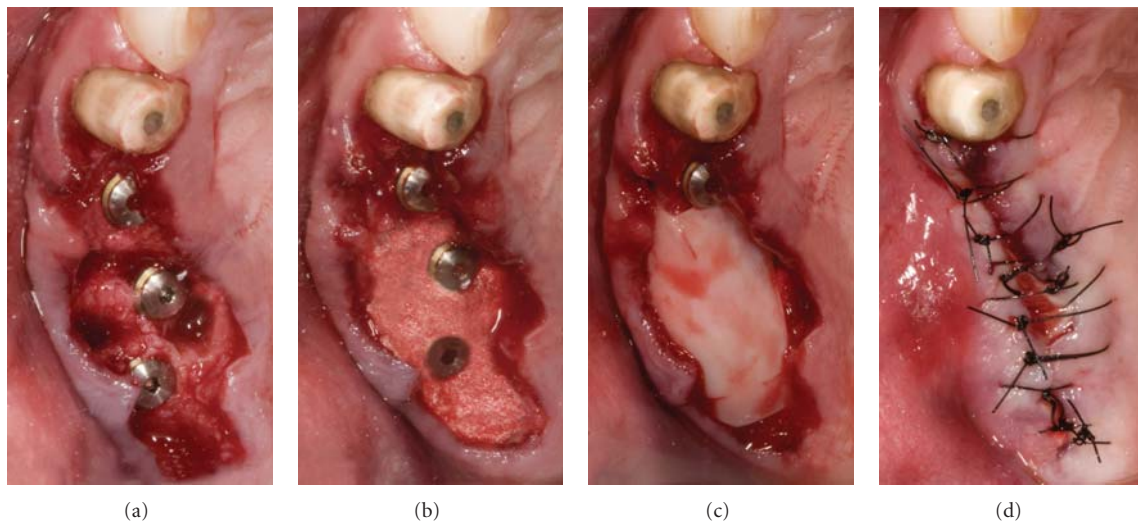


FIGURE 6: Gap filling and suture.

## 5. Discussion

Osteotome-mediated sinus lifting technique has been demonstrated to be a viable alternative option in implant rehabilitation of atrophic posterior maxilla [4–6]. However, the advantage of the use of bone graft was not clearly shown in previous reviews [6].

The review of literature performed in the present paper confirmed that osteotome sinus lift technique performed without the adjunctive use of any bone substitutes is a safe and effective procedure.

The cumulative survival rates for implants placed in non-grafted sites are comparable with those placed in augmented

grafted sites as was presented in previous systematic review [6].

The presented case report described implant placement in posterior atrophic maxilla. Osteotome sinus lifting technique was performed in a postextraction socket with the use of PRGF alone. Synthetic bone grafting material was used only to fill the gaps between implant and socket walls.

Crestal sinus lifting immediately after tooth extraction was described in few clinical reports [13, 33–35]. In the presented case report, a piezoelectric device was used in order to prepare implant site. Piezoelectric device allowed a more precise bone preparation of the socket walls where the use of standard drills could be complicated by the socket



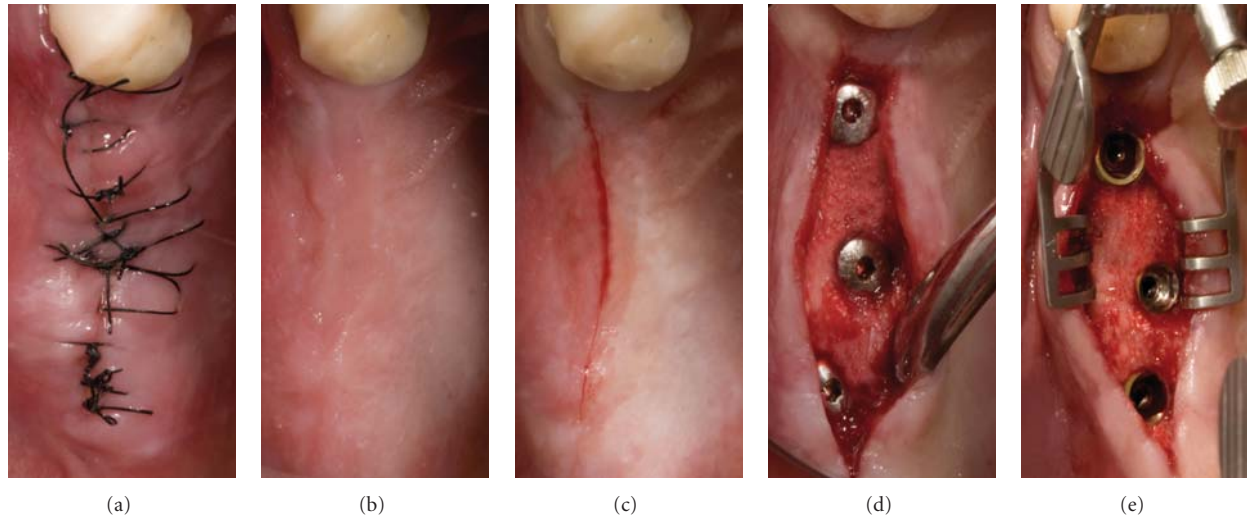


FIGURE 7: Second surgical phase.

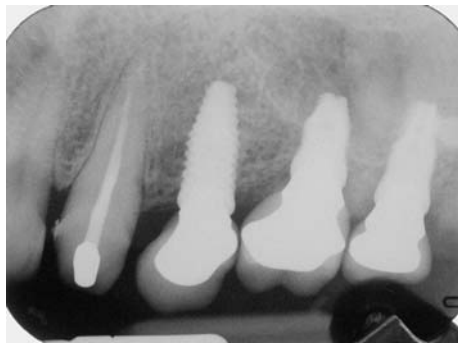


FIGURE 8: Radiographs taken at 6-month followup.

anatomy. Moreover, a piezoelectric preparation allowed the preservation of Schneiderian membrane in case of complete erosion of the sinus floor.

Platelet concentrate was used as an aid in membrane detachment acting as a cushion during the delicate use of osteotomes. The hydraulic pressure of PRGF clot caused a more controlled floor lifting avoiding excessive traumas to the cortical bone and to the Schneiderian membrane itself [12, 13, 36]. Furthermore, platelet derivatives can be beneficial to enhance soft tissue healing, reducing common postsurgical sequelae as swelling, pain, and hematoma [28, 29, 37]. This effect is achieved through the suppression of proinflammatory chemokines as IL-1 [38, 39] and through the release of many growth factors which promote tissue healing and regeneration [29].

In the presented case, a collagen membrane was then placed in contact with the PRGF clot, with the aim of guiding tissue regeneration in the apical portion.

After implant placement, the gaps between the fixture and the socket walls were filled by a mixture of biphasic synthetic bone and PRGF liquid. The biphasic material gives

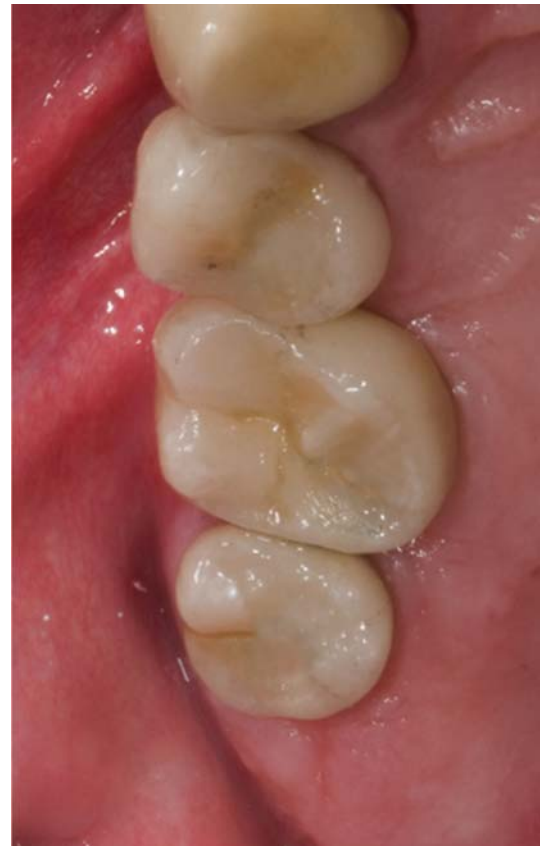

FIGURE 9: Occlusal view of the final prosthesis at 6-month followup.

a support to cellular adhesion and bone formation, but also a bioactivity that allows new bone formation [40, 41]. Moreover, it represented an ideal vehicle for PRGF growth factors and their release in the surrounding tissues [42].

The review of the scientific literature confirmed the successful outcomes of osteotome-mediated sinus lifting without the use of any bone substitute. This technique may be performed with the aid of platelet derivatives whose mechanical and biologic properties allow a safe detachment of the sinus membrane, possibly reducing the incidence of surgical and postsurgical complications.

The use of scaffold-like biomaterials to fill post-extraction sockets, when necessary, can emphasize the positive effect of platelet-derived factors, achieving an adequate bone filling, as shown in the present case report.

Although the presented technique may appear technically difficult, it showed a viable treatment option that could be considered and investigated through properly designed randomized controlled trials with adequate sample size.

## References

- [1] M. Del Fabbro, G. Rosano, and S. Taschieri, "Implant survival rates after maxillary sinus augmentation," *European Journal of Oral Sciences*, vol. 116, no. 6, pp. 497–506, 2008.
- [2] M. Peleg, A. K. Garg, and Z. Mazor, "Predictability of simultaneous implant placement in the severely atrophic posterior maxilla: a 9-year longitudinal experience study of 2,132 implants placed into 731 human sinus grafts," *International Journal of Oral and Maxillofacial Implants*, vol. 21, no. 1, pp. 94–102, 2006.
- [3] M. Esposito, M. G. Grusovin, J. Rees et al., "Effectiveness of sinus lift procedures for dental implant rehabilitation: a Cochrane systematic review," *European journal of oral implantology*, vol. 3, no. 1, pp. 7–26, 2010.
- [4] D. Emmerich, W. Att, and C. Stappert, "Sinus floor elevation using osteotomes: a systematic review and meta-analysis," *Journal of Periodontology*, vol. 76, no. 8, pp. 1237–1251, 2005.
- [5] W. C. Tan, N. P. Lang, M. Zwahlen, and B. E. Pjetursson, "A systematic review of the success of sinus floor elevation and survival of implants inserted in combination with sinus floor elevation Part II: transalveolar technique," *Journal of Clinical Periodontology*, vol. 35, no. 8, pp. 241–254, 2008.
- [6] M. Del Fabbro, S. Corbella, T. Weinstein, V. Ceresoli, and S. Taschieri, "Implant survival rates after osteotome-mediated maxillary sinus augmentation: a systematic review," *Clinical Implant Dentistry and Related Research*, vol. 14, no. s1, pp. 159–168, 2012.
- [7] H. Tatum Jr., "Maxillary and sinus implant reconstructions," *Dental clinics of North America*, vol. 30, no. 2, pp. 207–229, 1986.
- [8] R. B. Summers, "The osteotome technique: part 3—Less invasive methods of elevating the sinus floor," *Compendium*, vol. 15, no. 6, pp. 698–710, 1994.
- [9] M. Chanavaz, "Maxillary sinus: anatomy, physiology, surgery, and bone grafting related to implantology—eleven years of surgical experience (1979–1990)," *The Journal of Oral Implantology*, vol. 16, no. 3, pp. 199–209, 1990.
- [10] D. Schwartz-Arad, R. Herzberg, and E. Dolev, "The prevalence of surgical complications of the sinus graft procedure and their impact on implant survival," *Journal of Periodontology*, vol. 75, no. 4, pp. 511–516, 2004.
- [11] A. Katranji, P. Fotek, and H. L. Wang, "Sinus augmentation complications: etiology and treatment," *Implant Dentistry*, vol. 17, no. 3, pp. 339–349, 2008.
- [12] A. Diss, D. M. Dohan, J. Mouhyi, and P. Mahler, "Osteotome sinus floor elevation using Choukroun's platelet-rich fibrin as grafting material: a 1-year prospective pilot study with microthreaded implants," *Oral Surgery, Oral Medicine, Oral Pathology, Oral Radiology and Endodontology*, vol. 105, no. 5, pp. 572–579, 2008.
- [13] S. Taschieri and M. Del Fabbro, "Postextraction osteotome sinus floor elevation technique using plasma-rich growth factors," *Implant Dentistry*, vol. 20, no. 6, pp. 418–424, 2011.
- [14] R. Fermergård and P. Åstrand, "Osteotome sinus floor elevation and simultaneous placement of implants—a 1-year retrospective study with astra tech implants," *Clinical Implant Dentistry and Related Research*, vol. 14, no. 2, pp. 198–205, 2009.
- [15] J. Tetsch, P. Tetsch, and D. A. Lysek, "Long-term results after lateral and osteotome technique sinus floor elevation: a retrospective analysis of 2190 implants over a time period of 15 years," *Clinical oral implants research*, vol. 21, no. 5, pp. 497–503, 2010.
- [16] G. B. Bruschi, R. Crespi, P. Cappare, F. Bravi, E. Bruschi, and E. Gherlone, "Localized management of sinus floor technique for implant placement in fresh molar sockets," *Clinical Implant Dentistry and Related Research*. In press.
- [17] O. Gabbert, A. Koob, M. Schmitter, and P. Rammelsberg, "Implants placed in combination with an internal sinus lift without graft material: an analysis of short-term failure," *Journal of Clinical Periodontology*, vol. 36, no. 2, pp. 177–183, 2009.
- [18] M. Jurisic, A. Markovic, M. Radulovic, B. M. B. Brkovic, and G. K. B. Sándor, "Maxillary sinus floor augmentation: comparing osteotome with lateral window immediate and delayed implant placements. An interim report," *Oral Surgery, Oral Medicine, Oral Pathology, Oral Radiology and Endodontology*, vol. 106, no. 6, pp. 820–827, 2008.
- [19] R. Nedir, N. Nurdin, S. Szmukler-Moncler, and M. Bischof, "Placement of tapered implants using an osteotome sinus floor elevation technique without bone grafting: 1-year results," *The International Journal of Oral & Maxillofacial Implants*, vol. 24, no. 4, pp. 727–733, 2009.
- [20] R. Nedir, M. Bischof, L. Vazquez, N. Nurdin, S. Szmukler-Moncler, and J. P. Bernard, "Osteotome sinus floor elevation technique without grafting material: 3-year results of a prospective pilot study," *Clinical Oral Implants Research*, vol. 20, no. 7, pp. 701–707, 2009.
- [21] F. Cavicchia, F. Bravi, and G. Petrelli, "Localized augmentation of the maxillary sinus floor through a coronal approach for the placement of implants," *International Journal of Periodontics and Restorative Dentistry*, vol. 21, no. 5, pp. 475–485, 2001.
- [22] P. R. Schmidlin, J. Müller, A. Bindl, and T. Imfeld, "Sinus floor elevation using an osteotome technique without grafting materials or membranes," *International Journal of Periodontics and Restorative Dentistry*, vol. 28, no. 4, pp. 401–409, 2008.
- [23] B. Leblebicioglu, S. Ersanli, C. Karabuda, T. Tosun, and H. Gokdeniz, "Radiographic evaluation of dental implants placed using an osteotome technique," *Journal of Periodontology*, vol. 76, no. 3, pp. 385–390, 2005.
- [24] P. A. Fugazzotto, "Immediate implant placement following a modified trephine/osteotome approach: success rates of 116 implants to 4 years in function," *International Journal of Oral and Maxillofacial Implants*, vol. 17, no. 1, pp. 113–120, 2002.
- [25] S. Volpe, M. Lanza, D. Verrocchi, and L. Sennerby, "Clinical outcomes of an osteotome technique and simultaneous placement of neoss implants in the posterior maxilla," *Clinical Implant Dentistry and Related Research*. In press.

- [26] J. Fornell, L. A. Johansson, A. Bolin, S. Isaksson, and L. Sennerby, "Flapless, CBCT-guided osteotome sinus floor elevation with simultaneous implant installation. I: radiographic examination and surgical technique. A prospective 1-year follow-up," *Clinical Oral Implants Research*, vol. 23, no. 1, pp. 28–34, 2012.
- [27] G. B. Bruschi, R. Crespi, P. Capparè, and E. Gherlone, "Transcrestal sinus floor elevation: a retrospective study of 46 patients up to 16 years," *Clinical Implant Dentistry and Related Research*. In press.
- [28] E. Anitua, "The use of plasma-rich growth factors (PRGF) in oral surgery," *Practical Procedures & Aesthetic Dentistry*, vol. 13, no. 6, pp. 487–487, 2001.
- [29] E. Anitua, I. Andia, B. Ardanza, P. Nurden, and A. T. Nurden, "Autologous platelets as a source of proteins for healing and tissue regeneration," *Thrombosis and Haemostasis*, vol. 91, no. 1, pp. 4–15, 2004.
- [30] E. Anitua, R. Prado, and G. Orive, "A lateral approach for sinus elevation using PRGF technology," *Clinical Implant Dentistry and Related Research*, vol. 11, supplement 1, pp. e23–e31, 2009.
- [31] C. E. Misch, M. L. Perel, H. L. Wang et al., "Implant success, survival, and failure: the International Congress of Oral Implantologists (ICOI) pisa consensus conference," *Implant Dentistry*, vol. 17, no. 1, pp. 5–15, 2008.
- [32] M. Del Fabbro, S. Taschieri, and R. Weinstein, "Quality of life after microscopic periradicular surgery using two different incision techniques: a randomized clinical study," *International Endodontic Journal*, vol. 42, no. 4, pp. 360–367, 2009.
- [33] Z. Artzi, A. Parson, and C. E. Nemcovsky, "Wide-diameter implant placement and internal sinus membrane elevation in the immediate postextraction phase: clinical and radiographic observations in 12 consecutive molar sites," *International Journal of Oral and Maxillofacial Implants*, vol. 18, no. 2, pp. 242–249, 2003.
- [34] A. Barone, R. Cornelini, R. Ciaglia, and U. Covani, "Implant placement in fresh extraction sockets and simultaneous osteotome sinus floor elevation: a case series," *International Journal of Periodontics and Restorative Dentistry*, vol. 28, no. 3, pp. 283–289, 2008.
- [35] S. Kolhatkar, M. Bhola, and T. N. Thompson-Sloan, "Sinus floor elevation via the maxillary premolar extraction socket with immediate implant placement: a case series," *Journal of Periodontology*, vol. 82, no. 6, pp. 820–828, 2011.
- [36] M. Toffler, "Osteotome-mediated sinus floor elevation: a clinical report," *International Journal of Oral and Maxillofacial Implants*, vol. 19, no. 2, pp. 266–273, 2004.
- [37] E. Anitua, M. Sánchez, A. T. Nurden, P. Nurden, G. Orive, and I. Andía, "New insights into and novel applications for platelet-rich fibrin therapies," *Trends in Biotechnology*, vol. 24, no. 5, pp. 227–234, 2006.
- [38] H. El-Sharkawy, A. Kantarci, J. Deady et al., "Platelet-rich plasma: growth factors and pro- and anti-inflammatory properties," *Journal of Periodontology*, vol. 78, no. 4, pp. 661–669, 2007.
- [39] J. Woodall Jr., M. Tucci, A. Mishra, A. Asfour, and H. Benghuzzi, "Cellular effects of platelet rich plasma/interleukin1 release from prp treated macrophages," *Biomedical Sciences Instrumentation*, vol. 44, pp. 489–494, 2008.
- [40] D. Engler-Hamm, W. S. Cheung, A. Yen, P. C. Stark, and T. Griffin, "Ridge preservation using a composite: bone graft and a bioabsorbable membrane with and without primary wound closure: a comparative clinical trial," *Journal of Periodontology*, vol. 82, no. 3, pp. 377–387, 2011.
- [41] R. A. Canuto, R. Pol, G. Martinasso, G. Muzio, G. Gallesio, and M. Mozzati, "Hydroxyapatite paste Ostim((R)), without elevation of full-thickness flaps, improves alveolar healing stimulating BMP- and VEGF-mediated signal pathways: an experimental study in humans," *Clinical Oral Implants Research*. In press.
- [42] S. Ghanaati, M. Barbeck, R. Detsch et al., "The chemical composition of synthetic bone substitutes influences tissue reactions in vivo: histological and histomorphometrical analysis of the cellular inflammatory response to hydroxyapatite, beta-tricalcium phosphate and biphasic calcium phosphate ceramics," *Biomedical Materials*, vol. 7, no. 1, Article ID 015005, 2012.

## Clinical Study

# Biological Principles and Physiology of Bone Regeneration under the Schneiderian Membrane after Sinus Lift Surgery: A Radiological Study in 14 Patients Treated with the Transcrestal Hydrodynamic Ultrasonic Cavitational Sinus Lift (Intralift)

A. Troedhan,<sup>1</sup> A. Kurrek,<sup>2</sup> and M. Wainwright<sup>3</sup>

<sup>1</sup> Center for Facial Esthetics Vienna, Brauhausgasse 12-14, 1050 Vienna, Austria

<sup>2</sup> Implantology Clinic Ratingen, Lintorfer Straße 7, 40878 Ratingen, Germany

<sup>3</sup> Implantology Clinic Kaiserswerth, Kaiserswerther Markt 25, 40489 Düsseldorf, Germany

Correspondence should be addressed to A. Troedhan, troed@aon.at

Received 16 March 2012; Accepted 18 April 2012

Academic Editor: Silvio Taschieri

Copyright © 2012 A. Troedhan et al. This is an open access article distributed under the Creative Commons Attribution License, which permits unrestricted use, distribution, and reproduction in any medium, provided the original work is properly cited.

**Introduction.** Sinus lift procedures are a commonly accepted method of bone augmentation in the lateral maxilla with clinically good results. Nevertheless the role of the Schneiderian membrane in the bone-reformation process is discussed controversially. Aim of this study was to prove the key role of the sinus membrane in bone reformation in vivo. **Material and Methods.** 14 patients were treated with the minimal invasive tHUCSL-Intralift, and 2 ccm collagenous sponges were inserted subantrally and the calcification process followed up with CBCT scans 4 and 7 months after surgery. **Results.** An even and circular centripetal calcification under the sinus membrane and the antral floor was detected 4 months after surgery covering 30% of the entire augmentation width/height/depth at each wall. The calcification process was completed in the entire augmentation volume after 7 months. A loss of approximately 13% of absolute augmentation height was detected between the 4th and 7th month. **Discussion.** The results of this paper prove the key role of the sinus membrane as the main carrier of bone reformation after sinus lift procedures as multiple experimental studies suggested. Thus the importance of minimal invasive and rupture free sinuslift procedures is underlined and does not depend on the type of grafting material used.

## 1. Introduction

Although subantral augmentation procedures (Sinus lifting) can be considered as an established and highly successful method to multiply bone prior to implant insertion into the lateral maxilla site, the biological mechanisms of subantral bone regeneration are still focus of controversial scientific discussions.

While in the eighties and nineties of the past century the discussion on graft material inserted subantrally focused on free autologous bone grafts the mainstream research turned over to heterologous, allogenic, xenogenic and synthetic bone graft materials.

Concerning free autologous bone grafts most questions were already answered in the late sixties of the past century by Scandinavian scientists.

Puranen [1] proved free autologous bone grafts stored in room air to lose all biological activity within 90 minutes, when kept in saline solution within 3 hours. Bohr et al. [2] investigated the osteogenic potency of freshly harvested autologous bone grafts in comparison to deproteinized cadaver bone: although he reported a better reossification of the fresh free autologous transplants in the augmentation site in the first five days following surgery, the overall advantage of fresh autologous bone grafts was beyond any experimental and clinical significance after the standard healing period.

The key role of the periosteum in bone healing and regeneration was proven in other disciplines of medicine for quite a time [3–5] and was verified again only lately [6, 7] but mostly neglected in dentistry and oral surgery.

Lundgren et al. [8] 2004 found sufficient bone regeneration after Sinus lift surgery without the insertion of any bone



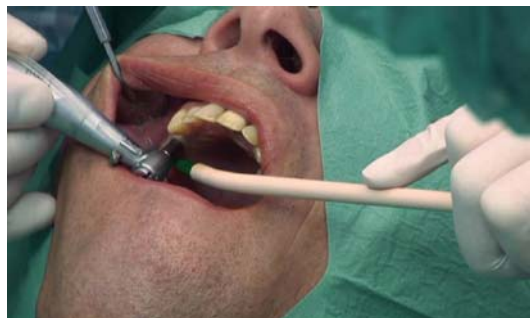

FIGURE 1: Intralift: 6 mm gingival punch or 6 × 6 mm top crestal flap to approach the alveolar crest.

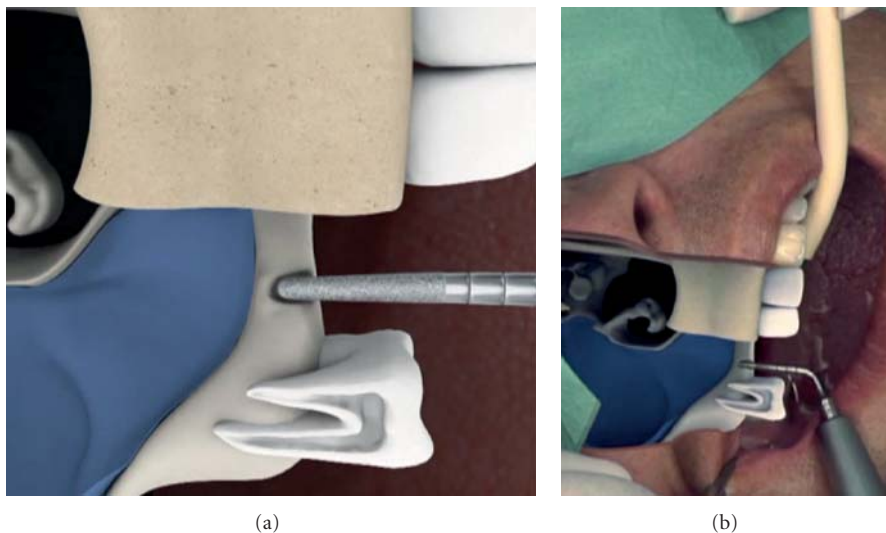


FIGURE 2: Intralift: trepanation of the subantral alveolar crest with the conical diamond coated tip TKW 1 for Piezotome.

graft material but sufficient bleeding into the subantral space but left open the answer to the question about the regeneration mechanisms which were then published by Srouji et al. in 2009 [9, 10]: the basal cell layer of the Schneiderian membrane is periosteum—as any other membrane covering vital bone like the Dura mater [5, 6]—that solely produces all necessary cellular and humoral factors for bone healing and bone regeneration such as Bone Morphing protein 2 (which has a key function in bone regeneration [11]), osteonectin, osteocalcin, and osteopontin.

Vital periosteum alone initiates bone regeneration and production in absence of any calcified structure or the presence of osteocytes needing only a stable blood coagulum as Srouji et al. were able to prove [10].

Based on the knowledge of the superior atraumaticity of ultrasonic surgery [12, 13] and of bone regeneration mechanisms under the Schneiderian membrane and the mandatory atraumatic detachment of the sinus membrane from the antral bone, the authors (TKW-Research-Group) developed the minimal invasive transcresal hydrodynamic ultrasonic cavitation Sinus lift (tHUCSL-Intralift) for Piezotome I/II/SOLO in cooperation with Satelec-ACTEON/France to preserve the sinus-membrane and its key function in the later bone regeneration [14–17].

The aim of the present study was to verify *in vivo* the postulated bone regeneration capabilities of the periosteum of the Schneiderian membrane in patients treated with the

tHUCSL-Intralift by detecting the origins of the calcification process radiographically on macroscopical level.

## 2. Material and Methods

Within a multicenter study on the success rates of the tHUCSL-Intralift using various radiopaque bone graft materials for subantral augmentation, 14 patients (8 female, 6 male) at an average age of 52 yrs ( $\pm 16$  yrs) were selected with vastly pneumatized sinuses on the right side and remaining subantral alveolar crest heights of 4 mm or less. Instead of radiopaque bone graft material only, a radiolucid collagenous sponge of a stable and defined volume of approximately 2 ccm was inserted subantrally to radiographically follow up the origins of new bone growth and calcification processes in CBCT scans to indirectly verify the findings by Lundgren et al. [8] and Srouji et al. [9, 10] in human sinuses *in vivo*.

Sinus lift surgery on the right maxillary sinus was performed according to the strict tHUCSL-Intralift protocol.

The subantral alveolar crest was revealed by either a single or dual 6 mm diameter gingival punch or an 6 mm rectangular top crestal mucoperiosteal flap (Figure 1). A pilot trepanation was performed with the diamond-coated TKW 1 ultrasonic tip for Piezotome I/II/SOLO (Satelec-ACTEON/France) (Figure 2).

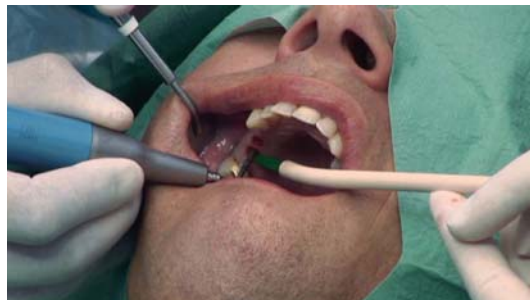

FIGURE 3: Intralift: opening of the sinus floor with the round diamond coated tip TKW2 for Piezotome.

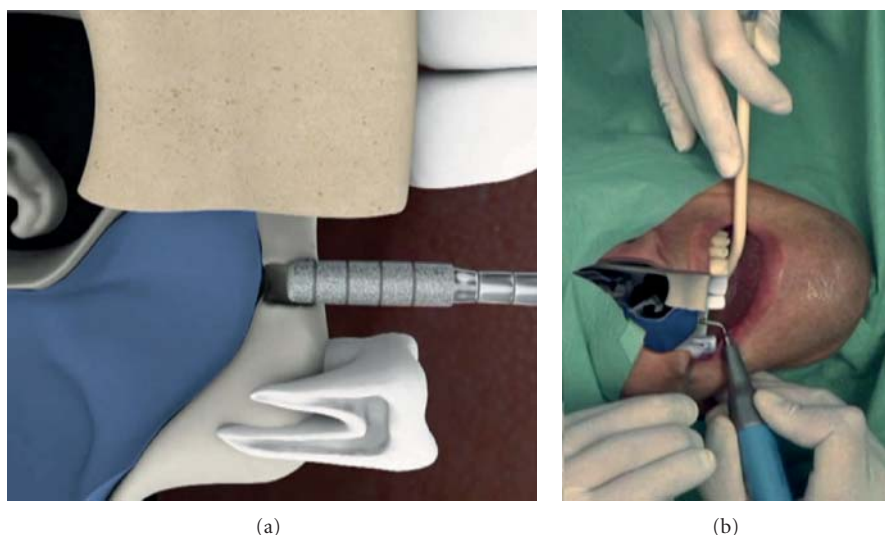


FIGURE 4: Intralift: preparation of the receptacle for the hydrodynamic cavitation ultrasound applicator with the diamond-coated tip TKW4 for Piezotome (preparation of a ventile seat).

The sinus floor was opened with the diamond-coated atraumatic TKW 2-ultrasonic tip (Figure 3) followed by the preparation of a receptacle for the elevation applicator TKW 5 with the flat diamond-coated TKW 4 ultrasonic tip (Figure 4).

The sinus membrane then was atraumatically separated from the antral bone with the hydrodynamic ultrasonic cavitation applicator TKW 5 (Figure 5) at a flow rate of saline solution of 30 mL/min for 5 seconds thus creating a subantral volume of 2,5 ccm under the elevated sinus membrane. (Although the differences in physics between a hydraulic and a hydrodynamic cavitation separation of the sinus membrane from the bone are significant, the basic process can be circumscribed as detaching and elevating the membrane with water-pressure).

Once the elevated sinus-membrane was verified to float free and unperforated/unruptured in the traditional unilateral Valsalva check, a form stable radiolucent collagenous sponge of approximately 2 ccm (Implante Colageno/EURO-Klee/Spain or Parasorb-Dentalkegel/RESORBA/Germany, (Figures 6(a)–6(e)) was inserted subantrally instead of radiopaque bone graft material to stabilize the elevated sinus membrane as well as the blood clot forming underneath and maintain the elevation volume achieved with

the tHUCSL-Intralift procedure. Patients were followed up for pain, swelling, and any sign of nightly bleeding out of the corresponding nostril and/or observation of blood-contaminated sputum and/or unusual sneezing attacks one, two, three, and seven days after surgery. Implants were inserted into the augmented site 8 months after tHUCSL-Intralift and prosthodontic treatment latest completed 11-12 months after initial Intralift surgery.

Radiographic followup was performed 4 and 7 months following surgery with calibrated CBCT scans and the scans modulated with sharpness, edge detection and contrast filters as well as additive and subtractive grayscale enhancement filters for better distinction between soft and hard tissues. The calcification process was determined with grayscale match algorithms to the surrounding natural bone in mm in the augmentation area with the augmentation center as origin (Figure 7 white arrow) in transversal, sagittal, and horizontal scan slides with the calibrated CBCTs measurement tool.

Measurements were taken in mm measuring the absolute height of the augmentation including the alveolar crest in transversal and sagittal slides (Figure 7 yellow arrow) and in 3, 6, 9, and 12 o'clock position (Figure 7 red reference cross) centripetally from the outer line of the visible calcification to the center. The maximum vertical height of

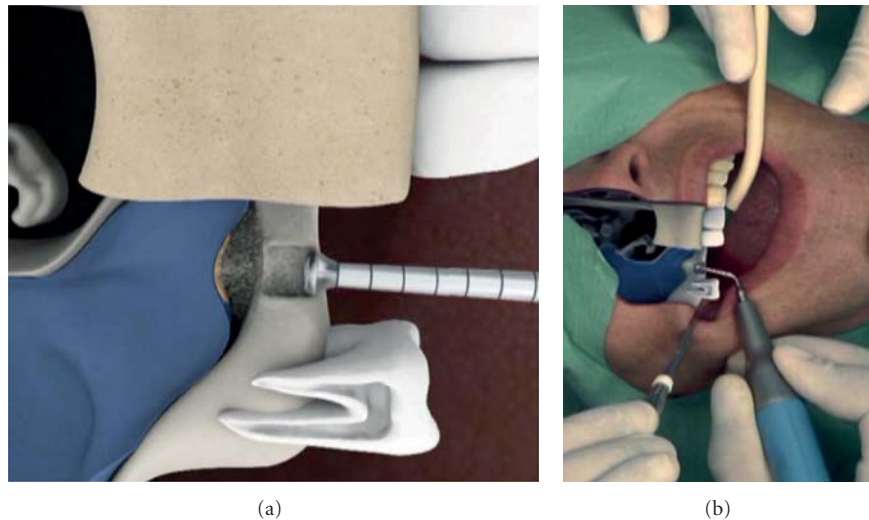


FIGURE 5: Intralift: detachment of the sinus membrane with the detachment applicator TKW5 which is sealed towards the oral cavity by the receptacle. By hydrodynamic cavitation pressure the sinus membrane is elevated and a subantral volume of 2,5 ccm created.

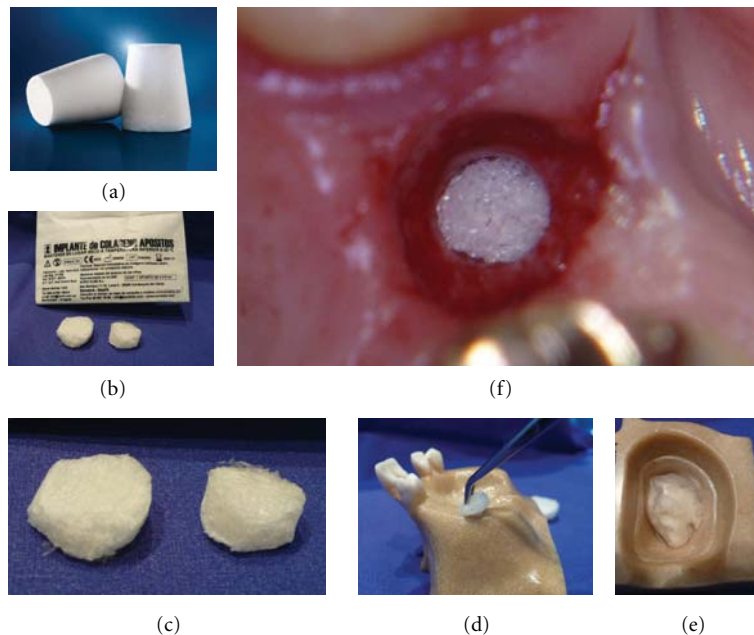


FIGURE 6: Collagenous sponges used: (a) Resorba Dentalkegel/Resorba/GER (1,9 ccm), ((b), (c)) Implante Colageno/EURO-Klee/ES (2,0 ccm), (d) insertion demonstration on a training model (the sponge is inserted after the sinus-membrane was elevated with the Intralift method), (e) view from inside the sinus in a training model, (f) surgical site with sponge inserted.

the augmentation site was measured in the transversal and sagittal slides including the alveolar crest since a precise radiological separation of the newly formed bone from the remaining alveolar crest was not possible. The same procedure was applied to all measurements in 6 o'clock position.

### 3. Results


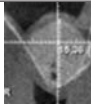
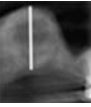
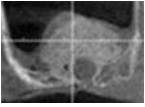
All 14 tHUCSL Intralift Sinus lift procedures were conducted without perforation of the sinus membrane, and no postsurgical complications suspicious of sinus-membrane perforations occurred. The mean height of the alveolar crest

in the 14 study patients was 3,2 mm (st. dev.  $\pm$  0,8 mm) at the entrance site of the Intralift procedure measured intraoperatively.

Figure 8 shows a typical presurgical (Figure 8(a)) and immediate postsurgical (Figure 8(b)) panoramic X-ray of a female study patient. In most cases the inserted sponge was similar to a typical mucocele or was not detectable at all in panoramic X-rays.

CBCT scans after 4 months revealed an average achieved augmentation height of 16,3 mm in the transversal slides (st. dev. 2,2 mm) and 16,8 mm in the sagittal slide (st.dev. 2,6 mm) which was reduced to an average of 14,6 mm in the transversal slides and 14,7 mm in the sagittal slides after 7 months (Table 1).

TABLE 1: Mean values in mm of absolute augmentation heights achieved after 4 and 7 months in sagittal and transversal CBCT slides (reference is the highest point).

	CBCT 4 month	14 sites mean (mm)	CBCT 7 month	14 sites mean (mm)
Vertical height absolute transversal slide (A)		16,3 St. dev. 2,2		14,6 St. dev. 1,9
Vertical height absolute sagittal slide (B)		16,8 St. dev. 2,6		14,7 St. dev. 1,8

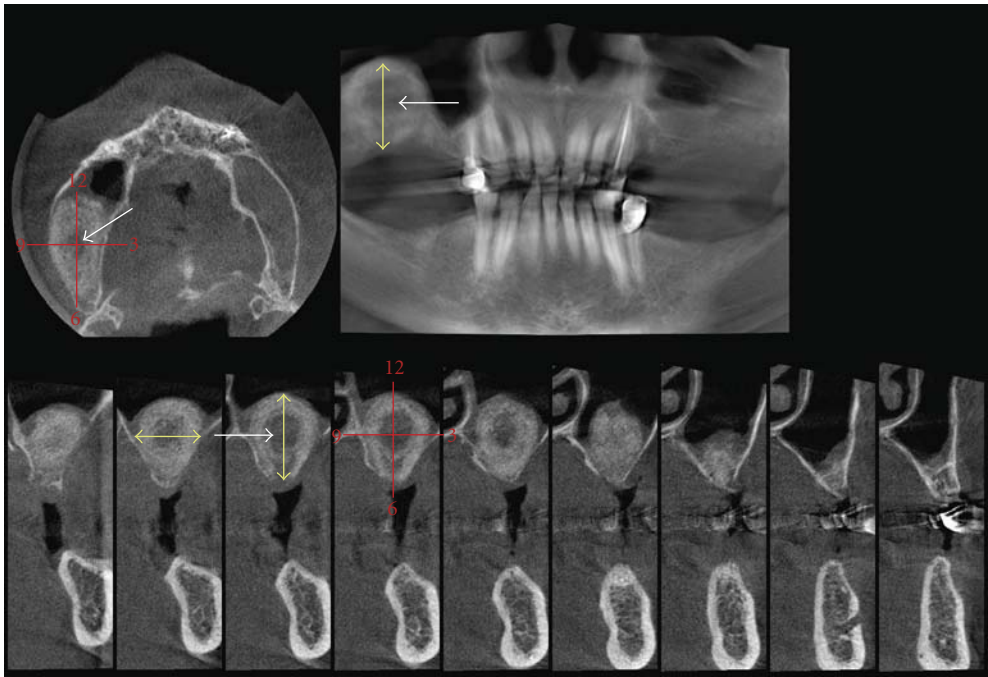


FIGURE 7: CBCT scan measurements: yellow arrows: total distances height/width/depth, red reference cross: measurements of calcification thicknesses in 3, 6, 9, and 12 o'clock position.

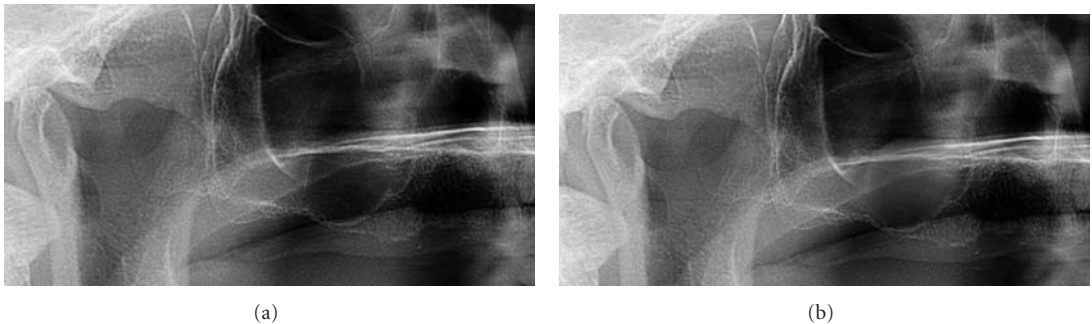


FIGURE 8: Immediate presurgical (a) and postsurgical (b) OPG: the collagenous sponge shows similar to a mucocoele or less.













The calcification process under the sinus-membrane radiologically showed an even centripetal circular distribution under the sinus-membrane and on the antral bone base with calcified tissue thicknesses of 3,6 mm to 4,3 mm (excluding all measurements in 6 o'clock position since these

measurements include the original alveolar crest height) (Table 2, Figure 9).

After a healing period of 7 months all CBCT scans showed a completion of the calcification process in the augmented subantral volume except some randomly distributed



TABLE 2: Mean values in mm of calcified tissue thicknesses in 3, 6, 9, and 12 o'clock position in CBCT scans after 4 and 7 months (for reference measurement positions for transversal, sagittal, and horizontal see Figure 6).

	CBCT 4 month	14 sites mean (mm)	CBCT 7 month	14 sites mean (mm)
Transversal 3 o'clock pos.		3,6 St. dev. 0,3		n/a
Transversal 6 o'clock pos. (incl. alv. crest) (C)		5,9 St. dev. 1,2		n/a
Transversal 9 o'clock pos.		3,8 St. dev. 0,4		n/a
Transversal 12 o'clock pos. (D)		4,1 St. dev. 0,3		n/a
Sagittal 3 o'clock pos.		4,0 St. dev. 0,6		n/a
Sagittal 6 o'clock pos. (incl. alv. crest) (E)		6,1 St. dev. 1,3		n/a
Sagittal 9 o'clock pos.		3,6 St. dev. 0,4		n/a
Sagittal 12 o'clock pos. (F)		4,3 St. dev. 0,4		n/a
Horizontal 3 o'clock pos.		4,2 St. dev. 0,5		n/a
Horizontal 6 o'clock pos.		4,1 St. dev. 0,4		n/a
Horizontal 9 o'clock pos.		3,9 St. dev. 0,2		n/a
Horizontal 12 o'clock pos.		3,8 St. dev. 0,3		n/a

minor radiolucent spots/areas thus not allowing a precise distinction for measurement between noncalcified areas and calcified tissue (Table 2, Figure 10).

The mean loss of absolute augmentation height of calcified tissue in the CBCT scans between 4 months and 7 months after surgery was 1,9 mm resulting in a final mean overall height of calcified tissue for implant insertion of 14,65 mm (Table 3).

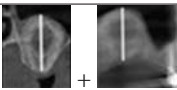
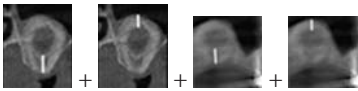
After 4 month approximately a third of the subantral augmented volume in each measurement position (3, 6, 9, 12 o'clock) related to the total width/height/depth of the augmentation was presented as calcified tissue in the CBCT

scans (Table 3, Figure 9). No precise distinction between calcified and noncalcified tissue could be made in the CBCT scans after 7 months.

All patients were successfully treated with two-stage dental implants from various manufacturers (mostly Q2-Implant/TRINON Karlsruhe GmbH/Germany, BEGO RI/BEGO/Germany, SICace/SIC-Group/Germany and others) after 8 months and prosthetic suprastructure after 11-12 months (Figure 11).

Figures 12, 13, 14, 15, 16, 17, 18, 19, and 20 show two more typical cases of the present study.

TABLE 3: Mean values in mm of absolute augmentation height loss in CBCT scans between 4 and 7 months after surgery and mean percentage of calcified tissue in 3, 6, 9, and 12 o'clock position in relation to entire distance measured (A, B ref. Table 1, C, D, E, F ref. Table 2).

Mean values		CBCT 4 month mm	CBCT 7 month mm
Mean Value (A) + (B) = X		16,55 (i)	14,65 (ii)
Mean (i)-(ii)			1,90
Mean Value (C) + (D) + (E) + (F) = Y		5,1	n/a
Mean % X/Y		32,5%	n/a

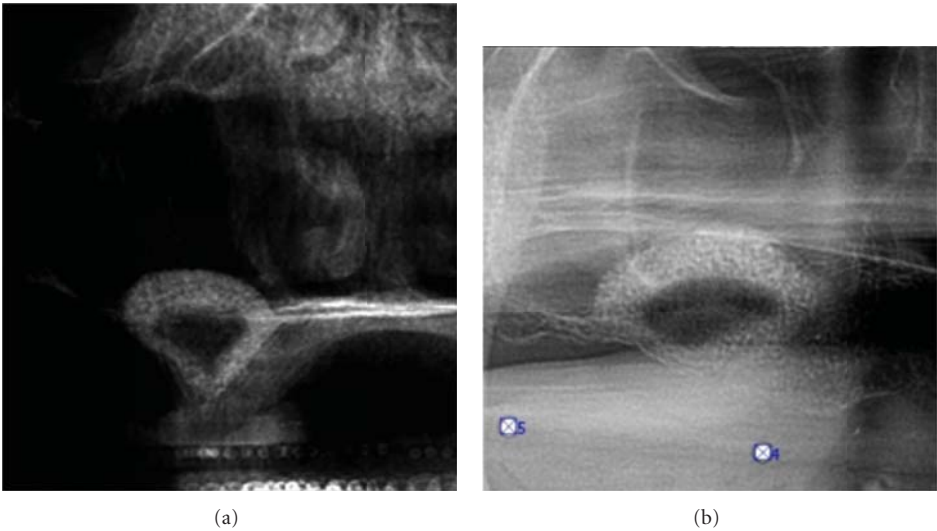


FIGURE 9: Transversal and parasagittal CBCT scan 4 months subsequent to tHUCSL-Intralift. The even circular centripetal calcification process can be observed.

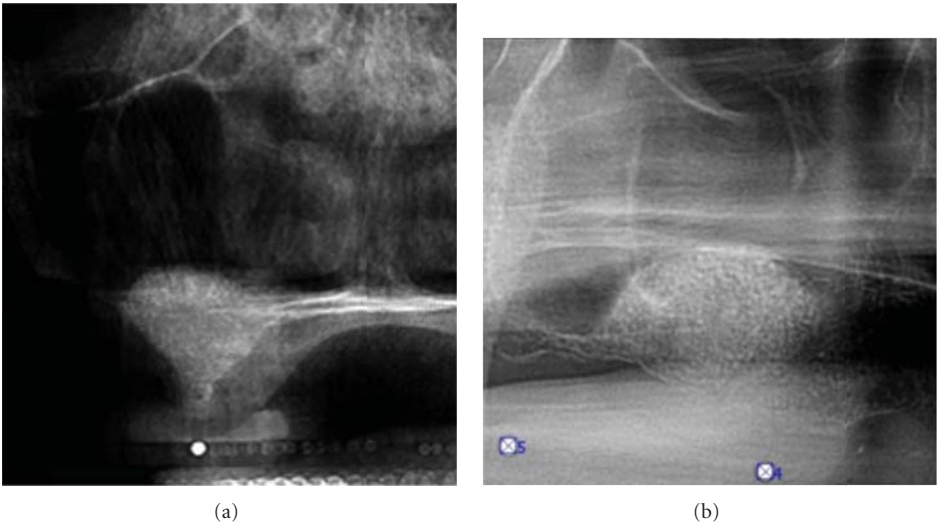


FIGURE 10: Transversal and parasagittal CBCT-scan 7 months post tHUCSL-Intralift. The ossification process is obviously completed.

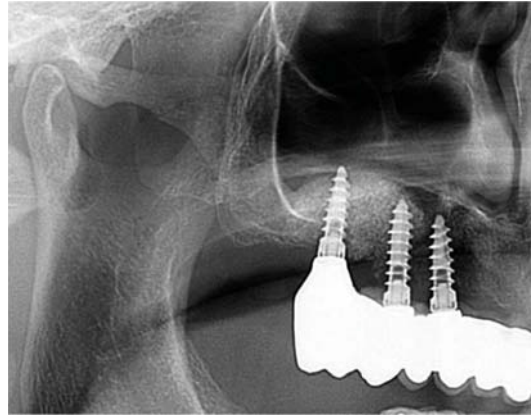


FIGURE 11: OPG with final prosthetic treatment after 11 months.

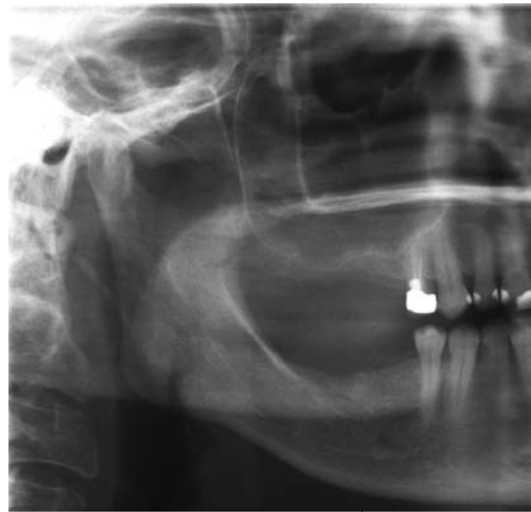

FIGURE 12: Case 2: presurgical condition in panoramic X-ray.

#### 4. Discussion

The radiological results of the present study confirm the experimental results published by Ortak et al. [7], Lundgren et al. [8], and Srouji et al. [9, 10] in vivo and suggest the Schneiderian membrane to be the primary carrier of bone reformation in Sinus lift procedures providing the necessary osteoprogenitor cells and humoral factors for bone regeneration [9, 11].

Nevertheless a volume stable subantral filling material is needed to stabilize the detached sinus membrane and formation of a blood coagulum in the upmost position to achieve sufficient augmentation heights and widths for implant insertion but the success of Sinus lift procedures does not seem to depend on the type of augmentation material (autologous, heterologous, xenogenic, synthetic calcified bone grafts) used. The results of this study proved a form stable collagenous sponge to be sufficient in stabilizing the sinus-membrane above the achieved subantral augmentation volume as well as the resulting stable blood clot forming in the collagenous sponge.

A general forensic drawback in using collagenous sponges in subantral augmentation procedures might be the inability to prove the successful Sinus lift immediately after surgery since in an OPG, a radiolucent sponge can hardly be detected (Figure 8(b) and 17(b)) and only verified by the bone formation and calcification process after 3-4 months (Figures 9 and 18) or at the time of implant insertion. To establish such a subantral augmentation procedure would call for mandatory radiopaque collagenous sponges to enable radiographic verification but would possibly decrease expenses for augmentation materials.

If the reduction of absolute augmentation height of an average of 2 mm between the 4th and the 7th month subsequent surgery could be prevented by the use of calcified bone graft instead of a collagenous sponge still has to be further investigated by a similar study protocol but has to be taken into consideration in the daily routine to prevent finally insufficient augmentation heights when using radiopaque collagenous sponges. Compared to the results of the surgical technique reported by Lundgren et. al. [8]

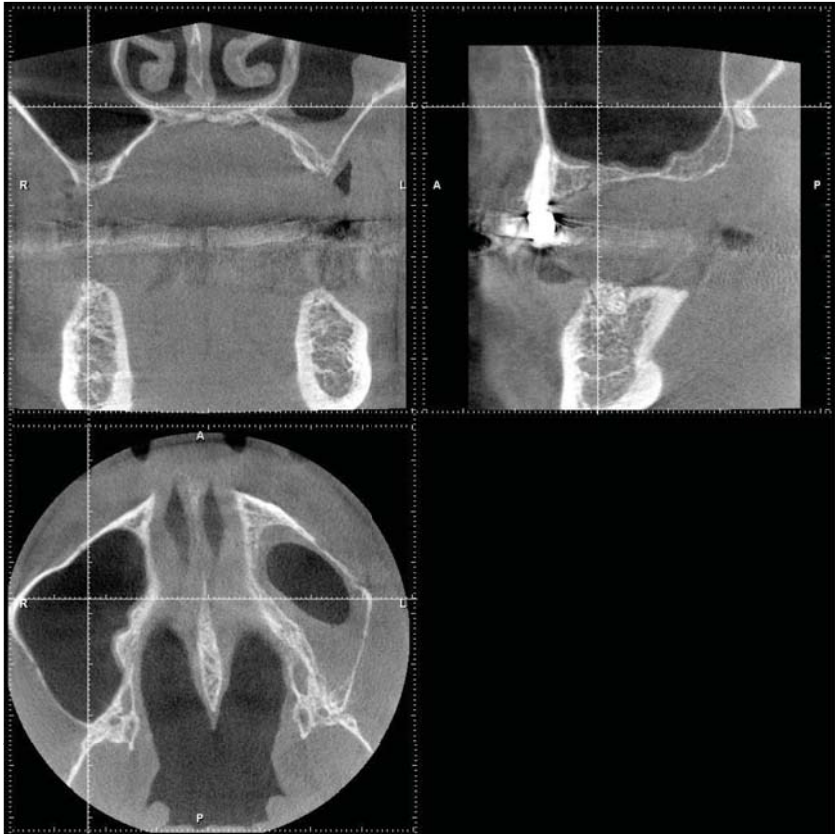

FIGURE 13: Case 2: presurgical situation in transversal, paramedian sagittal and horizontal CBCT-scan.

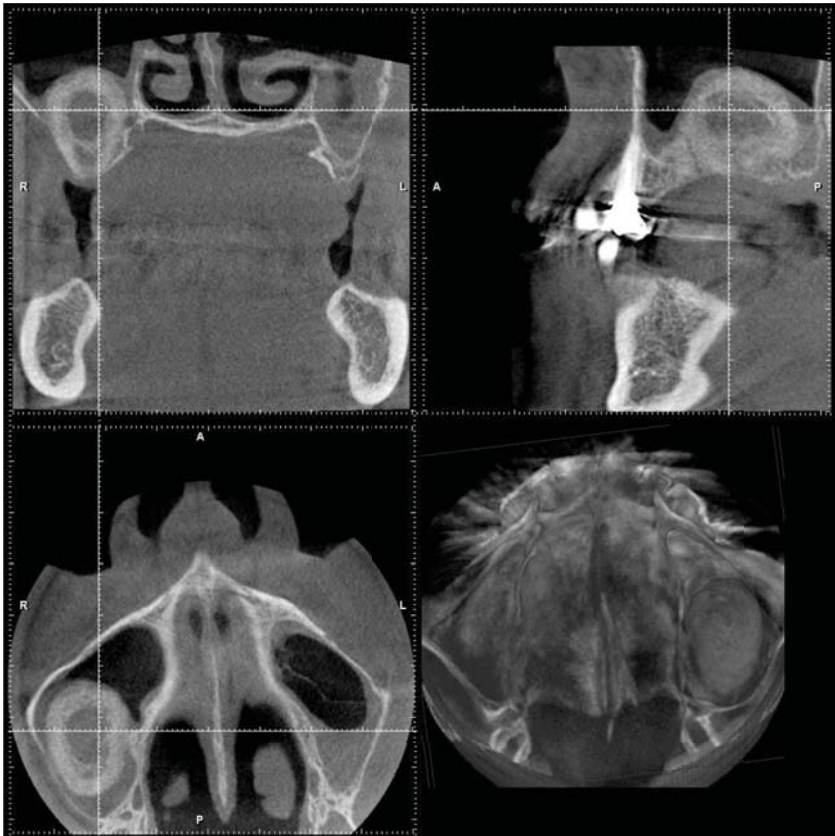


FIGURE 14: Case 2: CBCT scan 4 months following tHUCSL-Intralift. The even circular centripetal calcification process can be observed.



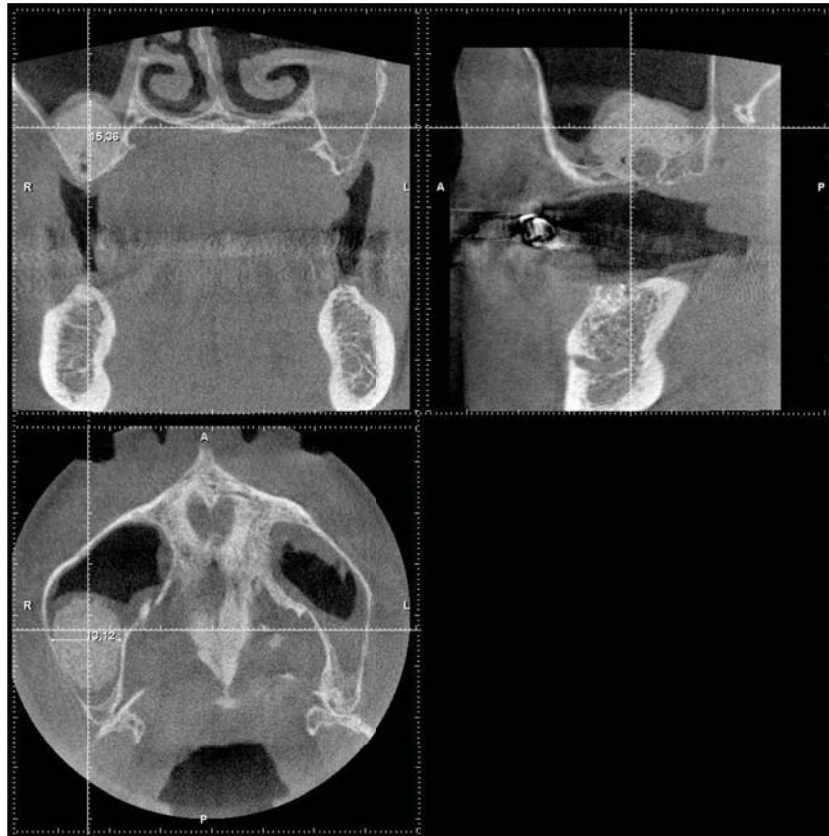

FIGURE 15: Case 2: CBCT scan 7 months after tHUCSL-Intralift: the completion of the calcification process except some smaller patches of undermineralized areas can be observed.

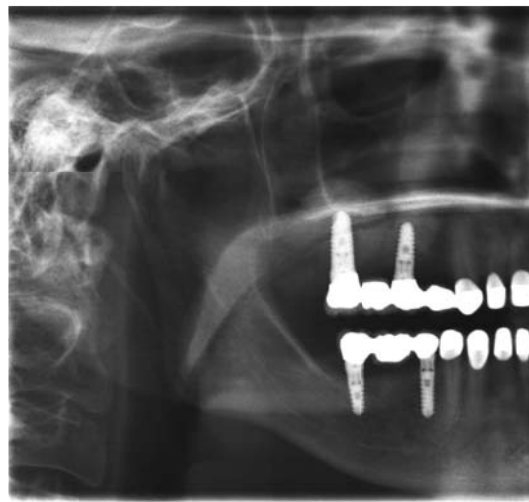


FIGURE 16: Follow-up panoramic X-ray after completion of implant insertion and prosthetic treatment 12 months following tHUCSL-Intralift.

the insertion of a collagenous sponge seems to have advantages concerning more sufficient final augmentation heights.

Furthermore the results of this study suggest that after an overall period of 7 months following minimal invasive transcresal Sinus lift, the calcification process of the augmented subantral site seems to be completed in all cases

even at augmentation volumes of 2 ccm. Nevertheless this healing duration might not be applicable to lateral approach of sinus lift procedures or cases of iatrogenic puncture or minor ruptures of the sinus-membrane due to a vaster traumatization of the sinus-membrane and surgical site. This probably might result in longer bone formation and

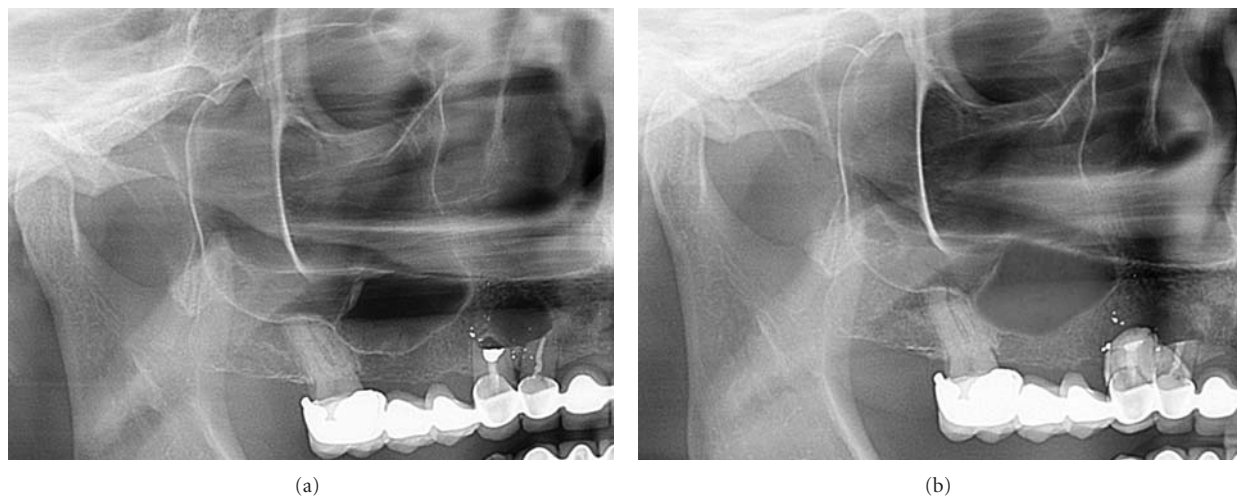


FIGURE 17: Case 3: presurgical (a) and immediate postsurgical (b) OPG: the collagenous sponge is almost not detectable. In this case the tHUCSL-Intralift was performed paracrestally from the buccal side due to the insufficient old bridge in site.

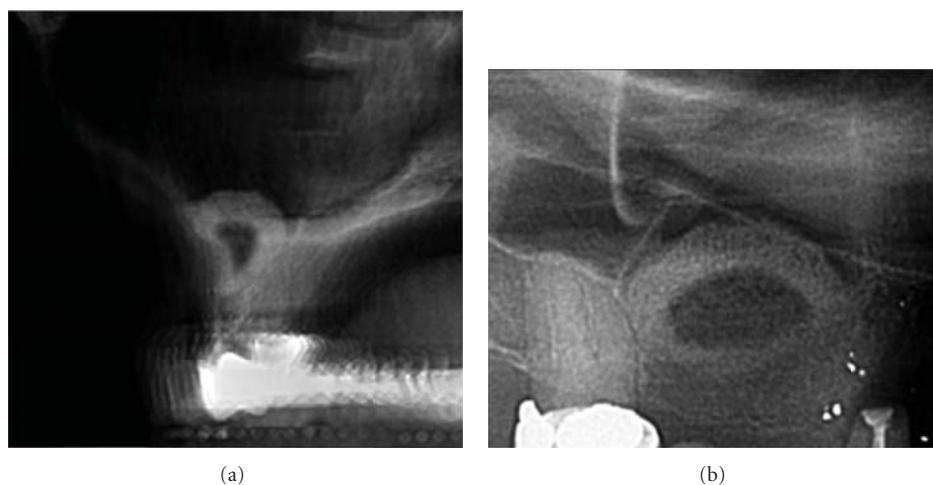


FIGURE 18: Case 3: transversal and parasagittal CBCT scan 4 months after tHUCSL-Intralift. The even circular centripetal calcification process can be observed.

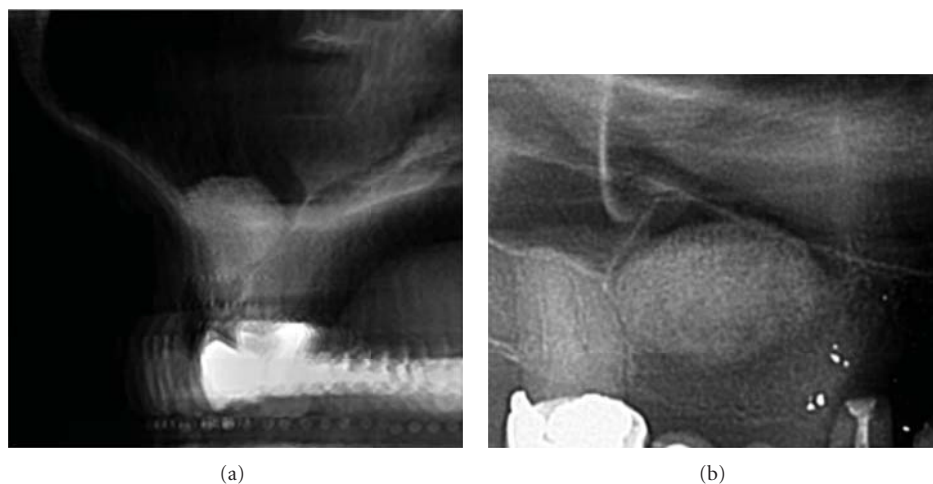


FIGURE 19: Case 3: transversal and parasagittal CBCT scan 7 months following tHUCSL-Intralift. The ossification process is obviously completed. A slim denser line on the antral floor marks the transition to the original alveolar crest.

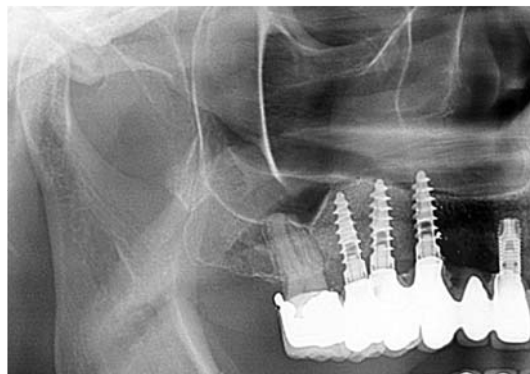


FIGURE 20: Case 3: panoramic X-ray after final prosthetic treatment after 11 months.

calcification duration due to healing processes and primary repair of the traumatized tissue before the bone formation and calcification process starts.

Finally the authors generally suggest to more rely on the osteogenic potential of the periosteum [4–7] and minimal invasive surgical techniques not only in Sinus lift procedures than on grafting materials of various kinds.

## References

- [1] J. Puranen, "Reorganization of fresh and preserved bone transplants. An experimental study in rabbits using tetracycline labelling," *Acta Orthopaedica Scandinavica*, vol. 92, supplement, pp. 1–75, 1966.
- [2] H. Bohr, H. O. Ravn, and H. Werner, "The osteogenic effect of bone transplants in rabbits," *Journal of Bone and Joint Surgery Series B*, vol. 50, no. 4, pp. 866–873, 1968.
- [3] T. Skoog, "The use of periosteum and Surgicel for bone restoration in congenital clefts of the maxilla. A clinical report and experimental investigation," *Scandinavian Journal of Plastic and Reconstructive Surgery*, vol. 1, no. 2, pp. 113–130, 1967.
- [4] E. Engdahl, "Bone regeneration in maxillary defects. An experimental investigation on the significance of the periosteum and various media (blood, surgicel, bone marrow and bone grafts) on bone formation and maxillary growth," *Scandinavian Journal of Plastic and Reconstructive Surgery*, vol. 8, pp. 1–79, 1972.
- [5] P. C. Hobar, J. A. Masson, R. Wilson, and J. Zerwekh, "The importance of the dura in craniofacial surgery," *Plastic and Reconstructive Surgery*, vol. 98, no. 2, pp. 217–225, 1996.
- [6] D. Celik, T. Turan, and F. Kabukcuoglu, "Bone induction capacity of the periosteum and neonatal dura in the setting of the zygomatic arch fracture model," *Archives of Facial Plastic Surgery*, vol. 5, pp. 301–308, 2003.
- [7] T. Ortak, R. Özdemir, A. Uysal et al., "Osteogenic capacities of periost grafts, periost flaps and prefabricated periosteal flaps: experimental study," *Journal of Craniofacial Surgery*, vol. 16, no. 4, pp. 594–600, 2005.
- [8] S. Lundgren, S. Andersson, F. Gualini, and L. Sennerby, "Bone reformation with sinus membrane elevation: a new surgical technique for maxillary sinus floor augmentation," *Clinical Implant Dentistry and Related Research*, vol. 6, no. 3, pp. 165–173, 2004.
- [9] S. Srouji, T. Kizhner, D. Ben David, M. Riminucci, P. Bianco, and E. Livne, "The schneiderian membrane contains osteoprogenitor cells: in vivo and in vitro study," *Calcified Tissue International*, vol. 84, no. 2, pp. 138–145, 2009.
- [10] S. Srouji, D. Ben-David, R. Lotan, M. Riminucci, E. Livne, and P. Bianco, "The innate osteogenic potential of the maxillary sinus (Schneiderian) membrane: an ectopic tissue transplant model simulating sinus lifting," *International Journal of Oral and Maxillofacial Surgery*, vol. 39, no. 8, pp. 793–801, 2010.
- [11] P. J. Boyne, L. C. Lilly, R. E. Marx et al., "De novo bone induction by recombinant human bone morphogenetic protein-2 (rhBMP-2) in maxillary sinus floor augmentation," *Journal of Oral and Maxillofacial Surgery*, vol. 63, no. 12, pp. 1693–1707, 2005.
- [12] S. Stübinger, C. Landes, O. Seitz, H. F. Zeilhofer, and R. Sader, "Ultrasonic bone cutting in oral surgery: a review of 60 cases," *Ultraschall in der Medizin*, vol. 29, no. 1, pp. 66–71, 2008.
- [13] A. Troedhan, A. Kurrek, and M. Wainwright, "Ultrasonic piezotome surgery: is it a benefit for our patients and does it extend surgery time? A retrospective comparative study on the removal of 100 impacted mandibular 3rd molars," *Open Journal of Stomatology*, vol. 1, pp. 179–184, 2011.
- [14] A. C. Troedhan, A. Kurrek, M. Wainwright, and S. Jank, "Hydrodynamic ultrasonic sinus floor elevation—an experimental study in sheep," *Journal of Oral and Maxillofacial Surgery*, vol. 68, no. 5, pp. 1125–1130, 2010.
- [15] S. Jank, A. Kurrek, M. Wainwright, V. E. Bek, and A. Troedhan, "Rupture length of the sinus membrane after 1.2 mm puncture and surgical sinus elevation: an experimental animal cadaver study," *Oral Surgery, Oral Medicine, Oral Pathology, Oral Radiology and Endodontology*, vol. 112, no. 5, pp. 568–572, 2011.
- [16] R. Velázquez-Cayón, M.-M. Romero-Ruiz, D. Torres-Lagares et al., "Hydrodynamic ultrasonic maxillary sinus lift: review of a new technique and presentation of a clinical case," *Medicina Oral, Patología Oral y Cirugía Bucal*, vol. 17, no. 2, pp. 271–275, 2012.
- [17] M. Wainwright, A. Troedhan, and A. Kurrek, "The IntraLift: a new minimal invasive ultrasonic technique for sinus grafting procedures, implants," *International Journal of Implantology*, vol. 3, pp. 30–34, 2007.