

**Advances in Urology**

# **Penile Reconstructive Surgery**

**Guest Editor: Miroslav L. Djordjevic**





---

# **Penile Reconstructive Surgery**

Advances in Urology

---

## **Penile Reconstructive Surgery**

Guest Editor: Miroslav L. Djordjevic



Copyright © 2008 Hindawi Publishing Corporation. All rights reserved.

This is a special issue published in volume 2008 of "Advances in Urology." All articles are open access articles distributed under the Creative Commons Attribution License, which permits unrestricted use, distribution, and reproduction in any medium, provided the original work is properly cited.



## Editor-in-Chief

Richard A. Santucci, Detroit Medical Center, USA

## Advisory Editor

Markus Hohenfellner, Germany

## Associate Editors

Hassan Abol-Enein, Egypt  
Darius J. Bagli, Canada  
Fernando J. Bianco, USA  
Steven B. Brandes, USA  
Robert E. Brannigan, USA  
James Brown, USA  
Peter Clark, USA  
Donna Deng, USA  
Paddy Dewan, Australia  
Miroslav L. Djordjevic, Serbia

Walid A. Farhat, Canada  
Christopher M. Gonzalez, USA  
Narmada Gupta, India  
Edward Kim, USA  
Badrinath Konety, USA  
Daniel W. Lin, USA  
William Lynch, Australia  
Maxwell V. Meng, USA  
Hiep Nguyen, USA  
Sangtae Park, USA

David F. Penson, USA  
Michael P. Porter, USA  
Jose Rubio Briones, Spain  
Douglas Scherr, USA  
Norm D. Smith, USA  
Arnulf Stenzl, Germany  
Flavio Trigo Rocha, Brazil  
Willie Underwood, USA

# Contents

**Penile Reconstructive Surgery**, Miroslav L. Djordjevic

Volume 2008, Article ID 564032, 2 pages

**Hypospadias**, N. Djakovic, J. Nyarangi-Dix, A. Özturk, and M. Hohenfellner

Volume 2008, Article ID 650135, 7 pages

**Tunneled Tunica Vaginalis Flap for Recurrent Urethrocuteaneous Fistulae**, Jonathan C. Routh, James J. Wolpert, and Yuri Reinberg

Volume 2008, Article ID 615928, 3 pages

**Adult Urethral Stricture Disease after Childhood Hypospadias Repair**, Shou-Hung Tang,

Clarisa C. Hammer, Leo Doumanian, and Richard A. Santucci

Volume 2008, Article ID 150315, 4 pages

**Male Genitoplasty for Intersex Disorders**, Shilpa Sharma and Devendra K. Gupta

Volume 2008, Article ID 685897, 5 pages

**Review of the Surgical Approaches for Peyronie's Disease: Corporeal Plication and Plaque Incision with Grafting**, Viet Q. Tran, Dennis H. Kim, Timothy F. Lesser, and Sherif R. Aboseif

Volume 2008, Article ID 263450, 4 pages

**Peyronie's Reconstruction for Maximum Length and Girth Gain: Geometrical Principles**,

Paulo H. Egydio and Salvatore Sansalone

Volume 2008, Article ID 205739, 9 pages

**Preservation of Cavernosal Erectile Function after Soft Penile Prosthesis Implant in Peyronie's Disease: Long-Term Followup**, Marco Grasso, Caterina Lania, Flavio Fortuna, Salvatore Blanco, and Igor Piacentini

Volume 2008, Article ID 646052, 5 pages

**A Preliminary Report on Combined Penoscrotal and Perineal Approach for Placement of Penile Prosthesis with Corporal Fibrosis**, John P. Brusky, Viet Q. Tran, Jocelyn M. Rieder, and Sherif R. Aboseif

Volume 2008, Article ID 524392, 3 pages

**Penile Corporeal Reconstruction during Difficult Placement of a Penile Prosthesis**, Viet Q. Tran, Timothy F. Lesser, Dennis H. Kim, and Sherif R. Aboseif

Volume 2008, Article ID 370947, 4 pages

**Penile Prosthesis: What Should We Do about Complications?**, C. Bettocchi, P. Ditonno, F. Palumbo, G. Lucarelli, G. Garaffa, B. Giammusso, and M. Battaglia

Volume 2008, Article ID 573560, 5 pages

**Organ-Preserving Surgery for Penile Carcinoma**, Francisco E. Martins, Raul N. Rodrigues, and Tomé M. Lopes

Volume 2008, Article ID 634216, 7 pages

**Reconstructive Surgery for Severe Penile Inadequacy: Phalloplasty with a Free Radial Forearm Flap or a Pedicled Anterolateral Thigh Flap**, N. Lumen, S. Monstrey, P. Ceulemans, E. van Laecke, and P. Hoebeke

Volume 2008, Article ID 704343, 5 pages

## Editorial

# Penile Reconstructive Surgery

**Miroslav L. Djordjevic**

*Pediatric Urology Department, University Children's Hospital, Tirsova 10, 11000 Belgrade, Serbia*

Correspondence should be addressed to Miroslav L. Djordjevic, [djordjevic@uromiros.com](mailto:djordjevic@uromiros.com)

Received 10 November 2008; Accepted 10 November 2008

Copyright © 2008 Miroslav L. Djordjevic. This is an open access article distributed under the Creative Commons Attribution License, which permits unrestricted use, distribution, and reproduction in any medium, provided the original work is properly cited.

Penile reconstructive surgery has always been a notable challenge in the field of genitourinary reconstruction because of the fact that it attaches huge importance to the functional and aesthetic aspects of this organ and the genital region as a whole. During the last decades, many operative procedures and their modifications for the treatment of both congenital and acquired anomalies are published. Based on the established principles of reconstruction, as we strive forward in this difficult art, we also feel the need to adapt to growing demands of rewriting the stiff challenges of techniques, their modifications, the long-term results, and futuristic issues which encompass this subspeciality.

One of the most common congenital anomalies is *hypospadias*. Repair of this anomaly has become easier with Snodgrass principle for distal and buccal mucosa graft combined with genital flaps for proximal forms. However, complication rate is still not minimized to be satisfied. Heidelberg group in the article entitled "Hypospadias" with their vast experience had discussed all aspects of hypospadias in details as it stands today commencing from its understanding as a developmental anomaly to its presentation, preparation, operative techniques as they stand today based on well defined historic and current concepts. Their overview emphasizes the fate of urethral plate in various distal and proximal surgical methods algorithmically to bring about satisfactory planning and execution of each treatment arm. The authors have in great details described their preferred approach of longitudinal preputial or penile flap in both distal and proximal hypospadias and presented its visual and schematic understanding.

Reinberg et al. in "Tunneled tunica vaginalis flap for recurrent urethrocutaneous fistulae" in a retrospective clinical analysis present their 5-year data on a set of 12 boys who underwent tunneled tunical vaginalis flap repair for recurrent fistulae in all locations. Another group from

Detroit have presented a unique group of patients in their 5-year study where they discuss a subset of "iatrogenic strictures" presenting in adulthood resulting from childhood hypospadias surgeries. The complexity of these cases is increased manifold due to reasons of delayed presentation of many decades, varying lengths, as well as poor healing capacity due to scarred territory from previous surgical attempts and associated complicating factors of renal failure and fistulae.

The current management of patients with *intersex*, now named as disorders of sex development, presents results of updated etiological and outcome data as well as refined surgical procedures, as discussed in "Adult urethral stricture disease after childhood hypospadias repair." Ambiguous genitalia play a role in gender differentiation, and surgical treatment should give answers for psychosexual questionnaire of this population. Gupta et al. in "Male genitoplasty for intersex disorders" have come up with a large series review to discuss dilemmas in gender reassignment in intersex disorders in the childhood age group. In their review which includes majority of cases of proximal hypospadias, authors advocate early and complete chordee correction in childhood for satisfactory phallic growth. The issue of gender reassignment is a delicate one in paediatric age group and needs to take into consideration the community, parental wishes, the state of child, and its phenotypic gender of being reared, as well as the age of presentation. In masculinising genitoplasty satisfactory hormonal treatment, removal or preservation of mullerian structures and parental counselling are key features. It involves a dedicated teamwork and close yet longterm followup for corrections with changing age and hormonal management.

The degree of curvature, the type of deformity, erectile dysfunction, and penile length are all characteristics that are assessed in choosing the best surgical intervention in

*Peyronie's disease.* The majority of procedures are usually followed with some loss of length. Using radical geometrical principles in creating and fashioning the graft with appropriate size leads to precise correction with penile lengthening. The first review from Aboseif et al. "Review of the surgical approaches for Peyronie's disease: corporeal plication and plaque incision with grafting" judges our understanding of surgical approaches to date in managing Peyronie's plaque—from plication to grafting. Their review article focuses on surgical evolution and compares the two methods from all recent publications thus judging the advantages of both techniques. A rationale approach today would be proper counseling of each well-informed patient and a surgeon capable of the armamentarium of techniques to choose from as required in an individual case with intraoperative decisions which hold the key. More complex and multiple deformities would benefit with a combination of the techniques described to ensure complete correction.

In another paper, "Peyronie's reconstruction for maximum length and girth gain—geometrical principles," Egydio et al. redefine their concept of straightening by geometrical principles in yet another landmark study of 521 treated patients over 8 years who achieved satisfactory sexual health with the performed straightening and enlargement technique divided into two arms of use of bovine pericardial grafts and the corresponding arm with additional penile prosthesis. A small subgroup of patients with grafting alone who developed deterioration of erectile function in postoperative followup were treated with penile prosthesis to satisfactory outcomes. The penile disassembly described earlier is a huge assistance in exposing even the most distal deformities for complete correction. As we strive toward the search of an ideal graft for penile reconstructive surgeries, the use of bovine pericardial grafts with its advantages as demonstrated in such large series safely gives confidence of yet another biocompatible graft with long-term results. Prospective comparative studies with other contemporary surgical techniques would go a long way in furthering our knowledge toward ultimate patient satisfaction in Peyronie's disease.

In contrast, Piacentini et al. in "Preservation of cavernosal erectile function after soft penile prosthesis implant in Peyronie's disease: long term follow up" present an excellent retrospective review of intermediate results of 6 years in 12 patients who have been treated with semirigid prosthesis alone for Peyronie's disease without any plaque treatment. Their study is based on the hypothesis which heavily relies on the residual cavernosal tissue that becomes a peripheral component to the prosthesis and plays a healing role in further straightening as well as being available for future pharmacologic therapy.

A wide variety of medications, devices, and surgical interventions are available for patients with *erectile dysfunction*. Technological improvement of penile prosthesis lead to their rising popularity, but strict indications and rigorous surgical principles for implantation should always be respected (followed) in order to avoid unnecessary surgery and possible complications with severe psychological consequences. The next exciting section of this issue is devoted to the difficult art

and contemporary world of penile prosthesis. Aboseif et al. in "A preliminary report on combined penoscrotal and perineal approach for placement of penile prosthesis with corporal fibrosis," in a comprehensive retrospective study of 15 patients, review their state-of-the-art techniques for penile reconstruction in difficult penile prosthesis placement. Their group is divided into two treatment arms of severe Peyronie's tunical fibrosis and the other of severe tunical fibrosis of previous prosthesis-related complications. The data are very interesting and larger prospective studies for longer duration could throw more light to our continued search for ideal techniques. In another review, "Penile corporeal reconstruction during difficult placement of a penile prosthesis," they discuss their preliminary results in combined penoscrotal and perineal approach for complex corporal fibrosis spanning 3 patients. Finally, Bettocchi et al. in "Penile prosthesis: what should we do about complications?" made a review of penile prosthesis implantations, indications, and, especially, a discussion about possibilities in the treatment of complications.

Last but not least, *penile carcinoma* is an aggressive disease with significant treatment-associated psychosexual morbidity. Despite high control rates with radical surgical approaches, organ-sparing surgery should be considered to achieve better psychosexual life. Lisbon group in "Organ preserving surgery for penile carcinoma" brought forth the idea of balance between the functional and anatomical aspects of this organ weighing against any compromise with local oncological radicality in this malignancy. They explore all possibilities of penile preserving approaches in penile cancers by various operative and nonoperative interventions in properly selected patient with a word of caution that the approach to organ preservation can be applied to low-grade and low-stage tumours until more evidence emerges from prospective studies. To further attempts at proper organ preservation techniques, the recent description of penile disassembly and excision—reconstruction would go a long way in achieving satisfactory results.

Finally, Hoebeke et al. in "Reconstructive surgery for severe penile inadequacy: phalloplasty with a free radial forearm flap or a pedicled anterolateral thigh flap?" have summarized their experience on the devastating condition of severe penile inadequacy in young males. Phalloplasty remains a challenge in reconstruction and is the hallmark achievement in transsexual surgery and severe penile deficiency that results from trauma, micropenis, and penile amputations. This series describes the procedure and consequences of 11 young males who underwent radial forearm flap or anterolateral thigh flap neophallus reconstruction.

Miroslav L. Djordjevic

## Review Article

# Hypospadias

**N. Djakovic, J. Nyarangi-Dix, A. Öztürk, and M. Hohenfellner**

*Department of Urology, University of Heidelberg, Medical Center, 69120, Heidelberg, Germany*

Correspondence should be addressed to N. Djakovic, [nenad.djakovic@med.uni-heidelberg.de](mailto:nenad.djakovic@med.uni-heidelberg.de) and J. Nyarangi-Dix, [joan.nyarangi@med.uni-heidelberg.de](mailto:joan.nyarangi@med.uni-heidelberg.de)

Received 30 May 2008; Accepted 9 September 2008

Recommended by Miroslav L. Djordjevic

**Objective.** The great possibility of variations in the clinical presentation of hypospadia, makes its therapy challenging. This has led to the development of a number of techniques for hypospadia repair. This article assesses past and present concepts and operative techniques with the aim of broadening our understanding of this malformation. **Materials and Methods.** The article not only reviews hypospadia in general with its development and clinical presentation as well as historical and current concepts in hypospadiologie on the basis of available literature, but it is also based on our own clinical experience in the repair of this malformation. **Results and Conclusion.** The fact that there are great variations in the presentation and extent of malformations existent makes every hypospadia individual and a proposal of a universal comprehensive algorithm for hypospadia repair difficult. The Snodgrass technique has found wide popularity for the repair of distal hypospadias. As far as proximal hypospadias are concerned, their repair is more challenging because it not only involves urethroplasty, but can also, in some cases, fulfil the dimensions of a complex genital reconstruction. Due to the development of modern operating materials and an improvement in current surgical techniques, there has been a significant decrease in the complication rates. Nonetheless, there still is room and, therefore, need for further improvement in this field.

Copyright © 2008 N. Djakovic et al. This is an open access article distributed under the Creative Commons Attribution License, which permits unrestricted use, distribution, and reproduction in any medium, provided the original work is properly cited.

## 1. INTRODUCTION

### 1.1. Definition, incidence and classification

With an incidence of 1:300, hypospadia is one of the most common genital anomalies in male newborns [1]. Hypospadia is defined as an anomaly (hypo- or dysplasia) involving the ventral aspect of the penis [2]. These malformations mainly comprise of an abnormal ventral opening of the urethral meatus, an abnormal ventral curvature of the penis (chordee) and/or an abnormal distribution of the foreskin. The extent of the malformation varies.

Such ectopic urethral openings (meatus) can be located at the tip of the glans penis (hypospadia sine hypospadias), glanular, coronal, subcoronal, along the penile shaft, penoscrotal, scrotal, or perineal. The form and extent of malformation of the urethral opening varies as well and in some cases widely gaping and resembling the mouth of a fish. A stenosis is rather rare.

Generally, severe forms of hypospadia are typically accompanied by an abnormal ventral curvature of the penis

(chordee). This is due to the difference in length between the ventral and the dorsal side of the penis (corporocavernosal dysproportion). Proximal hypospadias frequently have a penoscrotal transposition and/or bifid scrotum.

Further abnormalities in hypospadia concern the prepuce. Typically, there is a dorsal hump with excessive skin on the dorsal and a scarcity of foreskin on the ventral aspect of the penis. In most cases, the frenulum is entirely missing. In the rare cases when the prepuce is normally developed, it must be preserved and a circumcision avoided [3].

### 1.2. Background

The hypospadic penis is often anatomically similar to the normal penis, at least as far as the dorsal aspect is concerned. However, the ventral aspect is pathological: the development of the prepuce incomplete, the formation of the urethral plate into a urethra defective and the corpus spongiosum deficient. Histologically, the urethral plate consists of well-vascularised tissue with large endothelial sinuses lined around an abortive urethral spongiosum. Fibrosis and

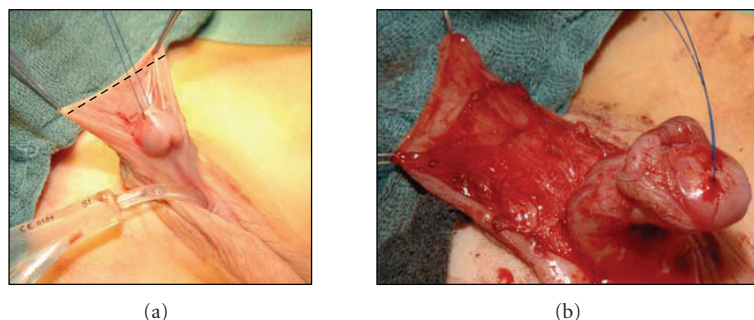


FIGURE 1: Preparation of the dartos flap.

cicatrization are rarely available [4]. These characteristics make the urethral plate ideal for urethroplasty [5].

The development of the urethral plate is genetically influenced by cell differentiation, hormonal and enzymatic activity, as well as tissue transformation. Before the 7th week of gestation, the structure of the genital is indifferent [2, 6]. Afterwards, the tissue differentiation, including the elongation of the phallus, the formation of the penile urethra, and the development of the prepuce [7] are influenced by the presence or absence of androgens and the signals of the SRY-gene. More recent studies support the theory of endodermal differentiation. According to this theory, the entire urethra stems from the urogenital sinus [8]. The continual development of the urethral plate into the genital tubercle is followed by the ventral fusion of the urethral folds [9]. The development of the prepuce not only occurs simultaneous to the fusion of the urethral plate, this development in fact depends on it. In cases where the fusion of the urethral plate is altered, the prepuce on the ventral aspect of the penis remains underdeveloped.

Interferences in the androgen metabolism, for example, 5 $\alpha$ -Reductase deficit, defects of the androgen receptor, or gene defects are possible aetiological factors for hypospadias, that are only found in <5% of the patients [10, 11]. Hypospadias is also found as a part of different syndromes.

The incidence of hypospadias is increasing worldwide. A possible explanation for this trend could be the increasing environmental pollution. In this context, it is known that human beings increasingly ingest substances with estrogen, for example, as found in certain insecticides, natural herbs, and so forth. Animal models demonstrated that estrogens lead to an alteration or even complete interruption of the development of the penis [12]. The aetiology of the majority of hypospadias though remains unknown.

## 2. TREATMENT

Surgical reconstruction is the only possible therapeutic option for hypospadias [2]. The primary objectives of the reconstruction are to create a vertically slit orthotopic meatus, straighten the penis in case of curvature and establish good cosmetic results that include a conically shaped glans. Other important aspects for the reconstruction are to avoid

shortening the penis and optimal skin coverage that excludes the use of scrotal skin for coverage of the penis.

The optimal age for correction of hypospadias is between the 6th and the 24th month. Thanks to the possibility of topical application of dihydrotestosterone, it is possible to optimise the size of the penis at this early age of operation [13]. In the majority of cases, the operation can be done in one step. A two-step approach is rarely necessary, for example, in case of insufficiency of the urethral plate or hypoplastic skin as often found in Re-Do Hypospadias [14].

Successful hypospadias surgery incorporates the following steps: straightening of the penis (orthoplasty), reconstruction of the urethra (urethroplasty), the meatus (meatoplasty), the glans (glanuloplasty) and the skin of the penis as well as that of the scrotum whenever necessary.

### 2.1. History

The fact that there are over 250 methods of surgical correction of hypospadias described in the literature indicates that the “hypospadiologists” are still in search of the ideal technique. The statement: “There is nothing new in surgery not previously described” [15] is especially true as far as hypospadias repair is concerned, because many so believed new techniques were, as a matter of fact, originally described in historical documents and books.

In the 19th century, Dieffenbach [16] tried to reconstruct a neourethra through secondary epithelialisation by perforating the glans with a canula and therefore establishing a connection to the hypospadiac urethra. Theofil Anger first used tubularised local flaps in the 19th century for hypospadias repair [17]. In 1875, Wood introduced the “meatal-based-flap-technique” that is the basic idea behind the Mathieu technique [18]. The idea of reconstructing the neourethra out of a vascularised island flap was also first described in the 19th century. In connection with this, Van Hook described the reconstruction of the neourethra with a dorsal preputial flap. The idea of using a free flap for urethroplasty is also not new. Towards the end of the 19th century, Nove-Josserand used skin grafts for the urethral reconstruction [19].

The above-mentioned techniques were further pursued and advanced in the 20th century. Ombrédanne created the neourethra out of a round local submeatal flap and



covered it with a dorsal preputial flap [19]. Similar strategies were followed by Mathieu and Brown. Horton and Devine introduced the so called “Flip-Flap technique” for the correction of distal hypospadias that is favoured by certain surgeons up to date [20]. At the same time, techniques that preferentially use vascularised island flaps were also further pursued. The best known of these is undoubtedly the urethroplasty using a transverse preputial island flap as popularised by Duckett in 1980 [21]. Although several trials were performed in the 20th century with free flaps, buccal mucosa is the only regularly used graft at the moment [22].

The mobilisation and elongation of the urethra is an interesting concept, which can in some cases be used to avoid urethroplasty. Duckett’s principle, which is also known as “MAGPI,” is based on this concept [23]. This idea too is not new and was first described by Beck in 1889 [24].

Even though under different conditions, the same concepts are still applied up to date. The surgical results have been further improved by the use of modern sutures, loupe magnification, modern dressing material, better foley catheters, and better methods for the diagnostic and correction of penis curvature through artificial or medically induced erections.

## 2.2. Urethroplasty

The selection of the surgical technique for the reconstruction of the neourethra should not only be influenced by the position of the meatus but must in fact take the entire complex of anomalies—that is, the quality of the urethral plate as well as that of the penile skin, the form of the glans, the length of the urethra, and the grade of corporocavernosal dysproportion—into consideration.

The major techniques of urethroplasty are described in detail under the subtitles “proximal hypospadias” and “distal hypospadias.”

## 2.3. Orthoplasty and penile skin coverage

The penile curvature results from the dysplasia/hypoplasia on the ventral aspect of the penis. Mild curvatures can already be corrected by complete mobilisation of the penile skin. This way, the so-called, “skin chordee” can be released. If the curvature is still existent after such mobilisation, other methods must be applied [25].

The presence of altered fibrotic tissue around the urethral plate and on the ventral aspect of the penis is seldom. This is, therefore, a rather rare reason for penile curvatures. It makes it also easy to understand that a chordectomy alone rarely leads to a straightening of the penis [2]. About 5% of the patients have a so-called corporocavernosal disproportion, which is an effect of the disparity in the development of the tunica albuginea on the ventral and dorsal aspects of the penis [25, 26].

Depending on the extent of the penile curvature, the reconstruction can either be performed per dorsal corporoplasty or with the use of a ventral patch. In the recent past, a number of authors seem to increasingly favour the

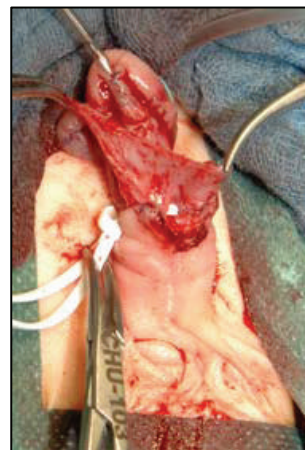

FIGURE 2: Incised and tubularised urethral plate with the ventrally transpositioned dartos flap.

midline dorsal plication [2]. This technique is based on studies on fetal phallus, which detected that there are no nerves running in the neurovascular bundles in the midline [26]. Mild and moderate curvatures can be corrected with this technique. We correct curvatures up to 40° using Yachia’s technique [27]. To avoid extreme shortening of the penis during correction of more severe penile curvatures, a ventral patch, in most cases out of preputial skin, can be used.

The reconstruction of the penile skin is particularly challenging after degloving, “excavation” of the penis, and urethroplasty. In such cases, it is important to pay attention not to embed the penis in the scrotum or the mons pubis. In cases of simultaneous penoscrotal transposition, the anomaly can also be corrected within the same session. This is done with scrotal rotational flaps that are only mobilised up to the subcutaneous layer in order not to compromise the vascularisation of the island flaps and the penile skin [14].

The straightening of the penis as well as an optimal plastic reconstruction of the scrotum and penile skin demands great expertise.

## 2.4. Distal hypospadias

The majority of patients with this type of hypospadias can urinate with a straight urine stream and have not pronounced penile curvatures. Nonetheless, most parents wish for a “normal penis” for their child. Therefore, the surgical reconstruction of distal hypospadias must meet these cosmetic requirements [2]. The psychosocial aspect is another important factor to consider while making the decision on performing the operative reconstruction in this group of patients.

As of today, the meatal advancement urethroplasty (MAGPI), glans approximation procedure (GAP), Mathieu’s procedure and the tubularised incised plate urethroplasty (Snodgrass technique) are among the most established and reliable methods [2].

With the use of the urethral plate for urethroplasty, the complication rate has been clearly reduced. At the beginning,

primary tubularisation, also known as the Thiersch-Duplay, was performed in patients with wide urethral plates and deep fossa navicularis [28]. In cases where the urethral plate is narrow, the Mathieu or MAGPI technique or variants thereof are applied. With these methods, a submeatal-based flap is augmented on the narrow urethral plate and the meatus repositioned on the glans [2].

Lately, the concept of incision and tubularisation of the urethral plate with consecutive secondary healing, as popularised by Snodgrass et al. [29], has revolutionised hypospadias surgery [5, 29]. Its low complication rates, excellent cosmetic results and the simple surgical technique have made it very popular among hypospadias surgeons [30]. The initial concerns and, subsequently, reports about increased stenosis have become quite seldom [31, 32]. As long as there is no penile curvature, this technique is the method of choice for distal hypospadias [32]. This method is increasingly applied for the repair of penile hypospadias as well [29].

Nonetheless, there are still complications mostly fistulas reported in [32]. In order to prevent fistulas, particularly healthy tissue from different areas is used to cover the neourethra using different techniques. Retik described the use of asymmetrical flaps from the dorsal penile skin and the prepuce [33]. Other authors use distal extensions of the parting corpus spongiosum to cover the neourethra [34]. Sozubir and Snodgrass used a dorsal dartos flap that was transposed to the ventral aspect of the penis over a buttonhole technique.

We, on our part, favour the longitudinal dorsal dartos flap. Mobilising the penile skin involves complete preservation of the dorsal hump. This skin is stretched by two stay sutures, and then incised proximal to the subcoronar region (see Figure 1). The preparation and deepithelialisation of the dartos flap begins proximal to the dorsal hump in an area where the subcutaneous tissue is not pathologically altered. This way, the preparation of the dartos flap is eased and a complete preservation of a well-vascularised dartos flap is possible (see Figure 1).

The urethral plate is mobilised in the layer of Buck's fascia and the tip of the glans incised at the fossa navicularis. In order to enable a tension-free suturing-up of the glans, the incision must be made all the way to the cavernous bodies. After making a midline incision into the urethral plate, it is tubularised with a continuous 7/0 Vicryl suture around a 6 Fr catheter. The dartos flap is then transpositioned to the ventral aspect of the penis with the buttonhole technique and sutured into the incised glans (see Figure 2). This way the neourethra is well covered by this dartos flap.

The glanuloplasty is done with two-layer sutures of Vicryl 7/0. In order to avoid stenosis, it is important to create a wide-enough meatus and evert it afterwards [32].

## 2.5. Proximal hypospadias

Usually, the intensity of the ventral dys- and hypoplasia increases with increasing grade of hypospadias. That means that the skin on the ventral aspect of the penis and the usability of the urethral plate decreases with an increase in

grade of dysplasia. At the same time the penile curvature increases, which makes it sometimes necessary to transect the urethral plate. This special anatomic constitution demands the selection of a surgical technique that is complex and challenging [25].

In such forms of hypospadias, the penis must be first straightened, the urethral plate mobilised up to healthy corpus spongiosum and then the urethroplasty performed with additional tissue. Principally, pedicled or free flaps are used to reconstruct the neourethra in onlay technique. The key to success, in this case, is the preservation of the urethral plate that builds the ventral portion of the neourethra. Most surgeons reconstruct the dorsal portion out of a pedicled inner preputial skin graft [2, 35, 36]. With the integration of the urethral plate, complications like proximal stenosis can be avoided. Furthermore, the fistula rate can be decreased down to 5–10% by using well-vascularised pedicled island grafts [36, 37]. This method has proved its worth in the long run [37–40].

We generally prefer the use of the longitudinal preputial/penile island flap from the preputial and/or the dorsal penile skin. During preparation of the flap, two lateral devascularised skin portions are developed with the vascularisation in favour of a centrally situated island flap (Figure 3). The devascularised skin is later trimmed off during the reconstruction of the penile skin. The length, width, and shape of this dorsal island flap are formed according to the morphology and quality of the urethral plate. The island flap is transposed ventrally with the buttonhole technique (Figures 3 and 4). Its pedicle contains, in respect to the flap, axially aligned vascularisation.

The reconstruction of the neourethra is done in “onlay technique.” First, the island flap is distally fixed to the hypospadiac meatus with interrupted sutures (Vicryl 7/0). Both of the sides of the anastomosis of the onlay are sutured with running suture. Both suture lines of this anastomosis are completely covered by the vascular pedicle of the dorsal island flap. The advantage of this flap over the Duckett-flap is that the longitudinal dorsal island flap lies right in the middle of a wide and well-vascularised pedicle (Figure 4). It is thus an island flap that lies in line with its vascularisation [16, 17]. On the other hand all suture lines are fully covered up by well-vascularised tissue. This way badly perfused borders and corners that are predispose to fistulation are avoided.

Generally, the urethral plate can be preserved while straightening the penis. In certain cases though, it must be lifted and incised (Figure 5). In yet other cases, the urethral plate is missing completely. In such patients, a tubularised urethroplasty is performed by using an island flap formed into a role to bridge the missing section of the urethral plate. Due to its increased complication rate, this tubularised urethroplasty has been abandoned by most surgeons. Such complications include segmental strictures and diverticula that occur in up to 69% of the cases [41].

An alternative to tubularised urethroplasty for complex and secondary hypospadias are two-step approaches, the most popular of them being the two-step technique of repair according to Bracka [42, 43]. In the 1st step, the penis is straightened and the cicatrization of the urethral plate



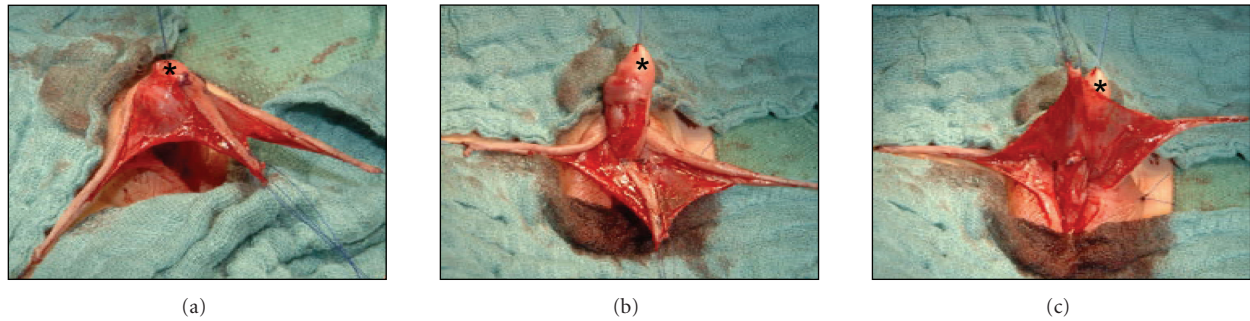


FIGURE 3: Ventral transposition of the longitudinal dorsal dartos flap with the buttonhole technique. Star shows the glans.

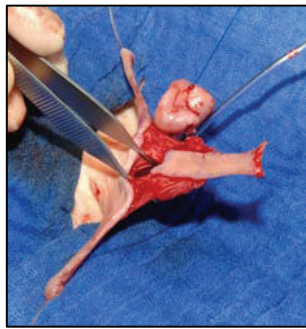


FIGURE 4: Dorsal perspective of the longitudinal island flap. The graft is right in the centre of the vascular pedicle. The buttonhole is already made.

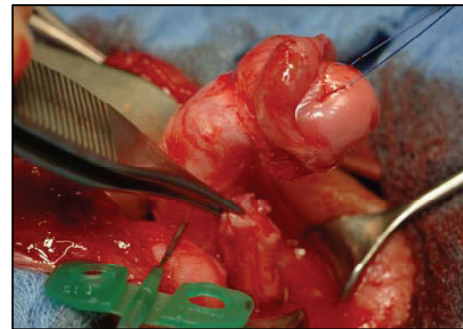


FIGURE 6: After horizontal incision of the urethral plate the penis is still ventrally curved and a large defect in the distal part of the urethral plate is revealed.

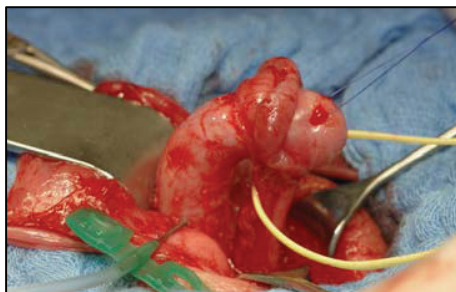
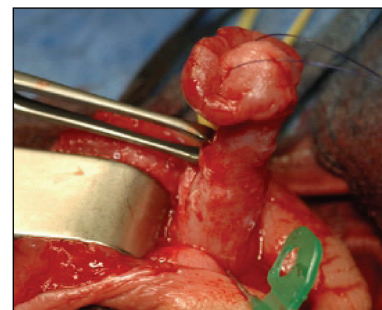
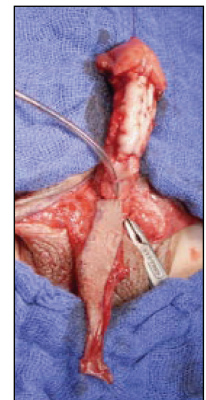


FIGURE 5: After complete mobilisation of the urethra and artificial erection of the penis, the ventral curvature with a short urethral plate becomes evident.



(a)



(b)

FIGURE 7: Straightening of the penis (a). The mucosal inlay graft is fixed on the cavernous bodies (b). The longitudinal island flap is ready for the onlay anastomosis (b).

eliminated. A mucosal graft out of the cheek or lower lip is harvested and placed on the prepared bed. The tips of the glans are also reconstructed and lined with the mucosal graft. In the 2nd step, approximately 6 months later, the mucosal grafts are mobilised, trimmed around the glans and tubularised to a neourethra. Bracka has reported good results in complex hypospadias with this method. Nonetheless, a two-step technique has a relevant disadvantage, namely that of the second operation with its additional complications as well as the negative psychosocial effects on the patient and his family [44].

In order to be able to perform a one-step procedure, a number of studies have been presented in the recent past

describing the use of a combination of mucosal grafts and local flaps. In such cases, the defect that results from incision of the urethral plate is bridged over using a mucosal inlay graft and the neourethra is reconstructed out of an island flap in onlay technique and all that in a single procedure [44]. This way, the advantages of a one-step procedure as well as those of the onlay technique are both exploited.

We on our part favour the longitudinal preputial and penile skin island flap. First the penile skin is mobilised, then the urethral plate is incised vertically beginning at the hypospadiac meatus all the way to the glans thereby building two glanular wings proximally. This mobilised urethral plate then lies as a groove between both glanular wings. In order to avoid bleeding out of dysplastic lateral branches of the corpus spongiosum, the preparation of the distal section of the urethral plate is done along Buck's fascia.

The decision of whether or not to horizontally incise the urethral plate is made depending on the intraoperative findings after artificial erection (Figure 5). We do the incision of the urethral plate proximal to the balanopenile furrow. This way, the proximal stump of the urethral plate is retracted and it, therefore, interrupted/missing along the mid section of the penis (Figure 6). In the next step we straighten the penis and then harvest the buccal mucosal graft. This graft is then perforated to enable drainage of haematoma between the cavernous bodies and the placed graft. We then place the buccal mucosal inlay graft on the cavernous bodies and fix it between the retracted proximal and the distal ends of the urethral plate (Figure 7). In order to enable a large surface of adhesion between the graft and the tunica albuginea, the graft is quilted on to its bed with Vicryl rapid 7/0.

In the same session, a longitudinal preputial/penile island flap won out of the preputial and dorsal penile skin is used for the reconstruction of the neourethra in onlay technique (Figure 7, [35]). Rotational and additionally island skin flaps are used in combination for coverage of the penis. A single-step procedure can be performed in 75% of the children with penoscrotal transpositions [14].

### 3. CONCLUSION

Hypospadias surgery is challenging. The fact that there are wide variations in the presentation and extent of malformations as well as tissue characteristics existent makes every hypospadias individual and a proposal of a universal comprehensive algorithm for hypospadias repair difficult. The Snodgrass technique has found wide popularity for the repair of distal hypospadias. As far as proximal hypospadias are concerned, their repair is complex and could in fact be seen as a form of genital reconstruction. This repair not only involves urethroplasty, but also has its goal in achieving good cosmetic results with a straight normal-proportioned penis and an orthotopic meatus in addition to the functional urethra. Even though the complication rates have decreased, thanks to modern operating materials and an improvement of current surgical techniques, there still is room and therefore need for further improvement in this field.

### REFERENCES

- [1] S. Perovic, Ed., *Atlas of Congenital Anomalies of the External Genitalia*, Belgrad, Yugoslavia, Refot-Arka, 1999.
- [2] L. S. Baskin and M. B. Ebberts, "Hypospadias: anatomy, etiology, and technique," *Journal of Pediatric Surgery*, vol. 41, no. 3, pp. 463–472, 2006.
- [3] S. Perovic, N. Djakovic, and M. Hohenfellner, "Penis- und Harnröhrenmissbildungen," *Der Urologe A*, vol. 43, no. 4, pp. 394–401, 2004.
- [4] A. Erol, L. S. Baskin, Y. W. Li, and W. H. Liu, "Anatomical studies of the urethral plate: why preservation of the urethral plate is important in hypospadias repair," *BJU International*, vol. 85, no. 6, pp. 728–734, 2000.
- [5] W. Snodgrass, "Tubularized, incised plate urethroplasty for distal hypospadias," *The Journal of Urology*, vol. 151, no. 2, pp. 464–465, 1994.
- [6] L. S. Baskin, A. Erol, P. Jegatheesan, Y. Li, W. Liu, and G. R. Cunha, "Urethral seam formation and hypospadias," *Cell and Tissue Research*, vol. 305, no. 3, pp. 379–387, 2001.
- [7] J. E. Jirásek, J. Raboch, and J. Uher, "The relationship between the development of gonads and external genitals in human fetuses," *American Journal of Obstetrics and Gynecology*, vol. 101, no. 6, pp. 830–833, 1968.
- [8] E. A. Kurzrock, L. S. Baskin, and G. R. Cunha, "Ontogeny of the male urethra: theory of endodermal differentiation," *Differentiation*, vol. 64, no. 2, pp. 115–122, 1999.
- [9] E. A. Kurzrock, L. S. Baskin, Y. Li, and G. R. Cunha, "Epithelial-mesenchymal interactions in development of the mouse fetal genital tubercle," *Cells Tissues Organs*, vol. 164, no. 3, pp. 125–130, 1999.
- [10] J. Géraudie and P. Ferretti, "Gene expression during amphibian limb regeneration," *International Review of Cytology*, vol. 180, pp. 1–50, 1998.
- [11] C. C. Zhu, G. Yamada, S. Nakamura, T. Terashi, A. Schweickert, and M. Blum, "Malformation of trachea and pelvic region in goosecoid mutant mice," *Developmental Dynamics*, vol. 211, no. 4, pp. 374–381, 1998.
- [12] J. C. Semenza, P. E. Tolbert, C. H. Rubin, L. J. Guillelte Jr., and R. J. Jackson, "Reproductive toxins and alligator abnormalities at Lake Apopka, Florida," *Environmental Health Perspectives*, vol. 105, no. 10, pp. 1030–1032, 1997.
- [13] G. Monfort and C. Lucas, "Dehydrotestosterone penile stimulation in hypospadias surgery," *European Urology*, vol. 8, no. 4, pp. 201–203, 1982.
- [14] S. Perovic and V. Vukadinovic, "Penoscrotal transposition with hypospadias: 1-stage repair," *The Journal of Urology*, vol. 148, no. 5, pp. 1510–1513, 1992.
- [15] E. D. Smith, "The history of hypospadias," *Pediatric Surgery International*, vol. 12, no. 2-3, pp. 81–85, 1997.
- [16] J. F. Dieffenbach, "Guerison des fentes congenitales de la verge, de l'hypospadias," *Gazette Hebdomadaire de Medecine et de Chirurgie*, vol. 5, pp. 156–158, 1837.
- [17] M. T. Anger, "Hypospadias péno-scrotal, complique de coudure de la verge: redressement du penis et urethroplastie par inclusion cutanée: guérison," *Bulletin de la Société Chimique de France*, p. 179, 1875.
- [18] A. T. Hadidi and A. F. Azmy, Eds., *Hypospadias Surgery: An Illustrated Guide*, Springer, Berlin, Germany, 2004.
- [19] J. Prévot, "The history of pediatric surgery in France," *Progress in Pediatric Surgery*, vol. 20, pp. 9–16, 1986.
- [20] M. Samuel, S. Capps, and A. Worthy, "Distal hypospadias: which repair?" *BJU International*, vol. 90, no. 1, pp. 88–91, 2002.
- [21] J. W. Duckett Jr., "Transverse preputial island flap technique for repair of severe hypospadias," *Urologic Clinics of North America*, vol. 7, no. 2, pp. 423–430, 1980.
- [22] I. A. Mokhless, M. A. Kader, N. Fahmy, and M. Youssef, "The multistage use of buccal mucosa grafts for complex hypospadias: histological changes," *The Journal of Urology*, vol. 177, no. 4, pp. 1496–1500, 2007.

- [23] J. W. Duckett Jr., "MAGPI (meatoplasty and glanuloplasty). A procedure for subcoronal hypospadias," *Urologic Clinics of North America*, vol. 8, no. 3, pp. 513–519, 1981.
- [24] C. N. Baran, Y. O. Tiftikcioglu, R. Ozdemir, and N. K. Baran, "What is new in the treatment of hypospadias?" *Plastic and Reconstructive Surgery*, vol. 114, no. 3, pp. 743–752, 2004.
- [25] S. Perovic, "Controversies in hypospadias surgery: penile curvatures," *Dialogues in Pediatric Urology*, vol. 19, no. 7, pp. 2–8, 1996.
- [26] L. S. Baskin, A. Erol, Y. W. Li, and W. H. Liu, "Anatomy of the neurovascular bundle: is safe mobilization possible?" *The Journal of Urology*, vol. 164, no. 3, pp. 977–980, 2000.
- [27] D. Yachia, "Modified corporoplasty for the treatment of penile curvature," *The Journal of Urology*, vol. 143, no. 1, pp. 80–82, 1990.
- [28] S. A. Amukele, A. C. Weiser, J. A. Stock, and M. K. Hanna, "Results of 265 consecutive proximal hypospadias repairs using the thiersch-duplay principle," *The Journal of Urology*, vol. 172, no. 6, pp. 2382–2383, 2004.
- [29] W. Snodgrass, M. Koyle, G. Manzoni, R. Hurwitz, A. Caldameone, and R. Ehrlich, "Tubularized incised plate hypospadias repair for proximal hypospadias," *The Journal of Urology*, vol. 159, no. 6, pp. 2129–2131, 1998.
- [30] W. Snodgrass, M. Koyle, G. Manzoni, R. Hurwitz, A. Caldameone, and R. Ehrlich, "Tubularized incised plate hypospadias repair: results of a multicenter experience," *The Journal of Urology*, vol. 156, no. 2, supplement 1, pp. 839–841, 1996.
- [31] V. R. Jayanthi, "The modified Snodgrass hypospadias repair: reducing the risk of fistula and meatal stenosis," *The Journal of Urology*, vol. 170, no. 4, part 2, pp. 1603–1605, 2003.
- [32] M. L. Djordjevic, S. V. Perovic, Z. Slavkovic, and N. Djakovic, "Longitudinal dorsal dartos flap for prevention of fistula after a Snodgrass hypospadias procedure," *European Urology*, vol. 50, no. 1, pp. 53–57, 2006.
- [33] J. G. Borer, S. B. Bauer, C. A. Peters, et al., "Tubularized incised plate urethroplasty: expanded use in primary and repeat surgery for hypospadias," *The Journal of Urology*, vol. 165, no. 2, pp. 581–585, 2001.
- [34] E. B. Yerkes, M. C. Adams, D. A. Miller, J. C. Pope IV, R. C. Rink, and J. W. Brock III, "Y-to-I wrap: use of the distal spongiosum for hypospadias repair," *The Journal of Urology*, vol. 163, no. 5, pp. 1536–1539, 2000.
- [35] S. Perovic, "Our modification of onlay island flap urethroplasty in severe hypospadias," *European Journal of Pediatric Surgery*, vol. 5, no. 2, pp. 94–100, 1995.
- [36] S. Perovic, V. Vukadinovic, and J. W. Duckett Jr., "Onlay island flap urethroplasty for severe hypospadias: a variant of the technique," *The Journal of Urology*, vol. 151, no. 3, pp. 711–714, 1994.
- [37] P. D. E. Mouriquand and P.-Y. Mure, "Current concepts in hypospadiology," *BJU International*, vol. 93, supplement 3, pp. 26–34, 2004.
- [38] L. S. Baskin, J. W. Duckett Jr., K. Ueoka, J. Seibold, and H. M. Snyder III, "Changing concepts of hypospadias curvature lead to more onlay island flap procedures," *The Journal of Urology*, vol. 151, no. 1, pp. 191–196, 1994.
- [39] C. Piró Biosca, J. A. Martín Osorio, D. Acosta Fariña, E. Chicaiza Marcillo, and M. Ezzedine Ezzedine, "Treatment of proximal hypospadias: the onlay technique," *Cirugia Pediatrica*, vol. 17, no. 1, pp. 25–27, 2004.
- [40] J. S. Elder, J. W. Duckett Jr., and H. M. Snyder III, "Onlay island flap in the repair of mid and distal penile hypospadias without chordee," *The Journal of Urology*, vol. 138, no. 2, pp. 376–379, 1987.
- [41] K. F. Parsons and G. F. Abercrombie, "Transverse preputial island flap neo-urethroplasty," *British Journal of Urology*, vol. 54, no. 6, pp. 745–747, 1982.
- [42] A. Bracka, "Hypospadias repair: the two-stage alternative," *British Journal of Urology*, vol. 76, supplement 3, pp. 31–41, 1995.
- [43] A. Bracka, "A versatile two-stage hypospadias repair," *British Journal of Plastic Surgery*, vol. 48, no. 6, pp. 345–352, 1995.
- [44] Q. Li, S. Li, W. Chen, et al., "Combined buccal mucosa graft and local flap for urethral reconstruction in various forms of hypospadias," *The Journal of Urology*, vol. 174, no. 2, pp. 690–692, 2005.



## Clinical Study

# Tunneled Tunica Vaginalis Flap for Recurrent Urethrocutaneous Fistulae

Jonathan C. Routh,<sup>1</sup> James J. Wolpert,<sup>2</sup> and Yuri Reinberg<sup>2</sup>

<sup>1</sup> Department of Urology, Mayo Clinic, Rochester, MN 55905, USA

<sup>2</sup> Division of Pediatric Urology, Pediatric Surgical Associates, Minneapolis, MN 55404, USA

Correspondence should be addressed to Yuri Reinberg, yurir@yahoo.com

Received 19 April 2008; Accepted 11 August 2008

Recommended by Miroslav L. Djordjevic

The tubularized incised plate (TIP) hypospadias repair is currently the most widely used urethroplasty technique. The most significant post-TIP complication is urethrocutaneous fistula (UCF) development. Tunneled tunica vaginalis flap (TVF) is a well-described technique for the repair of UCF. We retrospectively reviewed all patients undergoing repeat repair of UCF after TIP repair from 2001 to 2005. Twelve boys underwent TVF repair at our institution for recurrent UCF. Fistulae ranged from distal penile to penoscrotal in location. Median surgical time was 45 minutes and no postoperative complications occurred. After a median follow-up of 32 months (range 16–48 months), no patient has yet had a recurrence of UCF. In conclusion, TVF repair is a successful technique for the treatment of UCF after previous failed repair. TVF is technically simple to perform and should be considered for treating UCF following TIP urethroplasty, particularly in a repeat surgical setting.

Copyright © 2008 Jonathan C. Routh et al. This is an open access article distributed under the Creative Commons Attribution License, which permits unrestricted use, distribution, and reproduction in any medium, provided the original work is properly cited.

## 1. INTRODUCTION

Hypospadias has been recognized as a surgically treatable condition for nearly two millennia. Physicians of both the Hellenic (Heliiodorus and Antyllus) and Roman worlds (Celsus and Galen) described the condition as well as its possible surgical remedies [1, 2]. Needless to say, surgical techniques have evolved with time. The most significant recent advance in this evolution occurred in 1994 with Snodgrass' description of the tubularized incised plate (TIP) urethroplasty technique [3]. Since its initial description in cases of distal hypospadias, TIP urethroplasty has now been applied with notable success to both proximal [4] and reoperative [5, 6] hypospadias.

Despite these advances in urethroplasty technique, certain complications remain problematic for the modern hypospadiasologist, namely, meatal stenosis, urethral stricture or diverticulum, wound dehiscence, and, perhaps most importantly, urethrocutaneous fistulae (UCF). A recent review of TIP urethroplasty reveals a combined UCF rate of 2.4% across several major centers [7]. The interposition of vascularized tissue such as tunica vaginalis flap (TVF) or deepithelialized dartos tissue has been suggested as an

effective means of reducing UCF formation rate in multiple urethroplasty techniques, including TIP [7–9].

Successful fistula repair depends in large part upon meticulous attention to surgical detail, as well as the use of interposed tissue. In reoperative patients, however, this can be difficult to achieve, as well-vascularized tissues amenable to interposition may be sparse. One possibility for interposition graft for UCF repair is the use of tunneled TVF, which was first described in 1970 by Hosli [10] and subsequently popularized by Snow et al. [8, 9]. Despite the widespread use of both TIP urethroplasty and UCF repair, there is a lack of data describing TVF use for UCF following TIP urethroplasty. We have previously examined our results with the use of TVF for UCF following TIP urethroplasty [11]. We now update that experience in the most difficult patients, those who have undergone multiple previous penile surgeries including previous failed UCF repair following TIP.

## 2. MATERIALS AND METHODS

### 2.1. Patient selection

We retrospectively reviewed all records of patients undergoing TVF repair of post-TIP UCF at our practice between

January 2000 and December 2005. Only patients who had failed previous UCF repair were included in this study. All final UCF repairs were performed by the authors, although initial urethroplasty was performed elsewhere in some patients. Surgeries were performed under general anesthesia in our outpatient surgical facility with a 6-month minimum healing period between the previous penile surgery and UCF repair. For each patient, we abstracted the following data: age, surgeon, number of previous surgeries, number and location of fistulae, original pre- and postoperative location of urethral meatus, surgical/anesthetic duration, length of followup, and postoperative complications. We loosely defined complications to include meatal stenosis, postoperative wound infection, scrotal hematoma, penile torque, penile tethering, or recurrence of fistulae.

## 2.2. Surgical technique

Our surgical technique has been previously described [11]. Briefly, all patients undergo calibration of the distal urethra. Dilute Betadine solution is then instilled into the urethra through the meatus to visually confirm the exact location and number of all UCF. A Foley catheter is placed in the bladder. Each UCF tract is excised, and the urethra is primarily closed in two layers using 7-0 PDS suture. A 1-cm incision is then made at the penoscrotal junction and a flap of tunica vaginalis is harvested, taking great care to avoid inclusion of cremasteric muscle fibers. Flap length is determined by the distance from the harvest site to the UCF site. The TVF is then tunneled underneath the penile skin and brought out through the most distal UCF tract. The TVF is then fixed at each UCF site using 7-0 PDS. The skin overlying each UCF tract is then closed.

## 3. RESULTS

Twelve boys (mean age 2.2 years) underwent TVF repair of recurrent UCF at our institution during the study period. Six boys had distal shaft and 6 had proximal shaft or penoscrotal hypospadias. All patients had originally undergone TIP repair with subsequent UCF formation; 4 patients (33%) had their initial urethroplasty performed at our institution, with the remainder being referred after initial TIP repair done elsewhere. Eleven fistulae (92%) developed spontaneously within the first 2 years after initial TIP repair. One patient did well postoperatively but ultimately developed a UCF after direct trauma to the penis.

All boys had undergone previous attempted UCF repair, with 8 (67%) undergoing 1 repair, 2 (17%) undergoing 2 repairs, and 1 each (8%) undergoing 3 and 4 previous repairs. All patients had a subcoronal UCF, while 8 (67%) were found to have multiple fistulae along the distal shaft: 4 each (33%) with 3 and 4 fistulae, including 1 patient with a penoscrotal fistula. Median operative time was 45 minutes (range 30–90).

No pre- or postoperative complications have as yet occurred in any patient, including hematoma, wound infection, abscess, or secondary chordee or torque. After a mean followup of 32 months (range 16–48 months), no patient has yet had a recurrence of their UCF.

Following our initial experience with the patients described above, we have since performed this procedure on an additional 10 children, none of whom have had a fistula recurrence in followup of less than one year.

## 4. DISCUSSION

The use of TIP urethroplasty has greatly increased since its initial introduction by Snodgrass in 1994 [3], with several centers reporting it to, now, be their primary urethroplasty technique [5, 12]. However, the procedure is not without potential complications, including meatal stenosis, urethral stricture or diverticulum, wound dehiscence, and UCF. In a recent review, a UCF rate of 2.4% was noted [7]. Several reports, however, show a much higher fistula rate, including those of Chatterjee et al. (15%) [13], Amukele et al. (17%) [14], and Guralnick et al. (16%) [15].

Snow et al. have advocated the preventative use of TVF during primary hypospadias repair. When combined with use of the operative microscope, their reported posturethroplasty UCF rate is 0%, with a 2.2% complication rate, namely, scrotal hematoma and abscess [8]. The utilization of TVF has also been described as a means of UCF repair following initial urethroplasty using several techniques, with a combined recurrence rate of 7.9% and no complications reported [16–20]. Pattaras and Rushton have reported two patients who developed severe penile torque several years after primary urethroplasty using TVF in a preventative manner. In both cases the flap was simply divided with subsequent resolution of the torque [21].

The advantages of TVF are myriad, particularly in the reoperative patient. As the tunica lies well away from the operative field of the penile shaft, its blood supply remains uninterrupted even in the setting of numerous reoperations. Operative access to tunica vaginalis is technically simple, as evidenced by our median anesthesia time of 45 minutes. The low complication rate in our hands, which is consistent with previous reports [8, 16–18, 20, 21], provides further evidence that the procedure is safe and easy to perform, even in the setting of a reoperative patient with multiple fistulae. Obviously, strict adherence to the basic principles of UCF and hypospadias repair should be maintained.

The limitations of this study are primarily a question of length of followup; as noted by Pattaras and Rushton [21], several years may need to elapse before the development of truly long-term complications. Our relatively small sample size and average followup of 32 months may not be adequate to fully demonstrate all complications and thus may falsely lower our complication rate. However, it should be noted that complication rates are low even in studies with significantly longer followup [8]. This lends a measure of reassurance that our rates are not overly optimistic. Further, we feel that many complications can be successfully avoided by careful attention to detail—specifically, ensuring that the TVF is of adequate length in order to avoid secondary chordee and that no cremasteric fibers are included with the flap in order to avoid penile torque. By following these simple principles, a technically simple, highly successful repair of

recurrent UCF can be accomplished in minimal operative time.

## 5. CONCLUSIONS

Tunneled TVF repair is a highly successful technique for the treatment of posturethroplasty recurrent UCF. The technique is simple and quick to perform with no complications encountered in our experience. TVF repair is particularly useful as the tissue of choice for treating UCF in the repeat surgical setting following initial failed TIP urethroplasty, with excellent results at long-term followup.

## REFERENCES

- [1] J. Lascaratos, A. Kostakopoulos, and G. Louras, "Penile surgical techniques described by Oribasius (4th century CE)," *BJU International*, vol. 84, no. 1, pp. 16–19, 1999.
- [2] E. D. Smith, "The history of hypospadias," *Pediatric Surgery International*, vol. 12, no. 2-3, pp. 81–85, 1997.
- [3] W. Snodgrass, "Tubularized, incised plate urethroplasty for distal hypospadias," *The Journal of Urology*, vol. 151, no. 2, pp. 464–465, 1994.
- [4] W. Snodgrass, M. Koyle, G. Manzoni, R. Hurwitz, A. Caldameone, and R. Ehrlich, "Tubularized incised plate hypospadias repair for proximal hypospadias," *The Journal of Urology*, vol. 159, no. 6, pp. 2129–2131, 1998.
- [5] J. G. Borer, S. B. Bauer, C. A. Peters, et al., "Tubularized incised plate urethroplasty: expanded use in primary and repeat surgery for hypospadias," *The Journal of Urology*, vol. 165, no. 2, pp. 581–585, 2001.
- [6] W. T. Snodgrass and A. Lorenzo, "Tubularized incised-plate urethroplasty for hypospadias reoperation," *BJU International*, vol. 89, no. 1, pp. 98–100, 2002.
- [7] W. T. Snodgrass, "Tubularized incised plate hypospadias repair: indications, technique, and complications," *Urology*, vol. 54, no. 1, pp. 6–11, 1999.
- [8] B. W. Snow, P. C. Cartwright, and K. Unger, "Tunica vaginalis blanket wrap to prevent urethrocutaneous fistula: an 8-year experience," *The Journal of Urology*, vol. 153, no. 2, pp. 472–473, 1995.
- [9] B. W. Snow, "Use of tunica vaginalis to prevent fistulas in hypospadias surgery," *The Journal of Urology*, vol. 136, no. 4, pp. 861–863, 1986.
- [10] P. O. Hosli, "Eine technik zum verschluss von harnrohrenfistein," *Urologe*, vol. 9, p. 129, 1970.
- [11] J. C. Routh, J. J. Wolpert, and Y. Reinberg, "Tunneled tunica vaginalis flap is an effective technique for recurrent urethrocutaneous fistulas following tubularized incised plate urethroplasty," *The Journal of Urology*, vol. 176, no. 4, pp. 1578–1581, 2006.
- [12] R. E. Steckler and M. R. Zaontz, "Stent-free Thiersch-Duplay hypospadias repair with the Snodgrass modification," *The Journal of Urology*, vol. 158, no. 3, pp. 1178–1180, 1997.
- [13] U. S. Chatterjee, M. K. Mandal, S. Basu, R. Das, and T. Majhi, "Comparative study of dartos fascia and tunica vaginalis pedicle wrap for the tubularized incised plate in primary hypospadias repair," *BJU International*, vol. 94, no. 7, pp. 1102–1104, 2004.
- [14] S. A. Amukele, J. A. Stock, and M. K. Hanna, "Management and outcome of complex hypospadias repairs," *The Journal of Urology*, vol. 174, no. 4, part 2, pp. 1540–1543, 2005.
- [15] M. L. Guralnick, A. al-Shammari, P. E. Williot, and M. P. Leonard, "Outcome of hypospadias repair using the tubularized, incised plate urethroplasty," *The Canadian Journal of Urology*, vol. 7, no. 2, pp. 986–991, 2000.
- [16] E. H. Landau, O. N. Gofrit, S. Meretyk, G. Katz, D. Golijanin, O. Z. Shenfeld, and D. Pode, "Outcome analysis of tunica vaginalis flap for the correction of recurrent urethrocutaneous fistula in children," *The Journal of Urology*, vol. 170, no. 4, part 2, pp. 1596–1599, 2003.
- [17] Z. Kirkali, "Tunica vaginalis: an aid in hypospadias surgery," *British Journal of Urology*, vol. 65, no. 5, pp. 530–532, 1990.
- [18] R. B. Singh and N. M. Pavithran, "Tunica vaginalis interposition flap in the closure of massive disruption of the neourethral tube (macro urethrocutaneous fistulae)," *Pediatric Surgery International*, vol. 20, no. 6, pp. 464–466, 2004.
- [19] K. R. Shankar, P. D. Losty, M. Hopper, L. Wong, and A. M. K. Rickwood, "Outcome of hypospadias fistula repair," *BJU International*, vol. 89, no. 1, pp. 103–105, 2002.
- [20] G. E. Voges, H. Riedmiller, and R. Hohenfellner, "Tunica vaginalis free grafts for closure of urethrocutaneous fistulas," *Urologia Internationalis*, vol. 45, no. 2, pp. 88–91, 1990.
- [21] J. G. Pattaras and H. G. Rushton, "Penile torque after the use of tunica vaginalis blanket wrap as an aid in hypospadias repair," *The Journal of Urology*, vol. 161, no. 3, pp. 934–935, 1999.

## Research Article

# Adult Urethral Stricture Disease after Childhood Hypospadias Repair

Shou-Hung Tang,<sup>1</sup> Clarisa C. Hammer,<sup>2</sup> Leo Doumanian,<sup>3</sup> and Richard A. Santucci<sup>3</sup>

<sup>1</sup> Department of Urology, Tri-Service General Hospital, Neihu, Taipei 114, Taiwan

<sup>2</sup> Department of Surgery, St. John Oakland Hospital, Madison Heights, MI 48071, USA

<sup>3</sup> Center for Urologic Reconstruction, Detroit Receiving Hospital, University Health Center, MI 48201, USA

Correspondence should be addressed to Richard A. Santucci, rsantucc@dmc.org

Received 26 March 2008; Accepted 6 August 2008

Recommended by Miroslav L. Djordjevic

**Background.** Adult patients with urethral stricture after childhood hypospadias surgeries are infrequently discussed in the literature. We report our experience in treating such patients. **Materials and Methods.** A retrospective chart review was performed. From 2002 through 2007, nine consecutive adult patients who had current urethral stricture and had undergone childhood hypospadias surgeries were included. All adult urethral strictures were managed by a single surgeon. **Results.** Mean patient age was 38.9 years old. The lag time of urethral stricture presentation ranged from 25 to 57 years after primary hypospadias surgery, with an average of 36 years. Stricture length ranged from 1 to 17 cm (mean: 10.3 cm). Open graft-based urethroplasties were performed in 4/9 cases. Salvage perineal urethrostomy was performed in 2/9 cases. Another 3 cases chose to undergo repeat urethrotomy or dilatations—none of these patients was cured by such treatment. Complications included one urethrostomy stenosis and one urinary tract infection. **Conclusion.** Urethral stricture may occur decades after initial hypospadias surgery. It can be the most severe form of anterior urethral stricture, and may eventually require salvage treatment such as a perineal urethrostomy. Patients undergoing hypospadias surgery should receive lifelong follow-up protocol to detect latent urethral strictures.

Copyright © 2008 Shou-Hung Tang et al. This is an open access article distributed under the Creative Commons Attribution License, which permits unrestricted use, distribution, and reproduction in any medium, provided the original work is properly cited.

## 1. INTRODUCTION

Hypospadias is a common congenital abnormality occurring in 1/300 live births, and is the most common congenital penile anomaly [1, 2]. Numerous surgical techniques have been developed to correct this anomaly. However, no single method is considered the standard of care, and they all share the common complications of occasional urethrocutaneous fistula and urethral strictures. The incidence of urethral stricture after hypospadias surgery in pediatric population is reported, and occurs in about 6.5% after short followup [3]. On the other hand, there are few reports dealing with urethral strictures in adults after they had hypospadias surgery in childhood. In the current series, we described our experiences in 9 such cases, and review their particular characteristics and suggested treatments.

## 2. MATERIALS AND METHODS

A retrospective chart review was performed from 2002 through 2007. Nine consecutive adult patients who had

current urethral strictures and had undergone childhood hypospadias surgeries were included in this study. All adult urethral strictures were managed by a single surgeon (RAS). The strictures in these patients were all symptomatic and were documented by retrograde urethrography (RUG). Information regarding hypospadias repairs, previous urethral manipulations, presenting symptoms, stricture length, definite treatment, and short-term outcomes were obtained from medical records. In cases undergoing perineal urethrostomy, we suggested the “side-to-side” technique, which comprised longitudinal urethrotomy and everting the mucosal and submucosal layers of the urethra to the incised skin. Graft-based urethroplasty using buccal mucosal graft, in one-stage or two-stage repairs, was the preferred choice of formal reconstruction.

## 3. RESULTS

Mean patient age was 38.6 years old, and mean followup period was 1.9 years. All patients had their primary



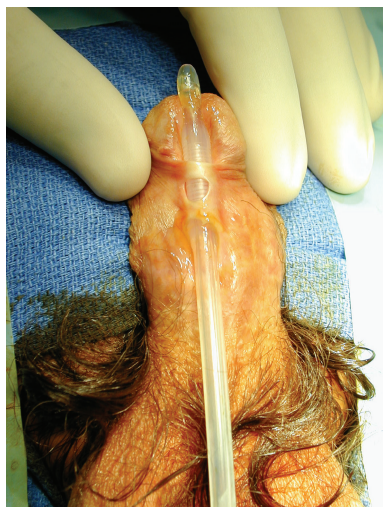

FIGURE 1: Typical complex urethral stricture after childhood hypospadias repair, with a distal penile location and complicating fistulae.

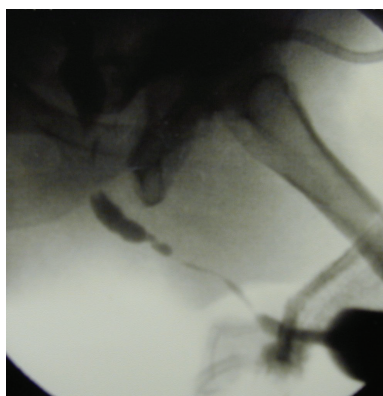


FIGURE 2: Typical retrograde urethrogram appearance of adult stricture after hypospadias repair showing a long stricture sparing only the bulbar urethra.

hypospadias surgeries between 1 and 12 years old. The lag time of the adult urethral stricture presentation ranged from 25 to 57 years, with an average of 36 years between hypospadias surgery and presentation to our clinic with urethral stricture.

Four of the 9 patients (44%) presented with acute urinary retention, and one of these patients developed acute renal failure due to prolonged urinary retention, before stricture was diagnosed. The other associated complications included fistula in one case. Only three of the 9 patients (33%) suffered from lower urinary tract symptoms (LUTS) including decreased voiding stream, spraying, dribbling, and nocturia. In one case, urethral stricture was discovered when we evaluated unresolved urethrocutaneous fistulas (see Figure 1). Before transferred to our institute, 5/9 patients had undergone endoscopic treatment for strictures, and 2/9 had failed open urethroplasties.

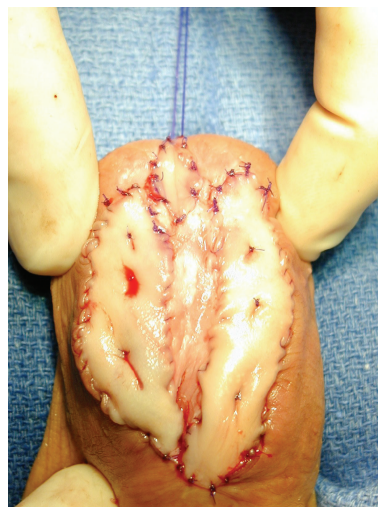


FIGURE 3: First-stage urethroplasty with buccal grafts.

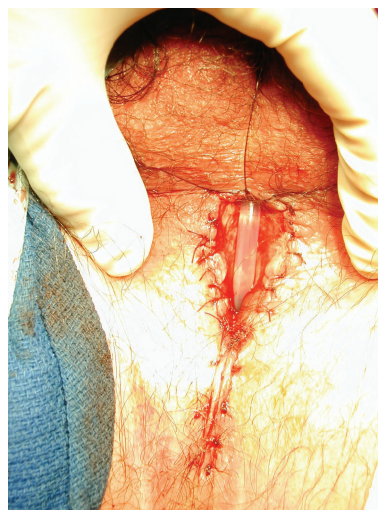

FIGURE 4: Perineal urethrostomy, performed using our suggested "side-to-side" technique.

Penile urethra was involved in all cases, and bulbar urethra was involved in 5/9. The stricture length ranged from 1 to 17 cm (mean, 10.3 cm) (see Figure 2, Table 1)

Open urethroplasties with buccal mucosal grafts were performed in 4/9 cases: two with single-stage repair and two with 2-stage repair with buccal grafts (see Figure 3). Salvage perineal urethrostomy was performed in 2/9 cases, usually in patients who did not wish complex definitive urethral surgery (see Figure 4). The perineal urethrostomy was planned to be permanent. Another 3 cases chose to receive repeated endoscopic treatments (direct visual internal urethrotomy (DVIU) and/or dilatations) although perineal urethrostomy or urethroplasty had been offered.

None was cured by DVIU/dilatations. Four patients receiving open urethroplasty with buccal grafts were free



TABLE 1: Characteristics of 9 adult urethral stricture patients with childhood hypospadias repair.

age	length (cm)	treatment	recurrence
25	1	Single-stage dorsal-onlay urethroplasty with buccal mucosal graft	no
26	6	Single-stage dorsal-onlay urethroplasty with buccal mucosal graft	no
39	4	Two-stage urethroplasty with buccal mucosal graft in first stage	no
55	5	Two-stage urethroplasty with buccal mucosal graft in first stage	no
26	17	DVIU/dilatations	yes
48	13	DVIU/dilatations	yes
37	15	DVIU/dilatations	yes
36	15	perineal urethrostomy	no
57	17	perineal urethrostomy	Yes, Y-V plasty

of stricture recurrence. Stenosis of urethrostomy developed in one case and was successfully managed by a V-Y plastic technique.

#### 4. DISCUSSION

There is little literature mentioning adult urethral stricture in hypospadias patients. Barbagli et al. published a series of 60 adults with previously failed hypospadias repair [4], including 34 cases that underwent treatment for urethral strictures. Their overall successful rate was 75% (83% for one-stage repair, 68% for multistage repairs). It was evident that those who needed multistage repair plans were at higher risk of failure because they had more severe strictures and extremely poor quality native tissue than those on whom the surgeons would consider risking a single-stage repair.

##### 4.1. How are these hypospadias stricture patients different?

Adult stricture patients with previous hypospadias repair differ from a usual population of stricture patients. First, they sometimes had no voiding complaints even when their strictures were severe. Second, they had complicating problems seldom seen in other stricture patients, including complete renal failure and urethral fistula. Third, they have a poor quality of tissue which requires more complex repairs such as first-stage Johanson operations, with buccal grafts placed in the first stage, followed by second-stage closure later. The associated complications do represent a factor influencing the surgical strategy. However, major determinants were the stricture length, availability of healthy tissue, as well as surgeon's own preference. In patients with long stricture and prominent scarring, we suggested staged repairs if formal reconstruction was planned. Last, they often have such long and hopeless abnormal anterior urethras, that is, by both patient and surgeon, it is determined best to treat them expediently with simple perineal urethrostomy instead of formal repair. In this way, reliable egress of urine can be virtually guaranteed after a short 1-2 hour operation, an option chosen by 5/9 (56%) of our cases. Our experience here exemplified that heroic measures were not always justified

to treat the severest urethral strictures, and that perineal urethrostomy can be a gratifying option.

##### 4.2. Healing in adults and children

While differences in wound healing ability between children and adults are well described [5], little direct data is available on the relative behavior of adult and childhood tissue in the urologic arena. Adult hypospadias surgery has been reported, and may provide some insight into the pitfalls of complex reconstructive surgery in the adult. For example, in a series of adults who underwent adult hypospadias repair, redo operations had a worse outcome than primary cases [6]. They found that previous surgeries and poor tissue quality attributed to higher failure rates. There was a significant difference in terms of wound healing, infection, complication rates, and overall success in adults compared to children. Increased surgical difficulty and high failure rate after redo adult hypospadias surgery may be well applied to adult urethral strictures such as seen in our population.

##### 4.3. Incidence of adult urethral stricture after childhood hypospadias repair

Urethral stricture is a known complication following hypospadias repair [7–9], but the true incidence is unknown. Some childhood hypospadias series do not follow the patients long enough to report any strictures, and when series do report strictures, they usually report them as acute events that occur while the patient is still in childhood, not later as adults. A series by Duel et al., for example, showed a stricture incidence as high as 6.5% (38 of 582) after pediatric hypospadias surgeries [3]. They demonstrated that strictures occurred after a (mean) interval of 27 months. 79% of these pediatric urethral strictures ultimately required open urethroplasty for correction, and they had a 78% overall successful rate.

The wide range of stricture length in our series was mainly affected by original type of hypospadias. Patients undergoing repair for scrotal hypospadias would have greater chance to have a subsequent longer urethral stricture. Unfortunately, the exact type of original hypospadias cannot

be determined simply by gross appearance or by history in most cases.

#### 4.4. How to treat the adult stricture patient

Repair of posthypospadias strictures in children has been widely discussed by pediatric urologists. Modern series now favored single-stage, two-stage buccal mucosal graft repair, or urethroplasties utilizing tunica vaginalis [10, 11]. We agree, and tend to offer two-stage buccal mucosal repairs such as described by Johanson in adults. We also acknowledge that some of these patients have such extensive disease, and little interest in a two-stage operation to fix the problem, and thus are most appropriately treated with a perineal urethrostomy. Perineal urethrostomy was offered as a second choice in addition to formal urethral repair. Comorbidity and previous failed urethroplasty were the major factors influencing patients who accepted perineal urethrostomy.

## 5. CONCLUSION

Urethral stricture can occur decades after initial hypospadias surgery. Patient often have few voiding complaints and can present with severe complications. The stricture can be very extensive and may require salvage treatment such as a perineal urethrostomy. Two-stage urethroplasties with buccal mucosal grafts can achieve good result when necessary. We suggest that patients undergoing hypospadias surgeries should receive lifetime followup to detect latent urethral strictures, and that research reports discussing stricture after hypospadias repair include very-long-term followup data to determine the exact incidence of this problem.

## REFERENCES

- [1] L. S. Baskin, K. Himes, and T. Colborn, "Hypospadias and endocrine disruption: is there a connection?" *Environmental Health Perspectives*, vol. 109, no. 11, pp. 1175–1183, 2001.
- [2] C. P. Nelson, J. M. Park, J. Wan, D. A. Bloom, R. L. Dunn, and J. T. Wei, "The increasing incidence of congenital penile anomalies in the United States," *The Journal of Urology*, vol. 174, no. 4, part 2, pp. 1573–1576, 2005.
- [3] B. P. Duel, J. S. Barthold, and R. Gonzalez, "Management of urethral strictures after hypospadias repair," *The Journal of Urology*, vol. 160, no. 1, pp. 170–171, 1998.
- [4] G. Barbagli, M. De Angelis, E. Palminteri, and M. Lazzeri, "Failed hypospadias repair presenting in adults," *European Urology*, vol. 49, no. 5, pp. 887–895, 2006.
- [5] R. J. Mackool, G. K. Gittes, and M. T. Longaker, "Scarless healing: the fetal wound," *Clinics in Plastic Surgery*, vol. 25, no. 3, pp. 357–365, 1998.
- [6] T. W. Hensle, S. Y. Tennenbaum, E. A. Reiley, and J. Pollard, "Hypospadias repair in adults: adventures and misadventures," *The Journal of Urology*, vol. 165, no. 1, pp. 77–79, 2001.
- [7] A. B. Retik and A. Atala, "Complications of hypospadias repair," *Urologic Clinics of North America*, vol. 29, no. 2, pp. 329–339, 2002.
- [8] J. W. Duckett Jr., G. W. Kaplan, J. R. Woodard, and C. J. Devine Jr., "Panel: complications of hypospadias repair," *Urologic Clinics of North America*, vol. 7, no. 2, pp. 443–454, 1980.
- [9] H. C. Scherz, G. W. Kaplan, M. G. Packer, and W. A. Brock, "Post-hypospadias repair urethral strictures: a review of 30 cases," *The Journal of Urology*, vol. 140, no. 5, part 2, pp. 1253–1255, 1988.
- [10] W. Snodgrass and J. Elmore, "Initial experience with staged buccal graft (Bracka) hypospadias reoperations," *The Journal of Urology*, vol. 172, no. 4, supplement 1, pp. 1720–1724, 2004.
- [11] J. Zargooshi, "Tube-onlay-tube tunica vaginalis flap for proximal primary and reoperative adult hypospadias," *The Journal of Urology*, vol. 171, no. 1, pp. 224–228, 2004.

## Clinical Study

# Male Genitoplasty for Intersex Disorders

**Shilpa Sharma and Devendra K. Gupta**

*Department of Pediatric Surgery, All India Institute of Medical Sciences, New Delhi 110029, India*

Correspondence should be addressed to Devendra K. Gupta, profdkgupta@gmail.com

Received 10 May 2008; Accepted 5 August 2008

Recommended by Miroslav L. Djordjevic

**Aim.** To evaluate surgical procedures adopted for male genitoplasty in intersex disorders. **Patients and Methods.** Case records of intersex patients undergoing male genitoplasty from Pediatric Intersex clinic were studied. **Results.** Of 356 intersex cases undergoing urethroplasty from 1989–2007, the hypospadias was penoscrotal (68%), scrotal (17%) and perineal (15%). 351 patients underwent chordee correction for mild: moderate: severe chordee in 24 : 136 : 191 cases. Byars flaps were fixed upto the corona in 267 cases. Urethroplasty performed was Theirsch duplay in 335 cases, Snodgrass in 16 cases and Ducketts onlay graft in 5 cases that did not require chordee correction. Age at urethroplasty was 2.5 years—22 years (mean 11.5 years, median—5.6 years). Penoscrotal transposition correction and testicular prosthesis insertion were performed independently. Complications included fistula (45), recurrent fistula (11), stricture (12), baggy urethra (8) and recurrent infection due to persistent vaginal pouch (5). Additional distal urethroplasty was required in 15 patients for previous urethroplasty done upto the corona 5–15 years earlier. **Conclusion.** Hypospadias in intersex disorders is associated with severe chordee in most cases and requires an early chordee correction to allow phallic growth, staged urethroplasty and multiple surgeries to achieve good cosmetic and functional results.

Copyright © 2008 S. Sharma and D. K. Gupta. This is an open access article distributed under the Creative Commons Attribution License, which permits unrestricted use, distribution, and reproduction in any medium, provided the original work is properly cited.

## 1. INTRODUCTION

To perform urethroplasty for cases of intersex disorders, now designated as disorders of sex differentiation, it requires far sight into the problems that are faced even many years after the urethroplasty. A number of surgical procedures need to be performed before the final outcome is attained. These will be discussed in detail in this article along with the authors experience in this field.

The vital decision in cases of intersex disorders is the accurate diagnosis and the gender assignment. The gender assignment takes into account the prevalent social factors in a community and the parent's desire [1]. There are still some countries where the parents would prefer to have an inadequate male rather than an incomplete female.

With lot of global discussion on the patient's wishes when they attain puberty, it has now become important to keep a possibility of a change in gender in some cases and wait a little longer before a definitive surgery unless there is parental pressure. These controversial issues have long been debated and vary from community to community.

## Purpose

This work aims to study the surgical procedures performed for male genitoplasty in cases of intersex disorders.

## 2. PATIENTS AND METHODS

Case records of 356 intersex patients undergoing male genitoplasty from 1989–2007 from the Pediatric Intersex clinic of the department of pediatric surgery, AIIMS, were studied. Preoperative investigations included chromosomal analysis, ascending urethrogram, abdominal ultrasonography, and hormonal work up to establish the diagnosis of intersexuality.

## 3. RESULTS

Of 526 patients that had undergone urethroplasty, 356 were cases of intersex disorders. These included 298 cases of male pseudohermaphrodite, 24 cases of True Hermaphrodite, 27 cases of mixed gonadal dysgenesis and dysgenetic male

pseudohermaphrodite, and 7 cases of congenital adrenal hyperplasia.

The hypospadias was penoscrotal in 242 (68%) cases, scrotal in 61 (17%), and perineal in 53 (15%) cases (Figures 1, 2). The müllerian duct opening was present in the perineum along with the urethral meatus in 35 (10%) cases. A genitogram performed in all cases was sufficient to outline a vaginal pouch and establish the diagnosis of male pseudohermaphrodite in the presence of unilateral- or bilateral-descended gonads and absent uterus with XY karyotype.

Out of 356 cases, 351 patients had chordee and underwent chordee correction between 2 months—7.6 years age (mean 23.6 months). Five patients did not have chordee. The chordee was mild: moderate: severe in 24:136:191 cases. Byars flaps for the chordee correction were fixed up to the corona in 267 cases. Testosterone (5–10%) cream was advised for local application daily for 3 months at one time. The patients were called for follow up after that, and the response was assessed. If response was noted, it was continued for other three months. The treatment was stopped if any side effects were noted.

Periodic local treatment with testosterone was also advised later, during childhood till puberty, to help in penile growth in patients with low testosterone level and those having a small-sized phallus. However, systemic injections were given only postpuberty to prevent bone maturation if given earlier.

Theirsch Duplay urethroplasty was performed in 335 cases, Snodgrass urethroplasty was made in 16 cases, and Ducketts onlay graft was performed in 5 cases for whom chordee correction was not required. The age at urethroplasty was 2.5–22 years (mean 11.5 years, median—5.6 years). Scrotal transpositions for cases with penoscrotal transposition as well as testicular prosthesis were performed as an independent operation so as not to jeopardize the perineal and preputial flaps (Figure 3). The complications included fistula formation in 45 cases, recurrent fistula formation in 11 cases, stricture formation in 12 cases, baggy urethra in 8 cases, and recurrent infection due to persistent vaginal pouch in 5 cases. Postoperative infection was more in the boys that were operated after ten years of age. Additional surgery was performed for diverticuli in 3 cases. An additional distal urethroplasty was requested by 15 patients, where the urethral tube was constructed earlier only up to the corona 5–15 years following the previous urethroplasty. Five patients out of 356 (1.4%) developed hair growth in the region of the scrotal neourethral tube that led to infection and urinary obstruction. They had to undergo epilation or redourethroplasty with removal of the skin patch.

The urethroplasty has been completed in 324 patients and 27 patients are still awaiting the urethroplasty. Of the 46 cases that had attained puberty, 23 (50%) of them had to milk their urethra after voiding. Intramuscular testosterone was administered every month for cases having a low testosterone level and those having a small-sized phallus. None had residual chordee on interrogation of the patients. The cases in which the chordee correction had been delayed

had a relatively small phallus than those in whom chordee correction had been done earlier. The postoperative urethrography revealed few urethral diverticulae and pouches in 5 cases that were otherwise asymptomatic. The uroflowmetry revealed low mean flow in 20 out of 46 cases. This was due to the fact that there is poor outflow resistance in these cases due to underdeveloped corpus spongiosum. Ten out of twenty cases interviewed were able to ejaculate, though the amount was less and 8 had to milk the ejaculate.

#### 4. DISCUSSION

To manage disorders of sexual differentiation, a growing need is felt for extensive counseling, informed consent, and adherence to ethical and legal norms that protect the rights of the child as outlined in respective constitutions and a multidisciplinary approach [2].

The foremost step is the sex assignment. This should be based upon what is judged to be the most likely adult gender identity, diagnosis, genital appearance and surgical options, fertility, cultural pressures, as well as family dynamics and social circumstance, with preference given to psychosocial factors when the outcome is unpredictable [3]. However, the complex management of these patients must be individualized [3]. In this series, seven cases of CAH were reared as males as they had already been reared as males for a long time before they came for treatment.

Gender assignment procedures have been questioned by intersex activists opposed to early genital surgery [4]. Western societies have a binary perspective on gender and this leads to a stigma on intersex cases [4]. Also, the current data challenges the past practice of sex reassignment, thus, a careful judgment is warranted [5]. The debate whether surgical genitaloplasty affects gender identity in the intersex infant centres around which is more vital for development of gender identity, that is, the biological sex of a child or the sex in which a child is reared [6].

Hormonal and genetic factors may have a more important role in gender identity and sexual satisfaction than previously recognized, whereas the importance of phallus size to male gender identity and sexual satisfaction may have been overestimated [7].

The impact of androgen imprinting on the developing brain has also been debated. A neutral upbringing may induce psychosocial consequences that are more damaging than carefully considered neonatal sex attribution and concordant surgical genitaloplasty [6].

The spectrum of iatrogenic harm to children with intersex characteristics has now become a legal issue [8]. Thus, a multidisciplinary approach involving pediatric surgeons, endocrinologist, and psychiatry is necessary, along with educational programmes that promote tolerance in society to variations in gender [4].

The most common disorder of sexual differentiation is male pseudohermaphroditism that comprises about 55–60% of all cases [9]. However, some series from endocrine centres have the largest number of cases as congenital adrenal hyperplasia [10]. The causes of male pseudohermaphroditism include 17 beta-hydroxysteroid



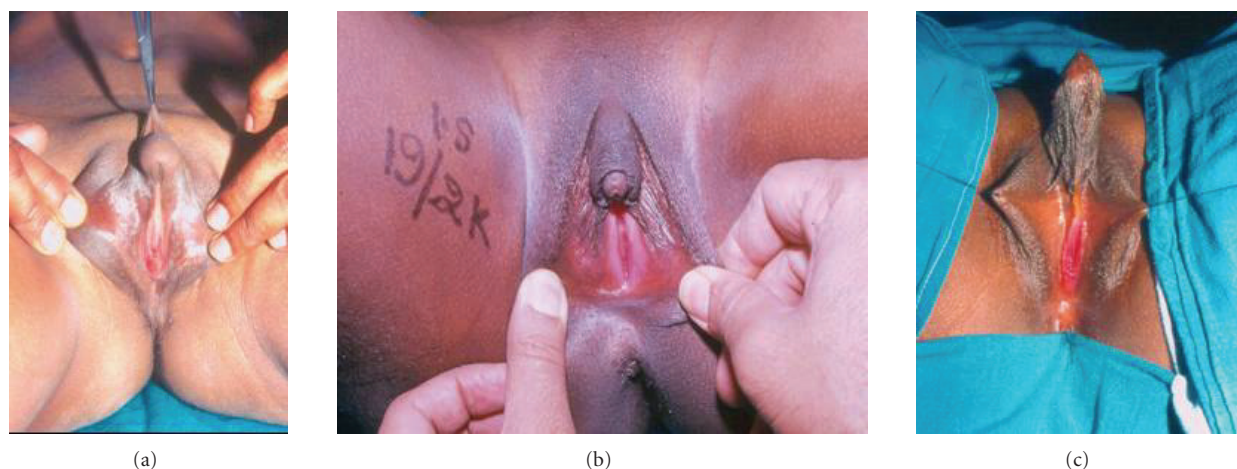

FIGURE 1: (a) A case of mixed gonadal dysgenesis with severe chordee, perineal hypospadias, and visible urethral and vaginal openings. (b) A case of intersex disorder with small phallus, fish mouth urethra, and mucosa-lined urethral plate. (c) Post chordee correction case of intersex disorder for second stage reconstruction with long urethroplasty.

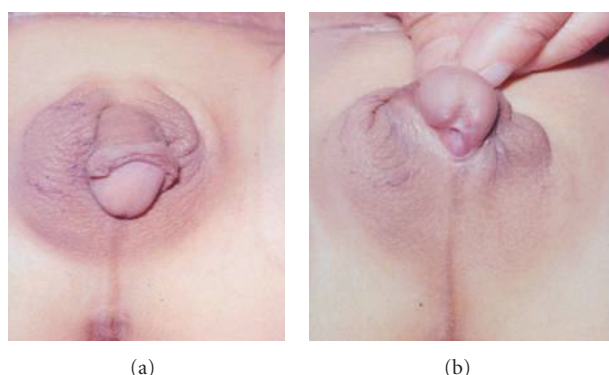


FIGURE 2: A case of True Hermaphrodite with (a) well-developed phallus and right scrotal ovotestis gonad, and (b) penoscrotal hypospadias and severe chordee.

dehydrogenase deficiency, 3 beta-hydroxysteroid dehydrogenase deficiency, 5 alpha-reductase deficiency, and idiopathic male pseudohermaphroditism [11].

The timing of performing the masculinisation procedures is still a controversy. However, most feel that the optimal time for external genital correction is 2 years of age [3, 9, 12]. However, in this series, most of the patients presented late after running from pillar to post for accurate diagnosis. Moreover, in recent years, traditional views regarding the management of infants with intersex conditions have been challenged [7].

Some authors perform urethroplasty only after obligatory testosterone treatment [10]. The application of testosterone helps to make the skin supple besides increasing the length and girth of the phallus. Though prior to 1980s, single-stage reconstruction was in vogue, with the passing time, it has been realised that single-stage reconstruction is associated with more complications in cases with intersex disorders [13]. These include fistula formation, complete

stricture, and wound dehiscence. The reason is that the phallus in these cases is inadequate to support the formation of a 6Fr urethral tube formed from the inadequate preputial skin at a tender age.

In this series, the number of urethroplasties in intersex cases is higher than that in hypospadias patients as being a tertiary-level hospital, the cases are selected for operations. Only the difficult cases or those with more proximal hypospadias are dealt with after ruling out intersex disorders.

In this series, most of the cases were operated with a two-stage procedure. In the first stage, the chordee is corrected, followed by urethroplasty from the neopenile skin flaps after an interval of at least 6 months. The Byars flaps for the chordee correction are fixed up to the corona in most cases as the glans is very underdeveloped at the time of chordee correction. The parents are then advised to apply local testosterone. For adequate chordee correction, the urethral plate was divided during the first stage. The fibrous tissue was excised. Total mobilisation was done up to the base of the phallus. As a result, the meatus moved proximally 3–6 cms. The excision of all fibrous strands assures the complete removal of chordee. The intervening deficiency after adequate chordee correction was covered with preputial skin that was mobilised during degloving of the phallus. The authors used to perform Gittes' test to assess chordee in the initial cases but soon realised that it is not necessary in cases where there is no doubt of residual chordee in cases where the urethral plate has been cut.

The severe chordee that is present in most of the cases prevents adequate growth of the phallus. The deficiency of testosterone, either systemically or locally due to various enzyme defects present in these cases, prevents adequate growth of the phallus both in length and girth. The application of steroid cream after chordee correction facilitates proper growth of the phallus that forms a good base for the neourethra. Also, the penile skin in these cases is thin and lacks strength and good vascularity for proper healing.

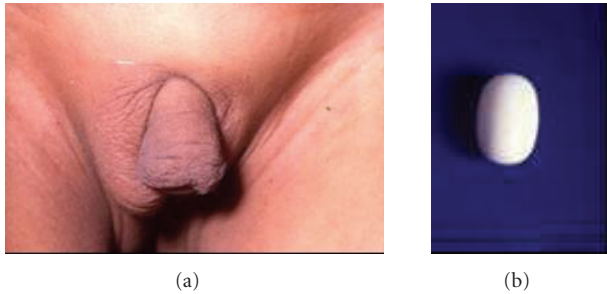


FIGURE 3: (a) A case of true hermaphrodite with right scrotal ovotestis and left undescended gonad needing a prosthesis. (b) Indigenized (DK Gupta) testicular prosthesis made of Teflon.

Dihydrotestosterone (DHT) is beneficial for patients with 5  $\alpha$ -reductase deficiency that are unable to convert testosterone into DHT due to absence/default of receptors. Some of these patients respond with an increase in penile size when 25 mg/d of 2% DHT cream is applied to the external genitalia. However, anabolic effects may enhance hypoglycaemia and bone maturation. Adverse reactions include pruritus, erythema, allergic contact dermatitis, and burning.

Once the phallus size is adequate, urethroplasty is performed. Recurrence of chordee was assessed by artificial penile erection test of Gittes and McLaughlin at the time of stage 2 reconstruction. The most common procedure adopted is Theirsch Duplay urethroplasty. Some authors have performed a single-stage procedure using a transverse pedicled preputial island flap as an onlay, tubularization of the mucosa in the perineal area, and end-to-end anastomosis to a tube made from the pedicled prepuce [11].

However, a one-stage male genitoplasty for male pseudohermaphroditism is accompanied by a reasonable incidence of major complications [11]. Thus, the two-stage technique for male genitoplasty is preferable [12]. The two-stage approach for severe hypospadias without intersex disorders results in excellent function, cosmesis, and patient satisfaction after puberty, with no chordee in patients though minor voiding and ejaculatory problems are to be expected [14].

However, cases with intersex disorders have a deficient spongiosum and thus the urethral tube is poorly supported. About 50% of them have to milk their urethra after voiding to keep themselves dry.

In intersex patients, Mullerian duct remnants are not an unusual occurrence. The presence of a vaginal pouch (utriculus prostaticus) does not affect the urethroplasty. A genitogram performed in all cases is usually sufficient to outline a vaginal pouch and establish the diagnosis. In this series, the Mullerian duct remnants were removed, if present, in all patients assigned a male gender, only the vaginal pouch was preserved. The uterus, fallopian tubes, and upper part of the vagina were removed in all, and the lower part of the pouch was left as such in all cases. The vaginal pouch was not removed in any case of male pseudohermaphrodite.

There is no evidence that removal of utriculus and Mullerian remnants, which are asymptomatic, is necessary.

Due to potential injury to continence mechanisms and for preservation of fertility (vas deferens often joins the utricule), it is better to reserve surgical treatment only to symptomatic cases.

However, there are others who prefer to remove a big or symptomatic utriculus prostaticus [15]. Due to the location of the pouch, a surgical removal from the perineal or sacral route is always risky. If at all required as in symptomatic cases, a laparoscopic removal is much safer. Authors prefer to include the opening of the utriculus in the urethroplasty. If the opening joining the urethra is narrow, the opening is widened endoscopically.

In a series of 47 boys, based on the symptoms and the size of the remnants, the structures were removed in 32 patients by extirpation done by perineal approach in younger asymptomatic children, by transperitoneal approach, by posterior sagittal pararectal approach, or by combined abdominal and perineal approach [15]. Complications like rectal or bladder injuries and temporary impotence after abdominoperineal extirpation may occur during attempted removal.

The presence of Mullerian duct remnants may occasionally lead to symptoms of urinary infection, urinary retention, or epididymitis. However, these are manageable with courses of antibiotics during acute episodes and preventable by executing a habit of milking out the contents after micturition. Thus, on comparing the risks with the benefits, it is wiser to leave the vaginal pouch as such. In this series, only 5 patients had problems due to the vaginal pouch. The rest remained asymptomatic. These were more frequent in the cases of congenital adrenal hyperplasia that preferred to be assigned a male gender.

There may be lack of ejaculation related to frequent intrauterine termination of the vas deferens [15]. Some patients with androgen insensitivity syndrome, that is, the other end of male pseudohermaphrodites who are initially assigned a female gender, may seek help for conversion into a male at a later date. For these cases, the neophallus may be created from sensate-free forearm flaps or regional abdominal flaps that exist [16]. The corporal tissue is preserved for sensations and placed at a suitable place in the perineum.

Most series are satisfied with their functional and cosmetic outcome of masculinising genitoplasty in patients with ambiguous genitalia raised as males [17]. Good results may be expected if the initial phallus size is adequate, especially those that have responded to local testosterone. The results are poor in cases with micropenis and minimal virilisation [13]. Intramuscular testosterone is administered every month to most cases with a low testosterone level. The uroflowmetry revealed low mean flow in 20 out of 46 cases in this series due to the fact that there is poor outflow resistance in these cases due to underdeveloped corpus spongiosum. Spontaneous puberty may be observed in true hermaphrodites raised as males [13]. Most cases have to undergo multiple genital surgeries to correct the appearance of their genitalia and/or to enable sexual functioning [18, 19].

To summarize, hypospadias in intersex disorders is associated with severe chordee in most of the cases and requires an early chordee correction to allow phallic growth. The issue

of genital surgery in infancy remains controversial although many adult patients do concur that infancy is the best time for such procedures. Good anatomical and functional results are achieved better with the two-stage repair and intervening period of local testosterone application.

## REFERENCES

- [1] D. K. Gupta and P. S. N. Menon, "Ambiguous genitalia—an Indian perspective," *Indian Journal of Pediatrics*, vol. 64, no. 2, pp. 189–194, 1997.
- [2] N. R. Maharaj, A. Dhari, R. Wiersma, and J. Moodley, "Intersex conditions in children and adolescents: surgical, ethical, and legal considerations," *Journal of Pediatric and Adolescent Gynecology*, vol. 18, no. 6, pp. 399–402, 2005.
- [3] Z. M. Nabhan and P. A. Lee, "Disorders of sex development," *Current Opinion in Obstetrics and Gynecology*, vol. 19, no. 5, pp. 440–445, 2007.
- [4] N. D. Duncan, L. Gabay, E. Williams, S. E. Dundas, N. Plummer, and P. A. Leake, "Hermaphroditism: cytogenetics, gonadal pathology and gender assignment: a case report," *West Indian Medical Journal*, vol. 55, no. 6, pp. 430–433, 2006.
- [5] D. Frimberger and J. P. Gearhart, "Ambiguous genitalia and intersex," *Urologia Internationalis*, vol. 75, no. 4, pp. 291–297, 2005.
- [6] C. Nihoul-Fékété, "Does surgical genitoplasty affect gender identity in the intersex infant?" *Hormone Research*, vol. 64, supplement 2, pp. 23–26, 2005.
- [7] C. P. Nelson and J. P. Gearhart, "Current views on evaluation, management, and gender assignment of the intersex infant," *Nature Clinical Practice Urology*, vol. 1, no. 1, pp. 38–43, 2004.
- [8] K. Gurney, "Sex and the surgeon's knife: the family court's dilemma... informed consent and the specter of iatrogenic harm to children with intersex characteristics," *American Journal of Law and Medicine*, vol. 33, no. 4, pp. 625–661, 2007.
- [9] Z. Krstić, S. Perovic, S. Radmanović, S. Nečlić, Ž. Smoljanić, and P. Jevtić, "Surgical treatment of intersex disorders," *Journal of Pediatric Surgery*, vol. 30, no. 9, pp. 1273–1281, 1995.
- [10] A. G. Coran and T. Z. Polley Jr., "Surgical management of ambiguous genitalia in the infant and child," *Journal of Pediatric Surgery*, vol. 26, no. 7, pp. 812–820, 1991.
- [11] B. Chertin, D. Koulikov, I. Hadas-Halpern, and A. Farkas, "Masculinizing genitoplasty in intersex patients," *The Journal of Urology*, vol. 174, part 2, no. 4, pp. 1683–1686, 2005.
- [12] W. C. Hecker, "Timing and technic of the surgical correction of childhood intersex genitals including the procedure for partial vaginal aplasia," *Zeitschrift für Kinderchirurgie*, vol. 37, no. 3, pp. 93–99, 1982.
- [13] C. Nihoul-Fékété, E. Thibaud, S. Lortat-Jacob, and N. Josso, "Long-term surgical results and patient satisfaction with male pseudohermaphroditism or true hermaphroditism: a cohort of 63 patients," *The Journal of Urology*, vol. 175, no. 5, pp. 1878–1884, 2006.
- [14] P. N. Lam, S. P. Greenfield, and P. Williot, "2-stage repair in infancy for severe hypospadias with chordee: long-term results after puberty," *The Journal of Urology*, vol. 174, no. 4, part 2, pp. 1567–1572, 2005.
- [15] Z. Krstić, Ž. Smoljanić, Ž. Mićović, V. Vukadinović, A. Sretenović, and D. Varinac, "Surgical treatment of the M"ullerian duct remnants," *Journal of Pediatric Surgery*, vol. 36, no. 6, pp. 870–876, 2001.
- [16] M. Sohn and H. A. G. Bosinski, "Gender identity disorders: diagnostic and surgical aspects," *The Journal of Sexual Medicine*, vol. 4, no. 5, pp. 1193–1208, 2007.
- [17] A. Farkas, D. Koulikov, and B. Chertin, "Masculinizing genitoplasty in male pseudohermaphroditism," *Pediatric Endocrinology Reviews*, vol. 2, no. 1, pp. 15–20, 2004.
- [18] L. Brinkmann, K. Schuetzmann, and H. Richter-Appelt, "Gender assignment and medical history of individuals with different forms of intersexuality: evaluation of medical records and the patients' perspective," *The Journal of Sexual Medicine*, vol. 4, no. 4, pp. 964–980, 2007.
- [19] S. Sharma and D. K. Gupta, "Gender assignment and hormonal treatment for disorders of sexual differentiation," *Pediatric Surgery International*, 2008.

## Review Article

# Review of the Surgical Approaches for Peyronie's Disease: Corporeal Plication and Plaque Incision with Grafting

Viet Q. Tran, Dennis H. Kim, Timothy F. Lesser, and Sherif R. Aboseif

*Section of NeuroUrology and Reconstructive Surgery, Department of Urology, Kaiser Permanente Medical Center, 4900 Sunset Boulevard, Los Angeles, CA 90027, USA*

Correspondence should be addressed to Sherif R. Aboseif, sherif.r.aboseif@kp.org

Received 2 May 2008; Revised 25 August 2008; Accepted 9 September 2008

Recommended by Miroslav L. Djordjevic

The understanding and management of Peyronie's disease (PD) has improved but elucidating the exact etiology of the disease has yet to be achieved. In this paper, we review the historical and clinical aspects of PD. We focus on the evolution of surgical management for PD and review recent published articles that compare popular surgical techniques such as plication and plaque incision with vein graft. These two techniques have been reported to be equivalent with respect to patient satisfaction; however, each technique has its own advantages and disadvantages.

Copyright © 2008 Viet Q. Tran et al. This is an open access article distributed under the Creative Commons Attribution License, which permits unrestricted use, distribution, and reproduction in any medium, provided the original work is properly cited.

## 1. INTRODUCTION

Peyronie's disease (PD) was named after the French physician Francois de la Peyronie in 1741. His original description was one of the fibrous cavernositis "preventing them from having normal ejaculation of semen" [1]. The disease is currently thought to affect between 3 and 9% of adult men, typically in the fifth to sixth decades of life. Overall, its prevalence appears to be rising, though this may be due to the fact that more men are seeking treatment for erectile dysfunction [2].

## 2. PATHOPHYSIOLOGY

Despite a volume of basic science and clinical research, much remains unknown about the etiology and ideal management of the disease. PD is a localized connective tissue disorder of the penis leading to fibrosis, scarring, and noncompliance of the tunica albuginea. One etiologic theory is that the root cause of the fibrosis is ischemia and inflammation from repeated penile trauma or microtrauma from activities such as sexual intercourse. The resulting microvascular tears in this region lead to collagen deposition in the form of plaques [3].

Some studies have suggested a link between PD and methotrexate, while others have shown a genetic predisposition to the disease due to an association with Dupuytren's

contracture and with HLA-B7 and HLA-B27 antigens. Still other authors have identified circulating antibodies that may point to a possible immunologic cause of PD [4–7].

## 3. CLINICAL PRESENTATION

Patients typically present with three, occasionally simultaneous, chief complaints: a palpable plaque, a painful erection, and/or penile curvature. Penile curvature can in fact be so severe in that it interferes with the ability to engage in sexual intercourse (Figure 1). The disease undergoes a transition between two phases: an acute inflammatory phase and a chronic phase. Painful erections, developing penile curvature and nodule formation mark the acute inflammatory phase. This phase is self-limiting, typically lasting between six and eighteen months. Because the disease is evolving during this phase, the patient's pain, the degree of curvature, and the size of the plaque may also undergo change. The chronic phase is characterized by minimal or no pain with stable nodule size and degree of penile deformity [8].

## 4. TREATMENT

A variety of medical (i.e., nonsurgical) treatments with isolated reports of treatment "successes" have been published, but none have been substantiated in a randomized controlled



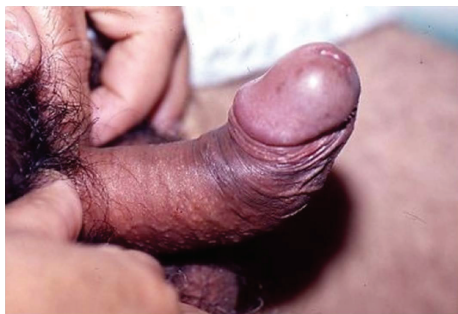

FIGURE 1: Penile deformity secondary to Peyronie's disease.

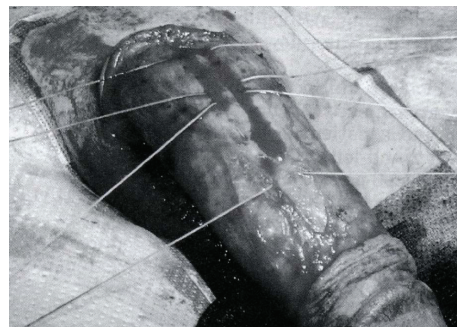

FIGURE 2: Correction of Peyronie's with corporeal plication.

fashion [9]. A thorough review of these therapies is beyond the scope of this article.

Surgical techniques for correcting the penile deformity from PD all share the same goals: correcting the curvature, preserving erectile function and penile length, and minimizing morbidity. For men with good erectile function, two main surgical concepts have been popularized: (1) lengthening the concave contracted side using a graft (with or without plaque incision/excision), and (2) shortening the convex, noncontracted side using tunical excision or plication. For men with poor erectile function and curvature, placement of a penile prosthesis to correct the erectile function can be sufficient if the degree of curvature is mild. If the curvature is more severe, a combination of one of the two approaches above with prosthesis placement is the preferred method of surgical repair.

#### 4.1. The Nesbit procedure

The original tunical shortening procedure—the Nesbit procedure (named after the surgeon who first described it)—was initially applied to those with congenital penile curvature and later used for PD [10]. The method involved excising an ellipse of tunica on the side opposite the curvature, thereby straightening the penis. Though Nesbit's concepts have helped to guide the other surgical techniques, the Nesbit procedure itself is fraught with complications including penile shortening, recurrence of curvature, cavernous tissue herniation, and erectile dysfunction [11]. The Nesbit procedure is increasingly being replaced by one of the two surgical techniques described below.

#### 4.2. Penile plication

Initially introduced by Essed and Schroeder as a less-invasive surgical option for PD, penile plication involves shortening the convex side of the curvature without excising the tunica (Figure 2) [12]. Lue expanded on this procedure by describing his “16 dot” technique that is rapid, involves no dissection of the neurovascular bundles or the urethra, spares the patient from tunical incision or excision, and reliably results in a straight penis in the appropriately selected patient. The procedure may be done with less potential morbidity to the patient under local anesthesia [13]. The

relatively straightforward nature of the procedure, however, is balanced by its limited applicability to PD patients. Patients with bottleneck deformities, hourglass deformities, or lateral indentations are not appropriately treated with plication; in fact, the procedure is almost exclusively applicable to patients with simple curvature. It is the authors' experience, however, that the majority of patients with PD fit into this category.

Penile plication is associated with a number of well-described potential drawbacks that should be discussed in full detail with the patient. First, penile shortening has been reported from 41 to 90% of the time and is indeed the major drawback for most PD patients. PD patients with severe contraction may thus not be ideal candidates for plication; however, these patients often have an element of erectile dysfunction and may be better suited for receiving a penile implant. Second, sexual or erectile dysfunction associated with plication has been reported anywhere from 7 to 40% of the time in various studies. Other potential drawbacks described in previous studies include loss of penile sensation in 3–48% of patients and permanent palpable knots reported as “bothersome” in 12–18% of patients [13–16].

A study from 2007 reported patient-perceived outcomes from the plication procedure in 57 patients who had undergone the penile plication procedure for PD over a 10 year period [17]. With a median follow-up of 51 months, 90% reported a satisfactory cosmetic result, though only 71% reported a satisfactory functional result defined as a “straight or almost straight penis on erection with pain-free penetration and normal sexual intercourse.” Interestingly, the subset analysis of long-term patients pointed to excellent subjective durability of the plication procedure. 82% of these patients reported satisfactory cosmesis and 71% reported functional satisfaction. No objective data is presented, but, in our opinion, patient-perceived outcomes on the success, especially functionally, of the procedure should be of paramount importance when describing the outcomes of the procedure.

#### 4.3. Plaque incision/excision with grafting

Conceptually, plaque incision or excision with venous grafting approaches the contralateral aspect of the curvature—the concave side—with the aim to lengthen the curvature on that contracted side (Figure 3). Both incision and excision

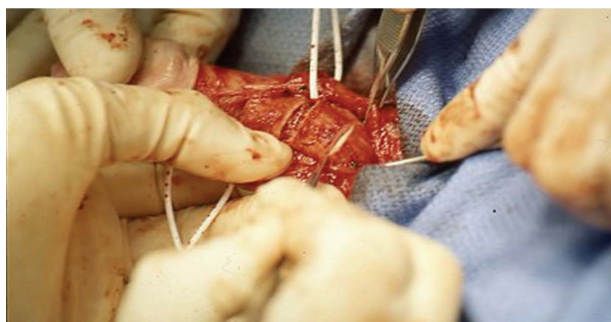


FIGURE 3: With the neurovascular bundles retracted laterally by the vessel loops, an H-incision is made at the point of maximal curvature.

of the plaque with grafting have been described with similar results, but no studies have compared results from the two procedures. Additionally, the use of both autologous and synthetic grafts have been described, with the synthetic grafts reported as being less elastic with a potential predisposition toward wound infection [18]. Similar to the intracorporeal space, venous grafts are lined by vascular endothelium and are, therefore, theoretically more physiologic than other autologous tissues. Additionally, venous grafts provide excellent elasticity and durability. We prefer to use saphenous vein grafting because it is easy to harvest, reliably provides sufficient length and width, and is associated with little morbidity during harvest [19].

Side effects and complications of vein grafting procedures have also been well described. Initial results from the procedure have always been promising, with excellent patient satisfaction (86–92%) and high rates of penile straightening (59–96%) in the first 12 months. A recent study involving 70 patients treated with plaque incision with venous grafting with a mean follow-up of 41.7 months reported 53/70 patients (75.7%) with “completely straightened” penile curvature. Of the remaining patients, 12.8% had residual curvature less than 20 degrees and the remaining 11.4% had curvature more than 20 degrees [20]. Interestingly, the lack of durability of the results has led to a more cautious consideration of the applicability of tunical lengthening procedures in the urological community. Two studies presenting five-year follow-up data reported a lack of durability of the initial promising results with vein grafting. The first study identified a significant decrease in patient satisfaction due to either erectile dysfunction (22.5%) or penile shortening (35%) while the second study reported overall satisfaction falling from 86% initially to 60% at five years [21, 22]. One of the reasons cited in the latter study for a decrease in satisfaction was a subjective loss of penile length occurring in *all* of the patients at five years. Theoretically, tunical lengthening procedures should actually prevent or improve the penile shortening often associated with PD, but many men nonetheless complained of a reduction in penile length. Objective data from the same institution with 32 months of follow-up reported no change in mean pre-versus postoperative penile length, despite a patient-reported shortening in 40% of this group [23].

Clearly, the objective and patient reported assessment of penile length is incongruous, which should be considered when counseling patients on the “tunical lengthening” procedures. Additionally, the reported long-term results of the procedure have led to some skepticism in the urologic community about the durability of the procedure, which should be conveyed to the patient when describing the long-term outcomes.

#### 4.4. Penile plication versus plaque incision with vein grafting

A recent study from our institution compared subjective patient reported experiences of tunical plication procedures ( $n = 35$ ) with plaque incision and saphenous vein grafting procedures ( $n = 32$ ) at one year of follow-up [24]. The short interval of follow-up is not ideal, especially with the questionable durability as described above, but nonetheless the results of our study are compelling. There were no statistically significant differences between the two groups with respect to straightening, overall patient satisfaction, erectile pain, and penile shortening. Patients who underwent plication were more likely to experience palpable sutures postoperatively but only 14% of patients reported this to be of a significant concern. Patients who underwent plaque incision with vein grafting were more likely to experience a loss in sensation as well as a loss in erectile rigidity. They were also more likely to be unable to have intercourse. Not surprisingly, the principle reason for the inability to have intercourse postoperatively was due to the loss in erectile rigidity. Loss in sensation was a significant patient concern in about one third of patients when it did occur. Length of operative times for the two groups varied drastically with an average time of 71 minutes for the plication group versus an average time of 234 minutes for the plaque incision and vein grafting group ( $P < .0001$ ).

Based on the results of our study and the literature, at our institution we currently offer both procedures to patients with simple curvature secondary to PD. The literature has not clearly shown an advantage of one technique over the other in terms of long-term functional or cosmetic results. Indeed, recent literature has even pointed to a relative lack of functional durability of the vein grafting technique relative to plication, though this has never been demonstrated in a clinical trial or with objective data. All of this, as well as a description of the surgical technique, is described in detail when counseling patients pre-operatively.

In patients with more complex anatomic abnormalities due to PD (hourglass deformities, bottleneck deformities, or lateral indentations), we do not offer plication. These patients can clearly not be adequately treated with plication and require more extensive reconstructive and grafting technique.

## 5. CONCLUSION

The understanding and management of Peyronie’s disease has been challenging but is improving. In reviewing the evolution of the surgical treatments, various refinements

have evolved. This evolution has not led to one ideal surgical procedure which corrects all cases of PD, but rather there now exist a repertoire of surgical techniques that can be offered by urologists and selectively utilized for each individual's deformity. The surgical management of PD should always involve patient counseling of the different operative approaches and additionally should emphasize how these approaches will best meet patients' expectations. Being informed of the advantages and disadvantages of each surgical technique, patients are better able to make an informed decision.

## REFERENCES

- [1] F. G. de la Peyronie, "Sur quelques obstacles qui s'opposent à l'éjaculation naturelle de la semence," *Memoires de l'Academie Royale des Sciences Montpellier Chir*, vol. 1, pp. 425–439, 1743.
- [2] J. M. Greenfield and L. A. Levine, "Peyronie's disease: etiology, epidemiology and medical treatment," *Urologic Clinics of North America*, vol. 32, no. 4, pp. 469–478, 2005.
- [3] C. J. Devine Jr., K. D. Somers, G. H. Jordan, and S. M. Schlossberg, "Proposal: trauma as the cause of the Peyronie's lesion," *The Journal of Urology*, vol. 157, no. 1, pp. 285–290, 1997.
- [4] M. J. I. Phelan, P. L. Riley, and M. P. Lynch, "Methotrexate associated Peyronie's disease in the treatment of rheumatoid arthritis," *British Journal of Rheumatology*, vol. 31, no. 6, pp. 425–426, 1992.
- [5] K. D. Somers, B. A. Winters, D. M. Dawson, et al., "Chromosome abnormalities in Peyronie's disease," *The Journal of Urology*, vol. 137, no. 4, pp. 672–675, 1987.
- [6] D. A. Nachtsheim and A. Rearden, "Peyronie's disease is associated with an HLA class II antigen, HLA-DQ5, implying an autoimmune etiology," *The Journal of Urology*, vol. 156, no. 4, pp. 1330–1334, 1996.
- [7] D. J. Ralph, R. Mirakian, J. P. Pryor, and G. F. Bottazzo, "The immunological features of Peyronie's disease," *The Journal of Urology*, vol. 155, no. 1, pp. 159–162, 1996.
- [8] M. K. Gelbard, F. Dorey, and K. James, "The natural history of Peyronie's disease," *The Journal of Urology*, vol. 144, no. 6, pp. 1376–1379, 1990.
- [9] F. L. Taylor and L. A. Levine, "Non-surgical therapy of Peyronie's disease," *Asian Journal of Andrology*, vol. 10, no. 1, pp. 79–87, 2008.
- [10] R. M. Nesbit, "Congenital curvature of the phallus: report of three cases with description of corrective operation," *The Journal of Urology*, vol. 93, pp. 230–232, 1965.
- [11] H. O. Andrews, M. Al-Akraa, J. P. Pryor, and D. J. Ralph, "The Nesbit operation for Peyronie's disease: an analysis of the failures," *BJU International*, vol. 87, no. 7, pp. 658–660, 2001.
- [12] E. Essed and F. H. Schroeder, "New surgical treatment for Peyronie's disease," *Urology*, vol. 25, no. 6, pp. 582–587, 1985.
- [13] S. S. Gholami and T. F. Lue, "Correction of penile curvature using the 16-dot plication technique: a review of 132 patients," *The Journal of Urology*, vol. 167, no. 5, pp. 2066–2069, 2002.
- [14] R. Chahal, N. K. Gogoi, S. K. Sundaram, and P. M. T. Weston, "Corporal plication for penile curvature caused by Peyronie's disease: the patients' perspective," *BJU International*, vol. 87, no. 4, pp. 352–356, 2001.
- [15] U. A. Geertsens, K. E. Brok, B. Andersen, and H. V. Nielsen, "Peyronie curvature treated by plication of the penile fasciae," *British Journal of Urology*, vol. 77, no. 5, pp. 733–735, 1996.
- [16] N. Thiounn, A. Missirliu, M. Zerbib, et al., "Corporeal plication for surgical correction of penile curvature. Experience with 60 patients," *European Urology*, vol. 33, no. 4, pp. 401–404, 1998.
- [17] T. Fazili, C. Kouriefs, F. Anjum, S. Masood, and G. R. Mufti, "Ten years outcome analysis of corporeal plication for Peyronie's disease," *International Urology and Nephrology*, vol. 39, no. 1, pp. 111–114, 2007.
- [18] C. K. Tornehl and C. C. Carson, "Surgical alternatives for treating Peyronie's disease," *BJU International*, vol. 94, no. 6, pp. 774–783, 2004.
- [19] T. F. Lue and A. I. El-Sakka, "Venous patch graft for Peyronie's disease—part I: technique," *The Journal of Urology*, vol. 160, no. 6, part 1, pp. 2047–2049, 1998.
- [20] A. Kadioglu, O. Sanli, T. Akman, M. Cakan, B. Erol, and F. Mamadov, "Surgical treatment of Peyronie's disease: a single center experience with 145 patients," *European Urology*, vol. 53, no. 2, pp. 432–440, 2008.
- [21] J. Kalsi, S. Minhas, N. Christopher, and D. Ralph, "The results of plaque incision and venous grafting (Lue procedure) to correct the penile deformity of Peyronie's disease," *BJU International*, vol. 95, no. 7, pp. 1029–1033, 2005.
- [22] F. Montorsi, A. Salonia, A. Briganti, et al., "Five year follow up of plaque incision and vein grafting for Peyronie's disease," in *Proceedings of the Annual Meeting of the American Urologic Association*, San Francisco, Calif, USA, May 2004.
- [23] F. Montorsi, A. Salonia, T. Maga, et al., "Evidence based assessment of long-term results of plaque incision and vein grafting for Peyronie's disease," *The Journal of Urology*, vol. 163, no. 6, pp. 1704–1708, 2000.
- [24] D. H. Kim, T. F. Lesser, and S. R. Aboseif, "Subjective patient-reported experiences after surgery for Peyronie's disease: corporeal plication versus plaque incision with vein graft," *Urology*, vol. 71, no. 4, pp. 698–702, 2008.

## Clinical Study

# Peyronie's Reconstruction for Maximum Length and Girth Gain: Geometrical Principles

Paulo H. Egydio<sup>1</sup> and Salvatore Sansalone<sup>2</sup>

<sup>1</sup> Urology Institute, Rua Iguatemi 192 Cj. 42, São Paulo 01451-010, Brazil

<sup>2</sup> Policlinico di Tor Vergata, Università di Roma, Viale Oxford, 81, 00133 Roma, Italy

Correspondence should be addressed to Paulo H. Egydio, phegydio@peyronie.com.br

Received 2 May 2008; Accepted 30 August 2008

Recommended by Miroslav L. Djordjevic

Peyronie's disease has been associated with penile shortening and some degree of erectile dysfunction. Surgical reconstruction should be based on giving a functional penis, that is, rectifying the penis with rigidity enough to make the sexual intercourse. The procedure should be discussed preoperatively in terms of length and girth reconstruction in order to improve patient satisfaction. The tunical reconstruction for maximum penile length and girth restoration should be based on the maximum length of the dissected neurovascular bundle possible and the application of geometrical principles to define the precise site and size of tunical incision and grafting procedure. As penile rectification and rigidity are required to achieve complete functional restoration of the penis and 20 to 54% of patients experience associated erectile dysfunction, penile straightening alone may not be enough to provide complete functional restoration. Therefore, phosphodiesterase inhibitors, self-injection, or penile prosthesis may need to be added in some cases.

Copyright © 2008 P. H. Egydio and S. Sansalone. This is an open access article distributed under the Creative Commons Attribution License, which permits unrestricted use, distribution, and reproduction in any medium, provided the original work is properly cited.

## 1. INTRODUCTION

Peyronie's disease (PD) is characterized by scar tissue development in the tunica albuginea, which makes it less elastic, causing penile deformity, and is invariably associated with a decrease in penile functional length. The condition has an impact on quality of life, and a significant psychological effect on 77% of patients [1].

Surgical decision is made after clinical treatment failure, when penile deformity (curvature, narrowing, or indentation) and plaques are completely stabilized, and pain has been absent for at least 6 months, provided that the patient experiences functional penile inadequacy.

Association between PD and erectile dysfunction (ED) is seen in 20% to 54% of cases [2]. Careful assessment of this associated condition is a key to correctly determine the need for surgery and to ensure the success rate of reconstruction procedures.

Penile deformity is consistently associated with functional length reduction, since the penis curves because one of its sides has lost more elasticity than the other.

A curved penis has a short and a long side. If an attempt is made to straighten it by shortening the longer side, this may not be satisfactory for the patient, because a decrease in final penile length may result. This decrease is proportional to the degree of penile curvature. It is possible during pharmacologically induced erection to estimate the penile size if the long side is going to be reduced and it is recommended to ask the patient whether that length will be enough to make him satisfied.

Therefore, for selected cases, surgical treatment should focus on functional penile-length restoration. Lengthening the shorter side is the alternative that provides maximum gain in penile length.

Surgical treatment is aimed at providing good penile function (i.e., rectification as well as adequate length and enough rigidity to enable healthy sexual activity). The geometrical technique is the most precise procedure to lengthen the short side, thereby recovering the length lost by scarring. Penile straightening is indicated for patients with normal spontaneous erection or erectile dysfunction that responds to medication, whereas those with untreatable



erectile dysfunction requiring penile prosthesis [3, 4] can have it implanted during the reconstructive procedure.

The size of the prosthesis is compatible with the longer side, as the shorter side is the one to be lengthened. Maximum length restoration was possible and limited by the length of the dissected neurovascular bundle [5].

## 2. MATERIALS AND METHODS

### 2.1. Preoperative Evaluation

#### 2.1.1. Sexual and Medical History

Preoperative evaluation should include complete clinical history as well as assessment of comorbidities, such as diabetes, heart/vascular/coronary conditions, arterial hypertension, smoking, alcohol consumption, signs and symptoms of hypogonadism, and regular medications, which may affect erection.

A detailed history should be obtained on associated erectile dysfunction, either prior to or concomitant with Peyronie's disease, as well as risk factors contributing to the development of the condition, such as sexual partner's lubrication status, achievement of an erection that continues until ejaculation, premature or late ejaculation, or inadequate habits that may cause injury to the tunica albuginea. A history of phosphodiesterase-5 (PDE5) inhibitor use is a key to establishing the presence of associated erectile dysfunction, as well as the response of this condition to the medication, the patient's tolerance to its side effects, and his compliance with treatment.

PD is consistently associated with shorter penile length. Some patients experience symmetric loss of elasticity, with little or no deformity. In such cases, a decrease in penile length may be the sole complaint.

#### 2.1.2. Assessment of Penile Deformity, Rigidity, Vascular Status, and Arterial Anomalies

A complete evaluation is essential in cases of sexual inadequacy with possible surgical indication. Patients with erectile dysfunction may need specific treatment, and assessment of their response to treatment before surgery is considered as a therapeutic option.

For deformity assessment, physical examination of a flaccid penis may reveal a palpable thickened tunica. Penile size may be determined by pulling the glans penis forward and upward to the position of a normal erection and asking the patient to indicate to which extent PD has shortened his penis.

Erection assessment is essential to establish surgical indication as well as the most appropriate surgical procedure. Penile tumescence, or partial rigidity, is often mistaken for erection, and the objective test of pharmacologically induced erection may change the therapeutic plan.

Rigidity assessment is performed both subjectively, as reported by the patient, and objectively, as observed by the physician after intracavernous injection (ICI) of alprostadil 10 to 20  $\mu$ g, which allows evaluation of penile deformity and objective rigidity, and, with Doppler ultrasound (DUS),

provides essential data for vascular assessment (arterial insufficiency and/or veno-occlusive dysfunction) as well as detection and localization of collaterals between dorsal and cavernous arteries.

After ICI, the patient holds his penis in an erection position, and the ultrasound scanning of thickened areas of the tunica, associated or not with calcification, is initiated. The measurement of flow indices—peak systolic velocity (PSV), end diastolic velocity (EDV), and calculated resistive index (RI)—begins at least 5 minutes thereafter, and a correlation of these indices to penile rigidity is established. One clinical study reported 44% of arterial anomalies and 10% of distal collateral arteries between dorsal and cavernous arteries [6]. In another retrospective study, vascular status was correlated to the type of penile deformity, demonstrating a relationship between type of curvature and penile hemodynamics [7].

Evaluation of patient's and partner's satisfaction and long-term results after surgical treatment for Peyronie's disease has shown that PSV values of 35 cm/s or above and RI higher than 0.9 were considered as parameters for a normal penile vascular system. EDV values above 5 cm/s were considered diagnostic for veno-occlusive dysfunction [2].

Information on penile arterial anatomy may be very useful for the surgeon to select the type of surgical technique to be used. Knowledge of the existence of a collateral branch is important to safely dissect the neurovascular bundle.

Because penile size before PD is unknown, information from the patient on the perceived extent of his penile length reduction is relevant. During erection induction for deformity assessment, the patient must be asked how satisfied he would be with the length resulting from straightening his penis by diminishing the longer side, as it is being shown to him, and which would be the extent of length loss compared to his penile size before PD. Penile length reduction by PD is very likely to have occurred when more than one site of fibrosis is seen, or when there is fibrosis on opposite sides. However, even if a thickened tunica cannot be palpated, longer-side reduction is not ruled out, since microstructural changes are enough to decrease the elasticity of the tunica [8]. There are patients with penile curvature and no palpable thickened tunica who undergo surgery. Penile deformity, not the plaque, is the main complaint of a PD patient. Surgery should focus on deformity correction rather than on plaques.

During or shortly after DUS, penile rigidity is objectively compared to self-reported rigidity. This allows more objective assessment of rigidity. If it is lower with the test, both crura penis are pressed to maximum rigidity to assess penile deformity, which will be apparent with maximum rigidity, while the other hand assesses axial rigidity by pressing on the glans to mimic a penetration attempt. If deformity is not pronounced and with good rigidity allows good axial stability, providing penile functionality, surgical treatment may not be indicated. A good erectile response to oral or injected medications may restore penetration ability in such cases.

Soon after this assessment, the patient is asked to palpate his penis and, by progressively relieving pressure on crura, to report the extent of rigidity, he observes in an ideal setting of

sexual stimulation. The physician is thereby provided with an objective evaluation, and, if a rigidity deficit is proven, the patient's ED can be treated. The physician will establish what a good rigidity is, and whether this desired goal can be achieved by the patient.

### 2.1.3. Tunical-Lengthening Procedures Based on Geometrical Principles [9–13]

#### Surgical Technique

- (1) The penis is degloved after a circumcision incision. Magnifying lenses 2.5 are used for better visualization. One of the cavernous bodies is punctured by a 21 scalpel, considering that, when necessary, both cavernous bodies can be punctured to achieve full erection by saline solution injection. The use of papaverin or prostaglandin can help full erection with saline solution injection.
- (2) In cases of dorsal curvature, two tangential lines to the penile axis (red lines) are drawn on the proximal and distal straight segments ( $a-a'$  and  $b-b'$ , resp.) toward the area of curvature of the erect penis (Figure 1).
- (3) From the point of maximum curvature ( $P$ ) located at the intersection of the lines  $a-a'$  and  $b-b'$ , a circumferential line (green line) is drawn at the bisector of the angle formed by these lines (Figure 1).
- (4) The point at which this circumferential line crosses the neurovascular bundle in the dorsal region and the urethra in the ventral region determines the region at which these structures must be separated from the tunica albuginea.
- (5) The transverse incision in the tunica will be made along this circumferential line (green line) later. Then the erection is reversed.
- (6) Two paraurethral incisions ( $c-c'$ ) are made where the circumferential line crosses the urethra to dissect Buck's fascia and its neurovascular bundle from the tunica around the complete circumference of the penis in all types of curvature, except at the level of the urethra (Figures 2(a), 2(b)).
- (7) A new erection is induced and a circumferential line is drawn again, but this time on the tunica, where the circular incision will be made (Figure 2(c)).
- (8) Complete penile straightening is achieved by a 5-mm incision in the intercavernous septum on each side of its intersection with the transverse incision in the circumferential line (Figure 3).
- (9) The width ( $W$ ) of the defect should be the same as the difference between the long and the short sides of the penis. This measurement is calculated by the distance between any two complete circumferential lines perpendicular to the penile axis drawn on the straight penile segments, that is, outside the area of curvature (before  $d-d'$  and after  $e-e'$ ) (Figure 1).

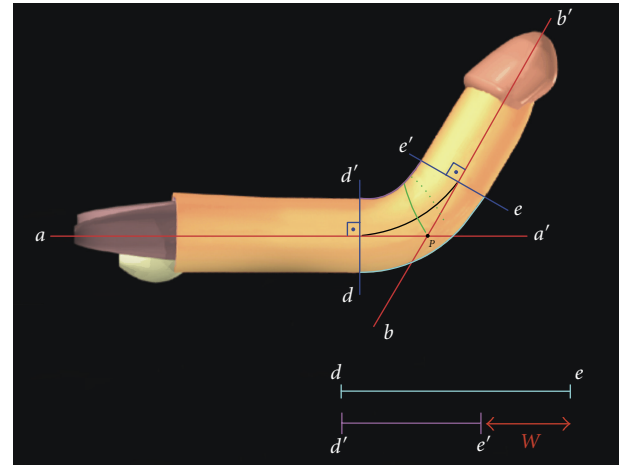


FIGURE 1: The intersection of the tangential lines to the penile axis  $a-a'$  and  $b-b'$  (red lines) determines the point of maximum curvature ( $P$ ). A circumferential line is drawn (green line) from point  $P$  in the bisector of the angle formed by the lines  $a-a'$  and  $b-b'$ .  $W$  (red arrow) is equal to the distance of the two points of the long side ( $d-e$ ) minus the equivalent distance ( $d'-e'$ ) in the short side of the penis ( $\theta = 90^\circ$ ).

- (10) The difference ( $W$ ) between  $d-e$  and  $d'-e'$  (red arrow, Figure 1) will be the size of the defect on each side of the urethra in cases of dorsal curvature (Figures 4(a), 4(c)).
- (11) On the circumferential line, a length of  $W/4$  away from the site where it meets the  $g$  line, points  $F$  and  $F'$  (Figures 4(a) and 5) are determined to mark the start of bifurcation, which extends to either side of the  $g$  line at a length of  $W/2$ , thus generating a  $120^\circ$  angle (Figure 5); the resulting defect will be more simple and stable as a tripod.
- (12) Defect length ( $L$ ) will be equivalent to the distance between the two paraurethral incisions for dorsal curvature, or between the two ends of the fork-shaped incision for any type of curvature passing round the short side of the erect penis (Figures 4(a), 6(a), 7(a)).
- (13) Once the circumferential line forked at the ends is determined, the incision is made in the tunica albuginea, producing a rectangular defect of an already known size.
- (14) To facilitate graft suturing, a 5-mm dissection is made between the 4 edges of the defect and the respective adjacent cavernous bodies. The graft is sutured and a new induced erection demonstrates complete penile straightening (Figure 4(c)).
- (15) In cases of ventral curvature, the technique is similar but with the following differences: the forking of the transverse incision is made in the dorsal region near the intercavernous septum which has its dorsal insertion maintained (Figure 6).

- (16) The urethra is dissected from its bed and the graft is placed between the urethra and the cavernous body (Figures 6(c) and 6(d)). A new induced erection demonstrates complete penile straightening (Figures 6(b) and 6(d)).
- (17) Dorsolateral curvatures with a larger dorsal component and ventrolateral curvatures with a larger ventral component are corrected by the same technique as for dorsal or ventral curvatures, respectively.
- (18) In cases of lateral curvature (Figure 7(a)), the defect turns out to have the shape of a trapezium instead of a rectangle as obtained in cases of dorsal and ventral curvature. The shorter side of the trapezium can vary from 0.5 to 1 cm ( $W'$ ). The longer side ( $W + W'$ ) is equal to the difference between the long and the short sides ( $W$ ) of the penis (obtained as the other curvatures), added to the length of the smaller side of the trapezium ( $W'$ ). The height of the trapezium ( $L$ ) is measured as described for the other types of curvature (Figure 7(a)). Thus this procedure avoids a defect of triangular shape which would make the graft procedure more difficult (Figures 7(c) and 7(d)).
- (19) The graft is cut according to the measurements already made (i.e., width  $W$  and length  $L$ ) but should be 1-2 mm wider and longer than the defect to provide room for the suture. However, the graft should only be this size when the material used is not likely to shrink; otherwise, a percentage for graft shrinkage should be allowed.
- (20) The length ( $L$ ) of the defect should be measured with the penis erect and outside any constricted area to allow girth correction in constricted penile shaft area.
- (21) Buck's fascia can be sutured on place. Penile degloving is reversed and foreskin, when present, is removed to avoid postoperative swelling and/or necrosis. Circumcision incision is closed with 5.0 poligle-caprone. A light compressive dressing is applied for 7 to 10 days. Although the patient can have spontaneous erection, a 6-week period of sexual abstinence is recommended. After a 6-month follow-up, alprostadil-induced erections are used to check penile straightening in those cases a penile prosthesis has not been implanted.

## 2.2. Grafting

An ideal graft should be ready to use; available in various sizes; have good tensile strength and low potential for inflammatory reactions; infection-resistant, with minimal or no risk for disease transmission; and be cost-effective.

Several types of grafts have been used, including biologic autografts—dermis, veins, penile crura, dura mater, tunica vaginalis, fascia lata—and allografts/xenografts—cadaveric pericardium, porcine small-intestine submucosa, acellular dermis, or synthetic grafts: polytetrafluoroethylene, Dacron, or sylvastic [14]. The disadvantage of using autologous

grafting includes lengthening of operative time, morbidity, and scarring on the harvest site. The amount of tissue may be another limiting factor.

Hellstrom and Reddy [15] reported on using human cadaveric pericardium, as Chun et al. [16] as well as Levine and Estrada [17] did. Leungwattanakij et al. [18] compared several types of grafts in a rat model showing a low rate of inflammatory reactions with cadaveric pericardium.

Knoll [19] reported the use of porcine small-intestine submucosa (SIS) grafts for tunical substitute, with promising results. Larger-sized and more uniform patches are advantages of SIS grafts, but absorption on larger defects must be slower, requiring the use of SIS with multilayer sheet.

With the increasing use of tissue engineering, new tunica albuginea substitutes may be developed [20, 21]. Advances in this area are prominent, and grafts will be available in the future that are much more similar to the tunica albuginea, or acellular matrix that may allow the tunica to be rebuilt, whether associated with cell culture and seeding or not.

A discussion concerning the best graft often involves postoperative outcomes, although the type of relaxing incision or excision has varied. Postoperative outcomes are not solely dependent on the graft used.

A personal experience with bovine pericardium associated with plaque excision gave discouraging results. In contrast, results were promising when using the same type of graft associated with a relaxing incision procedure [9].

In another personal experience, in four cases, it was necessary to remove the pericardium graft 2.5 to 8 months after surgery (in three cases due to infection in immunocompromised patients and in one case due to absorption of graft-graft suture with dehiscence and local hematoma formation); no leakage was seen after saline-induced erection, and the operative sites were left without grafts. After the recovery period, patients still have good-quality erections and axial rigidity, and are capable of having sexual intercourse. This has shown that grafts may even be absorbable, that is, the tunica may be allowed to rebuild on the structure of the graft, provided that this allows no new blood-vessel formation, which may lead to veno-occlusive dysfunction.

It is expected that all patients have a hematoma under the graft following a grafting procedure. A personal series of 20 patients were followed for 8 months, after which the hematoma disappeared in 50% and remained as a laminar hematoma in 50%, not causing any disturbance of penile functionality based on rigidity. It is a matter of concern to maintain a large hematoma that limits the expansion of sponge cavernous tissue based on the concealed fibrotic area in the outer part of the sponge tissue. The graft is important during this period to block leakage from the sponge tissue and to maintain good penile shape.

Of the four patients who had their grafts removed and had no leakage, two maintain a permanent constriction area at the site of the removed graft, which was filled by the hematoma underlying the graft.

With the purpose of trying to maintain a minimal hematoma under the graft until blockage occurs in the outer part of the sponge cavernous tissue, a light compressive postoperative dressing is applied to be kept in place for 7



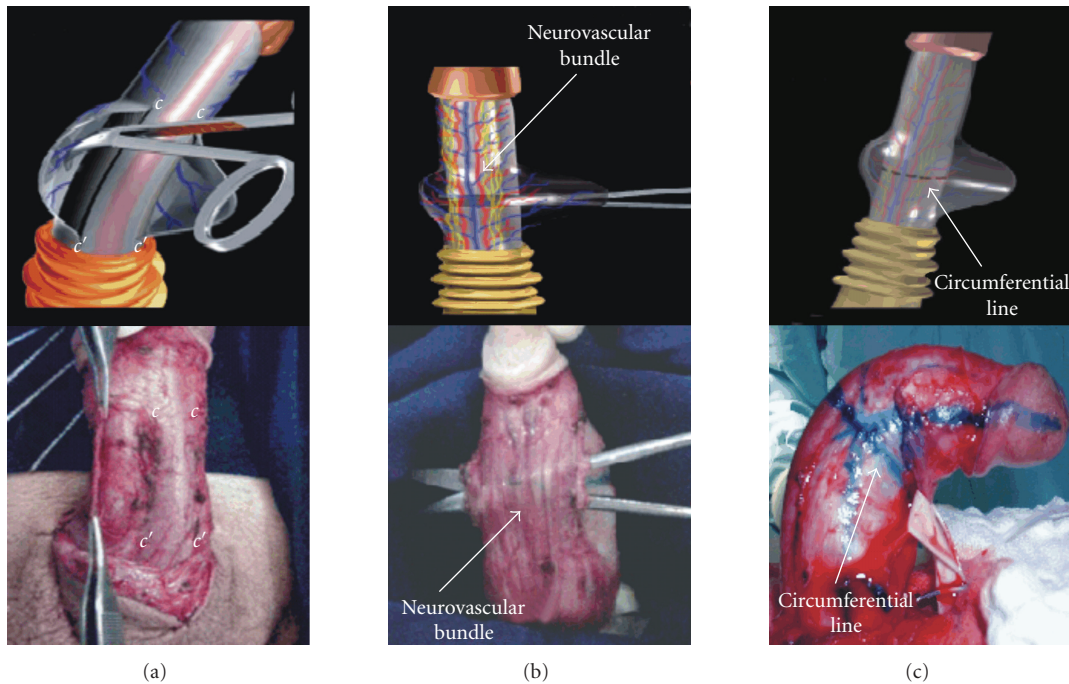


FIGURE 2: (a) Paraurethral incisions (c-c') in Buck's fascia. (b) Dissection of Buck's fascia and the neurovascular bundle from the tunica albuginea. (c) Drawing of the circumferential line in the point of maximum curvature.

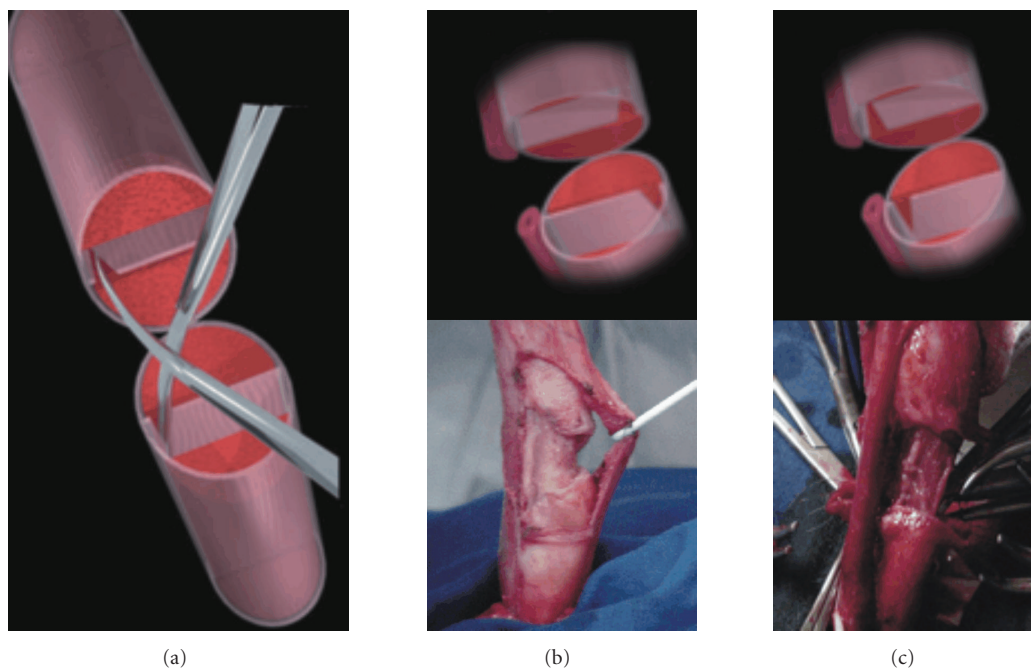


FIGURE 3: (a) Cutting of the intercavernous septum. (b) Septal cutting in cases of dorsal, dorsolateral, or lateral curvature. (c) Septal cutting in cases of ventral or ventrolateral curvature.

to 10 days, and the patient is started on a PDE5 inhibitor at bedtime on the 7th to 10th postoperative day, to stimulate smooth muscle relaxation, thereby expanding the cavernous tissue and compressing the hematoma as a means to help it

be absorbed or transformed into a laminar shape that does not affect axial rigidity. These medications are particularly important for patients with preoperative ED, and of utmost interest to reduce the hematoma and maintain physical



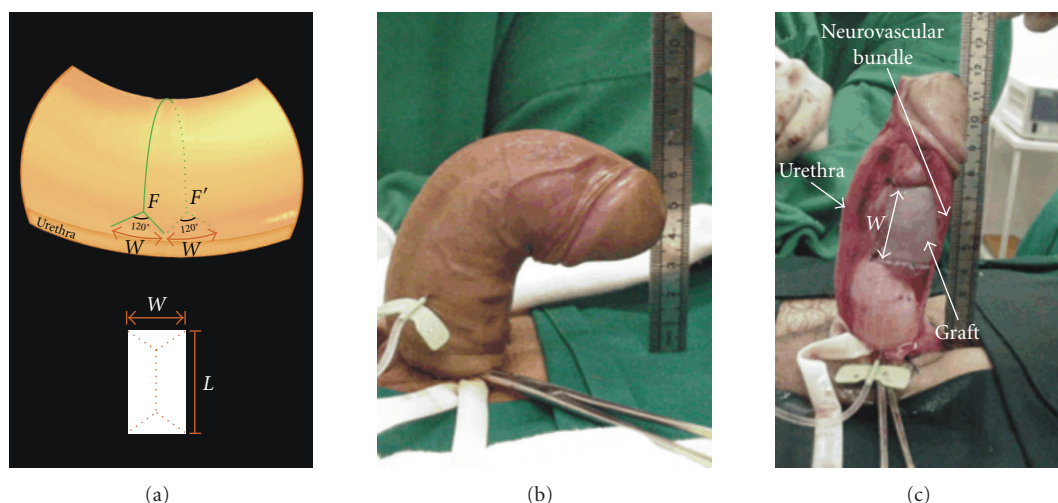


FIGURE 4: (a) Bifurcation of the transverse incision and the correspondent defects in the tunica albuginea in cases of dorsal curvatures.  $W$  = the width of the defect.  $L$  = the length of the defect.  $F$  and  $F'$  are the points from which the circular incision is forked. (b) Preoperative dorsal curvature. (c) Final result after straightening and graft suturing.

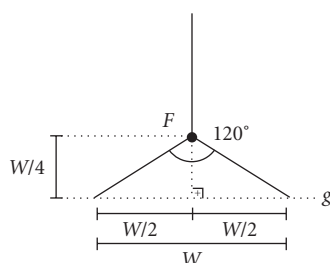


FIGURE 5: The starting point of the 120-degree bifurcation at the end of circumferential lines is established by marking a length of  $W/4$  back from the intersection with the  $g$  line.  $W$  is the differences measured between the longer and shorter side of the penis that correspond to the width ( $W$ ) of the tunica defect.

therapy with stimulated or reflex nocturnal erections. Early postoperative use of a vacuum device can only increase the hematoma underlying the graft, owing to negative pressure.

### 2.3. Penile Prosthesis Implantation

Patients with PD and ED that are nonresponsive to oral or injectable treatment will be candidates for penile prosthesis implantation. Depending on the type and degree of penile deformity, associated procedures (e.g., modeling, Nesbit/plication, or incision/excision as well as grafting for penile rectification and/or correction of constrictive lesions) may be necessary [22].

Rahman et al. [23] reported penile plication surgery associated with penile prosthesis. The inconvenience of this procedure is penile-length reduction. The higher the curvature degree, the greater this reduction will be.

Usta et al. [24] reported the long-term results of surgical treatment for PD, showing that penile prosthesis implantation and curvature correction with pericardium graft

added no risks of complications as compared to prosthesis implantation surgery alone.

Our personal experience is that pericardium reconstruction has not increased the risk for infection and complications. This may be due to the fact that pericardial tissue, in contrast to vein and dermal grafts, needs no imbibition to survive. That is why we prefer reconstruction with pericardium grafting according to geometric principles and single incision [5, 9, 11], and concomitant implantation of malleable or inflatable prosthesis of a size compatible with the longer side, as the shorter side has been elongated.

Perovic and Djordjevic [25] described the penile disassembly technique for distal penile deformity, which allows excellent distal exposure for distal reconstruction.

From April 1999 through September 2007, 521 patients who underwent geometrical incision correction were followed up: 311 patients underwent surgical straightening without penile prosthesis implantation and 210 patients underwent reconstruction with concomitant penile prosthesis implantation (malleable prostheses for 141; inflatable two pieces for 48; and inflatable three pieces for 21 patients). Patient preference was the criteria for prosthesis type choice.

A bovine pericardium graft (Braile-Biomedica and HP-Biopróteses, SP, Brazil) was sutured into the defect and its size trimmed to 1 to 2 mm wider and longer than the tunical defect in order to include this extra size in the suturing procedure. The suture was continuous, with polyglactone 4.0. The greater the curvature, the greater the graft size is. Mean graft width was  $3.2 \pm 0.3$  cm (range 2.5–4.0 cm), and mean graft length was  $7.7 \pm 0.4$  cm (range 7.5–8.5 cm).

The mean increase in functional penile size (dependent on curvature severity) was  $3.2 \pm 1.7$  cm (1.5–5.5 cm).

### 3. RESULTS AND DISCUSSION

311 patients underwent straightening procedure by geometrical principles and grafting without concomitant

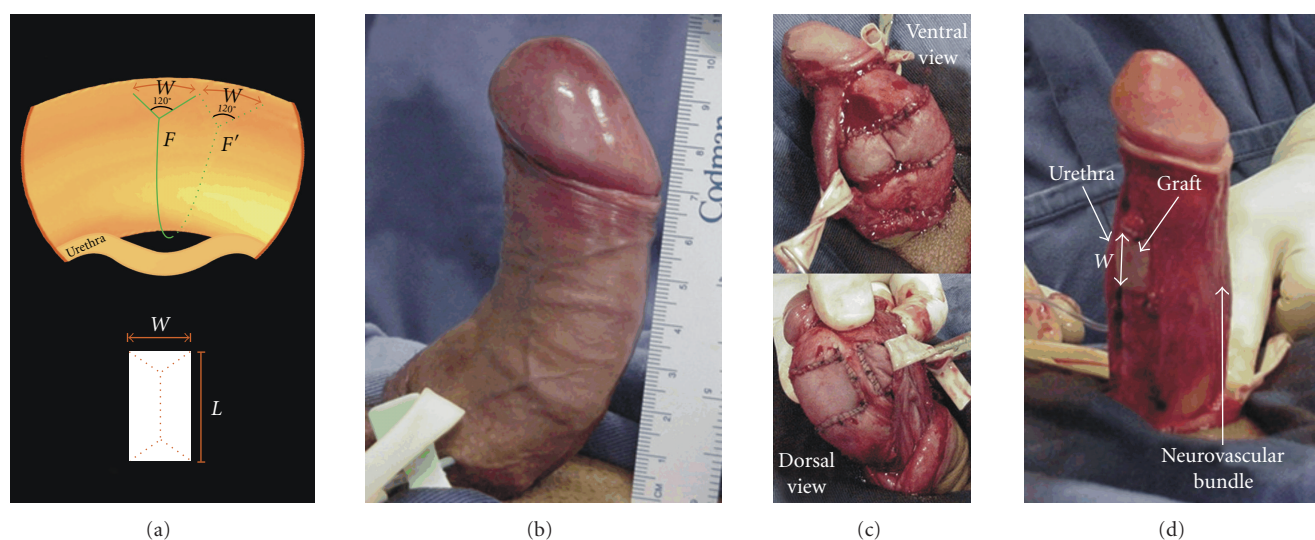


FIGURE 6: (a) Bifurcation of the transverse incision and the correspondent defects in the tunica in cases of ventral curvatures.  $W$  = the width of the defect.  $L$  = the length of the defect.  $F$  and  $F'$  are the points from which the circular incision is forked. (b) Preoperative ventral curvature. (c) Urethral dissection. (d) Final result after straightening and graft suturing.

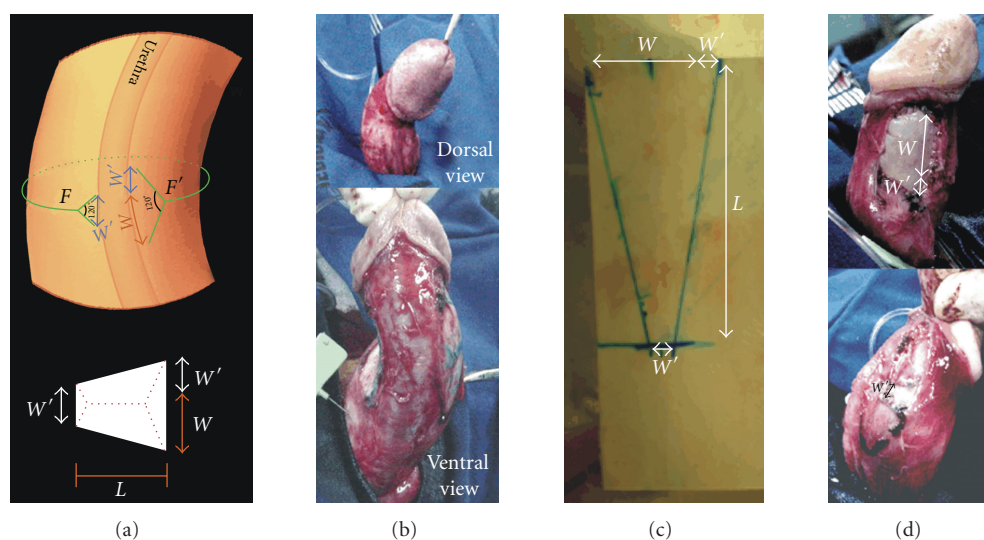


FIGURE 7: (a) Bifurcation of the transverse incision and the correspondent defects in the tunica in cases of lateral curvatures.  $W$  = the difference between the short and long side.  $W'$  = a measure added on both side  $L$  = the length of the defect.  $F$  and  $F'$  are the points from which the circular incision is forked. (b) Lateral curvature after a degloving procedure. (c) Trapezoidal graft was drawn in the pericardium. (d) Final result after straightening and graft suturing.

penile prosthesis implantation. Penile deformities were distributed as follows: dorsal 46% (143/311), dorsolateral 30% (93/311), lateral 12.5% (39/311), ventral 6% (19/311), and ventrolateral 5.5% (17/311). Mean penile curvature was  $75 \pm 15.7^\circ$  (range  $45-120^\circ$ ). The technique corrected both deformities in 15.5% (48/311) of patients with Peyronie's disease associated with penile constriction.

In four cases, it was necessary to remove the pericardium graft 2.5 to 8 months after surgery (in three cases due to infection in immunocompromised patients and in one

case due to absorption of graft-graft suture with dehiscence and local hematoma formation); no leakage was seen after saline-induced erection, and the operative sites were left without grafts. After the recovery period, patients still have good-quality erections and axial rigidity, and are capable of having sexual intercourse. Follow-up by prostaglandin-induced erection of Peyronie patients who did not receive prostheses has shown penile straightening in 87% and residual curvature of up to  $15^\circ$  in 7% and up to  $30^\circ$  in 6% which does not disturb penile functioning when a good erection

was obtained, either associated with PDE-5 inhibitors or not. A second surgery with penile prosthesis implantation was performed in 15% of cases whose follow-up showed deterioration of erectile function. The mean follow-up period was  $45.2 \pm 27.1$  months (range 6–96 months). The cases with greatest curvature showed the best intraoperative gain in penile length. The gain in functional penile size was maintained in patients who kept penile straightening and was reduced by up to 0.5 cm in those who developed curvature postoperatively. The preoperative erection status was preserved in most cases whose preoperative evaluation by Doppler ultrasound showed peak systolic velocity over 40 cm/s and end-diastolic velocity under 3 cm/s. Follow-up of cases with concomitant implantation of inflatable penile prostheses showed preserved penile straightening. Satisfactory penile sensitivity was maintained.

Even the patients who had deterioration on penile rigidity and underwent a second surgical procedure for penile prosthesis implantation recovered penetration ability and re-established satisfactory sexual intercourse. Patient satisfaction is obtained when patients recover their ability for penetration while maintaining orgasm.

### 3.1. Discussion

The technique herein presented is a standardized procedure since it is based on geometrical principles and meets, as no other technique previously presented, the needs of most patients. It can be applied irrespective of the characteristics of the plaque or type of curvature caused by Peyronie's disease, either associated with concomitant penile prostheses implantation or not.

The dissection of the neurovascular bundle has been standardized for all cases by means of the two paraurethral incisions in Buck's fascia. At this level, the circumflex veins are of lesser caliber, thus permitting their cauterization, which means a smaller number of ligatures. Furthermore, when the dissection is done ventrally, these manipulations are made far from the dorsal nerves of the penis, which means a lesser risk of damaging them. Another favorable aspect is that the dissection under the bundle may be limited to the area of the curvature, allowing the possibility of its being extended if necessary. This smaller dissection of the bundle in the dorsal region minimizes the risk of lesions to the eventual collaterals between the dorsal and cavernous arteries.

The puncture of one or more of the corpora cavernosa to induce and maintain a full erection is of great importance for the correct application of these geometrical principles which define the most appropriate site for the incision in the tunica albuginea. The lines  $d-d'$  and  $e-e'$  may be drawn at any positions in the straight portion of the penis because the difference ( $W$ ) between the two sides will always be the same. The crossing of the tangential lines  $a-a'$  and  $b-b'$  on any line parallel to the axis of the penis will always be at the bisector of the angle formed between them. The incomplete circumferential incision permits breaking all lines of force, allowing the correction of the curvature on two planes (dorsolateral or ventrolateral) by the same incision.

In lateral curvatures, a rectangular defect is created by cutting the intercavernous septum insertion in both dorsal and ventral regions. Due to the risk of erectile dysfunction that can be caused by incisions in the intercavernous septum on the dorsum and ventrum to create a rectangular tunical defect, a trapezoidal shape was chosen for the defect because, as in the other examples given, it is made by cutting the intercavernous septum at just one point (dorsal side).

The intercavernous septum may be involved in the pathogenesis of the deformity of the penis. The septal incision on both sides of the transverse incision in the shorter side of the tunica albuginea is a key to adequate lengthening of the short side and complete straightening of the penis. The traction of the penis after the incision in the tunica albuginea, the septal incision, and the dissection of the tunica albuginea from the spongy tissue of the cavernous body allowed checking whether complete straightening of the penis had been achieved. Neurovascular bundle dissection can be extended when the bundle restricts penile straightening.

A tripod-shaped bifurcation with legs 120 degrees apart from each other provides a most stable structure, allowing, according to the surgeon, better results in view of a simpler configuration of the defect in the tunica, a geometrical, more easily constructed graft shape, and a simpler suturing procedure. The bifurcations in this technique also permitted relaxation of constricted areas in the tunica and correction of associated constrictive lesions. The bifurcations in the dorsal region for ventral curvatures should not cross the intercavernous septum.

The size of the tunical defect can be calculated before tunical incision by applying the geometrical principles during a full erection, thereby allowing graft preparation even at the physician's office by induced erection.

The graft to be used may match the defect size if no graft shrinkage is likely, as is the case with pericardium grafts [9, 15]; when graft shrinkage is likely, a percentage should be added to the dimensions of the defect.

The length of the defect should be measured on an erect penis; in cases of constriction at the curvature site, it should be measured on a constriction-free site for appropriate girth restoration.

Under these circumstances, only one incision and one graft are necessary, provided that the penis shows a single point of maximum curvature (with two preferential directions only). If there are two significant curvatures at different points of the penis, two grafts may be made as described. Thus complementary plication—which not only harms the healthy side but also shortens the penis—may be avoided.

The technique herein described allows the standardization of a single tunical incision procedure that may be reproducible in multicenter studies, leading to a better understanding of the advantages and disadvantages of different types of graft material.

## 4. CONCLUSIONS

This single incision technique, applying geometrical principles, is a standardized procedure for the correction of



any penile curvature, either associated with tunical constriction or not, providing maximum penile gain and girth restoration. The present technique is effective to correct all types of penile curvature, regardless of plaque characteristics. The improvement of tissue engineering techniques will contribute to the development of grafts that are increasingly close to the ideal for tunica albuginea replacement.

## REFERENCES

- [1] M. K. Gelbard, F. Dorey, and K. James, "The natural history of Peyronie's disease," *The Journal of Urology*, vol. 144, no. 6, pp. 1376–1379, 1990.
- [2] M. F. Usta, T. J. Bivalacqua, Z. Tokatli, et al., "Stratification of penile vascular pathologies in patients with Peyronie's disease and in men with erectile dysfunction according to age: a comparative study," *The Journal of Urology*, vol. 172, no. 1, pp. 259–262, 2004.
- [3] D. K. Montague, K. W. Angermeier, M. M. Lakin, and B. J. Ingleright, "AMS 3-piece inflatable penile prosthesis implantation in men with Peyronie's disease: comparison of CX and Ultrex cylinders," *The Journal of Urology*, vol. 156, no. 5, pp. 1633–1635, 1996.
- [4] L. A. Levine and R. J. Dimitriou, "A surgical algorithm for penile prosthesis placement in men with erectile failure and Peyronie's disease," *International Journal of Impotence Research*, vol. 12, no. 3, pp. 147–151, 2000.
- [5] P. H. Egydio, "Surgical treatment of Peyronie's disease: choosing the best approach to improve patient satisfaction," *Asian Journal of Andrology*, vol. 10, no. 1, pp. 158–166, 2008.
- [6] E. M. Schaeffer, J. P. Jarow Jr., J. Vrablic, and J. P. Jarow, "Duplex ultrasonography detects clinically significant anomalies of penile arterial vasculature affecting surgical approach to penile straightening," *Urology*, vol. 67, no. 1, pp. 166–169, 2006.
- [7] M. Kendirci, S. Nowfar, S. Gur, G. W. Jabren, S. C. Sikka, and W. J. G. Hellstrom, "The relationship between the type of penile abnormality and penile vascular status in patients with Peyronie's disease," *The Journal of Urology*, vol. 174, no. 2, pp. 632–635, 2005.
- [8] K. Anafarta, Y. Bedük, Ö. Uluoglu, K. Aydos, and S. Baltaci, "The significance of histopathological changes of the normal tunica albuginea in Peyronie's disease," *International Urology and Nephrology*, vol. 26, no. 1, pp. 71–77, 1994.
- [9] P. H. Egydio, A. M. Lucon, and S. Arap, "Treatment of Peyronie's disease by incomplete circumferential incision of the tunica albuginea and plaque with bovine pericardium graft," *Urology*, vol. 59, no. 4, pp. 570–574, 2002.
- [10] P. H. Egydio, "Surgical straightening with tunica incision and grafting technique-single relaxing incision based on geometrical principles," in *Peyronie's Disease: A Guide to Clinical Management*, L. A. Levine, Ed., pp. 227–239, Hyman Press, Totowa, NJ, USA, 2006.
- [11] P. H. Egydio, A. M. Lucon, and S. Arap, "A single relaxing incision to correct different types of penile curvature: surgical technique based on geometrical principles," *BJU International*, vol. 94, no. 7, pp. 1147–1157, 2004.
- [12] A. Seftel, "Treatment of Peyronie's disease by incomplete circumferential incision of the tunica albuginea and plaque with bovine pericardium graft," *The Journal of Urology*, vol. 168, no. 2, p. 869, 2002.
- [13] P. H. Egydio, A. M. Lucon, and S. Arap, "A single relaxing incision to correct different types of penile deformity in Peyronie's disease: geometrical principles," *The Journal of Urology*, vol. 169, no. 4, supplement, p. 275, 2003.
- [14] M. Kendirci and W. J. G. Hellstrom, "Critical analysis of surgery for Peyronie's disease," *Current Opinion in Urology*, vol. 14, no. 6, pp. 381–388, 2004.
- [15] W. J. G. Hellstrom and S. Reddy, "Application of pericardial graft in the surgical management of Peyronie's disease," *The Journal of Urology*, vol. 163, no. 5, pp. 1445–1447, 2000.
- [16] J. L. Chun, A. McGregor, R. Krishnan, and C. C. Carson, "A comparison of dermal and cadaveric pericardial grafts in the modified Horton-Devine procedure for Peyronie's disease," *The Journal of Urology*, vol. 166, no. 1, pp. 185–188, 2001.
- [17] L. A. Levine and C. R. Estrada, "Human cadaveric pericardial graft for the surgical correction of Peyronie's disease," *The Journal of Urology*, vol. 170, no. 6, part 1, pp. 2359–2362, 2003.
- [18] S. Leungwattanakij, T. J. Bivalacqua, D.-Y. Yang, J.-S. Hyun, and W. J. G. Hellstrom, "Comparison of cadaveric pericardial, dermal, vein, and synthetic grafts for tunica albuginea substitution using a rat model," *BJU International*, vol. 92, no. 1, pp. 119–124, 2003.
- [19] L. D. Knoll, "Use of porcine small intestinal submucosal graft in the surgical management of Peyronie's disease," *Urology*, vol. 57, no. 4, pp. 753–757, 2001.
- [20] D. Schultheiss, R. R. Lorenz, R. Meister, et al., "Functional tissue engineering of autologous tunica albuginea: a possible graft for Peyronie's disease surgery," *European Urology*, vol. 45, no. 6, pp. 781–786, 2004.
- [21] D. Eberli, R. A. Susaeta, J. J. Yoo, and A. Atala, "Novel acellular collagen matrix for Peyronie's repair," *The Journal of Urology*, vol. 173, no. 4, supplement, p. 254, 2005.
- [22] J. J. Mulcahy and S. K. Wilson, "Management of Peyronie's disease with penile prostheses," *International Journal of Impotence Research*, vol. 14, no. 5, pp. 384–388, 2002.
- [23] N. U. Rahman, R. E. Carrion, D. Bochinski, and T. F. Lue, "Combined penile plication surgery and insertion of penile prosthesis for severe penile curvature and erectile dysfunction," *The Journal of Urology*, vol. 171, no. 6, part 1, pp. 2346–2349, 2004.
- [24] M. F. Usta, T. J. Bivalacqua, J. Sanabria, I. T. Koksai, K. Moparty, and W. J. G. Hellstrom, "Patient and partner satisfaction and long-term results after surgical treatment for Peyronie's disease," *Urology*, vol. 62, no. 1, pp. 105–109, 2003.
- [25] S. V. Perovic and M. L. J. Djordjevic, "The penile disassembly technique in the surgical treatment of Peyronie's disease," *BJU International*, vol. 88, no. 7, pp. 731–738, 2001.

## Clinical Study

# Preservation of Cavernosal Erectile Function after Soft Penile Prosthesis Implant in Peyronie's Disease: Long-Term Followup

Marco Grasso,<sup>1</sup> Caterina Lania,<sup>2</sup> Flavio Fortuna,<sup>3</sup> Salvatore Blanco,<sup>1</sup> and Igor Piacentini<sup>3</sup>

<sup>1</sup> Department of Urology, San Gerardo Hospital, 20052 Monza, Italy

<sup>2</sup> Department of Urology, San Raffaele Hospital, 20132 Milan, Italy

<sup>3</sup> Department of Urology, Desio Hospital, 20033 Desio, Italy

Correspondence should be addressed to Marco Grasso, marco.grasso@aovimercate.org

Received 30 April 2008; Accepted 16 October 2008

Recommended by Miroslav L. Djordjevic

The aim of this retrospective study is to evaluate the long-term followup of soft penile SSDA prosthesis, without plaque surgery in the treatment of Peyronie's disease. This study included 12 men with Peyronie's disease who underwent placement of a penile prosthesis. All patients were followed for at least 6 years. Prosthesis straightened the penile shaft in all cases, restoring patient sexual satisfaction. No operative or postoperative complications occurred, and no reoperations were needed. All patients have undergone further examination with basal and dynamic eco color Doppler. The findings are encouraging as the penis preserves the ability to enhance the tumescence and penile girth. We can conclude that SSDA penile prosthesis is safe and effective in Peyronie's disease.

Copyright © 2008 Marco Grasso et al. This is an open access article distributed under the Creative Commons Attribution License, which permits unrestricted use, distribution, and reproduction in any medium, provided the original work is properly cited.

## 1. INTRODUCTION

In 1743, de la Peyronie first described the characteristic penile curvature, nowadays known as Peyronie's disease or induratio penis plastica (IPP) [1]. In general, IPP refers to acquired penile deformities during erection (curvature and strictures) and/or penile shortening. This condition is usually associated with palpable hardening (plaque) on the penile shaft and eventually painful erection. Current researches suggest that IPP could be a localized connective tissue disorder affecting the tunica albuginea of the corpora cavernosa.

The aetiology of the disease remains unknown and many hypotheses have been formulated so far. Trauma is thought to be the promoter factor of IPP, causing mechanical stress and microvascular damage. As a consequence, even genetically induced, hyperactive wound healing may cause chronic inflammation and fibrosis of tunica albuginea with subsequent development of hardening and deformation of the penile shaft characteristic of the stabilized phase of disease.

Another hypothesis is related to a defect of immune response causing antibody reaction against the tunica albuginea.

IPP can occur in a familiar pattern and it has been reported in association with Dupuytren's disease as well.

Over years, various medical treatments such as radiation, laser therapy, ultrasound, shock wave lithotripsy have been reported without any of them being superior to others. However, surgery is considered the only effective treatment for stabilized disease when severe curvature or narrowing interferes with sexual intercourse [2–4].

Several surgical options have been proposed. Tunica shortening procedures are performed by reducing the length of the convex side of the penis opposite to the penile plaque (Nesbitt or Yachia procedures; plication of corpora cavernosa). Conversely, lengthening techniques are performed by plaque incision or excision while the resulting defect is then covered by a graft. As a result, the extension of the short side of the penile curvature gives the penile shaft the original length [2, 4–6]. Another possible treatment, especially with associated erectile dysfunction, is penile prosthesis placement. These surgical treatments warrant adequate correction of penile curvature and recovery of patient sexual satisfaction [7–9].

We have treated a patient series by placing a particular semirigid soft penile prosthesis (silicon soft dynamic antiextrusion (SSDA)) in which the cavernous tissue is displaced



TABLE 1

Age	No. of patients
30–40	1
40–50	3
50–60	7
60–70	1
Total	12

by prosthesis shaft as a peripheral layer of cavernous surrounding tissue.

Our hypothesis was that the residual function of this cavernous tissue could have a positive impact on penile curvature treatment and patient satisfaction. We report our retrospective study with a long-term followup.

## 2. MATERIAL AND METHODS

Between 1998 and 2001, 12 patients (36 to 67 years) (Table 1) were treated by soft penile prosthesis placement (SSDA). All patients presented erectile dysfunction associated with penile deformation. We previously excluded patients with diabetes and vasculogenic impotence. A severe penile shortening was reported in 6 patients. All patients were previously treated by various medical and physical therapies without any benefit. In all patients, the plaque was easily palpable on the penile shaft. Erectile function was tested by duplex dynamic color Doppler ultrasound, nocturnal penile tumescence, and hormone assay.

### 2.1. Description of SSDA prosthesis and surgical procedure

We reviewed our experience with implants on soft penile prosthesis called silicon soft dynamic antiextrusion (SSDA) (Figure 1). This prosthesis consists of silicone elastomer which has three zones with different features:

- (i) *the central zone* has a variable rigidity and size to satisfy different clinical necessities and to permit an easy insertion;
- (ii) *the distal zone* is made of softer silicone to reduce the risk of extrusion;
- (iii) *the proximal zone* presents a series of slightly cone-shaped segments, with a size of 3 mm, smaller than the central zone, to facilitate the insertion into corpora cavernosa. It requires less dilatation even in the presence of severe fibrosis and can reduce crural pain because of better flexibility [7, 8].

### 2.2. Surgical procedure

A penoscrotal longitudinal incision is our preferred surgical approach for SSDA prosthesis placement. Trichotomy is performed two hours before surgery and short-term antibiotic prophylaxis (Piperacillin 2 g and Netilmicin 150 mg) is

TABLE 2

No. of sexual intercourses in a month	No. of patients
Less than 1	1
Between 1 and 6	7
More than 6	4

administered. The patient is placed in lithotomic position under spinal anaesthesia. We perform a minimal longitudinally corporotomy (<2 cm), on each corpora cavernosa, and then we place the cylinder with appropriate length through the corporotomy. Routinely, a transurethral catheter is left in place until the first postoperative day. Each patient has been followed up until the surgical wound had healed and any surgical complications have been recorded in detail. Patients were then taught to manipulate the penile prosthesis and were allowed to start sexual activity after 6 weeks [10].

### 2.3. Followup

All patients underwent an annual clinical assessment. All patients reached a 6 years minimum followup. At this time, a questionnaire was administered to the patient and his partner. The questions regarded the frequency of sexual intercourse per month, the acceptance degree by patient and his partner (range 0–10), and the overall sexual satisfaction. In order to investigate the postoperative residual function of the corpora cavernosa, all patients were evaluated by color Doppler dynamic ultrasonography (Esaote-Technos, probe 7, 5–10 MHz) before and after taking oral 50 mg Sildenafil associated to visual sex stimulation. We measured thickness of cavernous tissue, peak systolic velocity, and the presence of plaques.

## 3. RESULTS

The implantation of an SSDA prosthesis straightened the penile shaft in all cases indicating a good surgical outcome and restored sexual satisfaction. All the patients have been discharged within the third postoperative day. We did not have any intraoperative complications. Only one patient had a wound infection without permanent consequences. No subsequent postoperative complications were encountered. Only one man reported less than 1 sexual intercourse in a month, 7 men indicated having 1 to 6 sexual intercourses and 4 men more than 6 sexual intercourses (Table 2). The degree of acceptance by couple was 7, 2 (range 4–10) for men and 7, 8 (range 5–9) for the partner. The overall sexual satisfaction was positive in 11 patients (Table 3). The color Doppler dynamic ultrasonography showed a significant thickness increase of cavernosal tissue (5 to 9 mm) as well as peak systolic velocity increase (7.5 cm/s to 16.5 cm/s) after the dynamic phase; no plaques were detected (Table 4) (Figures 2 and 3; Figures 4 and 5). In all cases, we noted an almost complete straightening of the penile shaft.

TABLE 3

	Mean	Range
Acceptance degree for men (1–10)	7, 2	4–10
Acceptance degree for partner (1–10)	7, 8	5–9
Overall satisfaction (yes-no)	Yes 11 pts (91%)	No 1 pt (9%)

TABLE 4

	Basal		Dynamic	
	Range	Mean	Range	Mean
Thickness of cavernosal tissue	1,7–2,2 mm	1,9 mm	2,8–7,2 mm	5 mm
Peak systolic value	6–9 cm/sec	7,5 cm/sec	13–20 cm/sec	16,5 cm/sec

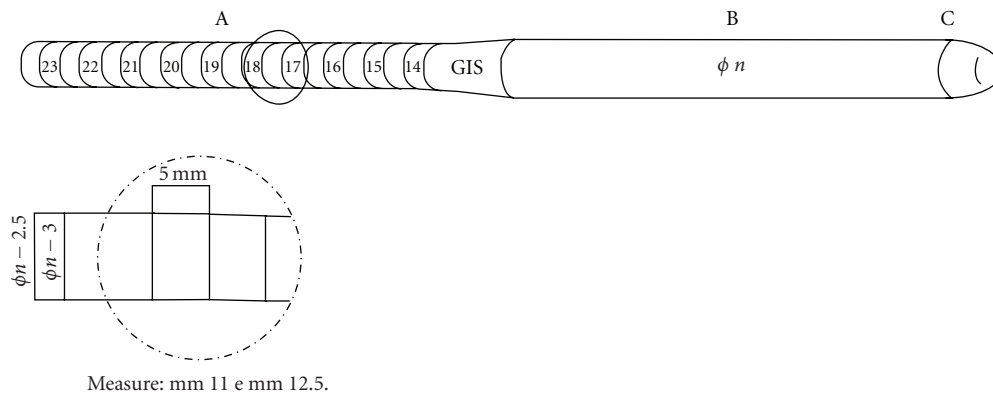


FIGURE 1: Prosthesis SSDA.

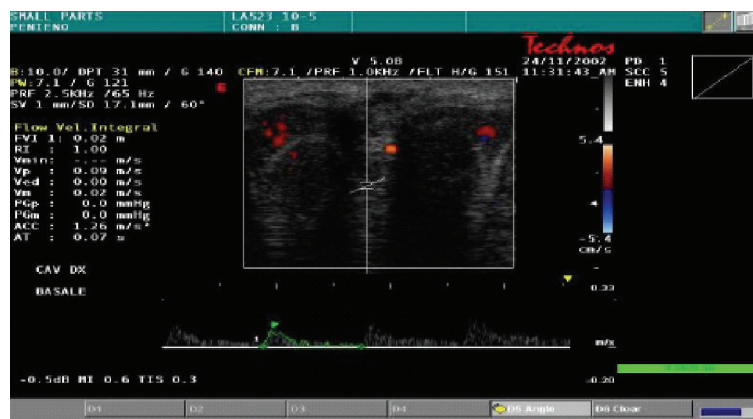

FIGURE 2: Basal cavernosal flow.

#### 4. DISCUSSION

The natural history of IPP can be summarized into early and late stages. The early stage is characterized by reactive inflammation with multifocal spreading into the tunica albuginea. Clinically, a palpable nodule or plaque that makes penis deformed in its shape during a usually painful erection can be shown. In the second phase, fibrosis and calcification of acute inflammation take place making the plaque hard and steadily causing a stable penile curvature, stricture, and some grade shortening during erection. Reduction of both

cavernous blood supply and the possibility of venous leakage due to the rigidity of tunica albuginea may cause some grade of erectile dysfunction.

This histological evolution seems to be constant, while the progression and timing of disease remain unpredictable. We do not have well-defined criteria to establish the end of the process: a quote of patients indeed presents recurrence after long time. Moreover, in younger patients, the course may be more severe [11].

For these reasons, in our opinion the surgical treatment of Peyronie's disease should be as simple as possible, even

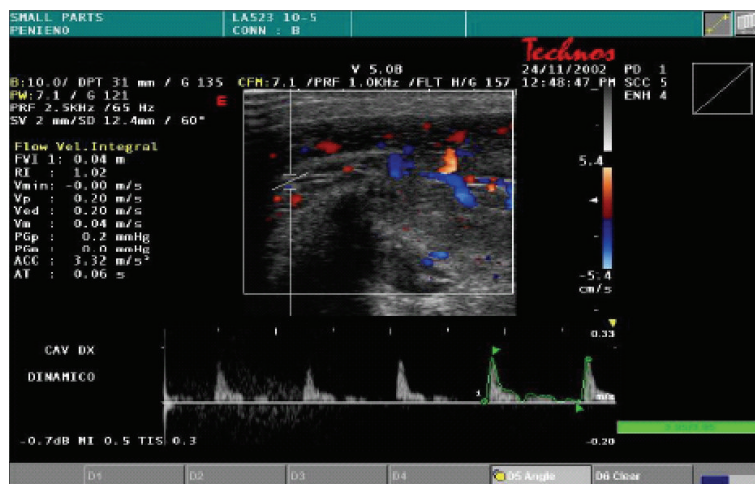


FIGURE 3: Dynamic cavernosal flow.

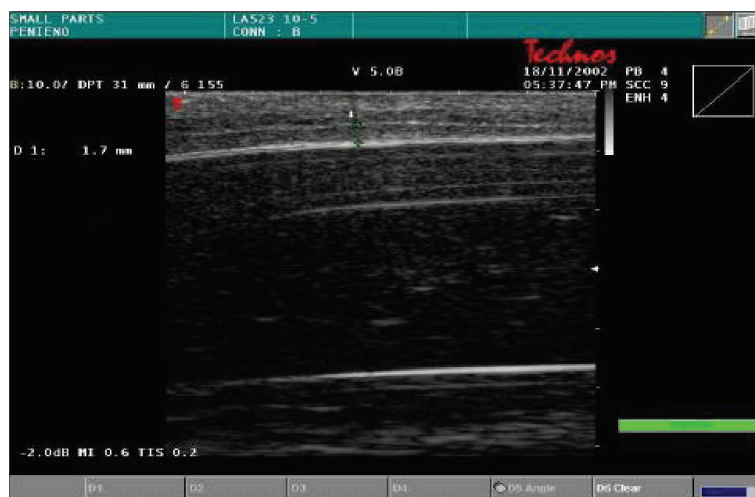

FIGURE 4: Basal thickness of cavernosal tissue.

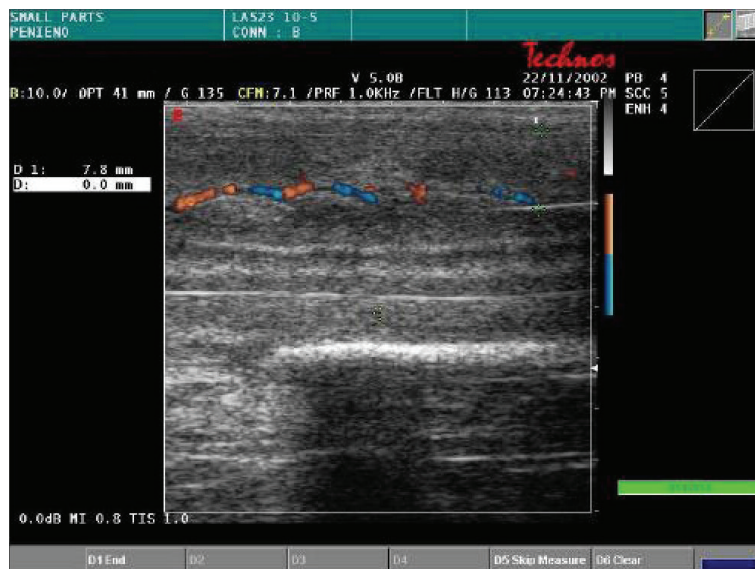


FIGURE 5: Dynamic thickness of cavernosal tissue.

considering the possible multifocal spreading of fibrosis. Moreover, in order to adhere to patient's perspectives, the ideal prosthetic implant should provide a firm and straightened penis, if possible, restoring the original length or girth of the natural erection [12].

The SSDA soft prosthesis satisfies all these criteria as it provides a good hardening and girth of the penis, implant is easy to perform, it has low cost and low mechanical failure rate while an adequate flexibility warranted by structure, shape, and by intrinsic silicone characteristics lead to a good patient tolerance and comfort. Moreover, after implantation, the residual cavernous surrounding tissue is kept intact with an adequate cavernous arterial blood flow making possible its adequate expansion under sexual stimulation. Furthermore, the characteristic softy tip lowers the pressure of the prosthetic shaft on the tip of corpora cavernosa with possible positive impact on pain and eventually on extrusion rate.

Our technique does not include the plaque treatment associated to prosthesis placement. Even in severe penile curvature, the simple placement of the cylinders makes the penile shaft less pronounced. Interestingly, we noted that over time the same penile curvature decreases until almost disappearing. It can be hypothesized that it may be due to continuous mechanical straighten induced by prosthesis associated with residual cavernous tissue function.

A peculiarity of our study is the dynamic study of residual cavernous tissue that gives the basis for a role of pharmacologic rehabilitative postoperative therapy in order to increase vasoactive response to sexual stimulation and improve patients' satisfaction.

If evaluation of patient satisfaction might be considered adequate considering the long-term followup, an even longer followup would be needed to rule out any long-term mechanical failure as well as spontaneous prosthesis extrusion that did not happen in the present study.

## 5. CONCLUSION

Silicon soft dynamic antiextrusion penile prosthesis is safe and effective in the treatment of severe Peyronie's disease associated to penile deformity during erection. Results in terms of penile curvature correction are good. The majority of patients report a sexual satisfaction. Moreover, the positive response to vasoactive drugs by residual cavernous tissue might give the rationale for a pharmacological adjuvant rehabilitation therapy in order to improve the patient satisfaction even in patients having an insufficient residual cavernous tissue erection.

## REFERENCES

- [1] F. G. de la Peyronie, "Sur quelques obstacles qui s'opposent à l'éjaculation naturelle de la semence," *Memoires de l'Academie Royale des Sciences Montpellier Chir*, vol. 1, pp. 425–439, 1743.
- [2] B. B. Garber, "Inflatable penile prosthesis: results of 150 cases," *British Journal of Urology*, vol. 78, no. 6, pp. 933–935, 1996.
- [3] M. Grasso, C. Lania, F. Ronchi, R. Colombo, V. Di Girolamo, and P. Rigatti, "A report of our experience in penile prosthesis

implant," *International College of Surgeons*, abstract no. 20, Il Cairo, 1985.

- [4] M. Grasso, F. Ronchi, V. Di Girolamo, et al., "Our experience in penile prosthesis implant," in *Proceedings of the 2nd World Meeting on Impotence*, Prague, Czech Republic, June 1986, abstract no. 1613.
- [5] R. Shabsigh, "Penile prostheses toward the end of the millennium," *The Journal of Urology*, vol. 159, no. 3, p. 819, 1998.
- [6] H.-S. Chiang, C.-C. Wu, and T.-C. Wen, "10 years of experience with penile prosthesis implantation in Taiwanese patients," *The Journal of Urology*, vol. 163, no. 2, pp. 476–480, 2000.
- [7] N. Burns-Cox, A. Burston, and J. C. Gingell, "Fifteen years experience of penile prosthesis insertion," *International Journal of Impotence Research*, vol. 9, no. 4, pp. 211–216, 1997.
- [8] C. Evans, "The use of penile prostheses in the treatment of impotence," *British Journal of Urology*, vol. 81, no. 4, pp. 591–598, 1998.
- [9] E. Rogers and D. M. Murphy, "Use of the AMS inflatable penile prosthesis in the management of erectile impotence," *Irish Medical Journal*, vol. 90, no. 3, pp. 105–106, 1997.
- [10] C. Lania, M. Grasso, F. Franzoso, S. Blanco, and P. Rigatti, "Peyronie's disease, natural history," *The Journal of Urology*, vol. 171, no. 4, p. 331, 2004.
- [11] K. K. Chew and B. G. A. Stuckey, "Use of transurethral alprostadil (MUSE) (prostaglandin E1) for glans tumescence in a patient with penile prosthesis," *International Journal of Impotence Research*, vol. 12, no. 3, pp. 195–196, 2000.
- [12] A. O. Mireku-Boateng, M. Dennery, and J. Littlejohn, "Use of Sildenafil in penile implant patients," *Urologia Internationalis*, vol. 66, no. 3, pp. 149–151, 2001.



## Research Article

# A Preliminary Report on Combined Penoscrotal and Perineal Approach for Placement of Penile Prosthesis with Corporal Fibrosis

John P. Brusky,<sup>1</sup> Viet Q. Tran,<sup>2</sup> Jocelyn M. Rieder,<sup>2</sup> and Sherif R. Aboseif<sup>2</sup>

<sup>1</sup> Department of Urology, Kaiser Permanente-Bellflower Medical Center, 9400 East Rosecrans Avenue, Bellflower, CA 90706, USA

<sup>2</sup> Department of Urology, Kaiser Permanente-Los Angeles Medical Center, 4867 Sunset Boulevard, Los Angeles, CA 90027, USA

Correspondence should be addressed to John P. Brusky, john.p.brusky@kp.org

Received 2 May 2008; Revised 12 August 2008; Accepted 9 October 2008

Recommended by Miroslav L. Djordjevic

**Purpose.** This paper aims at describing the combined penoscrotal and perineal approach for placement of penile prosthesis in cases of severe corporal fibrosis and scarring. **Materials and methods.** Three patients with extensive corporal fibrosis underwent penile prosthesis placement via combined penoscrotal and perineal approach from 1997 to 2006. Follow-up ranged from 15 to 129 months. **Results.** All patients underwent successful implantation of semirigid penile prosthesis. There were no short- or long-term complications. **Conclusions.** Results on combined penoscrotal and perineal approach to penile prosthetic surgery in this preliminary series of patients suggest that it is a safe technique and increases the chance of successful outcome in the surgical management of severe corporal fibrosis.

Copyright © 2008 John P. Brusky et al. This is an open access article distributed under the Creative Commons Attribution License, which permits unrestricted use, distribution, and reproduction in any medium, provided the original work is properly cited.

## 1. INTRODUCTION

Corporal scarring after infection of a penile prosthesis or priapism greatly increases the difficulty of subsequent prosthesis placement. Fibrosis shortens the penis and can obliterate the cavernosal lumen, preventing easy passage of dilators or prosthetic devices. In the case of extensive scarring, resection or cutting of scar tissue with subsequent reconstruction of the corpora with graft materials is often required. This adds additional complexity and time, and increases the likelihood of complication.

To simplify the procedure, we avoid extensive excision of fibrotic tissue whenever possible. We have found with our preliminary series of three patients that a combined penoscrotal and perineal approach allows for a safe dilation of the corpora, even through densely scarred tissue. Grafting of corporal defects is still possible when necessary.

## 2. PATIENTS AND METHODS

From 1997 to 2006, a total of 3 patients with extensive corporal scarring were treated with placement of semirigid penile prosthesis with a combined penoscrotal and perineal

approach. All patients had previous removal of infected penile prosthesis and corporal scarring was anticipated. One patient had a history of three prior implants which were removed for infection. In all patients, extensive corporal fibrosis was encountered preventing easy proximal passage of the Hegar metal dilators. In all cases, we felt that blind passage of the metal dilators was not possible or safe, and that prosthetic implantation would not be possible without a secondary approach. A combined penoscrotal and perineal approach was utilized and successful placement of prostheses was accomplished in all patients.

## 3. DESCRIPTION OF TECHNIQUE

All patients are placed in a low lithotomy position for easy access to the perineum and abdomen. The lower abdomen is prepped in the event that autologous rectus fascia is needed for corporal grafting. An extended 10-minute betadine scrub is utilized and the anus is excluded from the draped field. A foley catheter is placed and the surgeon changes his outer gloves. A longitudinal penoscrotal incision is made, except when circumcision is planned, in which case a subcoronal incision with degloving of the penis is performed. Liberal

use of antibiotic irrigating solution is utilized throughout the entire procedure.

Longitudinal corporal incisions are made with cutting current electrocautery and 2–0 vicryl stay sutures are placed in the cut edges for retraction. Metzenbaum scissors are initially used to gently dilate the corporal space. The corporotomies are extended proximally as necessary. Excision of the corpora is avoided if possible. If the corpora can be dilated easily, then a combined perineal approach is not necessary.

If blind passage of the dilators proximally is felt unsafe, then the perineal approach is also used. A longitudinal perineal incision is performed. The crus of each corpus cavernosum is exposed; a ring retractor with hooks aids with exposure. Longitudinal corporotomies are made and stay sutures are placed. We have found that the proximal corpora are usually less scarred in these cases, and the true lumen is more easily identified. With one finger in the corpora above, a tonsil clamp is passed from below and guided through the area of fibrosis by palpation. The tips of the instrument are pointed away from the urethra to avoid injury (Figure 1). Gentle spreading while withdrawing the instrument helps create the tract. A 6 French ureteral catheter may be placed through the tract to aid in its identification and avoid creation of false passages. Progressively, larger metal dilators are then passed through the tract, either from above or below, whichever proves easier. An appropriately sized prosthesis is then placed. In cases of excessive scarring, we recommend the use of a semirigid prosthesis. The corporotomies are closed with running 2–0 absorbable monofilament suture. If there is excessive tension while closing the corpora over the prosthesis, then a porcine acellular collagen matrix or autologous rectus fascia graft is used to reconstruct the defect.

#### 4. RESULTS

Three patients with postinfection fibrosis following prior removal of a penile prosthesis were implanted using the combined penoscrotal and perineal approach. All patients had extensive bilateral corporal fibrosis. Semirigid penile prostheses were placed in all patients. To aid in closing corporal defects, autologous fascia was grafted in two patients. Mean follow-up time was 91 months (range 15 to 129 months). To date there have been no complications and no reoperations.

#### 5. DISCUSSION

Penile fibrosis may result from untreated priapism, previous penile prosthesis removal, or intracavernosal injection therapy. Severe fibrosis can greatly complicate the placement of subsequent penile prostheses. The favored approach for severely fibrotic corpora includes excision of fibrotic tissue and grafting with a variety of materials as necessary to repair the defect. Others have advocated corporoscopic resection of fibrotic tissue [1].

In 1986, Herschorn et al. described a two-incision, combined penoscrotal/subcoronal technique for facilitating placement of prostheses in cases of severe distal corporal

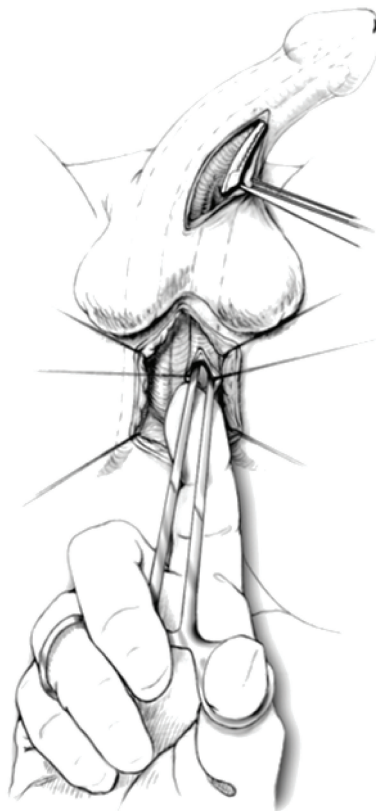

FIGURE 1: Combined perineal and penoscrotal approach facilitates passage of an instrument from above and below to allow adequate space to be created.

scarring [2]. Rajpurkar et al. described a minimal scar excision technique through a perineal approach, with a secondary subcoronal incision when necessary for distal scarring [3].

Our approach is somewhat different in that we start with the more familiar penoscrotal approach on all patients. The only initial difference is in patient positioning; a low lithotomy position provides access to the perineum if needed. In most instances when scarring was predicted, however, we were able to safely pass the prostheses proximally without the need for a second incision. In these cases, the low lithotomy position did not interfere with the purely penoscrotal approach.

We find that the most difficult and potentially dangerous step in prosthesis placement with corporal fibrosis is proximal dilation. Blind dilation with excessive force may cause false passages, crural perforation, or urethral injury. The pendulous corpora, however scarred they may be, are more easily visualized and confidently manipulated. Previously, operations have been aborted when proximal dilation was not achieved. Identification of the true corporal lumen is often easier when approached more proximally through a perineal incision. With corporal openings both proximally and distally, a long pointed clamp is more easily passed through the corpora with direct palpation of the instrument tip with the opposite hand. Placing a ureteral

catheter through the tract helps maintain accuracy while dilating the tract with gentle spreading of a clamp or metzenbaum scissors. Subsequent passage of metal dilators is then facilitated.

In these difficult cases, we prefer to use semirigid prostheses, although we believe that the same technique can be applied for placement of inflatable prostheses. Summerton et al. used downsized inflatable cylinders as tissue expanders in cases of severe fibrosis, later replacing them with larger cylinders [4]. Regardless of the type of prosthetic placed or the need for corporal excision or grafting, we based our preliminary result that using a combined penoscrotal and perineal approach greatly increases the chance of successful prosthetic placement.

## 6. CONCLUSION

Our preliminary result, based on three patients, suggests that a combined penoscrotal and perineal approach to penile prosthetic surgery is safe and increases the chance of successful outcome in the surgical management of severe corporal fibrosis. We do intend to enroll more patients to confirm these results.

## REFERENCES

- [1] O. Shaeer and A. Shaeer, "Corporoscopic excavation of the fibrosed corpora cavernosa for penile prosthesis implantation: optical corporotomy and trans-corporeal resection, Shaeer's technique," *Journal of Sexual Medicine*, vol. 4, no. 1, pp. 218–225, 2007.
- [2] S. Herschorn, M. Barkin, and R. Comisarow, "New technique for difficult penile implants," *Urology*, vol. 27, no. 5, pp. 463–464, 1986.
- [3] A. Rajpurkar, H. Li, and C. B. Dhabuwala, "Penile implant success in patients with corporal fibrosis using multiple incisions and minimal scar tissue excision," *Urology*, vol. 54, no. 1, pp. 145–147, 1999.
- [4] D. J. Summerton, T. R. Terry, J. R. Delk, and S. K. Wilson, "Reimplantation of inflatable penile prostheses (IPP) into scarred corporal bodies facilitated by the new AMS 700CXR cylinders," *BJU International*, vol. 95, supplement 5, p. 102, 2005.

## Review Article

# Penile Corporeal Reconstruction during Difficult Placement of a Penile Prosthesis

**Viet Q. Tran, Timothy F. Lesser, Dennis H. Kim, and Sherif R. Aboseif**

*Section of NeuroUrology and Reconstructive Surgery, Department of Urology, Kaiser Permanente Medical Center, 4900 Sunset Boulevard, Los Angeles, CA 90027, USA*

Correspondence should be addressed to Sherif R. Aboseif, [sherif.r.aboseif@kp.org](mailto:sherif.r.aboseif@kp.org)

Received 2 May 2008; Accepted 6 August 2008

Recommended by Miroslav L. Djordjevic

For some patients with impotence and concomitant severe tunical/corporeal tissue fibrosis, insertion of a penile prosthesis is the only option to restore erectile function. Closing the tunica over an inflatable penile prosthesis in these patients can be challenging. We review our previous study which included 15 patients with severe corporeal or tunical fibrosis who underwent corporeal reconstruction with autologous rectus fascia to allow placement of an inflatable penile prosthesis. At a mean follow-up of 18 months (range 12 to 64), all patients had a prosthesis that was functioning properly without evidence of separation, herniation, or erosion of the graft. Sexual activity resumed at a mean time of 9 weeks (range 8 to 10). There were no adverse events related to the graft or its harvest. Use of rectus fascia graft for coverage of a tunical defect during a difficult penile prosthesis placement is surgically feasible, safe, and efficacious.

Copyright © 2008 Viet Q. Tran et al. This is an open access article distributed under the Creative Commons Attribution License, which permits unrestricted use, distribution, and reproduction in any medium, provided the original work is properly cited.

## 1. INTRODUCTION

For some patients with both impotence and concomitant penile fibrosis, placement of a penile prosthesis is the only viable therapy to allow restoration of erectile function. Placement of a penile prosthesis in the setting of severe corporeal or tunica albuginea fibrosis can be very difficult and challenging. This may hinder the surgeon from satisfactorily dilating the corporeal bodies to accommodate the prosthesis and/or closing the tunica albuginea over the cylinders. This in turn may negatively affect the function of the prosthesis, limit the size of the prosthesis, and ultimately negatively impact the patient's overall satisfaction [1].

Several etiologies of corporeal fibrosis have been identified including multiple penile surgeries, prior removal of an implant for infection, erosion or malfunction, priapism, chronic intracavernous injections, penile trauma, or Peyronie's disease [2–5]. In phalluses with extreme fibrosis where satisfactory dilatation of the corpora and/or closure of the tunica albuginea is not feasible, several techniques have been described to allow for placement of a penile implant. One option is to use readily available downsized implants [6]. The Otis urethrotome has been used to perform an

extended corporotomy with extensive tunical excision to facilitate placement of an implant [7]. When these various techniques are unsuccessful, penile reconstruction with or without graft material is necessary [8].

Grafting of the penile corpora is a valuable tool that can help surgeons in penile reconstructive surgery. In 1950, Lowsley and Boyce described the first usage of a fat graft to surgically repair Peyronie's disease [9]. Since then, various grafts have been explored in search of an ideal graft that best mimics the properties of the tunica albuginea. These characteristics should include good compliance and pliability, minimal inflammation, high tensile strength to prevent bulging or aneurysmal dilatation, low antigenicity risk, low infection transmission risk, availability in various sizes, packaging, and cost [10]. Modern graft materials described in the literature include fat, vein, rectus fascia, tunica vaginalis, temporalis fascia, dermis, cadaveric dura, cadaveric pericardium, porcine small intestine submucosa (SIS), and synthetic grafts such as Dacron and Gore-Tex [11–20]. Choosing an appropriate graft material and technique is a crucial aspect for successful tunical/corporeal reconstruction and ideal functional outcome of prosthetic surgery.



The use of rectus fascia is well documented in the literature for a variety of uses in reconstructive surgery. As we previously reported, we evaluated the functional outcomes and patient satisfaction in patients who underwent rectus fascia grafting for reconstruction of the corporeal bodies in the setting of severe tunical/corporeal fibrosis in order to facilitate the placement of a penile prosthesis [21].

## 2. MATERIAL AND METHODS

As previously reported, 15 patients who underwent placement of an inflatable penile implant and corporeal/tunica reconstruction using autologous rectus sheath were included into the study [21]. The patients were divided into two groups. *Group I* included seven patients who had tunica fibrosis secondary to Peyronie's disease and associated severe erectile dysfunction. These patients had penile curvature and erectile dysfunction for more than 12 months (mean 14 months) and had exhausted all medical forms of treatment. None in this group had prior surgery for correction of penile curvature or impotence. *Group II* was composed of eight patients who had severe corporeal fibrosis related to a history of penile prosthesis removal secondary to malfunction ( $n = 1$ ), infection ( $n = 3$ ), or erosion ( $n = 4$ ). Patients had their devices placed at least 24 months prior to reinsertion (mean 36 months). Six of these eight patients had more than one implant surgery in the past.

All patients in *groups I* and *II* underwent placement of a three-piece inflatable penile prosthesis. Seven were recipients of a Mentor Alpha I inflatable penile implant and the other eight were recipients of an AMS 700 inflatable implant. Patients in both groups had a significant tunical albuginea defect after the placement of the prosthesis, requiring corporeal reconstruction with graft material to provide adequate corporeal coverage and closure. The defect size was determined at the time of surgery and a corresponding sized graft was harvested from rectus fascia. Postoperative evaluations and exams focused on the function of the prosthesis, with attention to any findings suggesting herniation or erosion. Also, patients' abdomens were closely examined for any evidence of hernia or wound infection related to the graft harvest site. Follow-up clinical exams and interviews were conducted at 1, 6, and 12 months, and yearly visits thereafter.

### 2.1. Surgical technique

The surgical technique is detailed here as we have previously described [21]. Preoperative intravenous antibiotics, including 1 gram of Vancomycin and 160 mg of Gentamicin (adjusted for patient weight and renal function), were administered to all patients. Patients were positioned supine on the operating room table. A 16 French Foley catheter was inserted prior to making the skin incision.

#### *Group I*

After making a circumcision incision, the penile skin was degloved exposing both corpora cavernosa and neurovas-

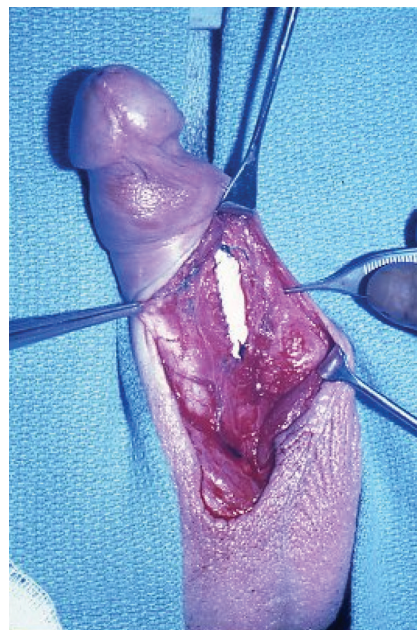


FIGURE 1: Augmentation of the tunica albuginea is shown here with a rectus fascia graft sewn in place allowing coverage of the penile prosthesis.

cular bundles. An artificial erection was induced using injectable saline with compression at the base of the penis. Both neurovascular bundles were dissected and reflected laterally and the tunical plaque was exposed. The point of maximum curvature was marked and an H-incision was made at this site: two lateral, longitudinal incisions for placement of the prosthetic cylinders, and a transverse incision on the plaque to release the curvature as previously described by Aboseif et al. [22]. After corporeal dilation and proper sizing of the implant, the rectus fascial graft was harvested through a transverse suprapubic incision. The grafts were excised as rectangular strip to correspond with the tunica albuginea defect size (mean 2 cm  $\times$  8 cm). The reservoir was then placed in the retroperitoneal space through the same incision. The graft was then fashioned to cover the defect, and secured using 4-0 Maxon suture in a running fashion (Figure 1). Caution was taken to prevent injury to the underlying inflatable implant during this step.

#### *Group II*

A midline penoscrotal incision was made to expose both corpora cavernosa. A longitudinal incision was made on the ventrolateral surface of each corpus, extending from the glans penis to the most proximal position possible. Caution was taken to avoid cutting through the full thickness of the corporeal bodies, as there is usually dense scar tissue obliterating the normal planes and possibly the intracorporeal tissue. Once in good position, the intracorporeal space was dilated both proximally and distally using Metzenbaum scissors. After proper sizing of the implant, the tunical defect was

measured, and the rectus fascia was harvested and secured with 4-0 Maxon as described earlier.

This technique is similar in concept to an on-lay urethroplasty for urethral stricture disease. By incising the tunica and placing a graft, the size of the corporeal bodies conceivably is enlarged which allows its closure without any tension or ischemia to the tissues.

Once the tunical defect was closed with the rectus fascia graft, inflation of the prosthesis was performed to ensure correction of the defect and proper function of the new prosthesis. The penile and the suprapubic wounds were closed in a normal fashion. Penile dressing and scrotal fluff were then applied.

Patients were admitted overnight for postoperative observation and continued on intravenous antibiotics. Average hospital stay was one day. The foley catheter was removed prior to the discharge. Patients were instructed to keep the device deflated for 6 weeks. Subsequent follow-up appointments were scheduled for 1-, 6-, and 12-month intervals, followed by yearly visits. Clinical data concerning the prosthesis function, integrity of the graft, wound healing, patient satisfaction and complications were evaluated during each follow-up visit.

### 3. RESULTS

Fourteen out of fifteen patients were available for evaluation, while the remaining patient was lost to follow-up. Placement of a functioning inflatable penile prosthesis with reconstruction of the tunical deficiency with autologous rectus fascia was successful in all 14 patients at a mean follow-up of 18 months (range 3 to 36). All of the implanted prostheses were functioning appropriately, with all 14 patients reporting satisfactory sexual intercourse. Six patients reported suprapubic discomfort with moderate-level activity in the first 3–6 months, which resolved in 5 of the 6 patients. Four patients had penile hypoesthesia of the glans, which eventually resolved in 2 patients but persisted in the other 2. One patient complained of shortening of his penis, but he was still able to have satisfactory intercourse. There was no evidence of rectus fascia graft compromise since no kinking or herniation of the prostheses was found. Furthermore, there were no adverse events such as infection, prosthesis malfunction, incisional hernia, or fluid collections at the site of graft harvest that resulted from the harvesting of the rectus fascia.

### 4. DISCUSSION

In a subset of patients with impotence and concomitant severe tunical and cavernous tissue fibrosis, reestablishment of erectile function is dependent on implantation of a penile prosthesis. In this setting, a sizable tunical defect may be encountered during penile prosthesis implantation and corporeal reconstruction may become necessary. Several surgical techniques have been described to handle such situations. Corporeal reconstruction with graft material is an acceptable option. Various materials for such reconstructive repairs have been used and described in the literature.

The use of nonautologous grafts for corporeal reconstruction has been widely reported in the literature. Commercially available human cadaveric fascia or porcine tissues are viable options for graft material. These free tissue grafts have been used extensively in various urologic procedures for other applications such as placement of a pubovaginal sling or during the surgical correction of Peyronie's disease [23, 24]. The use of the various porcine tissue grafts (including dermis, pericardium, and small intestinal submucosal) has been published, showing good results [18, 25]. These graft materials provide off-the-shelf availability, decreased operative time, and no donor site morbidity, however they are quite expensive.

Synthetic grafts (i.e., Gortex, dacron, prolene) are readily available, come prepackaged in various sizes, and do not require a second incision to harvest from a donor site. The drawbacks to using a synthetic graft are that they are costly, may predispose the patient to infection, and behave physiologically different than the tunica albuginea [6, 26]. The tensile strength of the synthetic graft is much greater than the native tunica albuginea resulting in limited expandability. These characteristics limit the full expansion potential of the cylinders [27].

Harvesting autologous grafts is performed for various urologic and nonurologic reconstructive surgeries. These grafts include rectus fascia, fascia lata, dermis, saphenous vein, temporalis fascia, and tunica albuginea. They have the advantage of being noninfectious and nonimmunogenic, possess good tensile strength, and are readily abundant to close any size tunical defect. The potential disadvantages of using autologous grafts may include increased operative time secondary to harvest time, bleeding, and morbidity related to the harvest site [10]. Venous grafts have been shown to be superior to other autologous tissues in the repair of Peyronie's disease owing to its physiologic properties that better mimic the vascular intercorporeal space [28, 29]. It is more elastic and is less likely to contract than other autologous tissues, and the venous endothelium offers the theoretical advantage of nitric oxide secretion to maintain normal erectile physiology [28]. When tissue graft material is used to reconstruct the corpora in facilitating implantation of a prosthesis, reconstructing the corpora with tissue material that is nonsynthetic and has high tensile strength is crucial in providing adequate tissue support for the inflatable penile prosthesis. In our reported study, we elected to use autologous rectus fascia because it fulfills these requirements and it also allowed harvesting of the graft to occur through the same suprapubic incision that is made for the placement of the inflatable prosthesis reservoir without having to make a separate incision [21].

Using an autologous rectus fascial graft for corporeal reconstruction helps facilitate the placement of a penile prosthesis when encountering severe tunical/corporeal fibrosis. This is similar in concept to on-lay urethroplasty for stricture disease; the graft allows the overall corporeal body circumference to increase which in turn allows the implant to inflate better. Furthermore, it allows closure of the tunica without tension, thus avoiding any possible ischemia of the tissues with its risk of infection and complications. All

patients in the study incurred no complications related to the use or harvesting of the graft. Long-term follow-up demonstrated that all the patients in the study had excellent prosthetic function and were satisfied with their overall outcomes.

## 5. CONCLUSION

We concluded in our study that the use of rectus fascia grafts for the augmentation of the tunical deficiencies and corporeal reconstruction during difficult penile prosthesis implantation yielded excellent clinical results. Long-term outcomes demonstrated high overall patient satisfaction. Ease of harvesting, reduced cost, elimination of the synthetic and xenographic materials make this graft an excellent anatomic and functional tunical substitute. Rectus fascia graft is a valuable addition to the reconstructive urological repertoire and should be considered when tunical defect precludes adequate tunical closure during penile prosthesis implantation.

## REFERENCES

- [1] L. D. Knoll and W. L. Furlow, "Corporeal reconstruction and prosthetic implantation for impotence associated with non-dilatable corporeal cavernosal fibrosis," *Acta Urologica Belgica*, vol. 60, no. 1, pp. 15–25, 1992.
- [2] R. A. Bertram, G. D. Webster, and C. C. Carson III, "Priapism: etiology, treatment, and results in series of 35 presentations," *Urology*, vol. 26, no. 3, pp. 229–232, 1985.
- [3] J. N. Macaluso Jr. and J. W. Sullivan, "Priapism: review of 34 cases," *Urology*, vol. 26, no. 3, pp. 233–236, 1985.
- [4] B. R. Orvis and J. W. McAninch, "Penile rupture," *The Urologic Clinics of North America*, vol. 16, no. 2, pp. 369–375, 1989.
- [5] C. J. Devine Jr. and C. E. Horton, "Bent penis," *Seminars in Urology*, vol. 5, no. 4, pp. 251–261, 1987.
- [6] L. D. Knoll and W. L. Furlow, "Comparison of the use of a downsized inflatable penile prosthesis vs. prosthetic implantation with gore-tex grafting for nondilatable cavernosal fibrosis," *The Journal of Urology*, vol. 149, no. 2, p. 335, 1993.
- [7] L. D. Knoll, "Use of penile prosthetic implants in patients with penile fibrosis," *The Urologic Clinics of North America*, vol. 22, no. 4, pp. 857–863, 1995.
- [8] I. J. Fishman, "Corporeal reconstruction procedures for complicated penile implants," *The Urologic Clinics of North America*, vol. 16, no. 1, pp. 73–90, 1989.
- [9] O. S. Lowsley and W. H. Boyce, "Further experiences with an operation for the cure of Peyronie's disease," *The Journal of Urology*, vol. 63, no. 5, pp. 888–902, 1950.
- [10] C. C. Carson and J. L. Chun, "Peyronie's disease: surgical management: autologous materials," *International Journal of Impotence Research*, vol. 14, no. 5, pp. 329–335, 2002.
- [11] O. S. Lowsley and W. H. Boyce, "Surgical treatment of plastic induration of the penis," *New York State Journal of Medicine*, vol. 43, p. 2273, 1943.
- [12] H. Sachse, "Venenwandplastik bei Induratio penis plastica," *Urologe A*, vol. 15, no. 3, pp. 131–132, 1976.
- [13] S. Craatz, K. Spanel-Borowski, J.-F. Begemann, R. Olanas, M. Fisch, and R. Hohenfellner, "The dorsal lamina of the rectus sheath: a suitable grafting material for the penile tunica albuginea in Peyronie's disease?" *BJU International*, vol. 97, no. 1, pp. 134–137, 2006.
- [14] M. Amin, W. L. Broghamer Jr., J. I. Harty, and R. Long Jr., "Autogenous tunica vaginalis graft for Peyronie's disease: an experimental study and its clinical application," *The Journal of Urology*, vol. 124, no. 6, pp. 815–817, 1980.
- [15] H. Bruschini and A. I. Mitre, "Peyronie disease: surgical treatment with muscular aponeurosis," *Urology*, vol. 13, no. 5, pp. 505–506, 1979.
- [16] A. Kelami, "Surgical treatment of Peyronie's disease using human dura," *European Urology*, vol. 3, no. 3, pp. 191–192, 1977.
- [17] L. A. Levine and C. R. Estrada, "Human cadaveric pericardial graft for the surgical correction of Peyronie's disease," *The Journal of Urology*, vol. 170, no. 6, part 1, pp. 2359–2362, 2003.
- [18] L. D. Knoll, "Use of porcine small intestinal submucosal graft in the surgical management of tunical deficiencies with penile prosthetic surgery," *Urology*, vol. 59, no. 5, pp. 758–761, 2002.
- [19] P. C. Ho, C. L. Parsons, and J. D. Schmidt, "Surgical treatment of Peyronie's disease with a dacron graft," in *Proceedings of the Annual Meeting of the Western Section, American Urological Association*, Tucson, Ariz, USA, July 1979.
- [20] E. S. Cohen, J. D. Schmidt, and C. L. Parsons, "Peyronie's disease: surgical experience and presentation of a proximal approach," *The Journal of Urology*, vol. 142, no. 3, pp. 740–742, 1989.
- [21] A. S. Pathak, J. H. Chang, A. R. Parekh, and S. R. Aboseif, "Use of rectus fascia graft for corporeal reconstruction during placement of penile implant," *Urology*, vol. 65, no. 6, pp. 1198–1201, 2005.
- [22] S. R. Aboseif, L. S. Baskin, T. S. B. Yen, and T. F. Lue, "Congenital defect in sinusoidal smooth muscles: a cause of organic impotence," *The Journal of Urology*, vol. 148, no. 1, pp. 58–60, 1992.
- [23] M. K. Gelbard and B. Hayden, "Expanding contractures of the tunica albuginea due to Peyronie's disease with temporalis fascia free grafts," *The Journal of Urology*, vol. 145, no. 4, pp. 772–776, 1991.
- [24] L. A. Levine and C. R. Estrada, "Human cadaveric pericardial graft for the surgical correction of Peyronie's disease," *The Journal of Urology*, vol. 170, no. 6, part 1, pp. 2359–2362, 2003.
- [25] J. L. Chun, A. McGregor, R. Krishnan, and C. C. Carson, "A comparison of dermal and cadaveric pericardial grafts in the modified Horton-Devine procedure for Peyronie's disease," *The Journal of Urology*, vol. 166, no. 1, pp. 185–188, 2001.
- [26] J. P. Jarow, "Risk factors for penile prosthetic infection," *The Journal of Urology*, vol. 156, no. 2, pp. 402–404, 1996.
- [27] M. Bitsch, B. Kromann-Andersen, J. Schou, and E. Sjøntoft, "The elasticity and the tensile strength of tunica albuginea of the corpora cavernosa," *The Journal of Urology*, vol. 143, no. 3, pp. 642–645, 1990.
- [28] A. I. El-Sakka, H. M. Rashwan, and T. F. Lue, "Venous patch graft for Peyronie's disease—part II: outcome analysis," *The Journal of Urology*, vol. 160, no. 6, part 1, pp. 2050–2053, 1998.
- [29] F. Montorsi, A. Salonia, T. Maga, et al., "Evidence based assessment of long-term results of plaque incision and vein grafting for Peyronie's disease," *The Journal of Urology*, vol. 163, no. 6, pp. 1704–1708, 2000.

## Review Article

# Penile Prosthesis: What Should We Do about Complications?

**C. Bettocchi,<sup>1</sup> P. Ditonno,<sup>1</sup> F. Palumbo,<sup>1</sup> G. Lucarelli,<sup>1</sup> G. Garaffa,<sup>2</sup> B. Giammusso,<sup>3</sup>  
and M. Battaglia<sup>1</sup>**

<sup>1</sup> *Department of Emergency and Organ Transplantation, Urology Andrology and Kidney Transplantation Unit, University of Bari, 70124 Bari, Italy*

<sup>2</sup> *St Peter's Department of Andrology, University College London Hospitals, London W1G 6BJ, UK*

<sup>3</sup> *Department of Urology, Vittorio Emanuele Hospital, University of Catania, 95124 Catania, Italy*

Correspondence should be addressed to C. Bettocchi, [bettocchi@urologia.uniba.it](mailto:bettocchi@urologia.uniba.it)

Received 21 May 2008; Accepted 13 September 2008

Recommended by Miroslav L. Djordjevic

Even in the era of phosphodiesterase type 5 inhibitors, penile implants are considered the definitive solution for the treatment of organic erectile dysfunction. The advent of new surgical tools and new infection-resistant materials has significantly reduced the risk of intra and post-operative complications and the need for revision surgery. Various companies have also improved their mechanical systems in order to reduce the risk of failures, and their products are now so good they may last lifelong. In this article, we evaluate the intraoperative and postoperative complications recorded in our experience and in literature reports, and make some suggestions as to how to prevent or correct them.

Copyright © 2008 C. Bettocchi et al. This is an open access article distributed under the Creative Commons Attribution License, which permits unrestricted use, distribution, and reproduction in any medium, provided the original work is properly cited.

## 1. INTRODUCTION

Nowadays implanting a penile prosthesis is the definitive solution for the treatment of organic erectile dysfunction (ED), even in the era of effective and safe oral medications [1]. The types of prosthesis most commonly implanted are the three-piece inflatable device, the two-piece inflatable device, and the soft and malleable prosthesis. In the last few years, the three-piece inflatable device has been used for preference, as it improves the erection, the flaccid, and appearance of the penis and as it yields a more acceptable and cosmetical functional results [2]. On the other hand, the relative complexity of this last device is also the source of mechanical failures and patients' difficulties in managing the device. In the last decade, there has been a continuous improvement in the mechanical function of the devices and in the composition of the materials used but device-related complications still occur.

Some complications can be prevented by a correct preoperative assessment. The surgeon has to understand the patient's real needs and expectations, as well as those of his partner in order to be able to choose the right device. The counselling must also include a complete, clear explanation of how the device functions and the obvious changes that will arise in the sexual life of the couple. Informed consent

to the procedure is mandatory, and when discussing the option of a penile implant with the patient, issues such as complications and the irreversibility of the procedure should be exhaustively discussed.

In this paper, we evaluate the intraoperative and post-operative complications recorded in our experience and in literature reports, and make some suggestions as to how to prevent or correct them.

## 2. INTRAOPERATIVE COMPLICATIONS

### 2.1. *Cylinders positioning*

During the implant procedure, after having exposed the corpora cavernosa and performed the corporotomy, the first critical step is dilating the corpora. In most patients the corpus cavernosum cavity is dilated to the maximum capacity using Hegar dilators of various sizes. The dilator must be introduced through the corpus by pushing it in an outward direction in order to avoid cross-over perforation. In cases of fibrotic corpora, special dilators may be useful to create an appropriate space (Rossello dilators or Otis urethrotome) because perforation is especially risky in this case.

A distal corpora perforation can be corrected first of all by exposing the damaged corpus apex. Then, if it is only a





FIGURE 1: A dacron sock created around the tip of a malleable prosthesis in a case of proximal corpus cavernosum perforation.

small hole, the tip can be closed with separate PDS stitches. The way to manage distal perforation in cases of larger holes is by covering the damaged apex with a dacron or gore-tex sleeve.

Proximal corpora perforation usually occurs during dilatation of the corpus cavernosum crura. A possible way to evaluate a proximal perforation intraoperatively is by positioning dilators in both crura and checking whether they are at different heights, showing that one has penetrated too deeply inside the corpus. If not discovered during the operation, a postoperative MRI scan is the best evaluation to confirm a proximal perforation. One of the two ways of managing this complication is by creating dacron or gore-tex socks, especially in cases of a malleable or soft prosthesis (Figure 1). The other possibility, indicated for inflatable devices, is to fix the cylinders to the surrounding corpora tissue, placing stitches above and below the tubes input. The anchored cylinder tends not to protrude, allowing healing of the perforation. Another similar solution involves fashioning a sling through the tip extender using nonabsorbable sutures.

Incorrect introduction of the dilators is the main cause of cross-over perforation. It is important to recognise this kind of perforation as soon as possible so as to implant two cylinders in the same corpus. Usually a redo correct ipsilateral dilatation is sufficient to correct the cross-over perforation.

Another consequence of incorrect dilators introduction is urethral perforation. To check for urethral injuries, it is always best to irrigate the corpora with a saline plus antibiotic solution: if the fluid leaks through the urethral meatus, a perforation has occurred. The diagnosis can be confirmed by cystoscopy. The treatment option in such cases is urethral repair for proximal perforations. If the laceration involves the urethral meatus, it is advisable to postpone the procedure. It is possible to position a urethral catheter if necessary with a suprapubic catheter, delaying insertion of the cylinder or positioning of a malleable prosthesis until the damaged urethra has healed. The malleable prosthesis will be replaced by the inflatable cylinder at a later date during a second operation.

A rare complication has been described by Hatzimouratidis et al. [3]; it occurred during dilation of the corpora cavernosa with Brooks dilators: the head detached and stuck to the tip of the corpus cavernosum. The case was managed by incising the distal lateral part of the corpora cavernosa and then removing the head of the dilators. In any case, we strongly recommend examining all surgical tools carefully before using them.

## 2.2. Reservoir positioning

The possible complications occurring during the reservoir positioning step are mostly due to this peculiar blind procedure. If the fascia is not completely opened, the reservoir may not pass through, remaining outside: this is a typical postoperative complication. Another possibility is to open the peritoneum: in this case, it is mandatory to check for bowel injuries.

During reservoir positioning, it is very important to have positioned a urethral catheter and ensured that the patient has completely emptied his bladder. If not, the risk of bladder perforation is high. This complication can also occur in patients who have previously undergone pelvic surgery, such as radical prostatectomy. If a bladder perforation occurs, cystoscopy can confirm the damage severity; usually leaving a catheter in place for a few days is sufficient to treat such complications. In rare cases of wide perforation, an open bladder repair can be performed.

## 2.3. Component failure/breakage

In order to avoid a malfunctioning device, it is always advisable to check correct device functioning before placement and to activate the pump with cylinders connected after the placement. At this surgical stage, it is easy to substitute a nonfunctioning device.

Another possible complication is breakage of device components during cavernotomy closure or during repositioning of Scott retractor's hooks during the operation. One way to prevent device perforation is to put the stitches in before performing the corporotomy and before positioning the cylinders.

## 3. POSTOPERATIVE COMPLICATIONS

### 3.1. Cylinders complications

#### Infections

Infection is one of the most fearsome complications, having an incidence of 8 to 20%, as reported in large series of implants [2–4]. Infections can occur a few months after surgery and a typical sign is persistent, unchanging, or even increasing pain. The pain could be exacerbated by activating the device. Other signs of infection are penile or scrotal erythema, fever, purulent drainage from the wound, or skin erosion. Diabetic patients are more likely to develop an infection, even if the previous concept that poor glycemic control increases the risk has not been confirmed [5]. Moreover, insulin dependency and hemoglobin A1C

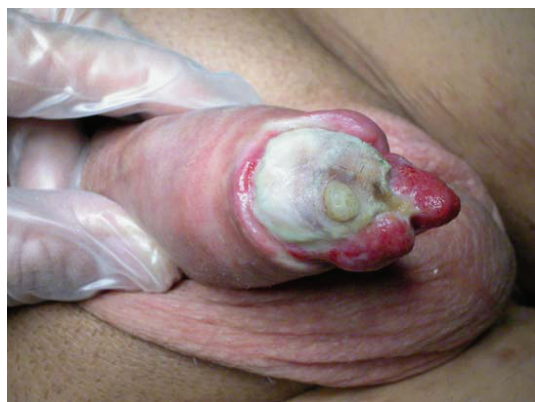

FIGURE 2: Distal erosion with massive glans necrosis.

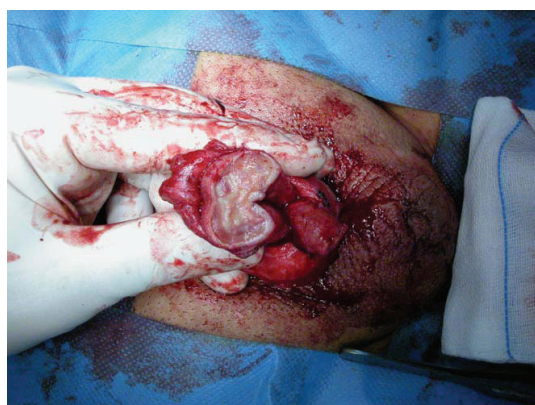


FIGURE 3: Penile amputation to eliminate all the necrotic tissue surrounding the extruded cylinders.

serum levels are not considered additional risk factors. Other conditions, possibly associated with an increased risk of infection, are the use of immunosuppressive drugs and steroids, and the presence of spinal cord injury.

When the presence of infection is confirmed, the use of systemic antibiotics therapy is not sufficient in the vast majority of cases. This is due to the infectious agent's ability to create a biofilm surrounding the prosthesis components, protecting bacteria from the antibiotic action. In most cases, the infection is sustained by opportunistic bacteria such as *Staphylococcus epidermidis* or *Streptococcus agalactiae*; more rarely, toxic bacteria like *Escherichia coli*, *Staphylococcus aureus*, *Enterococcus faecalis*, or *Pseudomonas* are involved. The latter agents tend to present early in the postoperative period, with fever, deep tissue penetration, and abundant purulent drainage.

The classical approach to an infected device is the immediate removal of all the components and placement of a new implant after some delay for healing. The advantage of this solution is that the new implant is scheduled only when the infection has completely cleared. The main disadvantage is the scarring process that occurs inside the penis and hence penile retraction causing more difficult surgery later. In the last years salvage procedures have been proposed that allow

positioning of a new penile prosthesis at the same time as removal of the infected one [6, 7]. The immediate salvage procedure consists of removal of the infected prosthesis and wound irrigation with seven different antiseptic solutions including antibiotics (Kanamycin, Bacitracin, Vancomycin, and Gentamycin), hydrogen peroxide, and betadine. A new prosthesis is then easily placed, and the overall success rate is more than 80%. The delayed salvage procedure consists of placement of a drainage tube after removal of the prosthesis; antibiotic solution is irrigated through the drain and a new prosthesis is placed about 3 days later. Actually, no advantage has been demonstrated for the delayed salvage procedure over the immediate one. A few years ago, based on the evidence that some antibiotics are particularly indicated to protect silicone graft materials, the American Medical System Company developed a minocycline-rifampicin-coated penile prosthesis called Inhibizone [8]. Early experiences with this new device have demonstrated an evident reduction of overall infections, and no infections at all in primary implanted patients [9]. Another local approach to prevent device infection has been proposed by the Mentor Corporation Company and consists of applying a special hydrophilic coating that seems to inhibit bacterial adherence. The prosthesis is then soaked in antibiotics and the combined effect should reduce the risk of infection. In an initial experience, the Mentor Titan prosthesis has also demonstrated effectiveness in reducing the infection rate [10].

In some patients, the infection could be associated with important tissue necrosis: in this case, a salvage procedure is not advisable. Severe distal tissue necrosis is a dramatic event that may even require penile glansectomy or amputation (Figures 2 and 3) after prosthesis removal.

### Wrong sizing

Using an oversized cylinder can lead to an S-shaped deformity and buckling. As reported by Moncada et al. [11], an oversized cylinder is responsible for constant pain and exposes the patient to the risk of erosion. The solution in such cases is to replace the device. The opposite problem is undersizing, which will have the effect of a so-called "concorde deformity" (Figure 4) with excess mobility of the glans. In this case, cylinder removal is not necessary and it is possible to mobilize the glans with a subcoronal incision. When the cylinder tip becomes visible, nonabsorbable sutures can be used to hitch the glans and anchor it to the tunica albuginea, in order to completely cover the head of the prosthesis.

### Erosion

In the era of hydraulic inflatable devices, erosions are considered a rare complication. Distal erosion can be due to an excessive intraoperative corpora cavernosa dilatation, when oversized cylinders are used, in patients with loss of penile sensation (cold glans syndrome) and in patients unable to deflate the device when not in use. To manage distal erosion, it is necessary to remove the cylinder if oversized and replace it with a smaller prosthesis. The new device

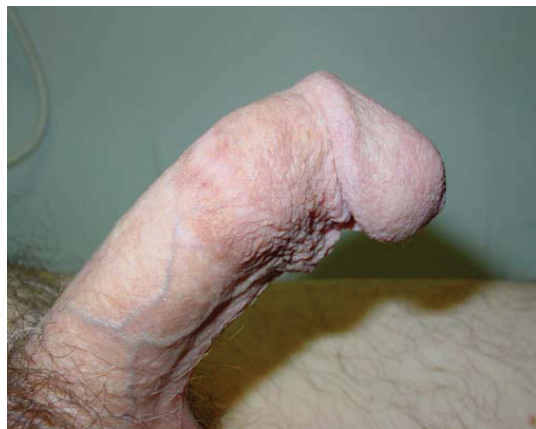

FIGURE 4: A "Concorde" effect due to undersized cylinders.

has to be placed far from the scar tissue, performing a new dilatation. Cavernosa reconstruction can be performed with albugineal surgery, as proposed by Mulcahy [12]. The cylinder can usually be readily resealed in an area of spongy tissue behind the back wall of the sheath containing the extruded cylinder. This is done by making a corporotomy over the cylinder laterally, about half the distance towards the penoscrotal junction, retracting the cylinder to the side, incising the back wall of the cylinder sheath, and dilating a new cavity behind this back wall up to the subglandular area. The cylinder can then be resealed in this new cavity and the back wall of the cylinder sheath will act as the outer covering of the cylinder. A second layer consisting of the outer wall of the cylinder sheath can also be closed to create a more secure barrier against the extrusion of parts. The corporotomy is closed with long-term adsorbable suture. The cylinder is now secured in its proper location by two tough layers comprising the back wall of the original sheath and the corporotomy closure. Cavernosa reconstruction can also be made using synthetic materials like dacron or Gore-Tex.

A peculiar kind of distal erosion is urethral erosion. A possible solution is to remove the cylinder and to position a suprapubic catheter to allow healing of the urethral perforation. A single-stage procedure has been described by Shaeer [13]: having mobilized the glans off the tip of the corpus cavernosum, the caverno-urethral fistula is disconnected and sealed by primary sutures. The perforation on the corpus cavernosum side is corrected by double breasting or by grafting. The prosthesis is then reimplanted.

Proximal erosion and cross-over erosion are usually intraoperative complications. MRI will confirm the diagnosis: the management consists of removal of the protruded cylinder. A cavernosa reconstruction with a dacron sock is necessary before inserting a new prosthesis.

#### *Mechanical failure*

Cylinders mechanical failure would involve loss of fluid due to breakage, bulging, or aneurysmatic dilatation. The only solution to manage such cases is to remove the broken device and replace it with a new penile prosthesis. The introduction

of new covering materials like Parylene has dramatically reduced the risk of cylinders bulging.

### **3.2. Pump complications**

Pump infections require the same management as described above for cylinders. Prevention of hematoma and swelling with closed-suction drains has been shown not to increase the infection rate and to promote an earlier recovery time. In a large series of 425 consecutive primary three-piece penile prosthesis implantations, there were a total of 14 (3.3%) infections and three hematomas (0.7%) during a mean follow-up of 18 months [14].

Pump or connecting tubes erosion is usually associated with infections. If the infection is not extensive and not associated with severe tissue necrosis, a salvage procedure can be performed locally and a new pump can be inserted. In cases of considerable loss of tissue, poor patient conditions, and fever, it is advisable to remove the prosthesis and delay the reimplant.

Pump migration or incorrect positioning is mainly due to insufficient closure of the scrotal space. If the pump is no longer useful because of its incorrect position, a new operation is required to fix it in the correct scrotal place.

### **3.3. Reservoir complications**

Reservoir complications are not frequent but include positioning of the reservoir over the fascia. Migration is a rare event and usually occurs when a too big space is created through the fascia to access the Retzius space. With a suprapubic incision, the reservoir can be replaced in the correct paravesical space.

A difficult or failed device deflation can be due to pseudocapsule formation around a partially emptied reservoir. To prevent capsule formation, it is usually sufficient to leave the reservoir half-filled for 24 hours after the operation. Early hospital testing of the prosthesis function is also advisable. When a pseudocapsule is present, surgical revision will be needed to access the Retzius space once more, to break the capsule, and to replace the reservoir. If the previous side is no longer available, it is best to replace the reservoir in the other paravesical space or, if necessary, in the peritoneum.

## **4. CONCLUSIONS**

Penile prosthesis implantation is a fascinating surgical technique that has gained an important role in the treatment of severe erectile dysfunction. The advent of new surgical tools and new infection-resistant materials has significantly reduced the risk of intra- and postoperative complications and the need for revision surgery. Various companies have also improved their mechanical systems in order to reduce the risk of failures, and their products are now very good as they may last lifelong. Nevertheless, surgical skill and a meticulous respect for sterility rules remain fundamental requirements to guarantee the success of a penile prosthesis implant.



## ACKNOWLEDGMENT

The authors wish to thank M. V. Pragnell, B. A., for English revision of the manuscript.

## REFERENCES

- [1] H. Sadeghi-Nejad, "Penile prosthesis surgery: a review of prosthetic devices and associated complications," *Journal of Sexual Medicine*, vol. 4, no. 2, pp. 296–309, 2007.
- [2] A. Minervini, D. J. Ralph, and J. P. Pryor, "Outcome of penile prosthesis implantation for treating erectile dysfunction: experience with 504 procedures," *BJU International*, vol. 97, no. 1, pp. 129–133, 2006.
- [3] K. Hatzimouratidis, N. Koliakos, I. Koutsogiannis, K. Moissidis, A. Giakoumelos, and D. Hatzichristou, "Removal of a detached head of the Brooks dilator from the corpora cavernosa during penile prosthesis implantation," *Journal of Sexual Medicine*, vol. 4, no. 4ii, pp. 1179–1181, 2007.
- [4] A. Natali, R. Olianias, and M. Fisch, "Penile implantation in Europe: successes and complications with 253 implants in Italy and Germany," *Journal of Sexual Medicine*, vol. 5, no. 6, pp. 1503–1512, 2008.
- [5] S. K. Wilson, C. C. Carson, M. A. Cleves, and J. R. Delk II, "Quantifying risk of penile prosthesis infection with elevated glycosylated hemoglobin," *The Journal of Urology*, vol. 159, no. 5, pp. 1537–1540, 1998.
- [6] J. J. Mulcahy, "Long-term experience with salvage of infected penile implants," *The Journal of Urology*, vol. 163, no. 2, pp. 481–482, 2000.
- [7] L. D. Knoll, "Penile prosthetic infection: management by delayed and immediate salvage techniques," *Urology*, vol. 52, no. 2, pp. 287–290, 1998.
- [8] G. Brock, D. Bochinski, and C. B. Mahoney, "InhibiZone treatment: the first antibiotic treatment impregnated into the tissue-contacting surface of an inflatable penile prosthesis," *The Journal of Urology*, vol. 165, p. A1047, 2001.
- [9] S. K. Wilson, J. R. Delk, and G. D. Henry, "Short-term follow-up for enhanced American medical systems 700 CX prosthesis," *The Journal of Urology*, vol. 167, supplement, p. 150, abstract 600, 2002.
- [10] C. E. Wolter and W. J. G. Hellstrom, "Early experience with the hydrophilic-coated three-piece IPP (Titan alpha-1 IPP)," *The Journal of Urology*, vol. 169, supplement, abstract 1333, 2003.
- [11] I. Moncada, C. Hernández, J. Jara, et al., "Buckling of cylinders may cause prolonged penile pain after prosthesis implantation: a case control study using magnetic resonance imaging of the penis," *The Journal of Urology*, vol. 160, no. 1, pp. 67–71, 1998.
- [12] J. J. Mulcahy, "Distal corporoplasty for lateral extrusion of penile prosthesis cylinders," *The Journal of Urology*, vol. 161, no. 1, pp. 193–195, 1999.
- [13] O. Shaeer, "Management of distal extrusion of penile prosthesis: partial disassembly and tip reinforcement by double breasting or grafting," *Journal of Sexual Medicine*, vol. 5, no. 5, pp. 1257–1262, 2008.
- [14] H. Sadeghi-Nejad, P. Ilbeigi, S. K. Wilson, et al., "Multi-institutional outcome study on the efficacy of closed-suction drainage of the scrotum in three-piece inflatable penile prosthesis surgery," *International Journal of Impotence Research*, vol. 17, no. 6, pp. 535–538, 2005.



## Review Article

# Organ-Preserving Surgery for Penile Carcinoma

Francisco E. Martins,<sup>1</sup> Raul N. Rodrigues,<sup>1</sup> and Tomé M. Lopes<sup>1,2</sup>

<sup>1</sup> Departamento de Urologia, Centro Hospitalar Lisboa Norte, Hospital de Santa Maria, Universidade de Lisboa, Avenida Professor Egas Moniz, 1649-035 Lisboa, Portugal

<sup>2</sup> Serviço de Urologia do Centro Hospitalar Lisboa Norte, Hospital de Santa Maria, Avenida Professor Egas Moniz, 1649-035 Lisboa, Portugal

Correspondence should be addressed to Francisco E. Martins, faemartins@mai.com

Received 7 May 2008; Accepted 26 July 2008

Recommended by Miroslav L. Djordjevic

**Introduction.** Penile carcinoma has traditionally been treated by either surgical amputation or radical radiotherapy, both associated with devastating anatomical, functional, and psychological impact on the patient's life. Innovative surgical techniques have focused on penile preservation in well-selected patients to minimize physical disfigurement and consequently maximize quality of life. The objective of this article is to define the current status of these organ-preserving surgical options for penile carcinoma. **Materials and Methods.** An extensive review of the Pubmed literature was performed to find articles discussing only reconstructive surgery which have contributed significantly to change traditional, frequently mutilating treatments, to develop less disfiguring surgery, and to improve patients' quality of life over the last two decades. **Results.** Several articles were included in this analysis in which a major contribution to the change in therapy was thought to have occurred and was documented as beneficial. Some articles reported novel techniques of less-mutilating surgery involving different forms of glans reconstruction with the use of flaps or grafts. The issue of safe surgical margins was also addressed. **Conclusion.** The development of less-disfiguring techniques allowing phallus preservation has reduced the negative impact on functional and cosmetic outcomes of amputation without sacrificing oncological objectives in appropriately selected patients based on stage, grade, and location of the tumour. Until more prospective studies are available and solid evidence is documented, organ preservation should be offered with caution.

Copyright © 2008 Francisco E. Martins et al. This is an open access article distributed under the Creative Commons Attribution License, which permits unrestricted use, distribution, and reproduction in any medium, provided the original work is properly cited.

## 1. INTRODUCTION

In the industrialized world, particularly in Europe and in the USA, penile carcinoma is an uncommon malignancy with an incidence of less than 1 per 100 000 of the male adult population. However, its incidence may be as high as 19 per 100 000 in parts of Asia, South America, Africa and may even reach 50 per 100 000 males in parts of north-eastern Brazilian states [1, 2]. This different worldwide distribution varies with age, circumcision, and hygiene patterns.

Historically, the majority (90%) are primary carcinomas, of which 95% are squamous cell carcinomas, involving the glans, prepuce, or both in over 78% of the cases. The management of penile carcinoma, particularly its invasive form, has changed little over the decades. Available treatments include surgical amputation and penis-preserving treatments, either surgical (circumcision, laser ablation, Mohs micrographic surgery, glansectomy associated with

various forms of reconstruction) or nonsurgical (radiotherapy, immunotherapy, chemotherapy). Surgical amputation is the oldest of all modalities [3]. It has resulted in local control rates greater than 90% of the primary tumor and, therefore, remains the oncological "gold standard" for all stages [4–6]. Although the radical surgical approach provides excellent local control, it is often mutilating and is associated with urinary and sexual dysfunction as well as dramatic psychological morbidity [7]. These negative factors have led to a significant change in the approach to the primary penile lesion and to the development of several surgical organ-preserving techniques. Nowadays, the definitive treatment of penile carcinoma is stage-dependent, with the penile-preserving options especially reserved for low-grade and low-stage tumors. These techniques aim to remove as little of the functional anatomy as possible, without compromising local oncological radicality [8]. However, data from retrospective studies suggest a statistically higher local recurrence

rate following penis-preserving treatments compared with radical surgery. Most recurrences are surgically salvageable and overall mortality is comparable to primary amputation [9]. The objective of this article is to give an overview of the current status and the role of these organ-preserving surgical options for penile carcinoma and state their limitations.

## 2. INDICATIONS AND GOALS OF ORGAN PRESERVATION

Some retrospective studies have reported good cosmetic and functional outcomes with conservative treatment options and an overall organ preservation of 60% [9]. Because about 80% of penile carcinomas occur distally, involving the glans and/or prepuce, they are potentially amenable to organ-preserving surgery [10, 11].

It is generally accepted that patients with penile carcinomas associated with favourable histology (stages Tis, Ta, T1; grades 1 and 2) are at low risk for local progression and/or distant metastatic spread (Table 1). These patients are also the best candidates for penile-/glans-preserving treatment options [2]. Recently, however, some series have suggested that these indications can be expanded in order to include T2 and even some distal T3 tumors as well as recurrences after radiotherapy [8]. Nonetheless, until more rigorous scientific evidence is available, organ-preserving strategies should be reserved to well-selected patients with limited low-grade, low-stage disease [11, 12]. A traditional 2 cm excision margin has been challenged as unnecessary for patients undergoing partial penectomy for squamous cell carcinoma. Conservative techniques involving surgical margins of only less than 10 mm appear to offer excellent oncological control [13, 14].

The goals of penile-preserving treatments are to maintain penile/glans sensation and to maximize penile shaft length where possible. However, cosmetic and functional results should not compromise long-term oncological outcomes.

## 3. METHODS OF SURGICAL ABLATION FOR ORGAN PRESERVATION

A variety of penile-preserving therapeutic approaches have been used for low-grade and low-stage penile carcinoma, including topical treatments (5-fluorouracil or imiquimod cream for Tis only), radiotherapy, Mohs micrographic surgery, laser ablation or excision, and conservative excision strategies (Table 2). This article will focus exclusively on surgical strategies to achieve organ preservation. Nonsurgical options are beyond the scope of this review.

### 3.1. Mohs micrographic surgery

Mohs micrographic surgery (MMS) refers to a surgical technique of excising accessible tumors under microscopic control [15]. The tumor is excised in layers and the undersurface of each layer is examined microscopically by systematic frozen sections in multiple sessions. This excision is continued until the undersurface of the excised tissue is negative, at which point another section of tissue is

TABLE 1: TNM classification of penile carcinoma (1997/2002).

T-Primary tumor
TX Primary tumor cannot be assessed
T0 No evidence of primary tumor
Tis Carcinoma <i>in situ</i>
Ta Non-invasive verrucous carcinoma
T1 Tumor invades subepithelial connective tissue
T2 Tumor invades corpus spongiosum or cavernosum
T3 Tumor invades urethra or prostate
T4 Tumor invades other adjacent structures
N-Regional lymph nodes
NX Regional lymph nodes cannot be assessed
N0 No evidence of lymph node metastasis
N1 Metastasis in a single inguinal lymph node
N2 Metastasis in multiple or bilateral superficial lymph nodes
N3 Metastasis in deep inguinal or pelvic lymph nodes, unilateral or bilateral
M-Distant metastasis
MX Distant metastases cannot be assessed
M0 No evidence of distant metastases
M1 Distant metastases

removed to ensure a clear resection margin. This sequential microscopic guidance offers increased precision and control of the negative surgical margin, while maximizing safe organ preservation. MMS is most commonly used for skin tumors but the accessibility of penile carcinomas (most commonly on the glans) makes it a suitable candidate for such a procedure. In Mohs' 50-year experience with 35 cases, the success rate was stage-dependent. A percentage of 86% of stage T1 and 82% of stage T2 cases were tumor-free compared to none of stage T3 at a followup of 5 years.

This technique is attractive because it allows reassurance of local complete excision and preservation of local penile anatomy and function. However, because local failure rate is apparently higher (32%) than amputation, it should be reserved to patients with penile carcinoma *in situ* or with small, distal, superficially invasive tumors. Further reports with this technique are necessary to allow comparison and reproducibility of outcomes in order to encourage its more widespread use. Complications may include meatal stenosis and glans disfigurement.

### 3.2. Laser ablation or excision

Penile laser surgery has been used since the 1980s. The four types of lasers used are carbon dioxide, argon, neodymium yttrium aluminium garnet (Nd:YAG), and potassium titanyl phosphate (KTP) lasers, the CO<sub>2</sub> and Nd:YAG modes being the most commonly used in current practice [16, 17]. CO<sub>2</sub> laser has a very low penetration power (only 0.1 mm) and is, therefore, unsuitable for most tumors, resulting in recurrence rates of up to 50% [18]. Nd:YAG has a much

TABLE 2: Organ-preserving therapeutic strategies for penile carcinoma.

A nonsurgical					
(1)	Topical treatments	5-Fluorocil solution Imiquimol cream			
(2)	Radiotherapy	Plesiotherapy Interstitial brachytherapy External beam radiotherapy			
(3)	Cryosurgery				
(4)	Chemotherapy				
(5)	Immunotherapy				
B Surgical					
(1)	Laser ablation or excision	CO <sub>2</sub> Nd:YAG KTP			
(2)	Mohs micrographic surgery				
Circumcision					
(3)	Conservative surgery	Glans-preserving techniques	Partial glansectomy	with primary closure with graft reconstruction of the glans	Split-thickness skin grafts Full-thickness skin grafts Buccal mucosa
		Glans-removing techniques	Total Glansectomy	with split-thickness skin grafts with distal corporectomy and reconstruction	

higher penetration power of about 6 mm due to its rather short wavelength ( $\lambda = 1.06 \mu\text{m}$ , i.e., 10 times less than CO<sub>2</sub>), resulting in protein denaturation at such depth. Overall recurrence rates after laser ablation are also stage-dependent, averaging 7.7% for Tis tumors, and as high as 25% for T1 lesions [16]. Other authors have reported good outcomes after Nd:YAG laser for T1 tumors with excellent cosmetic and functional results and high satisfaction rates. Recurrences were noted in 6.9% of the patients, which is comparable to recurrence rates after partial amputation (0–8%) [19].

The available data to date demonstrate that laser surgery is feasible and may achieve results comparable to those of traditional amputative surgery, particularly in highly selected patients and in conjunction with frozen-section biopsies. Additionally, it has significant anatomical, cosmetic, and functional advantages over traditional amputation. However, as the local recurrence is higher, a close surveillance is mandatory for early detection. Therefore, patient selection is extremely important. Because in laser surgery the depth of tumor invasion is crucial, only those invading less than 6 mm into tissues are suitable for this treatment modality.

### 3.3. Conservative surgery

#### Circumcision

It is the most simple and common surgical procedure in the management of penile carcinoma. The majority of men

with penile carcinoma are uncircumcised. It is indicated for symptomatic treatment of painful or haemorrhagic tumors as well as for acquired phimosis secondary to preputial tumors. It is always recommended before radiotherapy as it allows better targeting and definition of the tumor, simultaneously preventing preputial radiotherapy-related adverse reactions, and, above all, it improves local oncological surveillance. Noteworthy, circumcision alone is a sufficient primary curative treatment for small low-stage (Tis, Ta, T1) and low-grade (grades 1 and 2) disease limited to the distal prepuce [20]. If the tumor is more proximal and close to the coronal sulcus, the circumcision margin will need to be extended proximally to the penile shaft to ensure adequate oncological resection, as recurrence rates may be as high as 50% [21]. Therefore, case selection is critical to reduce local recurrence rates.

#### Glansectomy

It can be done either partial or total, has recently been introduced for the local excision of distal tumors on the glans and prepuce [8, 12, 22, 23]. Frozen sections from the cavernosal bed and urethral stump should be carried out during the procedure to ensure negative surgical margins followed by an end-shaft urethrostomy. Glansectomy is usually combined with grafting procedures to create a neoglans. Basically, there are 2 forms of glansectomy: (i) partial glansectomy, which removes the portion of the glans affected

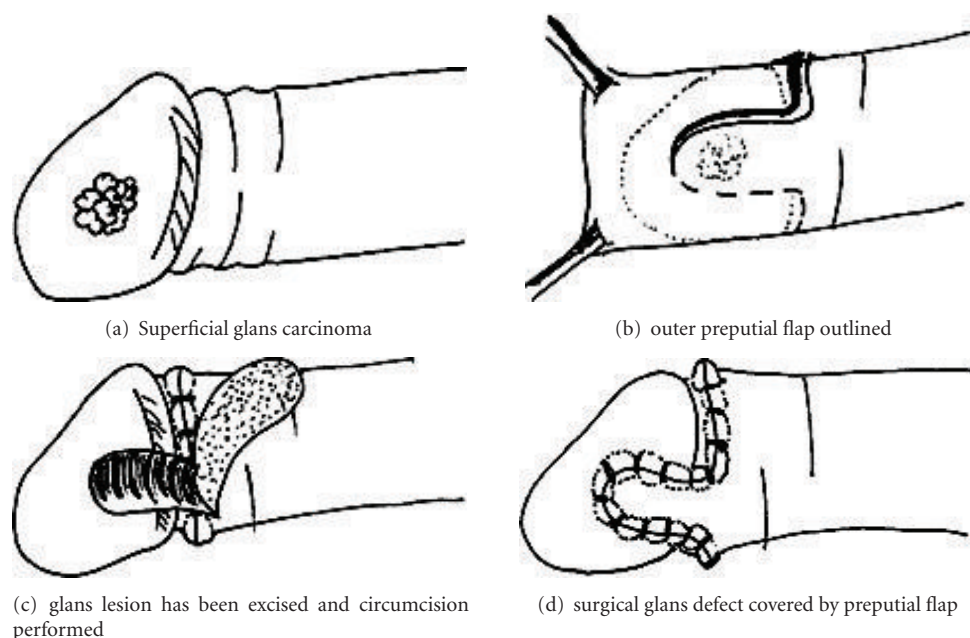


FIGURE 1: Outer preputial full-thickness skin flap as described by Ubrig et al. (2001) to cover surgical glans defects.

by the tumor, leaving behind remaining glanular epithelium with malignant potential, and (ii) total glansectomy, which removes all the glans tissue, thus preventing 'de novo' tumor growth.

Traditionally, amputative surgery has been based on the assumption that a 2 cm resection margin is required to achieve local oncological clearance [24]. However, the scientific value of a 2 cm margin has not been supported uniformly and several authors have recently questioned it [13, 14, 25], concluding in their studies that a 2 cm surgical margin was not only unnecessary but also overtreatment in many cases. About 80% of the penile carcinomas arise distally, which render them potential candidates for penile-preserving surgery. This type of surgery includes an extirpative component leaving in some cases a simple defect amenable to primary closure. If the defect is larger and primary closure is not possible or safe, various techniques have been suggested to cover or reconstruct the area [8, 12, 22, 23, 26–33]. Ubrig described a simple technique in 2001 in which an outer preputial skin flap was used to cover the glans defect if primary closure was impossible. However, the tumor should not be too deep (Figure 1). Pietrzak et al. have suggested the use of a full-thickness flap of penile skin or extragenital (lateral aspect of the thigh) split-thickness skin graft to reconstruct the glans associated with partial or total glans removal. In cases of invasion of tunica albuginea by distal tumors, distal corporectomy was included [8]. In glans-preserving procedures, partial glansectomy with primary glans closure was essentially an excisional biopsy of a small distal tumor. Larger lesions necessitated partial glansectomy followed by glans reconstruction which was performed with the use of split-thickness or full-thickness grafting. In glans-removing procedures, total glansectomy was performed followed by either split-thickness skin graft

reconstruction or reconstruction of cavernosal tips and grafting, if a distal corporectomy was required. In some cases, a penile-lengthening procedure was added to the reconstruction to maintain as much cavernosal tissue as possible. In all forms of penile-preserving surgery, a frozen biopsy of the surgical bed is mandatory to confirm tumor clearance (negative margins). A subtotal glans excision without grafting has been described as a simple and cosmetically attractive alternative to other forms of conservative surgery for penile carcinoma [23]. This procedure involves excision of the tumor and glans between 2 incision lines leaving the urethra intact. The residual glans and urethral meatus is sutured down to the distal corpora and the penile skin is advanced to be sutured to the distal glans at the level of spatulated urethra. A urethral catheter is left indwelling for 24 hours. No skin or any other source of grafting is required and the patient is discharged the next day. Apparently, patients maintain their voiding characteristics unchanged (e.g., no spraying) and avoid graft-related complications (e.g., donor-site morbidity, graft failure, and infection). However, this technique should be avoided in patients with penile tumors very close to (less than 5 mm) or invading the urethral meatus. Other forms of glansectomy without glans reconstruction have also been described [22, 33]. These usually create a new urethral stoma and attach the residual urethra to the foreskin with acceptable cosmetic and functional outcomes. However, some authors have reported that these procedures only partially resolve aesthetic and psychological problems associated with surgery. Also, they do not resolve the question of penile sensation, and consequently ejaculation and orgasm, as well as penile length and appearance. To overcome these pitfalls, they suggested a technique of glans reconstruction using the distal urethra [27].



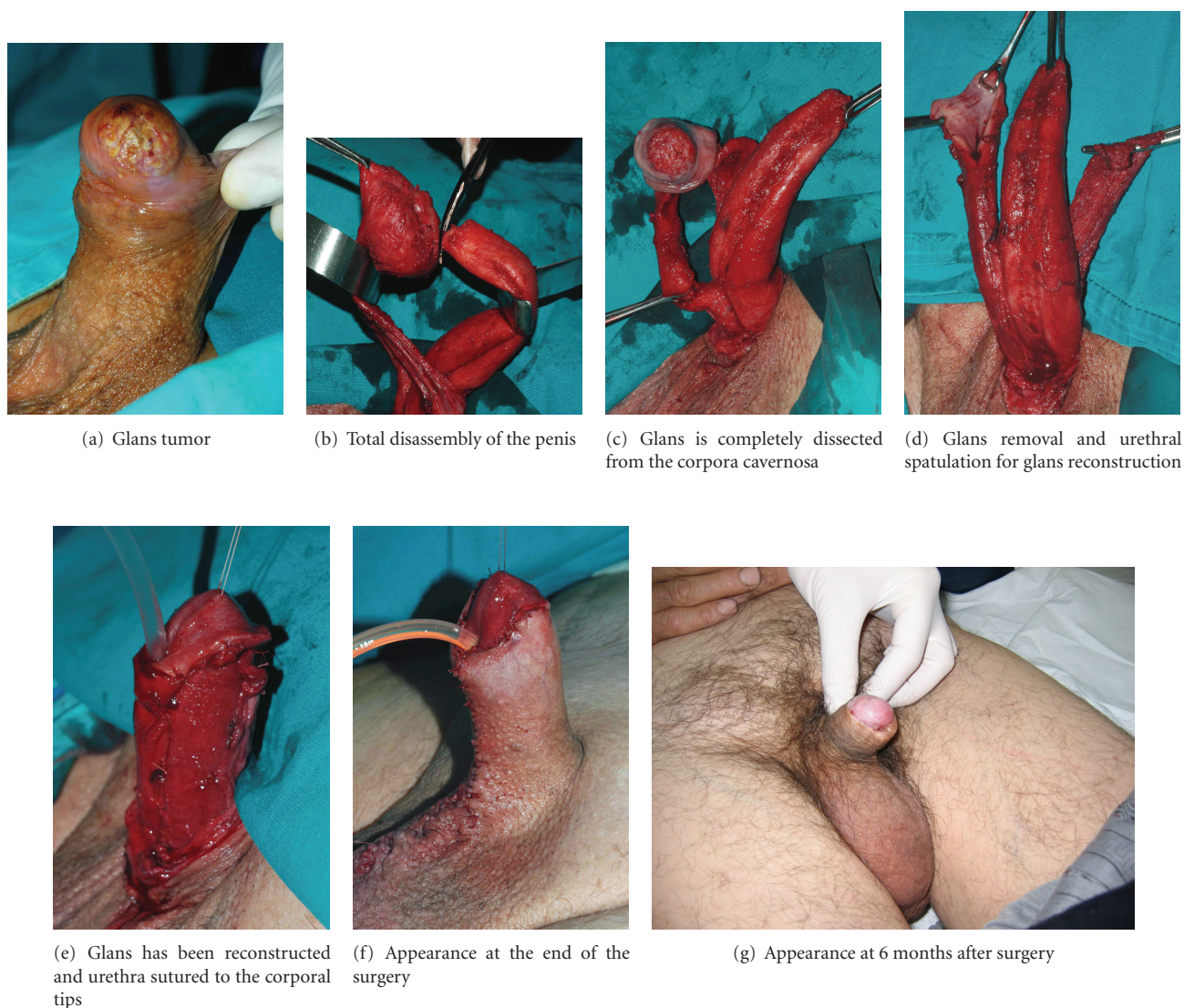


FIGURE 2: Penile disassembly for the conservative treatment of penile carcinoma.

More recently, an alternative approach to organ-sparing surgery for penile carcinoma based on a penile disassembly technique has been utilized by Djordjevic et al. with good results [28]. Penile disassembly was first described by Perovic in the early 1990s as a surgical technique to treat most congenital and acquired penile deformities in paediatric and adult male populations, such as hypospadias, extrophy-epispadias complex, penile curvature, and Peyronie's disease. This technique has been employed in low-grade and low-stage tumors, mostly T1G1-2 lesions. The procedure begins with urethral mobilization together with Bucks fascia (Figure 2). Dorsally, the neurovascular bundle is dissected off by blunt and sharp manoeuvres. Glans with urethra ventrally and neurovascular bundle dorsally are completely separated from the corpora cavernosa. The neurovascular bundle is divided 2 cm proximal to the glans cap. The glans is removed after division of the urethra. Biopsies of the surgical margins are performed routinely to confirm oncological

clearance. The urethra is spatulated 4 cm in length and sutured to the corpora cavernosa. The spatulated urethra is used for neoglans construction. The corpora cavernosa are fixed to the skin proximally using U-shaped sutures to avoid penile retraction. Reconstruction of the penile skin is performed as in circumcision. The authors believe that penile disassembly represents a radical but very useful approach to organ-preserving surgery in penile carcinoma with excellent cosmetic, functional, and oncological outcomes.

Some authors have long reported on a surgical strategy for refashioning of phallus stumps to make them longer and more natural in appearance. Where this was not feasible, a neophallus was performed. Perineal urethrostomy was avoided completely [29, 33]. This was even considered to reflect a failure of surgical skill [29].

Total glansectomy for penile tumors was first described by Austoni in 1996 [34]. Since that time, enormous efforts have been made in the development of more refined and

appealing surgical alternatives to improve both function and cosmesis, as well as local oncological control. Early results have been encouraging but more reproducible studies and longer followup are still required to consider organ preservation as the gold standard treatment of penile carcinoma. Until then, it should be used with caution.

#### 4. CONCLUSION

Historically, amputative surgery and radical radiotherapy were the only options to treat penile carcinoma. Over the last two decades, several innovative techniques have been described and proposed for organ-preserving surgery in penile carcinoma. These should avoid complications and maximize both cosmetic and functional outcomes, simultaneously not compromising local oncological long-term control. At present, definitive management of penile carcinoma remains stage-dependent. Penile amputation has been challenged by more recent conservative surgical techniques and should perhaps be considered overtreatment in low-stage disease. Glansectomy appears to offer good local control rates. Glans reconstruction with or without grafting procedures have offered excellent cosmetic results where applicable. However, until further studies are available and sufficient evidence reproducible in common day practice, and until the surgical margin issue is safely addressed in prospective studies, penile amputation (partial or total) with all its attendant anatomical, psychosocial, and sexual disabilities should still be regarded as the gold standard treatment for all stages of penile carcinoma, even for Tis, Ta and T1 tumors.

#### REFERENCES

- [1] F. R. Romero, K. R. Romero, M. A. Mattos, C. R. Garcia, R. C. Fernandes, and M. D. Perez, "Sexual function after partial penectomy for penile cancer," *Urology*, vol. 66, no. 6, pp. 1292–1295, 2005.
- [2] E. F. Solsona, S. Algaba, G. Horenblas, G. Pizzocaro, and T. Windahl, "EAU guidelines on penile cancer," *European Urology*, vol. 46, no. 1, pp. 1–8, 2004.
- [3] L. Lewis, "Young's radical operation for the cure of cancer of the penis: a report of 34 cases," *The Journal of Urology*, vol. 26, p. 295, 1931.
- [4] W. S. McDougal, F. K. Kirschner Jr., R. H. Edwards, and L. T. Killion, "Treatment of carcinoma of the penis: the case for primary lymphadenectomy," *The Journal of Urology*, vol. 136, no. 1, pp. 38–41, 1986.
- [5] S. Horenblas, H. van Tinteren, J. F. M. Delemarre, T. A. Boon, L. M. Moonen, and V. Lustig, "Squamous cell carcinoma of the penis. II. Treatment of the primary tumor," *The Journal of Urology*, vol. 147, no. 6, pp. 1533–1538, 1992.
- [6] G. Pizzocaro, L. Piva, G. Bandieramonte, and S. Tana, "Up-to-date management of carcinoma of the penis," *European Urology*, vol. 32, no. 1, pp. 5–15, 1997.
- [7] S. Opjordsmoen and S. D. Fossa, "Quality of life in patients treated for penile cancer. A follow-up study," *British Journal of Urology*, vol. 74, no. 5, pp. 652–657, 1994.
- [8] P. Pietrzak, C. Corbishley, and N. Watkin, "Organ-sparing surgery for invasive penile cancer: early follow-up data," *BJU International*, vol. 94, no. 9, pp. 1253–1257, 2004.
- [9] D. Cotsadze, B. Matveev, B. Zak, and V. Mamaladze, "Is conservative organ-sparing treatment of penile carcinoma justified?" *European Urology*, vol. 38, no. 3, pp. 306–312, 2000.
- [10] R. Sarin, A. R. Norman, G. G. Steel, and A. Horwich, "Treatment results and prognostic factors in 101 men treated for squamous carcinoma of the penis," *International Journal of Radiation Oncology, Biology, Physics*, vol. 38, no. 4, pp. 713–722, 1997.
- [11] N. K. Bissada, H. H. Yakout, W. E. Fahmy, et al., "Multi-institutional long-term experience with conservative surgery for invasive penile carcinoma," *The Journal of Urology*, vol. 169, no. 2, pp. 500–502, 2003.
- [12] J. W. Davis, P. F. Schellhammer, and S. M. Schlossberg, "Conservative surgical therapy for penile and urethral carcinoma," *Urology*, vol. 53, no. 2, pp. 386–392, 1999.
- [13] A. Agarwal, D. Pai, N. Ananthakrishnan, S. R. Smile, and C. Ratnakar, "The histological extent of the local spread of carcinoma of the penis and its therapeutic implications," *BJU International*, vol. 85, no. 3, pp. 299–301, 2000.
- [14] S. Minhas, O. Kayes, P. Hegarty, P. Kumer, A. Freeman, and D. Ralph, "What surgical resection margins are required to achieve oncological control in men with primary penile cancer?" *BJU International*, vol. 96, no. 7, pp. 1040–1043, 2005.
- [15] F. E. Mohs, S. N. Snow, and P. O. Larson, "Mohs micrographic surgery for penile tumors," *The Urologic Clinics of North America*, vol. 19, no. 2, pp. 291–304, 1992.
- [16] T. R. Malloy, A. J. Wein, and V. L. Carpinello, "Carcinoma of penis treated with neodymium YAG laser," *Urology*, vol. 31, no. 1, pp. 26–29, 1988.
- [17] A. C. von Eschenbach, D. E. Johnson, K. I. Wishnow, R. J. Babaian, and D. Tennay, "Results of laser therapy for carcinoma of the penis: organ preservation," *Progress in Clinical and Biological Research*, vol. 370, pp. 407–412, 1991.
- [18] B. P. J. van Bezooijen, S. Horenblas, W. Meinhardt, and D. W. W. Newling, "Laser therapy for carcinoma in situ of the penis," *The Journal of Urology*, vol. 166, no. 5, pp. 1670–1671, 2001.
- [19] D. Frimberger, E. Hungerhuber, D. Zaak, R. Waidelich, A. Hofstetter, and P. Schneede, "Penile carcinoma. Is Nd:YAG laser therapy radical enough?" *The Journal of Urology*, vol. 168, no. 6, pp. 2418–2421, 2002.
- [20] N. K. Bissada, "Conservative extirpative treatment of cancer of the penis," *The Urologic Clinics of North America*, vol. 19, no. 2, pp. 283–290, 1992.
- [21] A. S. Narayana, L. E. Ohney, S. A. Loening, G. W. Weimar, and D. A. Culp, "Carcinoma of the penis: analysis of 219 cases," *Cancer*, vol. 49, no. 10, pp. 2185–2191, 1982.
- [22] D. G. Hatzichristou, A. Apostolidis, V. Tzortzis, K. Hatzimouratidis, E. Ioannides, and K. Yannakoyorgos, "Glansectomy: an alternative surgical treatment for Buschke-Löwenstein tumors of the penis," *Urology*, vol. 57, no. 5, pp. 966–999, 2001.
- [23] C. T. Brown, S. Minhas, and D. J. Ralph, "Conservative surgery for penile cancer: subtotal glans excision without grafting," *BJU International*, vol. 96, no. 6, pp. 911–912, 2005.
- [24] P. F. Schellhammer, G. H. Jordan, and S. M. Schlossberg, "Tumors of the penis," in *Campbell's Urology*, P. C. Walsh, A. B. Retik, T. A. Stamey, and E. D. Vaughn, Eds., vol. II, chapter 31 of , pp. 1264–1298, WB Saunders, Philadelphia, Pa, USA, 6th edition, 1992.
- [25] M. Hoffman, A. Renshwa, K. Loughlin, et al., "Squamous cell carcinoma of the penis and microscopic pathologic margins.

- How much margin is needed for local cure?" *Cancer*, vol. 85, pp. 299–300, 1999.
- [26] B. Ubrig, M. Waldner, M. Fallahi, and S. Roth, "Preputial flap for primary closure after excision of tumors on the glans penis," *Urology*, vol. 58, no. 2, pp. 274–276, 2001.
- [27] G. Gulino, F. Sasso, R. Falabella, and P. F. Bassi, "Distal urethral reconstruction of the glans for penile carcinoma: results of a novel technique at 1-year of follow-up," *The Journal of Urology*, vol. 178, no. 3, pp. 941–944, 2007.
- [28] M. Djordjevic, S. Perovic, and F. E. Martins, "Penile disassembly for the conservative treatment of penile carcinoma," in preparation.
- [29] S. Parkash, N. Ananthakrishnan, and P. Roy, "Refashioning of phallus stumps and phalloplasty in the treatment of carcinoma of the penis," *British Journal of Surgery*, vol. 73, no. 11, pp. 902–905, 1986.
- [30] O. N. Mazza and G. M. J. Cheliz, "Glanuloplasty with scrotal flap for partial penectomy," *The Journal of Urology*, vol. 166, no. 3, pp. 887–889, 2001.
- [31] M. Djordjevic, S. Perovic, and G. Korac, "Penile carcinoma: organ-sparing surgery," *Urology*, vol. 68, supplement 1, p. 216, 2006, abstr. V-05.11.
- [32] G. Venkov, "Organ-sparing surgery for invasive penile cancer with use of buccal mucosal graft for resurfacing after excision of tumors on the glans penis: early follow-up data," *Urology*, vol. 70, no. 3, supplement 1, p. 288, 2003, abstr. POS-03.52.
- [33] M. L. Greenberger and B. A. Lowe, "Penile stump advancement as an alternative to perineal urethrostomy after penile amputation," *The Journal of Urology*, vol. 161, no. 3, pp. 893–894, 1999.
- [34] E. Austoni, O. Fenice, Y. Kartalas Goumas, F. Colombo, F. Mantovani, and E. Pisani, "New trends in the surgical treatment of penile carcinoma," *Archivio Italiano di Urologia, Andrologia*, vol. 68, no. 3, pp. 163–168, 1996 (Italian).



## Clinical Study

# Reconstructive Surgery for Severe Penile Inadequacy: Phalloplasty with a Free Radial Forearm Flap or a Pedicled Anterolateral Thigh Flap

N. Lumen,<sup>1</sup> S. Monstrey,<sup>2</sup> P. Ceulemans,<sup>2</sup> E. van Laecke,<sup>1</sup> and P. Hoebeke<sup>1</sup>

<sup>1</sup> Department of Paediatric Urology and Urogenital Reconstruction, Ghent University Hospital, De Pintelaan 185, B-9000 Gent, Belgium

<sup>2</sup> Department of Plastic, Reconstructive and Aesthetic Surgery, Ghent University Hospital, De Pintelaan 185, B-9000 Gent, Belgium

Correspondence should be addressed to N. Lumen, lumennicolaas@hotmail.com

Received 19 April 2008; Accepted 6 July 2008

Recommended by Miroslav L. Djordjevic

**Objectives.** Severe penile inadequacy in adolescents is rare. Phallic reconstruction to treat this devastating condition is a major challenge to the reconstructive surgeon. Phallic reconstruction using the free radial forearm flap (RFF) or the pedicled anterolateral thigh flap (ALTF) has been routinely used in female-to-male transsexuals. Recently we started to use these techniques in the treatment of severe penile inadequacy. **Methods.** Eleven males (age 15 to 42 years) were treated with a phallic reconstruction. The RFF is our method of choice; the ALTF is an alternative when a free flap is contraindicated or less desired by the patient. The RFF was used in 7 patients, the ALTF in 4 patients. Mean followup was 25 months (range: 4–49 months). Aesthetic and functional results were evaluated. **Results.** There were no complications related to the flap. Aesthetic results were judged as “good” in 9 patients and “moderate” in 2 patients. Sensitivity in the RFF was superior compared to the ALTF. Four patients developed urinary complications (stricture and/or fistula). Six patients underwent erectile implant surgery. In 2 patients the erectile implant had to be removed due to infection or erosion. **Conclusion.** In case of severe penile inadequacy due to whatever condition, a phalloplasty is the preferred treatment nowadays. The free radial forearm flap is still the method of choice. The anterolateral thigh flap can be a good alternative, especially when free flaps are contraindicated, but sensitivity is markedly inferior in these flaps.

Copyright © 2008 N. Lumen et al. This is an open access article distributed under the Creative Commons Attribution License, which permits unrestricted use, distribution, and reproduction in any medium, provided the original work is properly cited.

## 1. INTRODUCTION

The biological male without penis or with severe penile inadequacy remains a major challenge to the reconstructive urological surgeon. A clear definition of severe penile inadequacy has not yet been established but we consider it as an insufficient penile length and function to obtain successful sexual intercourse. This implies that puberty must be finished and that the patient must be sexually active.

Next to congenital conditions, which resulted in inadequate penile development, traumatic events and medically indicated penile amputations, as well as failed reconstructions of congenital anomalies are also the main reasons for severe penile inadequacy.

An absent or inadequate penis is a devastating condition with significant psychological and physical impact. Although uncommon, it is a challenging condition to treat.

The different cosmetic and functional requirements for penile reconstruction are well known as follows. (i) The aesthetic appearance of the neophallus must be as normal as possible. (ii) The penile shaft must contain a urethra to allow voiding in a standing position and with a normal stream. (iii) The penile shaft must allow the implantation of a penile stiffener in order to allow intercourse. (iv) Morbidity of the donor area must be minimal with an easily concealed scar. Although phallic reconstruction is a complex surgical procedure, it is nowadays possible to fulfil most of the above-mentioned requirements using the new techniques developed in plastic and reconstructive surgery.

A large experience has been obtained at our centre with more than 350 female-to-male transsexuals who underwent a penile reconstruction. In this paper, our experience in phalloplasty using the free radial forearm free flap (RFF) or



TABLE 1: Patients' characteristics.

Patient	indications	type of phalloplasty	age (years)
1	shrivelled penis—infected penile stiffener	anterlateral thigh flap	42
2	shrivelled penis—bladder exstrophy	radial forearm free flap	23
3	shrivelled penis—bladder exstrophy	radial forearm free flap	16
4	penile amputation—epitheloid sarcoma	radial forearm free flap	15
5	crippled penis—hypospadias	radial forearm free flap	20
6	shrivelled penis—bladder exstrophy	radial forearm free flap	15
7	penile necrosis—traffic accident	radial forearm free flap	32
8	shrivelled penis—cloacal exstrophy	anterlateral thigh flap	16
9	shrivelled penis—cloacal exstrophy	anterlateral thigh flap	16
10	micropenis—partial androgen insensitivity syndrome	radial forearm free flap	30
11	penile necrosis—embolisation for priapism	anterlateral thigh flap	38

the pedicled anterolateral thigh flap (ALTF) is described for patients with severe penile inadequacy.

## 2. MATERIAL AND METHODS

A cohort of 11 patients (age: 15–42 years) who underwent phalloplasty at our institution was retrospectively analyzed. Median followup was 25 months (range: 4–49 months). All of them lost most of their functional penile tissues due to different conditions (Table 1). Emptying of the bladder was done through a urethral opening in 6 patients and by catheterisation through an appendico-vesicostomy in 5 patients. Two of these patients requested a urethral reconstruction for ejaculation, the other 3 preferred to keep their ejaculatory opening at the ventral aspect of the scrotum. All of the patients received psychological support and were given the opportunity to talk with previously operated transsexuals. Our method of choice for penile reconstruction is the RFF. One patient refused an RFF because he wanted to avoid a scar on the forearm and, therefore, chose in favour an ALTF. Three patients were not a good candidate for a free flap: two patients had a micropenis due to cloacal exstrophy in which previous corrective and reconstructive surgeries had altered the pelvic anatomy and vasculature. One patient underwent penile amputation because of penile necrosis after persistent priapism. This patient was treated first with an unsuccessful cavernosal-femoral shunt and later embolisation of the pudendal artery. In this case, vascular anatomy was uncertain as well and a free flap was contraindicated. Thus, seven patients were treated with the RFF and 4 patients with an ALTF.

### 2.1. Surgical technique

Two operative teams are working simultaneously: the urological team (P. Hoebeke and N. Lumen) is preparing the acceptor area, while the flap is harvested by the plastic surgeons (S. Monstrey and P. Ceulemans). Depending on the underlying condition, any useful penile and cavernosal tissue is preserved in order to be incorporated at the basis of the phallus (Figure 1). The urethral stump, if available,

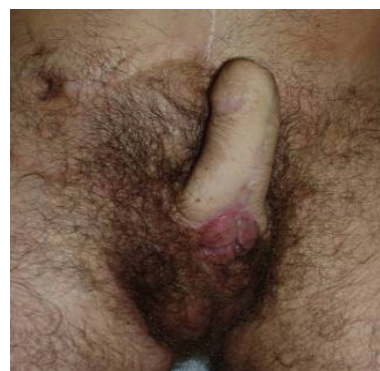

FIGURE 1: Incorporation of residual penile tissue at the base of the phallus.

is prepared for connection with the phallic urethra and, if available, a dorsal penile nerve is identified.

#### 2.1.1. Free radial forearm flap (Figure 2)

This flap is harvested from the forearm and shaped to a phallus using a tube-in-a-tube technique while being attached to the forearm by its vascular pedicle. A small skin flap and skin graft are used to create a corona and a sulcus to imitate a circumcised glans of the penis. The free flap is then transferred to the pubic area and after performing the urethral anastomosis, the radial artery is microsurgically connected end-to-side to the common femoral artery. The venous anastomosis is performed under microscopic magnification between the cephalic vein and the greater saphenous vein. One forearm nerve (N.cutaneus antebrachi) is connected to the ilioinguinal nerve for protective sensation and the other nerve is anastomosed to the dorsal penile nerve for erogenous sensation.

#### 2.1.2. Anterolateral thigh flap (Figure 3)

This flap is a pedicled perforator flap supplied by the descending branch of lateral femoral circumflex artery. The perforator vessels are identified using Doppler-ultrasound

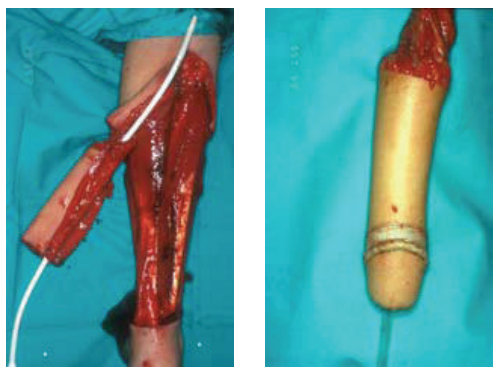
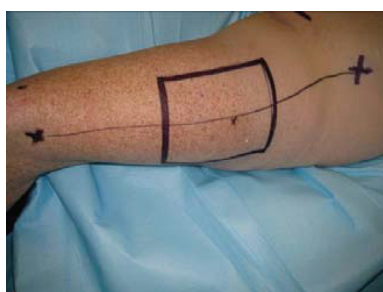
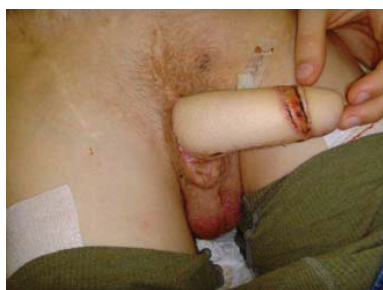

FIGURE 2: The radial forearm free flap using the tube-in-a-tube principle for creation of the neourethra.



(a)



(b)

FIGURE 3: The anterolateral thigh flap. (a) Preoperative: the vascular pedicle is marked at the middle using Doppler-ultrasound. (b) Postoperative.

just prior to incision. The lateral femoral cutaneous nerve is transected after harvesting the flap. The flap is tunneled underneath the adductor muscles and then transferred to the pubic area. At this moment, the flap is shaped into a phallus using the tube-in-tube technique. Once at the pubic area, the urethral anastomosis is finished. Any tension on the pedicle must be avoided. The nerve is reattached to its stump using a subcutaneous tunnel above the adductor muscles.

The defect on the donor area is covered with split-thickness skin grafts harvested from the medial and anterior thigh. All patients receive a suprapubic urinary diversion postoperatively. The patients remain in bed during a one-week period after which the transurethral catheter is removed. One week later, the suprapubic catheter is clamped and voiding is started. It sometimes takes several days

before good voiding is observed. The average admission period for the phalloplasty procedure is about 2,5 weeks. Tattooing of the glans can be performed after a 3 to 6 month period, before sensation is returned to the penis. For the implantation of a penile prosthesis, return of sensation to the top of the neophallus is required. This usually takes about one year. An AMS Ambico prosthesis using one cylinder is implanted. A median scrotal incision is used and the tract through the phallus is bluntly dilated. If possible, the base of the cylinder is fixed in the remnants of the corpora cavernosa. If not, the cylinder is attached to the ramus inferior ossis pubis with a nonresorbable suture. Evaluation of sensation and aesthetic appearance was done by questionnaire. Voiding was evaluated by uroflowmetric and measurement of residual urine by echography. In case a stricture was suspected, urethrography was performed

### 3. RESULTS

Mean dimensions of the flap (including urethra) were 15 by 14 cm.

A total flap survival was noticed in all patients, and there were no complications concerning the donor area. Eight of the eleven patients underwent urethral reconstruction. In 2 patients, this was only done for ejaculation through the phallus. In 8 patients, there was sufficient penile and/or cavernosal tissue to be incorporated at the base of the newly reconstructed phallus.

Of 8 patients in which a urethra was reconstructed, 4 patients developed urethral complications. A persistent fistula at the anastomosis of the neourethra to the native urethra developed in 3 patients (all treated by RFF), of which a concomitant urethral stricture was present in 2 patients. One ALTF-patient developed an isolated urethral stricture, also at the anastomosis site. In case of a fistula, surgical closure was needed and successful in all 3 patients. The urethral strictures were managed by end-to-end urethroplasty in one patient and by a two-stage urethroplasty in the other patient. After these secondary procedures, all patients (without appendicovesicostomy) could void in a standing position.

Aesthetic appearance was excellent in 9 patients (Figure 4), which all expressed their extreme happiness with the result. In 2 patients, the aesthetic results were moderate. One patient was treated by an RFF and developed a hypertrophic scar causing a clear deformity of the phallus. A Z-plasty was used to solve this problem. The other patient was treated by an ALTF and suffered from a skin rash of unknown origin at the phallus but also at other places of his body.

All of the patients treated by RFFF report protective and erotic sensitivity in their phallus. The patients treated by ALTF have some sensation in the phallus supplied by the lateral femoral cutaneous nerve but markedly inferior compared to the RFF due to the fact that only protective sensation has been provided.

A penile prosthesis was implanted in 6 patients. Unfortunately, in 2 patients the erectile implant had to be removed because of infection. The other 4 patients report satisfactory sexual intercourse.

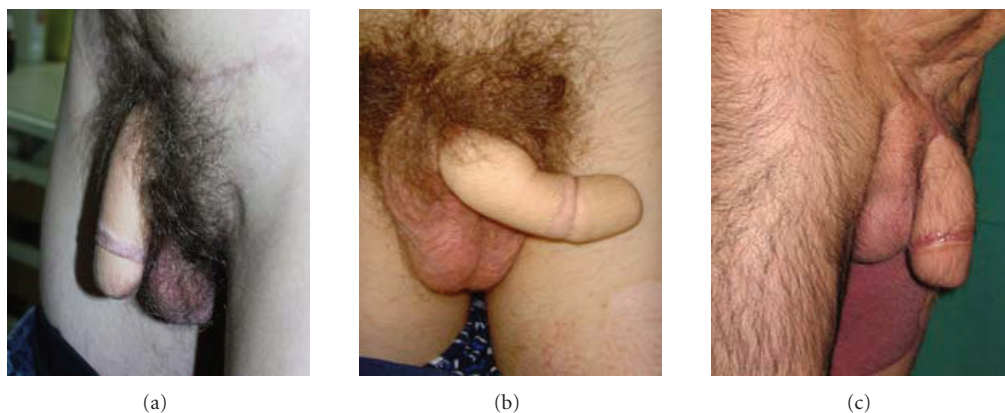


FIGURE 4: Excellent aesthetic appearance after RFF (a)-(b) and ALTF (c) phalloplasty.

#### 4. DISCUSSION

Reconstructive surgery for severe penile insufficiency is necessary because of the devastating effect on psychological and sexual function. Gender reassignment, as used in the past, has controversial results and is nowadays abandoned [1]. Reconstructive surgery with phalloplasty is available and generally used in female-to-male transsexuals. Phalloplasty procedures have followed advances made in plastic surgery. The development of microsurgical free-flap techniques made the first microsurgical phalloplasty possible using a free radial forearm flap [2]. The radial forearm flap has been widely accepted as the best donor site for penile reconstruction and is nowadays the golden standard in phalloplasty for female-to-male transsexuals [3–5]. This same technique can also be applied for severe penile insufficiency.

In this series, the RFF was the method of choice. No complications concerning flap survival or at the donor site were reported. Of the seven patients treated with RFF, the aesthetic appearance was good in 6 patients and moderate in 1 patient. Other series using the RFF in penile insufficiency also report encouraging results with a good aesthetic appearance and low donor site morbidity. The results of phalloplasty using radial forearm free flap in penile insufficiency are encouraging, the aesthetic appearance is good and donor morbidity is low [6, 7]. Erotic sensation was reported by all patients treated with RFF. Although subjective (a questionnaire was used), this finding is consistent with the work of Selvaggi et al. [8]. Coaptation of one of the cutaneous nerves of the flap with a remnant of the dorsal penile nerve seems to be essential in obtaining this result.

Nevertheless, other types of free flaps have been described: Djordjevic et al. [9] reported the musculocutaneous latissimus dorsi free flap, Sengezer et al. [10] suggested the osteocutaneous free-fibula flap, and N. Felici and A. Felici [11] described the free anterolateral thigh flap. They all report satisfactory results. The type of free flap that is used mostly depends on the personal preference and the experience of the plastic surgeon that is involved in phalloplasty.

In case of uncertain pelvic vasculature and anatomy, the use of a pedicled flap is preferred because it brings its own blood supply to the phallus. In our series, 2 patients had uncertain pelvic anatomy because of several previous reconstructive pelvic surgeries for cloacal exstrophy and one patient had uncertain pelvic vasculature because of previous shunting procedures and embolisation for persistent priapism. Possible flaps in these situations are the pedicled island groin flap (insensate) [12] or the pedicled anterolateral thigh flap [13]. In this series, one patient was a good candidate for RFF but he refused this technique because of the extensive scar at the forearm. This scar can be considered as a tell-tale sign of transsexualism. For this reason he preferred an ALTF. Although the aesthetic appearance was good in 3 patients and moderate in 1 patient, sensitivity remains a concern in these pediculated flaps. Although subjective (a questionnaire was used), they all reported less sensitivity compared to the patients treated with RFF. For this reason, an additional connection to the clitoris nerve should be considered.

The major drawbacks of phalloplasty are the urethral complications and the problems with the penile stiffeners. Urethral complication rate (stricture and/or fistula) was high but this is comparable to the large experience with transsexual phalloplasty [3]. Secondary procedures are needed to treat these complications in which the treatment of urethral strictures, especially, is challenging and difficult. Late occurrences of urethral stenosis are always possible because the skin urethra is prone to retract in the long term. If urethral reconstruction is not necessary, for example, in case of continent urinary diversion, it should not be performed unless the patient specifically asks for it.

Obtaining sufficient rigidity to allow penetration is extremely difficult because there is no good substitute for the unique erectile tissue of the penis. The RFF and ALTF are too soft and, thus, implantation of a penile stiffener is needed for sexual intercourse. The implantation must be withheld until the urethra is free of strictures or fistulas and until the phallus is endowed with sufficient protective sensation. This usually takes 12 months. Sufficient protective

sensation is needed in preventing breakdown and erosion of the stiffener. Despite all, explantation rates are high (20–50%) [3, 14, 15] and comparable to the 33,3% explantation rate in this series. One of the possible explanations for this is the less vascularised skin and subcutaneous tissue in the neophallus which can lead to diminished resistance against infection and perforation. Another reason can be the much more intensive use of the penile stiffener in comparison with mostly older and less active impotent men, with a higher chance of malfunction on the long term.

## 5. CONCLUSIONS

Due to the devastating impact on the psychological and sexual function, penile reconstruction of severe penile inadequacy is needed. Today, penile reconstruction using phalloplasty is available. A free flap, such as the radial forearm free flap, is the method of choice because of good aesthetic results, low donor site morbidity, and excellent erogenous sensitivity. In case a free flap is contraindicated, a pedicled flap, such as the anterolateral thigh flap, should be used. This flap has comparable aesthetic results, but sensitivity is a major concern in this flap.

Urinary complications and problems with penile stiffeners are frequent and patients must be informed about these possible complications. Despite this, phalloplasty is a valuable treatment option for severe penile insufficiency.

## REFERENCES

- [1] W. G. Reiner and J. P. Gearhart, "Discordant sexual identity in some genetic males with cloacal exstrophy assigned to female sex at birth," *The New England Journal of Medicine*, vol. 350, no. 4, pp. 333–341, 2004.
- [2] T. S. Chang and W. Y. Hwang, "Forearm flap in one-stage reconstruction of the penis," *Plastic and Reconstructive Surgery*, vol. 74, no. 2, pp. 251–258, 1984.
- [3] S. Monstrey, P. Hoebeke, M. Dhont, et al., "Radial forearm phalloplasty: a review of 81 cases," *European Journal of Plastic Surgery*, vol. 28, no. 3, pp. 206–212, 2005.
- [4] D. A. Gilbert, C. E. Horton, J. K. Terzis, C. J. Devine Jr., B. H. Winslow, and P. C. Devine, "New concepts in phallic reconstruction," *Annals of Plastic Surgery*, vol. 18, no. 2, pp. 128–136, 1987.
- [5] J. J. Hage, J. J. A. M. Bloem, and H. M. Suliman, "Review of the literature on techniques for phalloplasty with emphasis on the applicability in female-to-male transsexuals," *The Journal of Urology*, vol. 150, no. 4, pp. 1093–1098, 1993.
- [6] N. Lumen, S. Monstrey, G. Selvaggi, et al., "Phalloplasty: a valuable treatment for males with penile insufficiency," *Urology*, vol. 71, no. 2, pp. 272–276, 2008.
- [7] D. A. Gilbert, G. H. Jordan, C. J. Devine Jr., B. H. Winslow, and S. M. Schlossberg, "Phallic construction in prepubertal and adolescent boys," *The Journal of Urology*, vol. 149, no. 6, pp. 1521–1526, 1993.
- [8] G. Selvaggi, S. Monstrey, P. Ceulemans, G. T'Sjoen, G. De Cuypere, and P. Hoebeke, "Genital sensitivity after sex reassignment surgery in transsexual patients," *Annals of Plastic Surgery*, vol. 58, no. 4, pp. 427–433, 2007.
- [9] M. L. Djordjevic, M. Z. Bumbasirevic, P. M. Vukovic, S. Sansalone, and S. V. Perovic, "Musculocutaneous latissimus dorsi free transfer flap for total phalloplasty in children," *Journal of Pediatric Urology*, vol. 2, no. 4, pp. 333–339, 2006.
- [10] M. Sengezer, S. Öztürk, M. Devci, and Z. Odabaşı, "Long-term follow-up of total penile reconstruction with sensate osteocutaneous free fibula flap in 18 biological male patients," *Plastic and Reconstructive Surgery*, vol. 114, no. 2, pp. 439–450, 2004.
- [11] N. Felici and A. Felici, "A new phalloplasty technique: the free anterolateral thigh flap phalloplasty," *Journal of Plastic, Reconstructive & Aesthetic Surgery*, vol. 59, no. 2, pp. 153–157, 2006.
- [12] S. Perovic, "Phalloplasty in children and adolescents using the extended pedicle island groin flap," *The Journal of Urology*, vol. 154, no. 2, pp. 848–853, 1995.
- [13] M. J. Descamps, P. M. Hayes, and D. A. Hudson, "Phalloplasty in complete aphallia: pedicled anterolateral thigh flap," *Journal of Plastic, Reconstructive & Aesthetic Surgery*, 2007.
- [14] P. Hoebeke, G. De Cuypere, P. Ceulemans, and S. Monstrey, "Obtaining rigidity in total phalloplasty: experience with 35 patients," *The Journal of Urology*, vol. 169, no. 1, pp. 221–223, 2003.
- [15] N. Lumen, S. Monstrey, K. Decaestecker, Y. Opdenakker, M. Beysens, and P. Hoebeke, "Erectile implants in female-to-male transsexuals: our experience in 130 patients," *European Urology Supplements*, vol. 7, no. 3, p. 117, 2008.