Canadian Journal of Gastroenterology and Hepatology

Hepatocellular Carcinoma: From Molecular Basis to Novel Treatment Approaches

Lead Guest Editor: Hikmet Akkız
Guest Editors: Ali Canbay, Brian I. Carr, Yaman Tokat, and Shuichiro Shiina

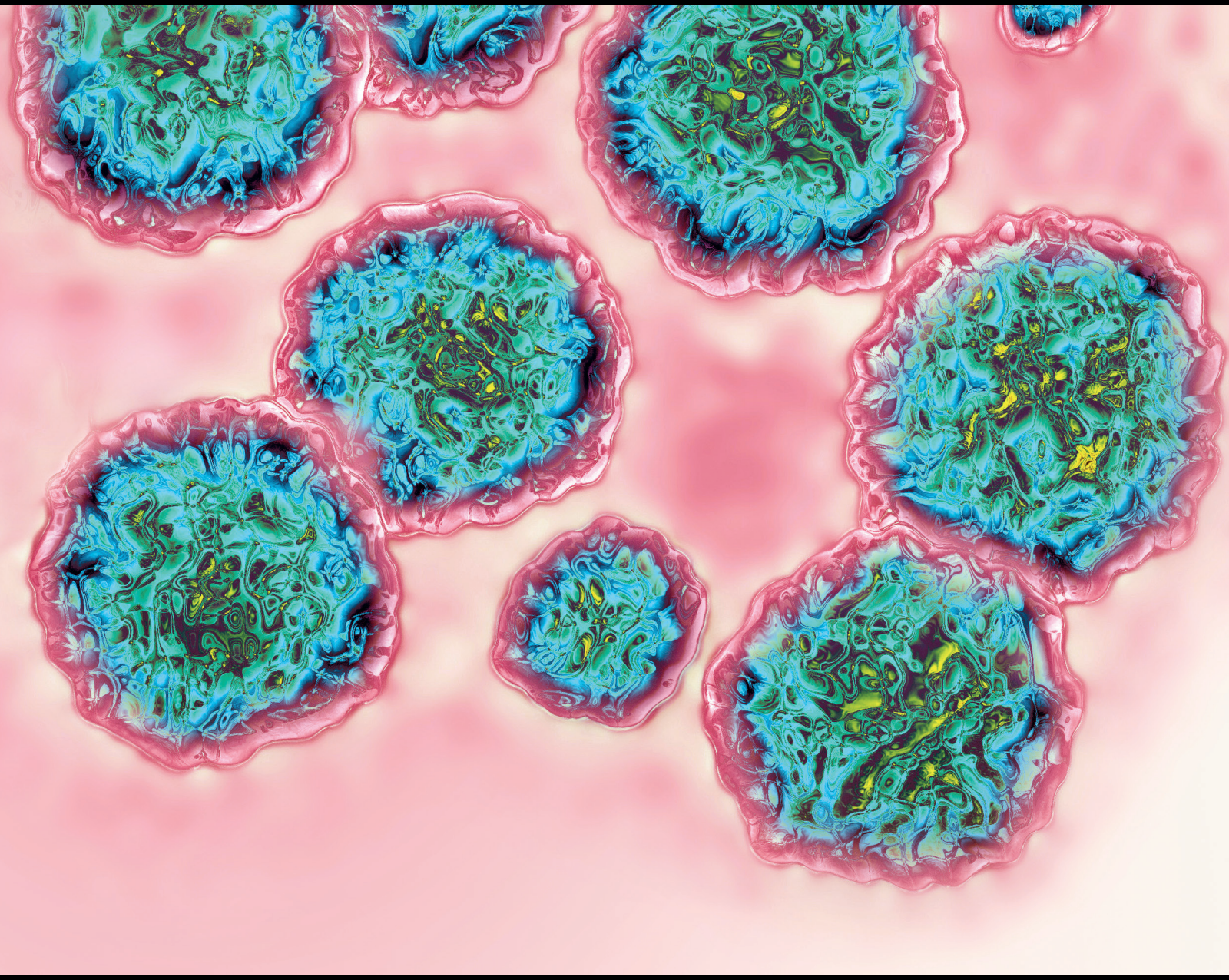

Hepatocellular Carcinoma: From Molecular Basis to Novel Treatment Approaches

Canadian Journal of Gastroenterology and Hepatology

Hepatocellular Carcinoma: From Molecular Basis to Novel Treatment Approaches

Lead Guest Editor: Hikmet Akkiz
Guest Editors: Ali Canbay, Brian I. Carr, Yaman Tokat, and Shuichiro Shiina

Editorial Board

Contents

Hindawi
Canadian Journal of Gastroenterology and Hepatology
Volume 2019, Article ID 4970731, 2 pages
https://doi.org/10.1155/2019/4970731

Editorial

Hepatocellular Carcinoma: From Molecular Basis to Novel Treatment Approaches

Hikmet Akkız

Professor of Gastroenterology and Hepatology, Head of Gastroenterology and Hepatology, Çukurova University, Turkey

Correspondence should be addressed to Hikmet Akkız; hakkiz@superonline.com

Received 20 December 2018; Accepted 31 December 2018; Published 3 March 2019

Hepatocellular carcinoma (HCC) is among the most prevalent and lethal cancers in the world and is the fifth most common cancer and the second leading cause of cancer-related deaths. HCC incidence has increased dramatically during the last decade worldwide. HCC is endemic in East Asia and sub-Saharan Africa where the major risk factors are hepatitis B virus (HBV) and hepatitis C Virus (HCV) infection. Aflatoxin B1 is a relevant cofactor for HCC in sub-Saharan Africa. In the United States and Western Europe, Nonalcoholic Steatohepatitis is an emerging risk factor for the development of HCC.

Recently, Genome-Wide Association Study (GWAS) and Next Generation Sequencing (NGS) technologies have significantly improved our understanding of the molecular pathogenesis of HCC. Hepatocarcinogenesis is driven by interaction between host genetic polymorphisms, environmental factors including metabolic syndrome, aflatoxin B1, alcohol consumption, and viral factors including HBV and HCV infection. Key molecular drivers involved in hepatocarcinogenesis have been demonstrated. Molecular alterations at genomic, transcriptomic, and epigenomic level have been shown to be drivers in hepatocarcinogenesis. Genomic instability is key driver in hepatocarcinogenesis that may result in copy number alterations and somatic mutations. Epigenomic alterations causing DNA mutilation, histone modification, and chromatin remodeling regulate gene expression at the genome. Telomere and Telomerase have a key role in HCC development. Telomerase reverse transcriptase promoter (TERT) mutation is an early somatic alteration in hepatocarcinogenesis. Telomerase reactivation occurs in approximately 90% of HCC patients due to TERT promoter mutation, TERT amplification, and HBV insertion into the TERT promoter. Inactivation of p53 pathway, alterations in cell cycle signaling pathway, activation of Wnt/B-Catenin signaling and oxidative stress pathways, epigenetic alterations causing chromatin remodeling, and activation of Akt-mTOR-MAPK signaling have been shown to promote HCC progression.

Barcelona Clinic Liver Cancer (BCLC) staging system is the most used staging system in the world for estimating the prognosis of HCC patients and contributes to clinicians choice of an evidence-based allocation of curative and palliative treatments. According to BCLC staging system, potential curative treatments such as ablation, hepatic resection, and liver transplantation are standard options in stage 0 and A HCC patients. Although BCLC A stage is quite specific, BCLC stage B HCC (intermediate stage) is characterized by high heterogeneity which shows a significant challenge in terms of determining the most effective therapy. BCLC staging system recommends transarterial chemoembolization (TACE) for BCLC B patients. However, potential curative treatments may provide more favorable clinical outcomes in some BCLC B patients with preserved liver function.

The advanced stage HCC (BCLC C) includes an extremely heterogeneous patient population characterized by extrahepatic metastasis, macrovascular invasion, a wide range of Child-Pugh scores (A5-B9), and Eastern Cooperative Oncology Group performance status (PS 0-2) and systemic therapy with the multikinase inhibitor, sorafenib, being recommended in patients with advanced stage HCC.

This special issue includes relevant research articles and review articles. In the review article titled "Pleiotropic Effects of Heparins: From Clinical Applications to Molecular Mechanisms in Hepatocellular Carcinoma" published by P. Korhan et al., the authors summarize the state of knowledge whereby heparin may crosstalk with molecules playing a role in hepatocarcinogenesis, and highlight new experimental and

clinical research-related personalized therapy in patients with cancer at risk of thromboembolism.

The research article published by G. Odabas et al. showed that Plexin C1 distinguishes HCC cells of epithelial characteristics from those with the mesenchymal phenotype and HCC tissue overexpresses Plexin C1 compared to stroma.

In the review article titled "Molecular Pathogenesis of Nonalcoholic Steatohepatitis- (NASH-) Related Hepatocellular Carcinoma" written by O. Kutlu et al., the investigators provide comprehensive knowledge of NASH-related hepatocarcinogenesis and highlight molecular signaling pathways that may have a role in HCC development.

H. Akkiz et al. have demonstrated the association between portal vein thrombosis and maximum tumor diameter, multifocality, and AFP in the large cohort study.

In the review article on local ablation therapies for HCC, S. Shiina et al. have given updated knowledge about various ablation techniques and compared them to surgical modalities.

Conflicts of Interest

The editors declare that they have no conflicts of interest regarding the publication of this special issue.

Acknowledgments

Finally, I would like to knowledge the Guest Editors DR. Yaman Tokat, Dr. Brian Carr, Dr. Ali Canbay, and Dr. Shuichiro Shiina for valuable endeavours and contributions. Additionally, I would like to thank the Çukurova University for financial support.

Hikmet Akkız

Hindawi
Canadian Journal of Gastroenterology and Hepatology
Volume 2018, Article ID 7568742, 8 pages
https://doi.org/10.1155/2018/7568742

Review Article

Pleiotropic Effects of Heparins: From Clinical Applications to Molecular Mechanisms in Hepatocellular Carcinoma

Peyda Korhan,[1] Yeliz Yılmaz,[1,2] Ezgi Bağırsakçı,[1,3] Ayşim Güneş,[1] Hande Topel,[1,2] Brian I. Carr,[1] and Neşe Atabey[1]

[1]*Izmir Biomedicine and Genome Center, 35340, Turkey*
[2]*Medical Biology and Genetics, Heath Sciences Institute, Dokuz Eylul University, 35340, Turkey*
[3]*Izmir International Biomedicine and Genome Institute, Dokuz Eylul University, 35340, Turkey*

Correspondence should be addressed to Neşe Atabey; nese.atabey@ibg.edu.tr

Received 29 July 2018; Revised 4 October 2018; Accepted 9 October 2018; Published 22 October 2018

Academic Editor: Pierluigi Toniutto

Hepatocellular carcinoma (HCC) is a major health problem worldwide and most cases are incurable because of late presentation. It is the most common primary neoplasm of the liver and often arises in the context of a chronic liver disease that impairs coagulation. Portal vein thrombosis (PVT) is a common complication of HCC that is associated with a poor prognosis. Heparin derivatives are widely used in the management of venous thromboembolism (VTE). Among them low molecular weight heparin (LMWH) favorably influences the survival in patients with advanced cancer, including HCC. Due to their pleiotropic function, heparins affect tumorigenesis in many ways and may promote or hamper tumorigenic transformation depending on the cancer type and cancer stage along with their structural properties and concentration. Thus, their application as an antithrombotic along with the conventional therapy regime should be carefully planned to develop the best management strategies. In this review, we first will briefly review clinical applications of heparin derivatives in the management of cancer with a particular focus on HCC. We then summarize the state of knowledge whereby heparin can crosstalk with molecules playing a role in hepatocarcinogenesis. Lastly, we highlight new experimental and clinical research conducted with the aim of moving towards personalized therapy in cancer patients at risk of thromboembolism.

1. Introduction

Worldwide, liver cancer is the sixth most common cancer and is the second leading global cause of cancer-related deaths [1, 2]. Among all primary liver cancers, HCC is the most prevalent malignancy, accounting for approximately 90% of cases [1–3]. The prognosis for HCC is very poor, with an incidence rate almost equaling the mortality rate (overall ratio of mortality to incidence of 0.95) [1]. The incidence of HCC increases progressively worldwide with advancing age in all populations, reaching a peak at 70 years [1]. The highest incidence and mortality rates of HCC are found in the less developed regions of the world, such as Southeast Asian countries [1], as compared to those in more developed regions in Europe and North America [1–3]. This global variation in incidence rates of HCC is closely related to the risk factors for HCC. HCC is common in patients with advanced hepatic fibrosis and cirrhosis, particularly with chronic damage caused by HBV or HCV infection, alcohol abuse, metabolic disease, and nonalcoholic fatty liver disease/obesity [4]. Tobacco smoke inhalation and dietary ingestion of fungal aflatoxins have been also recognized as major risk factors for HCC [4]. HCC originates as a result of an accumulation of genetic and epigenetic alterations, leading to an aberrant production of driver molecules. These altered expression profiles result in a multistep progression of precursor lesions to invasive/advanced HCC [4]. Importantly, Cancer Research, UK, has announced that 49% of liver cancer cases in the UK are preventable [5]. HBV vaccination, the establishment of treatments for HBV or HCV infections and widespread screening for hepatitis B or C viral infection, and interrupting the transmission of hepatitis virus infection via blood transfusion and blood products have all been shown to prevent liver cancer in high-incidence countries such as Japan [1, 5, 6].

Advances in science and technology have resulted in substantial opportunities for the management of HCC; however, prognosis of this disease is still poor due to the advanced stage at disease presentation, often due to absence of pathognomonic symptoms [7–10]. Larger tumor size, vascular invasion, poor liver functional status, and nodal metastasis are all associated with a poor prognosis [7–10]. Additionally, extraordinary inter- and intratumor heterogeneity of HCC contribute to drug resistance and recurrence, which pose a substantial bar to survival [11].

This complexity of HCC has led to the development of staging systems which combine both tumor and liver factors and a set of management guidelines, such as the Barcelona Clinic Liver Cancer (BCLC) guidelines recommended by the American Association for the Study of Liver Diseases (AASLD) and the European Association for the Study of the Liver (EASL) [8–10]. Surgical resection, transplantation, and ablation are potentially curative treatment options for HCC [8–10]. Unfortunately, less than 30% of patients globally who are diagnosed with early stage disease (Stage 0 or A) are eligible for these procedures [8–10]. For patients with intermediate stage disease (stage B), where patients are not eligible to be operated on, transarterial chemoembolisation (TACE) or transarterial radioembolisation (TARE) are recommended to establish local control and palliation [8–10]. TACE could potentially also be an adjuvant therapy for resectable HCC patients after hepatectomy, which could prevent recurrence and improve long-term survival [8–10]. Patients with advanced HCC which is considered as incurable have limited treatment options and chemotherapy provides minimal clinical benefit. Currently, Sorafenib, Lenvatinib, Regorafenib, or Opdivo, which are multitargeted kinase inhibitors or immune checkpoint inhibitors (Opdivo), are the only systemic agents demonstrated to extend overall survival (OS) compared with placebo in patients with advanced HCC by approximately three months [12–14].

Although TACE is relatively safe, it may cause liver damage complications, especially in presence of PVT [15]. In addition, like many cancers, HCC is also associated with hemostatic activation, with a reported incidence of PVT ranging from 20%-65% [16]. The presence of PVT in patients with HCC is associated with systemic VTE, worse hepatic function, intraarterial tumor invasion, portal hypertension, and poorer tolerance to undergoing treatment which are collectively lead to reduced survival [16, 17]. Not surprisingly, PVT is frequent in patients with liver cirrhosis which can be life-threatening [18]. Hemostatic alterations are well documented in liver disease: hemostasis is often impaired by thrombocytopenia and the reduced synthesis of coagulation factors that normally takes places in the liver [19]. These alterations can be worsened following surgery and chemotherapy even causing hemorrhagic complications [20, 21]. Thus, pharmacological prophylaxis of VTE is often needed in HCC patients. Despite the clinical relevance of the matter, there are no guidelines available on the administration of antithromboembolic prophylaxis in HCC patients. Currently, LMWH is strongly recommended for intervention in the prevention and management of thromboembolism complications [21–23]. Strikingly, several clinical and experimental studies have suggested that heparin derivatives affect cancer progression independent of their anticoagulant effects. Considering the fact that heparin derivatives are involved in a wide variety of biological activities, their application as an antithrombotic along with conventional therapy regime should be carefully planned to develop the best management strategies.

In this review, we firstly briefly review clinical applications of heparin derivatives in the management of cancer with a particular focus on HCC. Then we summarize the state of knowledge whereby heparin can cross-talk with molecules playing a role in hepatocarcinogenesis. Lastly, we highlight new experimental and clinical research conducted with the aim of moving towards personalized therapy in cancer patient at risk of thromboembolism.

2. Heparin Derivatives in the Management of Cancer

As mentioned above, patients with cancer are frequently treated with anti-coagulants, such as heparins, to treat or prevent thrombosis. Heparins are not absorbed orally, thus, they must be administrated parentally by intravenous infusion or subcutaneous injections [24]. UFH and other LMWHs, such as fondaparinux and danaparoid, do not possess intrinsic anticoagulant activity but potentiate antithrombin III that inhibits activated coagulation agents [25]. For many years unfractionated heparin (UFH) has been the standard treatment for initial anticoagulation [26]. However, recent randomized trials have demonstrated that LMWH is possibly superior to UFH in the initial treatment of VTE in people with cancer [26]. Moreover, LMWH provide other advantages versus UFH, including lower cost and simple dosing, and is associated with a lower risk for heparin-induced thrombocytopenia (HIT) [27]. Thus, LMWH is strongly recommended for intervention in the prevention and management of thromboembolism complications in cancer [21–23]. However, long-term use has been associated with bruising at injection sites, recurrent thromboembolism, thrombocytopenia, and bleeding which then causes interruption of essential cancer therapies [22, 26].

Importantly, randomized trials comparing LMWH to UFH for the treatment of thrombosis have also indicated that heparins may improve outcomes of patients with cancer, particularly in those with early stage disease cancer including HCC and in patients with small cell lung [28, 29]. The PROTECHT study (Prophylaxis of Thromboembolism during Chemotherapy; ClinicalTrials.gov Identifier: NCT00951574) has been designed to evaluate if prophylaxis with nadroparin (LMWH) conferred any additional benefit in terms survival, depending on whether chemotherapy disease control was achieved [30]. Notably, a statistically significant interaction between nadroparin treatment and response to chemotherapy was found, thus supporting the hypothesis difference in survival depends on the response to chemotherapy and nadroparin [30]. LMWHs lend themselves to such studies because of their pleiotropic effects and the relative ease of administration compared to UFH. A completed clinical trial, the results of which have not yet been released, investigated

whether addition of LMWHs to TACE would improve HCC patient compared with TACE alone (ClinicalTrials.gov Identifier: NCT00827554). In addition, a current trial, which is not recruiting yet, aims to examine antithrombotic therapy with TACE in HCC to minimize mortality and to improve survival rate without provoking excessive bleeding (ClinicalTrials.gov Identifier: NCT02715492).

3. Heparin Derivatives

Heparin is a glycosaminoglycan that is synthesized by mast cells and basophils. Glycosaminoglycans are linear carbohydrate polymers that are composed of alternating uronate and hexosamine saccharides linked by glyosidic linkages [31]. Heparin undergoes extensive sulfation and rarely phosphorylation or carboxylation during synthesis and hence is a highly negatively charged biological molecule [32]. UHF is a naturally occurring mixture of glycosaminoglycan chains from porcine or bovine origin, each consisting of 200-300 saccharides units with molecular weights in the range of 12-14 kDa [33, 34]. LMWH consists of smaller fragments of UFH (nearly 18 saccharide units long, molecular weight approximately 5 kDa) produced by controlled enzymatic or chemical depolymerisation [33, 34]. Due to their structural differences, LMWH have relatively little antithrombotic activity compared to UFH [32].

4. Brief Review for Mechanisms of Heparin Affects Cancer Pathways

There are multiple experimental studies supporting the hypothesis that cancer progression can be influenced by heparins. Several *in vitro* and *in vivo* cancer models supported the idea that cancer cells exploit the coagulation system to facilitate cell growth, angiogenesis, immune evasion, and metastasis formation, by distinct mechanisms. In addition, numerous studies have demonstrated that heparins do not affect cancer only by their interaction with the coagulation cascade but also by various other ways, including by inhibition of cell-cell interaction by blocking cell-adhesion molecules (selectins), the inhibition of extracellular matrix proteinase heparanase, and the inhibition of angiogenesis.

Heparins are located primarily in the cell membrane and the extracellular matrix (ECM). They bind transiently with ECM-associated molecules, like the growth factors, cytokines, and enzymes, and alter their organization and functions [35]. One such example is heparin involvement in vascular epithelial growth factor- (VEGF-) fibronectin binding, where transient interaction of heparin with fibronectin promotes an open-conformation of fibronectin, which enhances binding to VEGF [36]. Consequently, VEGF binding to fibronectin is sufficient to mediate VEGF induced Erk1/2 activation, endothelial cell proliferation, and migration which are key steps in angiogenesis [37]. Moreover, blockage of the interaction between heparin and fibroblast growth factor (FGF), a well-known stimulator of angiogenesis, inhibits angiogenesis, tumor growth, and metastasis [38]. Duckworth et al. have shown that chemically modified heparin inhibits galectin-3-ligand binding and thereby prevents cancer-cell-endothelial adhesion and angiogenesis [39]. Also, heparin enhances ECM remodeling through the activation of metalloproteinase-2 and acts as a heparanase inhibitor that results in *in vitro* tubular morphogenesis of microvessels that is necessary for angiogenesis [33, 40]. Similarly, chemically modified nonanticoagulant species of heparin that specifically inhibit selectin-mediated heparanase enzymatic activity attenuate metastasis of melanoma cells [41]. It has been reported that heparin binds to platelets via P-selectin and prevents tumor invasion in lung cancer cells [42] Borsig et al. reported that heparin blocks P-selectin based platelet interactions through cell surface proteins such as mucins and thereby attenuates metastasis [42]. Furthermore, heparin binds L- and P-selectins to inhibit acute inflammation and thereby suppresses inflammatory processes in tumor microenvironment which is important for immune evasion. Moreover, heparin can also inhibit fibrin deposition around tumor cells for protecting cells from the immune system [43].

Another heparin interacting protein is factor 4 (CXCL4-PF4) which is released from activated platelets during platelet aggregation and promotes blood coagulation [44]. In addition, CXCL4-PF4 induces immune cells activation, differentiation, and migration but also inhibits endothelial cell migration, proliferation, and angiogenesis [44]. Relevant for this review are the effects of CXCL4-PF4 on the hemostatic system [44]. CXCL4-PF4 and heparin binding neutralise heparin on the endothelial surface of blood vessels, thereby inhibiting local antithrombin III activity and promoting coagulation [44]. In some patients exposed to heparin, CXCL4-PF4/heparin complex triggers an immunogenic response eventually leading to production of anti-CXCL4-PF4/heparin antibodies [44]. This may lead to a severe clinical condition characterized by platelet activation and aggregation, thrombocytopenia, and thrombocytopenia, which is commonly called heparin-induced thrombocytopenia (HIT). HIT typically develops 5-14 days after exposure to prophylactic or therapeutic doses of heparin [45]. In some cases, patients who previously had been exposed to heparin trigger HIT quicker [45].

In contrast to the anticarcinogenic effect above, heparin may also be involved in the activation of the metastatic cascade by forming a complex with midkine (MK). MK is highly expressed in HCC and in cancers of the stomach, colon, esophagus, pancreas lung, neuroblastoma, glioma, and urinary bladder [46–48]. MK is activated when it forms homodimers that are stabilised by heparin. Activated MK/heparin complex leads to metastasis and drug resistance [49]. Notably, Jia et al. demonstrated that LMWH significantly blocked coadhesion between connective tissue growth factor/CCN family 2 (CCN2) and low-density lipoprotein receptor-related protein 6 (LRP6) and enhanced chemotherapeutic effect of oxaliplatin on HCC [50]. CCN2 functions to orchestrate LRP6 which is coreceptor in Wnt signalling. Wnt signalling is key signaling related to stem-ness, and chemoresistance [50]. Combination treatment with oxaliplatin and LMWH showed improved response rates to chemotherapy [50] Likewise, Pfankuchen et al. reported that a therapeutic dosage of LMWH (tinzaparin) reversed cisplatin resistance in

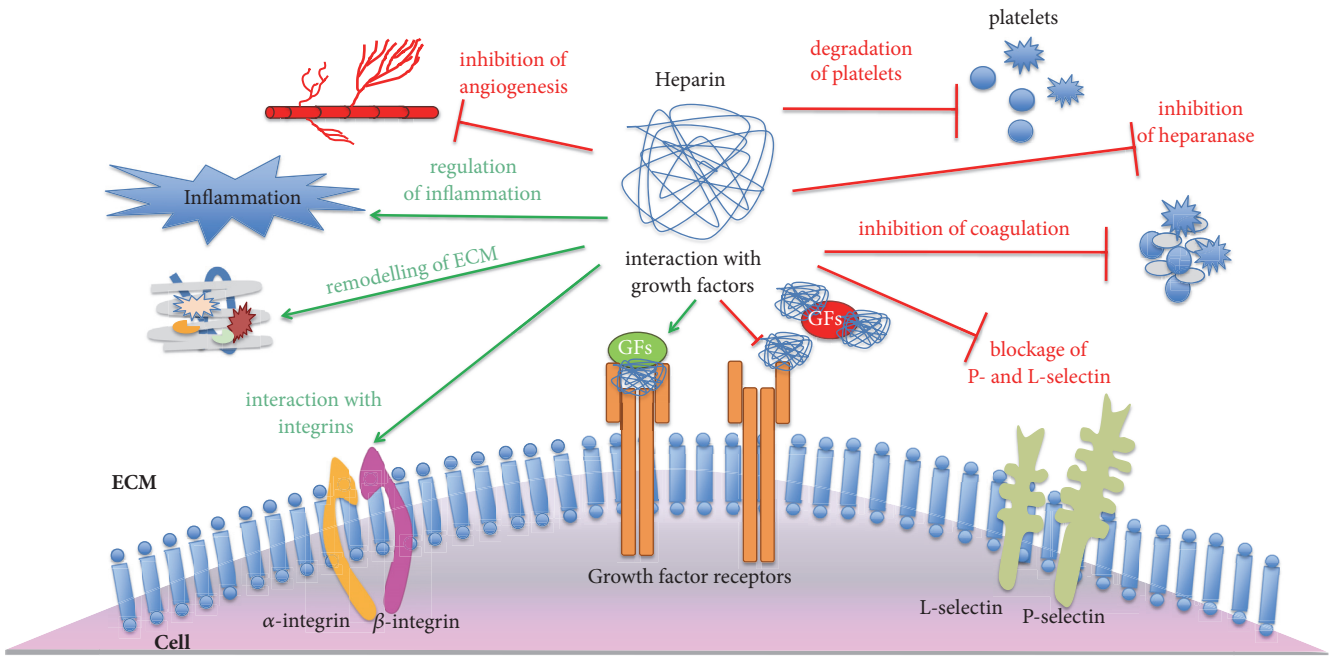

Figure 1: **Biological effects of heparin**. Heparin has inhibitory and activating roles in molecular and cellular mechanisms. It has a role in degradation of platelets, inhibition of coagulation, and angiogenesis. It also acts as a heparanase inhibitor and blocks P- and L-selectin to interact with platelets and prevents metastasis. Moreover, it interacts with ECM proteins and enhances remodeling of the ECM. It is involved in inflammatory processes and regulates inflammation. Heparin interacts with integrins and growth factors. However, in some growth factor signaling pathways it may have inhibitory as well as activating effects. For instance, it interacts with factors such as FGF, TGFB1, and MK and regulates the signaling positively. In contrast, it also interacts with FGF and HGF and regulates the signaling negatively (ECM: extracellular matrix; FGF: fibroblast growth factor; and HGF: hepatocyte growth factor.

a clone of ovarian cancer cell line to the level of sensitive cells [51, 52]. According to the follow up study, cisplatin resistant cells showed 3-fold higher Wnt signaling activity compared to wild type cells and Wnt pathway blockade increased cisplatin sensitivity. LMWH treatment reduced Wnt pathway activity and TCF-4 expression and enhanced cisplatin sensitivity in cisplatin resistant clones [51].

LMWH is also used as a nanocarrier to deliver drugs in cancer therapies. Modification of heparin molecules to generate nanocarriers become useful for applications like imaging, disease, and cancer treatments. Yan et al. prepared gambogic acid grafted low molecular weight heparin micelles to combine anti-tumor effect of gambogic acid with anti-angiogenic and anti-metastatic effect of heparin [53]. This *in vivo* study suggested that drugs grafted to LMWHs can be delivered to the liver and enhance their therapeutic effects by combining antitumor effects of heparin [53]. Furthermore, Du et al. modified LMWH to carry doxorubicin to overcome doxorubicin resistance in HCC [54].

5. Factors Influencing the Pleiotropic Role of Heparins

Due to their heterogeneity and natural location, heparins are able to interact with a wide variety molecules and mediate diverse biological processes (Figure 1). Therefore, it is not surprising that the role of heparins in tumor genesis is context dependent.

To clarify the various potential mechanisms of heparin anticancer activity, Niers et al. evaluated the data from preclinical studies (published between 1960 and 2005) in which heparins have been tested as anticancer therapy [32]. They suggested that heparin may affect the formation of metastasis rather than the growth of primary tumors. They also documented that chemically modified heparins with no or limited anticoagulant activity also showed antimetastatic properties [32]. They concluded with possible mechanisms to explain the effects on the process of metastasis include inhibition of blood coagulation, inhibition of cancer cell-platelet, and cancer cell-endothelial interactions by inhibition of cell invasion and angiogenesis [32]. They also documented interesting results highlighting the importance of types, duration, timing, and dose of heparin used, animal tumor model tested, and route of heparin administration in the course of disease [32]. Similarly, LMWH treatment was shown to inhibit FGF-induced mitogenesis of tumor derived endothelial cells in a time and concentration dependent manner [55]. Likewise, in Jha et al.'s study, to understand the effects of molecular weight and concentration of heparin on transforming growth factor (TGF)-β1 signaling, they used heparin-containing hyaluronic acid based hydrogels to analyze growth factor affinity and retention [56]. At equal concentrations, high molecular weight heparin has the highest amount of TGF-β1 retention from hydrogel compared to low molecular weight or unfractionated heparin. This response is critical for stem cell differentiation and lineage specification [56].

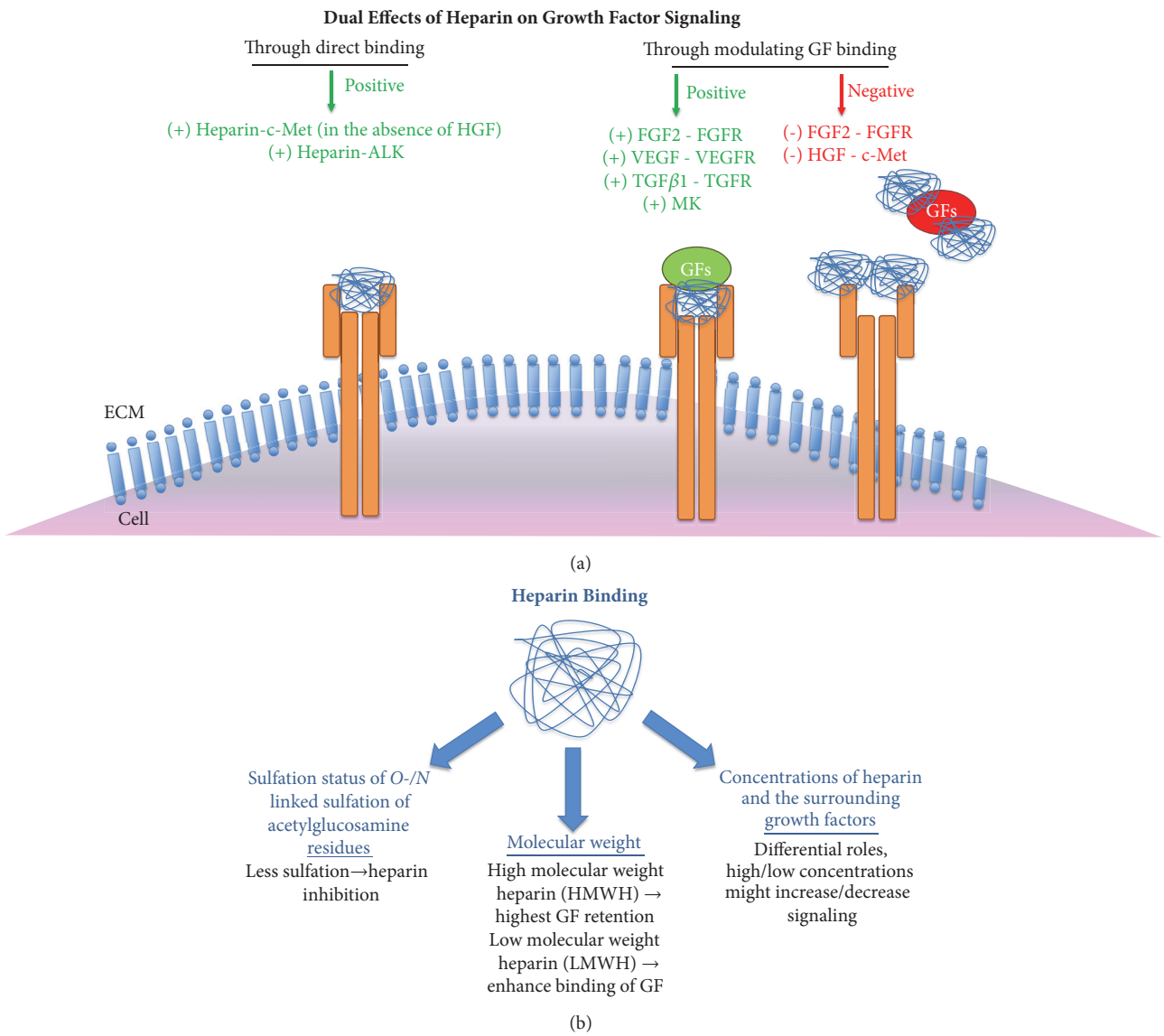

Figure 2: **Effects and effectors of heparin binding**. Heparin binding has context-dependent roles in Growth Factor (GF) signaling, it might directly bind to Growth Factor Receptors (GFRs) or it might modulate signaling positively or negatively through binding to both GFs and GFRs (a). Heparin binding to GFs and GFRs are affected by several factors including sulfation status, the molecular weight of heparin and the concentrations of both heparin and the GFs (b).

LaRochelle et al. determined that low concentrations of heparin enhance the binding of keratinocyte growth factor (KGF) to its receptor in CHO cells lacking HS proteoglycans but this effect is not observed in wild type CHO cells. In contrast higher heparin concentrations inhibit KGF signaling [57]. Furthermore, while heparins with short chain lengths are not able to activate anaplastic lymphoma kinase (ALK), heparins with longer chain lengths can induce dimerization and activation ALK in neuroblastoma cells [58]. Interestingly, in our previous studies, we showed that heparin can activate the c-Met signaling pathway by activating dimerization of c-Met receptor, which can then induce HCC cell invasion [59] However, when Hepatocyte Growth Factor (HGF), ligand of c-Met, is in the environment, heparin suppressed HGF/c-Met signaling mediated adhesion, motility, and invasion [59]. When we performed a microarray analysis to identify the molecular mechanisms behind heparin mediated biological responses, we observed that heparin modulates transcription of several genes involved in glucose metabolism, tumor angiogenesis, and EMT [60]. In our further analysis, we demonstrated that heparin controlled thioredoxin-interacting protein (TXNIP) gene expression through two mechanisms: (1) it can either directly bind to a unique carbohydrate response element located on the promoter of this gene or (2) it can trigger epigenetic modifications [60]. In either case, increased expression of TXNIP, which is a regulator glucose metabolism, accelerates migration and invasion abilities of HCC cells [60]. These data imply that, in

addition to its regulatory role on receptor dimerization and ligand binding to its receptor, heparin also has a transcription regulatory role in HCC.

Overall, these studies emphasised that both intrinsic (such as tumor type) and extrinsic (such as heparin type) determinants play roles in the actions of heparin on tumors. For instance, while heparin administration increases tumor growth and metastasis in colon cancer, it reduces metastases in fibrosarcomas, lung, prostate, and mammary carcinomas [61–63]. These pleotropic effects of heparin might be related to expression or activation levels of growth factors and/or their receptors, as well as by heparin type and concentration. As summarized in Figure 2, heparin can directly bind to growth factor receptors or growth factors to stimulate signaling pathways, whereas it could block growth factor-receptor interaction as a context dependent manner.

6. Conclusions

The management of HCC along with other advanced-stage cancers remains a challenge. Venous thrombosis is a common complication in patients with cancer and indicates a poor prognosis. LMWH is widely used in the clinic as an anticoagulant as part of a treatment regimen in cancer patients to treat or control thrombosis. Many studies highlight the benefit of heparin derivatives in increasing patient survival, mostly through their antithrombotic effect. There is also a growing amount of evidence for the anticancer effects of heparin, which are mostly via its inhibition of metastasis rather than on primary tumor growth. However, there is also evidence revealing that heparin can act as a metastasis promoting agent. Clearly, due to its pleiotropic actions, heparin affects tumorigenesis in many ways and may promote or hamper cell transformation, depending on the cancer type and stage along with its structural properties and concentration. This phenomenon stresses the fact that heparin use in the clinic should be assessed carefully. In addition, the use of a same therapy approach for all patients might result in variable and unpredictable responses, because of heterogeneity among tumors and genotypic differences between patients. Hence, personalized medicine (PM) offers an attractive approach for cancer management and care. PM implements "-omic" sciences (genomics, epigenomics, transcriptomics, proteomics, etc.) to integrate various data sets with the aim of dissecting molecular signatures and functional pathways that help to classify tumor subtypes and determine their natural course, prognosis, and responsiveness to therapies [64]. Thus, stratification of the subset of patients who might respond to particular combinations of therapies is crucial in the management of cancer. For instance, mutations of the KDM6A, CUL9, FDG6, AKAp3, and RFN139 genes are associated with the development of PVT in advanced HBV-related HCC [65]. Since effective management of PVT may improve treatment results for HCC, these genes can be used for the identification or prediction of high-risk patients who will benefit most from antithrombotic therapy. Moreover, anti-CXCL4-PF4/heparin antibodies can be used as a predictive factor to identify patients who should avoid heparin treatment. Further studies are needed for better understanding of heparin and tumor biology and the determination of biomarkers for the planning of best evidence-based approaches that meet the needs of patients for disease treatment, reduction of symptoms, and improvement in quality of life.

Conflicts of Interest

The authors declare that there are no conflicts of interest regarding the publication of this review.

Authors' Contributions

Peyda Korhan and Yeliz Yılmaz have equal contributions.

References

[1] "GLOBOCAN 2012, Cancer Incidence and Mortality Worldwide: IARC, vol. 11, International Agency for Research on Cancer, Lyon, France, 2018".

[2] "Globocan 2012 Liver Cancer Act Sheet, IARC: International Agency Research on Cancer, Lyon, 2012".

[3] G. Klöppel and World Health Organization Classification of Tumours, *Pathology and Genetics of Tumours of the Digestive System: Ductal Adenocarcinoma of the Pancreas*, International Agency for Research on Cancer Press, 2000.

[4] J. M. Llovet, J. Zucman-Rossi, E. Pikarsky et al., "Hepatocellular carcinoma," *Nature Reviews Disease Primers*, vol. 2, p. 16018, 2016.

[5] "Cancer Research UK Liver cancer risk factors," 2014, https://www.cancerresearchuk.org/health-professional/cancer-statistics/statistics-by-cancer-type/liver-cancer#heading-Three.

[6] M. Ikeda, S. Mitsunaga, S. Shimizu, I. Ohno, H. Takahashi et al., "Current status of hepatocellular carcinoma in Japan," *Chinese Clinical Oncology*, vol. 2, no. 4, p. 40, 2013.

[7] European Association for the Study of The Liver, "EASL-EORTC Clinical Practice Guidelines: management of hepatocellular carcinoma," *European Journal of Cancer*, vol. 48, no. 5, pp. 599–641, 2012.

[8] P. R. Galle, A. Forner, J. M. Llovet et al., "EASL Clinical Practice Guidelines: Management of hepatocellular carcinoma," *Journal of Hepatology*, vol. 69, no. 1, pp. 182–236, 2018.

[9] J. W. Park, M. Chen, M. Colombo et al., "Global patterns of hepatocellular carcinoma management from diagnosis to death: the BRIDGE Study," *Liver International*, vol. 35, no. 9, pp. 2155–2166, 2015.

[10] J. Bruix, M. Reig, and M. Sherman, "Evidence-based diagnosis, staging, and treatment of patients with hepatocellular carcinoma," *Gastroenterology*, vol. 150, no. 4, pp. 835–853, 2016.

[11] L. Li and H. Wang, "Heterogeneity of liver cancer and personalized therapy," *Cancer Letters*, vol. 379, no. 2, pp. 191–197, 2016.

[12] C. J. Wilhelm, R. A. Johnson, P. G. Lysko, A. J. Eshleman, and A. Janowsky, "Effects of methamphetamine and lobeline on vesicular monoamine and dopamine transporter-mediated dopamine release in a cotransfected model system," *The Journal of Pharmacology and Experimental Therapeutics*, vol. 310, no. 3, pp. 1142–1151, 2004.

[13] J. M. Llovet, S. Ricci, V. Mazzaferro et al., "Sorafenib in advanced hepatocellular carcinoma," *The New England Journal of Medicine*, vol. 359, no. 4, pp. 378–390, 2008.

[14] J. Bruix, S. Qin, P. Merle et al., "Regorafenib for patients with hepatocellular carcinoma who progressed on sorafenib

treatment (RESORCE): a randomised, double-blind, placebo-controlled, phase 3 trial," *The Lancet*, vol. 389, no. 10064, pp. 56–66, 2017.

[15] J. P. Silva, N. G. Berger, S. Tsai et al., "Transarterial chemoembolization in hepatocellular carcinoma with portal vein tumor thrombosis: a systematic review and meta-analysis," *HPB*, vol. 19, no. 8, pp. 659–666, 2017.

[16] G. C. Connolly, R. Chen, O. Hyrien et al., "Incidence, risk factors and consequences of portal vein and systemic thromboses in hepatocellular carcinoma," *Thrombosis Research*, vol. 122, no. 3, pp. 299–306, 2008.

[17] S. L. Chan, C. C. N. Chong, A. W. H. Chan, D. M. C. Poon, and K. S. H. Chok, "Management of hepatocellular carcinoma with portal vein tumor thrombosis: Review and update at 2016," *World Journal of Gastroenterology*, vol. 22, no. 32, pp. 7289–7300, 2016.

[18] L. von Köckritz, A. De Gottardi, J. Trebicka, and M. Praktiknjo, "Portal vein thrombosis in patients with cirrhosis," *Gastroenterology Report*, vol. 5, no. 2, pp. 148–156, 2017.

[19] T. Lisman and F. W. G. Leebeek, "Hemostatic alterations in liver disease: A review on pathophysiology, clinical consequences, and treatment," *Digestive Surgery*, vol. 24, no. 4, pp. 250–258, 2007.

[20] M. Vivarelli, M. Zanello, C. Zanfi et al., "Prophylaxis for venous thromboembolism after resection of hepatocellular carcinoma on cirrhosis: Is it necessary?" *World Journal of Gastroenterology*, vol. 16, no. 17, pp. 2146–2150, 2010.

[21] O. Negm, S. Abou Saif, M. El Gharib, M. Yousef, and S. Abd-Elsalam, "Role of low-molecular-weight heparins in prevention of thromboembolic complication after transarterial chemoembolization in hepatocellular carcinoma," *European Journal of Gastroenterology & Hepatology*, vol. 29, no. 3, pp. 317–321, 2017.

[22] S. Noble, A. Nelson, and S. Seaman, "Cancer-associated thrombosis, low-molecular-weight heparin, and the patient experience: a qualitative study," *Patient Preference and Adherence*, vol. 8, pp. 453–461, 2014.

[23] M. B. Hakoum, L. A. Kahale, I. G. Tsolakian et al., "Anticoagulation for the initial treatment of venous thromboembolism in people with cancer," *Cochrane Database of Systematic Reviews*, 2018.

[24] J. Hirsh, "Low molecular weight heparin," *Thrombosis and Haemostasis*, vol. 70, no. 1, pp. 204–207, 1993.

[25] J. Hirsh, K. A. Bauer, and M. B. Donati, "Parenteral anticoagulants: American College of Chest Physicians Evidence-Based Clinical Practice Guidelines (8th Edition)," *CHEST*, vol. 133, supplement 6, pp. 141S–159S, 2008.

[26] E. Donnellan and A. A. Khorana, "Cancer and venous thromboembolic disease: a review," *The Oncologist*, vol. 22, no. 2, pp. 199–207, 2017.

[27] N. Martel, J. Lee, and P. S. Wells, "Risk for heparin-induced thrombocytopenia with unfractionated and low-molecular-weight heparin thromboprophylaxis: a meta-analysis," *Blood*, vol. 106, no. 8, pp. 2710–2715, 2005.

[28] D. Sanford, A. Naidu, N. Alizadeh, and A. Lazo-Langner, "The effect of low molecular weight heparin on survival in cancer patients: An updated systematic review and meta-analysis of randomized trials," *Journal of Thrombosis and Haemostasis*, vol. 12, no. 7, pp. 1076–1085, 2014.

[29] N. Zhang, W. Lou, F. Ji, L. Qiu, B. K. Tsang, and W. Di, "Low molecular weight heparin and cancer survival: clinical trials and experimental mechanisms," *Journal of Cancer Research and Clinical Oncology*, vol. 142, no. 8, pp. 1807–1816, 2016.

[30] S. Barni, E. Bonizzoni, M. Verso et al., "To the editor: The effect of low-molecular-weight heparin in cancer patients: The mirror image of survival?" *Blood*, vol. 124, no. 1, pp. 155-156, 2014.

[31] S. Mohamed and D. Coombe, "Heparin Mimetics: Their Therapeutic Potential," *Pharmaceuticals*, vol. 10, no. 4, p. 78, 2017.

[32] T. M. H. Niers, C. P. W. Klerk, M. DiNisio et al., "Mechanisms of heparin induced anti-cancer activity in experimental cancer models," *Critical Review in Oncology/Hematology*, vol. 61, no. 3, pp. 195–207, 2007.

[33] S. M. Smorenburg and C. J. F. Van Noorden, "The complex effects of heparins on cancer progression and metastasis in experimental studies," *Pharmacological Reviews*, vol. 53, no. 1, pp. 93–105, 2001.

[34] S. A. Mousa, R. Linhardt, J. L. Francis, and A. Amirkhosravi, "Anti-metastatic effect of a non-anticoagulant low-molecular-weight heparin versus the standard low-molecular-weight heparin, enoxaparin," *Thrombosis and Haemostasis*, vol. 96, no. 6, pp. 816–821, 2006.

[35] F. Peysselon and S. Ricard-Blum, "Heparin-protein interactions: From affinity and kinetics to biological roles. Application to an interaction network regulating angiogenesis," *Matrix Biology*, vol. 35, pp. 73–81, 2014.

[36] M. Mitsi, K. Forsten-Williams, M. Gopalakrishnan, and M. A. Nugent, "A catalytic role of heparin within the extracellular matrix," *The Journal of Biological Chemistry*, vol. 283, no. 50, pp. 34796–34807, 2008.

[37] E. S. Wijelath, S. Rahman, M. Namekata et al., "Heparin-II domain of fibronectin is a vascular endothelial growth factor-binding domain: Enhancement of VEGF biological activity by a singular growth factor/matrix protein synergism," *Circulation Research*, vol. 99, no. 8, pp. 853–860, 2006.

[38] S. M. Plum, J. W. Holaday, A. Ruiz, J. W. Madsen, W. E. Fogler, and A. H. Fortier, "Administration of a liposomal FGF-2 peptide vaccine leads to abrogation of FGF-2-mediated angiogenesis and tumor development," *Vaccine*, vol. 19, no. 9-10, pp. 1294–1303, 2000.

[39] C. A. Duckworth, S. E. Guimond, P. Sindrewicz et al., "Chemically modified, non-anticoagulant heparin derivatives are potent galectin-3 binding inhibitors and inhibit circulating galectin-3-promoted metastasis," *Oncotarget* , vol. 6, no. 27, pp. 23671–23687, 2015.

[40] L. Ling, S. K. Tan, T. H. Goh et al., "Targeting the heparin-binding domain of fibroblast growth factor receptor 1 as a potential cancer therapy," *Molecular Cancer*, vol. 14, no. 1, article no. 136, 2015.

[41] N. Hostettler, A. Naggi, G. Torri et al., "P-selectin- and heparanase-dependent antimetastatic activity of non-anticoagulant heparins," *The FASEB Journal*, vol. 21, no. 13, pp. 3562–3572, 2007.

[42] L. Borsig, R. Wong, J. Feramisco, D. R. Nadeau, N. M. Varki, and A. Varki, "Heparin and cancer revisited: mechanistic connections involving platelets, P-selectin, carcinoma mucins, and tumor metastasis," *Proceedings of the National Acadamy of Sciences of the United States of America*, vol. 98, no. 6, pp. 3352–3357, 2001.

[43] H. Engelberg, "Actions of heparin that may affect the malignant process," *Cancer*, vol. 85, no. 2, pp. 257–272, 1999.

[44] P. M. Sandset, "CXCL4-platelet factor 4, heparin-induced thrombocytopenia and cancer," *Thrombosis Research*, vol. 129, pp. S97–S100, 2012.

[45] N. Lubenow, R. Kempf, A. Eichner, P. Eichler, L. E. Carlsson, and A. Greinacher, "Heparin-induced thrombocytopenia: Temporal

pattern of thrombocytopenia in relation to initial use or reexposure to heparin," *CHEST*, vol. 122, no. 1, pp. 37–42, 2002.

[46] J. Yao, W.-Y. Li, and S.-G. Gao, "The advances of Midkine with peripheral invasion in pancreatic cancer," *American Journal of Cancer Research*, vol. 5, no. 9, pp. 2912–2917, 2015.

[47] Y. Xu, X. Qu, X. Zhang et al., "Midkine positively regulates the proliferation of human gastric cancer cells," *Cancer Letters*, vol. 279, no. 2, pp. 137–144, 2009.

[48] B. Sun, C. Hu, Z. Yang et al., "Midkine promotes hepatocellular carcinoma metastasis by elevating anoikis resistance of circulating tumor cells," *Oncotarget* , vol. 8, no. 20, pp. 32523–32535, 2017.

[49] K. Kadomatsu, S. Kishida, and S. Tsubota, "The heparin-binding growth factor midkine: the biological activities and candidate receptors," *The Journal of Biochemistry*, vol. 153, no. 6, pp. 511–521, 2013.

[50] Q. Jia, Y. Bu, Z. Wang et al., "Maintenance of stemness is associated with the interation of LRP6 and heparin-binding protein CCN2 autocrined by hepatocellular carcinoma," *Journal of Experimental & Clinical Cancer Research*, vol. 36, no. 1, article 117, 2017.

[51] D. B. Pfankuchen, F. Baltes, T. Batool, J. Li, M. Schlesinger, and G. Bendas, "Heparin antagonizes cisplatin resistance of A2780 ovarian cancer cells by affecting the Wnt signaling pathway," *Oncotarget*, vol. 8, no. 40, pp. 67553–67566, 2017.

[52] D. B. Pfankuchen, D. P. Stölting, M. Schlesinger, H.-D. Royer, and G. Bendas, "Low molecular weight heparin tinzaparin antagonizes cisplatin resistance of ovarian cancer cells," *Biochemical Pharmacology*, vol. 97, no. 2, pp. 147–157, 2015.

[53] X. Yan, Y. Yang, L. He, D. Peng, and D. Yin, "Gambogic acid grafted low molecular weight heparin micelles for targeted treatment in a hepatocellular carcinoma model with an enhanced anti-angiogenesis effect," *International Journal of Pharmaceutics*, vol. 522, no. 1-2, pp. 110–118, 2017.

[54] H. Du, M. Liu, A. Yu, J. Ji, and G. Zhai, "Insight into the role of dual-ligand modification in low molecular weight heparin based nanocarrier for targeted delivery of doxorubicin," *International Journal of Pharmaceutics*, vol. 523, no. 1, pp. 427–438, 2017.

[55] S. L. Smiley, D. O. Henry, and M. K. Wong, "The mechanism of low molecular weight heparin (LMWH) inhibition of tumor growth," *Journal of Clinical Oncology*, vol. 24, supplement 18, pp. 13093-13093, 2006.

[56] A. K. Jha, A. Mathur, F. L. Svedlund, J. Ye, Y. Yeghiazarians, and K. E. Healy, "Molecular weight and concentration of heparin in hyaluronic acid-based matrices modulates growth factor retention kinetics and stem cell fate," *Journal of Controlled Release*, vol. 209, pp. 308–316, 2015.

[57] W. J. LaRochelle, K. Sakaguchi, N. Atabey et al., "Heparan sulfate proteoglycan modulates keratinocyte growth factor signaling through interaction with both ligand and receptor," *Biochemistry*, vol. 38, no. 6, pp. 1765–1771, 1999.

[58] P. B. Murray, I. Lax, A. Reshetnyak et al., "Heparin is an activating ligand of the orphan receptor tyrosine kinase ALK," *Science Signaling*, vol. 8, no. 360, pp. ra6–ra6, 2015.

[59] E. Ozen, A. Gozukizil, E. Erdal, A. Uren, D. P. Bottaro, and N. Atabey, "Heparin inhibits Hepatocyte growth factor induced motility and invasion of hepatocellular carcinoma cells through early growth response protein 1," *PLoS ONE*, vol. 7, no. 8, article e42717, 2012.

[60] A. Gunes, E. Iscan, H. Topel et al., "Heparin treatment increases thioredoxin interacting protein expression in hepatocellular carcinoma cells," *The International Journal of Biochemistry & Cell Biology*, vol. 65, pp. 169–181, 2015.

[61] C. Lim, H. Multhaupt, and J. R. Couchman, "Cell surface heparan sulfate proteoglycans control adhesion and invasion of breast carcinoma cells," *Molecular Cancer*, vol. 14, no. 1, article no. 15, 2015.

[62] G.-X. Zhong, Y. Gong, C.-J. Yu et al., "Significantly inhibitory effects of low molecular weight heparin (Fraxiparine) on the motility of lung cancer cells and its related mechanism," *Tumor Biology*, vol. 36, no. 6, pp. 4689–4697, 2015.

[63] A. Takeuchi, Y. Yamamoto, S. Munesue et al., "Low molecular weight heparin suppresses receptor for advanced glycation end products-mediated expression of malignant phenotype in human fibrosarcoma cells," *Cancer Science*, vol. 104, no. 6, pp. 740–749, 2013.

[64] P. Korhan, R. Verkerk, and W. R Critchley, "Scientific rationale for integrative and personalised strategies for pancreatic ductal adenocarcinoma management," *Integrative Molecular Medicine*, vol. 4, no. 5, pp. 1–32, 2017.

[65] J. Huang, Q. Deng, Q. Wang et al., "Exome sequencing of hepatitis B virus-associated hepatocellular carcinoma," *Nature Genetics*, vol. 44, no. 10, pp. 1117–1121, 2012.

Hindawi
Canadian Journal of Gastroenterology and Hepatology
Volume 2018, Article ID 4040787, 9 pages
https://doi.org/10.1155/2018/4040787

Research Article

Plexin C1 Marks Liver Cancer Cells with Epithelial Phenotype and Is Overexpressed in Hepatocellular Carcinoma

Gorkem Odabas,[1] Metin Cetin,[1] Serdar Turhal,[2] Huseyin Baloglu,[3] A. Emre Sayan,[4] and Tamer Yagci[1]

[1] *Department of Molecular Biology and Genetics, Gebze Technical University, Kocaeli, 41400, Turkey*
[2] *Department of Medical Oncology, Anadolu Medical Center, Gebze-Kocaeli, 41400, Turkey*
[3] *Department of Pathology, Anadolu Medical Center, Gebze-Kocaeli, 41400, Turkey*
[4] *Faculty of Medicine, Cancer Sciences, University of Southampton, Southampton, SO16 6YD, UK*

Correspondence should be addressed to Tamer Yagci; tyagci@gtu.edu.tr

Received 31 July 2018; Accepted 10 September 2018; Published 19 September 2018

Guest Editor: Hikmet Akkız

Background and Aims. Hepatocellular carcinoma is an aggressive malignancy of the liver and is ranked as the sixth most common cancer worldwide. There is still room for novel markers to improve the diagnosis and monitoring of HCC. Our observations in cancer databases that *PLXNC1* is upregulated in HCC led us to investigate the expression profile of Plexin C1 mRNA and protein in HCC cell lines and tissues. *Methods.* A recombinant protein encompassing part of the extracellular domain of Plexin C1 was used as an antigen for monoclonal antibody development. Transcript and protein levels of Plexin C1 in HCC cell lines were determined by RT-qPCR and Western blotting, respectively. *In vivo* evaluation of Plexin C1 expression in HCC tissues was accomplished by immunohistochemistry studies in tissue microarrays. *Results.* A monoclonal antibody, clone PE4, specific to Plexin C1, was generated. *In silico* and *in vitro* analyses revealed a Plexin C1-based clustering of well-differentiated HCC cell lines. Staining of HCC and nontumoral liver tissues with PE4 showed a membrane-localized overexpression of Plexin C1 in tumors ($p=0.0118$). In addition, this expression was correlated with the histological grades of HCC cases. *Conclusions.* Plexin C1 distinguishes HCC cells of epithelial characteristics from those with the mesenchymal phenotype. Compared to the nontumoral liver, HCC tissues significantly overexpress Plexin C1. The newly generated PE4 antibody can be evaluated in larger HCC cohorts and might be exploited for the examination of Plexin C1 expression pattern in other epithelial malignancies.

1. Introduction

Hepatocellular carcinoma (HCC) is the fifth most common cancer among man and seventh among woman and ranked as the third most common cause of cancer-related deaths [1, 2]. Chronic liver injury, Hepatitis B (HBV) and C (HCV) virus infections, alcohol-associated diseases, and aflatoxin intoxications are the leading causes of HCC development. Several mutations affecting WNT/β-Catenin, PI3K/RAS, and oxidative stress signaling pathways as well as hot spot mutations in TP53 were frequently observed in hepatocarcinogenesis [3]. Orthotopic liver transplantation (OLT) is the most effective treatment option for patients with early diagnosis, albeit not suitable for advanced cases [4]. Despite the approval of two tyrosine kinase inhibitors, namely, sorafenib and regorafenib, for advanced cases, 5-year survival of HCC patients is only less than 20% [1].

Plexins comprise a large family of receptor proteins initially described in the nervous system [5]. Their ligands are semaphorins (Sema), a group of membrane-anchored or secreted proteins involved in several cellular functions including axon guidance, cell adhesion, and motility that altogether drive the development of tissues and organs [6]. Plexin receptors are characterized by their extracellular SEMA, PSI (Plexins, Semaphorins, and Integrins) and G-P (Glycine-Proline rich) domains and are divided into four subfamilies: Plexin A1-4, Plexin B1-3, Plexin C1, and Plexin D1 [5, 6]. Plexin C1, previously known as VESPR (Virus Encoded Semaphorin Protein Receptor), is a receptor for soluble viral semaphorin A39R originating from Vaccinia

virus, which stimulates cytokine production from monocytes [7]. Later on, Tamagnone et al. reported that human ligand for Plexin C1 is the GPI-anchored Semaphorin 7A (Sema 7A) [5]. Increased phospho-cofilin level but decreased focal adhesion kinase (FAK) phosphorylation upon binding of A39R to Plexin C1 on mouse dendritic cells induced actin cytoskeleton rearrangement, which resulted in the inhibition of integrin-mediated adhesion as well as impaired chemokine-induced migration *in vitro* [8]. However, Sema 7A binding to Plexin C1 on melanocytes increased phosphorylation of both cofilin and FAK and total LIMK2 protein levels as well. These findings suggested that Plexin C1 may act as a tumor suppressor during melanoma progression through phosphorylation-mediated inactivation of cofilin [9]. Interestingly, Plexin C1 was found to impede Sema 7A functions that emerge from its binding to β1Integrin, another receptor for Sema 7A. Plexin C1 inhibited Sema 7A-β1Integrin mediated events including spreading and dentricity of melanocytes [10], and migration capacity of GN11 immortalized mouse cells secreting GnRH-1 [11]. Like other Plexins, Plexin C1 has a RAS-GAP activity evidenced by the fact that COS-7 cells transfected with cytoplasmic region of Plexin C1 display decreased R-RAS activity and their ECM-mediated migration decreases in a ligand-independent manner [12]. Sema 7A mediated axon outgrowth was shown to be mediated through β1-Integrin and independent of Plexin C1 [13], yet upregulated Plexin C1 transcript levels were found in especially early phases of neuronal development of rats [14]. Immunohistochemistry studies revealed that 66% of the metastatic melanoma tissues are devoid of Plexin C1 protein expression, while nontumoral adjacent tissues have modest to high level of Plexin C1 [9]. In line with this, Stirewalt et al. have found that Acute Myeloid Leukemia (AML) cells display decreased *PLXNC1* transcript levels when compared to normal hematopoietic cells [15]. Besides its prominent role in nervous system development, the aforementioned studies indicated differential expression of Plexin C1 in human malignancies. However, the expression of Plexin C1 in HCC cell lines and tissues and its role in hepatocarcinogenesis have not been defined so far. Therefore, we investigated Plexin C1 expression at both transcriptional and protein levels in HCC and studied its expression pattern in liver tissues by using a homemade anti-Plexin C1 monoclonal antibody.

2. Materials and Methods

2.1. Cell Culture and Reagents. HCC cell lines PLC/PRF/5, HEP3B, HEPG2, HUH7, and SK-HEP1 were maintained in low-glucose DMEM medium supplemented with 10% fetal bovine serum (FBS), nonessential amino acids, and antibiotics. SNU387, SNU398, and SNU423 cells were cultured in RPMI medium supplemented with 10% FBS and antibiotics. HEK293T cell line, SP2/0 mouse myeloma cells, and monoclonal anti-Plexin C1 antibody-secreting hybridoma cells were cultured in high glucose DMEM supplemented with 10% FBS and antibiotics. All cells were grown in a humidified incubator maintained at 37°C and 5% CO_2 atmosphere.

2.2. In silico Analyses. Plexin C1 transcript levels in HCC were analyzed at Oncomine database (https://www.oncomine.org/resource/login.html) across "Chen Liver" microarray data filtered through "Hepatocellular Carcinoma vs. Normal" selection (104 HCCs vs. 76 liver tissues) [16]. In order to determine the expression of Plexin C1 transcript levels in epithelial vs. mesenchymal HCC cell lines, a search at "EMBL-EBI Expression Atlas" website (https://www.ebi.ac.uk/gxa/home) for *PLXNC1*, *CDH1*, *VIM*, and *PRKCA* genes on *Homo sapiens* dataset with "Cell Line" and "CCLE-Hepatocellular carcinoma" filters was accomplished. The output was downloaded and analyzed on R (3.3.3) to generate a heat map.

2.3. Production of shPLXNC1 Lentiviral Particles and Transduction PLC/PRF/5 Cells. Lentiviral particles were produced as follows: first, lentiviral *PLXNC1* shRNA (TRCN0000060645, Sigma-Aldrich, St. Louis, MO, USA) or control pLKO.1 (Addgene #8453) plasmids were mixed with packaging plasmids pCMV-dR8.2 dvrp (Addgene #8455) and pCMV-VSV-G (Addgene #8454) at a ratio of 1,5:1,5:1 in 250 μl Optimem (Thermo Fisher Scientific, Rockford, IL, USA). Then, a second mixture consisting of the transfection agent PEI (Polysciences, Germany), which was added to 250 μl Optimem at a ratio of 1:3 (DNA μg: PEI μl), was prepared. The two mixtures were assembled in a single tube to generate a transfection reagent, which was used to transfect HEK293T cells after incubation for 20 min at room temperature. After 36 hours, viral particles were harvested from the supernatant of the transfected cells, filtered through 0.45 μm, and stored at -80°C. $1.5x10^5$ PLC/PRF/5 cells plated into a 6-well plate were transduced with viral particles in the presence of 8 μg/ml Polybrene (Thermo Fisher Scientific). The next day, selection of transduced cells was initiated with the addition of 2 μg/ml puromycin (InvivoGen, San Diego, CA, USA) into the culture medium.

2.4. Production of the Recombinant Protein. A partial recombinant protein encompassing the extracellular 66-274 aa. of the protein was produced as previously described [17]. Briefly, the coding region of *PLXNC1* corresponding to extracellular protein domain between 66 and 274 aa was cloned into pET101/D (Invitrogen, Carlsbad, Ca, USA) vector with an N-terminal 6-histidine tag. Recombinant protein was produced in Escherichia coli (BL21) and purified under denaturing conditions using Ni–NTA resin (QIAgen, Valencia, CA, USA). Refolding of the purified protein was performed by buffer exchange to phosphate buffered saline (PBS) by using NAP buffer exchange columns (Amersham, Piscataway, NJ, USA). Finally, the pure recombinant protein was concentrated using Centripreps centrifugal filters (Millipore, Billerica, MA, USA).

2.5. Monoclonal Antibody Production. 8-10-week-old BALB/c mice were first immunized with 50 μg recombinant protein emulsified in Complete Freund's Adjuvant (Sigma-Aldrich) and then the following injections were carried out every 3 weeks with recombinant protein mixed with Incomplete Freund's Adjuvant (Sigma-Aldrich). Sera of the immunized

and control mice were tested for reactivity against recombinant Plexin C1 with indirect ELISA after third and fourth immunizations. Briefly, ELISA plates were coated with 100 ng of recombinant Plexin C1 protein in carbonate buffer (pH: 9,6). Mice sera were serially diluted and assessed for their immunoreactivity with Plexin C1 protein. Alkaline phosphatase-conjugated goat anti-mouse IgG (Sigma-Aldrich) was used as secondary antibody (1:1000). Colorimetric reaction developed upon addition of the substrate para-nitrophenyl-phosphate (Sigma-Aldrich) was measured at 405 nm in Varioscan Flash plate reader (Thermo Fisher Scientific). The mouse with the highest immunoreactivity against Plexin C1 was further boosted three days before the fusion. The fusion of freshly isolated splenocytes with SP2/0 myeloma cells was performed as described previously [18]. After fusion procedure, the cells were seeded in 96-well plates and then were selected first with HAT and then with HT. After single cell subcloning of the hybridoma cells, specific clones were expanded in culture and hybridomas were stored in liquid nitrogen. Antibody isotype was determined by Pierce Rapid Antibody Isotyping Kit (Thermo Fisher Scientific) according to manufacturer's instructions.

2.6. Purification of the Antibodies. Anti-Plexin C1 monoclonal antibodies were purified from hybridoma supernatants on AKTA-Purifier Chromatography (GE, Massachusetts, USA) using protein G affinity column (HiTrap protein G, GE). 50 ml hybridoma supernatant was loaded on the Protein G column, which was washed rigorously with sodium phosphate buffer (pH: 7,2). The bound antibodies were eluted with 0,1 M Glycine-HCI (pH: 2,7) and eluate fractions were neutralized with 50 μl 1.5 M Tris-HCI (pH: 9,5). Purified antibodies were stored in aliquots at -20°C.

2.7. Western Blotting. Cell lysates were prepared by incubating cells on ice for 20 min in Triton X-100 lysis buffer [50 mM Tris–HCl pH: 8.0, 150 mM NaCl, 1% Triton X-100 with complete protease inhibitor cocktail tablets (Roche Diagnostics, Mannheim, Germany)]. Cells were scraped, transferred to microcentrifuge tubes, and incubated for 20 min on ice with occasional shaking. Then, cell debris was discarded by centrifugation at 18000 g and protein-containing supernatants were collected and stored at -80°C until use. The protein concentration of the samples was determined by a fluorometric assay using Qubit 3 Flourometer (Thermo Fisher Scientific). 50 μg total protein samples were separated by SDS-PAGE gel and the transfer of proteins to PVDF membrane (Thermo Fisher Scientific) was performed with a semidry Trans-Blot Turbo Transfer System (Bio-Rad Laboratories, Hercules, Ca, USA). Membranes were first blocked with 5% skim milk in TBS containing 0.05% Tween-20 (TBS-T) and then were incubated overnight at 4°C with primary antibodies against Plexin C1 (1μg/ml, clone PE4) and α-tubulin antibodies (Cell Signaling Technology, 1:10000) for equal loading control. After washing 3 times with TBS-T, membranes were treated with the HRP-conjugated goat-anti-mouse IgG secondary antibody (Cell Signaling Technology, Danvers, MA, USA, 1:10000) and washed again with TBS-T for 3 times. Protein bands were developed by using the Chemiluminescent Substrate Supersignal West Femto ECL (Thermo Fisher Scientific) and visualized using a ChemiDoc XRS system (Bio-Rad).

2.8. Immunofluorescence Assay. $5x10^4$ cells were cultured on glass coverslips in 24-well plates overnight and fixed with 100% cold methanol on ice for 1 h. Fixed cells were blocked with 2% BSA in TBS for 45 min at room temperature. Cells were first incubated with the anti-Plexin C1 antibody (1:50) in blocking buffer containing 0.05% Tween-20 (BSA-T) for 1 h at room temperature and then with Alexa Fluor 488-conjugated anti-mouse IgG (Cell Signaling Technology) secondary antibody (1:500, in BSA-T) for 1 h at room temperature. After washing with PBS-Tween-20 the coverslips were mounted on glass slides with Prolong Gold antifade medium (Invitrogen) and sealed with nail polish. The staining was visualized using a Zeiss LSM 800 Airyscan Confocal Microscope (Zeiss, Germany).

2.9. RNA Isolation and RT-PCR. Total RNA was isolated from cell lines using a NucleoSpin RNA Plus kit (Macharey-Nagel, Düren, Germany). cDNAs were synthesized using a Protoscript M-MulV Taq RT-PCR kit (New England Biolabs, Massachusetts, USA) according to manufacturer's protocol. Real-time quantitative PCR (RT-qPCR) reactions were performed using a Maxima SYBR Green qPCR master mix (Thermo Fisher Scientific), including 0.2 μM primers and 50 ng cDNA in a total volume of 20 μl. The PCR reactions were started by an initial denaturation at 95°C for 10 min, followed by 45 cycles each consisting of 15 s denaturation at 95°C, 30 s annealing at 60°C, and 30 s extension at 72°C. Relative expression of *PLXNC1* mRNA in HCC cell lines was measured by normalizing *PLXCN1* expression to that of *GAPDH* and calculated with $2^{-\Delta Ct}$ formula [ΔCt = Ct (PLXNC1) - Ct (GAPDH)]. The primers for *PLXNC1* were 5′-AACTGTTCCCTTCCTTGACTAC-3′ and 5′-TCGTTGGCGTCTCTGTTATG-3′ and sequences of primers for *GAPDH* were 5′-GGCTGAGAACGGGAAGCTTGTCAT-3′ and 5′-CAGCCTTCTCCATGGTGGTGAAGA-3′.

2.10. Tissue Microarray (TMA) and Immunohistochemistry. In order to determine the protein levels of Plexin C1 *in vivo*, HCC TMA slides containing 90-paired tumoral and adjacent normal tissues were purchased from US Biomax (Rockville, MD, USA). Tissue array slides were deparaffinized first at 70°C and then in xylene. After rehydration in graded alcohol series, glass slides were immersed in 10 mM citrate buffer, pH 6.0, and transferred into a microwave oven for 20 min for antigen retrieval. Endogenous peroxidase was blocked by incubation of slides in 3% H_2O_2 for 30 min [17]. Immunohistochemical staining of the tissues was carried out in an autostainer (BenchMark-XT, Ventana Medical Technologies, Roche Diagnostics). Briefly, tissues were first incubated with the anti-Plexin C1 monoclonal antibody (1:100) or with isotype antibody (Cell Signaling Technology) for 30 min at room temperature, and then with the secondary HRP-conjugated

anti-mouse IgG antibody (Cell Signaling Technologies). The probed proteins were then visualized using chromogenic substrate 3,3′-diaminobenzidine (DAB) and examined under a Leica DM IL LED microscope (Leica Microsystems, NJ, USA). Photographs were taken with a microscope-attached Leica MC170 HD camera (Leica Microsystems). The level of Plexin C1 staining was determined by the histoscore (H-score) calculated by the multiplication of intensity score (0 = none, 1 = weak, 2 = moderate, and 3 = strong) with values representing the percentage of positively stained cells (0 = <10%; 1= 10-25%; 2= 25–50%; 3= 50 –75%; and 4= >75%). For chi-square analyses patients were grouped according to their H-score as follows: 0 = negative, 1-6 = weak, and 7-12 = strong.

2.11. Statistical Analyses. Paired Student's t-test was used for statistical analyses of immunohistochemistry scores. Chi-square analyses were performed to determine the correlation of Plexin C1 reactivity of HCC tumors with the clinicopathological characteristics of patients. Significant differences were denoted as follows: $*p < 0.05$, $**p < 0.01$, and $***p < 0.001$.

3. Results

3.1. In Silico Analyses of PLXNC1 Transcripts on HCC Cell Lines and Tissues. In order to determine *PLXNC1* expression levels in HCC, "Chen Liver" microarray dataset (containing 10,802 measured genes through 76 normal and 104 HCC samples) deposited on Oncomine database was analyzed [16]. *PLXNC1* mRNA expression was statistically higher (p=3.62e-20) in HCC tissues than in nontumoral adjacent tissues (Figure 1(a)). The differential expression of *PLXNC1* between HCC and normal tissues prompted us to investigate whether *PLXNC1* transcripts segregate the differentiation status of HCC cell lines. To this end, we explored on "EMBL-EBI Expression Atlas" database the expression of *PLXNC1* in HCC cell lines along with the epithelial marker *CDH1* and the mesenchymal markers *PRKCA* and *VIM* genes. Interestingly, *PLXNC1* expression clustered HCC cells with epithelial characteristics with a distinction capacity comparable to *CDH1*. In sharp contrast, no *PLXNC1* expression was found in HCC cells displaying a mesenchymal phenotype (Figure 1(b)).

3.2. Differential Expression of Plexin C1 in HCC Cell Lines. To expand our analyses of Plexin C1 expression in HCC cells and tissues, we generated a monoclonal antibody of IgG2a isotype against a partial recombinant protein encompassing 66-274 aa. of Plexin C1 extracellular domain. Designated as PE4, we tested the specificity of this monoclonal antibody in shPLXNC1 knockdown PLC/PRF/5 HCC cells (Figure 2(a)). Further, in immunofluorescence microscopy, PE4 stained the membrane of pLKO.1-PLC/PRF/5 but the signal disappeared upon silencing *PLXNC1* expression by lentiviral shPLXNC1 transduction (Figure 2(b)). Next, to validate *in silico* data, the relative expressions of *PLXNC1* were measured in HCC cell lines by RT-qPCR and the protein levels of Plexin C1 were detected with PE4 antibody in Western blotting experiments. Consistent with our findings in *in silico* analyses, we observed in both assays higher expression of Plexin C1 in PLC/PRF/5, HEP3B, HEPG2 and HUH7 HCC cells with epithelioid phenotype compared to its highly downregulated expressions in SNU387, SNU423, SNU398 and SK-HEP1 HCC cell lines with mesenchymal characteristics (Figure 3).

3.3. Plexin C1 Is Significantly Overexpressed in HCC Tissues. Finally, we turned to the analysis of Plexin C1 protein expression in HCC tissues. We performed immunohistochemical staining of TMA slides containing 90-paired spots of tumoral and nontumoral tissues of HCC patients. Hepatic cirrhosis and HCC coexisted in 16 tissues, but data on the etiological background of nontumoral liver and other HCC tissues was not available. The clinicopathological characteristics of patients are given in Supplement Table 1. PE4 antibody selectively stained the membrane of hepatocytes and HCC tumor cells (Figure 4(a)), and tumor tissues had significantly higher Plexin C1 protein levels (p=0.0118) than adjacent nontumoral areas (Figure 4(b)). Correlation analyses of Plexin C1 expression with clinicopathological characteristics of the samples did not show any correlation between the Plexin C1 levels of tissues and age, sex, stage and survival status of patients (Table 1). However, a significant correlation was found between Plexin C1 reactivity and the grade of HCC tumors ($p<0.05$). Grade I, Grade I-II and Grade II were considered as well-differentiated, and Grade II-III and Grade III were considered as poorly differentiated HCC tumors. Strong Plexin C1 staining was found in 66.15% and 55% of HCC cases with well-differentiated and poorly differentiated tumors, respectively. In contrast, weakly stained cases were higher in poorly differentiated compared to well-differentiated HCCs (36% vs. 13.85%).

4. Discussion

Hepatocellular carcinoma is the most common type of liver cancers with a very poor prognosis [19]. Currently, radiology, serum alpha-fetoprotein (AFP) levels and liver biopsy in advanced cases are used in clinical practice for the diagnosis of HCC [20–22]. Isoforms of AFP such as AFP-L3 and other markers including fucosylated Golgi Protein 73 (FC-GP73), α-l-fucosidase (AFU) and squamous cell carcinoma antigen (SCCA) have been evaluated in combination or as a single indicator and showed a sensitivity superior to AFP [23]. However, new serum and histologic markers are required to increase the sensitivity and specificity of HCC diagnosis. Plexin C1 was first discovered in the nervous system as an axon guidance receptor protein and was associated with neuronal cell adhesion [24, 25]. Engagement of Plexin C1 with its Sema7A ligand inhibited the spreading and dentricity of melanocytes [10]. In relation with this finding, an immunohistochemistry study in melanoma patients showed decreased levels of Plexin C1 protein in metastatic cases but its moderate to strong expression in non-metastatic melanoma and nevus tissues [9]. Recently, the interaction of Plexin C1 with its ligand Sema 7A was shown to inhibit pulmonary melanoma metastasis [26]. In addition, both Plexin C1 and its positive regulator GAS5, a long non-coding RNA, were downregulated in glioma tissues and cell lines

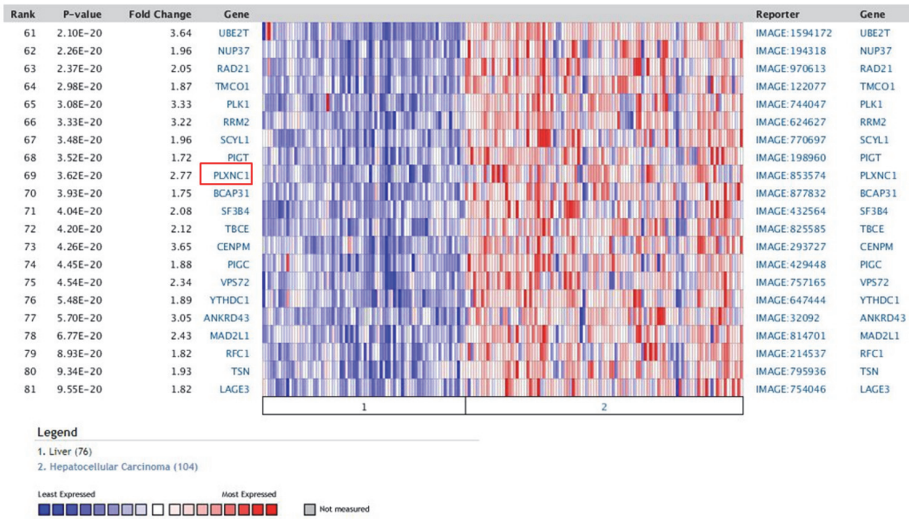

(a)

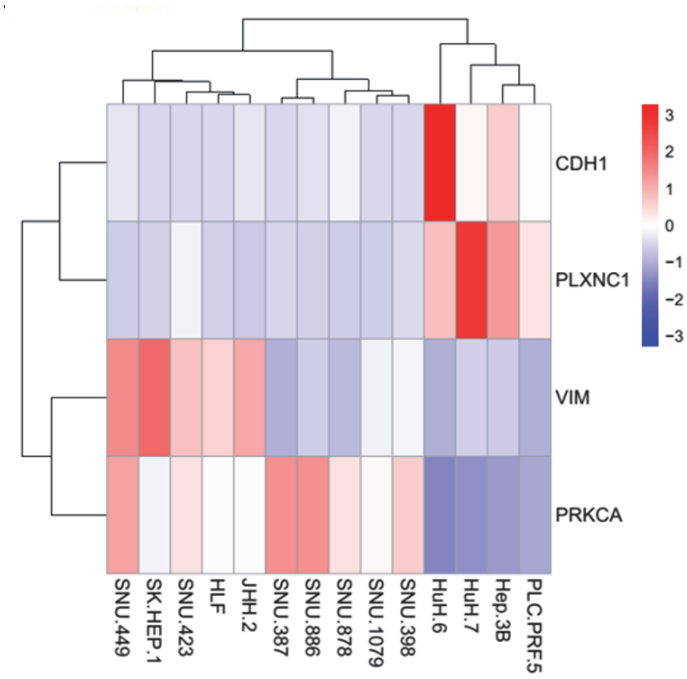

(b)

Figure 1: *In silico* analyses of *PLXNC1* expression. (a) Chen Liver microarray data compares the expression of 10802 genes between 104 HCC and 76 normal liver tissues. The mean of *PLXNC1* mRNA levels in HCCs is 2.77 fold higher than the mean of normal tissues. (b) Segregation of HCC *cell* lines with respect to their epithelial versus mesenchymal characteristics is analyzed on "EMBL-EBI Expression Atlas" database through the transcript levels of *PLXNC1*, *CDH1*, *PRKCA*, and *VIM* in HCC cells. HCC cells with epithelial phenotype include PLC/PRF/5, HEP3B, HUH7, and HUH6. HCC cell lines with mesenchymal phenotype are SNU398, SNU1079, SNU878, SNU886, SNU387, JHH2, HLF, SNU423, SK-HEP1, and SNU449.

[27]. Mechanistically, exogenous GAS5 inhibited miR222, a repressor of *PLXNC1*, and upregulated Plexin C1, which in turn inactivated cell motility protein cofilin. Therefore, compelling evidence was provided about the metastasis and tumor suppressor roles of Plexin C1 in human tumors. However, the expression profile of Plexin C1 in HCC and its role in hepatocarcinogenesis have not been elucidated so far.

After our initial observations through gene expression databases, namely, Oncomine and EMBL-EBI Expression Atlas, that *PLXNC1* is upregulated in HCC, we generated a monoclonal antibody, clone PE4, and demonstrated its specificity for Plexin C1 in *PLXNC1* knockdown and control cell clones by Western blotting and immunofluorescence. These results suggested a reactivity of PE4 with both denatured

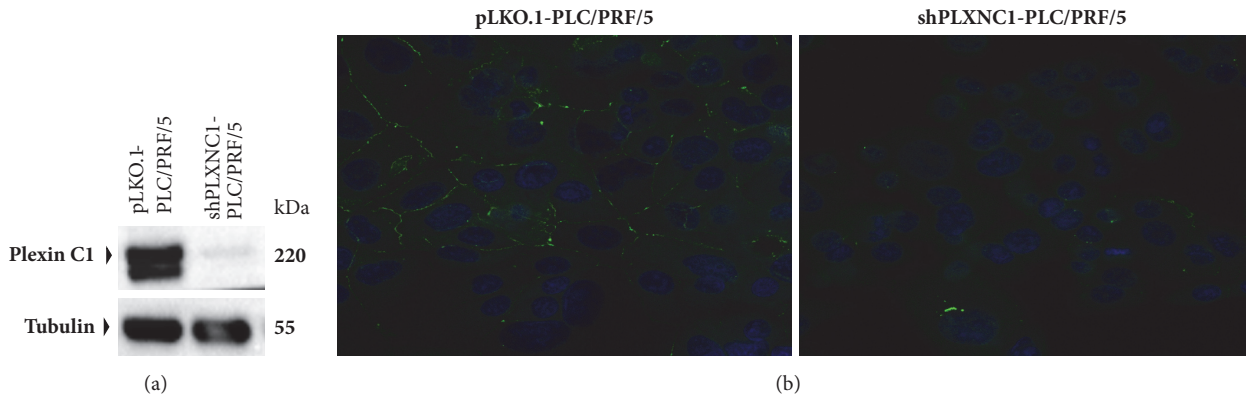

Figure 2: Validation of anti-Plexin C1 monoclonal antibody PE4. (a) Total proteins from PLC/PRF/5 cells transduced with shPLXNC1 and pLKO.1 empty control lentiviral particles are resolved on SDS-PAGE and Western blotting is carried out with the PE4 monoclonal antibody. Antitubulin monoclonal antibody is used for loading control. (b) Representative images from indirect immunofluorescence staining of pLKO.1-PLC/PRF/5 and shPLXNC1-PLC/PRF/5 cells with PE4 monoclonal antibody are shown.

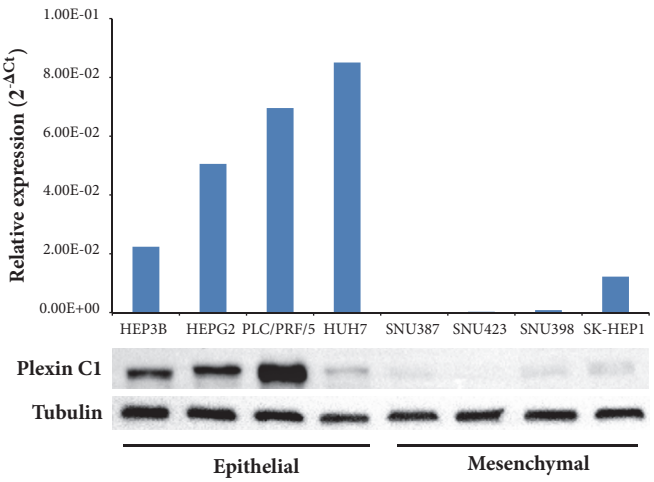

Figure 3: Expression of Plexin C1 transcripts and proteins in HCC cell lines. Epithelioid HEP3B, HEPG2, PLC/PRF/5, and HUH7 and fibroblast-like SNU387, SNU423, SNU398, and SK-HEP1 cells are analyzed. The upper diagram shows that the relative mRNA expression levels of *PLXNC1* and lower image display the protein expression profile of Plexin C1. Plexin C1 protein is detected using the PE4 monoclonal antibody. Tubulin is used for equal loading control.

and conformational forms of the protein. Exploration of mRNA and protein expression across HCC cell lines revealed that Plexin C1 clustered well-differentiated HCC cells with the epithelial phenotype. In contrast, HCC cells well known for their invasive behavior displayed barely detectable Plexin C1 levels [28]. These results were in line with the aforementioned reports indicating that Plexin C1 is a suppressor of cell motility and invasiveness, as well as with our *in silico* analyses showing increased expression of Plexin C1 in well-differentiated compared to poorly differentiated HCC cell lines. Plexin C1 expression in HCC and control liver tissues was assessed by immunohistochemistry studies using HCC tissue microarrays. Variable reactivity of PE4 with membrane Plexin C1 was observed in HCC and control tissues compared to nonreactive isotype control antibody staining. A statistically significant overexpression of Plexin C1 was found in HCC specimens compared to nontumoral adjacent liver tissues ($p<0.05$). In correlation analyses, we could not detect any association between Plexin C1 intensity and clinicopathological parameters such as age, sex, stage, cirrhosis background, and survival of patients. However, a significant correlation of Plexin C1 staining with grade of HCC tumors was found. As observed in the analysis of Plexin C1 expression in HCC cell lines, weakly stained tumors were higher in poorly differentiated HCCs (36%) compared to well-differentiated cases (13.85%). Despite the explicit difference of Plexin C1 expression between epithelial-like and mesenchymal-like HCC cell lines, both tumoral and nontumoral tissues of HCC cases displayed Plexin C1 reactivity, with a significant superiority of tumors to nonassociated tissues. However, the lower expression of Plexin C1 in high-grade tumors was in accordance with our *in vitro* observation that Plexin C1 segregates well-differentiated HCC cells. One can also speculate that HCC tumors do not

Table 1: Correlation of Plexin C1 staining with clinicopathological characteristics of the patients.

		Plexin C1 Staining			
	N	Negative	Weak	Strong	*P*
Age					
≤60	65	10 (15.38%)	12 (18.46%)	43 (66.15%)	
>60	25	5 (20%)	6 (24%)	14 (56%)	0.67
Gender					
F	16	3 (18.75%)	4 (25%)	9 (56.25%)	
M	74	12 (16.22%)	14 (18.92%)	48 (64.86%)	0.799
Stage					
1&2	52	11 (21.15%)	8 (15.38%)	33 (63.46%)	
3	31	4 (12.9%)	8 (25.81%)	19 (61.29%)	0.398
Grade					
Well-Differentiated	65	13 (20%)	9 (13.85%)	43 (66.15%)	
Poorly-Differentiated	25	2 (8%)	9 (36%)	14 (56%)	0.043
Disease Status					
HCC with cirrhosis	16	5 (31.25%)	2 (12.5%)	9 (56.25%)	
HCC	74	10 (13.51%)	16 (21.62%)	48 (64.86%)	0.204

N: number of cases. Correlation analyses were carried out with chi-square test. Plexin C1 staining was classified according to H-scores as follows: 0 = negative; 1-6 = weak; 7-12 = strong.

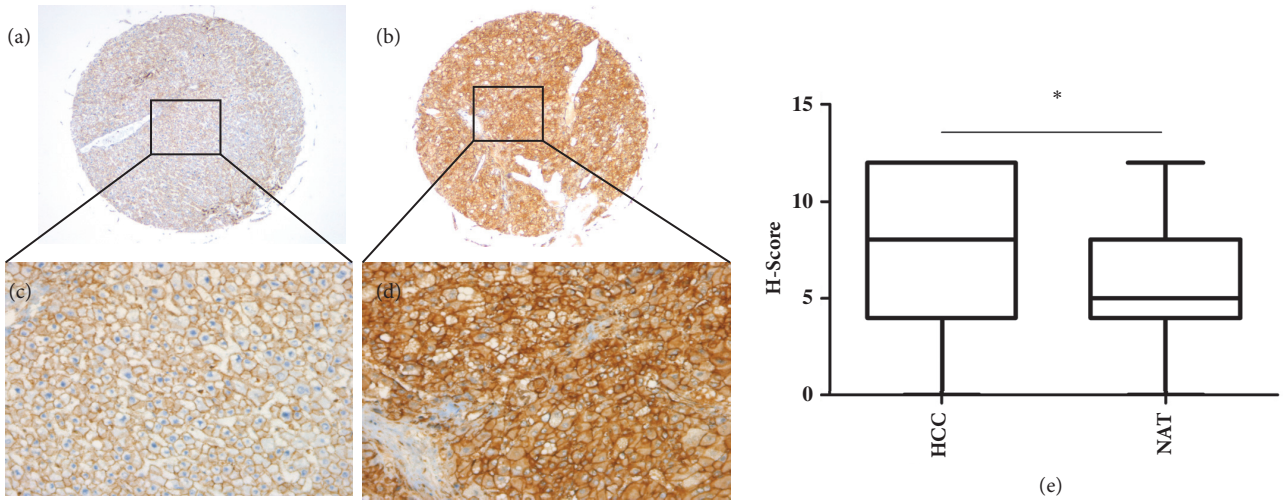

Figure 4: Immunohistochemical analysis of Plexin C1 in HCC and normal liver tissues. IHC is performed on HCC TMA. Representative images from nontumoral adjacent (a, c) and HCC tissues (b, d) are shown. The magnifications of the images are 50X for a and b and 200X for c and d. (e) H-scores of HCC and nontumoral adjacent tissues are compared with paired Student's t-test ($p<0.05$) and results are shown with box and whisker plots.

lose completely their epithelial characteristics and do not downregulate Plexin C1 extensively. Importantly, our results provide first evidence for the overexpression of Plexin C1 in tumors of epithelial origin. Specific membrane staining of Plexin C1 with PE4 antibody in paraffin-embedded HCC tissues further validated the usability of this monoclonal antibody for the study of Plexin C1 expression in other malignancies. Given the possibility of proteolytic ectodomain shedding of this receptor protein, screening of sera and tissues in a larger cohort of HCC patients may establish a diagnostic and/or prognostic value for Plexin C1.

5. Conclusions

In summary, we generated a monoclonal antibody specific for Plexin C1 capable to detect membrane-localized protein in paraffin-embedded tumor tissues. Our investigation of HCC cell lines and tissues revealed that Plexin C1 segregates HCC

tumors of epithelioid phenotype and is overexpressed in HCC tissues.

Data Availability

All data represented in this study are contained in the manuscript and supplementary information.

Conflicts of Interest

The authors declare that there are no conflicts of interest regarding the publication of this paper.

Acknowledgments

This study was supported by a grant from Turkish Association of Oncology Group to Tamer Yagci [Grant no. TOG_2014-1].

Supplementary Materials

Supplement Table 1: Clinicopathological characteristics of patients included in Tissue Microarray consist of age, sex, tumor grade, TNM staging, histopathological diagnosis, and survival data. NAT: nonassociated tissue *(Supplementary Materials)*

References

[1] S. L. Chan, A. M. Wong, K. Lee, N. Wong, and A. K. C. Chan, "Personalized therapy for hepatocellular carcinoma: Where are we now?" *Cancer Treatment Reviews*, vol. 45, pp. 77–86, 2016.

[2] A. Forner, M. Reig, and J. Bruix, "Hepatocellular carcinoma," *The Lancet*, vol. 391, no. 10127, pp. 1301–1314, 2018.

[3] C. Ozen, G. Yildiz, A. T. Dagcan et al., "Genetics and epigenetics of liver cancer," *New Biotechnology*, vol. 30, no. 4, pp. 381–384, 2013.

[4] A. Raza and G. K. Sood, "Hepatocellular carcinoma review: Current treatment, and evidence-based medicine," *World Journal of Gastroenterology*, vol. 20, no. 15, pp. 4115–4127, 2014.

[5] L. Tamagnone, S. Artigiani, H. Chen et al., "Plexins are a large family of receptors for transmembrane, secreted, and GPI-anchored semaphorins in vertebrates," *Cell*, vol. 99, no. 1, pp. 71–80, 1999.

[6] M. Negishi and I. Oinuma, "Semaphorin Receptors and Their Signaling," in *Semaphorins*, A. Kumanogoh, Ed., Springer, Tokyo, 2015.

[7] M. R. Comeau, R. Johnson, R. F. DuBose et al., "A poxvirus-encoded semaphorin induces cytokine production from monocytes and binds to a novel cellular semaphorin receptor, VESPR," *Immunity*, vol. 8, no. 4, pp. 473–482, 1998.

[8] T. Walzer, L. Galibert, M. R. Comeau, and T. De Smedt, "Plexin C1 engagement on mouse dendritic cells by viral semaphorin A39R induces actin cytoskeleton rearrangement and inhibits integrin-mediated adhesion and chemokine-induced migration," *The Journal of Immunology*, vol. 174, no. 1, pp. 51–59, 2005.

[9] G. A. Scott, L. A. McClelland, A. F. Fricke, and A. Fender, "Plexin C1, a receptor for semaphorin 7a, inactivates cofilin and is a potential tumor suppressor for melanoma progression," *Journal of Investigative Dermatology*, vol. 129, no. 4, pp. 954–963, 2009.

[10] G. A. Scott, L. A. McClelland, and A. F. Fricke, "Semaphorin 7a promotes spreading and dendricity in human melanocytes through β1-integrins," *Journal of Investigative Dermatology*, vol. 128, no. 1, pp. 151–161, 2008.

[11] A. Messina, N. Ferraris, S. Wray et al., "Dysregulation of semaphorin7A/β1-integrin signaling leads to defective GnRH-1 cell migration, abnormal gonadal development and altered fertility," *Human Molecular Genetics*, vol. 20, no. 24, Article ID ddr403, pp. 4759–4774, 2011.

[12] K. Uesugi, I. Oinuma, H. Katoh, and M. Negishi, "Different requirement for Rnd GTPases of R-Ras GAP activity of Plexin-C1 and Plexin-D1," *The Journal of Biological Chemistry*, vol. 284, no. 11, pp. 6743–6751, 2009.

[13] R. J. Pasterkamp, J. J. Peschon, M. K. Spriggs, and A. L. Kolodkin, "Semaphorin 7A promotes axon outgrowth through integrins and MAPKs," *Nature*, vol. 424, no. 6947, pp. 398–405, 2003.

[14] R. J. Pasterkamp, S. M. Kolk, A. J. C. G. M. Hellemons, and A. L. Kolodkin, "Expression patterns of semaphorin7A and plexinC1 during rat neural development suggest roles in axon guidance and neuronal migration," *BMC Developmental Biology*, vol. 7, article no. 98, 2007.

[15] D. L. Stirewalt, S. Meshinchi, and K. J. Kopecky, "Identification of genes with abnormal expression in AML," *Genes, Chromosomes & Cancer*, vol. 47, no. 1, pp. 8–20, 2008.

[16] D. R. Rhodes, J. Yu, K. Shanker et al., "ONCOMINE: a cancer microarray database and integrated data-mining platform," *Neoplasia*, vol. 6, no. 1, pp. 1–6, 2004.

[17] E. Oztas, M. E. Avci, A. Ozcan, A. E. Sayan, E. Tulchinsky, and T. Yagci, "Novel monoclonal antibodies detect Smad-interacting protein 1 (SIP1) in the cytoplasm of human cells from multiple tumor tissue arrays," *Experimental and Molecular Pathology*, vol. 89, no. 2, pp. 182–189, 2010.

[18] H. Celikkaya, C. Ciraci, E. Oztas, M. E. Avci, M. Ozturk, and T. Yagci, "Immunization with UV-induced apoptotic cells generates monoclonal antibodies against proteins differentially expressed in hepatocellular carcinoma cell lines," *Hybridoma*, vol. 26, no. 2, pp. 55–61, 2007.

[19] R. Cabrera and D. R. Nelson, "Review article: The management of hepatocellular carcinoma," *Alimentary Pharmacology & Therapeutics*, vol. 31, no. 4, pp. 461–476, 2010.

[20] X. Wang and Q. Wang, "Alpha-Fetoprotein and Hepatocellular Carcinoma Immunity," *Canadian Journal of Gastroenterology and Hepatology*, vol. 2018, Article ID 9049252, 8 pages, 2018.

[21] S. L. Chan, F. Mo, P. J. Johnson et al., "Performance of serum α-fetoprotein levels in the diagnosis of hepatocellular carcinoma in patients with a hepatic mass," *HPB*, vol. 16, no. 4, pp. 366–372, 2014.

[22] S. Shah, A. Shukla, and B. Paunipagar, "Radiological Features of Hepatocellular Carcinoma," *Journal of Clinical and Experimental Hepatology*, vol. 4, pp. S63–S66, 2014.

[23] Y. J. Zhao, Q. Ju, and G. C. Li, "Tumor markers for hepatocellular carcinoma," *Molecular and Clinical Oncology*, vol. 1, no. 4, pp. 593–598, 2013.

[24] S. Takagi, T. Tsuji, T. Amagai, T. Takamatsu, and H. Fujisawa, "Specific cell surface labels in the visual centers of Xenopus laevis tadpole identified using monoclonal antibodies," *Developmental Biology*, vol. 122, no. 1, pp. 90–100, 1987.

[25] K. Ohta, A. Mizutani, A. Kawakami et al., "Plexin: A novel neuronal cell surface molecule that mediates cell adhesion via a homophilic binding mechanism in the presence of calcium ions," *Neuron*, vol. 14, no. 6, pp. 1189–1199, 1995.

[26] B. Ma, E. L. Herzog, C. G. Lee et al., "Role of chitinase 3-like-1 and semaphorin 7a in pulmonary melanoma metastasis," *Cancer Research*, vol. 75, no. 3, pp. 487–496, 2015.

[27] X. Zhao, P. Wang, J. Liu et al., "Gas5 Exerts Tumor-suppressive Functions in Human Glioma Cells by Targeting miR-222," *Molecular Therapy*, vol. 23, no. 12, pp. 1899–1911, 2015.

[28] H. Yuzugullu, K. Benhaj, N. Ozturk et al., "Canonical Wnt signaling is antagonized by noncanonical Wnt5a in hepatocellular carcinoma cells," *Molecular Cancer*, vol. 8, article no. 1476, p. 90, 2009.

Hindawi
Canadian Journal of Gastroenterology and Hepatology
Volume 2018, Article ID 8543763, 9 pages
https://doi.org/10.1155/2018/8543763

Review Article

Molecular Pathogenesis of Nonalcoholic Steatohepatitis- (NASH-) Related Hepatocellular Carcinoma

Ozlem Kutlu,[1,2] **Humeyra Nur Kaleli**,[3] **and Ebru Ozer**[3]

[1]*Nanotechnology Research and Application Center, Sabanci University, Istanbul, Turkey*
[2]*Center of Excellence for Functional Surfaces and Interfaces for Nano Diagnostics (EFSUN), Sabanci University, Istanbul, Turkey*
[3]*Molecular Biology, Genetics and Bioengineering Program, Faculty of Engineering and Natural Sciences, Sabanci University, Istanbul, Turkey*

Correspondence should be addressed to Ozlem Kutlu; ozlemkutlu@sabanciuniv.edu

Received 12 June 2018; Accepted 12 August 2018; Published 29 August 2018

Academic Editor: José L. Mauriz

The proportion of obese or diabetic population has been anticipated to increase in the upcoming decades, which rises the prevalence of nonalcoholic fatty liver disease (NAFLD) and its progression to nonalcoholic steatohepatitis (NASH). Recent evidence indicates that NASH is the main cause of chronic liver diseases and it is an important risk factor for development of hepatocellular carcinoma (HCC). Although the literature addressing NASH-HCC is growing rapidly, limited data is available about the etiology of NASH-related HCC. Experimental studies on the molecular mechanism of HCC development in NASH reveal that the carcinogenesis is relevant to complex changes in signaling pathways that mediate cell proliferation and energy metabolism. Genetic or epigenetic modifications and alterations in metabolic, immunologic, and endocrine pathways have been shown to be closely related to inflammation, liver injury, and fibrosis in NASH along with its subsequent progression to HCC. In this review, we provide an overview on the current knowledge of NASH-related HCC development and emphasize molecular signaling pathways regarding their mechanism of action in NASH-derived HCC.

1. Introduction

Hepatocellular carcinoma (HCC) is an aggressive cancer with poor prognosis and its incidence increases exponentially in developing countries. The most common underlying causes of HCC are chronic liver diseases and cirrhosis, largely occurring due to hepatitis B, hepatitis C virus (HCV), or alcoholic liver disease [1]. In recent years, nonalcoholic fatty liver disease (NAFLD) also becomes one of leading etiologies for HCC. NAFLD is a spectrum of liver diseases ranging from simple steatosis to liver injury. The initial stage of an inflammatory phase in NAFLD is defined as nonalcoholic steatohepatitis (NASH) [2]. NASH is characterized by inflammation, hepatocellular damage, and fibrosis, which increase the risk of HCC with high rates of mortality (Figure 1). The emergence of HCC in NASH patients with or without cirrhosis is still controversial, such that HCC can also be seen in NASH patients without cirrhosis [3].

The progression of NASH-related HCC is a complex and multifactorial process, including several risk factors such as genomic instability, obesity, or diabetes [4, 5]. Involvement of the mechanisms related to these factors appears to cause changes in some common signaling pathways that lead to transition of dysplastic hepatocytes into hepatocellular carcinoma. Currently, the proposed mechanisms include genetic, metabolic, immunologic, and endocrine pathways, which subsequently activate oncogenic mechanisms [6] (Figure 2). In this review, we attempt to summarize recent knowledge in NASH progression and particularly focus on molecular signaling pathways involved in the conversion of NASH into hepatocarcinogenesis.

2. Cellular Mechanisms in NASH Progression

Clinical and epidemiological studies support a concept that multiple mechanisms derive NAFLD, NASH, and HCC

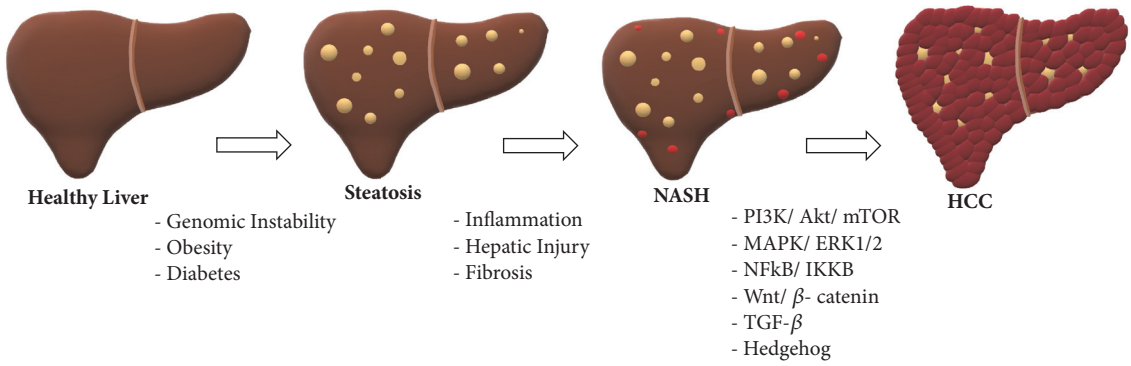

Figure 1: Development of NASH and HCC from healthy liver.

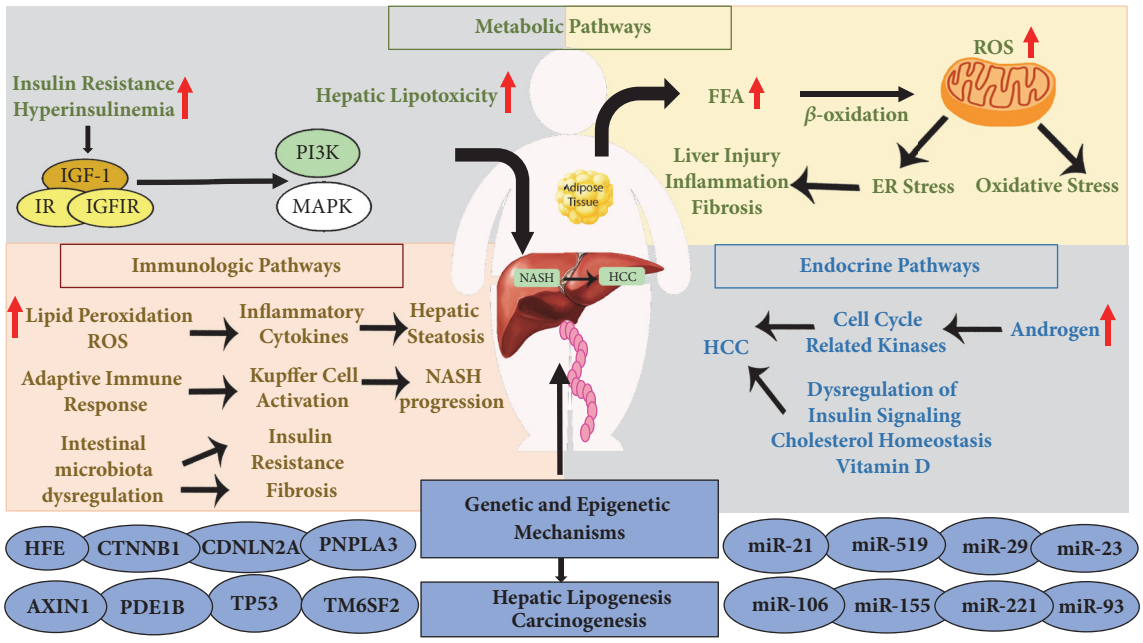

Figure 2: The proposed mechanisms in NASH-related HCC progression.

development. So far, the detailed mechanism of the progression from NAFLD to NASH has not been completely explained, yet a "two-hit hypothesis" was initially proposed [7, 8]. According to this hypothesis, the first hit was insulin resistance, and steatosis was the initiative cause of NASH progression [9]. Insulin resistance enhances lipolysis and increases the level of serum free fatty acid (FFA). Elevation of FFA leads to delivering triglycerides from the liver to peripheral organs, which induce hyper-synthesis of lipid thus causing excessive lipid storage in the liver, called steatosis. Meanwhile, accumulation of triglycerides promotes the appearance of the second hit, oxidative stress, that shows steatohepatitis because of increased level of fatty acid oxidation [10]. Oxidative stress triggers lipid peroxidation, release of proinflammatory molecules, and mitochondrial damage [11], which are the cellular mechanisms involved in the formation of hepatocellular damage, inflammation, and fibrosis in NASH pathology [12, 13].

Even though a large number of researches have supported the two-hit hypothesis, it is still unclear whether NASH develops sequentially on the background of a fatty liver, or it is rather a de novo response to the accumulated lipotoxicity. Instead of the two-hit hypothesis, there is a new consensus on the multiparallel hit theory, which better explains NASH development and its progression to HCC [14]. This theory suggests that NASH is the consequence of numerous conditions acting in parallel, including genetic variations, abnormal lipid metabolism, oxidative and/or endoplasmic reticulum stress, mitochondrial dysfunction, altered immune responses, and imbalance in gut microbiota [15]. According to this theory, hepatic inflammation is the first cause of fibrosis progression in NASH rather than steatosis [16]. The following section will focus on detailed mechanisms at molecular level and their related signaling pathways in NASH-dependent HCC progression (Figures 3 and 4).

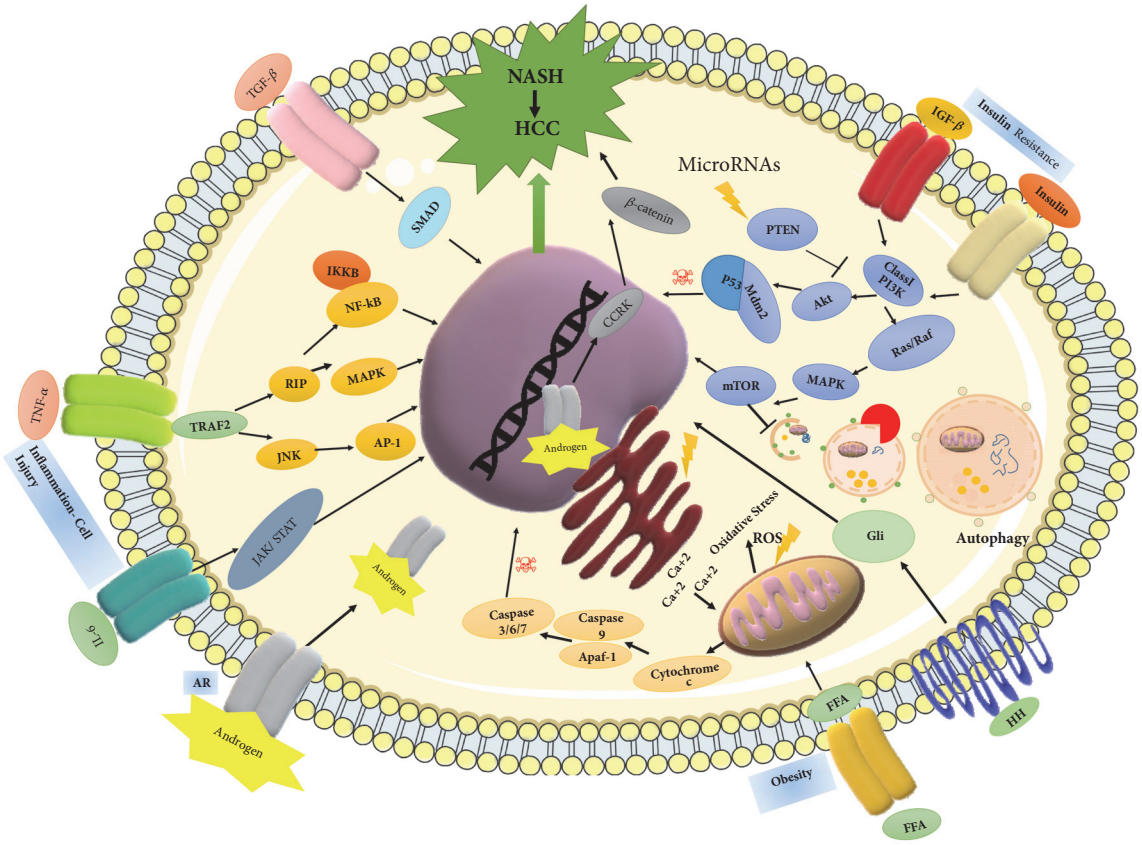

Figure 3: Molecular signaling pathways involved in NASH-related HCC.

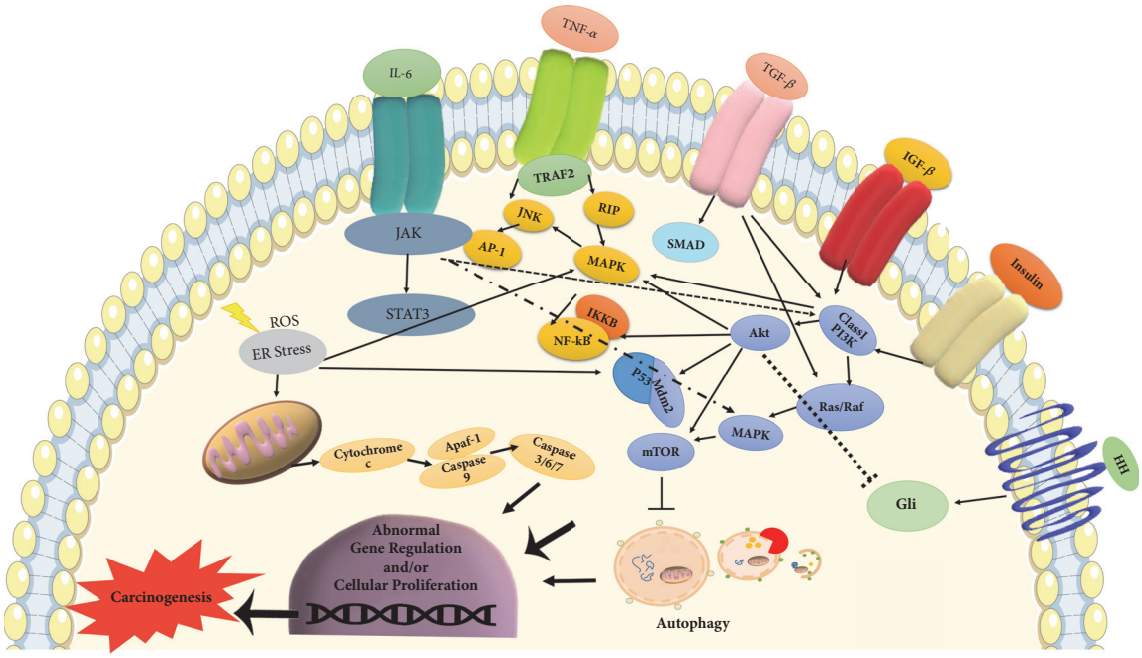

Figure 4: Interaction of oncogenic pathways in NASH-HCC progression.

3. Molecular Mechanisms Involved in NASH-Related HCC

3.1. Genetic and Epigenetic Mechanisms. Recent advances in genetic technology allow obtaining comprehensive data on the genetic alterations associated with HCC. Differential gene expression results from gene mutations in regulatory elements or epigenetic changes, which plays an important role in susceptibility to the development of HCC.

Genetic mutation in the gene encoding patatin-like phospholipase domain-containing protein 3 (PNPLA3) on chromosome 22 is a well-known factor in NASH-related HCC progression [17]. The variant (rs738409 c.444 C>G, p.I148M) causes a cytosine to guanine mutation resulting in isoleucine to methionine conversion. This mutation correlates with increased lipid accumulation in liver and predisposes individuals to fatty liver-associated diseases, from simple steatosis to steatohepatitis, NASH, and HCC [18]. Although the physiological and biological functions of PNPLA3 within the liver are not fully elucidated, the association of PNPLA3 mutations with HCC is evident [19]. Overexpression of I148M variant in mouse liver promotes accumulation of triacylglycerol, increases synthesis of fatty acids, and impairs triacylglycerol hydrolysis [20]. Moreover, the PNPLA3 genotype has been reported to influence liver storage of retinol and retinol serum levels in obese subjects [21] suggesting a potential role of PNPLA3 in regulating retinol metabolism and hepatic stellate cells (HSCs) biology. Similarly, PNPLA3 has been shown to be expressed in HSCs [22], but its role in HCC progression in these cells still needs to be investigated [23]. There is an increased prevalence of another mutation in the transmembrane 6 superfamily member 2 gene (TM6SF2) in NASH patients. Carriage of a genetic variant in TM6SF2 (rs58542926 c.449 C>T, p.E167K) on chromosome 19 (19p13.11) has been reported to correlate with steatosis and advanced fibrosis in NASH patients [24, 25], independently of diabetes, obesity, or PNPLA3 genotype. Although, conflicting data exists regarding its role in HCC progression, the TM6SF2 variant is thought to be associated with liver injury in NASH-related HCC pathogenesis [26]. Hemochromatosis gene (HFE) mutations (C282Y and H63D) in NASH increased the susceptibility to more severe form of disease with fibrosis or cirrhosis [27, 28] and implicated HCC development in these patients. Particularly, H63D mutation was found in noncirrhotic HCC and led to hepatic inflammation, fibrosis, and carcinogenesis due to increased iron load in these patients [29]. Recently, the rs641738 genotype, encoding the membrane bound O-acyltransferase domain-containing 7 (MBOAT7), was associated with more severe liver damage and increased risk of fibrosis in NASH patients; however, these findings need further investigation regarding HCC progression [30, 31]. In addition to various single mutations, the genetic instability in NASH patients was reported much higher than in NAFLD patients, and this was considered as one of the inducements for NASH-related HCC. Quantitative analysis revealed abundant amplifications of DNA, where the genes involved in oncogenic mechanisms are located. These genes encode telomerase reverse transcriptase (TERT), vascular endothelial growth factor A (VGFA), MET, and MYC proteins that are known to have a role in tumor growth. Moreover, exome-sequencing analysis of HCC showed the highest prevalence of mutation in oncogenic genes, like CTNNB1, AXIN1 (involved in β-catenin/WNT signaling pathway), albumin (ALB), TP53, and CDKN2A [32]. Furthermore, differential expressions of the exportin 4 (XPO4) and phosphodiesterase 1B (PDE1B) genes were identified in HCC as well as in NASH; however, the physiological role of these genes in NASH-related HCC is still unknown [33, 34].

Epigenetic changes, causing aberrant DNA methylation, have been considered another important mechanism in NASH progression [35]. It occurs through the enzyme methyltransferases (DNMTs), leading to silence of genes related to DNA damage and repair, lipid and glucose metabolism, and fibrosis progression [36]. The methylation of the CpG island near the PDE1B gene was shown to be linked with survival in HCC patients; nevertheless, the only epigenetic change that has clearly been linked to NASH-related HCC is the gene encoding chromodomain helicase DNA-binding protein 1 (CHD1) [37].

MicroRNAs (miRNAs) are endogenous, small noncoding RNAs, having a role in the regulation of gene expression. Convincing evidence showed that expression of miRNAs is dysregulated in many cancers through various mechanisms and they may function as either oncogenes or tumor suppressors under certain conditions [38]. So far, no studies have yet significantly focused on miRNA expression in human NASH-associated HCC; however, genome-wide analysis revealed 23 miRNAs, differentially expressed in NASH patients. Among them, liver specific miR-122 expression is reduced in NASH patients and, thus, negatively regulates hepatic lipogenesis [39]. Downregulation of miR-122 was also demonstrated in a mouse model of NASH-HCC, indicating direct role of this miRNA in NASH-associated HCC [40]. To date, most of the studies indicate a critical role of several miRNAs (miR-21, miR-29, miR-23, miR-155, miR-221, miR-222, miR-106, miR-93, miR-519) in NASH-associated carcinogenesis [32]. Strikingly, altered expression of these miRNAs have been found to be involved in major hepatocarcinogenic pathways, including the TGF-β, Wnt/β-catenin, mitogen-activate protein kinase (MAPK), and phosphatidylinositol 3-kinases (PI3K)/AKT/mTOR that regulate proliferation and energy metabolism in the cell [41]. Importantly, several of these miRNAs target the main inhibitor of the PI3K/AKT pathway, PTEN protein, and its mutations were found in HCC patients [42]. In accordance, PTEN deficient mice have been shown to develop steatosis, hepatomegaly, and HCCs [43, 44].

3.2. Metabolic Pathways. The common association of high-fat diet, obesity, and diabetes with NASH and HCC pathogenesis indicates that the molecular link between energy balance and cell cycle control in hepatocytes is the key mechanism for the progression of NASH-related HCC. Indeed, these metabolic factors are closely related to insulin resistance and hyperinsulinemia, which activates insulin receptor signaling via PI3K and MAPK pathway.

Experimental evidence indicated that insulin resistance and hyperinsulinemia increased the expression of insulin and insulin-like growth factor-1 (IGF-1) [45]. Binding of insulin or IGF-1 to their respective receptors, namely, insulin receptor (IR) and insulin-like growth factor-1 receptor (IGF1R), triggers signaling cascade via insulin receptor substrate-1 (IRS-1) that results in activation of its downstream PI3K and MAPK pathways. In fact, these pathways play a significant role in the carcinogenesis of HCC by induction of cell proliferation and inhibition of apoptosis [46, 47]. The role of PI3K pathway in the progression of HCC is mainly mediated by its effect on cyclin D1-dependent cell cycle, Mdm2/p53-dependent apoptosis, and mTOR-dependent cell growth [48]. On the other hand, MAPK pathway affects cell growth by inducing the transcription of protooncogenes, c-fos, and c-jun. In addition, MAPK pathway eventually activates the Wnt/β-catenin signaling cascade, which leads to fibrosis and carcinogenesis in liver [49].

Another important consequence of insulin resistance is excessive lipid accumulation in liver. In other words, imbalance in energy metabolism increases hepatic lipotoxicity, resulting in excessive production of FFAs [50]. Indeed, β-oxidation of these FFAs in mitochondria induces the formation of reactive oxygen species (ROS). Overproduction of ROS causes respiratory chain disruption and further functional defect in mitochondria, which is the main event for cytochrome c release and triggering apoptotic death signal. Recently, RIP1- and RIP3-activated JNK (Jun-(N)-terminal kinase) has been proposed as an apoptotic pathway responsible for the emergence of liver injury, inflammation, and fibrosis in NASH patients as well as in mouse model of steatohepatitis [51, 52].

Insulin signaling and lipotoxicity in mitochondria are connected to several other mechanisms, such as oxidative and endoplasmic reticulum (ER) stress, that contribute to hepatic cell injury and ultimately carcinogenesis in NASH [53]. Certainly, there is significant cross-talk between ROS production, oxidative and/or ER stress, and cell death mechanisms, correlating to the development of progressive disease conditions in NASH and HCC. ROS and oxidative stress disrupt ER functions via increased release of calcium from ER stores. Excess amount of calcium level induces mitochondrial and lysosomal permeabilization, which in turn increased further mitochondrial ROS release and potentiate sequential activation of proapoptotic pathway initiated by executive caspases 9 and 3 [54, 55]. Under normal catabolic condition in cells, the superoxides (incompletely reduced forms of oxygen) are converted into nontoxic water by glutathione peroxidase and catalase. The biochemical function of these enzymes is to protect the organism from oxidative damage by reducing the amount of free hydrogen peroxide. The level of iron is an important factor for glutathione peroxidase and catalase activities, which is upregulated during intake of excess iron; otherwise, it induces oxidative stress by enhancing FA oxidation. Accordingly, elevated level of iron is observed in NASH patients and considered as a risk factor for HCC development [56].

Autophagy is one of the important stress response pathways in cells, supporting cell survival by recycling metabolic components. This mechanism reduces cytosolic organelles or macromolecules by sequestering them in double-membrane vesicles and delivering them to the lysosomes for degradation. Recent discoveries showed a molecular connection between lipolysis and autophagy mechanisms. In the liver, autophagy suppresses protein aggregate, lipid accumulation, oxidative stress, chronic cell death, and inflammation. On the contrary, autophagy regulates adipogenesis and adipose tissue differentiation [57]. Now, the emerging role of autophagy in NASH and NASH-derived HCC is a double-edged sword. On the one hand, autophagy enables the hepatocytes to tolerate stress and promote tumorigenesis. On the other hand, autophagy plays an important role in damage mitigation in response to stress that can limit tumorigenesis [58, 59]. Although there is controversy whether autophagy promotes or inhibits NASH progression, its role in energy metabolism via PI3K/mTOR pathway strongly supports the idea that autophagy may be an ideal candidate for therapeutic purposes. Therefore, further investigations are needed to determine the exact role of autophagy in NASH-associated HCC.

3.3. Immunologic Pathways. Mitochondrial dysfunction and stimulation of stress mediators not only facilitate the production of ROS, but also contribute to the progression of HCC by immune reactions. Insulin resistance and oxidative stress stimulate IKKβ- (inhibitor of kappa light polypeptide gene enhancer in B-cells, kinase beta) dependent NF-κB (nuclear factor kappa-light-chain-enhancer of activated B-cells) signaling pathway and promote hepatocyte survival in addition to their crucial role in liver inflammatory responses [60]. It has been shown that ROS along with products of lipid peroxidation increases the release of several inflammatory and inhibitory cytokines such as tumor necrosis factor-alpha (TNF-α), interleukin-6 (IL-6), leptin, and adiponectin [61]. TNF-α activates prooncogenic pathways via JNK and IKKβ that promote the synthesis of AP-1 and NF-κB. Phosphorylation and subsequent degradation of IKKβ lead to the nuclear entry of NF-κB, triggering inflammatory cascades, which in turn aggravate NF-κB activation. Extracellular lipid can also activate IKKβ by engaging TLRs (Toll-like receptors). The TLR-deficient mice studies revealed the attenuation of severe steatosis, indicating TLR as an important proinflammatory mediator in NASH progression [62]. On the other hand, IL-6 activates STAT-3 (signal transducer and activator of transcription 3), an oncogenic transcription factor that induces cell proliferation and antiapoptotic pathways, and was found to be important for NASH-related HCC development [63]. Leptin has been described as profibrotic and proangiogenic factor in liver carcinogenesis by initiating an intracellular signaling cascade of proinflammatory cytokines (TNF-α and IL-6). Moreover, binding of leptin to its respective receptor in HCC cells activates JAK2/STAT, MAPK, and PI3K signaling pathways [64]. Interestingly, leptin has also been shown to upregulate the TERT and thereby lead to immortalization of tumor cells in HCC [65]. Adiponectin is an anti-inflammatory cytokine, specifically produced in adipose tissue. Under normal physiological conditions, it inhibits angiogenesis via

modulation of apoptosis [66]. However, insulin resistance reduced level of adiponectin and the release of TNF-α and IL-6 that further inhibit adiponectin production and thus potentiate HCC development [67]. Adiponectin and leptin act antagonistically on liver fibrogenesis and inflammation [68]. However, reports of serum levels of adiponectin and the expression of its receptor are inconsistent [69]. Therefore, further investigations are necessary to clarify the function of adipokines in NASH and HCC development.

Immune activation is a prerequisite for the development of NASH, which is also linked to adaptive immune responses. In several animal models, the potential role of CD8+ T-lymphocytes, and CD4+ T-lymphocytes in liver damage and carcinogenesis was demonstrated [70, 71]. Moreover, liver damage stimulates the recruitment of different types of immune cells to the site of injury. Kupffer cell (KC) activation is critical in NASH and precedes the recruitment of other cells, therefore contributing to NASH progression [72]. In NASH, a number of ligands and cytokines can also activate Natural Killer (NK) cells; however, data obtained from animal models are contradictory, indicating that two different phenotypes of NK cells have been associated with liver disease and act oppositely during inflammation [73, 74]. The involvement of adaptive immune system was demonstrated in response to liver injury and inflammation, but its exact role in NASH-related HCC is still unknown.

Acute cell injury triggers another signaling pathway, Hedgehog, a complex cellular pathway for liver repair and regeneration. This pathway induces mobilization of hepatic progenitor cells at the site of injury and replaces damaged hepatocytes [75]. Current data suggest that abnormal Hedgehog signaling results in dysregulated cellular repair and malignant transformation in HCC progression. Moreover, the development of HCC has been described as a contrary function of Hedgehog pathway, in which hyperactivation of progenitor cells could survive independently from regulation of NF-κB, thereby being less susceptible to NF-κB-driven apoptosis [76].

The gut microflora plays an important role in the development and function of the host immune system. Through the portal circulation, liver is directly exposed to gut-derived products, being the first line of defense against bacterial toxins [77]. The studies in both animal models and human showed that alteration in intestinal microflora triggers an immune response, inflammation, and immune cell infiltration of liver and adipose tissue. Modulation of gut microbiota induces insulin resistance by inhibiting expression of gut-secreted anorectic hormones, such as GLP-1 and PYY. In addition, the reduced expression of a LPL- (lipoprotein lipase-) suppressor FIAF (fasting-induced adipose factor) prevents FA release leading to FA and triglyceride accumulation [78]. The shift on the bacterial community prevalence in gut microbiota results in release of pathogen-associated molecular patterns (PAMPs). PAMPs are recognized by TLRs and other pattern recognition receptors (PRRs) and potentiate innate immune responses. Lipopolysaccharides (LPSs), a major component of outer membrane of gram negative bacteria, are considered the prototypical class of PAMPs. While LPSs are specifically recognized by TLR4, the other PAMPs such as flagellin, lipoteichoic acid, peptidoglycan, nucleic acid variants (dsRNA), or unmethylated CpG motifs are recognized by other receptors, such as TLR2, TLR3, TLR5, and TLR9 [79]. Similarly, human TLR2, TLR4, and TLR9 are involved in the pathogenesis of NASH [80]. Interaction of LPSs and TLR4 with the monocyte differentiation antigen CD14 system on Kupffer cells triggers inflammatory cascade, which activates NF-κB pathway and induces the production of TNF-α, IL-1, and IL-6 cytokines [81]. The stimulation of this pathway was demonstrated in animal model of NASH, and elevated TNF-α expression as well as serum LPS-binding proteins was detected [82]. In HSCs, the activation of TRL4-dependent pathway was shown to be involved in fibrosis progression [83]. Although further investigations are necessary to show the generation of secondary bile acids by gut microbiota in NASH-HCC, the studies have shown the induction of DNA damage by one of the secondary bile acids, sDCA [84, 85].

3.4. Endocrine Pathways. The incidence of NASH and HCC is higher in males irrespective of the etiology. This suggests that the differential endocrine signaling might increase the tendency of HCC development in NASH patients. Both estrogen and androgen are steroid hormones that mediate their action by binding to nuclear receptors and acting as transcription factors to regulate the expression of multiple genes. It was suggested that androgen and androgen receptors (ARs) might promote HCC progression and/or that estrogen and estrogen receptors might suppress HCC development [86]. The AR gene encodes AR molecule, which is a transcriptional factor able to bind DNA with its DNA-binding domain. AR is activated directly by androgen hormone and induces the transcription of cell cycle-related kinase (CCRK) that upregulates β-catenin/T-cell factor signaling, leading to promotion of HCC [87]. ARs can also be activated by other signaling pathways such as MAPK and PI3K, which are well-known in the development of HCC in NASH [88]. Although ARs are extensively studied in HCC, their role in NASH is still under investigation. Several animal studies demonstrated the development of liver steatosis, insulin resistance, altered lipid metabolism, and progression of NASH to HCC via either SREB1 (sterol regulatory element-binding protein), PEPCK (phosphoenolpyruvate carboxykinase), and PTB-1B (protein tyrosine phosphatase 1B) or SREB2 and CYP27A1 [89]. These molecules play significant role in insulin signaling, cholesterol homeostasis, and vitamin D3 metabolism through activation of the JNK pathway [90].

4. Conclusion and Future Perspectives

NASH is the aggressive form of NAFLD and its prevalence is progressively increasing due to the growing epidemic of obesity and diabetes. Accumulated evidence is likely to make NASH one of the most common causes of HCC in upcoming years. Recent advances in whole genome association study (WGAS) and next generation sequencing (NGS) allow clarifying remarkable genetic changes in signaling pathways related to energy metabolism and cell proliferation that are directly linked to carcinogenesis. Currently, the data

obtained from various clinical and in vivo molecular studies achieve the consensus that genomic instability, abnormal lipid metabolism, uncontrolled stress mediators, and altered immune responses are coordinately acting mechanisms, prompting inflammation, liver injury, and fibrosis along with HCC. Our understanding of the underlying molecular basis in the NASH-related HCC development is that the signaling pathways involved in NASH pathogenesis seem to act simultaneously in HCC development. In this complex scenario, key molecules involved in reciprocal interaction between several pathways lead to overactivation of prooncogenic mechanism and, meanwhile, inactivate tumor-suppressive or antioncogenic mechanisms. Ongoing clinical trials of a wide range of molecules, targeting different pathways, have been shown to reduce the NASH-HCC progression in several pathogenic aspects, yet the translation of these findings into personalized therapy is still a major challenge. Thus, a better understanding of the molecular signaling pathways involved in NASH-related HCC will allow the discovery of novel targeting molecules for therapeutic and preventive approaches.

Conflicts of Interest

The authors declare that there are no conflicts of interest regarding the publication of this paper.

References

[1] G. Baffy, E. M. Brunt, and S. H. Caldwell, "Hepatocellular carcinoma in non-alcoholic fatty liver disease: an emerging menace," *Journal of Hepatology*, vol. 56, no. 6, pp. 1384–1391, 2012.

[2] S. Bellentani, "The epidemiology of non-alcoholic fatty liver disease," *Liver International*, vol. 37, pp. 81–84, 2017.

[3] G. A. Michelotti, M. V. Machado, and A. M. Diehl, "NAFLD, NASH and liver cancer," *Nature Reviews Gastroenterology & Hepatology*, vol. 10, no. 11, pp. 656–665, 2013.

[4] M. S. Ascha, I. A. Hanouneh, R. Lopez, T. A.-R. Tamimi, A. F. Feldstein, and N. N. Zein, "The incidence and risk factors of hepatocellular carcinoma in patients with nonalcoholic steatohepatitis," *Hepatology*, vol. 51, no. 6, pp. 1972–1978, 2010.

[5] A. Said and A. Ghufran, "Epidemic of non-alcoholic fatty liver disease and hepatocellular carcinoma," *World Journal of Clinical Oncology*, vol. 8, no. 6, pp. 429–436, 2017.

[6] C. Margini and J. F. Dufour, "The story of HCC in NAFLD: From epidemiology, across pathogenesis, to prevention and treatment," *Liver International*, vol. 36, no. 3, pp. 317–324, 2016.

[7] C. P. Day and O. F. W. James, "Steatohepatitis: A Tale of Two 'Hits'?" *Gastroenterology*, vol. 114, no. 4, pp. 842–845, 1998.

[8] C. L. Gentile and M. J. Pagliassotti, "The role of fatty acids in the development and progression of nonalcoholic fatty liver disease," *The Journal of Nutritional Biochemistry*, vol. 19, no. 9, pp. 567–576, 2008.

[9] Y. Sumida, E. Niki, Y. Naito, and T. Yoshikawa, "Involvement of free radicals and oxidative stress in NAFLD/NASH," *Free Radical Research*, vol. 47, no. 11, pp. 869–880, 2013.

[10] Y. Kawano and D. E. Cohen, "Mechanisms of hepatic triglyceride accumulation in non-alcoholic fatty liver disease," *Journal of Gastroenterology*, vol. 48, no. 4, pp. 434–441, 2013.

[11] S. A. Al-Busafi, M. Bhat, P. Wong, P. Ghali, and M. Deschenes, "Antioxidant therapy in nonalcoholic steatohepatitis," *Hepatitis Research and Treatment*, vol. 2012, Article ID 947575, 8 pages, 2012.

[12] J. D. Browning and J. D. Horton, "Molecular mediators of hepatic steatosis and liver injury," *The Journal of Clinical Investigation*, vol. 114, no. 2, pp. 147–152, 2004.

[13] E. M. Brunt, D. E. Kleiner, L. A. Wilson, P. Belt, and B. A. Neuschwander-Tetri, "Nonalcoholic fatty liver disease (NAFLD) activity score and the histopathologic diagnosis in NAFLD: distinct clinicopathologic meanings," *Hepatology*, vol. 53, no. 3, pp. 810–820, 2011.

[14] H. Tilg and A. R. Moschen, "Evolution of inflammation in nonalcoholic fatty liver disease: the multiple parallel hits hypothesis," *Hepatology*, vol. 52, no. 5, pp. 1836–1846, 2010.

[15] A. Takaki, D. Kawai, and K. Yamamoto, "Multiple hits, including oxidative stress, as pathogenesis and treatment target in non-alcoholic steatohepatitis (NASH)," *International Journal of Molecular Sciences*, vol. 14, no. 10, pp. 20704–20728, 2013.

[16] W. Peverill, L. W. Powell, and R. Skoien, "Evolving concepts in the pathogenesis of NASH: beyond steatosis and inflammation," *International Journal of Molecular Sciences*, vol. 15, no. 5, pp. 8591–8638, 2014.

[17] S. Sookoian and C. J. Pirola, "Meta-analysis of the influence of I148M variant of patatin-like phospholipase domain containing 3 gene (PNPLA3) on the susceptibility and histological severity of nonalcoholic fatty liver disease," *Hepatology*, vol. 53, no. 6, pp. 1883–1894, 2011.

[18] P. Dongiovanni, B. Donati, R. Fares et al., "PNPLA3 I148M polymorphism and progressive liver disease," *World Journal of Gastroenterology*, vol. 19, no. 41, pp. 6969–6978, 2013.

[19] A. C. Yopp and M. A. Choti, "Non-alcoholic steatohepatitis-related hepatocellular carcinoma: A growing epidemic?" *Digestive Diseases*, vol. 33, no. 5, pp. 642–647, 2015.

[20] E. Smagris, S. BasuRay, J. Li et al., "*Pnpla3I148M* knockin mice accumulate PNPLA3 on lipid droplets and develop hepatic steatosis," *Hepatology*, vol. 61, no. 1, pp. 108–118, 2015.

[21] A. Mondul, R. M. Mancina, A. Merlo et al., "PNPLA3 I148M variant influences circulating retinol in adults with nonalcoholic fatty liver disease or obesity," *Journal of Nutrition*, vol. 145, no. 8, pp. 1687–1691, 2015.

[22] C. Pirazzi, L. Valenti, B. M. Motta et al., "PNPLA3 has retinyl-palmitate lipase activity in human hepatic stellate cells," *Human Molecular Genetics*, vol. 23, no. 15, pp. 4077–4085, 2014.

[23] F. V. Bruschi, M. Tardelli, T. Claudel, and M. Trauner, "PNPLA3 expression and its impact on the liver: current perspectives," *Hepatic Medicine: Evidence and Research*, vol. Volume 9, pp. 55–66, 2017.

[24] J. Kozlitina, E. Smagris, S. Stender et al., "Exome-wide association study identifies a TM6SF2 variant that confers susceptibility to nonalcoholic fatty liver disease," *Nature Genetics*, vol. 46, no. 4, pp. 352–356, 2014.

[25] Y.-L. Liu, H. L. Reeves, A. D. Burt et al., "*TM6SF2* rs58542926 influences hepatic fibrosis progression in patients with non-alcoholic fatty liver disease," *Nature Communications*, vol. 5, article 4309, 2014.

[26] L. Z. Chen, H. H. Xia, Y. N. Xin, Z. H. Lin, and S. Y. Xuan, "TM6SF2 E167K Variant, a novel genetic susceptibility variant, contributing to nonalcoholic fatty liver disease," *Journal of Clinical and Translational Hepatology*, vol. 3, no. 4, pp. 265–270, 2015.

[27] E. Bugianesi, P. Manzini, S. D'Antico et al., "Relative contribution of iron burden, HFE mutation and insulin resistance to fibrosis in nonalcoholic fatty liver," *Hepatology*, vol. 39, no. 1, pp. 179–187, 2004.

[28] J. E. Nelson, R. Bhattacharya, K. D. Lindor et al., "HFE C282Y mutations are associated with advanced hepatic fibrosis in caucasians with nonalcoholic steatohepatitis," *Hepatology*, vol. 46, no. 3, pp. 723–729, 2007.

[29] Q. Ye, B.-X. Qian, W.-L. Yin, F.-M. Wang, and T. Han, "Association between the HFE C282Y, H63D polymorphisms and the risks of non-alcoholic fatty liver disease, liver cirrhosis and hepatocellular carcinoma: An updated systematic review and meta-analysis of 5,758 cases and 14,741 controls," *PLoS ONE*, vol. 11, no. 9, Article ID e0163423, 2016.

[30] R. M. Mancina, P. Dongiovanni, S. Petta et al., "The *MBOAT7-TMC4* variant rs641738 increases risk of nonalcoholic fatty liver disease in individuals of European descent," *Gastroenterology*, vol. 150, no. 5, pp. 1219–1230, 2016.

[31] K. Thabet, H. L. Y. Chan, S. Petta et al., "The membrane-bound O-acyltransferase domain-containing 7 variant rs641738 increases inflammation and fibrosis in chronic hepatitis B," *Hepatology*, vol. 65, no. 6, pp. 1840–1850, 2017.

[32] K. Schulze, S. Imbeaud, E. Letouzé et al., "Exome sequencing of hepatocellular carcinomas identifies new mutational signatures and potential therapeutic targets," *Nature Genetics*, vol. 47, no. 5, pp. 505–511, 2015.

[33] X.-T. Liang, K. Pan, M.-S. Chen et al., "Decreased expression of XPO4 is associated with poor prognosis in hepatocellular carcinoma," *Journal of Gastroenterology and Hepatology*, vol. 26, no. 3, pp. 544–549, 2011.

[34] S. M. Zain, R. Mohamed, D. N. Cooper et al., "Genome-wide analysis of copy number variation identifies candidate gene loci associated with the progression of non-alcoholic fatty liver disease," *PLoS ONE*, vol. 9, no. 4, Article ID e95604, 2014.

[35] V. Iacobazzi, A. Castegna, V. Infantino, and G. Andria, "Mitochondrial DNA methylation as a next-generation biomarker and diagnostic tool," *Molecular Genetics and Metabolism*, vol. 110, no. 1-2, pp. 25–34, 2013.

[36] V. P. Tryndyak, T. Han, L. Muskhelishvili et al., "Coupling global methylation and gene expression profiles reveal key pathophysiological events in liver injury induced by a methyl-deficient diet," *Molecular Nutrition & Food Research*, vol. 55, no. 3, pp. 411–418, 2011.

[37] F. Liu, H. Li, H. Chang, J. Wang, and J. Lu, "Identification of hepatocellular carcinoma-associated hub genes and pathways by integrated microarray analysis," *TUMORI*, vol. 101, no. 2, pp. 206–214, 2015.

[38] D. J. Erstad, B. C. Fuchs, and K. K. Tanabe, "Molecular signatures in hepatocellular carcinoma: A step toward rationally designed cancer therapy," *Cancer*, vol. 124, no. 15, pp. 3084–3104, 2018.

[39] O. Cheung, P. Puri, C. Eicken et al., "Nonalcoholic steatohepatitis is associated with altered hepatic microRNA expression," *Hepatology*, vol. 48, no. 6, pp. 1810–1820, 2008.

[40] Y. Takaki, Y. Saito, A. Takasugi et al., "Silencing of microRNA-122 is an early event during hepatocarcinogenesis from non-alcoholic steatohepatitis," *Cancer Science*, vol. 105, no. 10, pp. 1254–1260, 2014.

[41] A. de Conti, J. F. Ortega, V. Tryndyak et al., "MicroRNA deregulation in nonalcoholic steatohepatitisassociated liver carcinogenesis," *Oncotarget* , vol. 8, no. 51, pp. 88517–88528, 2017.

[42] A. Khalid, T. Hussain, S. Manzoor, M. Saalim, and S. Khaliq, "PTEN: A potential prognostic marker in virus-induced hepatocellular carcinoma," *Tumor Biology*, vol. 39, no. 6, Article ID 101042831770575, 2017.

[43] Y. Liu, X. Qi, Z. Zeng et al., "CRISPR/Cas9-mediated p53 and Pten dual mutation accelerates hepatocarcinogenesis in adult hepatitis B virus transgenic mice," *Scientific Reports*, vol. 7, no. 1, article 2796, 2017.

[44] Z. Xu, J. Hu, H. Cao et al., "Loss of Pten synergizes with c-Met to promote hepatocellular carcinoma development via mTORC2 pathway," *Experimental & Molecular Medicine*, vol. 50, no. 1, article e417, 2018.

[45] S. De Minicis, L. Agostinelli, C. Rychlicki et al., "HCC development is associated to peripheral insulin resistance in a mouse model of NASH," *PLoS ONE*, vol. 9, no. 5, Article ID e97136, 2014.

[46] F. Janku, A. O. Kaseb, A. M. Tsimberidou, R. A. Wolff, and R. Kurzrock, "Identification of novel therapeutic targets in the PI3K/AKT/mTOR pathway in hepatocellular carcinoma using targeted next generation sequencing," *Oncotarget* , vol. 5, no. 10, pp. 3012–3022, 2014.

[47] S. Yang and G. Liu, "Targeting the RAS/RAF/MEK/ERK pathway in hepatocellular carcinoma," *Oncology Letters*, vol. 13, no. 3, pp. 1041–1047, 2017.

[48] Y. Kudo, Y. Tanaka, K. Tateishi et al., "Altered composition of fatty acids exacerbates hepatotumorigenesis during activation of the phosphatidylinositol 3-kinase pathway," *Journal of Hepatology*, vol. 55, no. 6, pp. 1400–1408, 2011.

[49] H. Chettouh, M. Lequoy, L. Fartoux, C. Vigouroux, and C. Desbois-Mouthon, "Hyperinsulinaemia and insulin signalling in the pathogenesis and the clinical course of hepatocellular carcinoma," *Liver International*, vol. 35, no. 10, pp. 2203–2217, 2015.

[50] P. Hirsova, S. H. Ibrabim, G. J. Gores, and H. Malhi, "Thematic review series: Lipotoxicity: Many roads to cell dysfunction and cell death lipotoxic lethal and sublethal stress signaling in hepatocytes: Relevance to NASH pathogenesis," *Journal of Lipid Research*, vol. 57, no. 10, pp. 1758–1770, 2016.

[51] M. B. Afonso, P. M. Rodrigues, T. Carvalho et al., "Necroptosis is a key pathogenic event in human and experimental murine models of non-alcoholic steatohepatitis," *Clinical Science*, vol. 129, no. 8, pp. 721–739, 2015.

[52] J. Gautheron, M. Vucur, F. Reisinger et al., "A positive feedback loop between RIP3 and JNK controls non-alcoholic steatohepatitis," *EMBO Molecular Medicine*, vol. 6, no. 8, pp. 1062–1074, 2014.

[53] S. Fu, L. Yang, P. Li et al., "Aberrant lipid metabolism disrupts calcium homeostasis causing liver endoplasmic reticulum stress in obesity," *Nature*, vol. 473, no. 7348, pp. 528–531, 2011.

[54] P. Bozaykut, A. Sahin, B. Karademir, and N. K. Ozer, "Endoplasmic reticulum stress related molecular mechanisms in nonalcoholic steatohepatitis," *Mechanisms of Ageing and Development*, vol. 157, pp. 17–29, 2016.

[55] E. Novo and M. Parola, "Redox mechanisms in hepatic chronic wound healing and fibrogenesis," *Fibrogenesis & Tissue Repair*, vol. 1, article 5, 2008.

[56] J. E. Nelson, L. Wilson, E. M. Brunt et al., "Relationship between the pattern of hepatic iron deposition and histological severity in nonalcoholic fatty liver disease," *Hepatology*, vol. 53, no. 2, pp. 448–457, 2011.

[57] G. Onal, O. Kutlu, D. Gozuacik, and S. Dokmeci Emre, "Lipid droplets in health and disease," *Lipids in Health and Disease*, vol. 16, article 128, 2017.

[58] L. Liu, J.-Z. Liao, X.-X. He, and P.-Y. Li, "The role of autophagy in hepatocellular carcinoma: Friend or foe," *Oncotarget* , vol. 8, no. 34, pp. 57707–57722, 2017.

[59] Y. Mao, F. Yu, J. Wang, C. Guo, and X. Fan, "Autophagy: a new target for nonalcoholic fatty liver disease therapy," *Hepatic Medicine: Evidence and Research*, vol. 8, pp. 27–37, 2016.

[60] G. He and M. Karin, "NF-κB and STAT3- key players in liver inflammation and cancer," *Cell Research*, vol. 21, no. 1, pp. 159–168, 2011.

[61] E. J. Park, J. H. Lee, G.-Y. Yu et al., "Dietary and genetic obesity promote liver inflammation and tumorigenesis by enhancing IL-6 and TNF expression," *Cell*, vol. 140, no. 2, pp. 197–208, 2010.

[62] L. Jia, C. R. Vianna, M. Fukuda et al., "Hepatocyte toll-like receptor 4 regulates obesity-induced inflammation and insulin resistance," *Nature Communications*, vol. 5, article 3878, 2014.

[63] H. Min, F. Mirshahi, A. Verdianelli et al., "Activation of the GP130-STAT3 axis and its potential implications in nonalcoholic fatty liver disease," *American Journal of Physiology-Gastrointestinal and Liver Physiology*, vol. 308, no. 9, pp. G794–G803, 2015.

[64] Q. Sun, N. Jiang, and R. Sun, "Leptin signaling molecular actions and drug target in hepatocellular carcinoma," *Drug Design, Development and Therapy*, vol. 8, pp. 2295–2302, 2014.

[65] N. Stefanou, V. Papanikolaou, Y. Furukawa, Y. Nakamura, and A. Tsezou, "Leptin as a critical regulator of hepatocellular carcinoma development through modulation of human telomerase reverse transcriptase," *BMC Cancer*, vol. 10, article 442, 2010.

[66] S.-Q. Xing, C.-G. Zhang, J.-F. Yuan, H.-M. Yang, S.-D. Zhao, and H. Zhang, "Adiponectin induces apoptosis in hepatocellular carcinoma through differential modulation of thioredoxin proteins," *Biochemical Pharmacology*, vol. 93, no. 2, pp. 221–231, 2015.

[67] J. Shen, C.-C. Yeh, Q. Wang, I. Gurvich, A. B. Siegel, and R. M. Santella, "Plasma adiponectin and hepatocellular carcinoma survival among patients without liver transplantation," *Anticancer Reseach*, vol. 36, no. 10, pp. 5307–5314, 2016.

[68] F. Carbone, C. la Rocca, and G. Matarese, "Immunological functions of leptin and adiponectin," *Biochimie*, vol. 94, no. 10, pp. 2082–2088, 2012.

[69] M. Nannipieri, F. Cecchetti, M. Anselmino et al., "Pattern of expression of adiponectin receptors in human liver and its relation to nonalcoholic steatohepatitis," *Obesity Surgery*, vol. 19, no. 4, pp. 467–474, 2009.

[70] C. Ma, A. H. Kesarwala, T. Eggert et al., "NAFLD causes selective CD4+ T lymphocyte loss and promotes hepatocarcinogenesis," *Nature*, vol. 531, no. 7593, pp. 253–257, 2016.

[71] M. Wolf, A. Adili, K. Piotrowitz et al., "Metabolic activation of intrahepatic CD8+ T cells and NKT cells causes nonalcoholic steatohepatitis and liver cancer via cross-talk with hepatocytes," *Cancer Cell*, vol. 26, no. 4, pp. 549–564, 2014.

[72] N. Lanthier, "Targeting Kupffer cells in non-alcoholic fatty liver disease/non-alcoholic steatohepatitis: why and how?" *World Journal of Hepatology*, vol. 7, no. 19, pp. 2184–2188, 2015.

[73] B. V. Martin-Murphy, Q. You, H. Wang et al., "Mice lacking natural killer T cells are more susceptible to metabolic alterations following high fat diet feeding," *PLoS ONE*, vol. 9, no. 1, Article ID e80949, 2014.

[74] Z. Tian, Y. Chen, and B. Gao, "Natural killer cells in liver disease," *Hepatology*, vol. 57, no. 4, pp. 1654–1662, 2013.

[75] X. Zheng, W. Zeng, X. Gai et al., "Role of the Hedgehog pathway in hepatocellular carcinoma (Review)," *Oncology Reports*, vol. 30, no. 5, pp. 2020–2026, 2013.

[76] C. M. Della Corte, G. Viscardi, F. Papaccio et al., "Implication of the Hedgehog pathway in hepatocellular Carcinoma," *World Journal of Gastroenterology*, vol. 23, no. 24, pp. 4330–4340, 2017.

[77] M. C. Noverr and G. B. Huffnagle, "Does the microbiota regulate immune responses outside the gut?" *Trends in Microbiology*, vol. 12, no. 12, pp. 562–568, 2004.

[78] A. Żak-Gołąb, M. Olszanecka-Glinianowicz, P. Kocełak, and J. Chudek, "The role of gut microbiota in the pathogenesis of obesity," *Postepy Higieny i Medycyny Doswiadczalnej*, vol. 68, pp. 84–90, 2014.

[79] M. Valentini, A. Piermattei, G. Di Sante, G. Migliara, G. Delogu, and F. Ria, "Immunomodulation by gut microbiota: Role of toll-like receptor expressed by T cells," *Journal of Immunology Research*, vol. 2014, Article ID 586939, 8 pages, 2014.

[80] K. Brandl and B. Schnabl, "Intestinal microbiota and nonalcoholic steatohepatitis," *Current Opinion in Gastroenterology*, vol. 33, no. 3, pp. 128–133, 2017.

[81] S. Bashiardes, H. Shapiro, S. Rozin, O. Shibolet, and E. Elinav, "Non-alcoholic fatty liver and the gut microbiota," *Molecular Metabolism*, vol. 5, no. 9, pp. 782–794, 2016.

[82] A. G. Ruiz, F. Casafont, J. Crespo et al., "Lipopolysaccharide-binding protein plasma levels and liver TNF-alpha gene expression in obese patients: evidence for the potential role of endotoxin in the pathogenesis of non-alcoholic steatohepatitis," *Obesity Surgery*, vol. 17, no. 10, pp. 1374–1380, 2007.

[83] P. Brun, I. Castagliuolo, M. Pinzani, G. Palù, and D. Martines, "Exposure to bacterial cell wall products triggers an inflammatory phenotype in hepatic stellate cells," *American Journal of Physiology-Gastrointestinal and Liver Physiology*, vol. 289, no. 3, pp. G571–G578, 2005.

[84] A. Borrelli, P. Bonelli, F. M. Tuccillo et al., "Role of gut microbiota and oxidative stress in the progression of non-alcoholic fatty liver disease to hepatocarcinoma: Current and innovative therapeutic approaches," *Redox Biology*, vol. 15, pp. 467–479, 2018.

[85] S. Yoshimoto, T. M. Loo, K. Atarashi et al., "Obesity-induced gut microbial metabolite promotes liver cancer through senescence secretome," *Nature*, vol. 499, no. 7456, pp. 97–101, 2013.

[86] N. Nagasue, L. Yu, H. Yukaya, H. Kohno, and T. Nakamura, "Androgen and oestrogen receptors in hepatocellular carcinoma and surrounding liver parenchyma: Impact on intrahepatic recurrence after hepatic resection," *British Journal of Surgery*, vol. 82, no. 4, pp. 542–547, 1995.

[87] P. K. Awuah and S. P. Monga, "Cell cycle-related kinase links androgen receptor and β-catenin signaling in hepatocellular carcinoma: Why are men at a loss?" *Hepatology*, vol. 55, no. 3, pp. 970–974, 2012.

[88] T. Kanda, X. Jiang, and O. Yokosuka, "Androgen receptor signaling in hepatocellular carcinoma and pancreatic cancers," *World Journal of Gastroenterology*, vol. 20, no. 28, pp. 9229–9236, 2014.

[89] H.-Y. Lin, I.-C. Yu, R.-S. Wang et al., "Increased hepatic steatosis and insulin resistance in mice lacking hepatic androgen receptor," *Hepatology*, vol. 47, no. 6, pp. 1924–1935, 2008.

[90] M. Norlin, H. Pettersson, W. Tang, and K. Wikvall, "Androgen receptor-mediated regulation of the anti-atherogenic enzyme CYP27A1 involves the JNK/c-jun pathway," *Archives of Biochemistry and Biophysics*, vol. 506, no. 2, pp. 236–241, 2011.

Hindawi
Canadian Journal of Gastroenterology and Hepatology
Volume 2018, Article ID 3120185, 8 pages
https://doi.org/10.1155/2018/3120185

Research Article

Macroscopic Portal Vein Thrombosis in HCC Patients

Hikmet Akkiz,[1] Brian I. Carr,[2] Sedef Kuran,[1] Ümit Karaoğullarından,[1] Oguz Üsküdar,[1] Salih Tokmak,[1] Burcu Arslan,[1] Figen Doran,[1] Hüseyin Tugsan Balli,[1] Abdulalh Ülkü,[1] Tolga Atılgan Akçam,[1] Halil İbrahim Bahçeci,[3] Kamil Yalçın Polat,[4] Necati Örmeci,[5] Halis Şimşek,[6] Abdullah Sonsuz,[7] Ali Demir,[8] Engin Altıntaş,[9] Mehmet Demir,[10] Kendal Yalçın,[11] Nazım Ekinci,[11] Ayşegül Harmancı Özakyol,[12] Mehmet Yücesoy,[13] Ahmet Uygun,[14] Vito Guerra,[15] Anıl Delik,[1] Yaman Tokat,[16] Sezai Yilmaz,[17] Ahmet Bektaş,[18] and Murat Kılıç[19]

[1] *Çukurova University Gastroenterology Department, Adana, Turkey*
[2] *İzmir Biomedicine and Genome Institute, Dokuz Eylül University, İzmir, Turkey*
[3] *Fırat University, Turkey*
[4] *İstanbul Memorial Hospital, Turkey*
[5] *Ankara University, Turkey*
[6] *Hacettepe University, Turkey*
[7] *İstanbul Cerrahpaşa University, Turkey*
[8] *Konya Necmettin Erbakan University, Turkey*
[9] *Mersin University, Turkey*
[10] *Hatay Mustafa Kemal University, Turkey*
[11] *Dicle University, Turkey*
[12] *Eskişehir Osmangazi University, Turkey*
[13] *Erciyes University, Turkey*
[14] *Haydarpaşa Sultan Abdülhamid Eğitim Araştırma Hospital, Turkey*
[15] *Trials Centre, National Institute for Digestive Diseases, IRCCS "Saverio de Bellis", Castellana, Bari, Italy*
[16] *Florence Nightingale Hospital, İstanbul, Turkey*
[17] *İnonu University, Malatya, Turkey*
[18] *Ondokuz Mayıs University, Turkey*
[19] *Izmir Kent Hospital, Turkey*

Correspondence should be addressed to Brian I. Carr; brianicarr@hotmail.com

Received 8 December 2017; Accepted 22 March 2018; Published 13 June 2018

Academic Editor: Pascal Lapierre

Macroscopic portal vein invasion (PVT) by hepatocellular carcinoma (HCC) in the liver is one of the most important negative prognostic factors for HCC patients. The characteristics of a large cohort of such patients were examined. We found that the percent of patients with PVT significantly increased with increasing maximum tumor diameter (MTD), from 13.7% with tumors of MTD <5cm to 56.4% with tumors of MTD >10cm. There were similar numbers of HCC patients with very large tumors with and without PVT. Thus, MTD alone was insufficient to explain the presence of PVT, as were high AFP levels, since less than 50% of high AFP patients had PVT. However, the percent of patients with PVT was also found to significantly increase with increasing blood alpha-fetoprotein (AFP) levels and tumor multifocality. A logistic regression model that included these 3 factors together showed an odds ratio of 17.9 for the combination of MTD>5.0cm plus tumor multifocality plus elevated AFP, compared to low levels of these 3 parameters. The presence or absence of macroscopic PVT may therefore represent different HCC aggressiveness phenotypes, as judged by a significant increase in tumor multifocality and AFP levels in the PVT positive patients. Factors in addition to MTD and AFP must also contribute to PVT development.

1. Introduction

The prognosis of patients with hepatocellular carcinoma (HCC) depends upon both tumor factors and liver factors [1]. The tumor factors include the maximum tumor diameter (MTD), number of tumors, presence of macroscopic (clinically evident) portal vein thrombosis (PVT), and blood levels of alpha-fetoprotein (AFP). The presence of PVT may be the most important tumor factor, as it reflects tumor aggressiveness (migration, invasion, and potential for metastasis), limits the options for curative resection or transplantation, and can also worsen residual liver function. It is thought that up to 45% of HCC patients have some form of macroscopic PVT [2–5] and may be gross or macroscopic as shown on CT or MRI scan or microscopic as evidenced only on pathology. It is poorly understood, with few biological models and little understanding of its causes. However, predisposing factors include increased MTD, with increased levels of the HCC plasma tumor markers des-gamma carboxyprothrombin (DCP) and AFP, decreased serum albumin, and elevated platelet counts [6–11]. The current study in a large HCC cohort confirms the increased percent of PVT with increasing MTD, as well as with increasing multifocality and AFP. Furthermore, we found that PVT occurred in 13.7% of small HCCs <5cm, but in 56.4% of large HCCs >10cm.

2. Methods

2.1. Patient Data. We analyzed a database of 1773 prospectively accrued HCC patients who had full baseline tumor parameter data, including CT scan information on HCC size, number of tumor nodules, and presence or absence of PVT and plasma AFP levels; complete blood count; routine blood liver function tests (total bilirubin, GGTP, ALKP, albumin, and transaminases); and patient demographics. Diagnosis was made either via tumor biopsy or according to international guidelines. Of these patients, 1029 had low AFP levels (≤100 IU/ml) and are the subject of this study. Database management conformed to legislation on privacy and this study conforms to the ethical guidelines of the Declaration of Helsinki and approval for this retrospective study on deidentified HCC patients was obtained by the Institutional Review Board.

2.2. Statistical Analysis. Mean and SD for continuous variables and relative frequency for categorical variables were used as indices of centrality and dispersion of the distribution. For categorical variables, the Chi-square and z test for proportions were used. The Wilcoxon rank-sum (Mann–Whitney) test was to test the difference between two categories and the Kruskal-Wallis rank test to test the difference among categories.

Logistic regression model was to evaluate the associations between PVT (No/Yes) on single variables examined.

Final multiple linear or logistic regression models were obtained with the backward stepwise method and the variables that showed associations with $p<0.10$ were left in the models.

When testing the null hypothesis of no association, the probability level of α error, two tailed, was 0.05. All the statistical computations were made using STATA 12.1 Statistical Software (StataCorp), 2014, release 12 (College Station, TX).

3. Results

3.1. PVT in Tumor Size (MTD) Groups. Patients were initially analyzed according to PVT status in different tumor size (MTD) groups (Table 1). There was a large percent increase in PVT positive patients with increase in MTD, 13.7% for small tumors, 33.9% for intermediate tumors, and 56.4% for very large tumors. For small and intermediate size tumor patients, there were more Child-Pugh score A patients without PVT. However, the prevalence of cirrhosis was not different across MTD groups, nor were there differences in total serum bilirubin values. Albumin values were lower in the patients with PVT, but significant only for the small tumor groups. Patients with PVT had a small but significant increase in MTD, in the small and intermediate size tumor groups compared to patients without PVT. However, the AFP levels were significantly higher in the PVT positive patients, for all 3 tumor size groups, as was tumor multifocality. Thus, on the whole, patients with PVT had larger and more multifocal tumors with higher AFP values, yet similar bilirubin levels, across the tumor size groups.

3.2. PVT-Associated Parameters. The parameters that were associated with presence of PVT were next examined. A logistic regression model of PVT showed significance for several single parameters as continuous variables (Table 2(A)), but when all parameters were considered together, there was significance in the final model (Table 2(B)) for tumor multifocality, MTD, AFP, ALKP, and albumin. Two of these parameters versus PVT values are shown graphically in Figure 1, which shows significant increases in percent PVT, in relation to increase of both MTD and AFP. However, even in the highest AFP categories, less than r50% of patients had PVT (Figure 2).

A logistic regression model of PVT was then performed for the variables of MTD (large or small), AFP (high or low), and tumor multifocality versus unifocality, considered singularly (Table 3(A)) or together (Table 3(B)), as these were the 3 parameters with highest odds ratio (OR) in Table 2. High ORs were found for the high values of each of the 3 parameters, whether considered singularly or together. However, when we combined all 3 parameters of MTD >5cm plus tumor multifocality plus AFP >100 IU/ml, an OR of 17.9 was obtained (Table 3(C)).

4. Discussion

Clinical macroscopic PVT is typically diagnosed as obstruction and expansion of the portal vein on CT or MRI scan [12–14] or by contrast-enhanced ultrasonography [15]. It is associated with several serum changes, such as the des-gamma-carboxy-prothrombin/vitamin K pathway [16–23] and is a well-recognized predictor of poor survival in

Table 1: Comparisons amongst HCC patients between portal vein thrombosis groups, in single MTD categories.

Parameter*	MTD<5.0 (cm)			5.0≤MTD≤10.0 (cm)			MTD>10.0 (cm)		
	PVT(No) (n=701)	PVT(Yes) (n=112) (13.7%)	p$^{\psi}$	PVT(No) (n=388)	PVT(Yes) (n=199) (33.9%)	p$^{\psi}$	PVT(No) (n=84)	PVT(Yes) (n=109) (56.4%)	p$^{\psi}$
Sex (M) (%)	145 (79.32)	88 (78.57)	0.86$^{\wedge}$	319 (82.22)	164 (82.41)	0.95$^{\wedge}$	72 (85.71)	96 (88.07)	0.63$^{\wedge}$
Age (yr)	61.55±11.04	61.59±11.53	0.98	63.86±10.95	61.24±11.88	0.005	63.89±12.52	60.69±13.68	0.08
Cigarettes smoke (%)	159 (44.04)	32 (42.11)	0.76$^{\wedge}$	129 (60.85)	79 (56.03)	0.37$^{\wedge}$	26 (55.32)	32 (57.14)	0.85$^{\wedge}$
Alcohol (%)	63 (17.65)	8 (11.11)	0.17$^{\wedge}$	27 (13.85)	25 (18.12)	0.29$^{\wedge}$	7 (20.00)	7 (12.07)	0.30$^{\wedge}$
Child-Pugh (B&C)			0.01 $^{\wedge}$			<0.001$^{\wedge}$			0.47 $^{\wedge}$
A	217 (39.19)	18 (22.22)		138 (44.23)	44 (26.04)		26 (35.14)	23 (26.44)	
B	212 (38.27)	41 (50.62)		118 (37.82)	70 (41.42)		28 (37.84)	39 (44.83)	
C	125 (22.56)	22 (27.16)		56 (17.95)	55 (32.54)		20 (27.03)	25 (28.74)	
Cirrhosis (%)	542 (79.47)	88 (87.13)	0.07 $^{\wedge}$	301 (77.98)	168 (85.71)	0.03$^{\wedge}$	62 (73.81)	81 (77.88)	0.51 $^{\wedge}$
Albumin (g/dL)	3.15±0.76	2.95±0.76	0.02	3.11±0.75	2.97±0.71	0.07	3.04±0.74	3.00±0.63	0.60
GGTP (U/L)	148.07±186.14	143.42±134.30	0.41	147.47±153.36	210.61±206.48	0.0003	186.06±153.04	213.74±175.12	0.34
AST (U/L)	118.06±226.07	102.20±92.59	0.86	100.88±121.40	114.37±105.87	0.02	146.35±425.67	114.46±112.63	0.07
ALKP (U/L)	190.97±216.09	191.34±168.76	0.40	193.97±139.92	279.19±313.31	0.02	232.77±149.04	268.86±241.38	0.96
Bilirubin (mg/dL)	2.41±3.45	2.52±3.41	0.67	2.27±3.67	3.60±5.44	0.009	1.96±3.06	2.58±3.61	0.22
Platelet counts ($10^3/\mu$L)	139.16±85.58	141.80±90.29	0.92	161.86±89.36	180.04±108.38	0.10	226.94±141.19	227.79±127.74	0.63
AFP (IU/mL)	1774.84±13163.19	2722.60±8062.90	<0.0001	3504.43±18586.15	10976.9±54278.4	0.0007	9395.0±29325.7	18393.3±55766.2	0.02
MTD (cm)	2.91±1.01	3.13±0.94	0.03	7.00±1.73	7.47±1.66	0.0004	14.29±3.56	14.24±3.17	0.91
Nodules number (%)			0.002 $^{\wedge}$			<0.001$^{\wedge}$			<0.001$^{\wedge}$
Unifocal	507 (72.53)	62 (57.94)		271 (70.76)	98 (50.52)		67 (79.76)	55 (55.00)	
Multifocality (≥2)	192 (27.47)	45 (42.06)		112 (29.24)	96 (49.48)		17 (20.24)	45 (45.00)	

* All values: means ± standard deviation as continuous; Frequencies and percentage (%) as categorical.
$^{\psi}$ Wilcoxon rank-sum (Mann–Whitney) test; $^{\wedge}$ Chi-square test.
GGTP, gamma glutamyl transpeptidase; ALKP, alkaline phosphatase; AFP, alpha-fetoprotein; MTD, maximum tumor diameter; PVT, portal vein thrombosis.

Table 2: Logistic regression model of PVT *(No/Yes)*, on single variables **(A)**. Final multiple logistic regression model in stepwise method of PVT *(No/Yes)*, on all variables included together in the model **(B)**. All models in total cohort.

Parameter ∗	OR	se(OR)	p-value	95% C.I.
(**A**)				
Platelet counts ($10^3/\mu$L)	1.002	0.001	0.003	1.001 to 1.004
Hemoglobin (g/dL)	0.899	0.034	0.005	0.835 to 0.969
GGTP (U/L)	1.001	0.0004	0.006	1.0003 to 1.0021
ALKP (U/L)	1.001	0.0004	0.002	1.0004 to 1.0019
Total Bilirubin (mg/dL)	1.042	0.021	0.04	1.002 to 1.084
Albumin (g/dL)	0.711	0.080	0.002	0.571 to 0.887
AFP (IU/mL)				
≤100 *[Ref. category]*	1			
>100	2.091	0.354	<0.001	1.500 to 2.913
MTD (cm)	1.178	0.027	<0.001	1.127 to 1.231
Tumor Nodule #	1.714	0.284	0.001	1.238 to 2.372
Cirrhosis (yes)	1.388	0.303	0.13	0.905 to 2.130
(**B**)				
ALKP (U/L)	1.001	0.0004	0.02	1.0001 to 1.0017
Albumin (g/dL)	0.758	0.093	0.02	0.595 to 0.965
AFP (IU/mL)				
≤100 *[Ref. category]*	1			
>100	1.632	0.297	0.007	1.143 to 2.331
MTD (cm)	1.166	0.027	<0.001	1.114 to 1.219
Tumor Nodule #	1.558	0.281	0.01	1.094 to 2.219

∗ All variables included in the model were considered as continuous, except the AFP which was considered as categorical.
OR, odds ratio; se(OR), standard error of odds ratio; GGTP, gamma glutamyl transpeptidase; ALKP, alkaline phosphatase; AFP, alpha-fetoprotein; MTD, maximum tumor diameter; PVT, portal vein thrombosis.

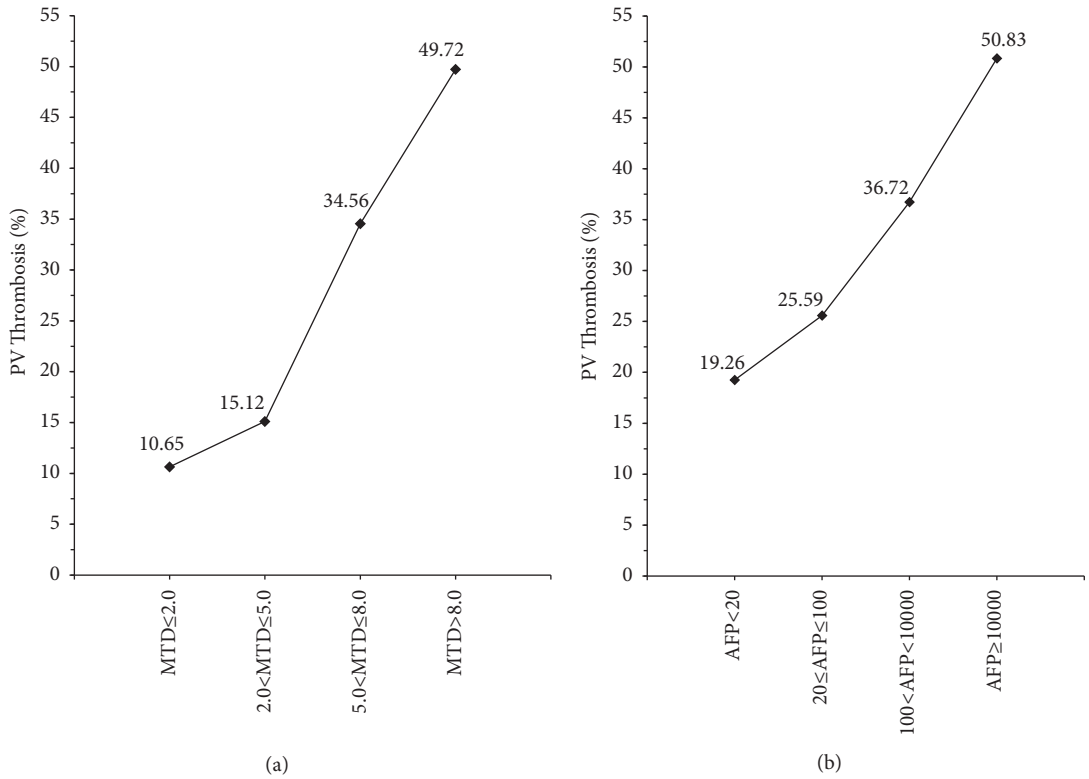

Figure 1: Percentage of patients with PV Thrombosis in **(a)** MTD (cm) categories, in total cohort ($p < 0.0001^*$)^i **(b)** AFP (IU/mL) categories ($p < 0.0001^*$)^i ∗ Chi-square test for trend; PVT, portal vein thrombosis; MTD, maximum tumor dimension; AFP, alpha-fetoprotein.

Table 3: Logistic regression model of PVT (*No/Yes*), on single variables (**A**), all as categories. Final multiple logistic regression model in stepwise method of PVT (*No/Yes*), on all variables as categories, included together in the model (**B**). Combination of MTD (<5.0/≥5.0), focality (Unifocality/Multifocality), and AFP (≤100/>100) (**C**).

Parameter	OR	se(OR)	p-value	95% C.I.
(**A**)				
MTD (cm)				
<5.0 *[Ref. category]*	1			
≥5.0	3.97	0.53	<0.001	3.05 to 5.17
Tumor Nodule #				
Unifocality (n=1) *[Ref. category]*	1			
Multifocality (n≥2)	2.43	0.31	<0.001	1.90 to 3.11
AFP (IU/mL)				
≤100 *[Ref. category]*	1			
>100	2.55	0.32	<0.001	2.00 to 3.25
(**B**)				
MTD (cm)				
<5.0 *[Ref. category]*	1			
≥5.0	3.49	0.48	<0.001	2.66 to 4.57
Tumor Nodule #				
Unifocality (n=1) *[Ref. category]*	1			
Multifocality (n≥2)	2.22	0.29	<0.001	1.71 to 2.88
AFP (IU/mL)				
≤100 *[Ref. category]*	1			
>100	2.05	0.27	<0.001	1.58 to 2.65
(**C**)				
Combination of: MTD, Focality, and AFP				
MTD<5.0 & Unifocality & AFP≤100 *[Ref. category]*	1			
MTD<5.0 & Unifocality & AFP>100	2.80	0.82	<0.001	1.57 to 4.99
MTD<5.0 & Multifocality & AFP≤100	2.17	0.71	0.02	1.15 to 4.11
MTD<5.0 & Multifocality & AFP>100	6.93	2.31	<0.001	3.60 to 13.31
MTD≥5.0 & Unifocality & AFP≤100	4.68	1.20	<0.001	2.83 to 7.73
MTD≥5.0 & Unifocality & AFP>100	7.48	1.92	<0.001	4.52 to 12.38
MTD≥5.0 & Multifocality & AFP≤100	9.50	2.76	<0.001	5.37 to 16.80
MTD≥5.0 & Multifocality & AFP>100	17.94	4.80	<0.001	10.62 to 30.30

OR, odds ratio; se(OR), standard error of odds ratio; PVT, portal vein thrombosis; MTD, maximum tumor diameter; AFP, alpha-fetoprotein.

HCC patients [1, 5–7, 24–26]. It is typically diagnosed radiologically [13–15] and although pathological confirmation often requires examination of resected or transplantation specimens, percutaneous biopsy material can also be used [27, 28]. Despite this, some factors have been associated with discriminate better survival among patients with PVT. These include serum albumin levels [9], C-reactive protein [11], and AFP levels [29] and some subsets of patients have been identified as having better prognosis [24, 25, 30, 31]. The causes of increased death in HCC patients with PVT include worsened residual liver function and the presence of tumor cells in the vein as a pathway to systemic spread of tumor and distant metastasis.

The mechanisms involved in the pathogenesis of PVT include disruption of the tumor matrix, migration and invasion of the tumor cells, systemic inflammation [32], and DCP [16–19]. AFP levels are typically elevated in HCC patients with PVT, but whether they are cause or consequence is unclear.

Treatment of HCC patients with PVT is controversial [5] with more than usual complications and some limited survival benefit [33, 34]. Recently, radioembolization has emerged as a safer therapy [35, 36], but its effects on survival have yet to be proved. However, some evidence suggests that chemoembolization may also be useful in the presence of PVT [37, 38]. Furthermore, Sorafenib has been found to be a safe treatment in this setting [39] and may be as effective as radioembolization. In additional, multiple different radiation modalities have been evaluated in the presence of PVT, with few differences between them [40].

A major finding in this analysis was the increase in % of patients with PVT as MTD increased (Tables 1, 2, and 3, Figure 1). We considered 2 possible explanations for this. One is that the same factors that induce tumor growth, such as stem cells or growth factors, also enhance tumor invasion and thus MTD. Alternatively, there might be some change in HCC biology beyond a certain size that is associated with more

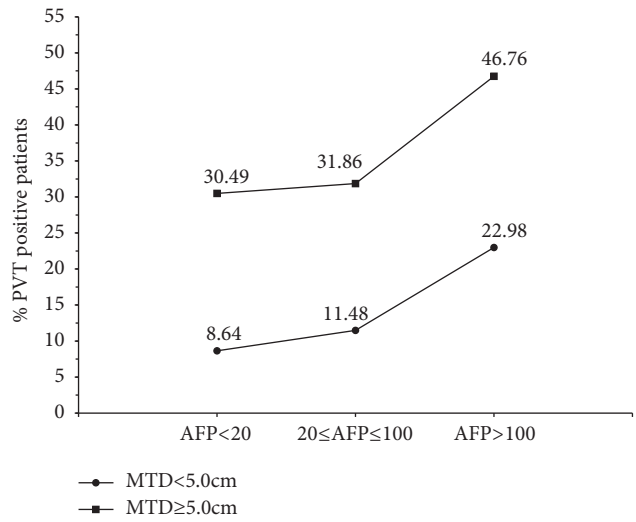

Figure 2: Percentage of patients with PVT in MTD (cm) categories: MTD<5.0cm ($p < 0.0001^*$) and MTD≥5.0cm ($p < 0.0001^*$). * Chi-square test for trend; PVT, portal vein thrombosis; MTD, maximum tumor dimension (cm); AFP, alpha-fetoprotein (IU/mL).

aggressive features. Table 1 shows that the proportion of very large MTD tumors with and without PVT is similar. Furthermore, within this category, average MTD is almost identical. This suggests that it is not tumor size per se. Perhaps there are 2 different growth pathways, one associated with PVT and the other not. This could explain why large tumors are well represented in the PVT positive and negative groups (Table 1). The same Table 1 also shows that both tumor multifocality and average AFP values are always significantly higher in every MTD category that has PVT patients compared to each PVT negative category, suggesting that the tumors are more aggressive in the PVT patients, whether they are larger or not. However, even in the highest AFP groups, less than 50% of the patients were PVT positive, as shown in Figure 2. Other reports have found elevated bilirubin levels in PVT patients, but our data do not really show this. Thus, the patients with PVT in this cohort have aggressive HCCs which did not destroy sufficient liver parenchyma to cause liver failure. PVT is generally classified as macroscopic or microscopic [5]. The current study was based on clinical/nonsurgical evidence (macroscopic) for PVT. Thus, a proportion of our patients classed as PVT negative macroscopically could still be PVT positive microscopically. It has also been reported that PVT seems to occur at a very early stage of HCC evolution [41]. These findings support the idea of 2 possible HCC developmental pathways, namely, HCCs with and without macroscopic PVT. Factors other than MTD and AFP must also be involved in the development of PVT.

Abbreviations

HCC: Hepatocellular carcinoma
PVT: Portal vein thrombosis
AFP: Alpha-fetoprotein
GGTP: Gamma glutamyl transpeptidase
ALKP: Alkaline phosphatase
AST: Aspartate aminotransferase
Alb: Albumin
MTD: Maximum tumor diameter
CRP: C-reactive protein
CT: Computerized axial tomography
MRI: Magnetic resonance imaging.

Authors' Contributions

Hikmet Akkiz and Brian I. Carr contributed equally.

Conflicts of Interest

The authors declare no conflicts of interest. All authors have read and agree with this paper.

Acknowledgments

This work is supported in part by NIH Grant CA 82723 (Brian I. Carr)

References

[1] B. I. Carr, P. Pancoska, and R. A. Branch, "Tumor and liver determinants of prognosis in unresectable hepatocellular carcinoma: a large case cohort study," *Hepatology International*, vol. 4, no. 1, pp. 396–405, 2010.

[2] M. Schöniger-Hekele, C. Müller, M. Kutilek, C. Oesterreicher et al., "Hepatocellular carcinoma in Central Europe: prognostic features and survival," *Gut*, vol. 48, pp. 103–109, 2001.

[3] M. Pirisi, C. Avellini, C. Fabris et al., "Portal vein thrombosis in hepatocellular carcinoma: Age and sex distribution in an autopsy study," *Journal of Cancer Research and Clinical Oncology*, vol. 124, no. 7, pp. 397–400, 1998.

[4] S. Roayaie, I. N. Blume, S. N. Thung et al., "A system of classifying microvascular invasion to predict outcome after resection in patients with hepatocellular carcinoma," *Gastroenterology*, vol. 137, no. 3, pp. 850–855, 2009.

[5] M. Quirk, Y. H. Kim, S. Saab, and E. W. Lee, "Management of hepatocellular carcinoma with portal vein thrombosis," *World Journal of Gastroenterology*, vol. 21, no. 12, pp. 3462–3471, 2015.

[6] S. Hagiwara, M. Kudo, T. Kawasaki et al., "Prognostic factors for portal venous invasion in patients with hepatocellular carcinoma," *Journal of Gastroenterology*, vol. 41, no. 12, pp. 1214–1219, 2006.

[7] M. Gotoh, "Prediction of invasive activities in hepatocellular carcinomas with special reference to alpha-fetoprotein and des-gamma-carboxyprothrombin," *Japanese Journal of Clinical Oncology*, vol. 33, no. 10, pp. 522–526, 2003.

[8] Y. Koike, Y. Shiratori, S. Sato et al., "Des-gamma-carboxy prothrombin as a useful predisposing factor for the development of portal venous invasion in patients with hepatocellular carcinoma: a prospective analysis of 227 patients," *Cancer*, vol. 91, pp. 561–569, 2001.

[9] B. I. Carr and V. Guerra, "Serum Albumin Levels in Relation to Tumor Parameters in Hepatocellular Carcinoma Patients," *The International Journal of Biological Markers*, vol. 32, no. 4, pp. 391–396, 2017.

[10] A. Kinoshita, H. Onoda, K. Takano et al., "Pretreatment serum C-reactive protein level predicts poor prognosis in patients with hepatocellular carcinoma," *Medical Oncology*, vol. 29, no. 4, pp. 2800–2808, 2012.

[11] J. M. Kim, C. H. D. Kwon, J.-W. Joh et al., "C-reactive protein may be a prognostic factor in hepatocellular carcinoma with malignant portal vein invasion," *World Journal of Surgical Oncology*, vol. 11, article no. 92, 2013.

[12] C. R. Taylor, "Computed tomography in the evaluation of the portal venous system," *Journal of Clinical Gastroenterology*, vol. 14, no. 2, pp. 167–172, 1992.

[13] M. E. Tublin, G. D. Dodd 3rd, and R. L. Baron, "Benign and malignant portal vein thrombosis: differentiation by CT characteristics," *American Journal of Roentgenology*, vol. 168, no. 3, pp. 719–723, 1997.

[14] S. Rossi, G. Ghittoni, V. Ravetta et al., "Contrast-enhanced ultrasonography and spiral computed tomography in the detection and characterization of portal vein thrombosis complicating hepatocellular carcinoma," *European Radiology*, vol. 18, no. 8, pp. 1749–1756, 2008.

[15] L. Tarantino, P. Ambrosino, and M. N. D. Di Minno, "Contrast-enhanced ultrasound in differentiating malignant from benign portal vein thrombosis in hepatocellular carcinoma," *World Journal of Gastroenterology*, vol. 21, no. 32, pp. 9457–9460, 2015.

[16] M. Suzuki, H. Shiraha, T. Fujikawa et al., "Des-γ-carboxy prothrombin is a potential autologous growth factor for hepatocellular carcinoma," *The Journal of Biological Chemistry*, vol. 280, no. 8, pp. 6409–6415, 2005.

[17] Y. Zhang, J. Chu, S. Cui, Z. Song, and X. Qu, "Des-gamma-carboxy prothrombin (DCP) as a potential autologous growth factor for the development of hepatocellular carcinoma," *Cellular Physiology and Biochemistry*, vol. 34, no. 3, pp. 903–915, 2014.

[18] P. Yue, Z.-H. Gao, X. Xue et al., "Des-γ-carboxyl prothrombin induces matrix metalloproteinase activity in hepatocellular carcinoma cells by involving the ERK1/2 MAPK signalling pathway," *European Journal of Cancer*, vol. 47, no. 7, pp. 1115–1124, 2011.

[19] T. Suehiro, T. Matsumata, H. Itasaka, A. Taketomi, K. Yamamoto, and K. Sugimachi, "Des-gamma-carboxy prothrombin and proliferative activity of hepatocellular carcinoma," *Surgery*, vol. 117, no. 6, pp. 682–691, 1995.

[20] M. Ma, X.-J. Qu, G.-Y. Mu et al., "Vitamin K2 inhibits the growth of hepatocellular carcinoma via decrease of des-gamma-carboxy prothrombin," *Chemotherapy*, vol. 55, pp. 28–35, 2009.

[21] M. Otsuka, N. Kato, R.-X. Shao et al., "Vitamin K2 inhibits the growth and invasiveness of hepatocellular carcinoma cells via protein kinase A activation," *Hepatology*, vol. 40, no. 1, pp. 243–251, 2004.

[22] B. I. Carr, Z. Wang, M. Wang, and G. Wei, "Differential effects of vitamin K1 on AFP and DCP levels in patients with unresectable HCC and in HCC cell lines," *Digestive Diseases and Sciences*, vol. 56, no. 6, pp. 1876–1883, 2011.

[23] Z. Wang, M. Wang, F. Finn, and B. I. Carr, "The growth inhibitory effects of vitamins K and their actions on gene expression," *Hepatology*, vol. 22, no. 3, pp. 876–882, 1995.

[24] J. Bruix, A. Cheng, G. Meinhardt, K. Nakajima, Y. De Sanctis, and J. Llovet, "Prognostic factors and predictors of sorafenib benefit in patients with hepatocellular carcinoma: Analysis of two phase III studies," *Journal of Hepatology*, vol. 67, no. 5, pp. 999–1008, 2017.

[25] A. A. Mokdad, A. G. Singal, J. A. Marrero, H. Zhu, and A. C. Yopp, "Vascular Invasion and Metastasis is Predictive of Outcome in Barcelona Clinic Liver Cancer Stage C Hepatocellular Carcinoma," *Journal of the National Comprehensive Cancer Network*, vol. 15, no. 2, pp. 197–204, 2017.

[26] The Cancer of the Liver Italian Program (CLIP) Investigators, "Prospective validation of the CLIP score: a new prognostic system for patients with cirrhosis and hepatocellular carcinoma," *Hepatology*, vol. 31, pp. 840–845, 2000.

[27] Dodd GD 3rd and B. I. Carr, "Percutaneous biopsy of portal vein thrombus: A new staging technique for hepatocellular carcinoma," *American Journal of Roentgenology*, vol. 161, pp. 229–233, 1993.

[28] I. De Sio, L. Castellano, M. Calandra, M. Romano, M. Persico, and C. Del Vecchio-blanco, "Ultrasound guided fine needle aspiration biopsy of portal vein thrombosis in liver cirrhosis: results in 15 patients," *Journal of Gastroenterology and Hepatology*, vol. 10, pp. 662–665, 1995.

[29] B. I. Carr and V. Guerra, "Low Alpha-Fetoprotein Levels Are Associated with Improved Survival in Hepatocellular Carcinoma Patients with Portal Vein Thrombosis," *Digestive Diseases and Sciences*, vol. 61, pp. 937–947, 2016.

[30] K.-W. Lee, S.-W. Suh, Y. Choi et al., "Macrovascular invasion is not an absolute contraindication for living donor liver transplantation," *Liver Transplantation*, vol. 23, no. 1, pp. 19–27, 2017.

[31] S. H. Kang, D. Y. Kim, S. M. Jeon et al., "Clinical characteristics and prognosis of hepatocellular carcinoma with different sets of serum AFP and PIVKA-II levels," *European Journal of Gastroenterology & Hepatology*, vol. 24, no. 7, pp. 849–856, 2012.

[32] X. Li, Z.-H. Chen, Y.-F. Xing et al., "Platelet-to-lymphocyte ratio acts as a prognostic factor for patients with advanced hepatocellular carcinoma," *Tumor Biology*, vol. 36, no. 4, pp. 2263–2269, 2015.

[33] Y. Yamamoto, H. Ikoma, R. Morimura, K. Shoda et al., "Post-hepatectomy survival in advanced hepatocellular carcinoma with portal vein tumor thrombosis," *World Journal of Gastroenterology*, vol. 21, no. 1, pp. 246–253, 2015.

[34] Y. P. Le Treut, J. Hardwigsen, P. Ananian et al., "Resection of Hepatocellular Carcinoma with Tumor Thrombus in the Major Vasculature. A European Case-Control Series," *Journal of Gastrointestinal Surgery*, vol. 10, no. 6, pp. 855–862, 2006.

[35] L. M. Kulik, B. I. Carr, M. F. Mulcahy, and R. J. Lewandowski, "Safety and efficacy of 90Y radiotherapy for hepatocellular carcinoma with and without portal vein thrombosis," *Hepatology*, vol. 47, pp. 71–81, 2008.

[36] W.-Y. Lau, B. Sangro, P.-J. Chen et al., "Treatment for hepatocellular carcinoma with portal vein tumor thrombosis: the emerging role for radioembolization using yttrium-90," *Oncology*, vol. 84, no. 5, pp. 311–318, 2013.

[37] B. I. Carr, W. Irish, and M. P. Federle, "Chemoembolization for unresectable hepatocellular carcinoma in patients with or without portal vein thrombosis," *Hepato-Gastroenterology*, vol. 57, no. 104, pp. 1375–1381, 2010.

[38] J. Y. Cheong, K. M. Lee, S. W. Cho et al., "Survival benefits of intra-arterial infusion chemotherapy in patients with advanced hepatocellular carcinoma with portal vein tumor thrombosis," *Hepatology Research*, vol. 32, no. 2, pp. 127–133, 2005.

[39] J. Edeline, L. Crouzet, B. Campillo-Gimenez et al., "Selective internal radiation therapy compared with sorafenib for hepatocellular carcinoma with portal vein thrombosis," *European Journal of Nuclear Medicine and Molecular Imaging*, vol. 43, no. 4, pp. 635–643, 2016.

[40] C. H. Rim, C. Y. Kim, D. S. Yang, and W. S. Yoon, "Comparison of radiation therapy modalities for hepatocellular carcinoma with portal vein thrombosis: A meta-analysis and systematic review," *Radiotherapy & Oncology*, vol. 17, pp. 32730–32735, Dec, 2017.

[41] Y. Zhong, M. Deng, and R. Xu, "Reappraisal of evidence of microscopic portal vein involvement by hepatocellular carcinoma cells with stratification of tumor size," *World Journal of Surgery*, vol. 39, no. 5, pp. 1142–1149, 2015.

Hindawi
Canadian Journal of Gastroenterology and Hepatology
Volume 2018, Article ID 4756147, 8 pages
https://doi.org/10.1155/2018/4756147

Review Article

Percutaneous Ablation for Hepatocellular Carcinoma: Comparison of Various Ablation Techniques and Surgery

Shuichiro Shiina,[1] Koki Sato,[1] Ryosuke Tateishi,[2] Motonori Shimizu,[1] Hideko Ohama,[1] Takeshi Hatanaka,[1] Masashi Takawa,[1] Hiroaki Nagamatsu,[1] and Yasuharu Imai[1]

[1]*Department of Gastroenterology, Juntendo University School of Medicine, Japan*
[2]*Department of Gastroenterology, The University of Tokyo, Japan*

Correspondence should be addressed to Shuichiro Shiina; ivo@juntendo.ac.jp

Received 31 December 2017; Revised 3 April 2018; Accepted 22 May 2018; Published 3 June 2018

Academic Editor: Tatsuo Kanda

Image-guided percutaneous ablation is considered best in the treatment of early-stage hepatocellular carcinoma (HCC). Ablation is potentially curative, minimally invasive, and easily repeatable for recurrence. Ethanol injection used to be the standard in ablation. However, radiofrequency ablation has recently been the most prevailing ablation method for HCC. Many investigators have reported that radiofrequency ablation is superior to ethanol injection, from the viewpoints of treatment response, local tumor curativity, and overall survival. New-generation microwave ablation can create a larger ablation volume in a shorter time period. Further comparison studies are, however, mandatory between radiofrequency ablation and microwave ablation, especially in terms of complications and long-term survival. Irreversible electroporation, which is a non-thermal ablation method that delivers short electric pulses to induce cell death due to apoptosis, requires further studies, especially in terms of long-term outcomes. It is considerably difficult to compare outcomes in ablation with those in surgical resection. However, radiofrequency ablation seems to be a satisfactory alternative to resection for HCC 3 cm or smaller in Child-Pugh class A or B cirrhosis. Furthermore, radiofrequency ablation may be a first-line treatment in HCC 2 cm or smaller in Child-Pugh class A or B cirrhosis. Various innovations would further improve outcomes in ablation. Training programs may be effective in providing an excellent opportunity to understand basic concepts and learn cardinal skills for successful ablation. Sophisticated ablation would be more than an adequate alternative of surgery for small- and possibly middle-sized HCC.

1. Introduction

Hepatocellular carcinoma (HCC) is the sixth in prevalence and the second in mortality among malignant neoplasms in the world [1]. Currently, almost 80% of victims are found in Asia, and the global incidence of HCC is increasing steadily [2, 3]. Surgical resection can be applicable in only 20 % of HCC patients [4]. Furthermore, HCC frequently recurs even after apparently curative resection. Liver transplantation, which is the best therapeutic option in some patients because it can be a treatment not only for HCC but also for cirrhosis, plays a limited role by organ donor shortage. Thus, various nonsurgical therapies have developed [3, 5, 6]. Among these, image-guided percutaneous ablation is regarded as best in the treatment of early-stage HCC. It includes ethanol injection [7–9], microwave ablation (MWA) [10], radiofrequency ablation (RFA) [11–13], irreversible electroporation (IRE), and cryoablation. Ablation can be curative, minimally invasive, and easily repeatable for recurrence. Ablation is generally indicated on patients with small HCC, preferably for those with Child-Pugh class A or B liver dysfunction, up to three tumors each 3 cm or smaller in diameter [14, 15].

2. Ethanol Injection

Percutaneous ethanol injection was first described in the early 1980s [7–9] and had long been the standard in ablation. It is a well-tolerated, low-cost, and considerably safe treatment. Survival of patients who underwent ethanol injection has been reported to be 38–60% at 5 years [16–19]. In our study of 685 primary HCC patients on whom we performed 2,147 ethanol injection treatments, with a median follow-up of 51.6

months, survival rates were 49.0%, 17.9%, and 7.2% at 5, 10, and 20 years, respectively [19]. It has been reported that local tumor progression rates after percutaneous ethanol injection were 6–31%, which were significantly related to the size of tumor [16, 18, 20, 21]. There has been a general agreement that percutaneous ethanol injection is a safe procedure, with mortality and morbidity of 0–3.2% and 0–0.4%, respectively [18–20, 22]. Nowadays, ethanol injection is a treatment of choice only in cases in which RFA cannot be feasible because of either enterobiliary reflux, adhesion of the tumor with the gastrointestinal tract, or other reasons [15].

3. RFA

RFA uses high-frequency alternating current to destroy solid tumor tissue. Radiofrequency energy emitted from the exposed tip of the electrode is converted into heat. Heat is conducted considerably homogeneously in all directions; the capsule or septa of the lesion may not be a barrier of the conduction to a great degree. There are three types of electrodes: multitined expandable electrodes, internally cooled ones, and perfusion ones. RFA has recently been the most prevailing ablation technique for HCC [15]. It has been reported that survival at 5 years was 39.9–68.5% [14, 23–27]. In our study of 1,170 primary HCC patients on whom we performed 2,982 RFA treatments, with a median follow-up of 38.2 months, survival rates were 60.2 % and 27.3 % at 5 and 10 years, respectively [14]. It has been reported that local tumor progression rates after RFA were 2.4–27.0% [14, 23–27]. It has been reported that mortality and morbidity of RFA were 0.9–7.9% and 0–1.5%, respectively [14, 23–26]. Various clinical attempts, such as combination of transcatheter arterial chemoembolization followed by RFA [28] and hepatic arterial balloon occlusion during RFA [29], have been conducted to increase the ablation volume by decreasing the cooling effect of the arterial flow. There have also been some studies in which they say that multipolar RFA would be useful to increase the volume of ablation and reduce local tumor progression [30].

4. MWA

In MWA, tumor tissue is destroyed by direct hyperthermic injury produced by electromagnetic wave emitted from the noninsulated portions of the antenna. Microwave coagulation has been used in transaction of the liver to control bleeding from planes during resection. The first-generation MWA for clinical practice was reported in the 1990s [10]. However, its necrotic volume was small. It was prolate spheroid, 1.5 cm in short diameter and 2.5 cm in long diameter. Still worse, antenna shaft became hot from reflected power in the first-generation MWA, which results in development of pleural effusion or skin burn at the insertion site. We shifted from ethanol injection and the first-generation MWA to RFA in Japan [31].

MWA is, however, considered to have physical advantages in comparison with RFA. These advantages include a larger volume of active heating resulting in shorter procedure times, insensitivity to carbonization, higher tissue temperatures beyond the threshold of water vaporization, and less susceptibility to the heat sink effect of blood flow which results in incomplete ablation [32–34]. Thus, new-generation MWA systems incorporating water or gas antenna cooling and high-power generation have been developed and have recently been attracting large attention [35]. New-generation MWA may create a more predictable ablation zone and a larger ablation volume in a shorter time period. However, its clinical data have been insufficient compared with that of RFA. Further studies are mandatory especially in terms of long-term survival [36, 37].

5. IRE

IRE is a non-thermal ablation treatment that delivers short electric pulses to induce cell death due to apoptosis. The basic principle of IRE is to create irreversible pores in cellular bilipid membranes by subjecting them to a series of high voltage (>640 V/cm) and high intensity (>20 A) electrical pulses of short duration (70–100 μsec) [38]. With this method, the skeleton of connective tissue, vessels, and bile ducts are largely preserved [39]. IRE seems to be an attractive alternative option for tumors near the porta hepatis or others in which thermal ablations are risky to be performed [40, 41]. However, IRE is more invasive and troublesome because general anesthesia with muscular blockade is needed. In addition, IRE also produces some degree of thermal effects which can injure bile ducts and other structures. Further studies are mandatory in IRE especially in terms of long-term outcomes.

6. Cryoablation

In contrast to RFA and MWA, cryoablation uses extremely low temperature to kill tumors. Tumor tissue is destroyed by both direct and indirect effects. The direct effect is a result of intra-and extracellular ice crystal formation and solute-solvent shifts, which induce cell dehydration and rupture. The indirect effect resulted from the vascular injury which would result in ischemic hypoxia. Apoptosis and immunomodulation may also play a role in cell injury [42]. Cryoablation has an advantage of its precise monitoring of ablated area during the procedure by various imaging modalities, such as CT, MRI, or ultrasound [43], therefore optimally controlling the treatment effects. A meta-analysis concluded that RFA is superior to cryoablation from the viewpoints of complications, local recurrence of patient, and local recurrence of tumor although there was no significant difference in mortality [44]. However, a randomized controlled trial said that local tumor progression is significantly less frequent in cryoablation than in RFA, although complications, tumor-free survival rates, and overall survival rates were not significantly different between the two techniques [45].

7. Comparison among Percutaneous Ablation Therapies

Six randomized controlled trials have been reported to compare RFA with ethanol injection. Superiority of RFA to ethanol injection, from the viewpoints of treatment response,

local tumor curativity, and overall survival, has been found in four of them [13, 46–48], while the other two trials showed that the overall survival was not significantly different between them [49]. Ethanol injection, however, does not need special instruments and is inexpensive [50]. Ethanol injection may be an option in very small HCC.

Regarding the first-generation MWA, a randomized controlled trial to compare it with RFA demonstrated that the number of treatment sessions was smaller in RFA, although there was no statistically significant difference in terms of complete therapeutic effect, major complication, and local tumor progression between them [51]. A cohort study to compare the first-generation MWA with RFA for HCC of up to 2 cm in diameter showed that RFA was more effective than the first-generation MWA, because there was a significant difference in terms of treatment sessions, size of necrotic area, local recurrence rate, cumulative survival rate, adverse events of pain, fever, biliary injury, pleural effusion, and ascites between the two therapies [52].

Regarding new-generation MWA, many studies failed to show that new-generation MWA is superior to RFA from the viewpoint of local control and overall survival. A cohort study to compare it with RFA showed that there was no significant difference in complete therapeutic response, residual foci of untreated disease rate, recurrence rate, or progression-free survival between the two therapies [53]. Another cohort study to compare new-generation MWA with RFA for HCC up to 5 cm in diameter showed that there was no significant difference in complete ablation, local tumor progression, overall survival, or disease-free survival rates [54]. Another study also failed to show that there was a significant difference in terms of complete ablation, local recurrence, major adverse events, disease-free survival, or overall survival rates between the two therapies [55]. Another study to compare the two therapies for HCC within the Milan criteria did not demonstrate that complete ablation, local recurrence, disease-free survival, cumulative survival, or major complication rates were different between them, either [56]. Another comparative study showed that there was no significant difference in complete ablation, complication, de novo lesions, portal vein thrombosis, abdominal lymphadenopathy, and overall survival rates between the two therapies, while local recurrence rates were significantly lower in MWA [57]. Further comparison studies are mandatory between RFA and new-generation MWA, especially in terms of adverse events and long-term survival.

8. Comparison between Percutaneous Ablation Therapies and Surgical Resection

Comparison of ablation with surgical resection is considerably difficult; the indications are somewhat different between the two treatments. Patients of multiple lesions, advanced age, or more deteriorated liver function tend to undergo ablation while those of a large tumor tend to receive surgical resection. Furthermore, both treatments are highly operator-dependent and their indications may be different from institution to institution. Thus, a patient who is decided by medical professionals to undergo ablation or surgical resection at an institution may not be given the same treatment at others.

There have been four randomized controlled trials to compare RFA with surgical resection. Three of them demonstrated that overall survival was not significantly different between the two treatments. A study on patients with a solitary HCC up to 5 cm in diameter showed that overall survival and disease-free survival were not statistically different between the two treatments, but adverse events were more frequent and severe in surgical resection [58]. Another study on patients with nodular diameters of less than 4 cm and one or two nodules showed that there were no significant differences between the two treatments in overall survival and recurrence-free survival [59]. In another trial on patients with HCC up to 3 cm in diameter, there was no significant difference of the disease-free and overall survival between the two treatments, although the postoperative adverse events were significantly more frequent and hospital stay was significantly longer in surgical resection [60]. Only the remaining study on patients within the Milan criteria showed that there was a significant difference in overall survival and recurrence-free survival between the two treatments [61]. There was a randomized controlled trial to compare chemoembolization plus RFA with partial hepatectomy for HCC within the Milan criteria, which said that partial hepatectomy had better overall and recurrence-free survival than the combination of chemoembolization with RFA [61, 62]. However, it does not seem to be widely used to combine chemoembolization with RFA for HCC within the Milan criteria.

Concerning overall survival, some nonrandomized comparative studies reported that RFA had similar outcomes to resection [63–76] while others found that resection had better survival [74, 77–82]. There was a study in which RFA showed a better long-term survival than surgical resection after propensity score analysis [83]. There was another study which reported that, in HCC cases of 2 cm or smaller, major adverse events occurred significantly more often in surgical resection than in RFA and overall survival was better in RFA than in surgical resection [84]. Even in studies in which surgical resection was reported to be superior to RFA, there were no significant differences in overall survival between the two treatments in patients with HCC 2 cm or smaller [80] or 3 cm or smaller in diameter [74, 78, 79]. RFA was associated with less frequent adverse events [71, 79] and shorter hospital stay [71]. From the viewpoint of cost-effectiveness, RFA may be superior to surgical resection [85]. RFA seems to be a satisfactory alternative to resection for HCC up to 3 cm in diameter in Child-Pugh class A or B cirrhosis. Furthermore, RFA may be a first-line treatment in HCC up to 2 cm in diameter in Child-Pugh class A or B cirrhosis.

Most studies reported that recurrence-free survival was better in surgical resection than in RFA, although overall survival was not significantly different between the two treatments. This is probably because surgical resection sacrifices a much larger volume of non-cancerous liver tissue. It may remove some latent metastases and reduce new carcinogenesis, resulting in lower recurrence rates. However, it may lead to liver decompensation in some cases. In addition, most recurrence can be treated curatively by iterative RFA but not

Figure 1: We participated in development of a dedicated ultrasonic transducer and have used it in 12,000 procedures of radiofrequency ablation. The dedicated ultrasonic transducer has the following advantages: (1) needle slot is located inside the transducer, (2) a puncture angle of 100 degrees is available in addition to 55, 70, and 85 degrees, (3) the same image is obtained as a regular convex transducer generates, (4) a puncture attachment is unified with the transducer, and (5) it is capable of multimodality fusion imaging.

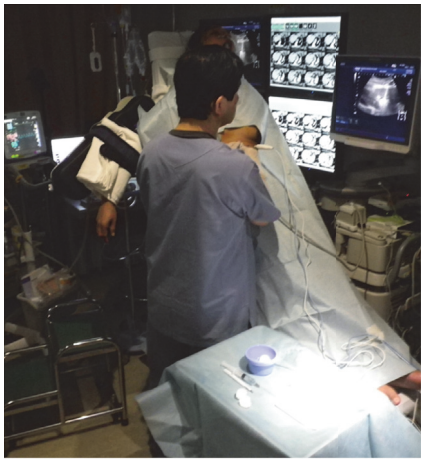

Figure 2: We developed a dedicated procedure bed. Using this bed, we can keep a patient in an optimal position, such as right hemilateral decubitus position, left hemilateral decubitus position, head-up position, sitting position, and almost standing position.

Figure 3: Lecture topics are current status of ablation, ablation systems, ultrasound systems, various techniques in ablation, and others.

by repeated surgical resection. In our study, the first recurrence was treated by iterative RFA in 659 (88.9 %) of the 741 patients. In the remaining, transarterial chemoembolization in 69 (9.3 %), systemic chemotherapy in 4 (0.5 %), surgical resection in 3 (0.4 %), radiation therapy in 2 (0.3 %), and supportive care in 4 (0.5 %) were chosen [14]. On the other hand, repeated surgical resection can be an option in only 20-30% of patients with recurrent HCC.

9. Various Innovations and Sophisticated Instruments

We developed a dedicated ultrasound transducer for puncture (PVT-350BTP, Toshiba, Japan) (Figure 1) in corporation with Toshiba. We have performed RFA over 10,000 cases of liver tumors using this dedicated ultrasound probe. Contrast-enhanced ultrasound is useful to detect viable tumor persistence following locoregional treatment (either ablation or chemoembolization). There are cases in which B-mode ultrasound cannot clearly identify a viable portion of the tumor. Using ultrasound contrast agents, vascular imaging shows a hypervascular area which represents the residual cancer tissue. We developed a dedicated procedure bed (Figure 2). Using this bed, we can keep a patient in an optimal position. Multimodality fusion imaging is also useful to detect tumors not clearly identified by ultrasound. It is a system in which fused CT or MR images created from previously acquired imaging data demonstrate the same plane and move synchronously with **real-time** ultrasound images. Various innovations would further improve outcomes in percutaneous ablation.

10. Training Programs

Because ablation appears a simple procedure, it may be done without sufficient training. However, ablation is considerably operator-dependent. Its skills and outcomes differ much from operator to operator. In order to disseminate skills and know-hows, there are some training programs for ablation. For example, our training programs are composed of comprehensive lectures (Figure 3), live demonstrations (Figure 4), and case studies (Figure 5). We have held domestic training programs 10 times, and a total of 170 doctors attended. We also have had international ones 4 times, which were successfully completed with 49 participants in total. Training programs may be effective in providing an excellent opportunity to understand basic concepts and learn cardinal skills for successful ablation.

11. Conclusions

Ablation has been widely performed in the treatment of HCC. Ablation is potentially curative, minimally invasive,

Figure 4: In live demonstrations, we perform ablation on various cases: a case of first diagnosed cancer not difficult to ablate judging from its size and location, a case of a tumor beneath the diaphragm requiring artificial ascites, a case of a tumor in the caudate lobe, a case of a tumor adjacent to the heart, a case of a tumor next to portal vein or hepatic vein at porta hepatis, a case of a tumor over 5 cm in diameter, a case of more than five tumors, cases of hepatic metastasis from the colorectal cancer or the gastric cancer, a case of simple nodular type HCC with extranodular growth or confluent multinodular type HCC, a case of a tumor with unclear boundaries on ultrasound which requires contrast-enhanced ultrasound to perform RFA, a case in which a tumor cannot be detected on ultrasound and requires support of fusion imaging, and others. From these cases, we demonstrate the importance of appropriate patient posture, usefulness of our original dedicated probe for interventional procedures and our RFA dedicated operation table, and the way to carry out ablation under contrast-enhanced ultrasound guidance and with multimodality fusion imaging.

Figure 5: In case studies, difficult to ablate cases from participants' institutions are presented and discussed.

and easily repeatable for recurrence. In RFA, outcomes in over 10-year period clearly show that RFA is a curative treatment and enables long-term survival. There are still arguments regarding whether it is proper to perform ablation on resectable cases or not. The number of patients treated by ablation, however, has been increasing. Various innovations would further improve outcomes in ablation. Training programs may be effective in acquiring necessary skills, knowledge, and experience for successful ablation. Sophisticated ablation would be more than an adequate alternative of surgery for small- and possibly middle-sized HCC.

Conflicts of Interest

The authors declare that there are no conflicts of interest regarding the publication of this paper.

References

[1] D. Maxwell Parkin, F. Bray, J. Ferlay, and P. Pisani, "Estimating the world cancer burden: Globocan 2000," *International Journal of Cancer*, vol. 94, no. 2, pp. 153–156, 2001.

[2] D. Poon, B. O. Anderson, L.-T. Chen et al., "Management of hepatocellular carcinoma in Asia: consensus statement from the Asian Oncology Summit 2009," *The Lancet Oncology*, vol. 10, no. 11, pp. 1111–1118, 2009.

[3] S. D. Ryder, "Guidelines for the diagnosis and treatment of hepatocellular carcinoma (HCC) in adults," *Gut*, vol. 52, no. 3, pp. iii1–iii8, 2003.

[4] F. Borie, A.-M. Bouvier, A. Herrero et al., "Treatment and prognosis of hepatocellular carcinoma: A population based study in France," *Journal of Surgical Oncology*, vol. 98, no. 7, pp. 505–509, 2008.

[5] J. M. Llovet, A. Burroughs, and J. Bruix, "Hepatocellular carcinoma," *The Lancet*, vol. 362, no. 9399, pp. 1907–1917, 2003.

[6] J. Bruix and M. Sherman, "Management of *Hepatocellular carcinoma*," *Hepatology*, vol. 42, no. 5, pp. 1208–1236, 2005.

[7] N. Sugiura, "Ultrasound image-guided percutaneous intratumor ethanol injection for small hepatocellular carcinoma," *Acta Hepatologica Japonica*, pp. 24–920, 1983 (Japanese).

[8] T. Livraghi, D. Festi, F. Monti, A. Salmi, and C. Vettori, "US-guided percutaneous alcohol injection of small hepatic and abdominal tumors," *Radiology*, vol. 161, no. 2, pp. 309–312, 1986.

[9] S. Shiina, H. Yasuda, H. Muto et al., "Percutaneous ethanol injection in the treatment of liver neoplasms.," *AJR. American journal of roentgenology*, vol. 149, no. 5, pp. 949–952, 1987.

[10] T. Seki, M. Wakabayashi, T. Nakagawa et al., "Ultrasonically guided percutaneous microwave coagulation therapy for small hepatocellular carcinoma," *Cancer*, vol. 74, no. 3, pp. 817–825, 1994.

[11] S. Rossi et al., "Percutaneous radiofrequency interstitial thermal ablation in the treatment of small hepatocellular carcinoma," *Cancer J Sci Am*, vol. 1, no. 1, pp. 73–81, 1995.

[12] T. Livraghi, S. N. Goldberg, S. Lazzaroni, F. Meloni, L. Solbiati, and G. S. Gazelle, "Small hepatocellular carcinoma: treatment with radio-frequency ablation versus ethanol injection," *Radiology*, vol. 210, no. 3, pp. 655–661, 1999.

[13] S. Shiina, T. Teratani, S. Obi et al., "A randomized controlled trial of radiofrequency ablation with ethanol injection for small hepatocellular carcinoma," *Gastroenterology*, vol. 129, no. 1, pp. 122–130, 2005.

[14] S. Shiina, R. Tateishi, T. Arano et al., "Radiofrequency ablation for hepatocellular carcinoma: 10-Year outcome and prognostic factors," *American Journal of Gastroenterology*, vol. 107, no. 4, pp. 569–577, 2012.

[15] M. Omata, A.-L. Cheng, N. Kokudo et al., "Asia–Pacific clinical practice guidelines on the management of hepatocellular carcinoma: a 2017 update," *Hepatology International*, vol. 11, no. 4, pp. 317–370, 2017.

[16] M. Ebara, S. Okabe, K. Kita et al., "Percutaneous ethanol injection for small hepatocellular carcinoma: Therapeutic efficacy based on 20-year observation," *Journal of Hepatology*, vol. 43, no. 3, pp. 458–464, 2005.

[17] S. Shiina, K. Tagawa, Y. Niwa et al., "Percutaneous ethanol injection therapy for hepatocellular carcinoma: Results in 146 patients," *American Journal of Roentgenology*, vol. 160, no. 5, pp. 1023–1028, 1993.

[18] Y. M. Sung et al., "Long-term results of percutaneous ethanol injection for the treatment of hepatocellular carcinoma in Korea," *Korean J Radiol*, vol. 7, no. 3, pp. 187–192, 2006.

[19] S. Shiina, R. Tateishi, M. Imamura et al., "Percutaneous ethanol injection for hepatocellular carcinoma: 20-year outcome and prognostic factors," *Liver International*, vol. 32, no. 9, pp. 1434–1442, 2012.

[20] T. Livraghi, A. Giorgio, G. Marin et al., "Hepatocellular carcinoma and cirrhosis in 746 patients: Long-term results of percutaneous ethanol injection," *Radiology*, vol. 197, no. 1, pp. 101–108, 1995.

[21] H. Ishii, *Local recurrence of hepatocellular carcinoma after percutaneous ethanol injection*, vol. 77, Cancer, 1996.

[22] M. Di Stasi, L. Buscarini, T. Livraghi et al., "Percutaneous ethanol injection in the treatment of hepatocellular carcinoma: A multicenter survey of evaluation practices and complication rates," *Scandinavian Journal of Gastroenterology*, vol. 32, no. 11, pp. 1168–1173, 1997.

[23] R. Lencioni, D. Cioni, L. Crocetti et al., "Early-stage hepatocellular carcinoma in patients with cirrhosis: long-term results of percutaneous image-guided radiofrequency ablation," *Radiology*, vol. 234, no. 3, pp. 961–967, 2005.

[24] R. Tateishi, S. Shiina, T. Teratani et al., "Percutaneous radiofrequency ablation for hepatocellular carcinoma. An analysis of 1000 cases," *Cancer*, vol. 103, no. 6, pp. 1201–1209, 2005.

[25] T. Livraghi, F. Meloni, M. Di Stasi et al., "Sustained complete response and complications rates after radiofrequency ablation of very early hepatocellular carcinoma in cirrhosis: is resection still the treatment of choice?" *Hepatology*, vol. 47, no. 1, pp. 82–89, 2008.

[26] K. Yan, "Radiofrequency ablation of hepatocellular carcinoma: long-term outcome and prognostic factors," *Eur J Radiol*, vol. 67, no. 2, pp. 336–347, 2008.

[27] Y.-S. Kim, H. K. Lim, H. Rhim et al., "Ten-year outcomes of percutaneous radiofrequency ablation as first-line therapy of early hepatocellular carcinoma: analysis of prognostic factors," *Journal of Hepatology*, vol. 58, no. 1, pp. 89–97, 2013.

[28] M. Morimoto, K. Numata, M. Kondou, A. Nozaki, S. Morita, and K. Tanaka, "Midterm outcomes in patients with intermediate-sized hepatocellular carcinoma: A randomized controlled trial for determining the efficacy of radiofrequency ablation combined with transcatheter arterial chemoembolization," *Cancer*, vol. 116, no. 23, pp. 5452–5460, 2010.

[29] M. Kobayashi, K. Ikeda, Y. Kawamura et al., "Randomized controlled trial for the efficacy of hepatic arterial occlusion during radiofrequency ablation for small hepatocellular carcinoma - Direct ablative effects and a long-term outcome," *Liver International*, vol. 27, no. 3, pp. 353–359, 2007.

[30] V. Cartier, J. Boursier, J. Lebigot, F. Oberti, I. Fouchard-Hubert, and C. Aubé, "Radiofrequency ablation of hepatocellular carcinoma: Mono or multipolar?" *Journal of Gastroenterology and Hepatology*, vol. 31, no. 3, pp. 654–660, 2016.

[31] S. Shiina, T. Teratani, S. Obi, K. Hamamura, Y. Koike, and M. Omata, "Nonsurgical treatment of hepatocellular carcinoma: From percutaneous ethanol injection therapy and percutaneous microwave coagulation therapy to radiofrequency ablation," *Oncology*, vol. 62, no. 1, pp. 64–68, 2002.

[32] C. L. Brace, P. F. Laeseke, L. A. Sampson, T. M. Frey, D. W. Van Der Weide, and F. T. Lee Jr., "Microwave ablation with a single small-gauge triaxial antenna: In vivo porcine liver model," *Radiology*, vol. 242, no. 2, pp. 435–440, 2007.

[33] G. D. Dodd III, N. A. Dodd, A. C. Lanctot, and D. A. Glueck, "Effect of variation of portal venous blood flow on radiofrequency and microwave ablations in a blood-perfused bovine liver model," *Radiology*, vol. 267, no. 1, pp. 129–136, 2013.

[34] W. Fan, X. Li, L. Zhang, H. Jiang, and J. Zhang, "Comparison of microwave ablation and multipolar radiofrequency ablation in vivo using two internally cooled probes," *American Journal of Roentgenology*, vol. 198, no. 1, pp. W46–W50, 2012.

[35] M. G. Lubner, C. L. Brace, J. L. Hinshaw, and F. T. Lee Jr., "Microwave tumor ablation: mechanism of action, clinical results, and devices," *Journal of Vascular and Interventional Radiology*, vol. 21, no. 8, pp. S192–S203, 2010.

[36] R. T. Groeschl, C. H. C. Pilgrim, E. M. Hanna et al., "Microwave ablation for hepatic malignancies: A multiinstitutional analysis," *Annals of Surgery*, vol. 259, no. 6, pp. 1195–1200, 2014.

[37] Y. Liu, Y. Zheng, S. Li, B. Li, Y. Zhang, and Y. Yuan, "Percutaneous microwave ablation of larger hepatocellular carcinoma," *Clinical Radiology*, vol. 68, no. 1, pp. 21–26, 2013.

[38] E. W. Lee, C. Chen, V. E. Prieto, S. M. Dry, C. T. Loh, and S. T. Kee, "Advanced hepatic ablation technique for creating complete cell death: Irreversible electroporation," *Radiology*, vol. 255, no. 2, pp. 426–433, 2010.

[39] J. F. Edd, L. Horowitz, R. V. Davalos, L. M. Mir, and B. Rubinsky, "In vivo results of a new focal tissue ablation technique: irreversible electroporation," *IEEE Transactions on Biomedical Engineering*, vol. 53, no. 7, pp. 1409–1415, 2006.

[40] R. Cannon, S. Ellis, D. Hayes, G. Narayanan, and R. C. G. Martin II, "Safety and early efficacy of irreversible electroporation for hepatic tumors in proximity to vital structures," *Journal of Surgical Oncology*, vol. 107, no. 5, pp. 544–549, 2013.

[41] T. P. Kingham, A. M. Karkar, M. I. D'Angelica et al., "Ablation of perivascular hepatic malignant tumors with irreversible electroporation," *Journal of the American College of Surgeons*, vol. 215, no. 3, pp. 379–387, 2012.

[42] N. E. Hoffmann and J. C. Bischof, "The cryobiology of cryosurgical injury," *Urology*, vol. 60, no. 2, pp. 40–49, 2002.

[43] A. Orlacchio, G. Bazzocchi, D. Pastorelli et al., "Percutaneous cryoablation of small hepatocellular carcinoma with US guidance and CT monitoring: Initial experience," *CardioVascular and Interventional Radiology*, vol. 31, no. 3, pp. 587–594, 2008.

[44] Y.-Z. Huang, S.-C. Zhou, H. Zhou, and M. Tong, "Radiofrequency ablation versus cryosurgery ablation for hepatocellular carcinoma: A meta-analysis," *Hepato-Gastroenterology*, vol. 60, no. 125, pp. 1131–1135, 2013.

[45] C. Wang, H. Wang, W. Yang et al., "Multicenter randomized controlled trial of percutaneous cryoablation versus radiofrequency ablation in hepatocellular carcinoma," *Hepatology*, vol. 61, no. 5, pp. 1579–1590, 2015.

[46] R. A. Lencioni, H.-P. Allgaier, D. Cioni et al., "Small hepatocellular carcinoma in cirrhosis: Randomized comparison of radio-frequency thermal ablation versus percutaneous ethanol injection," *Radiology*, vol. 228, no. 1, pp. 235–240, 2003.

[47] S.-M. Lin, C.-J. Lin, C.-C. Lin, C.-W. Hsu, and Y.-C. Chen, "Radiofrequency ablation improves prognosis compared with ethanol injection for hepatocellular carcinoma ≤4 cm," *Gastroenterology*, vol. 127, no. 6, pp. 1714–1723, 2004.

[48] S.-M. Lin, C.-J. Lin, C.-C. Lin, C.-W. Hsu, and Y.-C. Chen, "Randomised controlled trial comparing percutaneous radiofrequency thermal ablation, percutaneous ethanol injection, and percutaneous acetic acid injection to treat hepatocellular carcinoma of 3 cm or less," *Gut*, vol. 54, no. 8, pp. 1151–1156, 2005.

[49] F. Brunello, A. Veltri, P. Carucci et al., "Radiofrequency ablation versus ethanol injection for early hepatocellular carcinoma: A randomized controlled trial," *Scandinavian Journal of Gastroenterology*, vol. 43, no. 6, pp. 727–735, 2008.

[50] A. Giorgio, A. Di Sarno, G. De Stefano et al., "Percutaneous radiofrequency ablation of hepatocellular carcinoma compared to percutaneous ethanol injection in treatment of cirrhotic patients: An Italian randomized controlled trial," *Anticancer Reseach*, vol. 31, no. 6, pp. 2291–2295, 2011.

[51] T. Shibata, Y. Iimuro, Y. Yamamoto et al., "Small hepatocellular carcinoma: Comparison of radio-frequency ablation and percutaneous microwave coagulation therapy," *Radiology*, vol. 223, no. 2, pp. 331–337, 2002.

[52] K. Ohmoto, N. Yoshioka, Y. Tomiyama et al., "Comparison of therapeutic effects between radiofrequency ablation and percutaneous microwave coagulation therapy for small hepatocellular carcinomas," *Journal of Gastroenterology and Hepatology*, vol. 24, no. 2, pp. 223–227, 2009.

[53] T. J. Vogl, P. Farshid, N. N. N. Naguib et al., "Ablation therapy of hepatocellular carcinoma: a comparative study between radiofrequency and microwave ablation," *Abdominal Imaging*, vol. 40, no. 6, pp. 1829–1837, 2015.

[54] L. Zhang, N. Wang, Q. Shen, W. Cheng, and G.-J. Qian, "Therapeutic efficacy of percutaneous radiofrequency ablation versus microwave ablation for hepatocellular carcinoma," *PLoS ONE*, vol. 8, no. 10, Article ID e76119, 2013.

[55] M.-D. Lu, H.-X. Xu, X.-Y. Xie et al., "Percutaneous microwave and radiofrequency ablation for hepatocellular carcinoma: A retrospective comparative study," *Journal of Gastroenterology*, vol. 40, no. 11, pp. 1054–1060, 2005.

[56] J. Ding, X. Jing, J. Liu et al., "Comparison of two different thermal techniques for the treatment of hepatocellular carcinoma," *European Journal of Radiology*, vol. 82, no. 9, pp. 1379–1384, 2013.

[57] A. Abdelaziz, T. Elbaz, H. I. Shousha et al., "Efficacy and survival analysis of percutaneous radiofrequency versus microwave ablation for hepatocellular carcinoma: an egyptian multidisciplinary clinic experience," *Surgical Endoscopy*, vol. 28, no. 12, pp. 3429–3434, 2014.

[58] M. S. Chen et al., "A prospective randomized trial comparing percutaneous local ablative therapy and partial hepatectomy for small hepatocellular carcinoma," *Ann Surg*, vol. 243, no. 3, pp. 321–328, 2006.

[59] K. Feng, J. Yan, X. Li et al., "A randomized controlled trial of radiofrequency ablation and surgical resection in the treatment of small hepatocellular carcinoma," *Journal of Hepatology*, vol. 57, no. 4, pp. 794–802, 2012.

[60] Y. Fang, W. Chen, X. Liang et al., "Comparison of long-term effectiveness and complications of radiofrequency ablation with hepatectomy for small hepatocellular carcinoma," *Journal of Gastroenterology and Hepatology*, vol. 29, no. 1, pp. 193–200, 2014.

[61] J. Huang, Y. Zeng, H. Wu, Z. Chen, and Q. Lu, "A Randomized Trial Comparing Radiofrequency Ablation and Surgical Resection For HCC Conforming to the Milan Criteria," *Annals of Surgery*, vol. 254, no. 5, p. 839, 2011.

[62] H. Liu, Z. G. Wang, S. Y. Fu et al., "Randomized clinical trial of chemoembolization plus radiofrequency ablation versus partial hepatectomy for hepatocellular carcinoma within the Milan criteria," *British Journal of Surgery*, vol. 103, no. 4, pp. 348–356, 2016.

[63] S. N. Hong et al., "Comparing the outcomes of radiofrequency ablation and surgery in patients with a single small hepatocellular carcinoma and well-preserved hepatic function," *J Clin Gastroenterol*, vol. 39, no. 3, pp. 247–252, 2005.

[64] K. Yamagiwa, K. Shiraki, K. Yamakado et al., "Survival rates according to the Cancer of the Liver Italian Program scores of 345 hepatocellular carcinoma patients after multimodality treatments during a 10-year period in a retrospective study," *Journal of Gastroenterology and Hepatology*, vol. 23, no. 3, pp. 482–490, 2008.

[65] K. Yamakado, A. Nakatsuka, H. Takaki et al., "Early-stage hepatocellular carcinoma: Radiofrequency ablation combined with chemoembolization versus hepatectomy," *Radiology*, vol. 247, no. 1, pp. 260–266, 2008.

[66] G.-A. Kim, J. H. Shim, M.-J. Kim et al., "Radiofrequency ablation as an alternative to hepatic resection for single small hepatocellular carcinomas," *British Journal of Surgery*, vol. 103, no. 1, pp. 126–135, 2016.

[67] L. Jiang, L. Yan, T. Wen et al., "Comparison of Outcomes of Hepatic Resection and Radiofrequency Ablation for Hepatocellular Carcinoma Patients with Multifocal Tumors Meeting the Barcelona-Clinic Liver Cancer Stage A Classification," *Journal of the American College of Surgeons*, vol. 221, no. 5, pp. 951–961, 2015.

[68] T. W. Kang, J. M. Kim, H. Rhim et al., "Small hepatocellular carcinoma: Radiofrequency ablation versus nonanatomic resection - Propensity score analyses of long-term outcomes," *Radiology*, vol. 275, no. 3, pp. 908–919, 2015.

[69] H. Yang, J. Lee, D. H. Lee et al., "Small Single-Nodule Hepatocellular Carcinoma: Comparison of Transarterial Chemoembolization, Radiofrequency Ablation, and Hepatic Resection by Using Inverse Probability Weighting," *Radiology*, vol. 271, no. 3, pp. 909–918, 2014.

[70] A. Cucchetti, F. Piscaglia, M. Cescon et al., "An explorative data-analysis to support the choice between hepatic resection and radiofrequency ablation in the treatment of hepatocellular carcinoma," *Digestive and Liver Disease*, vol. 46, no. 3, pp. 257–263, 2014.

[71] Z. Zhou and et al., "Liver resection and radiofrequency ablation of very early hepatocellular carcinoma cases (single nodule <2 cm): a single-center study," *Eur J Gastroenterol Hepatol*, vol. 26, no. 3, pp. 339–344, 2014.

[72] S. Tohme, D. A. Geller, J. S. Cardinal et al., "Radiofrequency ablation compared to resection in early-stage hepatocellular carcinoma," *HPB*, vol. 15, no. 3, pp. 210–217, 2013.

[73] T. Takayama, M. Makuuchi, and K. Hasegawa, "Single HCC smaller than 2 cm: Surgery or ablation? Surgeon's perspective," *Journal of Hepato-Biliary-Pancreatic Sciences*, vol. 17, no. 4, pp. 422–424, 2010.

[74] H. Hung, Y. Chiou, C. Hsia et al., "Survival Rates Are Comparable After Radiofrequency Ablation or Surgery in Patients With Small Hepatocellular Carcinomas," *Clinical Gastroenterology and Hepatology*, vol. 9, no. 1, pp. 79–86, 2011.

[75] R. Santambrogio, E. Opocher, M. Zuin et al., "Surgical resection versus laparoscopic radiofrequency ablation in patients with hepatocellular carcinoma and child-pugh class a liver cirrhosis," *Annals of Surgical Oncology*, vol. 16, no. 12, pp. 3289–3298, 2009.

[76] K.-M. Wong, M.-L. Yeh, S.-C. Chuang et al., "Survival comparison between surgical resection and percutaneous radiofrequency ablation for patients in Barcelona Clinic Liver Cancer early stage hepatocellular carcinoma," *Indian Journal of Gastroenterology*, vol. 32, no. 4, pp. 253–257, 2013.

[77] M. Vivarelli, A. Guglielmi, A. Ruzzenente et al., "Surgical resection versus percutaneous radiofrequency ablation in the treatment of hepatocellular carcinoma on cirrhotic liver," *Annals of Surgery*, vol. 240, no. 1, pp. 102–107, 2004.

[78] A. Guglielmi, A. Ruzzenente, A. Valdegamberi et al., "Radiofrequency ablation versus surgical resection for the treatment of hepatocellular carcinoma in cirrhosis," *Journal of Gastrointestinal Surgery*, vol. 12, no. 1, pp. 192–198, 2008.

[79] I. Gory, M. Fink, S. Bell et al., "Radiofrequency ablation versus resection for the treatment of early stage hepatocellular carcinoma: a multicenter Australian study," *Scandinavian Journal of Gastroenterology*, vol. 50, no. 5, pp. 567–576, 2015.

[80] K. Hasegawa, N. Kokudo, M. Makuuchi et al., "Corrigendum to: "Comparison of resection and ablation for hepatocellular carcinoma: A cohort study based on a Japanese nationwide survey" [J Hepatol 2013;58:724–729]," *Journal of Hepatology*, vol. 59, no. 3, p. 641, 2013.

[81] W. K. Yun, M. S. Choi, D. Choi et al., "Superior long-term outcomes after surgery in child-pugh class a patients with single small hepatocellular carcinoma compared to radiofrequency ablation," *Hepatology International*, vol. 5, no. 2, pp. 722–729, 2011.

[82] J. Desiderio, S. Trastulli, R. Pasquale et al., "Could radiofrequency ablation replace liver resection for small hepatocellular carcinoma in patients with compensated cirrhosis? A 5-year follow-up," *Langenbeck's Archives of Surgery*, vol. 398, no. 1, pp. 55–62, 2013.

[83] Y.-H. Lee, C.-Y. Hsu, C.-W. Chu et al., "Radiofrequency ablation is better than surgical resection in patients with hepatocellular carcinoma within the Milan criteria and preserved liver function: A retrospective study using propensity score analyses," *Journal of Clinical Gastroenterology*, vol. 49, no. 3, pp. 242–249, 2015.

[84] Z.-W. Peng, X.-J. Lin, Y.-J. Zhang et al., "Radiofrequency ablation versus hepatic resection for the treatment of hepatocellular carcinomas 2 cm or smaller: A retrospective comparative study," *Radiology*, vol. 262, no. 3, pp. 1022–1033, 2012.

[85] A. Cucchetti, F. Piscaglia, M. Cescon et al., "Cost-effectiveness of hepatic resection versus percutaneous radiofrequency ablation for early hepatocellular carcinoma," *Journal of Hepatology*, vol. 59, no. 2, pp. 300–307, 2013.