International Journal of Biomaterials

Advanced Biomaterials and Technologies in Implantology

Guest Editors: Yasuhiro Tanimoto, Yo Shibata,
Jukka Pekka Matinlinna, Osamu Komiyama, and Masaru Yamaguchi

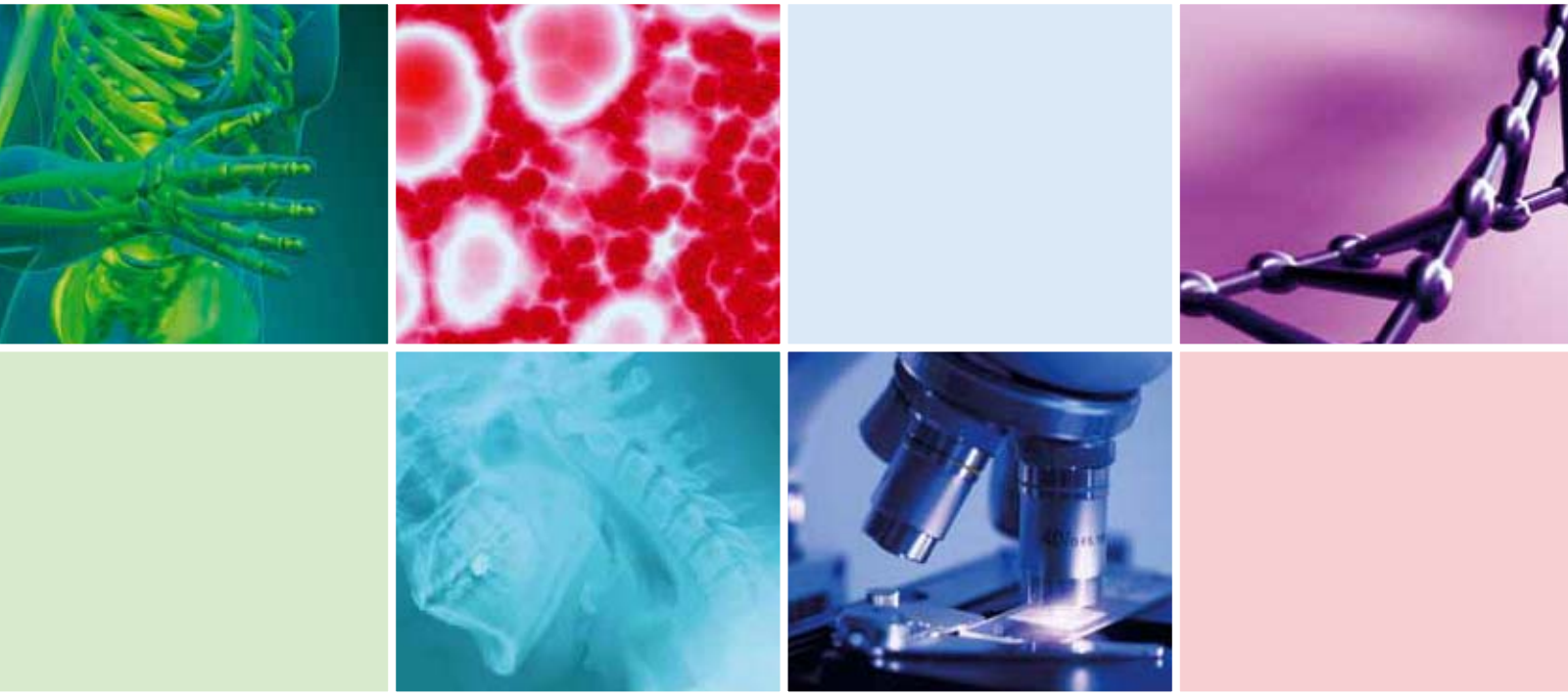

Advanced Biomaterials and Technologies in Implantology

International Journal of Biomaterials

Advanced Biomaterials and Technologies in Implantology

Guest Editors: Yasuhiro Tanimoto, Yo Shibata, Jukka Pekka Matinlinna, Osamu Komiyama, and Masaru Yamaguchi

Copyright © 2012 Hindawi Publishing Corporation. All rights reserved.

This is a special issue published in "International Journal of Biomaterials." All articles are open access articles distributed under the Creative Commons Attribution License, which permits unrestricted use, distribution, and reproduction in any medium, provided the original work is properly cited.

Editorial Board

Jake E. Barralet, Canada
Bikramjit Basu, India
Gordon W. Blunn, UK
Lawrence Bonassar, USA
Traian V. Chirila, Australia
Sanjukta Deb, UK
Mohan Edirisinghe, UK
Paul Hatton, UK
Esmaiel Jabbari, USA
J. Lawrence Katz, USA
Tadashi Kokubo, Japan
Rosalind Labow, Canada
Chwee Teck Lim, Singapore
Feng-Huei Lin, Taiwan
Claudio Migliaresi, Italy
Bruce Milthorpe, Australia
Ravin Narain, Canada
Abdelwahab Omri, Canada
Sean Peel, Canada
Mohamed Rahaman, USA
Sang-Hoon Rhee, Korea
Colin A. Scotchford, UK
Alexander Marcus Seifalian, UK
Hasan Uludağ, Canada
Thomas J. Webster, USA
Tai Horng Young, Taiwan

Contents

Advanced Biomaterials and Technologies in Implantology, Yasuhiro Tanimoto, Yo Shibata, Jukka Pekka Matinlinna, Osamu Komiyama, and Masaru Yamaguchi
Volume 2012, Article ID 524532, 2 pages

The Effect of Zirconia in Hydroxyapatite on *Staphylococcus epidermidis* Growth, Widowati Siswomihardjo, Siti Sunarintyas, and Alva Edy Tontowi
Volume 2012, Article ID 432372, 4 pages

Cytotoxicity of *Cricula triphenestrata* Cocoon Extract on Human Fibroblasts, Siti Sunarintyas, Widowati Siswomihardjo, and Alva Edy Tontowi
Volume 2012, Article ID 493075, 5 pages

Stress Analysis of a Class II MO-Restored Tooth Using a 3D CT-Based Finite Element Model, Yiu Pong Chan, Chak Yin Tang, and Bo Gao
Volume 2012, Article ID 657519, 9 pages

Soft and Hard Tissue Management in Implant Therapy—Part I: Surgical Concepts, Antonio D'Addona, Marjan Ghassemian, Luca Raffaelli, and Paolo Francesco Manicone
Volume 2012, Article ID 531202, 8 pages

Soft and Hard Tissue Management in Implant Therapy—Part II: Prosthetic Concepts, Paolo Francesco Manicone, Luca Raffaelli, Marjan Ghassemian, and Antonio D'Addona
Volume 2012, Article ID 356817, 6 pages

Assessment of the Quality of Newly Formed Bone around Titanium Alloy Implants by Using X-Ray Photoelectron Spectroscopy, Hiroshi Nakada, Toshiro Sakae, Yasuhiro Tanimoto, Mari Teranishi, Takao Kato, Takehiro Watanabe, Hiroyuki Saeki, Yasuhiko Kawai, and Racquel Z. LeGeros
Volume 2012, Article ID 615018, 7 pages

Mini-Implants in the Anchorage Armamentarium: New Paradigms in the Orthodontics, Masaru Yamaguchi, Toshihiro Inami, Ko Ito, Kazutaka Kasai, and Yasuhiro Tanimoto
Volume 2012, Article ID 394121, 8 pages

Clinical Management of Implant Prostheses in Patients with Bruxism, Osamu Komiyama, Frank Lobbezoo, Antoon De Laat, Takashi Iida, Tsuyoshi Kitagawa, Hiroshi Murakami, Takao Kato, and Misao Kawara
Volume 2012, Article ID 369063, 6 pages

MC3T3-E1 Cells on Titanium Surfaces with Nanometer Smoothness and Fibronectin Immobilization, Tohru Hayakawa, Eiji Yoshida, Yoshitaka Yoshimura, Motohiro Uo, and Masao Yoshinari
Volume 2012, Article ID 743465, 6 pages

Hindawi Publishing Corporation
International Journal of Biomaterials
Volume 2012, Article ID 302825, 2 pages
doi:10.1155/2012/302825

Editorial

Advanced Biomaterials and Technologies in Implantology

Yasuhiro Tanimoto,[1] Yo Shibata,[2] Jukka Pekka Matinlinna,[3] Osamu Komiyama,[4] and Masaru Yamaguchi[5]

[1] *Department of Dental Biomaterials, Nihon University School of Dentistry at Matsudo, 2-870-1 Sakaecho Nishi, Chiba, Matsudo 271-8587, Japan*
[2] *Department of Oral Biomaterials and Technology, Showa University School of Dentistry, Tokyo 142-8555, Japan*
[3] *Department of Dental Materials Science, Faculty of Dentistry, The University of Hong Kong, Sai Ying Pun, Hong Kong*
[4] *Department of Clinical Oral Physiology, Nihon University School of Dentistry at Matsudo, Chiba, Matsudo 271-8587, Japan*
[5] *Department of Orthodontics, Nihon University School of Dentistry at Matsudo, Chiba, Matsudo 271-8587, Japan*

Correspondence should be addressed to Yasuhiro Tanimoto, tanimoto.yasuhiro@nihon-u.ac.jp

Received 10 December 2012; Accepted 10 December 2012

Copyright © 2012 Yasuhiro Tanimoto et al. This is an open access article distributed under the Creative Commons Attribution License, which permits unrestricted use, distribution, and reproduction in any medium, provided the original work is properly cited.

The variety of implant devices has been available because modifications in design or materials will enable superior performance of the implant. Events leading to integration of an implant into bone, and hence determining the performance of a device, take place largely at the tissue and implant interface. These include not only implant-related factors, such as material shape, topography, and surface chemistry, but mechanical loading, surgical techniques, and host immunity as well. This special issue focuses on both materials science and clinical practice in the current implantology, to improve the quality and longevity of human life. For example, in implantology based on materials science, an understanding of the bone-implant interface is critical for the development of proactive titanium implants that can promote desired outcomes. Especially, the ideal nanomicroscale topography and chemistry should be defined for enhancing implant integration into native tissue. Meanwhile, in implantology based on clinical practice, an understanding of the dynamics and anatomical and biological concepts of the periodontium and peri-implant tissues both at the surgical and prosthetic phases of treatment which contributes to better soft and hard tissue management is important, for implant specialists.

With the above-described points based on both materials science and clinical practice as background, this special issue contains five research papers and four review papers to contribute better understanding and solution involved in the current implantology as follows.

In the paper entitled "*The effect of zirconia in hydroxyapatite on Staphylococcus epidermidis growth,*" W. Siswomihardjo et al. investigate the effect of zirconia concentrations in hydroxyapatite on the growth of *Staphlococcus epidermidis*. Recently, many researchers have reported with regard to both mechanical and biological properties of composites of hydroxyapatite and inert high-strength bioceramics such as zirconia and alumina. They report that local hydroxyapatite with 20% zirconia proved to be an effective concentration to inhibit the growth of *Staphlococcus epidermidis* colony.

In the paper entitled "*Cytotoxicity of Cricula triphenestrata cocoon extract on human fibroblasts,*" S. Sunarintyas et al. present the cytotoxicity of Indonesian silkworm cocoon extract of *Cricula triphenestrata* on human fibroblasts. They indicate that *Cricula triphenestrata* cocoon extract has the potential for the use of bone substitutes, because that is not cytotoxic on human gingival fibroblast cells.

In the paper entitled "*Stress analysis of a class II MO-restored tooth using a 3D CT-based finite element model,*" Y. P. Chan et al. propose a method to create a 3D finite element assembly model for a restored tooth and its corresponding mandible based on CT images. In this study, the tooth model is a triphasic one, consisting of enamel, dentin, and pulp phases, which gives rise to a more realistic simulation to estimate the stress distribution of the tooth and the restoration. The proposed method offers a computational scheme assisting dentists to design a more effective tooth repair strategy.

In the paper entitled "*Soft and hard tissue management in implant therapy—part I: surgical concepts,*" A. D'Addona et al. discuss the reason why surgical augmentation procedures are often required to enhance postextraction sites. Moreover, they discuss the use and selection of autogenous grafts,

nonautogenous graft material, and finally the timing of implant placement in relation to the extraction, which have been identified as the key concepts in the soft and hard tissue management (SHTM).

In the paper entitled "*Soft and hard tissue management in implant therapy—part II: prosthetic concepts,*" P. H. Manicone et al. describe the key concepts both the theoretical and clinical prosthetic components which the literature has emphasized as having an important role in SHTM in implant therapy, by discussing their direct effect on these structures, and hence, on the final result.

In the paper entitled "*Assessment of the quality of newly formed bone around titanium alloy implants by using X-ray photoelectron spectroscopy,*" H. Nakada et al. analyze the differences in bones quality between newly formed bone and cortical bone formed around titanium alloy implant by using X-ray photoelectron spectroscopy (XPS). XPS analysis is a useful technique for determining of information on elemental qualitative and quantitative bone composition. This paper presents that the peaks and quantities of each element of newly formed bone were similar to those of cortical bone at 8 weeks, suggestive of a strong physicochemical resemblance.

In the paper entitled "*Mini-implants in the anchorage armamentarium: new paradigms in the orthodontics,*" M. Yamaguchi et al. present the development, clinical use, benefits, and drawbacks of the miniscrew and plate type implants used to obtain a temporary but absolute skeletal anchorage for orthodontic applications. As a future of mini-implants, the application of calcium phosphate-based biomaterials as new types of mini-implants is proposed, because the improvement in designed screw including the diameter, length, and thread may reach the limit.

In the paper entitled "*Clinical management of implant prostheses in patients with bruxism,*" O. Komiyama et al. discuss the importance of the occlusal scheme used in implant restorations for implant longevity, and suggest a clinical approach and occlusal materials for implant prostheses in order to prevent complications related to bruxism. As is well known, dental implant must withstand varying degrees of force during mastication and for some patients from bruxism or clenching. The authors therefore explain that the clinical management of bruxism will become an important subject for implant prostheses.

In the paper entitled "*MC3T3-E1 cells on titanium surfaces with nanometer smoothness and fibronectin immobilization,*" T. Hayakawa et al. investigate the effects of mechanical treatment (nanometer smoothing and sandblasting) and biochemical treatment (with and without fibronectin immobilization) of a titanium surface on cell viability and total protein contents of MC3T3-E1 on the titanium surface. Fibronectin can be easily immobilized on both nanometer smooth and sandblasted titanium surfaces by their originally developed method, namely, the tresyl chloride-activation technique. They report that the combination of sandblasting and fibronectin immobilization enhanced the cell viability and fibronectin immobilization providing better arrangements of attached cells.

Finally, it is hoped that the contents of this special issue might provide valuable insights, to the researcher and the clinician, into the important topic of implantology.

Yasuhiro Tanimoto
Yo Shibata
Jukka Pekka Matinlinna
Osamu Komiyama
Masaru Yamaguchi

Hindawi Publishing Corporation
International Journal of Biomaterials
Volume 2012, Article ID 432372, 4 pages
doi:10.1155/2012/432372

Research Article

The Effect of Zirconia in Hydroxyapatite on *Staphylococcus epidermidis* Growth

Widowati Siswomihardjo,[1,2] Siti Sunarintyas,[1,2] and Alva Edy Tontowi[2,3]

[1] *Department of Biomaterials, Faculty of Dentistry, Gadjah Mada University, Yogyakarta 55281, Indonesia*
[2] *Department of Biomedical Engineering, School of Graduate Studies, Gadjah Mada University, Yogyakarta 55281, Indonesia*
[3] *Department of Mechanical and Industrial Engineering, Faculty of Engineering, Gadjah Mada University, Yogyakarta 55281, Indonesia*

Correspondence should be addressed to Widowati Siswomihardjo, bundi.kunto@gmail.com

Received 15 March 2012; Revised 28 May 2012; Accepted 13 June 2012

Academic Editor: Jukka Pekka Matinlinna

Copyright © 2012 Widowati Siswomihardjo et al. This is an open access article distributed under the Creative Commons Attribution License, which permits unrestricted use, distribution, and reproduction in any medium, provided the original work is properly cited.

Synthetic hydroxyapatite (HA) has been widely used and developed as the material for bone substitute in medical applications. The addition of zirconia is needed to improve the strength of hydroxyapatite as the bone substitute. One of the drawbacks in the use of biomedical materials is the occurrence of biomaterial-centred infections. The recent method of limiting the presence of microorganism on biomaterials is by providing biomaterial-bound metal-containing compositions. In this case, *S. epidermidis* is the most common infectious organism in biomedical-centred infection. *Objective*. This study was designed to evaluate the effect of zirconia concentrations in hydroxyapatite on the growth of *S. epidermidis*. *Methods and Materials*. The subjects of this study were twenty hydroxyapatite discs, divided into four groups in which one was the control and the other three were the treatment groups. Zirconia powder with the concentrations of 20%, 30%, and 40% was added into the three different treatment groups. Scanning electron microscope analysis was performed according to the hydroxyapatite and hydroxyapatite-zirconia specimens. All discs were immersed into *S. epidermidis* culture for 24 hours and later on they were soaked into a medium of PBS. The cultured medium was spread on mannitol salt agar. After incubation for 24 hours at 37°C , the number of colonies was measured with colony counter. Data obtained were analyzed using the ANOVA followed by the pairwise comparison. *Result*. The statistical analysis showed that different concentrations of zirconia powder significantly influenced the number of *S. epidermidis* colony ($P < 0.05$) . *Conclusion*. The addition of zirconia into hydroxyapatite affected the growth of *S. epidermidis*. Hydroxyapatite with 20% zirconia proved to be an effective concentration to inhibit the growth of *S. epidermidis* colony.

1. Introduction

Angiogenesis, osteogenesis, and chronic wound healing are natural repairing mechanisms that occur in human body. However, there are some critical defects of size in which these tissues cannot regenerate themselves and need clinical repair [1]. Therefore, the treatment for posttraumatic skeletal conditions such as bone loss is becoming a challenging field to be studied [2]. In most cases, restoration of alignment and stable fixation of the bone is necessary to achieve a successful reconstruction. Bone grafts have an important role in orthopaedic surgery, as well as in the replacement of bone after a trauma or tumour removal [3]. In many cases, adjunctive measures such as bone grafting or bone transports are required to stimulate bone healing and fill the bone defects [2]. Autologous cancellous bone is the most effective biological graft material [4]. It is the most preferable procedure for bone augmentation because of osteoinductive effect and high biocompatibility. However, limitation of available amount and postoperative discomforts including inflammation at donor site are the disadvantages [5]. Skeletal bones comprise mainly of collagen and hydroxyapatite, both are osteoconductive components [1]. Nowadays hydroxyapatite, $[Ca_{10}(PO_4)_6(OH)_2]$, as a very important bioceramic is used extensively in medical applications to repair or replace the bone tissues [6, 7]. Dentistry and orthopaedic applications deal a lot with this material because of its good biocompatibility, osteoconductivity, and the bone-bonding

properties [8]. Pure hydroxyapatite has chemical composition, biological and crystallographic properties which are highly similar to the bone and the teeth [9].

Hydroxyapatite (HA) powder can be synthesized from various minerals, including coral, gypsum ($CaSO_4 \cdot 2H_2O$), and calcite [1]. Some methods have been developed in preparing HA powders, the wet methods and solid state reactions. The wet methods can be divided into hydrolysis and hydrothermal techniques. The hydrothermal technique provides HA powder with high degree of crystallinity with Ca-P ratio which is close to the stoichiometric value [10]. It is proved that HA powder can be synthesized from local gypsum using microwave-hydrothermal method [11].

Bulk hydroxyapatite exhibits poor mechanical properties, therefore, for full utilization that must withstand high loads, the improvement of mechanical properties is needed [6]. The primary purpose of adding filler particles is to strengthen a composite [12]. Zirconia is one of the important filler among many fillers or reinforcements, which has been used to increase the strength and toughness of many ceramic materials [7]. In bone surgery zirconia has shown very wide applications [13].

One of the major drawbacks in the use of biomaterials is the occurrence of biomaterial-centred infections [14]. After implantation, the host will interact with biomaterial by forming a conditioning film on its surface. Adherence of microorganisms is mediated by the properties of the biomaterial surface itself. Subsequent surface growth of microorganism will initiate the occurrence of infection. An *in vitro* study proved that the number of microorganism *S. epidermidis* increased in the first 8 to 12 hours after the implantation [14]. Efforts have been done in preventing the contamination of microorganism on the foreign materials during implantation. No doubt that the use of antibiotics might reduce the occurrence of biomaterials-centred infection, but still a significant number of patients are suffering from this condition. The aim of this research was to examine the effect of zirconia on the growth of *S. epidermidis*.

2. Materials and Methods

2.1. Synthesis of Local Hydroxyapatite and Discs Preparation. The synthesis of hydroxyapatite was conducted and modified [15] to produce powder of hydroxyapatite from local gypsum (Kulon Progo Yogyakarta, Indonesia). The gypsum powder was obtained by pulverizing the gypsum rock. Gypsum powder (20 gr) and 800 mL of 1 M diammonium hydrogen phosphate [$(NH_4)2HPO_4$] were well mixed and treated at 100°C for 20 minutes in a pyrex glass using a microwave digestion system. The system was operated at frequency of 2.45 GHz. After the hydrothermal reaction, reacted sample was washed with distilled water to remove residual ion and dried. The conversion of gypsum to L-HA was estimated from the ratio of X-ray intensities of gypsum peak (d = 7.261) and the HA peak (d = 2.787) using powder X-ray diffractometry.

Powder of hydroxyapatite (0.4 gr) was put in a mould of compaction instrument [11]. Powder of hydroxyapatite was mixed homogenously with zirconia. In this study the different concentrations of zirconia used were 10%, 20%, 30%, and 40% (weight/weight). Powder of hydroxyapatite-zirconia is put in a mould and pressed with 120 Mpa to produce a disc with a diameter of 10 mm and 3 mm in thickness. Finally, discs were sintered for 2 hours at 1450°C. The sterilization of the hydroxyapatite-zirconia discs was done by keeping the discs in the autoclave for 15 minutes at 121°C. Twenty discs were prepared and divided into five discs for each group of concentration.

2.2. Scanning Electron Microscope Examination. The disc specimens were mounted with silver paste on metallic stub. The specimens were then gold coated with a sputtering system under vacuum desiccation. Examination was performed under scanning electron microscope at an acceleration voltage of 7 to 10 KV.

2.3. S. epidermidis Culturing and Colonies Counting. The *S. epidermidis* (clinical strain) was cultured in mannitol salt agar (MSA) and incubated for 24 hours at 37°C. The cultured bacteria was then transferred into 2 mL of brain heart infusion (BHI) and incubated for 24 hours at 37°C. Solution of NaCl was added into the BHI. Five discs of hydroxyapatite-zirconia from each group of concentration were put into 3 mL culture of *S. epidermidis* in BHI (Brown standard III of 10^8 CFU/mL). Incubation was followed for 24 hours at 37°C. After incubation, all discs were transferred into 1 mL phosphate buffer saline (PBS) and put on a vibrator to remove the attached *S. epidermidis*. Without taking measurement, all discs were then taken out from the PBS solution, and the solution was diluted up to 10^{-4}. Next step, 0.1 mL medium of BHI was transferred into the MSA at the petri dish, using a spreader. The petri dish was incubated for 24 hours at 37°C. The number of colonies was counted using colony counter.

3. Discussion

The average and standard deviations of the *S. epidermidis* number of colony on MSA when reacted with hydroxyapatite mixed with zirconia at concentrations of 20%, 30%, and 40% are presented at Table 1.

On Table 1 it is noted that the colony number of *S. epidermidis* is consistently influenced by zirconia concentrations in the hydroxyapatite. It is shown that the number of colonies of *S. epidermidis* was smaller as the concentration of zirconia in the hydroxyapatite was increased. In the group of hydroxyapatite without zirconia, it shows the most number of colonies, whereas the concentration of 40% shows the smallest number of colonies. Statistical analysis of this data is carried out using the one-way analysis of variance. This analysis proved whether the different concentrations of zirconia have significant influence on the growth of *S. epidermidis*, and it is indicated by the numbers of the colonies of *S. epidermidis*. The probability from the ANOVA is 0.001, and this value is less then 0.05 confidence levels. From this result it was proved that hydroxyapatite with different concentrations of zirconia had a significant influence on the number of colonies of *S. epidermidis*.

Table 1: Measurement of the number of colony of *S. epidermidis* after being reacted with hydroxyapatite mixed with different concentrations of zirconia.

Replications	Concentrations of zirconia			
	0%	20%	30%	40%
1	30	15	7	3
2	57	16	8	0
3	64	14	10	0
4	32	16	7	0
5	25	12	12	0
x	**41.6**	**14.6**	**8.8**	**0.6**
$x \pm$ sd	**41.6 ± 17.61**	**14.6 ± 1.67**	**8.8 ± 2.16**	**0.6 ± 1.34**

Table 2: Statistical result of the pairwise comparisons from hydroxyapatite with different concentrations of zirconia on the number of colonies of *S. epidermidis*.

(*I*) VAR0000	(*J*) VAR0000	Mean difference (*I*-*J*)	Std. error	Sig.	95% Confidence interval	
1	1				Lower bound	Upper bound
1.0	2.00	27.00000*	5.65332	.000	15.0155	38.9845
	3.00	32.80000*	5.65332	.000	20.8155	44.7845
	4.00	41.00000*	5.65332	.000	29.0155	2.9845
2.0	1.00	−27.00000*	5.65332	.000	−38.9845	−15.0155
	3.00	5.80000	5.65332	.320	−6.1845	17.7845
	4.00	14.00000*	5.65332	.025	2.0155	25.9845
3.0	1.00	−32.80000*	5.65332	.000	−44.7845	−20.8155
	2.00	−5.8000	5.65332	.320	−17.7845	6.1845
	4.00	8.20000	5.65332	.166	−3.7845	20.1845
4.0	1.00	−41.00000*	5.65332	.000	−52.9845	−29.0155
	2.00	−14.00000*	5.65332	.025	−25.9845	−2.0155
	3.00	−8.20000	5.65332	.166	−20.1845	3.7845

*The mean difference is significant at the 0.05 level.

The result of this study coincided with the research which stated that the factors influencing bacteria adherence to a biomaterial surface include the surface roughness or physical configuration of the material [16]. The microstructure of hydroxyapatite and hydroxyapatite-zirconia had been tested using scanning electron microscope, and the result proves that hydroxyapatite zirconia has smoother surface roughness than hydroxyapatite [13]. Furthermore, it is stated that the particles of zirconia fill in the pores among the particles of hydroxyapatite [17]. This statement coincides with the scanning electron microscope examination as presented in Figures 1 and 2.

It can be understood that hydroxyapatite-zirconia has less pores compared to hydroxyapatite without zirconia. Material with least pores among particles gives smoother surface of the material. The result of the ANOVA proved that there was significant relation between the zirconia concentrations and the colonies growth of *S. epidermidis* ($P < 0.05$). The number of colonies in hydroxyapatite-zirconia was influenced by the addition of zirconia. This situation related to the statement which mentioned that the present invention provides a method of limiting the presence of a microorganism by contacting the microorganism with material-bound metal-containing compositions [18]. One of the commonly used filler which contain heavy metal is zirconia [12]. The small number of colonies of *S. epidermidis* in hydroxyapatite-zirconia might be assumed due to the toxicity of zirconia as metal. ANOVA analysis was followed by the pairwise comparisons.

The data in Table 2 show significant differences in almost all pair of groups, except the differences between (20–30)% and (30–40)%. Based on this result it can be drawn that zirconia with the concentration of 20% proved to have been an effective concentration in inhibiting the growth of *S. epidermidis*. Moreover, as 20% becomes the effective concentration, a detailed research is still needed. It is important to find out the most effective concentration of zirconia to be added into hydroxyapatite.



Figure 1: Microstructure of hydroxyapatite.



Figure 2: Microstructure of hydroxyapatite with zirconia fill in the pores.

4. Conclusions

From this study, it can be concluded that concentration of zirconia influenced the number of colonies of *S. epidermidis*. Local hydroxyapatite with 20% zirconia proved to have been an effective concentration in inhibiting the growth of *S. epidermidis*. Scanning electron microscopy examination showed that zirconia filled in the hydroyapatite pores, whereas the less pores the less number of *S. epidermidis* attached.

Acknowledgment

This paper has been presented at the 88th IADR General Session and Exhibition, held at Barcelona, Spain, on July 14–17, 2010.

References

[1] D. A. Wahl and J. T. Czernuszka, "Collagen-hydroxyapatite composites for hard tissue repair," *European Cells and Materials*, vol. 11, pp. 43–56, 2006.

[2] C. G. Finkemeier, "Bone-grafting and bone-graft substitutes," *Journal of Bone and Joint Surgery A*, vol. 84, no. 3, pp. 454–464, 2002.

[3] Y. H. Hsu, I. G. Turner, and A. W. Miles, "Fabrication of porous bioceramics with porosity gradients similar to the bimodal structure of cortical and cancellous bone," *Journal of Materials Science*, vol. 18, no. 12, pp. 2251–2256, 2007.

[4] S. Bansal, V. Chauhan, S. Sharma, R. Maheshwari, A. Juyal, and S. Raghuvanshi, "Evaluation of hydroxyapatite and beta-tricalcium phosphate mixed with bone marrow aspirate as a bone graft substitute for posterolateral spinal fusion," *Indian Journal of Orthopaedics*, vol. 43, no. 3, pp. 234–239, 2009.

[5] K. Tint, H. Kondo, S. Kuroda et al., "Effectiveness of extracted teeth as bone substitute, application to parietal bone defects in rabbit," *Journal of Oral Tissue Engineering*, vol. 3, no. 1, pp. 7–16, 2005.

[6] Q. Wang, S. Ge, and D. Zhang, "Highly bioactive nano-hydroxyapatite partially stabilized zirconia ceramics," *Journal of Bionics Engineering*, vol. 1, no. 4, pp. 215–220, 2004.

[7] Y. Nayak, R. P. Rana, S. K. Pratihar, and S. Bhattacharyya, "Pressureless sintering of dense hydroxyapatite-zirconia composites," *Journal of Materials Science*, vol. 19, no. 6, pp. 2437–2444, 2008.

[8] C. G. Simon, J. M. Antonucci, D. W. Liu, and D. Skrtic, "In vitro cytotoxicity of amorphous calcium phosphate composites," *Journal of Bioactive and Compatible Polymers*, vol. 20, no. 3, pp. 279–295, 2005.

[9] M. K. Herliansyah, M. Hamdi, A. I. Ektessabi, and M. W. Wildan MW, "Fabrication of hydroxyapatite bone graft for implant applicationa literature study," in *Proceedings of the First International Conference on Manufacturing and Material Processing*, pp. 559–564, Kuala Lumpur, Malaysia, 2006.

[10] W. Suchanek and M. Yoshimura, "Processing and properties of hydroxyapatite-based biomaterials for use as hard tissue replacement implants," *Journal of Materials Research*, vol. 13, no. 1, pp. 94–117, 1998.

[11] E. E. Pujiyanto, A. E. Tontowi, M. W. Wildan, and W. Siswomihardjo, "Sintesis hidro-Hidroksiapatit dari gipsum Tasikmalaya sebagai bahan baku produk tulang buatan," in *Seminar on Aplication and Research in Industrial Technology*, pp. 119–126, Jur Teknik Mesin dan Industri UGM, Yogyakarta, Indonesia, 2006.

[12] K. J. Anusavice, *Phillip's Science of Dental Materials*, Elsevier, 11th edition, 2009.

[13] R. Quan, D. Yang, X. Wu, H. Wang, X. Miao, and W. Li, "In vitro and in vivo biocompatibility of graded hydroxyapatite-zirconia composite bioceramic," *Journal of Materials Science*, vol. 19, no. 1, pp. 183–187, 2008.

[14] B. Gottonboss, *The development of antimicrobial biomaterial surface [thesis]*, Rijks University of Groningen, 2001.

[15] H. Katsuki, S. Furuta, and S. Komarneni, "Microwave versus conventional-hydrothermal synthesis of hydroxyapatite crystals from gypsum," *Journal of the American Ceramic Society*, vol. 82, no. 8, pp. 2257–2259, 1999.

[16] M. Katsikogianni and Y. F. Missirlis, "Concise review of mechanisms of bacterial adhesion to biomaterials and of techniques used in estimating bacteria-material interactions," *European Cells and Materials*, vol. 8, pp. 37–57, 2004.

[17] E. S. Ahn, N. J. Gleason, and J. Y. Ying, "The effect of zirconia reinforcing agents on the microstructure and mechanical properties of hydroxyapatite-based nanocomposites," *Journal of the American Ceramic Society*, vol. 88, no. 12, pp. 3374–3379, 2005.

[18] K. D. Landgrebe, D. J. Hastings, T. P. Smith, G. D. Cuny, A. Sengupta, and C. D. Brandys, Limiting the presence of microorganisms using polymer-bound metal-containing compositions, 2010, http://www.freepatentsonline.com/6432396.html.

Hindawi Publishing Corporation
International Journal of Biomaterials
Volume 2012, Article ID 493075, 5 pages
doi:10.1155/2012/493075

Research Article

Cytotoxicity of *Cricula triphenestrata* Cocoon Extract on Human Fibroblasts

Siti Sunarintyas,[1,2] Widowati Siswomihardjo,[1,2] and Alva Edy Tontowi[2,3]

[1] *Department of Dental Biomaterial, Faculty of Dentistry, Gadjah Mada University, Yogyakarta 55281, Indonesia*
[2] *Department of Biomedical Engineering, School of Graduate Studies, Gadjah Mada University, Yogyakarta 55281, Indonesia*
[3] *Department of Mechanical and Industrial Engineering, Faculty of Engineering, Gadjah Mada University, Yogyakarta 55281, Indonesia*

Correspondence should be addressed to Siti Sunarintyas, sunarintyassiti@yahoo.com

Received 15 March 2012; Accepted 29 June 2012

Academic Editor: Masaru Yamaguchi

Copyright © 2012 Siti Sunarintyas et al. This is an open access article distributed under the Creative Commons Attribution License, which permits unrestricted use, distribution, and reproduction in any medium, provided the original work is properly cited.

Objectives. The aim of this paper was to evaluate the cytotoxicity of Indonesian silkworm cocoon extract of *Cricula triphenestrata* on human fibroblasts. *Methods and Materials*. The cocoon shells of the silkworm *Cricula triphenestrata* were degumming. The shells were mixed with an aqueous solution of 0.3% Na_2CO_3 at 98°C for 1 hour. The solution was then dialyzed in cellulose membranes against deionized water for 3 days. The cocoon shells extract powder was collected via rotary evaporation and dried under freeze dryer. Cell culture medium was exposed to *Cricula triphenestrata* cocoon extract (0.01–100 μg/mL) for 24 hours. The primary human gingival fibroblasts were exposed to the treated cell culture medium for 24 hours. Cytotoxicity evaluation was done by MTT method. The data were analyzed by one-way ANOVA. *Result*. The result revealed no significant cytotoxicity of *Cricula triphenestrata* cocoon extract against human fibroblasts at a concentration up to 100 μg/mL ($P > 0.05$). *Conclusion*. *Cricula triphenestrata* cocoon extract was not cytotoxic on human gingival fibroblast cells.

1. Introduction

Many acute and chronic injuries require bone graft substitutes. Current options for bone graft substitutes include autograft, allograft, and synthetic materials. Each of the options has limitations, such as the need for second site of surgery, limited supply, inadequate size and shape, and the morbidity associated with donor site [1]; thus, there remains a need for the new option.

Synthetic hydroxyapatite is widely used as a bone substitute material because it can bond directly to the living bone and has excellent biocompatibility and bioactivity. However, hydroxyapatite does not have enough mechanical properties to act as substitute in loading-bearing parts of the human skeleton. Hydroxyapatite shows a higher Young's modulus and lower toughness than cortical bone [2]. It has been desired to develop a material that has mechanical properties analogous to those of natural bone. It is known that human bone has a three-dimensional woven apatite-polymer structure made of inorganic apatite crystals and organic collagen fibers [3]. Bone consists of an organic-inorganic hybrid with a characteristic structure that leads to specific mechanical properties such as high fracture toughness and flexibility. It is a good strategy to mimic bone structure in the design of bone-repairing materials. From this point of view, the fabrication of hybrid materials consisting of apatite and natural organic polymer can be expected to be a good strategy to obtain bone repairing materials that have both a bone bonding ability and mechanical properties similar to those of natural bone.

Previous study [4] reported that apatite-coated silk scaffolds can combine the osteoconductive properties of bioceramics with the mechanical resilience of polymer. Silk scaffolds combined with apatite promoted cellular attachment and bone formation *in vitro*, providing an appropriate osteogenic environment for tissue engineering.

In vivo research on mongrel dogs by Zhao et al. [5] showed that apatite-silk scaffolds could be successfully used to repair mandibular critical size border defects. The premineralization of the porous silk protein scaffold provided an increase osteoconductive environment for the cells to regenerate sufficient new bone tissue.

Silks are fibrous proteins with remarkable mechanical properties produced in fiber formed by silkworms and spiders [6]. Previous studies reported silks contained two natural macromolecular proteins namely, sericin and fibroin. Sericin comprised granular and high-molecular, water soluble glycoproteins and it acted as a protein glue to fix fibroin fibers together in the cocoon [7]. In silk textile processing, sericin is usually removed, resulting in fine silk fibers. The resulted fibroin fibers can be used to make fabrics.

Sericin is useful because of its properties. The protein which resists oxidation is antibacterial, UV-resistant, and absorbs and releases moisture easily. Sericin can be cross-linked, copolymerized, and blended with other macromolecular materials, especially artificial polymers, to produce materials with the improved properties. The protein is also used as an improving reagent or a coating material for natural and artificial fibers, fabrics, and articles. Sericin composites are useful as degradable biomaterials, biomedical materials, polymers for forming articles, functional membranes, fibers, fabrics, and articles [8, 9]. Sericin has a potential to facilitate apatite deposition and can be useful as polymer material in the fabrication of hybrid materials analogous to bone through biomimetic processes [10].

Research regarding the potentials of Indonesian silk is still limited. Indonesia is well known for its silk textile derived from wild silkworm cocoon of *Cricula triphenestrata*. *Cricula triphenestrata* is one of the world wild species of silkworms which only habitats in Java island. *Cricula triphenestrata* produces golden silk floss which is very luxurious and amazing [9]. The use of discarded sericin of *Cricula triphenestrata* cocoon extract from the water waste of silk textile industry as biomaterials will be beneficial for the local silk textile industry and also the development of natural biomaterials as bone substitute.

Biomaterials may have low, medium, or high potential risk to human safety depending on the type and the extent of patient contact. One of the International Standards [11] recommends the appropriate steps for the biological assessment of medical devices *in vitro* assessment of cytotoxicity of new biomaterials. In this primary screening, we aimed to evaluate the cytotoxicity of *Cricula triphenestrata* cocoon extract on human gingival fibroblasts.

2. Materials and Method

2.1. Materials. The cocoon shells of the silkworm *Cricula triphenestrata* (Figure 1) were obtained from PT Yarsilk Gora Mahottama Textile Industri at Yogyakarta, Indonesia. The cocoon shells were taken from Karang Tengah Forest at Kabupaten Bantul, Yogyakarta, Indonesia. The medium of RPMI 1640, Dulbecco's Modified Eagle's Minimum Essential medium (DMEM), penicillin, streptomycin, amphotericin, and trypsin were obtained from Gibco (Carlsbad, CA, USA).

Figure 1: The cocoon shells of the silkworm *Cricula triphenestrata*.

All other chemicals were analytical or pharmaceutical grade and obtained from Sigma-Aldrich Chemicals (Bornem, Belgium).

2.2. Preparation of Cricula triphenestrata Cocoon Extract. The cocoon shells of the silkworm *Cricula triphenestrata*, were mixed with an aqueous solution of 0.3% Na_2CO_3 (w/v) at 98°C for 1 hour. The solution was then dialyzed in cellulose membranes (MW = 3500 g/mol) against deionized water for 3 days by changing the water daily to remove the ions and other impurities. The cocoon extract powder was collected via rotary evaporation and drying under freeze dryer [12].

2.3. Cell Culture. Human gingival fibroblasts were obtained from biopsies of the attached gingival of sound permanent molar teeth of healthy persons. Informed consent based on an appropriate protocol was obtained from the donors. The biopsies were stored at 4°C for at most 24 hours in collection medium (RPMI 1640 supplemented with penicillin 100 U/mL, streptomycin 100 mg/mL, and amphotericin 2.5 mg/mL) prior to amplification.

The gingival tissues were cut into 1 to 2 mm^3 pieces then washed three times by RPMI 1640. After that, the cut biopsies were placed into 25 cm^2 tissue culture flasks. The explants were incubated with culture medium consisting of DMEM 90%, 10 mM HEPES, glucose (4.5 g/L), $NaHCO_3$ (3.7 g/L), penicillin (100 U/mL), streptomycin (100 mg/mL), and amphotericin (2.5 mg/mL), supplemented with 10% heat-inactivated fetal calf serum (FCS). The tissue samples were grown at 37°C in a humidified atmosphere of 10% carbon dioxide in the air. When outgrowth of cells was observed, the medium was replaced twice weekly until cells reached confluence. Cells were detached from the monolayer by a brief treatment with trypsin-EDTA (0.25% trypsin, 0.02% EDTA) and recultured in 75 cm^2 tissue flasks until confluent monolayer was reobtained [13].

2.4. MTT Cytotoxicity Test. The MTT cytotoxicity test is based on ISO 10993-5 [14] of Biological Evaluation of Medical Devices, Part 5: Tests for *In Vitro* Cytotoxicity. Cells (1×10^5 cells/mL) in DMEM of 50 μL were seeded into 96-well plates and maintained in culture for 24 hours to form a semiconfluent monolayer. They were then exposed

Table 1: Percentage of cytoviability of human gingival fibroblasts treated by *Cricula triphenestrata* cocoon extract.

Concentration (μg/mL)	% Cytoviability ± SD
100.000	64.486 ± 0.794
50.000	65.995 ± 0.365
25.000	65.998 ± 0.564
12.500	66.298 ± 0.237
6.250	66.698 ± 0.684
3.125	67.947 ± 0.329
1.563	69.433 ± 0.414
0.781	70.259 ± 0.248
0.010	71.184 ± 0.309

to the *Cricula triphenestrata* cocoon extracts (50 μL) over a range of 0.01–100 μg/mL concentration. After 24-hour exposure, the formazan formations were determined for each treatment concentration by ELISA reader at a wavelength of 570 nm. The relative viability of the treated cells as compared to the control cells were expressed as the % cytoviability, using the following formula:

$$\%\text{Cytoviability} = \frac{100\% \times \text{OD}_{570\ \text{treated}}}{\text{OD}_{570\ \text{control}}}, \quad (1)$$

where $\text{OD}_{570\ \text{treated}}$ is mean value of the measured optical density of the treated cells; $\text{OD}_{570\ \text{control}}$ is mean value of the measured optical density of the control cells.

The data were presented as means ± standard deviation (SD). Statistical analysis was performed using analysis of variance (ANOVA) to determine the effect of cocoon extract concentration on the fibroblast cells cytoviability.

2.5. IC_{50} Determination. This study used IC_{50} determination by the standard curve method. A standard curve was performed based on the extract concentrations numbers versus the cytoviability percentage value. The extract concentrations used were 100, 50, 25, 12.5, 6.25, 3.125, 1.563, 0.781, and 0.010 μg/mL. Each concentration was performed in four replicates. The determined cytoviability value was plotted in the standard curve. This research used the cytoviability values that only fall in the linear range of the standard curve to reduce error. A linear regression analysis was performed regarding to the corresponding concentration numbers and cytoviability values. The regression formula was $Y = aX + b$. The IC_{50} value was estimated using the fitted line of the linear regression as $IC_{50} = (0.5 - b)/a$.

3. Results

The result of relative viability of the fibroblast treated cells as compared to the control cells was expressed in Table 1.

Table 1 showed that increased concentration of the *Cricula triphenestrata* cocoon extract exposure on the cells resulted in the decreasing of cytoviability percentage of human gingival fibroblast cells. Further statistical analysis by ANOVA was shown in Table 2, which described that there was not any significant influence of the treated extracts concentration on the cytoviability of human gingival fibroblast ($P > 0.05$).

Table 2: ANOVA summary of the effect of cocoon extracts concentration on fibroblast cells.

	Sum of square	df	Mean square	F	Sig.
Between groups	1174.952	8	146.869	647.248	0.061
Within groups	4.084	18	0.227		
Total	1179.037	26			

The IC_{50} value of *Cricula triphenestrata* cocoon extract for a battery of fibroblast cells was obtained by regression analysis of the corresponding dose-response curve. The regression formula for the dose-response curve was $Y = 67.630 - 0.390X$. By the formula, determination of IC_{50} was 172 μg/mL.

4. Discussion

In the field of biomaterials, it is necessary to consider aspects of security, such as elimination of cytotoxicity and other harmful effects of the material to be used [15]. By definition, the cytotoxicity of an agent means the toxicological risks caused by a material or its extract in a cell culture [16]. The interactions of the materials and their components with the cells at a molecular level are responsible for tissue reactions, such as inflammation, necrosis [17], immunological alterations, genotoxicity [18], and apoptosis [19].

During the last years, the interest of *in vitro* systems as an alternative to animal experiments in toxicological research has been steadily increasing. Cytotoxicity testing includes numerous methods, both qualitative and quantitative. In this study we used indirect test, in which the rate of cell growth (cell number) and the metabolic activity (MTT) have indicated the degree of cytotoxicity of *Cricula triphenestrata* cocoon extract.

Table 1 shows the effect of *Cricula triphenestrata* cocoon extract on human gingival fibroblast cells viability measured by MTT test. MTT is a yellow water-soluble tetrazolium dye which is reduced by live cells to a purple formazan product insoluble in aqueous solutions. The amount of formazan generated is directly proportional to the number of viable cells [12]. As can be seen from Table 1, the cocoon extract exposure of 0.01–100 μg/mL during 24 hour of incubation induces the cytoviability of the fibroblast to be 71.184–64.486% in comparison to the control. The highest inhibition effect is induced by 100 μg/mL extract concentration and the weakest is on 0.01 μg/mL one. Although further statistical analysis shows no significant difference among the concentrations, but it is proved that there is an increasing cytoviability on the decreasing of the extract concentration exposure. It means that more concentration exposure tends to lower the fibroblast cytoviability.

The half maximal inhibitory concentration (IC_{50}) is a measure of the effectiveness of a compound in inhibiting biological or biochemical function. This quantitative measure indicates how much a particular substance is needed to inhibit a given biological process by half. In other words,

it is the half maximal (50%) inhibitory concentration (IC) of a substance (50% IC, or IC_{50}) [20]. The score of IC_{50} represents the concentration of a drug that is required for 50% inhibition *in vitro* [21]. In this study, the determination of IC_{50} by the formula of $Y = 67.630 - 0.390X$ is 172 μg/mL. It means that the highest treated concentration of 100 μg/mL cocoon extract reveals no significant cytotoxicity against human fibroblasts (less than 172 μg/mL).

Previous study reported that the IC_{50} of *Bombyx mori* silkworm cocoon extract on Vero cells was 230 μg/mL [22]. Comparing to the IC_{50} of *Cricula triphenestrata* cocoon extract in this study, the *Cricula triphenestrata* cocoon extract is lower than the *Bombyx mori*. It means that the *Cricula triphenestrata* cocoon extract is more cytotoxic than the *Bombyx mori*. Previous study reported that there was a correlation between environmental condition and the protein production of cocoon [23]. *Cricula triphenestrata* is a wild silkworm found only in Java island forest in Indonesia. It can be found in guava leaf, cashew leaf, and hardwood leaf. *Bombyx mori* silkworms are usually growth by the farmers to produce silk fabrics. They were usually fed with only mulberry leaves. The difference between the environmental condition and food consumption may influence the cocoon characteristic including the cytotoxicity.

In the present study, the cytotoxicity of *Cricula triphenestrata* cocoon extract which is aimed to be used as bone substitute is analyzed using a cell culture model of primary human gingival fibroblasts. Like other tissues, normal fibroblast function is critical to maintain the periodontal tissue function for optimal healing. Gingival fibroblasts are chosen due to their availability and culturing characteristics [13].

5. Conclusion

Biomaterials may have potential risk to human safety. Accurate biological assessment of the proposed medical biomaterial is needed. Based on the research of the cytotoxicity of Indonesian silkworm cocoon extract of *Cricula triphenestrata* on human fibroblasts, it was concluded that *Cricula triphenestrata* cocoon extract up to 100 μg/mL was not cytotoxic on human gingival fibroblast cells. By this finding, further researches are proposed to develop the *Cricula triphenestrata* cocoon extract as an alternative biomaterial for bone substitute.

References

[1] R. Z. LeGeros, "Properties of osteoconductive biomaterials: calcium phosphates," *Clinical Orthopaedics and Related Research*, no. 395, pp. 81–98, 2002.

[2] L. L. Hench and J. Wilson, "Introduction," in *Introduction to Bioceramics*, pp. 1–24, World Scientific, Singapore, 1993.

[3] J. B. Park and R. S. Lakes, "Structure property relationship of biological materials," in *Biomaterials: An Introduction*, pp. 185–222, Plenum Press, New York, NY ,USA, 2nd edition, 1992.

[4] H. J. Kim, U. J. Kim, H. S. Kim et al., "Bone tissue engineering with premineralized silk scaffolds," *Bone*, vol. 42, no. 6, pp. 1226–1234, 2008.

[5] J. Zhao, Z. Zhang, S. Wang et al., "Apatite-coated silk fibroin scaffolds to healing mandibular border defects in canines," *Bone*, vol. 45, no. 3, pp. 517–527, 2009.

[6] G. H. Altman, F. Diaz, C. Jakuba et al., "Silk-based biomaterials," *Biomaterials*, vol. 24, no. 3, pp. 401–416, 2003.

[7] Y. Z. Wang, H. J. Kim, G. Vunjak-Novakovic, and D. L. Kaplan, "Stem cell-based tissue engineering with silk biomaterials," *Biomaterials*, vol. 27, no. 36, pp. 6064–6082, 2006.

[8] Y. Q. Zhang, "Applications of natural silk protein sericin in biomaterials," *Biotechnology Advances*, vol. 20, no. 2, pp. 91–100, 2002.

[9] J. H. Wu, Z. Wang, and S. Y. Xu, "Preparation and characterization of sericin powder extracted from silk industry wastewater," *Food Chemistry*, vol. 103, no. 4, pp. 1255–1262, 2007.

[10] A. Takeuchi, C. Ohtsuki, T. Miyazaki, H. Tanaka, M. Yamazaki, and M. Tanihara, "Deposition of bone-like apatite on silk fiber in a solution that mimics extracellular fluid," *Journal of Biomedical Materials Research A*, vol. 65, no. 2, pp. 283–289, 2003.

[11] ISO 10993-1, "Biological evaluation of medical devices—part 1," *Evaluation and Testing*, ISO, pp. 1–14, 2003.

[12] F. Zhang, Z. Zhang, X. Zhu, E. T. Kang, and K. G. Neoh, "Silk-functionalized titanium surfaces for enhancing osteoblast functions and reducing bacterial adhesion," *Biomaterials*, vol. 29, no. 36, pp. 4751–4759, 2008.

[13] V. Janke, N. V. Neuhoff, B. Schlegelberger, G. Leyhausen, and W. Geurtsen, "TEGDMA causes apoptosis in primary human gingival fibroblasts," *Journal of Dental Research*, vol. 82, no. 10, pp. 814–818, 2003.

[14] ISO and 10993-5, "Biological evaluation of medical devices—Part 5," Test for In Vitro Cytotoxicity, ISO, pp. 24–8, 2009.

[15] D. Dufrane, O. Cornu, T. Verraes et al., "In vitro evaluation of acute cytotoxicity of human chemically treated allografts," *European Cells and Materials*, vol. 1, pp. 52–58, 2001.

[16] T. Cao, T. Y. Saw, B. C. Heng, H. Liu, A. U. J. Yap, and M. L. Ng, "Comparison of different test models for the assessment of cytotoxicity of composite resins," *Journal of Applied Toxicology*, vol. 25, no. 2, pp. 101–108, 2005.

[17] M. L. R. Accorinte, A. D. Loguercio, A. Reis, A. Muench, and V. C. Araújo, "Adverse effects of human pulps after direct pulp capping with the different components from a total-etch, three-step adhesive system," *Dental Materials*, vol. 21, no. 7, pp. 599–607, 2005.

[18] N. H. Kleinsasser, B. C. Wallner, U. A. Harréus et al., "Genotoxicity and cytotoxicity of dental materials in human lymphocytes as assessed by the single cell microgel electrophoresis (comet) assay," *Journal of Dentistry*, vol. 32, no. 3, pp. 229–234, 2004.

[19] A. Paranjpe, L. C. Bordador, M. Y. Wang, W. R. Hume, and A. Jewett, "Resin monomer 2-hydroxyethyl methacrylate (HEMA) is a potent inducer of apoptotic cell death in human and mouse cells," *Journal of Dental Research*, vol. 84, no. 2, pp. 172–177, 2005.

[20] Food and Drug Administration (FDA), "Dietary supplements containing ephedrine alkaloids: proposed rule," *Federal Register*, vol. 62, pp. 30678–30724, 1997.

[21] Y. C. Cheng and W. H. Prusoff, "Relationship between the inhibition constant (K1) and the concentration of inhibitor which causes 50 per cent inhibition (I50) of an enzymatic reaction," *Biochemical Pharmacology*, vol. 22, no. 23, pp. 3099–3108, 1973.

[22] M. Mondal, K. Trivedy, and S. N. Kumar, "The silk proteins, serecin and fibroin in silkworm Bombyx mori Linn," *Caspian Journal of Environmental Science*, vol. 5, no. 2, pp. 63–76, 2007.

[23] C. Dicko, J. M. Kenney, and F. Vollrath, "β-silks: enhancing and controlling aggregation," *Advances in Protein Chemistry*, vol. 73, pp. 17–53, 2006.

Hindawi Publishing Corporation
International Journal of Biomaterials
Volume 2012, Article ID 657519, 9 pages
doi:10.1155/2012/657519

Research Article

Stress Analysis of a Class II MO-Restored Tooth Using a 3D CT-Based Finite Element Model

Yiu Pong Chan,[1] Chak Yin Tang,[1] and Bo Gao[2]

[1] *Department of Industrial and Systems Engineering, The Hong Kong Polytechnic University, Hung Hom, Kowloon, Hong Kong*
[2] *Department of Prosthodontics, College of Stomatology, The Fourth Military Medical University, Xi'an 710032, China*

Correspondence should be addressed to Chak Yin Tang, mfcytang@inet.polyu.edu.hk

Received 15 March 2012; Accepted 25 May 2012

Academic Editor: Yasuhiro Tanimoto

Copyright © 2012 Yiu Pong Chan et al. This is an open access article distributed under the Creative Commons Attribution License, which permits unrestricted use, distribution, and reproduction in any medium, provided the original work is properly cited.

A computational method has been developed for stress analysis of a restored tooth so that experimental effort can be minimized. The objectives of this study include (i) developing a method to create a 3D FE assembly model for a restored tooth based on CT images and (ii) conducting stress analysis of the restored tooth using the 3D FE model established. To build up a solid computational model of a tooth, a method has been proposed to construct a 3D model from 2D CT-scanned images. Facilitated with CAD tools, the 3D tooth model has been virtually incorporated with a Class II MO restoration. The tooth model is triphasic, including the enamel, dentin, and pulp phases. To mimic the natural constraint on the movement of the tooth model, its corresponding mandible model has also been generated. The relative high maximum principal stress values were computed at the surface under loading and in the marginal region of the interface between the restoration and the tooth phases.

1. Introduction

Ethical concerns limit laboratory studies on living subjects, and advanced digital imaging technology has opened up new alternative possibilities in dentistry. The computational simulation method takes a more important position in both clinical and therapeutic applications in the dental industry [1]. Usage of virtual models offers an alternative method of investigation, and costs can also be reduced for in vivo and in vitro experiments.

In dental research, CT scanning is the most frequently used high resolution imaging technology. To conduct CT scans, the targeted object needs to be exposed to a certain amount of ionizing radiation in which the absorbed radiation is detected and imaged later on. A series of sliced 2D images, depicting a density map of the scanned object, can be obtained. Piling these images creates a 3D description of the scanned area. The development of CT technology has been used to study and quantify the morphology of bone [2, 3], to nondestructively evaluate porous biomaterials [4], and to investigate the architecture of scaffolds [5, 6]. The offering of reasonably high resolution is the main reason for using CT as imaging technology in the field of hard tissue engineering. Contrast segmentation is a technique used for tissue differentiation, in which the grayscale of the layered contour images is determined by the tissue density. Living tissues involve complex shapes, for example, teeth and mandibles that are possible to be digitized using CT scanned images to allow accurate measurement of small changes of irregularities [7]. Ulusoy and Darendeliler [8] have evaluated the effects on the stress distribution with different types of Class II activators using a mandible FE model constructed using CT-scanned images. Bujtár et al. [9] have digitized the mandibles of patients of different ages using CT-scanned images, and performed analyses with the simulation of supra normal chewing forces. Gao and Chae [10] have proposed a tooth segmentation method to visualize a tooth from CT images so as to provide assistance for dentists performing orthodontic surgery and treatment.

With the availability of the advanced imaging technology, significant progress has been made in the past decade. Ausiello et al. [1] have constructed a 3D premolar model through digitizing a plaster tooth model with manual operations of the literature data related to the volume of dentin and enamel. Cattaneo et al. [11] have attempted to build up a model of maxilla with two molars from a living object

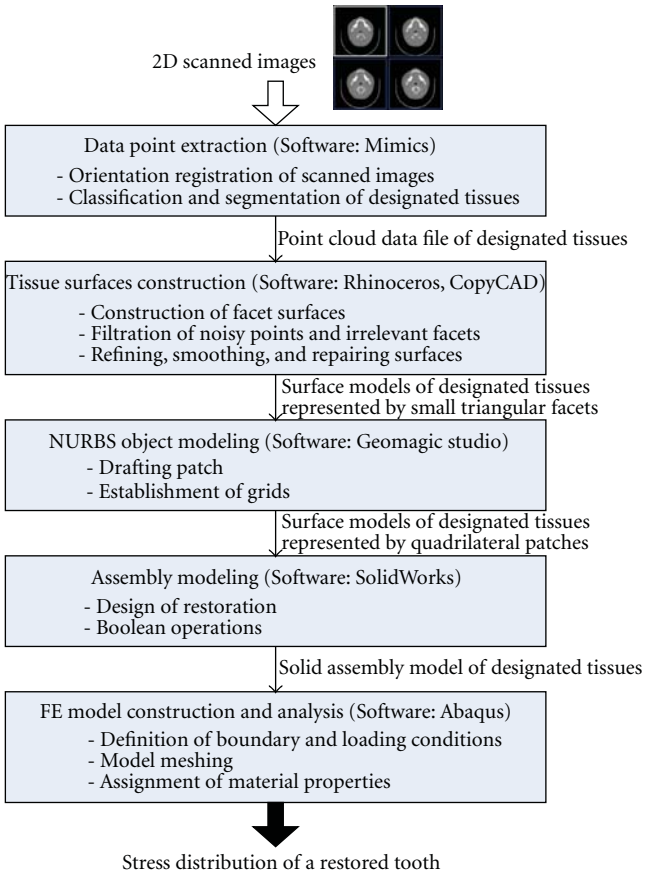

Figure 1: The five-procedure method in generating a 3D CT-based FE model from 2D scanned images.

and to investigate the distribution of stress under occlusal forces, in which the molar parts are assigned with uniform mechanical properties. Ichim et al. [12] have modeled the fracture behavior of a restoration using a 2D FE model constructed using CT-scanned images with the consideration of internal tooth structure. Magne [13] has demonstrated the usage of Boolean operations to build up a 3D tooth model with desired restoration morphologies using CT images. In contrast, Lin et al. [14, 15] have used a 3D tooth model constructed manually, according to the literature data describing the morphology of teeth, to determine the relative contribution of changes in cavity dimensions and various factors on the biomechanical response of a restoration during oral temperature changes. In 2010, Li et al. [16] constructed a 2D FE model from scanned images for optimizing the shape of the restoration cavity. Li et al. [17] have used scanned images to construct a 2D FE model for the simulation of debonding and fracture of a restored tooth.

Understanding how mastication loading is spread over a restored tooth is crucial to both clinical practitioners and material scientists [18]. Miura et al. [19] have stated that periodontal tissue, such as in the mandible, which constrains the location of the tooth, plays an important role for failure prediction in dental research. The aim of the present study is to develop a computational method for the stress analysis of a restored tooth so that experimental effort can be minimized. The objectives of this study therefore are to develop a method to create a 3D FE assembly model for a restored tooth and its corresponding mandible based on CT images; and to conduct stress analysis of the restored tooth using the 3D FE model established. In this study, the tooth model is a triphasic one, consisting of enamel, dentin, and pulp phases, which gives rise to a more realistic simulation to estimate the stress distribution of the tooth and the restoration. Moreover, the proposed method offers a computational scheme assisting dentists to design a more effective tooth repair strategy.

2. Methodology

In this study, a 3D FE model of a restored tooth with a mandible is created from CT-scanned images following the five stages shown in Figure 1. The first stage is to extract the 3D raw data representing the designated tissues in the format of a point cloud from 2D scanned images. The second stage aims to create surface models of the enamel, dentin, pulp, and mandible using tiny triangular facets based on the extracted point cloud data. The purpose of the third stage is to represent the surface models using tiny facets to bigger quadrilateral patches, which facilitates performing modifications on the generated model in the next stage. The fourth stage aims to transform the surface models

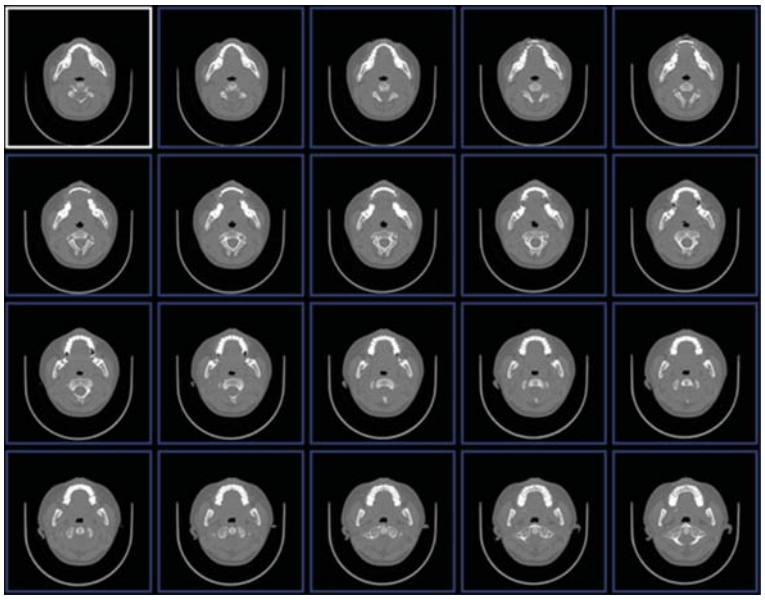

Figure 2: Part of the organized CT images in the top view.

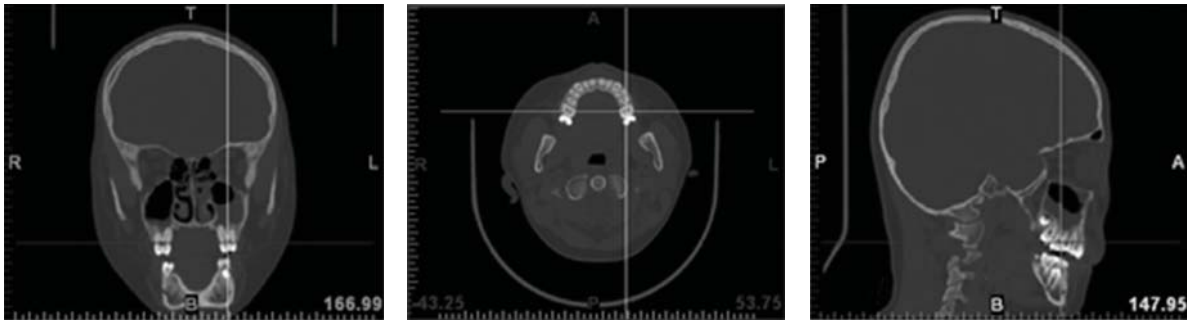

(a) (b) (c)

Figure 3: Orientation parameters registration, top T, bottom B, left L, right R, anterior A, and posterior P, for (a) front view images; (b) top view images, and (c) side view images.

into a solid assembly model comprising a tooth and a mandible submodel. In addition, a Class II mesioocclusal (MO) restoration structure has been incorporated into the tooth sub-model using the CAD tools. The last stage aims to build up the FE model based on the solid assembly model and undertake computational analysis of the stress distribution on a restored tooth under mastication loading.

2.1. Data Point Extraction. This procedure is to align the discrete 2D scanned images into one 3D coordinate system. In addition, it is aimed at extracting the geometric data of the designated tissues from the processed images and storing them in a point cloud format.

In this study, the primary input is the CT scan images. A CT scanner, Bright Speed ct 99 (GE Medical System), was used to obtain the skull images of a 20 years old male. The voltage used was 120 kV, and the current was 300 mA. The slice thickness was 1.25 mm and the pitch ratio was 0.875 : 1. The scan option was 0.8 s, and a total of 180 images were obtained in 60 s. The sets of anatomical images acquired from different 2D perspectives (i.e., top, front, and side) were stored in the DICOM format. The sliced images in the top view were organized in sequence and some are shown in Figure 2.

The organized images are then imported into the software package, Mimics, Version 10.01, Materialise, Leuven, Belgium, to perform the orientation registration process. The process involves the assignment of orientation parameters, top (T), bottom (B), left (L), right (R), anterior (A), and posterior (P), to each anatomical image (Figure 3). In addition, the separation distance for each consecutive scanned image was also specified. In this study, the distance was set as 1.25 mm.

Data on the designated tissues has been extracted through classification and segmentation processes. Each 2D image slice can be regarded as a pixel map of the radiation attenuation tissue coefficient. The level of attenuation can be measured in Hounsfield units (HUs). HU is a normalized

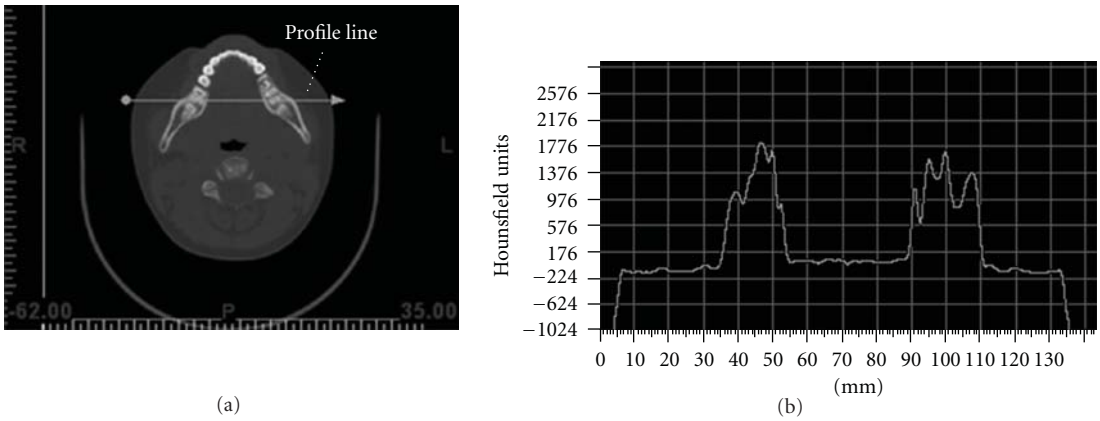

Figure 4: (a) A sliced image with a profile line (about the region with teeth and mandible); (b) the corresponding variations of HU value along the profile line.

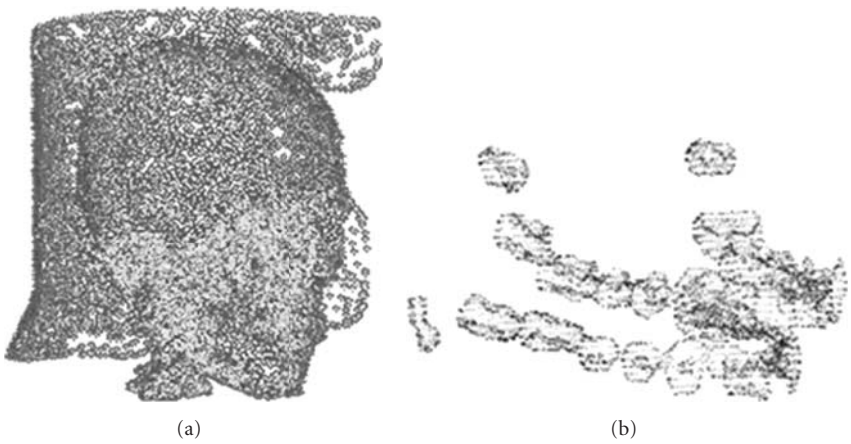

Figure 5: The preliminary obtained geometric point cloud data for (a) mandible, dentin, and pulp descriptions; (b) enamel description.

unit whereby water has a value of 0 while air has a value of –1024. The classification process aims at identifying the HU value describing the targeted tissue in each scanned image, while segmentation is a process of identifying the HU value representing the inner and outer surface boundaries of the tissue. To do so, a profile line was firstly constructed on a scanned image. The upper and lower limits in terms of HU values describing the designated tissues were determined from the profile map. Figure 4 shows a slice of a scanned image and the corresponding variations of HU along the profile line. Through the classification and segmentation functions of mimics, the geometric data of the desired anatomical tissue can be preliminary extracted. To extract the geometric data for the mandible, dentin, and pulp, an HU value within the range of 176–2176 has been used while 2042–3071 has been defined for enamel. Figure 5 presents the preliminary geometric descriptions, in which the descriptions are transformed and presented in point cloud format.

2.2. Tissue Surfaces Construction. The purpose of this procedure is to generate surface models of the designated tissues, which are free from imperfections, from the point cloud data through filtration, smoothing, refining, and repairing processes.

At first, the point cloud data acquired from the previous procedure underwent a polygon/facet creation process, and the software package, Rhino, Version 3.0, Rhinoceros, Seattle, USA, was employed. Facilitated by the software, facets were formed and joined. Surface models were then created as shown in Figure 6. Since the classification and segmentation processes (conducted in the previous procedure) are performed throughout the whole set of anatomic images, surfaces of nondesignated parts having similar HU description values were also generated. In addition, polygon/facet creation was a blind process. Irrelevant facets and noisy points are inevitably formed which could hinder the conversion to the solid model later on. Therefore, a filtering process was undertaken to erase the non-designated/unwanted parts as well as the noisy points and irrelevant facets.

The filtration process was performed with the aid of the embedded clustering function from Rhinoceros. As demonstrated in Figure 7, the surface contour of the mandible was extracted and separated from the noisy points and irrelevant

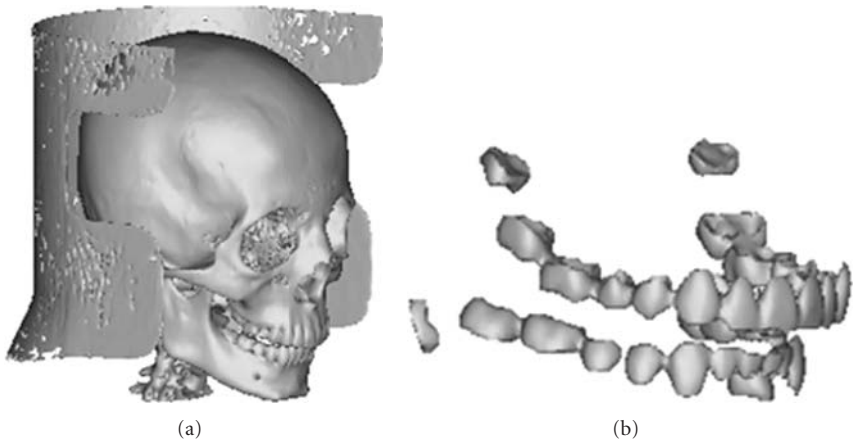

Figure 6: The surface models created through the polygon/facet creation process.

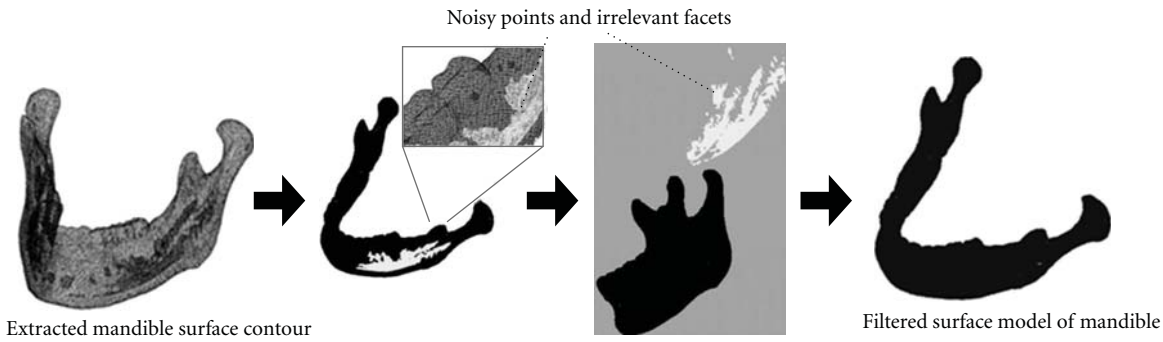

Figure 7: An illustrative example of separating noisy point data and irrelevant facets from the designated mandible tissue surface.

facets. Similarly, the surface contours of enamel, dentin, and pulp were also extracted and filtered.

Surface refinement and smoothing processes were then performed using the software package, CopyCAD, Delcam, Taipei City, Taiwan. Surface refinement involves the detection and deduction of sharp facet triangles and self-intersecting facet triangles. Such action can minimize the chance of error in creating the mesh model in the later procedure. A surface smoothing process was then carried out, which performs a similar operation through the action of modifications rather than deductions. This process involves the definition of a smooth factor (SF) value (a real number ranging from 0 to 1) and an iterative parameter (IP). In this study, the SF and IP parameters were given values of 0.1 and 3, respectively.

Surface repairing was also performed in this procedure, dealing with repairing imperfections, such as small holes and big cavities, in the designated surfaces. Such process was carried out through one of the three schemes, shown in Figure 8, based on the selection criteria. This procedure is important in constructing a closed-surface model which is a must condition for the solid model construction process in the later procedure.

2.3. NURBS Object Modeling. This procedure aims to represent the facet surfaces of the designated tissues using the non-uniform rational basis spline (NURBS) mathematical model. NURBS representing surfaces allows better performance in designing and creating restorations using CAD tools in the next stage. Patch sketching, patch refining, and grid generation are the three processes involved in converting the facet surfaces into NURBS representing surfaces. After the three processes, the morphology of the imported surface models can be kept but is represented using quadrilateral patches. Figure 9 illustrates the processes involved in creating the NURBS representing surfaces of dentin and mandible. This was done using the software package, Geomagic Studio, Version 10, Geomagic, Morrisville, USA.

2.4. Assembly Modeling. This procedure is aimed at transforming the NURBS surface model into a solid model. Using the CAD tools, a conceptual research idea can be substantiated virtually and established interactively according to the freeform geometry of living tissues. In this study, a Class II MO restoration structure has been incorporated virtually into a tooth model.

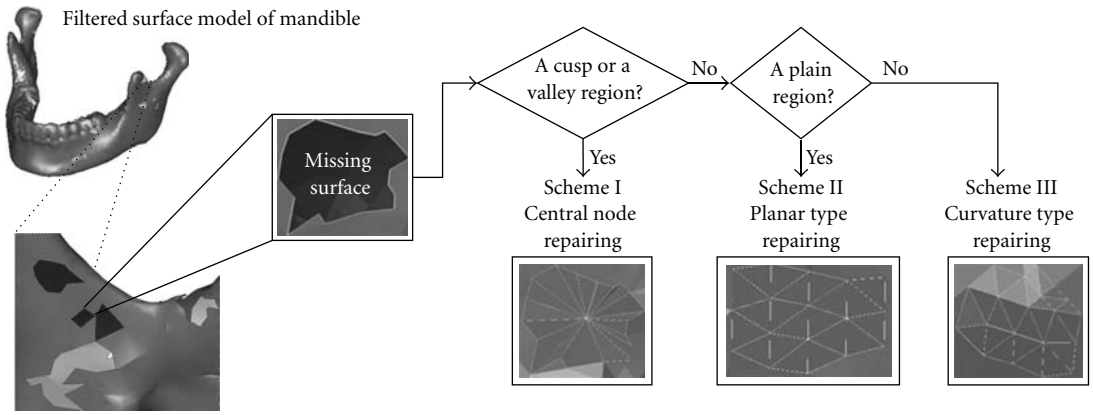

Figure 8: Surface repairing process involved in the tissue surface construction and processing step.

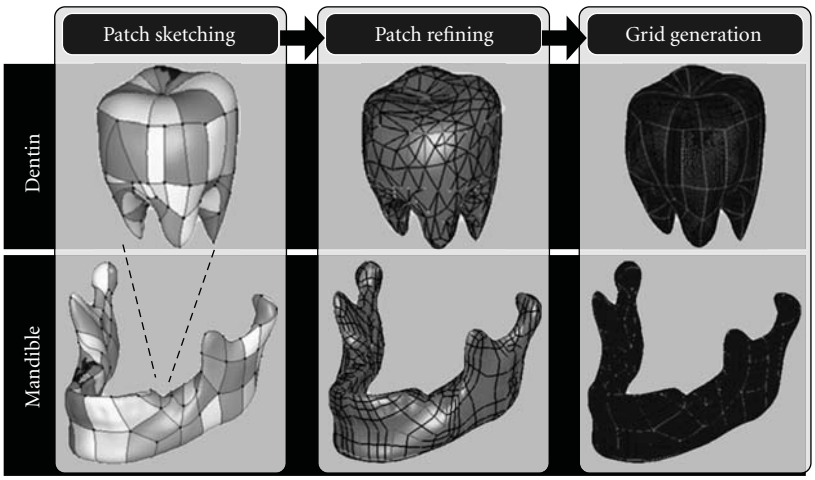

Figure 9: Processes involved in the NURBS object modeling procedure.

Firstly, the imported NURBS surface models of the mandible and tooth underwent a geometric diagnosis process using the CAD software package, SolidWorks Office Premium, Version 2007, SolidWorks, MA, USA. If a model is detected in an opened state, it needs to be reworked from the "Tissue Surfaces Construction" procedure, where the surface repairing process can be performed. If a model is identified to be in a closed state, a solid model can be generated directly.

Facilitated with the CAD tools, Boolean operations were performed for the construction of a restored tooth. Figure 10 demonstrates the Boolean subtraction process for creating a restoration cavity on the tooth model. Additionally, the Boolean union process was executed to trim off and customize the Class II MO restoration model according to the geometry of a tooth surface with dimensions given by Yaman et al. [20]. In addition, to simulate the mastication process, a ball with a diameter of 6 mm was constructed to apply occlusal loading to the tooth model [14]. The desired assembly model with a restored tooth and a mandible submodels was then prepared.

2.5. FE Model Construction and Analysis. This procedure aims to further develop the assembly solid model from the previous procedure to a FE model and involves the definition of the loading and boundary conditions, as well as meshing the model using finite elements. After assigning material properties to different phases of the model, analysis is undertaken to predict the stress distribution of a restored tooth under mastication loading.

As shown in Figure 11, the assembly model of a mandible with a restored tooth was meshed using 3D tetrahedral solid elements (C3D4). This was done using the CAE software package, ABAQUS, Version 6.8, Dassault Systèmes, Simulia, China. To simulate the mastication loading, a spherical morsel with diameter of 6 mm was used having impact velocity of 0.03 mm s^{-1} exerted on the restoration [15, 20].

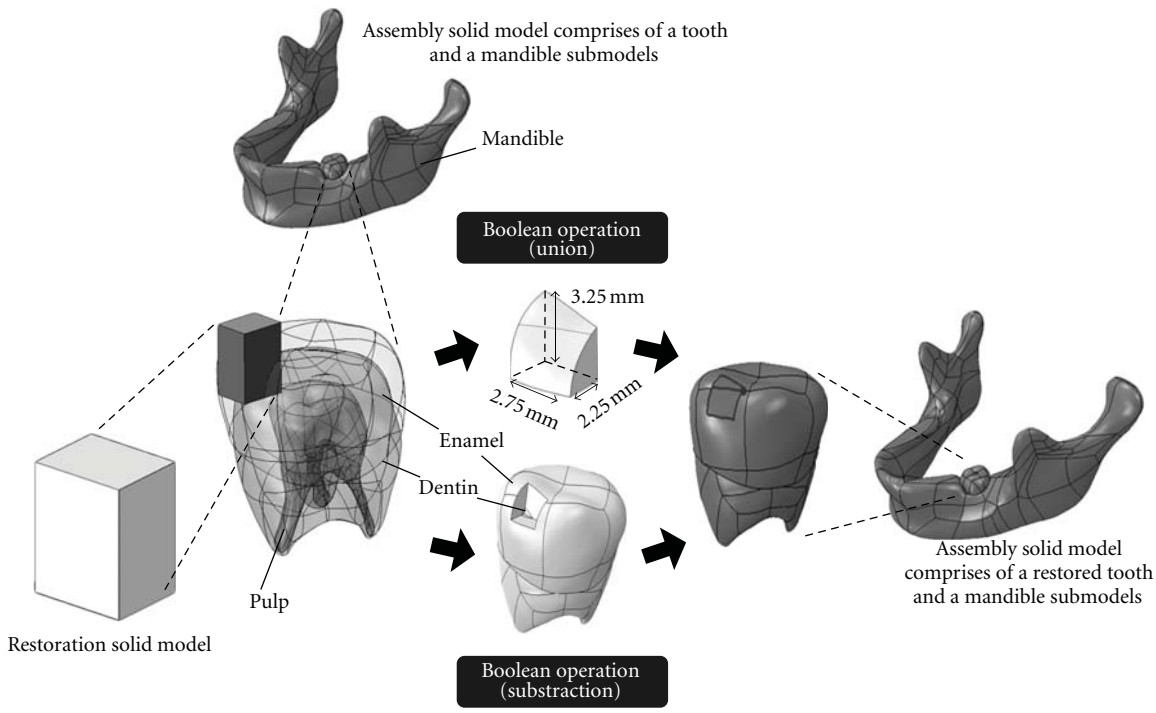

Figure 10: Processes involved in the assembly modeling procedure.

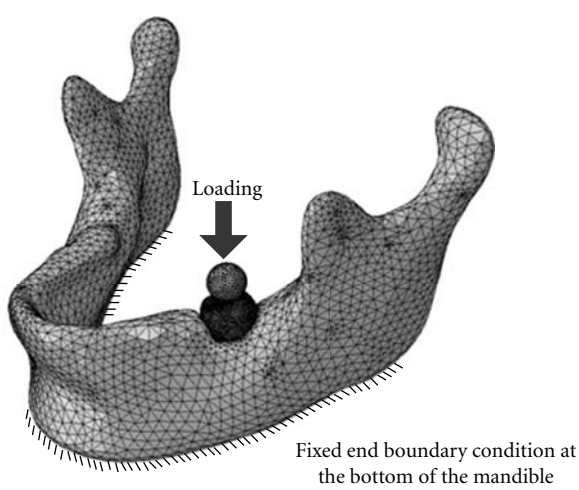

Figure 11: The meshed model (comprises of a restored tooth and a mandible) with description of loading and boundary conditions.

Table 1: Mechanical properties of the morsel, restoration, enamel, dentin, pulp, and mandible phases.

	Elastic modulus (GPa)	Poisson's ratio
Morsel [17]	210	0.30
Restoration [21]	10.7	0.28
Enamel [21]	80.4	0.33
Dentin [21]	19.9	0.31
Pulp [21]	2	0.45
Mandible [21]	14.7	0.30

Simplified boundary conditions were applied, and the base of the mandible model was fixed. The material properties for the morsel, restoration, enamel, dentin, pulp, and mandible phases of the model were assigned as stated in Table 1.

3. Results and Discussions

To construct the tissue surfaces, there involves the definition of SF and IP values. The SF value indicates the importance of the local geometry. If the local geometry is important, the value of the SF will be set to a small value, which indicates that the corresponding smoothing action is limited. If a large value of SF (close to 1) is set, the position of the nodes of the facet triangle sets would be rearranged and the newly assigned position is mainly determined by the position of the other points of the facet triangles in the neighborhood. The number of cycles for smoothing depends on the defined IP. The definition of IP needs to be exercised with caution and to avoid exaggeration. If too many cycles of smoothing are performed, the imported 3D object would be turned into a sphere-like object. Suitable iteration cycles can maintain the morphology of the part of interest while reducing computational loading when carrying out simulation analysis.

Budyn and Hoc (2007) stated that damage cracks can be initiated perpendicularly to the maximum principal stress direction, so the maximum principal stress of the model has been computed. Figure 12 presents the stress contours in the restoration and tooth phases under the simulated mastication loading. Concerning the restoration phase, most of the loading was sustained at the surface having direct contact

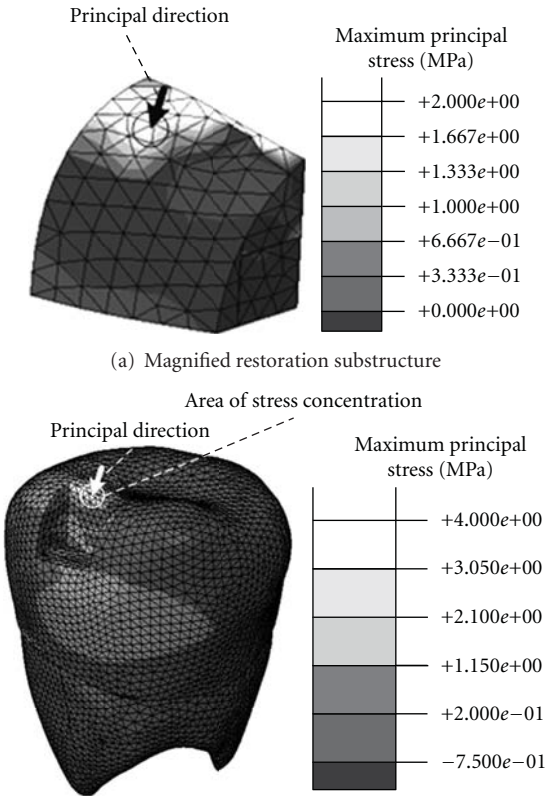

(a) Magnified restoration substructure

(b) Tooth structure

Figure 12: The predicted maximum principal stress of the restoration and tooth phases under the simulated mastication loading.

with the morsel and in the marginal region of the interface between the restoration and the tooth phases. Regarding the tooth phase, concentrations of stress were observed in the marginal region near to the loading. The principal direction of the element having the highest maximum principal stress value is also shown in the figure, which highlights the possible direction for the onset of damage. The predicted stress distribution can provide the important information to formulate a tooth repair strategy avoiding the failure of dental restoration before conducting actual repairs.

4. Conclusions

In this study, a viable alternative method involving the application of commercially available software packages has been used to create a 3D FE solid assembly model based on 2D CT images. A Class II MO restoration has been incorporated virtually into the tooth model. Computational analysis of the stress distribution on a restored tooth under mastication loading has also been conducted. With appropriate modifications, the generated assembly model can be extended for further computational investigations of various classes of restorations and cavity designs.

Acknowledgment

The authors would like to thank the support from the Research Committee of the Hong Kong Polytechnic University (Project codes: RGEP and G-YG18).

References

[1] P. Ausiello, A. Apicella, and C. L. Davidson, "Effect of adhesive layer properties on stress distribution in composite restorations—a 3D finite element analysis," *Dental Materials*, vol. 18, no. 4, pp. 295–303, 2002.

[2] S. K. Boyd, P. Davison, R. Müller, and J. A. Gasser, "Monitoring individual morphological changes over time in ovariectomized rats by in vivo micro-computed tomography," *Bone*, vol. 39, no. 4, pp. 854–862, 2006.

[3] P. A. Hulme, S. K. Boyd, and S. J. Ferguson, "Regional variation in vertebral bone morphology and its contribution to vertebral fracture strength," *Bone*, vol. 41, no. 6, pp. 946–957, 2007.

[4] D. Lacroix, A. Chateau, M. P. Ginebra, and J. A. Planell, "Micro-finite element models of bone tissue-engineering scaffolds," *Biomaterials*, vol. 27, no. 30, pp. 5326–5334, 2006.

[5] S. T. Ho and D. W. Hutmacher, "A comparison of micro CT with other techniques used in the characterization of scaffolds," *Biomaterials*, vol. 27, no. 8, pp. 1362–1376, 2006.

[6] P. B. Malafaya, T. C. Santos, M. van Griensven, and R. L. Reis, "Morphology, mechanical characterization and in vivo neo-vascularization of chitosan particle aggregated scaffolds architectures," *Biomaterials*, vol. 29, no. 29, pp. 3914–3926, 2008.

[7] H. Rudolph, R. G. Luthardt, and M. H. Walter, "Computer-aided analysis of the influence of digitizing and surfacing on the accuracy in dental CAD/CAM technology," *Computers in Biology and Medicine*, vol. 37, no. 5, pp. 579–587, 2007.

[8] Ç. Ulusoy and N. Darendeliler, "Effects of Class II activator and Class II activator high-pull headgear combination on the mandible: a 3-dimensional finite element stress analysis study," *American Journal of Orthodontics and Dentofacial Orthopedics*, vol. 133, no. 4, pp. 490–e9, 2008.

[9] P. Bujtár, G. K. B. Sndor, A. Bojtos, A. Szcs, and J. Barabs, "Finite element analysis of the human mandible at 3 different stages of life," *Oral Surgery, Oral Medicine, Oral Pathology, Oral Radiology and Endodontology*, vol. 110, no. 3, pp. 301–309, 2010.

[10] H. Gao and O. Chae, "Individual tooth segmentation from CT images using level set method with shape and intensity prior," *Pattern Recognition*, vol. 43, no. 7, pp. 2406–2417, 2010.

[11] P. M. Cattaneo, M. Dalstra, and B. Melsen, "The transfer of occlusal forces through the maxillary molars: a finite element study," *American Journal of Orthodontics and Dentofacial Orthopedics*, vol. 123, no. 4, pp. 367–373, 2003.

[12] I. Ichim, Q. Li, W. Li, M. V. Swain, and J. Kieser, "Modelling of fracture behaviour in biomaterials," *Biomaterials*, vol. 28, no. 7, pp. 1317–1326, 2007.

[13] P. Magne, "Efficient 3D finite element analysis of dental restorative procedures using micro-CT data," *Dental Materials*, vol. 23, no. 5, pp. 539–548, 2007.

[14] C. L. Lin, Y. H. Chang, and Y. F. Lin, "Combining structural-thermal coupled field FE analysis and the Taguchi method to evaluate the relative contributions of multi-factors in a premolar adhesive MOD restoration," *Journal of Dentistry*, vol. 36, no. 8, pp. 626–636, 2008.

[15] C. L. Lin, Y. H. Chang, and P. R. Liu, "Multi-factorial analysis of a cusp-replacing adhesive premolar restoration: a finite element study," *Journal of Dentistry*, vol. 36, no. 3, pp. 194–203, 2008.

[16] H. Li, X. Yun, J. Li et al., "Strengthening of a model composite restoration using shape optimization: a numerical and experimental study," *Dental Materials*, vol. 26, no. 2, pp. 126–134, 2010.

[17] H. Li, J. Li, Z. Zou, and A. S. L. Fok, "Fracture simulation of restored teeth using a continuum damage mechanics failure model," *Dental Materials*, vol. 27, no. 7, pp. e125–e133, 2011.

[18] L. H. He and M. V. Swain, "Influence of environment on the mechanical behaviour of mature human enamel," *Biomaterials*, vol. 28, no. 30, pp. 4512–4520, 2007.

[19] J. Miura, Y. Maeda, H. Nakai, and M. Zako, "Multiscale analysis of stress distribution in teeth under applied forces," *Dental Materials*, vol. 25, no. 1, pp. 67–73, 2009.

[20] D. Yaman, M. Yetmez, E. Türköz, and N. Akkas, "Fracture resistance of class II approximal slot restorations," *Journal of Prosthetic Dentistry*, vol. 84, no. 3, pp. 297–302, 2000.

[21] T. Gurbuz, F. Sengul, and C. Altun, "Finite element stress analysis of short-post core and over restorations prepared with different restorative materials," *Dental Materials Journal*, vol. 27, no. 4, pp. 499–507, 2008.

Hindawi Publishing Corporation
International Journal of Biomaterials
Volume 2012, Article ID 531202, 8 pages
doi:10.1155/2012/531202

Review Article

Soft and Hard Tissue Management in Implant Therapy—Part I: Surgical Concepts

Antonio D'Addona, Marjan Ghassemian, Luca Raffaelli, and Paolo Francesco Manicone

Institute of Clinical Dentistry, Catholic University of Sacred Heart, Largo A. Gemelli, 8 00168 Rome, Italy

Correspondence should be addressed to Paolo Francesco Manicone, pfrancesco.manicone@rm.unicatt.it

Received 14 March 2012; Revised 29 May 2012; Accepted 6 June 2012

Academic Editor: Osamu Komiyama

Copyright © 2012 Antonio D'Addona et al. This is an open access article distributed under the Creative Commons Attribution License, which permits unrestricted use, distribution, and reproduction in any medium, provided the original work is properly cited.

Implant therapy has become a reliable and predictable treatment alternative for the replacement of missing teeth with conventional removable and fixed partial dentures. Recently though, in the pursuit for improved esthetics, the literature has dedicated a considerable amount of its research on the successful maintenance and regeneration of the surrounding gingiva and bone, which are lost following extraction of a tooth. Thoroughly analyzing the anatomic situation and well-planned treatment has become a requirement, because incorrectly planned and positioned implants may jeopardize long-term esthetic and functional prognosis. In addition, many types of biocompatible materials, autogenous hard and soft tissue grafts, and different surgical techniques have been developed, and their viability has been investigated. As a result, implant specialists have gained a greater understanding of the dynamics and anatomical and biological concepts of the periodontium and peri-implant tissues both at the surgical and prosthetic phases of treatment, which contributes to better soft and hard tissue management (SHTM). This may further contribute to achieving a superior final result which is obtained by having a harmonious soft tissue profile, a correctly placed and contoured final restoration, and the reestablishment of masticatory function and phonetics.

1. Introduction

The increasing demand over the years for highly esthetic results in all facets of dentistry has also influenced dental implants and has made achieving optimal esthetic results more challenging for the implant specialist and subsequently led to a greater consideration and study of all the contributing factors, both at the micro- and macroscopical level to achieve such a result. The challenge lies in the successful management and modeling of the papilla and gingiva, which are harmonious with the soft tissues of the adjacent natural dentition, and must also be maintainable long-term. Implant esthetics has been thoroughly studied [1–4], and several authors have proposed esthetic indices to assess peri-implant gingival tissues [5, 6] and implant crowns [7]. Belser et al. (2009) proposed the New Esthetic Index: Pink Esthetic Score (PES)/White Esthetic Score (WES) [8], a variation of previously introduced indices.

Thus, an esthetically accepted result not only depends on the shade and form of the final restoration, but also in order to be achieved, it needs careful consideration, and often manipulation of the soft and hard structures adjacent to the implant, the abutment, and final restoration. This demand for better esthetics should accordingly alter the way in which implant specialists treatment plans and places dental implants, especially in the more esthetically demanding anterior region, by considering the soft and hard tissue management (SHTM) at the early treatment planning stage.

Part I of this paper will discuss the reason why surgical augmentation procedures are often required to enhance postextraction sites. Subsequently, it will discuss the use and selection of autogenous grafts, nonautogenous graft material, and finally the timing of implant placement in relation to the extraction, which have been identified as the key concepts in the SHTM. Part II of this paper will describe the key concepts both the theoretical and clinical prosthetic components which the literature has emphasized as having an important role in SHTM in implant therapy, by discussing their direct effect on these structures, and hence, on the final result.

Figure 1: Frontal view of maxillary anterior zone: loss of vertical bone in the edentulous space with loss of papillae and altered profile of alveolar crest.

2. Healing

The periodontium is a dynamic complex of tissues [9] which undergoes remodeling in the area following extraction of a tooth, because the alveolar bone requires mechanical stimulation to maintain its form and density; hence, following the loss of a tooth, there is a decrease in trabeculation and loss of its height and width (Figure 1). This topic has been studied by many authors both microscopically and macroscopically, both in human models [10–13] and canine models [14] and it has been accepted that the remaining structural elements which undergo these changes are both the hard and soft tissues; they are dependant on each other.

In terms of soft tissue changes, immediately following extraction of a tooth, there is loss of gingival architecture, resulting in a reduction in the scalloped soft and hard tissue. The subsequent changes that take place involving these structures include the maturation of the wound which induces the formation and calcification of the bony material. From one of the earliest human studies conducted on the histologic events of the healing sockets [15], the authors concluded that at the first stage there is the formation of a clot, which is made up of a coagulum of red and white blood cells, fibrin, and inflammatory cells. At the second stage, the coagulum is replaced by granulation tissue over a 4-5-day period. At the third stage, over a 2-week period, the granulation tissue contracts and is replaced by connective tissue. This is followed by the fourth stage, in which the calcification of the osteoid at the base and periphery of the socket commences. This formation of bony trabeculae continues for about 6 weeks and is followed by the fifth stage, in which there is complete epithelial closure of the socket. By the 16th week, the socket is completely filled with bone and osteogenic activity is ceased [16].

In results from a recent significant study carried out in human subjects [17], whereby the healing of the extraction socket was monitored for 6 months and analysis of cell populations was carried out, the authors indicated that there may be some differences to what previous research had suggested with regards to tissue healing following an extraction. This study has suggested that there is variability and possibly a delay in the formation and maturation of the alveolar socket following extraction of a tooth. It was found that the rate of healing varied significantly between subjects and that the process of replacement of woven bone with lamellar bone and marrow was slow, such that bone organization and architecture were not completed at 24 weeks after tooth extraction. This study is in contrast with earlier studies carried out and its clinical implications will be discussed subsequently.

In terms of the surrounding hard tissues, research has shown that once the tooth has been extracted the alveolar bone underwent resorption. This dimensional change has been measured both qualitatively, in terms of the surfaces which undergo the resorption, and quantitatively over a period of time and identified as loss in alveolar bone in both the buccolingual and vertical dimensions, resulting in a reduced gingival profile [11, 13, 18], especially if it is of a thin biotype. At a macroscopical level, the healing results in changes in both the bone and overlying soft tissues. Most of the bone resorption which takes place is in a buccolingual dimension, since there is about a 5–7 mm reduction in the alveolar bone crest, over a 6–12-month period, though most of the reduction takes place in the first 4 months. Concurrently, there is a reduction in the vertical dimension of the alveolar bone of approximately 2–4.5 mm. The resorption which takes place may be increased in sockets of molars and in multiple adjacent extraction sockets [13].

Significant hard tissue changes following tooth extraction and implant placement have also been observed in animal studies, including surface resorption of the buccal and lingual walls, the resorption of the marginal bundle bone, and reduction in height of the buccal bone, and reported that as healing continued the height of the buccal wall continued to resorb [19, 20]. It was also found that the buccal plate of the alveolar was often thinner than the lingual plate, and that in these cases this also was associated with more resorption [21, 22].

Other factors that can cause further bone resorption are a reduced alveolar bone width and injury to the alveolus, which may be sustained before or during tooth extraction as iatrogenic fracture. Other local factors include pathology caused by any infective process, such as periodontal and endodontic abscesses, cysts, and tumors [11]. The rate and type of resorption may be increased due to the formation of a fibrous tissue in the damaged areas, which may prevent normal healing and osseous regeneration from taking place [13]. Systemic conditions which may induce further bone loss include genetic predisposition, general and medical conditions, such as diabetes and smoking, and medication and bisphosphonates use [23].

3. Autogenous Grafts

The most common problem the implant specialist is often faced with is the lack of sufficient bone, both the vertical and horizontal dimensions, which if not contemplated at the initial stages of treatment, will induce an esthetically and functionally unacceptable result. From the literature, many authors have approached the problem of alveolar atrophy

by proposing different combinations of surgical techniques and procedures to replace or augment the defective tissue, and from this research have evolved many procedures, methodologies, and materials to encourage new tissue formation, or to discourage further loss of tissue following extraction of dental elements. Various grafting procedures have been developed, using autogenous bone grafts from various donor sites, which has been set as the gold standard for bone augmentation. Autogenous bone can be augmented in particulates or as a block depending on the amount of bone which has been lost and will need to be regenerated.

An autogenous graft is the gold standard because being patient's own bone there are many advantages to its use [24–26]. They contain live osteoblasts and osteoprogenitor cells, which proliferate and bridge the gap between the graft and recipient bone. Success rates are high because there is no immune reaction and the microscopic architecture is perfectly matched. Autografts usually result in the greatest regeneration of missing bone, due to minimal postoperative resorption of the grafted bone. In most cases, the acceptable donor site for block grafts is found intraorally and often enough in proximity to the area to be regenerated.

4. Origin of Graft

In earlier study carried out by Ozaki et al. [27] on animal subjects, the authors investigated the possible influence of microarchitecture and embryologic origin as influencing constituent for the success of autogenous onlay block grafts in the craniofacial skeleton. Prior to this study, it was believed that the embryologic origin of the graft is the main influencing factor, because grafts of membranous origin performed better than endochondral grafts. Though it remains a contributing factor for its success. From this study, the authors concluded that the microarchitecture was the more important constituent in the maintenance of onlay block grafts, and in particular cortical block grafts performed better than cancellous bone grafts.

Comparisons have also been made to determine the most successful source of autogenous graft, using more specific human study on bone augmentation procedures. In one study, 46 successful implants were placed in 32 patients who had the implants sites using 3 different autogenous donor sites. It was concluded that each of the donor sites resulted in a certain amount of bone regeneration, but between the groups significant differences were noted. The group that exhibited the most amount of bone regeneration was the group with the autogenous graft taken from the mandibular symphysis, followed by the ramus and finally the maxillary tuberosity. This study confirmed the success of these augmentation techniques and successfully identified the most reliable donor site in terms of bone gain [28]. And once again, this is in agreement with our clinical experience as the symphysis and ramus are the preferred donor sites.

The occurrence of complications and morbidity between ramus and symphysis have been compared in a retrospective human clinical study, whereby patients were asked to complete a questionnaire, followed by a clinical examination for other signs and symptoms such as sensory impairment [29]. From this study, the authors concluded that the ramus was preferred as a donor site for autogenous block grafts after modifying the surgical technique and increasing the access to the mandibular body area and using a long-shafted bur to create a groove instead of an inferior border osteotomy. Even though the symphysis grafts are more accessible, the ramus grafts encounter fewer complications and morbidity.

Another interesting aspect of onlay block grafts has been studied in a recent study, whereby authors compared the biotype of the patients in relation to the successful maintenance of the block grafts. A two-stage approach was used for implant placement in 40 patients who were categorized as either having a thin or thick biotype and the regenerated bone site was analyzed using computerized tomography for an average of 3.5 years. From their results, authors concluded autogenous block grafts can be used to restore both function and esthetics predictably and that the biotype of the teeth adjacent to the implant sites did not have an influence on the maintenance of the volume of the block grafts [30].

5. Surgical Graft Procedure

The viability of bone regenerated in autogenous guided bone regeneration (GBR) procedure has been thoroughly researched. In one study, the bone augmentation was carried out with autogenous block graft and nonresorbable barrier membranes. Of the 66 implants placed in regenerated bone sites, 60 were concluded to be successful, and the authors concluded from their clinical results that implants placed in generated bone using this particular technique were comparable to the results which can be achieved in nonregenerated bone [31]. This conclusion has been confirmed by other similar studies [32, 33], on the success of these GBR techniques.

The use of autogenous bone grafts used for vertical ridge augmentation can also be carried out with either resorbable barriers or nonresorbable titanium-reinforced barriers. In another study carried out where these two vertical bone augmentation procedures are investigated and compared, 22 implants were placed, half were assigned to each group. Though the number of implants placed was too small, the results indicate that no significant difference in bone gain was present between either of the procedures, and thus the authors concluded that both GBR techniques were effective for vertical bone augmentation [34].

The use of either resorbable or nonresorbable membranes, however, has been associated with a greater number of postoperative complication such as exposure of the membrane, and infection of the surgical site [34]. Conclusions from a clinical study where autogenous cortical block grafts were used without the use of membranes, but were fixated with titanium screws indicate that this technique is safe, effective, and simple [35]. This was confirmed by other human studies, one comparing the effectiveness of augmentation of bone using autogenous block grafts and osteodistraction [36], and the other using autogenous block grafts without membranes [37]. In our continuing experience, autogenous block grafts fixated without membranes

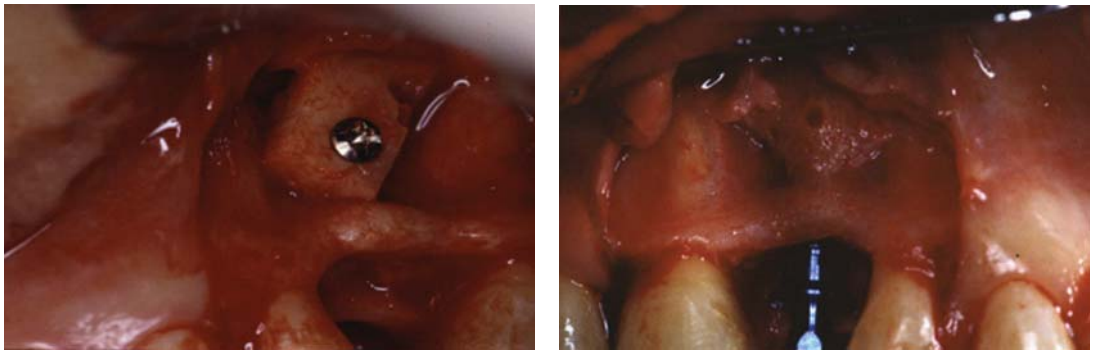

(a) (b)

Figure 2: Intraoral view of autogenous block graft taken from the mandibular symphysis, at time of fixation in no. 24 site (a). Intraoral view of placement of implant in no. 24 site after successful graft, at time of removal of fixation screw (b).

is a valid treatment option for bone augmentation prior to implant placement. This is due to the cellular and microarchitectural events following the positioning of an autogenous graft, which confirm its osteoinductive and osteogenetic characteristics [38] (Figure 2).

6. Nonautogenous Graft Material

The most commonly used nonautogenous materials are demineralized freeze-dried bone. When first introduced, they were used for augmentation in periodontal defects. Its bone forming properties are described as osteoconductive and slightly osteoinductive and its use has proven to be effective in periodontal regeneration [39]. Subsequently, its use was extended to socket preservation [40, 41] and implant therapy where augmentation procedures were indicated [42]. This nonautogenous material has many different applications, as it can be used in combination with autogenous bone grafts and resorbable and nonresorbable membranes. More recent human studies confirmed the efficacy of demineralized freeze-dried bone in augmentation procedures combined with implant therapy [43–45]. Authors from a recent retrospective radiographic study, whereby demineralized freeze-died bone was used in post-extraction sockets exhibited similar marginal bone loss to implants placed in patients bone [46].

Another more recent nonautogenous graft material is hydroxyapatite of β-tricalcium derivatives. This material alone does not have bone-forming capabilities and must be used in combination with other autogenous or nonautogenous graft materials. It shows elevated bioactive and biocompatible characteristics in physiological conditions because of the similarities it has with the inorganic components of bone [47]. This synthetic material has been extensively researched in animals [48–53]. From a recent animal study, the authors concluded that this new synthetic bioresorbable material scaffold may be potentially used in lateral ridge augmentation, though further long-term experimentation with regards to surgical technique and human studies is necessary [54].

Both these nonautogenous materials are used to augment hard tissue. However, a potentially significant preliminary report has been published with regards to peri-implant soft tissue augmentation. In this study of 6 patients who had previously had bone regeneration procedures, the authors used a resorbable collagen matrix as a scaffold for human platelet-derived growth factor. A moderate increase in soft tissue was found, however, authors concluded that improved measuring techniques were required to accurately measure soft tissue changes in volume [55].

7. Surgical Timing

7.1. Timing between Extraction and Implant Placement. The timing between extraction of a tooth and placement of an implant is an important factor in determining the esthetic and functional success of the final restoration, because it can indicate to the implant specialist the amount of bone resorption and loss of the soft tissue profile, which may have taken place within this time. Since it has been known that the rate of alveolar bone resorption is greatest in the first year after extraction, implant specialists try, if possible, to place the implants before a significant amount of resorption takes place. Relative to the postextractive time, the timing of the implant placement has been subdivided into three groups: immediate, delayed, and staged. In the immediate group, the implant placement occurs at the time of the extraction in the delayed group, the implant is placed approximately 2 months after the extraction, to allow complete soft tissue healing and closure of the socket. Whereas in the staged group, the placement of the implant is carried out about 6 months following the extraction, to consent a significant amount of bone healing [56].

7.2. Immediate Placement. The advantages claimed for the immediate implant placement protocol are the marked reduction in time taken for healing, the reduced number of surgical procedures, and the optimal availability of existing bone to allow primary stability of the implant. Furthermore, at a microscopical level, it is thought that

the postextraction osteogenic activity may improve the bone-to-implant contact when surface-treated implants are used [57]. Conclusions from another study which examined hard tissue changes following immediate implant placement only, partially supported the fact that bone defects around immediate implants could heal. The authors indicated that though from clinical examination new bone formation was observed, at a microscopical level the presence of a connective tissue layer was suspected, thus, they could not draw conclusions as to whether in these sites osseointegration between the bone and implant surface took place [58]. In addition, the buccolingual positioning of immediate implants must be carefully considered, because in contrast to what was previously thought, the immediate implant protocol does not completely prevent the buccolingual resorption of the buccal plate [59].

Another conceivable disadvantage of this technique is that it requires an acceptable amount of bone tissue, since it does not permit large amounts of hard and soft tissues to be grafted or augmented. If there are significant pathologies affecting the hard and soft tissues in the area of the extracted tooth, this technique is not recommended [13]. Some research on immediate implant placement has indicated that bone remodeling, apposition, and healing of bony tissue take place also in the implant neck area. This is believed to be the reason for the lack of implications which negatively affect the final esthetics [60], and conclusions from a 1-year clinical study whereby 35 immediate implants were placed have also confirmed that the immediate implant placement protocol can result in satisfactory peri-implant soft tissue and esthetic outcomes [61].

A recent review has been carried out examining the clinical outcomes of immediate or early placement protocols. The conclusions made from this literature analysis suggest that the use of the immediate procedure can result in high success in terms of survival rates. Whereas in terms of esthetic outcome, the authors did not make a decisive statement but concluded there is an increased risk of esthetic failure, though it is believed that if a thorough process of case selection is carried out, satisfactory results can be achieved. Therefore, the authors have suggested that these protocols can be used by implant specialists with an elevated level of experience [62]. This is in agreement with our clinical experience which underlines that no ideal timing exists between extraction of a tooth and implant placement, as each patient should be evaluated case by case. Though as a general rule, immediate implant placement protocol may be used in the posterior segments, whilst the delayed protocol is still preferred in the anterior segments.

7.3. Delayed Placement. As well as permitting primary soft tissue closure, the rationale to the delayed implant placement technique is to allow for the resolution of all signs of minor pathology associated with the tissues in the area of the extracted tooth, and to consent complete bone healing, thus, optimizing the healing and osseointegration of the implant, and integration of the tissues, if bone augmentation procedures and soft tissue grafts have been carried out [21].

As discussed earlier, one particular study carried out a comparative analysis to evaluate the healing of buccal marginal defects around implants after one year of being placed directly in extraction sockets (immediate), or 4–6 weeks (delayed immediate) after extraction and augmentation procedures with membranes and bone grafts. In relation to the timing, in the case of single implants, better statistical results were found with the delayed immediate protocol, due to the primary closure of the alveolus which seemed to help the integration of the implant, bone grafts, and barrier membranes [20]. These results were confirmed in another similar study that was carried out to compare the immediate and delayed protocols. However, in terms of the dimensions of the interproximal papilla, the authors were unable to significantly differentiate between the groups [63].

7.4. Staged Placement. When compared to the immediate technique of implant placement, it can be more difficult to achieve highly esthetic restoration with the staged technique, because of the resorption of the alveolar bone, which potentially results in a narrower ridge with a buccal concavity and contemporarily the loss of gingival architecture. In these cases, as it has been previously discussed, the implant specialist should decide to carry out soft and hard tissue regeneration procedures based on radiographic diagnosis and prosthetic treatment planning to restore the lost tissue and achieve satisfactory esthetics. Therefore, disadvantages of this technique include longer treatment time and increased number of surgical interventions.

8. Conclusion

It is imperative that implant specialists evaluate the presenting condition of each case individually, and carefully consider the consequences of the surgical interventions and their timing, to be able to achieve an acceptable result. Based on the initial condition of the hard and soft architecture, implant specialists must decide firstly whether hard or soft tissue augmentation are necessary prior to implant placement, and if so, which technique is appropriate. From the literature and based on our experience, autogenous bone grafts are a viable treatment option for hard tissue augmentation when there is not sufficient bone and particularly the use of block grafts taken from the mandibular symphysis area or the ramus, when a large quantity of graft material is required. In relation to timing-for-implant placement, our protocol follows the literature guidelines and the decision should be made for each case on an individual basis.

References

[1] C. D. J. Evans and S. T. Chen, "Esthetic outcomes of immediate implant placements," *Clinical Oral Implants Research*, vol. 19, no. 1, pp. 73–80, 2008.

[2] L. Meijndert, H. J. A. Meijer, K. Stellingsma, B. Stegenga, and G. M. Raghoebar, "Evaluation of aesthetics of implant-supported single-tooth replacements using different bone augmentation procedures: a prospective randomized clinical study," *Clinical Oral Implants Research*, vol. 18, no. 6, pp. 715–719, 2007.

[3] J. Cosyn, A. Eghbali, H. De Bruyn, K. Collys, R. Cleymaet, and T. De Rouck, "Immediate single-tooth implants in the anterior maxilla: 3-year results of a case series on hard and soft tissue response and aesthetics," *Journal of Clinical Periodontology*, vol. 38, no. 8, pp. 746–753, 2011.

[4] F. Raes, J. Cosyn, E. Crommelinck, P. Coessens, and H. De Bruyn, "Immediate and conventional single implant treatment in the anterior maxilla: 1-Year results of a case series on hard and soft tissue response and aesthetics," *Journal of Clinical Periodontology*, vol. 38, no. 4, pp. 385–394, 2011.

[5] T. Jemt, "Regeneration of gingival papillae after single-implant treatment," *International Journal of Periodontics and Restorative Dentistry*, vol. 17, no. 4, pp. 327–333, 1997.

[6] R. Fürhauser, D. Florescu, T. Benesch, R. Haas, G. Mailath, and G. Watzek, "Evaluation of soft tissue around single-tooth implant crowns: the pink esthetic score," *Clinical Oral Implants Research*, vol. 16, no. 6, pp. 639–644, 2005.

[7] H. J. A. Meijer, K. Stellingsma, L. Meijndert, and G. M. Raghoebar, "A new index for rating aesthetics of implant-supported single crowns and adjacent soft tissues—the Implant Crown Aesthetic Index: a pilot study on validation of a new index," *Clinical Oral Implants Research*, vol. 16, no. 6, pp. 645–649, 2005.

[8] U. C. Belser, L. Grütter, F. Vailati, M. M. Bornstein, H. P. Weber, and D. Buser, "Outcome evaluation of early placed maxillary anterior single-tooth implants using objective esthetic criteria: a cross-sectional, retrospective study in 45 patients with a 2- to 4-year follow-up using pink and white esthetic scores," *Journal of Periodontology*, vol. 80, no. 1, pp. 140–151, 2009.

[9] J. L. Saffar, J. J. Lasfargues, and M. Cherruau, "Alveolar bone and the alveolar process: the socket that is never stable," *Periodontology 2000*, vol. 14, no. 1, pp. 76–90, 1997.

[10] J. Pietrokovski and M. Massler, "Alveolar ridge resorption following tooth extraction," *The Journal of Prosthetic Dentistry*, vol. 17, no. 1, pp. 21–27, 1967.

[11] L. Schropp, A. Wenzel, L. Kostopoulos, and T. Karring, "Bone healing and soft tissue contour changes following single-tooth extraction: a clinical and radiographic 12-month prospective study," *International Journal of Periodontics and Restorative Dentistry*, vol. 23, no. 4, pp. 313–323, 2003.

[12] G. Cardaropoli, U. Lekholm, and J. L. Wennström, "Tissue alterations at implant-supported single-tooth replacements: a 1-year prospective clinical study," *Clinical Oral Implants Research*, vol. 17, no. 2, pp. 165–171, 2006.

[13] S. T. Chen, T. G. Wilson, and C. H. F. Hämmerle, "Immediate or early placement of implants following tooth extraction: review of biologic basis, clinical procedures, and outcomes," *International Journal of Oral and Maxillofacial Implants*, vol. 19, pp. 12–25, 2004.

[14] G. Cardaropoli, M. Araújo, R. Hayacibara, F. Sukekava, and J. Lindhe, "Healing of extraction sockets and surgically produced—augmented and non-augmented—defects in the alveolar ridge. An experimental study in the dog," *Journal of Clinical Periodontology*, vol. 32, no. 5, pp. 435–440, 2005.

[15] M. H. Amler, "The time sequence of tissue regeneration in human extraction wounds," *Oral Surgery, Oral Medicine, Oral Pathology*, vol. 27, no. 3, pp. 309–318, 1969.

[16] C. I. Evian, E. S. Rosenberg, J. G. Coslet, and H. Corn, "The osteogenic activity of bone removed from healing extraction sockets in humans," *Journal of Periodontology*, vol. 53, no. 2, pp. 81–85, 1982.

[17] L. Trombelli, R. Farina, A. Marzola, L. Bozzi, B. Liljenberg, and J. Lindhe, "Modeling and remodeling of human extraction sockets," *Journal of Clinical Periodontology*, vol. 35, no. 7, pp. 630–639, 2008.

[18] L. Schropp, L. Kostopoulos, and A. Wenzel, "Bone healing following immediate versus delayed placement of titanium implants into extraction sockets: a prospective clinical study," *International Journal of Oral and Maxillofacial Implants*, vol. 18, no. 2, pp. 189–199, 2003.

[19] M. G. Araújo, F. Sukekava, J. L. Wennström, and J. Lindhe, "Tissue modeling following implant placement in fresh extraction sockets," *Clinical Oral Implants Research*, vol. 17, no. 6, pp. 615–624, 2006.

[20] M. G. Araújo, F. Sukekava, J. L. Wennström, and J. Lindhe, "Ridge alterations following implant placement in fresh extraction sockets: an experimental study in the dog," *Journal of Clinical Periodontology*, vol. 32, no. 6, pp. 645–652, 2005.

[21] C. E. Nemcovsky, Z. Artzi, O. Moses, and I. Gelernter, "Healing of marginal defects at implants placed in fresh extraction sockets or after 4–6 weeks of healing: a comparative study," *Clinical Oral Implants Research*, vol. 13, no. 4, pp. 410–419, 2002.

[22] L. Prosper, E. F. Gherlone, S. Redaelli, and M. Quaranta, "Four-year follow-up of larger-diameter implants placed in fresh extraction sockets using a resorbable membrane or a resorbable alloplastic material," *International Journal of Oral and Maxillofacial Implants*, vol. 18, no. 6, pp. 856–864, 2003.

[23] L. J. A. Heitz-Mayfield, "Peri-implant diseases: diagnosis and risk indicators," *Journal of Clinical Periodontology*, vol. 35, no. 8, pp. 292–304, 2008.

[24] C. Tinti and S. Parma-Benfenati, "Vertical ridge augmentation: surgical protocol and retrospective evaluation of 48 consecutively inserted implants," *International Journal of Periodontics and Restorative Dentistry*, vol. 18, no. 5, pp. 435–443, 1998.

[25] M. Simion, S. A. Jovanovic, P. Trisi, A. Scarano, and A. Piattelli, "Vertical ridge augmentation around dental implants using a membrane technique and autogenous bone or allografts in humans," *International Journal of Periodontics and Restorative Dentistry*, vol. 18, no. 1, pp. 9–23, 1998.

[26] A. D'Addona and H. Nowzari, "Intramembranous autogenous osseous transplants in aesthetic treatment of alveolar atrophy," *Periodontology 2000*, vol. 27, no. 1, pp. 148–161, 2001.

[27] W. Ozaki, S. R. Buchman, S. A. Goldsteinand, and D. P. Fyhrie, "A comparative analysis of the microarchitecture of cortical membranous and cortical endochondral onlay bone grafts in the craniofacial skeleton," *Plastic and Reconstructive Surgery*, vol. 104, no. 1, pp. 139–147, 1999.

[28] A. A. Veis, A. T. Tsirlis, and N. A. Parisis, "Effect of autogenous harvest site location on the outcome of ridge augmentation for implant dehiscences," *International Journal of Periodontics and Restorative Dentistry*, vol. 24, no. 2, pp. 155–163, 2004.

[29] J. Clavero and S. Lundgren, "Ramus or chin grafts for maxillary sinus inlay and local onlay augmentation: comparison of donor site morbidity and complications," *Clinical Implant Dentistry and Related Research*, vol. 5, no. 3, pp. 154–160, 2003.

[30] F. Verdugo, K. Simonian, and H. Nowzari, "Periodontal biotype influence on the volume maintenance of onlay grafts," *Journal of Periodontology*, vol. 80, no. 5, pp. 816–823, 2009.

[31] D. Buser, S. Ingimarsson, K. Dula, A. Lussi, H. P. Hirt, and U. C. Belser, "Long-term stability of osseointegrated implants in augmented bone: a 5-year prospective study in partially edentulous patients," *International Journal of Periodontics and Restorative Dentistry*, vol. 22, no. 2, pp. 108–117, 2002.

[32] M. Nevins, J. T. Mellonig, D. S. Clem, G. M. Reiser, and D. A. Buser, "Implants in regenerated bone: long-term survival,"

International Journal of Periodontics and Restorative Dentistry, vol. 18, no. 1, pp. 35–45, 1998.

[33] M. Simion, S. A. Jovanovic, C. Tinti, and S. P. Benfenati, "Long-term evaluation of osseointegrated implants inserted at the time or after vertical ridge augmentation: a retrospective study on I23 implants with I-5 year follow-up," *Clinical Oral Implants Research*, vol. 12, no. 1, pp. 35–45, 2001.

[34] M. Merli, M. Migani, and M. Esposito, "Vertical ridge augmentation with autogenous bone grafts: resorbable barriers supported by ostheosynthesis plates versus titanium-reinforced barriers. A preliminary report of a blinded, randomized controlled clinical trial," *International Journal of Oral and Maxillofacial Implants*, vol. 22, no. 3, pp. 373–382, 2007.

[35] L. Cordaro, D. S. Amadè, and M. Cordaro, "Clinical results of alveolar ridge augmentation with mandibular block bone grafts in partially edentulous patients prior to implant placement," *Clinical Oral Implants Research*, vol. 13, no. 1, pp. 103–111, 2002.

[36] M. Chiapasco, M. Zaniboni, and L. Rimondini, "Autogenous onlay bone grafts vs. alveolar distraction osteogenesis for the correction of vertically deficient edentulous ridges: A 2-4-year prospective study on humans," *Clinical Oral Implants Research*, vol. 18, no. 4, pp. 432–440, 2007.

[37] L. Levin, D. Nitzan, and D. Schwartz-Arad, "Success of dental implants placed in intraoral block bone grafts," *Journal of Periodontology*, vol. 78, no. 1, pp. 18–21, 2007.

[38] A. A. Aalam and H. Nowzari, "Mandibular cortical bone grafts part 1: anatomy, healing process, and influencing factors," *Compendium of Continuing Education in Dentistry*, vol. 28, no. 4, pp. 206–213, 2007.

[39] E. Rosenberg and L. F. Rose, "Biologic and clinical considerations for autografts and allografts in periodontal regeneration therapy," *Dental clinics of North America*, vol. 42, no. 3, pp. 467–490, 1998.

[40] W. Becker, C. Clokie, L. Sennerby, M. R. Urist, and B. E. Becker, "Histologic findings after implantation and evaluation of different grafting materials and titanium micro screws into extraction sockets: case reports," *Journal of Periodontology*, vol. 69, no. 4, pp. 414–421, 1998.

[41] D. Carmagnola, P. Adriaens, and T. Berglundh, "Healing of human extraction sockets filled with Bio-Oss," *Clinical Oral Implants Research*, vol. 14, no. 2, pp. 137–143, 2003.

[42] C. H. F. Hämmerle, G. C. Chiantella, T. Karring, and N. P. Lang, "The effect of a deproteinized bovine bone mineral on bone regeneration around titanium dental implants," *Clinical Oral Implants Research*, vol. 9, no. 3, pp. 151–162, 1998.

[43] N. U. Zitzmann, P. Schärer, C. P. Marinello, P. Schüpbach, and T. Berglundh, "Alveolar ridge augmentation with Bio-Oss: a histologic study in humans," *International Journal of Periodontics and Restorative Dentistry*, vol. 21, no. 3, pp. 289–295, 2001.

[44] C. H. F. Hämmerle and N. P. Lang, "Single stage surgery combining transmucosal implant placement with guided bone regeneration and bioresorbable materials," *Clinical Oral Implants Research*, vol. 12, no. 1, pp. 9–18, 2001.

[45] C. H. F. Hämmerle, R. E. Jung, D. Yaman, and N. P. Lang, "Ridge augmentation by applying bioresorbable membranes and deproteinized bovine bone mineral: a report of twelve consecutive cases," *Clinical Oral Implants Research*, vol. 19, no. 1, pp. 19–25, 2008.

[46] T. Koutouzis and T. Lundgren, "Crestal bone-level changes around implants placed in post-extraction sockets augmented with demineralized freeze-dried bone allograft: a retrospective radiographic study," *Journal of Periodontology*, vol. 81, no. 10, pp. 1441–1448, 2010.

[47] S. Bose and S. Tarafder, "Calcium phosphate ceramic systems in growth factor and drug delivery for bone tissue engineering: a review," *Acta Biomaterialia*, vol. 8, no. 4, pp. 1401–1421, 2012.

[48] J. T. Schantz, D. W. Hutmacher, C. X. F. Lam et al., "Repair of calvarial defects with customised tissue-engineered bone grafts. II. Evaluation of cellular efficiency and efficacy in vivo," *Tissue Engineering*, vol. 9, no. 1, pp. S127–S139, 2003.

[49] J. T. Schantz, S. H. Teoh, T. C. Lim, M. Endres, C. X. F. Lam, and D. W. Hutmacher, "Repair of calvarial defects with customized tissue-engineered bone grafts. I. Evaluation of osteogenesis in a three-dimensional culture system," *Tissue Engineering*, vol. 9, no. 1, pp. S113–S126, 2003.

[50] A. Yeo, B. Rai, E. Sju, J. J. Cheong, and S. H. Teoh, "The degradation profile of novel, bioresorbable PCL-TCP scaffolds: an in vitro and in vivo study," *Journal of Biomedical Materials Research A*, vol. 84, no. 1, pp. 208–218, 2008.

[51] A. Yeo, E. Sju, B. Rai, and S. H. Teoh, "Customizing the degradation and load-bearing profile of 3D polycaprolactone-tricalcium phosphate scaffolds under enzymatic and hydrolytic conditions," *Journal of Biomedical Materials Research B*, vol. 87, no. 2, pp. 562–569, 2008.

[52] A. Yeo, W. J. Wong, H. H. Khoo, and S. H. Teoh, "Surface modification of PCL-TCP scaffolds improve interfacial mechanical interlock and enhance early bone formation: an in vitro and in vivo characterization," *Journal of Biomedical Materials Research A*, vol. 92, no. 1, pp. 311–321, 2010.

[53] A. Yeo, W. J. Wong, and S. H. Teoh, "Surface modification of PCL-TCP scaffolds in rabbit calvaria defects: evaluation of scaffold degradation profile, biomechanical properties and bone healing patterns," *Journal of Biomedical Materials Research A*, vol. 93, no. 4, pp. 1358–1367, 2010.

[54] A. Yeo, C. Cheok, S. H. Teoh, Z. Y. Zhang, D. Buser, and D. D. Bosshardt, "Lateral ridge augmentation using a PCL-TCP scaffold in a clinically relevant but challenging micropig model," *Clinical Oral Implants Research*. In press.

[55] M. Simion, I. Rocchietta, F. Fontana, and C. Dellavia, "Evaluation of a resorbable collagen matrix infused with rhPDGF-BB in peri-implant soft tissue augmentation: a preliminary report with 3.5 years of observation," *International Journal of Periodontics and Restorative Dentistry*, vol. 32, no. 3, pp. 273–282, 2012.

[56] S. Jivraj and W. Chee, "Treatment planning of implants in the aesthetic zone," *British Dental Journal*, vol. 201, no. 2, pp. 77–89, 2006.

[57] T. De Rouck, K. Collys, and J. Cosyn, "Single-tooth replacement in the anterior maxilla by means of immediate implantation and provisionalization: a review," *International Journal of Oral and Maxillofacial Implants*, vol. 23, no. 5, pp. 897–904, 2008.

[58] D. Botticelli, T. Berglundh, and J. Lindhe, "Hard-tissue alterations following immediate implant placement in extraction sites," *Journal of Clinical Periodontology*, vol. 31, no. 10, pp. 820–828, 2004.

[59] U. Covani, C. Bortolaia, A. Barone, and L. Sbordone, "Buccolingual crestal bone changes after immediate and delayed implant placement," *Journal of Periodontology*, vol. 75, no. 12, pp. 1605–1612, 2004.

[60] U. Covani, R. Cornelini, and A. Barone, "Vertical crestal bone changes around implants placed into fresh extraction sockets," *Journal of Periodontology*, vol. 78, no. 5, pp. 810–815, 2007.

[61] J. Y. K. Kan, K. Rungcharassaeng, and J. Lozada, "Immediate placement and provisionalization of maxillary anterior single implants: 1-Year prospective study," *International Journal of Oral and Maxillofacial Implants*, vol. 18, no. 1, pp. 31–39, 2003.

[62] L. Schropp and F. Isidor, "Timing of implant placement relative to tooth extraction," *Journal of Oral Rehabilitation*, vol. 35, no. 1, pp. 33–43, 2008.

[63] L. Schropp, F. Isidor, L. Kostopoulos, and A. Wenzel, "Interproximal papilla levels following early versus delayed placement of single-tooth implants: a controlled clinical trial," *International Journal of Oral and Maxillofacial Implants*, vol. 20, no. 5, pp. 753–761, 2005.

Hindawi Publishing Corporation
International Journal of Biomaterials
Volume 2012, Article ID 356817, 6 pages
doi:10.1155/2012/356817

Review Article

Soft and Hard Tissue Management in Implant Therapy—Part II: Prosthetic Concepts

Paolo Francesco Manicone, Luca Raffaelli, Marjan Ghassemian, and Antonio D'Addona

Institute of Clinical Dentistry, Catholic University of The Sacred Heart, Largo A. Gemelli 8, 00168 Rome, Italy

Correspondence should be addressed to Paolo Francesco Manicone, pfrancesco.manicone@rm.unicatt.it

Received 14 March 2012; Accepted 6 June 2012

Academic Editor: Masaru Yamaguchi

Copyright © 2012 Paolo Francesco Manicone et al. This is an open access article distributed under the Creative Commons Attribution License, which permits unrestricted use, distribution, and reproduction in any medium, provided the original work is properly cited.

The ongoing pursuit of aesthetic excellence in the field of implant therapy has incorporated prosthetic concepts in the early treatment-planning phase, as well as the previously discussed surgical concepts. The literature has addressed these prosthetic and laboratory approaches required to enhance and perfect the soft and hard tissue management (SHTM). After surgically providing an acceptable hard tissue architecture and adequate timing of loading of the implant, the prosthetic phase is responsible for the soft tissue modeling, through correctly planned and executed procedures, which induce a satisfactory soft tissue profile by considering the microvasculature, the abutment connection and positioning, and the implementation of an adequate provisional phase. The objectives are the modeling of the soft tissues through the use of a conforming periorestorative interface which will produce desired and stable results.

1. Introduction

As a component of the key factors responsible for the aesthetic success of implant therapy, the prosthetic aspect is equally as important as the surgical aspect. The surgical aspect should provide a reliable hard tissue foundation for the creation of a harmonious soft tissue profile, which is completed and perfected by a well-planned and carried out prosthetic phase. It Commences with the functional loading of the implant, with an appropriately designed abutment and temporary restoration in a provisional phase of treatment, which is responsible for the soft tissue modeling, followed by the placement of the permanent restoration once the desired soft tissue form has been obtained, which effectively maintains the results achieved through long-term stabilization of the tissues. The fundamental concepts that will be discussed in this paper are the timing of the loading of the implant, the principles and techniques used for tissue modeling, and the management of the periorestorative components interface to achieve stabilization of adequate and predictable aesthetics.

2. Timing of Loading

2.1. Timing Selection. The decision of when to load an implant is an important decision that is made by considering both the surgical and prosthetic aspects, which are responsible for the hard tissue integration to the implant and the final soft tissue results.

The timing of loading of an implant has been associated with the successful integration of an implant. Early studies of osseointegrated implants state that absence of micromovements and primary implant stability are important factors which contribute to the success of implant integration [1], as micromovements and reduced primary stability may lead to the formation of a soft tissue between the bony and implant surface. In addition, an excessive and uncontrolled mechanical load is thought to be a key factor that can contribute to implant failure due to bone remodeling, which may lead to increased or excessive marginal bone loss [2]. Conventional loading protocols require a healing period during which the implants placed are not to be functionally loaded.

The rationale has been that by delaying the functional loading, micromovements would be reduced or eliminated and primary stability maximized, thus, allowing for proper osseointegration.

However, subsequently, the practice of immediate loading has been introduced, where implants are subjected to functional loading immediately or shortly following implant placement [3]. The obvious advantages of this protocol were the reduction in total treatment time and elimination of provisional removable prosthetics, but, subsequently, it was noticed that the other beneficial results were improved gingival aesthetics, which resulted from an earlier modeling of the soft tissues. Authors have concluded that in the case of the edentulous maxilla, the cervical contour of the immediate provisional prosthesis and its corresponding embrasures seem to induce the final shape of the peri-implant mucosa, during the healing phase [4], and in the case of the edentulous mandible the variability in the final result is found not to be dependant on the time of loading [5].

Studies comparing the conventional and immediately loaded protocols have been carried out by a number of authors to analyze the varying occlusal characteristics both in partially edentulous and edentulous subjects. The studies are in agreement and have reported that there are no significant differences seen between these protocols in terms of implant stability, marginal bone changes, and soft tissue response [6]. Therefore, researchers believe that implants can be successfully loaded immediately or shortly thereafter, so long as sufficient primary stability is achieved [7, 8], though it is believed that successful results may not be achieved by all clinicians [7].

The bone-to-implant contact is a histological and clinical characteristic that contributes to the stability of the implant within the bone. Primary bone-to-implant contact is defined as the amount of original bone that is in contact with the implant at the time of placement, and the secondary bone-to-implant contact is defined as the bone that is formed around the implant after-placement [9]. And results from an in vitro clinical trial on canine models comparing such histological, and other clinical and radiographic consequences of differently loaded single-tooth implants have indicated that no significant statistical differences were noted between these protocols [10].

However, a most recent study has examined the histological changes in socket healing in human subjects at various stages [11]. This research only partly corroborates with previous animal studies in terms of histological changes in the postextraction socket, demonstrating that only in the early stages the healing observed in canines was similar to that of humans. This research indicates that, in contrast to what was previously thought, hard tissue formation in humans is slower than that of the canine models, and the rate of new hard tissue formation varies greatly. Furthermore, this research indicated that the timing in which mineralized bone is deposited is not as predictable as originally thought and concluded that by the 24th week following extraction of the tooth, the structural organization of the bone was not completed. In light of these new results, and by applying these findings of socket healing to the healing that takes place following the placement of an implant, and contrarily to what previous studies indicated in relation to different loading protocols, the timing of loading of an implant must be carefully considered, and often a more delayed prosthetic functional loading may be the safer protocol to carry out.

3. Soft Tissue Modeling

There are both anatomic and prosthetic factors that are responsible for a well-accomplished modeling of the soft tissues. Firstly, an adequate blood supply must be present to ensure the responsiveness of the soft tissues to the prosthetic stimuli, followed by accurately connected and positioned abutment, which becomes the foundation for a well-designed provisional prosthetic component.

3.1. Microvascular Function. Earlier studies of the microcirculation in rat subjects [12] have indicated that the mucosal microvasculature gingival tissues adjacent to implants are similar to those of natural teeth. From this it can be deduced that an adequate bloody supply to the peri-implant tissues is necessary for the nutritional requirements of the gingival tissues, just as it is for the gingival tissues around natural teeth (Figure 1).

The maintenance of an adequate blood supply of the peri-implant tissues is an important factor both during the surgical phase by preventing the undesired effects such as the loss of tissues following the surgical procedures and for the nutritional requirements of the tissues during the tissue conditioning stage of the prosthetic phase, either by the healing abutment or by the provisional restoration [13]. A reduced blood supply may be the result of the conventional surgical implant placement protocol or may be caused by increased pressure of the prosthetic components, which may lead to ischemia of the tissues resulting in necrosis or recession of the gingival tissues.

3.2. Abutment Connection and Positioning. Currently, there are many types of abutment connections, depending on the type of final restoration and type of implant. The implant-abutment interface connections can have either internal or external connections, and extensive research of its geometry has been carried out because it is crucial and consequential to prosthetic stability [14]. In addition, particular attention has been given to this region because research has suggested that bacterial colonization and plaque formation, which occur at the microgap of this interface, may cause tissue inflammation and bone resorption in the dog model [15], as a consequence, the concept of platform switching has been proposed to preserve bone around the head of a wide-diameter implant [16].

Another aspect of the abutment connection, which has been studied and thought to have an effect upon the soft tissue architecture, is the repetition of abutment removal and subsequent reconnection. Findings from this research confirmed previous data describing the transmucosal barrier, which is made up by an epithelial and connective tissue layer [17–19]. In addition, it was found that frequent dis- and

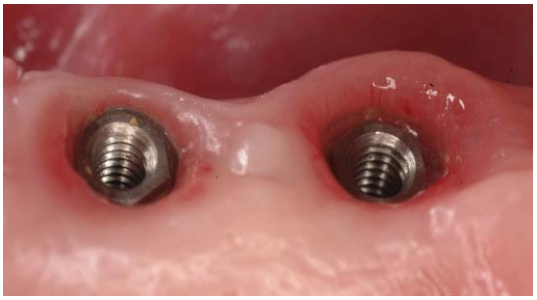

Figure 1: Intraoral view of healthy peri-implant soft tissues, with visible microvessels.

connections of the abutment compromised the integrity of the mucosa and caused tissue reactions which resulted in a more apically placed surface of connective tissue integration and in bone resorption, via mechanical disruption of the established biological width [20].

Subsequently, even the tissue response following the replacement of the healing abutment for a permanent abutment was researched. Results from a study carried out in canine models analyzing the tissue reactions that occurred following the removal of a healing abutment and placement of a permanent abutment indicated that this replacement did not result in further bone loss and thus, a single abutment shift did not jeopardize the mucosal attachment, as the connective tissue attachment to the titanium abutment was reestablished [21].

Although there are different timing protocols for the positioning of abutments, current literature recommends that provisional restorations be fabricated by making silicone matrices from the diagnostic wax ups prior to commencing the surgical procedures which can be relined intraorally and refined in the laboratory [22]. These provisional crowns are usually placed upon temporary abutments and maintained in the tissue conditioning phase.

3.3. Provisional Phase. A thorough understanding of the histological aspects of the healing phase also contributes to the success of the provisional phase, in promoting maintenance of health and soft tissue modeling, through correct contour, marginal fit, and interproximal spacing of the temporary crown [23] to establish the composition of the surface between the prosthetic recipient site and the restorative gingival interface [24]. In addition to this, extensive animal research has been carried out to examine the histological characteristics of soft tissue maturation stage following the placement of implants. Furthermore, it has been determined in the dog model that histological similarities exist between the initial stages of healing after extraction, and healing of soft tissues after placement of an implant. In the postextraction socket, the final stages of healing consist mainly of osteoid formation in the socket with epithelium formation to cover the socket, whereas the final stages of healing of peri-implant soft tissue comprise mainly formation and maturation of epithelial tissue, which take place within 6–8 weeks [25]. Keeping in mind these concepts, guided gingival regeneration can be used in the exposure and healing phase of placement of the healing abutment to develop a correct gingival contour [26].

Buser et al., in 1992 [27], described in the dog model the connective tissue component of the peri-implant tissues as an inflammation-free scar tissue. This indicates that the morphogenesis of these tissues are a dynamic process, which can be guided or modified. Therefore, the selection of an adequately designed provisional restoration in single-implant cases, substantially affects the aesthetic result during this phase of treatment [28].

Although the main goals of the provisional phase remain unchanged, over the years, different variations of techniques using provisional restorations of different materials during the phase of treatment for developing an aesthetic gingival peri-implant contour have been used, including the cervical contouring concept [29].

In our experience, to minimize abutment dis/and reconnection and maximize aesthetic soft tissue modeling, one of the techniques which has been employed for submerged and ideally positioned implants involves the following steps [22, 28–30]: (1) taking the final impression at the uncovering stage with a minimal flap access; (2) casting of the definitive abutment, framework, and provisional crown with anatomical characteristics derived from an ideal wax up; (3) immediate placement of the definitive abutment and provisional crown after 24 hours, allowing the healing of the soft tissue around an ideal profile and form of restoration; (4) when ideal architecture of the soft tissue is obtained, and after the removal of the provisional crown and positioning of the framework, an impression for the soft tissue profile is taken; (5) for the laboratory procedures, by using a silicon index of the initial wax up, the ceramic layering of the framework is realized with the same design as the provisional crown; (6) a final restoration identical to the initial wax up and the definitive crown can be positioned without altering the soft tissue stability enhanced during the healing phase.

4. Soft Tissue Stabilization

As much as all of the abovementioned concepts play a key role in the modeling of the peri-implant gingival tissues, arguably, the most significant incentive to favorable gingival aesthetics is given by an appropriately selected abutment with an anatomically designed final restoration. The significant factors which should generate and contribute to an optimal aesthetic result include the abutment selection, the crown design, and the soft tissue outcome.

4.1. Abutment Selection. The principles and guidelines for complete tooth preparations for fixed prosthesis have been reviewed and discussed in the literature and include the occlusal convergence, occlusocervical dimension, circumferential morphology, finish line location, form and depth, and others. All these principles are thought to produce a tooth preparation which is sound mechanically, biologically, and aesthetically and have been thoroughly discussed [31]. In addition, authors believe that by associating the principles of

ideal tooth preparations with precise tooth form dimensions, exemplary machine-milled abutments can be generated [32].

More specifically to implant supported restorations, however, the most important ideal characteristics for the selection, fabrication, and placement of implant abutments have been described and include an exact interface between the abutment and implant, having the possibility to modify the long axis of the implant with an angled abutment and using an abutment that fits passively with a correct emergence profile and a finishing line that follows the morphology of the peri-implant tissues [30].

Permanent abutment connections can be classified in many ways, because implants have been used in a variety of reconstructive procedures, ranging from single-tooth implant to implant retained full prosthesis, and to be able to handle different clinical situations [14]. Whichever the type of abutment that is used, the fabrication techniques used to date are stock abutments which can be modified in the chair, cast-metal abutments, and CADCAM-milled abutments.

Though ideal aesthetics of implant therapy begin with correctly placed and positioned implants: however, implants with jeopardized positions should be rectified with modified abutments [33]. Recently, these different abutment-fabrication methods have been compared to identify the most advantageous method of fabrication. From the literature, advantages of using modified or customized abutments over stock abutments have been reported [34].

To further classify and identify the best characteristics of customized abutments, the techniques used for customized abutment fabrication are classified into a casting of the wax pattern, into ceramic or gold abutments, machine-milled titanium abutments, or customizable prefabricated titanium abutments [32]. Some of the advantages of customized abutments include changes in direction and position of the axis of the final restoration and modification of the form, diameter and gingival margin position, which induce better aesthetics.

As well as differentiating between differently designed abutments, several authors have studied the effects on soft tissue by using implant components of different materials. Other than the original titanium components, the other materials which have been studied extensively include zirconia and a gold alloy. In vitro studies analyzing the biological properties of zirconia have indicated that it has low cytotoxic properties and strongly induces adhesion of fibroblasts to its surface, by increasing the cellular growth rate, as compared to feldspathic ceramics [35]. Other clinical data published to date suggest that restorations made of zirconium oxide are adequately tolerated and resistant [36], resulting in favourable mucosal conditions and marginal bone levels [37].

An animal study indicates that the soft tissue healing of both titanium and zirconia abutments remain, stable between 2 and 5 months, whereas a gold/palladium alloy abutments showed signs of "apical shift of the barrier epithelium and marginal bone between 2 and 5 months of healing," which may result from lower amounts of collagen and fibroblast and greater amounts of leukocytes than in titanium and zirconia abutments [38]. These results are in contrast with a recent systematic review of the literature that has analyzed the difference in peri-implant stability of titanium abutments, compared with gold, aluminum, and zirconium oxide [39]. The conclusions collected by the authors indicate that there is no evidence to prove that titanium abutments perform better in terms of maintaining an unaltered tissue condition as compared to the other materials. Another randomized controlled clinical study comparing the technical and biological characteristics of titanium and zirconia abutments such as probing pocket depths, plaque control records, bleeding on probing, bone level measurements, and difference in colour of the periodontal tissues at 6, 12, and 36 months found that both materials exhibited similar properties [40].

Another animal study found similar bone and soft tissue dimensions when using either titanium or gold transmucosal parts. It is thought that these differences may be due to different methodologies. This study seems to confirm other previous studies in demonstrating that the attachment and proliferation of the epithelial cells in the metallic surfaces are favourable especially on smooth surfaces [41].

Another characteristic of the abutment which has been recently analyzed is the surface topography and results from this systematic review indicate that rougher surfaces promote the formation of plaque [42].

5. Conclusions

Considering the increase in demand for better aesthetics in recent years, there has been a change in the treatment planning and execution of the clinical and laboratory procedures of implant-supported restorations. The realization requires collaboration between operators, including the surgeon, the prosthodontist, and the dental technician, to obtain a predictable, satisfactory and maintainable aesthetic result. From a prosthetic aspect, the optimization of the SHTM requires an accurate planning of prosthetic paradigms: an adequate timing of loading, and the selection of an ideal abutment that is capable of guiding the remodeling of the soft tissues during the provisional phase, allowing a thorough stabilization and integration of the definitive restoration with the remaining natural dentition.

References

[1] T. Albrektsson, P. I. Branemark, H. A. Hansson, and J. Lindstrom, "Osseointegrated titanium implants. Requirements for ensuring a long-lasting, direct bone-to-implant anchorage in man," *Acta Orthopaedica Scandinavica*, vol. 52, no. 2, pp. 155–170, 1981.

[2] L. Sennerby and J. Roos, "Surgical determinants of clinical success of osseointegrated oral implants: a review of the literature," *International Journal of Prosthodontics*, vol. 11, no. 5, pp. 408–420, 1998.

[3] P. A. Schnitman, P. S. Wohrle, and J. E. Rubenstein, "Immediate fixed interim prostheses supported by two-stage threaded implants: methodology and results," *Journal of Oral Implantology*, vol. 16, no. 2, pp. 96–105, 1990.

[4] G. O. Gallucci, A. Mavropoulos, J. P. Bernard, and U. C. Belser, "Influence of immediate implant loading on peri-implant soft tissue morphology in the edentulous maxilla," *International*

Journal of Oral and Maxillofacial Implants, vol. 22, no. 4, pp. 595–602, 2007.

[5] E. De Smet, J. Duyck, J. V. Sloten, R. Jacobs, and I. Naert, "Tim-ing of loading-immediate, early, or delayed-in the outcome of implants in the edentulous mandible: a prospective clinical trial," *International Journal of Oral and Maxillofacial Implants*, vol. 22, no. 4, pp. 580–594, 2007.

[6] J. A. G. Hall, A. G. T. Payne, D. G. Purton, and B. Torr, "A randomized controlled clinical trial of conventional and immediately loaded tapered implants with screw-retained crowns," *International Journal of Prosthodontics*, vol. 19, no. 1, pp. 17–19, 2006.

[7] M. Esposito, M. G. Grusovin, M. Willings, P. Coulthard, and H. V. Worthington, "The effectiveness of immediate, early, and conventional loading of dental implants: a cochrane systematic review of randomized controlled clinical trials," *International Journal of Oral and Maxillofacial Implants*, vol. 22, no. 6, pp. 893–904, 2007.

[8] T. De Rouck, K. Collys, and J. Cosyn, "Immediate single-tooth implants in the anterior maxilla: a 1-year case cohort study on hard and soft tissue response," *Journal of Clinical Periodontology*, vol. 35, no. 7, pp. 649–657, 2008.

[9] R. K. Schenk and D. Buser, "Osseointegration: a reality," *Periodontology*, vol. 17, no. 1, pp. 22–35, 1998.

[10] P. Quinlan, P. Nummikoski, R. Schenk et al., "Immediate and early loading of SLA ITI single-tooth implants: an in vivo study," *International Journal of Oral and Maxillofacial Implants*, vol. 20, no. 3, pp. 360–370, 2005.

[11] L. Trombelli, R. Farina, A. Marzola, L. Bozzi, B. Liljenberg, and J. Lindhe, "Modeling and remodeling of human extraction sockets," *Journal of Clinical Periodontology*, vol. 35, no. 7, pp. 630–639, 2008.

[12] N. J. Selliseth and K. A. Selvig, "Microvascular adaptation to transmucosal implants. A scanning electron microscopic study in the rat," *Clinical Oral Implants Research*, vol. 6, no. 4, pp. 205–212, 1995.

[13] P. V. Goldberg, F. L. Higginbottom, and T. G. Wilson, "Periodontal considerations in restorative and implant therapy," *Periodontology*, vol. 25, no. 1, pp. 100–109, 2001.

[14] P. P. Binon, "Implants and Components: entering the New Millennium," *International Journal of Oral and Maxillofacial Implants*, vol. 15, no. 1, pp. 76–94, 2000.

[15] J. S. Hermann, J. D. Schoolfied, R. K. Schenk, D. Buser, and D. L. Cochran, "Influence of the size of the microgap on crestal bone changes around titanium implants. A histometric evaluation of unloaded non-submerged implants in the canine mandible," *Journal of Periodontology*, vol. 72, no. 10, pp. 1372–1383, 2001.

[16] R. J. Lazzara and S. S. Porter, "Platform switching: a new concept in implant dentistry for controlling postrestorative crestal bone levels," *International Journal of Periodontics and Restorative Dentistry*, vol. 26, no. 1, pp. 9–17, 2006.

[17] M. Nevins, D. M. Kim, S. H. Jun, K. Guze, P. Schupbach, and M. L. Nevins, "Histologic evidence of a connective tissue attachment to laser microgrooved abutments: a canine study," *The International Journal of Periodontics & Restorative Dentistry*, vol. 30, no. 3, pp. 245–255, 2010.

[18] M. Degidi, A. Piattelli, A. Scarano, J. A. Shibli, and G. Iezzi, "Peri-implant collagen fibers around human cone Morse connection implants under polarized light: a report of three cases," *International Journal of Periodontics and Restorative Dentistry*, vol. 32, pp. 323–328, 2012.

[19] D. Farronato, G. Santoro, L. Canullo, D. Botticelli, C. Maiorana, and N. P. Lang, "Establishment of the epithelial attachment and connective tissue adaptation to implants installed under the concept of "platform switching": a histologic study in minipigs," *Clinical Oral Implants Research*, 2011.

[20] I. Abrahamsson, "The mucosal barrier following abutment dis/reconnection an experimental study in dogs," *Journal of Clinical Periodontology*, vol. 24, no. 8, pp. 568–572, 1997.

[21] I. Abrahamsson, T. Berglundh, S. Sekino, and J. Lindhe, "Tissue reactions to abutment shift: an experimental study in dogs," *Clinical Implant Dentistry and Related Research*, vol. 5, no. 2, pp. 82–88, 2003.

[22] I. Gamborena and M. Blatz, "Current clinical and technical protocols for single-tooth immediate implant procedures," in *Quintessence of Dental Technology*, vol. 31, Quintessence, 2008.

[23] S. Holst, M. B. Blatz, E. Hegenbarth, M. Wichmann, and S. Eitner, "Prosthodontic considerations for predictable single-implant esthetics in the anterior maxilla," *Journal of Oral and Maxillofacial Surgery*, vol. 63, no. 9, pp. 89–96, 2005.

[24] D. A. Garber and U. C. Belser, "Restoration-driven implant placement with restoration-generated site development," *Compendium of Continuing Education in Dentistry*, vol. 16, no. 8, pp. 796–804, 1995.

[25] T. Berglundh, I. Abrahamsson, M. Welander, N. P. Lang, and J. Lindhe, "Morphogenesis of the peri-implant mucosa: an experimental study in dogs," *Clinical Oral Implants Research*, vol. 18, no. 1, pp. 1–8, 2007.

[26] H. Salama, M. A. Salama, T. F. Li, D. A. Garber, and P. Adar, "Treatment planning 2000: an esthetically oriented revision of the original implant protocol," *Journal of Esthetic Dentistry*, vol. 9, no. 2, pp. 55–67, 1997.

[27] D. Buser, H. P. Weber, K. Donath, J. P. Fiorellini, D. W. Paquette, and R. C. Williams, "Soft tissue reactions to non-submerged unloaded titanium implants in beagle dogs," *Journal of Periodontology*, vol. 63, no. 3, pp. 225–235, 1992.

[28] G. Priest, "Esthetic potential of single-implant provisional restorations: selection criteria of available alternatives," *Journal of Esthetic and Restorative Dentistry*, vol. 18, no. 6, pp. 326–339, 2006.

[29] N. Bichacho and C. J. Landsberg, "Single implant restorations: prosthetically induced soft tissue topography," *Practical Periodontics and Aesthetic Dentistry*, vol. 9, no. 7, pp. 745–754, 1997.

[30] G. Calesini, G. B. Bruschi, A. Scipioni, C. Micarelli, and A. Di Felice, "Abutments modificati anatomicamente (A.M.A.). Una tecnica originale per lo sviluppo razionale della morfologia coronale in protesi ancorata ad impianti osteointegrati," *Quint Int*, no. 5-6, pp. 169–175, 1997.

[31] C. J. Goodacre, W. V. Campagni, and S. A. Aquilino, "Tooth preparations for complete crowns: an art form based on scientific principles," *Journal of Prosthetic Dentistry*, vol. 85, no. 4, pp. 363–376, 2001.

[32] R. B. Kerstein, F. Castellucci, and J. Osorio, "Ideal gingival form with computer-generated permanent healing abutments," *Compendium of Continuing Education in Dentistry*, vol. 21, no. 10, pp. 793–800, 2000.

[33] C. E. Rieder, "Customized implant abutment copings to achieve biologic, mechanical, and esthetic objectives," *International Journal of Periodontics and Restorative Dentistry*, vol. 16, no. 1, pp. 21–29, 1996.

[34] G. Priest, "Virtual-designed and computer-milled implant abutments," *Journal of Oral and Maxillofacial Surgery*, vol. 63, no. 9, pp. 22–32, 2005.

[35] L. Raffaelli, P. R. Iommetti, E. Piccioni et al., "Growth, viability, adhesion potential, and fibronectin expression in fibroblasts cultured on zirconia or feldspatic ceramics in vitro," *Journal of Biomedical Materials Research A*, vol. 86, no. 4, pp. 959–968, 2008.

[36] P. F. Manicone, P. Rossi Iommetti, and L. Raffaelli, "An overview of zirconia ceramics: basic properties and clinical applications," *Journal of Dentistry*, vol. 35, no. 11, pp. 819–826, 2007.

[37] R. Glauser, I. Sailer, A. Wohlwend, S. Studer, M. Schibli, and P. Schärer, "Experimental zirconia abutments for implant-supported single-tooth restorations in esthetically demanding regions: 4-Year results of a prospective clinical study," *International Journal of Prosthodontics*, vol. 17, no. 3, pp. 285–290, 2004.

[38] M. Welander, I. Abrahamsson, and T. Berglundh, "The mucosal barrier at implant abutments of different materials," *Clinical Oral Implants Research*, vol. 19, no. 7, pp. 635–641, 2008.

[39] T. Linkevicius and P. Apse, "Influence of abutment material on stability of peri-implant tissues: a systematic review," *International Journal of Oral and Maxillofacial Implants*, vol. 23, no. 3, pp. 449–456, 2008.

[40] A. Zembic, I. Sailer, R. E. Jung, and C. H. F. Hämmerle, "Randomized-controlled clinical trial of customized zirconia and titanium implant abutments for single-tooth implants in canine and posterior regions: 3-year results," *Clinical Oral Implants Research*, vol. 20, no. 8, pp. 802–808, 2009.

[41] I. Abrahamsson and G. Cardaropoli, "Peri-implant hard and soft tissue integration to dental implants made of titanium and gold," *Clinical Oral Implants Research*, vol. 18, no. 3, pp. 269–274, 2007.

[42] W. Teughels, N. Van Assche, I. Sliepen, and M. Quirynen, "Effect of material characteristics and/or surface topography on biofilm development," *Clinical Oral Implants Research*, vol. 17, no. 2, pp. 68–81, 2006.

Hindawi Publishing Corporation
International Journal of Biomaterials
Volume 2012, Article ID 615018, 7 pages
doi:10.1155/2012/615018

Research Article

Assessment of the Quality of Newly Formed Bone around Titanium Alloy Implants by Using X-Ray Photoelectron Spectroscopy

Hiroshi Nakada,[1,2] Toshiro Sakae,[2,3] Yasuhiro Tanimoto,[2,4] Mari Teranishi,[5] Takao Kato,[2,5] Takehiro Watanabe,[1] Hiroyuki Saeki,[1] Yasuhiko Kawai,[1,2] and Racquel Z. LeGeros[6]

[1] *Department of Removable Prosthodontics, Nihon University School of Dentistry at Matsudo, 2-870-1 Sakaecho-Nishi Matsudo City, Chiba 271-8587, Japan*
[2] *Research Institute of Oral Science, Nihon University School of Dentistry at Matsudo, 2-870-1 Sakaecho-Nishi Matsudo City, Chiba 271-8587, Japan*
[3] *Department of Histology, Nihon University School of Dentistry at Matsudo, 2-870-1 Sakaecho-Nishi Matsudo City, Chiba 271-8587, Japan*
[4] *Department of Dental Biomaterials, Nihon University School of Dentistry at Matsudo, 2-870-1 Sakaecho-Nishi Matsudo City, Chiba 271-8587, Japan*
[5] *Department of Oral Implantology, Nihon University School of Dentistry at Matsudo, 2-870-1 Sakaecho-Nishi Matsudo City, Chiba 271-8587, Japan*
[6] *Department of Biomaterials and Biomimetics, New York University College of Dentistry, 345 East 24th Street, New York, NY 10010, USA*

Correspondence should be addressed to Hiroshi Nakada, nakada.hiroshi@nihon-u.ac.jp

Received 7 December 2011; Accepted 29 February 2012

Academic Editor: Yo Shibata

Copyright © 2012 Hiroshi Nakada et al. This is an open access article distributed under the Creative Commons Attribution License, which permits unrestricted use, distribution, and reproduction in any medium, provided the original work is properly cited.

The aim of this study was to evaluate differences in bones quality between newly formed bone and cortical bone formed around titanium alloy implants by using X-ray photoelectron spectroscopy. As a result of narrow scan measurement at 4 weeks, the newly formed bone of C1s, P2p, O1s, and Ca2p were observed at a different peak range and strength compared with a cortical bone. At 8 weeks, the peak range and strength of newly formed bone were similar to those of cortical bone at C1s, P2p, and Ca2p, but not O1s. The results from this analysis indicate that the peaks and quantities of each element of newly formed bone were similar to those of cortical bone at 8 weeks, suggestive of a strong physicochemical resemblance.

1. Introduction

Dental implantation is a treatment method in which fixtures are implanted in the jawbone, followed by prosthetic implantation after a resting period of approximately 3–6 months, at which time new bone is formed around the fixtures [1]. This process sets the cortical bone as the primary anchorage unit. Bone modeling and remodeling processes are important (1) to induce long-term stability of the implants; (2) to develop osseointegration between implant materials and the bone; (3) to allow the maturation of new bone around the implants. It has been reported that the maximum occlusal force in adults with a natural dentition is 430 N [2], and similar loads are likely to be applied to implants as well as normal prostheses. Therefore, to achieve long-term retention and stability of implants under such conditions, the quality of newly formed bone around implants is important.

Many studies have reported that newly formed bone around implants is spongy bone [3]. However, although the morphology of newly formed bone is reportedly like spongy bone, it is difficult to discriminate whether the bone quality is mature like cortical bone, or immature like spongy, osteoid,

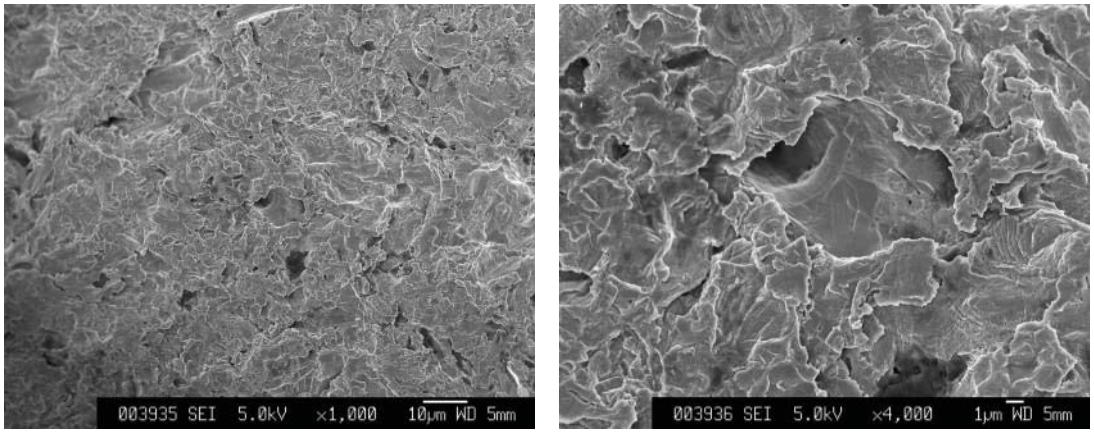

(a) (b)

Figure 1: Scanning electron microscope photographs of implant surface at (a) low magnification and (b) high magnification.

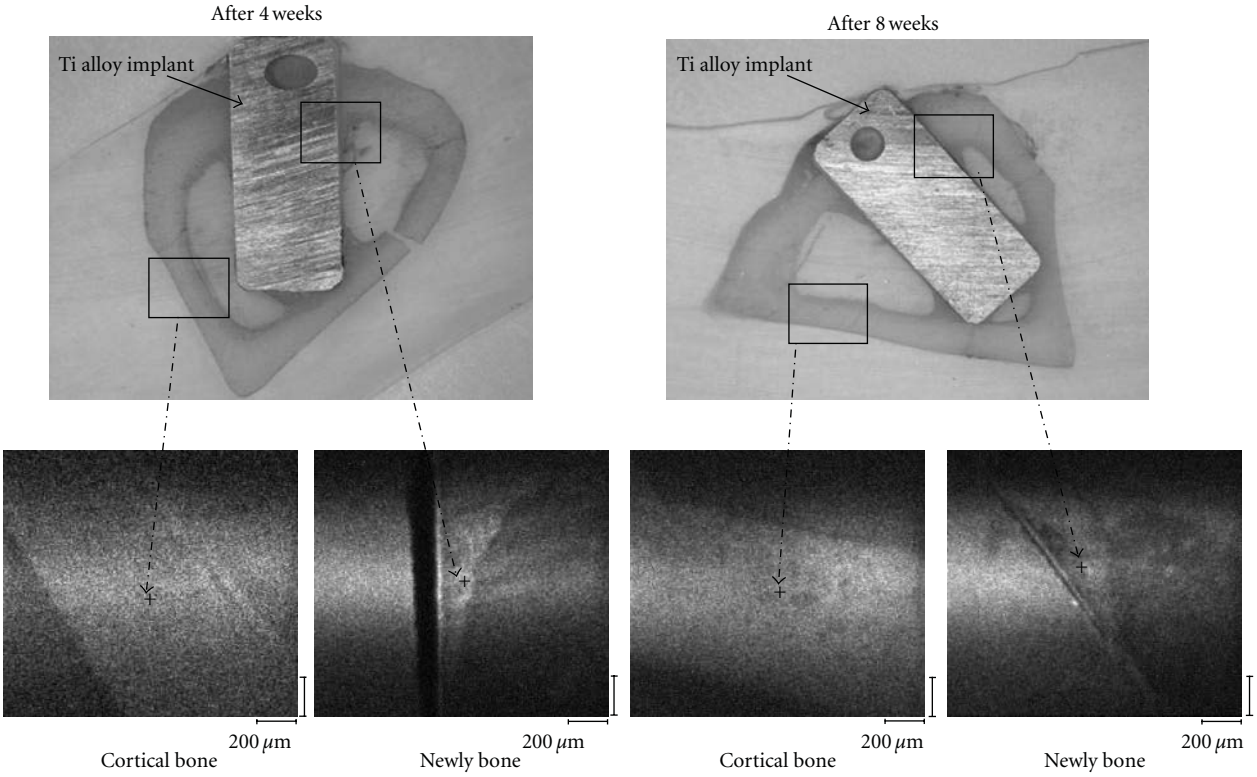

Figure 2: Measurement areas for XPS analysis (upper: thin section specimens; lower: enlarged images; +: measurement areas). Newly bone: newly formed bone.

or cartilaginous bone; therefore, evaluation of the bone quality is required.

The quality of bone forming around implants has been investigated by various groups. Nakano et al. [4] evaluated bone density and alignment of biological apatite (BAp), and Boskey and Pleshko [5] used Fourier-transform infrared (FTIR) imaging to assess bone and cartilage quality and composition. In addition, our group has reported on the use of polarized microscopy [6] and scanning electron microscopy (SEM) [7] to evaluate new bone and cortical bone quality, as well as microscopic Raman spectroscopy to analyze phosphate peaks of bone apatite [6], and microcomputed tomography (micro-CT) to assess trabecular microarchitecture and bone mineral density (BMD) [8–10]. However, basic research on new bone formation has been sparse, and molecular and elemental characterization of BAp, the basic building block of bone, has generally been overlooked. Moreover, responses to early dynamic loading in implants,

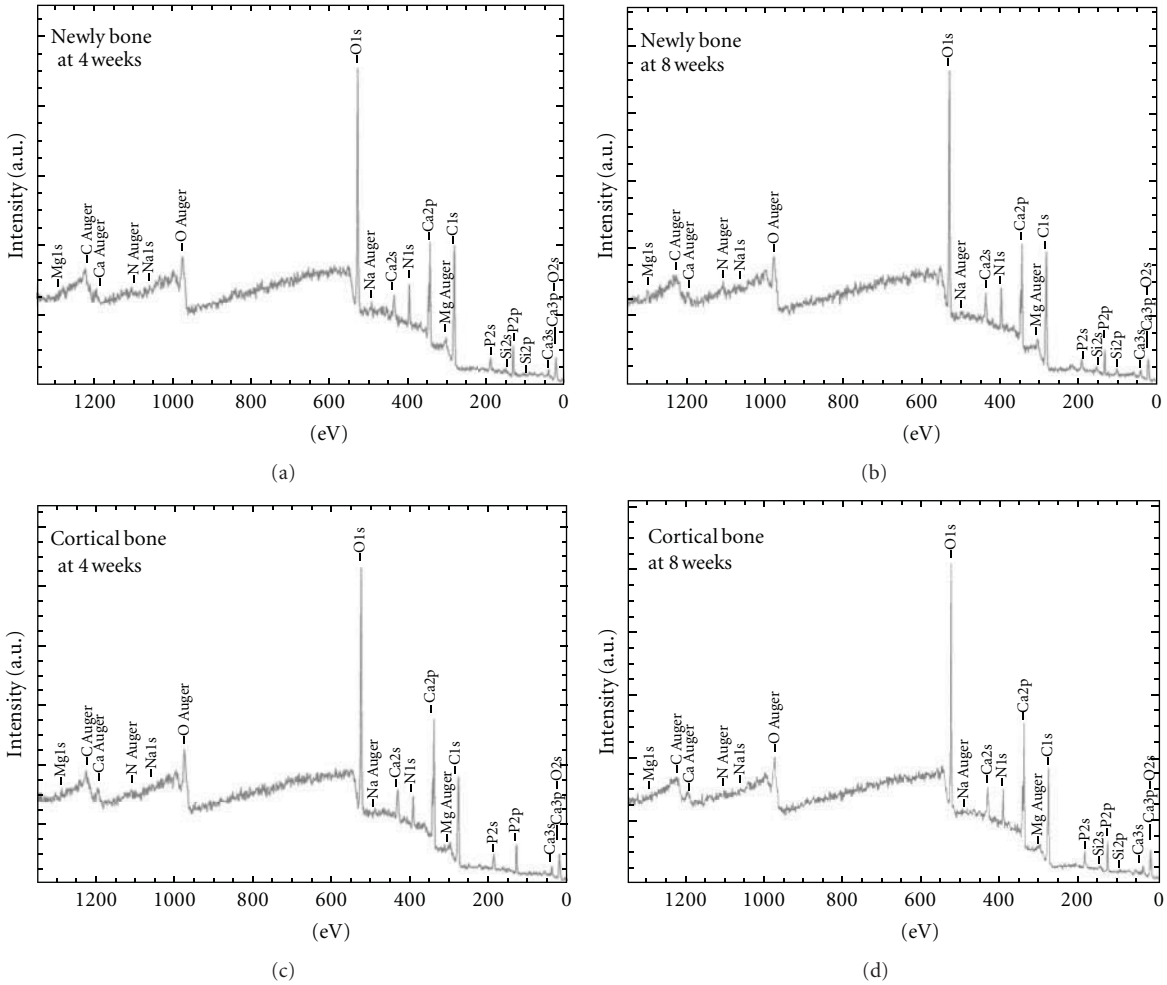

Figure 3: Wide scan peaks of each element at 4 and 8 weeks. Newly bone: newly formed bone.

with analysis of changes in new bone quality associated with mineralization, remain an important issue for further research.

In this study, differences in the bone quality between newly formed bone and cortical bone formed around titanium (Ti) alloy implants were investigated using X-ray photoelectron spectroscopy (XPS).

2. Materials and Methods

2.1. Experimental Animals. Six 18-week-old New Zealand White Rabbits (Sankyo Labo Service Co., Tokyo, Japan) were used in experiments. The rabbits were housed in individual metal cages at a room temperature of 23 ± 1°C and humidity of 50 ± 1%, with ad libitum access to food and water. The experimental protocol was approved by an animal experimentation ethics committee (approval number ECA 07-0016). All experiments were conducted according to the Guidelines for the Treatment of Animals, Nihon University, Chiba, Japan.

2.2. Materials. Implants (diameter, 3.0 mm; length, 7.0 mm) were fabricated using Ti-15%Zr-4%Nb-4%Ta (Ti-15-4-4) alloy [11–15] (Table 1 displays its chemical composition). Surface treatment of implants consisted of sulfuric acid-etching and grit-blasting with apatitic abrasive (particle size 250 μm, HiMed Co., NY, USA) (Figure 1).

2.3. Implantation. Rabbits underwent general anesthesia with 2.0 mg/kg of intravenous Ketalar (Daiichi Sankyo, Tokyo, Japan). Implant cavities were surgically created in the tibia 10 mm distal to the knee joint, one each bilaterally, by using a 1.0 mm and 3.0 mm diameter round bar, while irrigating the area with sterile saline. Implants were inserted into the right tibia, with each rabbit receiving one implant (8 implants were used in total). After surgery, the areas were disinfected with tincture of iodine for 3 days. Rabbits were sacrificed by anesthesia overdose at 4 or 8 weeks after-implantation, and the tibias were resected.

2.4. XPS Analysis. For XPS analysis, newly formed bone in close proximity to implants and cortical bone (control) which not in close proximity to implants were analyzed using thin-cut nondecalcified histological specimens. Since both bone resorption by osteoclasts and bone formation by

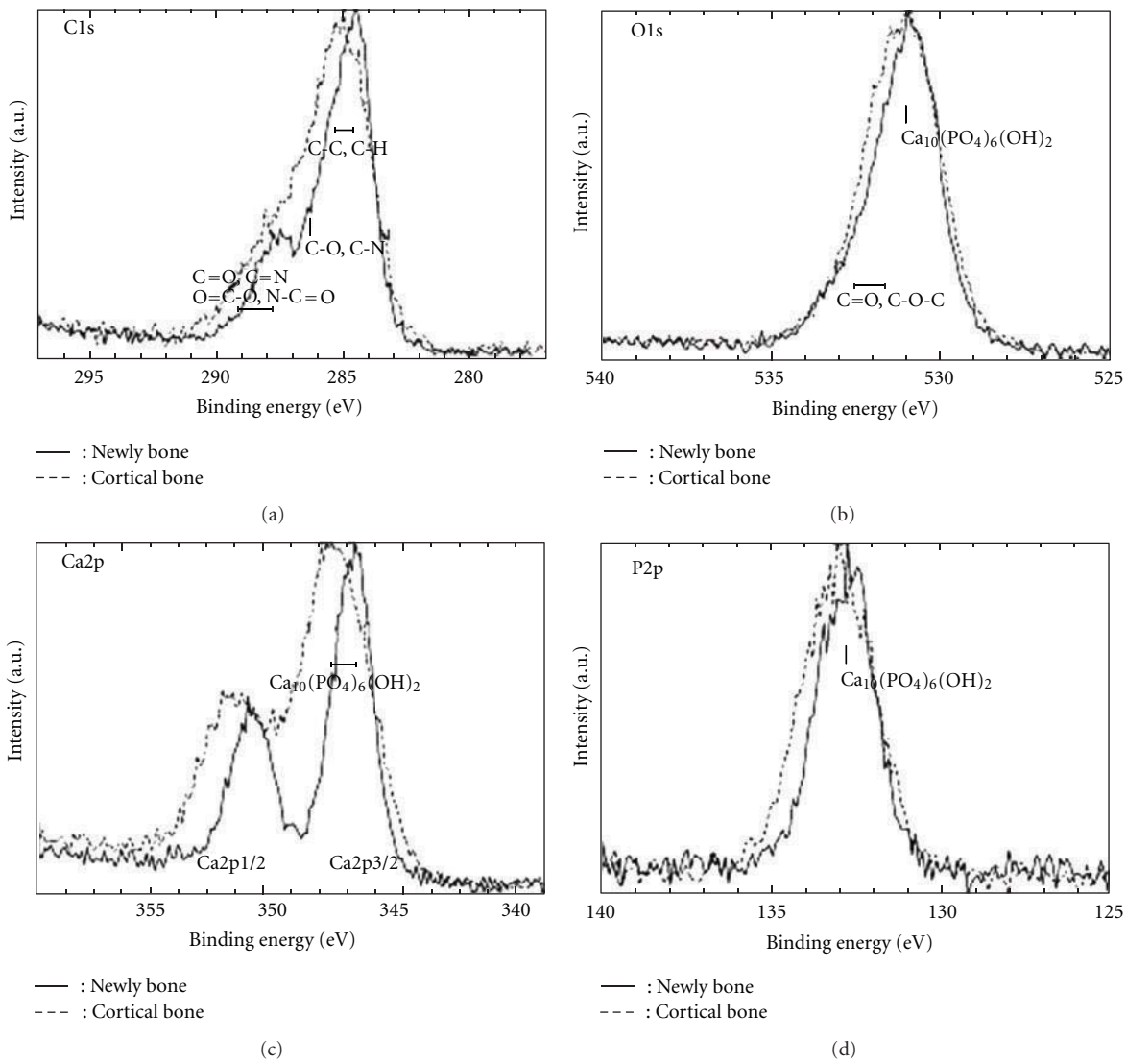

Figure 4: Narrow scan peaks of each element at 4 weeks. Newly bone: newly formed bone.

Table 1: Chemical composition (mass %) of the Ti-15-4-4 alloy used in the present study.

Titanium alloy	(mass %)									
	Zr	Nb	Ta	Pd	Fe	O	N	H	C	Ti
Ti-15-4-4	15.24	3.90	3.92	0.22	0.022	0.162	0.048	0.011	0.002	Bal.**

** Bal.: balance.

osteoblasts progress concurrently, differences in measurement of bone tissue results are apt to occur; therefore, it is difficult to specify the measurement area. In the present study, more than 3 areas of newly formed bone close to implants and those of cortical bone were measured, and sites within which appropriate average values were obtained were determined as the measurement areas (Figure 2). An XPS analysis was performed under the following conditions: X-ray source: monochromatic AlKα (1,486.6 eV), detection region: 20 μmθ, and detection depth: approximately 4-5 nm (take-off angle: 45°).

Qualitative analysis was performed using wide scan measurement, and the chemical bonding conditions of detected elements were analyzed using narrow scan measurement. Hydroxyapatite powders were used as the standard specimens, followed by performance of measurements with a correction for relative sensitivity factors (RSFs).

3. Results

Qualitative analysis of the peak strengths on newly formed bone around implants and cortical bone at 4 and 8 weeks is

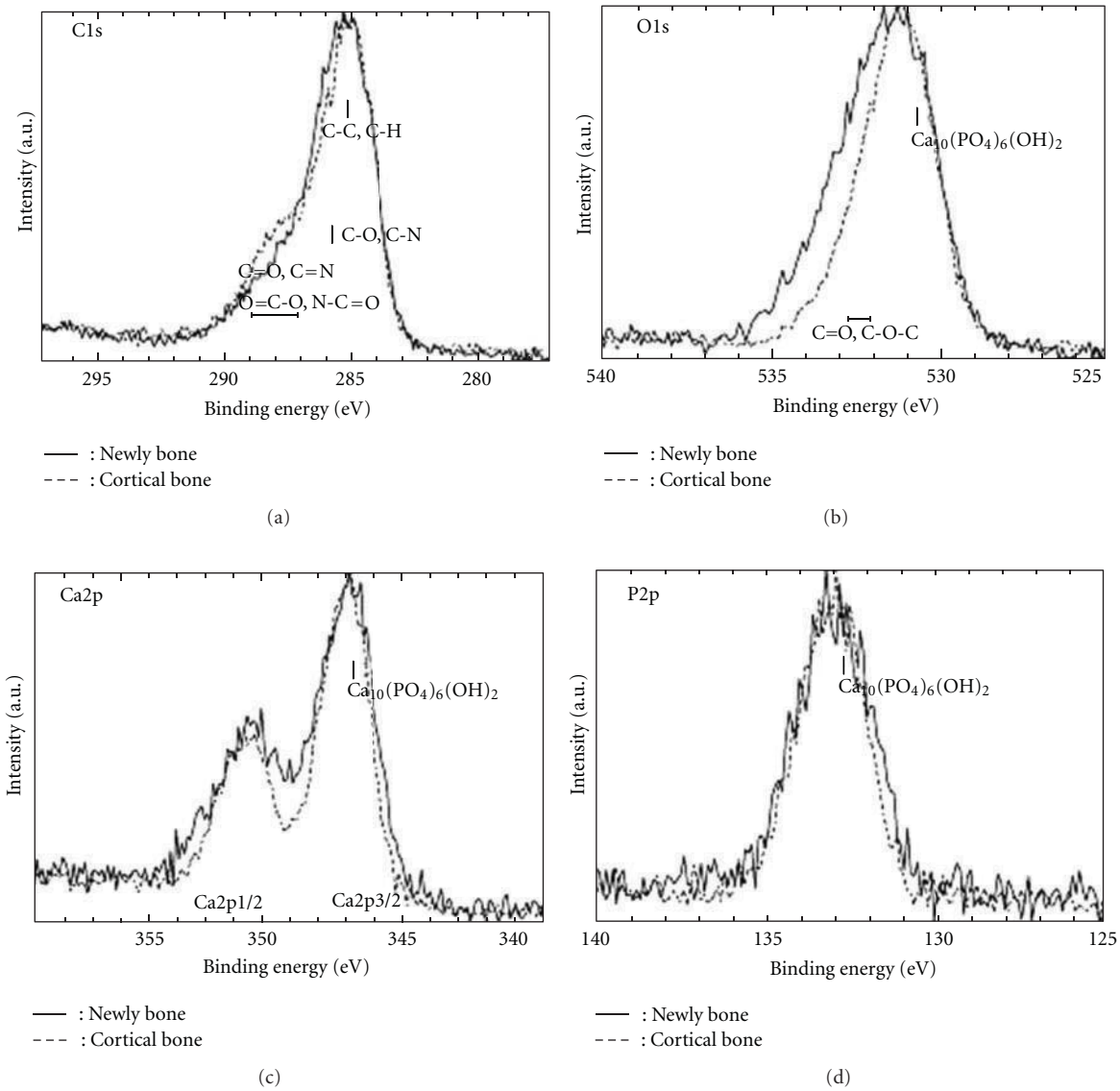

Figure 5: Narrow scan peaks of each element at 8 weeks. Newly bone: newly formed bone.

shown in Figure 3. Although peaks of Ca, O, P, C, Mg, N, and Na were detected, a marked unevenness in these peaks was observed at 4 weeks, in contrast to 8 weeks. Based on the results of wide scan measurement, narrow scan measurement of elements related to $Ca_{10}(PO_4)_6OH_2$ was performed. The resulting overlap of C1s, O1s, Ca2p, and P2p of newly formed and cortical bone at 4 weeks is shown in Figures 3 and 4, respectively; the results at 8 weeks are shown in Figure 5.

The results of narrow scan measurement at 4 weeks (Figure 4) indicate that, although the peak strengths of newly formed and cortical bone were almost equal at O1s, the half-width became smaller in newly formed bone. At P2p and C1s, although a shifting of the peak in newly formed bone was observed, the half-width became smaller in newly formed bone; the peak strength of newly formed bone at C1s were lower than that of cortical bone. At Ca2p (Ca2p 3/2), although the peak strengths of newly formed bone was lower than that of cortical bone, the half-width became smaller in newly formed bone, and a shifting of the peak was observed. The chemical bonding condition observed for each element in newly formed bone differed from that of cortical bone.

As a result of narrow scan measurement at 8 weeks (Figure 5), the half-width and strength of newly formed bone were almost equal to those of cortical bone at C1s, P2p, and Ca2p. At O1s, the half-width became small in newly formed bone, and a shifting of the peak was observed. The chemical bonding condition observed for each element of newly formed bone was similar to that of cortical bone.

Table 2 shows the results of the quantitative analysis of each element and the Ca/P ratio. The results for newly formed bone were Ca: 15.07 ± 2.83 weight percent and P: 7.83 ± 1.56 weight percent at 4 weeks; Ca: 17.33 ± 2.393 weight percent and P: 8.90 ± 0.80 weight percent at 8 weeks. These values gradually became similar to those of cortical

Table 2: Results of the quantitative analysis of newly formed bone around implants at 4 and 8 weeks, and cortical bone. Newly bone: newly formed bone.

	(Weight %)		
	Ca	P	Ca/P
4 weeks newly bone	15.07 ± 2.83	7.83 ± 1.56	1.93 ± 0.10
4 weeks cortical bone	19.77 ± 1.65	10.27 ± 1.05	1.93 ± 0.07
8 weeks newly bone	17.33 ± 2.39	8.90 ± 0.80	1.94 ± 0.10
8 weeks cortical bone	21.33 ± 1.88	11.03 ± 0.70	1.93 ± 0.05

Table 3: Main chemical bonding of each element and peak position (eV).

Peak	Binding energy (eV)	Peak position
O1s	Metal—O	530-531
	Metal—PO*x*, −OH	531-532
	C=O, C–O–C	532-533
C1s	C–C, C–H	284.8
	C–O, C–N	286
	C=O	287-288
	O=C–O	289
Ca2p 3/2	Ca	346
	CaO	346-347
	Ca_{10} $(PO_4)_6$ $(OH)_2$	346-347
P2p	Metal—P	129
	Metal—PO*x*	133.5
	P_2O_5	135
	Ca_{10} $(PO_4)_6$ $(OH)_2$	133–133.5
Nls	C–N, C=N, N–H	398.5–401
	Metal–N	396–398
	NO	401–403
Si2p	Si	99.4
	SiO*x*, SiOC	101–103
	SiO_2	103–103.6

bone at 4 weeks (Ca: 17.33 ± 2.39 weight percent and P: 8.90 ± 0.80 weight percent) and at 8 weeks (Ca: 21.33 ± 1.88 weight percent and P: 11.03 ± 0.70 weight percent).

4. Discussion

The use of XPS analysis in the present experiment has been employed in industry since the 1960s and is now being clinically applied to the qualitative analysis of several nanometer-sized areas on material surfaces. Elemental analysis showed complex spectra based on chemical bond arrangement and elemental compositional changes. Changes in spectra reveal alterations in chemical bonds based on changes in interatomic transition and valence-band state density.

In the present study, newly formed bone at 4 weeks showed differences in the Ca/P ratio (Table 2), and in peak position, peak height, and half-width on the narrow scan measurement of each element (Figures 4 and 5). Many mineral elements were present in newly formed bone at 4 weeks, suggesting that the arrangement of chemical bonding and element composition in newly formed bone differed from those in cortical bone. Furthermore, the peak position, peak height, and half-width on narrow scan measurement at 8 weeks in newly formed and cortical bone showed similar traces, and the quantitative analysis of new and cortical bone at 8 weeks (Table 2) showed similar results. These results suggest that newly formed bone at 8 weeks showed a similar bone quality to that of cortical bone, due to progressive bone maturation and bone metabolism of minerals.

Each element showed a complex spectrum with changes in the arrangement of chemical bonding regarding the peak and element composition. The spectrum is related to changes in the chemical bonding of elements caused by interatomic transition and changes in the density or state of the valence band. Under the atomic arrangement of BAp crystals in immature new bone, various minor and trace elements, including CO_3^{2-}, Na^+, and Mg^{2+}, were substituted for Ca^{2+}, PO_4^{3-}, and OH^-. Such substitutions have been shown to affect the properties of BAp crystals [16]. For example, substitution of CO_3^{2-} for PO_4^{3-} in the apatite lattice can cause changes in chemical bonding that leads to strain and reduced crystallite size in BAp [16, 17]. Such changes in chemical bonds can result in changes in binding energy in the magnitude of several electron volts (eV). In chemical bonds, trace element peaks shift to higher energy as differences in the electronegativity of bond-forming elements and the electron valence of elements increase. Peak shifts are easily influenced by the surrounding molecular environment, and peak shift and half-width variations signify the presence of compounds with different molecular weights and atomic arrangement. The peak value in a chemical bond is clear with many reports [18–21]. The main combined states of each element and a corresponding peak are shown in Table 3.

In the present study, differences were observed in XPS spectra between new bone at 4 weeks postimplantation and cortical bone, indicating immature bone quality due to BAp imperfection. In the chemical bonds of each spectrum, changes in the order of 0.1 eV affected BAp crystallinity [22].

The XPS spectra of new bone at 8 weeks postimplantation resembled those of cortical bone, and quantitative analysis showed higher Ca and P in newly formed bone compared to 4 weeks. This indicated that the composition of newly formed bone was closer to that of cortical bone at 8 weeks.

Osseointegration around implants occurs as mineralization progresses, involving the accumulation of mineral components or BAp nanocrystals [23]. However, the present study was unable to analyze in detail the chemical bonding present in BAp nanocrystals, a subject for future analysis.

Acknowledgments

This study was supported in part by Grants-in-Aid for Scientific Young Scientists (B) (22791942 and 23792297) and a Grant for Supporting Project for Strategic Research (S0801032) 2008–2012 from The Ministry of Education, Culture, Sports, Science and Technology, Japan.

References

[1] P. I. Branemark, "Osseointegration and its experimental background," *The Journal of Prosthetic Dentistry*, vol. 50, no. 3, pp. 399–410, 1983.

[2] A. Van Der Bilt, A. Tekamp, H. Van Der Glas, and J. Abbink, "Bite force and electromyograpy during maximum unilateral and bilateral clenching," *European Journal of Oral Sciences*, vol. 116, no. 3, pp. 217–222, 2008.

[3] T. Albrektsson, "Direct bone anchorage of dental implants," *The Journal of Prosthetic Dentistry*, vol. 50, no. 2, pp. 255–261, 1983.

[4] T. Nakano, K. Kaibara, Y. Tabata et al., "Unique alignment and texture of biological apatite crystallites in typical calcified tissues analyzed by microbeam X-ray diffractometer system," *Bone*, vol. 31, no. 4, pp. 479–487, 2002.

[5] A. Boskey and N. Pleshko Camacho, "FT-IR imaging of native and tissue-engineered bone and cartilage," *Biomaterials*, vol. 28, no. 15, pp. 2465–2478, 2007.

[6] Y. Numata, H. Nakada, T. Sakae et al., "Assessments of the new bone quality around implants using microscopic FTIR and polarizing microscope," *Journal of Hard Tissue Biology*, vol. 17, no. 3, pp. 131–140, 2008.

[7] H. Nakada, T. Sakae, R. Z. Legeros et al., "Early tissue response to modified implant surfaces using back scattered imaging," *Implant Dentistry*, vol. 16, no. 3, pp. 281–289, 2007.

[8] H. Nakada, T. Suwa, Y. Numata et al., "Analysis of bone mineral density and bone area of newly formed bone around implants using micro-CT after pull-out tests," *International Journal of Oral-Medical Sciences*, vol. 5, no. 2, pp. 97–106, 2007.

[9] H. Nakada, Y. Numata, T. Sakae et al., "Comparison of bone mineral density and area of newly formed bone around Ti-15%Zr-4%Nb-4%Ta alloy and Ti-6%A1-4%V alloy implants," *Journal of Hard Tissue Biology*, vol. 17, no. 3, pp. 99–108, 2008.

[10] H. Nakada, S. Suzuki, T. Sakae et al., "Quantitative and qualitative analyses of low-mineral-diet ovariectomised rat femora using microscopic computed tomography," *Journal of Hard Tissue Biology*, vol. 20, pp. 107–114, 2011.

[11] Y. Okazaki, S. Rao, Y. Ito, and T. Tateishi, "Corrosion resistance, mechanical properties: corrosion fatigue strength and cytocompatibility of new Ti alloys without A1 and V," *Biomaterials*, vol. 19, no. 13, pp. 1197–1215, 1998.

[12] Y. Okazaki, E. Nishimura, H. Nakada, and K. Kobayashi, "Surface analysis of Ti-15Zr-4Nb-4Ta alloy after implantation in rat tibia," *Biomaterials*, vol. 22, no. 6, pp. 599–607, 2001.

[13] Y. Okazaki, "Effect of friction on anodic polarization properties of metallic biomaterials," *Biomaterials*, vol. 23, no. 9, pp. 2071–2077, 2002.

[14] Y. Okazaki, E. Gotoh, T. Manabe, and K. Kobayashi, "Comparison of metal concentrations in rat tibia tissues with various metallic implants," *Biomaterials*, vol. 25, no. 28, pp. 5913–5920, 2004.

[15] Y. Okazaki and E. Gotoh, "Comparison of metal release from various metallic biomaterials in vitro," *Biomaterials*, vol. 26, no. 1, pp. 11–21, 2005.

[16] R. Z. LeGeros, "Calcium phosphates in enamel," in *Calcium Phosphates in Oral Biology and Medicine*, M. M. Howard, Ed., pp. 108–110, Karger, Basel, Switzerland, 1991.

[17] R. Z. LeGeros, "Apatites in biological systems," *Progress in Crystal Growth And Characterization*, vol. 4, no. 1-2, pp. 1–45, 1981.

[18] C. D. Wagner, W. M. Riggs, L. E. Davis, J. F. Moulder, and G. E. Mullenberg, "A reference book of standard data for use in X-ray Photoelectron spectroscopy," in *Handbook of X-ray Photoelectron Spectroscopy*, G. E. Muilenberg, Ed., Perkin-Elmer, Eden Prairie, Minn, USA, 1979.

[19] A. Ide-Ektessabi, T. Yamaguchi, and Y. Tanaka, "RBS and XPS analyses of the composite calcium phosphate coatings for biomedical applications," *Nuclear Instruments and Methods in Physics Research B*, vol. 241, no. 1–4, pp. 685–688, 2005.

[20] M. Morra, C. Cassinelli, L. Meda, M. Fini, G. Giavaresi, and R. Giardino, "Surface analysis and effects on interfacial bone microhardness of collagen-coated titanium implants: a rabbit model," *International Journal of Oral and Maxillofacial Implants*, vol. 20, no. 1, pp. 23–30, 2005.

[21] T. F. Stoica, C. Morosanu, A. Slav et al., "Hydroxyapatite films obtained by sol-gel and sputtering," *Thin Solid Films*, vol. 516, no. 22, pp. 8112–8116, 2008.

[22] H. Nakada, Y. Numata, T. Sakae et al., "Changes in bone quality associated with the mineralization of new bone formed around implants—using XPS, polarized microscopy, and FTIR imaging," *Journal of Hard Tissue Biology*, vol. 19, no. 2, pp. 101–110, 2010.

[23] Y. Shibata and T. Miyazaki, "Anode glow discharge plasma treatment enhances calcium phosphate adsorption onto titanium plates," *Journal of Dental Research*, vol. 81, no. 12, pp. 841–844, 2002.

Hindawi Publishing Corporation
International Journal of Biomaterials
Volume 2012, Article ID 394121, 8 pages
doi:10.1155/2012/394121

Review Article

Mini-Implants in the Anchorage Armamentarium: New Paradigms in the Orthodontics

Masaru Yamaguchi,[1] Toshihiro Inami,[1] Ko Ito,[2] Kazutaka Kasai,[1] and Yasuhiro Tanimoto[3]

[1] *Department of Orthodontics, Nihon University School of Dentistry at Matsudo, 2-870-1 Sakaecho-Nishi, Chiba, Matsudo 271-8587, Japan*
[2] *Maxillofacial Surgery, Nihon University School of Dentistry at Matsudo, Chiba, Matsudo 271-8587, Japan*
[3] *Dental Biomaterials, Nihon University School of Dentistry at Matsudo, Chiba, Matsudo 271-8587, Japan*

Correspondence should be addressed to Masaru Yamaguchi, yamaguchi.masaru@nihon-u.ac.jp

Received 5 March 2012; Accepted 6 April 2012

Academic Editor: Yo Shibata

Copyright © 2012 Masaru Yamaguchi et al. This is an open access article distributed under the Creative Commons Attribution License, which permits unrestricted use, distribution, and reproduction in any medium, provided the original work is properly cited.

Paradigms have started to shift in the orthodontic world since the introduction of mini-implants in the anchorage armamentarium. Various forms of skeletal anchorage, including miniscrews and miniplates, have been reported in the literature. Recently, great emphasis has been placed on the miniscrew type of temporary anchorage device (TAD). These devices are small, are implanted with a relatively simple surgical procedure, and increase the potential for better orthodontic results. Therefore, miniscrews not only free orthodontists from anchorage-demanding cases, but they also enable clinicians to have good control over tooth movement in 3 dimensions. The miniplate type also produces significant improvements in treatment outcomes and has widened the spectrum of orthodontics. The purpose of this paper is to update clinicians on the current concepts and versatile uses and clinical applications of skeletal anchorage in orthodontics.

1. Introduction

The goal of orthodontic treatment is to improve the patient's life through enhancement of dentofacial functions and esthetics. Anchorage, defined as a resistance to unwanted tooth movement [1], is a prerequisite for the orthodontic treatment of dental and skeletal malocclusions [2, 3].

Controlling anchorage helps to avoid undesirable tooth movements. However, even a small reactive force can cause undesirable movements; it is important to have absolute anchorage to avoid them [4, 5]. Absolute or infinite anchorage is defined as no movement of the anchorage unit (zero anchorage loss) as a consequence to the reaction forces applied to move teeth [1]. Such an anchorage can only be obtained by using ankylosed teeth or dental implants as anchors, both relying on bone to inhibit movement [6]. Anchorage provided by devices, such as implants or miniscrew implants fixed to bone, may be obtained by enhancing the support to the reactive unit (indirect anchorage) or by fixing the anchor units (direct anchorage), thus facilitating skeletal anchorage.

Orthodontic anchorage is an important factor in obtaining good treatment results. Stable anchorage is a pre-requisite for orthodontic treatment with fixed appliances. Traditional appliances for reinforcement of anchorage have included headgear and intraoral elastics. The inclusion of implants for skeletal anchorage can move a tooth without the use of headgear and intraoral elastics.

Skeletal anchorage with temporary anchorage devices (TADs) has been widely incorporated into orthodontic treatment for expanding the boundary of tooth movement without patient compliance [7–10]. TAD skeletal anchorage is especially useful for treating malocclusion with vertical problems such as open bite and overeruption of teeth due to loss of antagonists [11–17]. Traditionally, skeletal open bite requires aggressive surgical impaction to reduce the maxillary dentoalveolar height. Supererupted teeth were usually corrected by endodontic intervention and crown restoration

at the expense of tooth vitality before TAD skeletal anchorage became popular. However, orthodontic intrusion with TAD skeletal anchorage provides a conservative treatment approach with little irreversible damage if patients can accept a longer treatment time [11, 12, 16, 17]. TAD skeletal anchorage is not only useful for resolving vertical problems in orthodontics but also eliminates the need for patient compliance for sagittal dental movement such as mesializing or distalizing the entire dentition both with and without extraction [10, 18]. With a correct diagnosis and mechanical design, TAD skeletal anchorage is sufficiently versatile to treat all types of malocclusions, except those accompanied by facial deformities requiring invasive and extensive surgeries to obtain a harmonious skeletal relationship [18, 19].

Various types of TAD have been used in orthodontics [20, 21]. Turley et al. [2] and Roberts et al. [22] reported conventional osseointegrated implants. Costa et al. [7] and Freudenthaler et al. [23] reported mini- and microimplants and Wehrbein et al. [24–26] reported palatal implants.

The aim of this paper is to present the development, clinical use, benefits, and drawbacks of the miniscrew and plate type implants used to obtain a temporary but absolute skeletal anchorage for orthodontic applications.

2. Dental Implant and Mini-Implants

Titanium implants have been used largely in dentistry over past decades. The close contact between bone and titanium implants provides an ankylosis-like type of interaction, an event named osseointegration [27]. Because osseointegration offers necessary conditions for load and transfer bearing, the use of dental implants as orthodontic anchorages has increased progressively over the years [22, 28]. Although implants provide excellent anchorage, some limitations such as the waiting time for allowing osseointegration, invasive surgery, high cost, and difficulty of removing the dental implant after completion of orthodontic treatment were noted initially because of their routine use in orthodontics [29, 30]. Another initial difficulty was that conventional implants are placed in edentulous sites with sufficient bone for anchorage; however, most orthodontic patients are young and do not have edentulous areas. To overcome this limitation, titanium screws with smaller dimensions (miniscrews) were introduced and were referred to as orthodontic mini-implants [31]; these can be placed in unconventional sites such as the alveolar bone of adjacent teeth without damaging roots and without requiring time for osseointegration [32–34]. Furthermore, Rinaldi and Arana-Chavez showed that repair occurred at the mini-implant surface through cementoblastic activity. In addition, the periodontal ligament space was well preserved in all specimens, and no microankylotic spots were detected [35].

3. Two Main Systems

Two main systems are used to retract the anterior teeth: miniscrews (Figures 1 and 2) [36–44] and miniplates [45, 46].

3.1. Miniscrews

3.1.1. Palatal Implants. Most of the published studies on the retraction of anterior teeth with miniscrews are case reports [29, 41–44] (Figure 1(a)). In the cases presented, the miniscrews were applied directly to the hooks on the archwire to retract all upper 6 anterior teeth simultaneously with a loading force of about 150 g. Furthermore, the extraction space was fully utilized in the retraction of anterior teeth without anchorage loss. The posterior teeth even moved distally slightly in some cases [41–44]. One of the advantages of the mechanics involved in these cases was the direct application of load to the vertical hooks on the archwire: in this setup, the point of force application was close to the center of resistance of the anterior segment, thereby allowing bodily sliding of the whole segment with minimal tipping, and in turn, shortening the treatment time [44] (Figure 1(b)).

In the cases inserted within palatal, Wehrbein et al. [24] prospectively studied 9 patients with Class II malocclusion in whom anchorage was indirectly reinforced by connection of a transpalatal bar to a palatal implant after extraction of the upper first premolars. The loading force applied was 200 g over 11 months, and the reduction of overjet ranged from 5.1 to 7.8 mm (mean, 6.22 mm). The loss of anchorage ranged from 0.2 to 1.6 mm, and was attributed to the deformation of the transpalatal bar (Figure 1(c)).

3.2. Miniplates. In 1985, Jenner and Fitzpatrick [47] reported an alternative orthodontic anchorage method using a bone plate. Umemori et al. [11] introduced miniplate skeletal anchorage that was effective in controlling the cant and level of the occlusal plane during orthodontic open-bite correction without serious side-effects. Rattanayatikul et al. [48] described the use of miniplates for temporary skeletal anchorage in treating skeletal Class III malocclusions with missing posterior teeth. Tseng et al. [49] reported that miniplates as skeletal anchorage are effective for managing severely impacted mandibular second molars.

Miniplates have also been used to retract anterior teeth [45, 46]. De Clerck et al. [45] followed up 27 patients undergoing retraction of canines (11 bilateral and 16 unilateral) using a miniplate fixed with 3 miniscrews. The setup used sliding mechanics with power arms attached to the canines and a loading force of 50 to 100 g. The mean rate of distalization among the patients studied was 1.14 mm per month.

The miniplate's one end is fixed to the infrazygomatic crest and the other end has attachments to engage orthodontic auxiliaries. Meanwhile, the miniscrew is fixed to only the alveolar cortical bone. Therefore, higher loading rate should be applicable to miniplates rather than miniscrews as the direct bone anchor is available in case of miniplates.

4. Tooth Movement

4.1. Retraction of Anterior Teeth. Park et al. [50] described a case of anterior retraction in which an innovative miniscrew technique circumvented the need for brackets during retraction. First, maxillary miniscrews were placed between

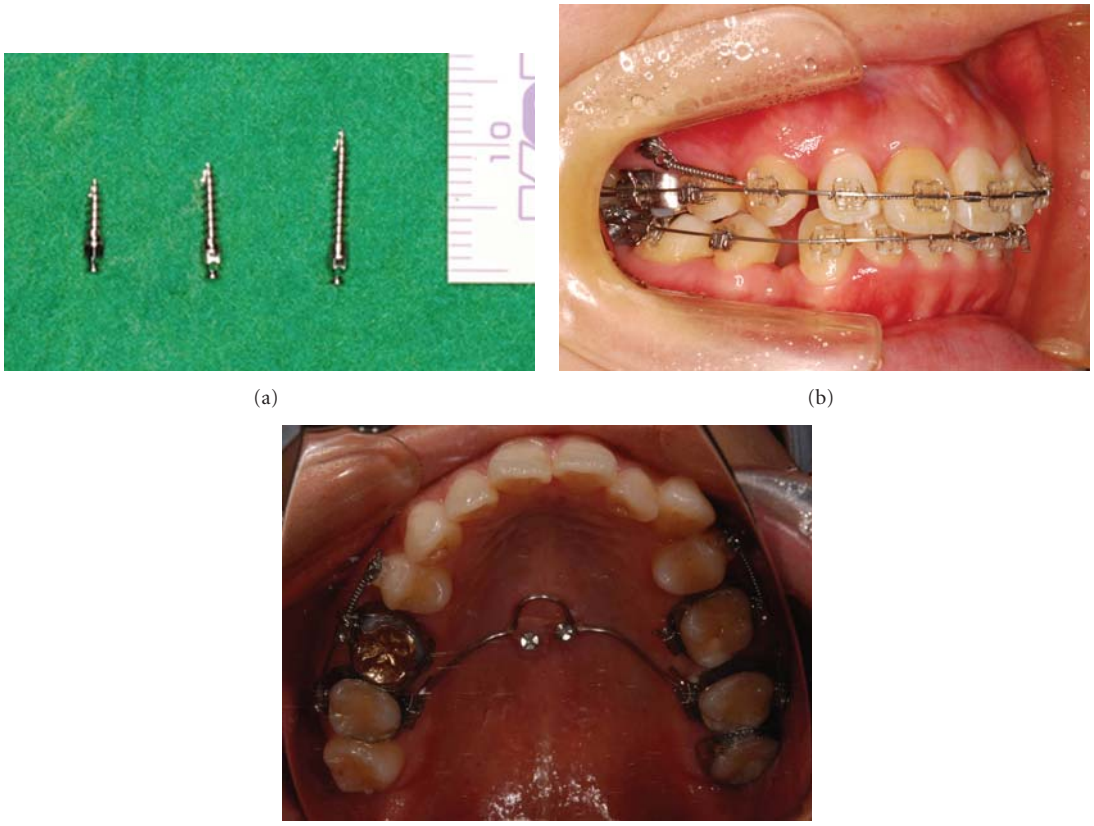

(a) (b)

(c)

Figure 1: (a) Miniscrews, (b) the maxillary right canine was retracted with a closed coil from miniscrew, and (c) palatal implants. The maxillary 2nd molars were connected with trance palatal arch and palatal implants.

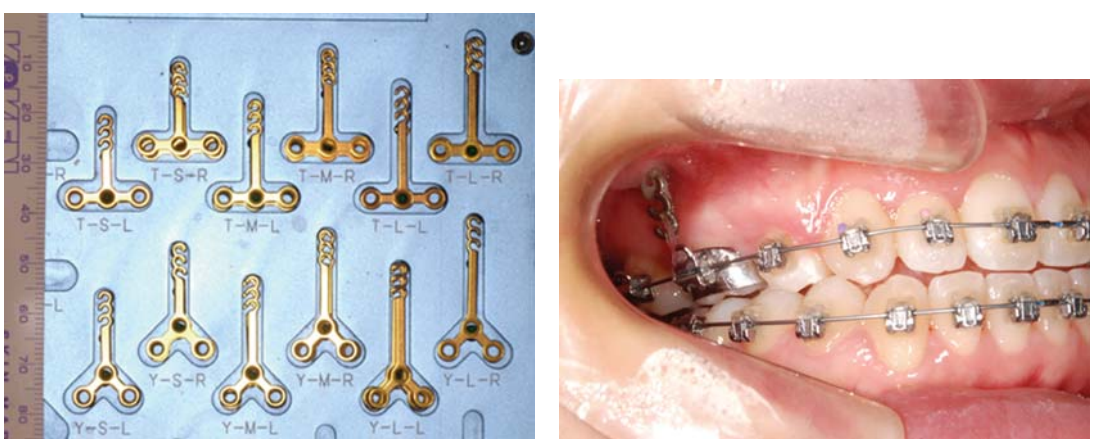

(a) (b)

Figure 2: (a) Miniplates, (b) the maxillary right 1st molar was intruded with an elastic chain from miniplate.

the first molar and second premolar. Second, a segmental hard acrylic splint with 2 lever arms distal to the canines was fabricated on the 6 anterior teeth. Elastics were then attached from the miniscrews to the lever arm. The 6 anterior teeth that were embedded in the clear splint were thus retracted without a bracket during the 6 months of retraction. Brackets were needed only in the finishing stage in the last 6 months. In a prospective split-mouth study, Thiruvenkatachari et al. [51] measured anchorage loss during canine retraction in 10 patients in whom only 1 side of the mouth received

miniscrew treatment. The canines were retracted in 4 to 6 months, with no anchorage loss on the implant side but with 1 to 2 mm of anchorage loss on the nonimplant side.

4.2. Intrusion of Dentition. Intrusion of posterior or anterior dentition is always difficult to achieve without the side effect of extrusion of the anchorage teeth, and the placement of mini-implants for skeletal anchorage may provide the solution. For example, intrusion of posterior teeth is essential in the correction of open bite, and case reports have shown that miniplates can lead to the intrusion of upper and lower molars by 3 to 5 mm, while also achieving counterclockwise mandibular rotation [52–55]. Sugawara et al. [56] investigated the amount of intrusion of mandibular molars among 9 patients after miniplate treatment, and found that 1.7 mm and 2.8 mm of intrusion was achieved in first and second molars, respectively, although there was about 30% relapse. Erverdi et al. [12] also reported using miniplates to intrude upper molars by 2.6 mm in 10 patients. Even as early as 1983, Creekmore and Eklund [57] demonstrated the use of miniscrews to intrude maxillary central incisors by 6 mm. In 2005, Ohnishi et al. [58] described a case of gummy smile correction with intrusion of the upper incisors by 3.5 mm.

4.3. Intrusion or Extrusion of Individual Teeth. In the management of overeruption of unopposed teeth, molar intrusion is a common indication for orthodontic treatment before prosthodontic replacement of missing teeth. Two cases have been reported in which overerupted lower and upper molars were intruded with miniscrews but without any braces on other teeth [59, 60]. Upper molars can also be intruded with miniscrews on buccal and palatal sides before the prosthetic restoration of the lower missing teeth is commenced [61, 62]. In another case, overerupted upper left first and second molars were intruded by the fixation of a miniplate on buccal bone and a miniscrew on palatal bone, with a loading force of 150 to 200 g delivered by a power chain [17].

A miniscrew has been used for forced tooth extrusion in a 51-year-old woman who presented with a bridge that replaced a missing upper right incisor with the central incisor and canine as abutments. Because the gingiva at the central incisor and canine had receded by 3 to 4 mm, both of them required extrusion to match the gingival level of the contralateral side before a new bridge could be constructed. To do this, a miniscrew was placed into the alveolus of the missing upper lateral incisor and an open coil was applied perpendicularly to an orthodontic wire connecting the central incisor and canine [63].

5. Complications

Kravitz and Kusnoto [64], reviewed the potential risks and complications of orthodontic miniscrews with regard to insertion, orthodontic loading, and peri-implant soft tissue health.

5.1. Trauma to the Periodontal Ligament or the Dental Root during Insertion. Interradicular placement of orthodontic miniscrews risks trauma to the periodontal ligament or the dental root. Potential complications of root injury include loss of tooth vitality, osteosclerosis, and dentoalveolar ankylosis [65, 66]. Trauma to the outer dental root without pulpal involvement will most likely not influence the tooth's prognosis [67]. Dental roots damaged by orthodontic miniscrews have demonstrated complete repair of tooth and periodontium in 12 to 18 weeks after removal of the miniscrew. Interradicular placement requires proper radiographic planning, including surgical guide with panoramic and periapical radiographs to determine the safest site for miniscrew placement [29, 32, 68–70]. In the maxillary buccal region, the greatest amount of interradicular bone is between the second premolar and the first molar, 5 to 8 mm from the alveolar crest [71–73]. In the mandibular buccal region, the greatest amount of interradicular bone is either between the second premolar and the first molar, or between the first molar and the second molar, approximately 11 mm from the alveolar crest [71–73]. During interradicular placement in the posterior region, there is a tendency for the clinician to change the angle of insertion by inadvertently pulling the hand driver toward their body, increasing the risk of root contact. To avoid this, the clinician may consider using a finger wrench or work the hand driver slightly away from their body with each turn. If the miniscrew begins to approximate the periodontal ligament, the patient will experience increased sensation under topical anesthesia [69, 74]. If root contact occurs, the miniscrew may either stop or begin to require greater insertion strength. If trauma is suspected, the clinician should unscrew the miniscrew 2 or 3 turns and evaluate it radiographically.

5.2. Stationary Anchorage Failure under Orthodontic Loading. According to the literature, the rates of stationary anchorage failure of miniscrews under orthodontic loading vary between 11% and 30% [75–77]. If a miniscrew loosens, it will not regain stability and will probably need to be removed and replaced [59]. Stability of the orthodontic miniscrew throughout treatment depends on bone density, peri-implant soft tissues, miniscrew design, surgical technique, and force load [78–82]. The key determinant for stationary anchorage is bone density [83, 84]. Stationary anchorage failure is often a result of low bone density due to inadequate cortical thickness [67].

In general, stationary anchorage failure is greater in the maxilla, with the exception of the midpalatal region, due to the greater trabeculae and lower bone density [85, 86]. Loss of midpalat miniscrews is likely a result of tongue pressure. Peri-implant soft tissue type, health, and thickness can affect stationary anchorage of the miniscrew. Miniscrews placed in nonkeratinized alveolar tissues have greater failure rates than those in attached tissues [77]. The movable, nonkeratinized alveolar mucosa is easily irritated; soft tissue inflammation around the miniscrew is directly associated with increased mobility [79]. Additionally, miniscrews placed in regions of thick keratinized tissue, such as the palatal slope, are less likely to obtain adequate bony stability [87]. Thin, keratinized tissue, seen in the dentoalveolar or midpalatal region, is ideal for miniscrew placement [87]. Miniscrew geometry

and surgical technique directly influence the stress distribution of peri-implant bone [78]. Most miniscrew losses occur as a result of excessive stress at the screw-bone interface [75]. Self-drilling miniscrews can have greater screw-bone contacts (mechanical grip) and holding strengths compared with self-tapping screws [86–88]. Heidemann et al. [87] reported greater residual bone between screw threads of self-drilling miniscrews compared with self-tapping miniscrews. Self-tapping miniscrews, like self-drilling screws, can be placed without a predrilled pilot hole in the dentoalveolar region if the cortical bone is thin [89]. If a pilot hole is to be used, for either self-drilling or self-tapping miniscrews, the pilot hole size should be no greater than 85% of the diameter of the miniscrew shaft for optimal stability [90]. It is still not clear the maximum force-load, a miniscrew can withstand with regard to stationary anchorage [86]. Dalstra et al. [91] reported that miniscrews inserted into thin cortical bone and fine trabeculae should be limited to 50 g of immediate loaded force. Büchter et al. [76] reported that miniscrews placed in dense mandibular bone remained clinically stable with up to 900 g of force. Many articles reported miniscrew stability with loading forces of 300 g or less [76, 81, 92]. In regions of poor bone density, simply placing a longer miniscrew under smaller orthodontic force does not ensure stationary anchorage [93].

5.3. Soft Tissue Coverage of the Miniscrew Head and Auxiliary. Miniscrews placed in alveolar mucosa, particularly in the mandible, might become covered by soft tissue. The bunching and rubbing of loose alveolar tissue can lead to coverage of both the miniscrew head and its attachments (i.e., coil spring, elastic chain) within a day after placement. Soft tissue coverage might be a risk factor for miniscrew stability, as well as a clinical concern for the patient, who might think that the miniscrew has fallen out. Miniscrew attachments (elastic chain, coil spring) that rest on tissues will likely become covered by tissue. The soft tissue overlaying the miniscrew is relatively thin and can be exposed with light finger pressure, typically without an incision or local anesthetic. Soft tissue overgrowth can be minimized by placement of a healing abutment cap, a wax pellet, or an elastic separator [94]. In addition to its antibacterial properties that minimize tissue inflammation, chlorhexidine slows down epithelialization and might reduce the likelihood of soft tissue overgrowth [95]. The authors suggest partial insertion with a longer miniscrew (10 mm) in regions of loose alveolar mucosa, leaving 2 or 3 threads of the shaft exposed to minimize the possibility of soft tissue coverage.

5.4. Soft Tissue Inflammation, Infection, and Peri-Implantitis. Healthy peri-implant tissue plays an important role as a biologic barrier to bacteria [96]. Tissue inflammation, minor infection, and peri-implantitis can occur after miniscrew placement [97]. Inflammation of the peri-implant soft tissue has been associated with a 30% increase in failure rate [79]. Peri-implantitis is inflammation of the surrounding implant mucosa with clinically and radiographically evident loss of bony support, bleeding on probing, suppuration, epithelia infiltrations, and progressive mobility [95]. The clinician should be forewarned of soft tissue irritation if the soft tissues begin twisting around the miniscrew shaft during placement. Some clinicians advocate a 2-week soft tissue healing period for miniscrews placed in the alveolar mucosa before orthodontic loading [98].

6. Feature of Mini-Implants

The rates of stationary anchorage failure of miniscrews under orthodontic loading vary between 11% and 30% [75–77]. The rates are not low, and it may leave much room for improvement. However, the improvement in designed screw including the diameter, length, and thread may reach the limit. Therefore, new materials instead of titanium such as CaP may be necessary to investigate in future.

7. Conclusions

On the basis of this systematic review, the following can be concluded.

(1) Miniscrew implants can function as viable alternative to conventional molar anchorage. They are simple and efficient anchors for canine retraction, especially in moderate to maximum anchorage situations.

(2) The placement of mini-implants for skeletal anchorage may provide the intrusion of posterior without the side effect of extrusion of the anchorage teeth.

Acknowledgment

The paper received Grant-in-Aid for Scientific Research from the Japan Society for the Promotion of Science (C: 22592297, C: 22792069, C: 23792449, C: 23593044).

References

[1] J. Daskalogiannakis, *Glossary of Oorthodontic Terms*, Quintessence, Leipzig, Germany, 2000.

[2] P. K. Turley, C. Kean, J. Schur et al., "Orthodontic force application to titanium endosseous implants," *Angle Orthodontist*, vol. 58, no. 2, pp. 151–162, 1988.

[3] M. A. Papadopoulos, "Overview of the intra-maxillary noncompliance appliances with absolute anchorage," in *Orthodontic Treatment for the Class II Non-Compliant Patient: Current Principles and Techniques*, M. A. Papadopoulos, Ed., pp. 341–344, Elsevier, Mosby, Edinburgh, UK, 2006.

[4] S. Weinstein, D. C. Haak, L. Y. Morris, B. B. Snyder, and H. E. Attaway, "On equilibrium theory of tooth position," *The Angle Orthodontist*, vol. 33, pp. 1–26, 1963.

[5] J. J. Pilon, A. M. Kuijpers-Jagtman, and J. C. Maltha, "Magnitude of orthodontic forces and rate of bodily tooth movement. An experimental study," *American Journal of Orthodontics & Dentofacial Orthopedics*, vol. 110, no. 1, pp. 16–23, 1996.

[6] B. Melsen and D. Garbo, "Treating the "impossible case" with the use of the Aarhus Anchorage System," *Orthodontics*, vol. 1, pp. 13–20, 2004.

[7] A. Costa, M. Raffainl, and B. Melsen, "Miniscrews as orthodontic anchorage: a preliminary report," *The International*

Journal of Adult Orthodontics and Orthognathic Surgery, vol. 13, no. 3, pp. 201–209, 1998.

[8] J. Sugawara, "Dr. Junji Sugawara on the skeletal anchorage system. Interview by Dr. Larry W. White," *Journal of Clinical Orthodontics*, vol. 33, no. 12, pp. 689–696, 1999.

[9] J. Mah and F. Bergstrand, "Temporary anchorage devices: a status report," *Journal of Clinical Orthodontics*, vol. 39, no. 3, pp. 132–153, 2005.

[10] J. H. Sung, H. M. Kyung, S. M. Bae, H. S. Park, O. W. Kwon, and J. A. McNamara, *Microimplants in Orthodontics*, Dentos, Daegu, Korea, 2006.

[11] M. Umemori, J. Sugawara, H. Mitani, H. Nagasaka, and H. Kawamura, "Skeletal anchorage system for open-bite correction," *American Journal of Orthodontics & Dentofacial Orthopedics*, vol. 115, no. 2, pp. 166–174, 1999.

[12] N. Erverdi, N. Tosun, and A. Keles, "A new anchorage site for the treatment of anterior open bite: zygomatic anchorage. A case report," *World Journal of Orthodontics*, vol. 3, pp. 147–153, 2002.

[13] N. Erverdi, A. Keles, and R. Nanda, "The use of skeletal anchorage in open bite treatment: a cephalometric evaluation," *Angle Orthodontist*, vol. 74, no. 3, pp. 381–390, 2004.

[14] K. H. Sherwood, J. G. Burch, and W. J. Thompson, "Closing anterior open bites by intruding molars with titanium miniplate anchorage," *American Journal of Orthodontics & Dentofacial Orthopedics*, vol. 122, no. 6, pp. 593–600, 2002.

[15] H. S. Park, T. G. Kwon, and O. W. Kwon, "Treatment of open bite with microscrew implant anchorage," *American Journal of Orthodontics & Dentofacial Orthopedics*, vol. 126, no. 5, pp. 627–636, 2004.

[16] C. C. J. Yao, J. J. Lee, H. Y. Chen, Z. C. J. Chang, H. F. Chang, and Y. J. Chen, "Maxillary molar intrusion with fixed appliances and mini-implant anchorage studied in three dimensions," *Angle Orthodontist*, vol. 75, no. 5, pp. 754–760, 2005.

[17] C. C. J. Yao, C. B. Wu, H. Y. Wu, S. H. Kok, H. F. F. Chang, and Y. J. Chen, "Intrusion of the overerupted upper left first and second molars by mini-implants with partial-fixed orthodontic appliances: a case report," *Angle Orthodontist*, vol. 74, no. 4, pp. 550–557, 2004.

[18] J. Cope and J. Graham, "Treatment planning for temporary anchorage device applications," in *OrthoTADs: The Clinical Guide and Atlas*, J. Cope, Ed., pp. 67–88, Under Dog Media, LP, Dallas, Tex, USA, 2007.

[19] S. Kuroda, Y. Sugawara, T. Deguchi, H. M. Kyung, and T. Takano-Yamamoto, "Clinical use of miniscrew implants as orthodontic anchorage: success rates and postoperative discomfort," *American Journal of Orthodontics & Dentofacial Orthopedics*, vol. 131, no. 1, pp. 9–15, 2007.

[20] G. C. Heymann and J. F. C. Tulloch, "Implantable devices as orthodontic anchorage: a review of current treatment modalities," *Journal of Esthetic and Restorative Dentistry*, vol. 18, no. 2, pp. 68–80, 2006.

[21] J. Prabhu and R. R. Cousley, "Current products and practice: bone anchorage devices in orthodontics," *Journal of Orthodontics*, vol. 33, no. 4, pp. 288–307, 2006.

[22] W. E. Roberts, F. R. Helm, K. J. Marshall, and R. K. Gongloff, "Rigid endosseous implants for orthodontic and orthopedic anchorage," *Angle Orthodontist*, vol. 59, no. 4, pp. 247–256, 1989.

[23] J. W. Freudenthaler, R. Haas, and H. P. Bantleon, "Bicortical titanium screws for critical orthodontic anchorage in the mandible: a preliminary report on clinical applications," *Clinical Oral Implants Research*, vol. 12, no. 4, pp. 358–363, 2001.

[24] H. Wehrbein, H. Feifel, and P. Diedrich, "Palatal implant anchorage reinforcement of posterior teeth: a prospective study," *American Journal of Orthodontics & Dentofacial Orthopedics*, vol. 116, no. 6, pp. 678–686, 1999.

[25] H. Wehrbein, J. Glatzmaier, U. Mundwiller, and P. Diedrich, "The Orthosystem—a new implant system for orthodontic anchorage in the palate," *Journal of Orofacial Orthopedics*, vol. 57, no. 3, pp. 142–153, 1996.

[26] H. Wehrbein, B. R. Merz, and P. Diedrich, "Palatal bone support for orthodontic implant anchorage—a clinical and radiological study," *European Journal of Orthodontics*, vol. 21, no. 1, pp. 65–70, 1999.

[27] P. I. Brånemark, B. O. Hansson, R. Adell et al., "Osseointegrated implants in the treatment of the edentulous jaw. Experience from a 10-year period," *Scandinavian Journal of Plastic and Reconstructive Surgery. Supplementum*, vol. 16, pp. 1–132, 1977.

[28] K. W. Higuchi and J. M. Slack, "The use of titanium fixtures for intraoral anchorage to facilitate orthodontic tooth movement," *The International Journal of Oral & Maxillofacial Implants*, vol. 6, no. 3, pp. 338–344, 1991.

[29] S. M. Bae, H. S. Park, H. M. Kyung, O. W. Kwon, and J. H. Sung, "Clinical application of micro-implant anchorage," *Journal of Clinical Orthodontics*, vol. 36, no. 5, pp. 298–302, 2002.

[30] U. Fritz, A. Ehmer, and P. Diedrich, "Clinical suitability of titanium microscrews for orthodontic anchorage—preliminary experiences," *Journal of Orofacial Orthopedics*, vol. 65, no. 5, pp. 410–418, 2004.

[31] T. Deguchi, T. Takano-Yamamoto, R. Kanomi, J. K. Hartsfield, W. E. Roberts, and L. P. Garetto, "The use of small titanium screws for orthodontic anchorage," *Journal of Dental Research*, vol. 82, no. 5, pp. 377–381, 2003.

[32] A. Carano, S. Velo, P. Leone, and G. Siciliani, "Clinical applications of the Miniscrew Anchorage system," *Journal of Clinical Orthodontics*, vol. 39, no. 1, pp. 9–24, 2005.

[33] C. Arcuri, F. Muzzi, F. Santini, A. Barlattani, and A. Giancotti, "Five years of experience using palatal mini-implants for orthodontic anchorage," *Journal of Oral and Maxillofacial Surgery*, vol. 65, no. 12, pp. 2492–2497, 2007.

[34] B. Vande Vannet, M. M. Sabzevar, H. Wehrbein, and K. Asscherickx, "Osseointegration of miniscrews: a histomorphometric evaluation," *European Journal of Orthodontics*, vol. 29, no. 5, pp. 437–442, 2007.

[35] J. C. Rinaldi and V. E. Arana-Chavez, "Ultrastructure of the interface between periodontal tissues and titanium mini-implants," *Angle Orthodontist*, vol. 80, no. 3, pp. 459–465, 2010.

[36] H. Wehrbein, B. R. Merz, P. Diedrich, and J. Glatzmaier, "The use of palatal implants for orthodontic anchorage: design and clinical application of the orthosystem," *Clinical Oral Implants Research*, vol. 7, no. 2, pp. 410–416, 1996.

[37] T. Bernhart, J. Freudenthaler, O. Dörtbudak, H. P. Bantleon, and G. Watzek, "Short epithetic implants for orthodontie anchorage in the paramedian region of the palate—a clinical study," *Clinical Oral Implants Research*, vol. 12, no. 6, pp. 624–631, 2001.

[38] H. Wehrbein and B. R. Merz, "Aspects of the use of endosseous palatal implants in orthodontic therapy," *Journal of Esthetic Dentistry*, vol. 10, no. 6, pp. 315–324, 1998.

[39] H. Wehrbein, B. R. Merz, C. H. F. Hämmerle, and N. P. Lang, "Bone-to-implant contact of orthodontic implants in humans subjected to horizontal loading," *Clinical Oral Implants Research*, vol. 9, no. 5, pp. 348–353, 1998.

[40] K. Chung, S. H. Kim, and Y. Kook, "C-orthodontic microimplant for distalization of mandibular dentition in class III correction," *Angle Orthodontist*, vol. 75, no. 1, pp. 119–128, 2005.

[41] J. S. Lee, H. S. Park, and H. M. Kyung, "Micro-implant anchorage for lingual treatment of a skeletal Class II malocclusion," *Journal of Clinical Orthodontics*, vol. 35, no. 10, pp. 643–647, 2001.

[42] H. S. Park, S. M. Bae, H. M. Kyung, and J. H. Sung, "Micro-implant anchorage for treatment of skeletal Class I bialveolar protrusion," *Journal of Clinical Orthodontics*, vol. 35, no. 7, pp. 417–422, 2001.

[43] H. S. Park and T. G. Kwon, "Sliding mechanics with microscrew implant anchorage," *Angle Orthodontist*, vol. 74, no. 5, pp. 703–710, 2004.

[44] H. S. Park, O. W. Kwon, and J. H. Sung, "Microscrew implant anchorage sliding mechanics," *World Journal of Orthodontics*, vol. 6, no. 3, pp. 265–274, 2005.

[45] H. De Clerck, V. Geerinckx, and S. Siciliano, "The zygoma anchorage system," *Journal of Clinical Orthodontics*, vol. 36, no. 8, pp. 455–459, 2002.

[46] K. R. Chung, Y. S. Kim, J. L. Linton, and Y. J. Lee, "The miniplate with tube for skeletal anchorage," *Journal of Clinical Orthodontics*, vol. 36, no. 7, pp. 407–412, 2002.

[47] J. D. Jenner and B. N. Fitzpatrick, "Skeletal anchorage utilising bone plates," *Australian Orthodontic Journal*, vol. 9, no. 2, pp. 231–233, 1985.

[48] C. Rattanayatikul, K. Godfrey, J. Chawengchettanon, and T. Vattraraphoudet, "Miniplates and screws in treatment of skeletal Class III malocclusion with missing posterior teeth. A case report," *Australian Orthodontic Journal*, vol. 22, no. 2, pp. 167–172, 2006.

[49] Y. C. Tseng, C. M. Chen, and H. P. Chang, "Use of a miniplate for skeletal anchorage in the treatment of a severely impacted mandibular second molar," *British Journal of Oral and Maxillofacial Surgery*, vol. 46, no. 5, pp. 406–407, 2008.

[50] Y. C. Park, J. H. Chu, Y. J. Choi, and N. C. Choi, "Extraction space closure with vacuum-formed splints and miniscrew anchorage," *Journal of Clinical Orthodontics*, vol. 39, no. 2, pp. 76–79, 2005.

[51] B. Thiruvenkatachari, A. Pavithranand, K. Rajasigamani, and H. M. Kyung, "Comparison and measurement of the amount of anchorage loss of the molars with and without the use of implant anchorage during canine retraction," *American Journal of Orthodontics & Dentofacial Orthopedics*, vol. 129, no. 4, pp. 551–554, 2006.

[52] S. Kuroda, A. Katayama, and T. Takano-Yamamoto, "Severe anterior open-bite case treated using titanium screw anchorage," *Angle Orthodontist*, vol. 74, no. 4, pp. 558–567, 2004.

[53] K. H. Sherwood, J. Burch, and W. Thompson, "Intrusion of supererupted molars with titanium miniplate anchorage," *Angle Orthodontist*, vol. 73, no. 5, pp. 597–601, 2003.

[54] C. H. Paik, Y. J. Woo, and R. L. Boyd, "Treatment of an adult patient with vertical maxillary excess using miniscrew fixation," *Journal of Clinical Orthodontics*, vol. 37, no. 8, pp. 423–428, 2003.

[55] K. H. Sherwood and J. G. Burch, "Skeletally based miniplate supported orthodontic anchorage," *Journal of Oral and Maxillofacial Surgery*, vol. 63, no. 2, pp. 279–284, 2005.

[56] J. Sugawara, U. B. Baik, M. Umemori et al., "Treatment and posttreatment dentoalveolar changes following intrusion of mandibular molars with application of a skeletal anchorage system (SAS) for open bite correction," *The International Journal of Adult Orthodontics and Orthognathic Surgery*, vol. 17, no. 4, pp. 243–253, 2002.

[57] T. D. Creekmore and M. K. Eklund, "The possibility of skeletal anchorage," *Journal of Clinical Orthodontics*, vol. 17, no. 4, pp. 266–269, 1983.

[58] H. Ohnishi, T. Yagi, Y. Yasuda, and K. Takada, "A mini-implant for orthodontic anchorage in a deep overbite case," *Angle Orthodontist*, vol. 75, no. 3, pp. 444–452, 2005.

[59] S. M. Bae and H. M. Kyung, "Mandibular molar intrusion with miniscrew anchorage," *Journal of Clinical Orthodontics*, vol. 40, no. 2, pp. 107–108, 2006.

[60] J. C. Lin, E. J. Liou, and C. L. Yeh, "Intrusion of overerupted maxillary molars with miniscrew anchorage," *Journal of Clinical Orthodontics*, vol. 40, no. 6, pp. 378–383, 2006.

[61] J. S. Lee, H. K. Doo, Y. C. Park, S. H. Kyung, and T. K. Kim, "The efficient use of midpalatal miniscrew implants," *Angle Orthodontist*, vol. 74, no. 5, pp. 711–714, 2004.

[62] Y. J. Chang, H. S. Lee, and Y. S. Chun, "Microscrew anchorage for molar intrusion," *Journal of Clinical Orthodontics*, vol. 38, no. 6, pp. 325–330, 2004.

[63] A. Roth, M. Yildirim, and P. Diedrich, "Forced eruption with microscrew anchorage for preprosthetic leveling of the gingival margin: case report," *Journal of Orofacial Orthopedics*, vol. 65, no. 6, pp. 513–519, 2004.

[64] N. D. Kravitz and B. Kusnoto, "Risks and complications of orthodontic miniscrews," *American Journal of Orthodontics & Dentofacial Orthopedics*, vol. 131, no. 4, pp. S43–S51, 2007.

[65] K. Asscherickx, B. V. Vannet, H. Wehrbein, and M. M. Sabzevar, "Root repair after injury from mini-screw," *Clinical Oral Implants Research*, vol. 16, no. 5, pp. 575–578, 2005.

[66] K. Mine, Z. Kanno, T. Muramoto, and K. Soma, "Occlusal forces promote periodontal healing of transplanted teeth and prevent dentoalveolar ankylosis: an experimental study in rats," *Angle Orthodontist*, vol. 75, no. 4, pp. 637–644, 2005.

[67] B. Melsen and C. Verna, "Miniscrew implants: the Aarhus anchorage system," *Seminars in Orthodontics*, vol. 11, no. 1, pp. 24–31, 2005.

[68] C. Morea, G. C. Dominguez, A. V. Wuo, and A. Tortamano, "Surgical guide for optimal positioning of mini-implants," *Journal of Clinical Orthodontics*, vol. 39, no. 5, pp. 317–321, 2005.

[69] K. Dula, R. Mini, P. F. van der Stelt, and D. Buser, "The radiographic assessment of implant patients: decision-making criteria," *International Journal of Oral and Maxillofacial Implants*, vol. 16, no. 1, pp. 80–89, 2001.

[70] E. Y. Suzuki and B. Buranastidporn, "An adjustable surgical guide for miniscrew placement," *Journal of Clinical Orthodontics*, vol. 39, no. 10, pp. 588–590, 2005.

[71] A. Carano, S. Velo, C. Incorvati, and P. Poggio, "Clinical applications of the Mini-Screw-Anchorage-System (M.A.S.) in the maxillary alveolar bone," *Progress in Orthodontics*, vol. 5, no. 2, pp. 212–235, 2004.

[72] M. A. Schnelle, F. M. Beck, R. M. Jaynes, and S. S. Huja, "A radiographic evaluation of the availability of bone for placement of miniscrews," *Angle Orthodontist*, vol. 74, no. 6, pp. 832–837, 2004.

[73] P. M. Poggio, C. Incorvati, S. Velo, and A. Carano, "Safe zones: a guide for miniscrew positioning in the maxillary and mandibular arch," *Angle Orthodontist*, vol. 76, no. 2, pp. 191–197, 2006.

[74] H. M. Kyung, H. S. Park, S. M. Bae, J. H. Sung, and I. B. Kim, "Development of orthodontic micro-implants for intraoral anchorage," *Journal of Clinical Orthodontics*, vol. 37, no. 6, pp. 321–328, 2003.

[75] R. Adell, U. Lekholm, B. Rockler, and P. I. Branemark, "A 15-year study of osseointegrated implants in the treatment of the edentulous jaw," *International Journal of Oral Surgery*, vol. 10, no. 6, pp. 387–416, 1981.

[76] A. Büchter, D. Wiechmann, S. Koerdt, H. P. Wiesmann, J. Piffko, and U. Meyer, "Load-related implant reaction of mini-implants used for orthodontic anchorage," *Clinical Oral Implants Research*, vol. 16, no. 4, pp. 473–479, 2005.

[77] S. J. Cheng, I. Y. Tseng, J. J. Lee, and S. H. Kok, "A prospective study of the risk factors associated with failure of mini-implants used for orthodontic anchorage," *International Journal of Oral and Maxillofacial Implants*, vol. 19, no. 1, pp. 100–106, 2004.

[78] A. Büchter, J. Kleinheinz, H. P. Wiesmann et al., "Biological and biomechanical evaluation of bone remodelling and implant stability after using an osteotome technique," *Clinical Oral Implants Research*, vol. 16, no. 1, pp. 1–8, 2005.

[79] S. Miyawaki, I. Koyama, M. Inoue, K. Mishima, T. Sugahara, and T. Takano-Yamamoto, "Factors associated with the stability of titanium screws placed in the posterior region for orthodontic anchorage," *American Journal of Orthodontics & Dentofacial Orthopedics*, vol. 124, no. 4, pp. 373–378, 2003.

[80] I. H. Orenstein, D. P. Tarnow, H. F. Morris, and S. Ochi, "Factors affecting implant mobility at placement and integration of mobile implants at uncovering," *Journal of Periodontology*, vol. 69, no. 12, pp. 1404–1412, 1998.

[81] W. E. Roberts, K. J. Marshall, and P. G. Mozsary, "Rigid endosseous implant utilized as anchorage to protract molars and close an atrophic extraction site," *Angle Orthodontist*, vol. 60, no. 2, pp. 135–152, 1990.

[82] M. Sevimay, F. Turhan, M. A. Kiliçarslan, and G. Eskitascioglu, "Three-dimensional finite element analysis of the effect of different bone quality on stress distribution in an implant-supported crown," *Journal of Prosthetic Dentistry*, vol. 93, no. 3, pp. 227–234, 2005.

[83] C. E. Misch, *Contemporary Implant Dentistry*, Mosby, St Louis, Mo, USA, 2nd edition, 1998.

[84] C. E. Misch, "Density of bone: effect on treatment plans, surgical approach, healing, and progressive boen loading," *The International Journal of Oral Implantology*, vol. 6, no. 2, pp. 23–31, 1990.

[85] K. A. Schlegel, F. Kinner, and K. D. Schlegel, "The anatomic basis for palatal implants in orthodontics," *The International Journal of Adult Orthodontics and Orthognathic Surgery*, vol. 17, no. 2, pp. 133–139, 2002.

[86] H. S. Yun, H. J. Kim, and Y. C. Park, *The thickness of the maxillary soft tissue and cortical bone related with an orthodontic implantation*, thesis, Yonsei University, Seoul, Korea, 2001.

[87] W. Heidemann, H. Terheyden, and K. L. Gerlach, "Analysis of the osseous/metal interface of drill free screws and self-tapping screws," *Journal of Cranio-Maxillofacial Surgery*, vol. 29, no. 2, pp. 69–74, 2001.

[88] W. Heidemann, H. Terheyden, and K. L. Gerlach, "In vivo studies of screw-bone contact of drill-free screws and conventional self-tapping screws," *Mund-, Kiefer- und Gesichtschirurgie*, vol. 5, no. 1, pp. 17–21, 2001.

[89] B. G. Maino, P. Mura, and J. Bednar, "Miniscrew implants: the Spider Screw anchorage system," *Seminars in Orthodontics*, vol. 11, no. 1, pp. 40–46, 2005.

[90] A. Gantous and J. H. Phillips, "The effects of varying pilot hole size on the holding power of miniscrews and microscrews," *Plastic and Reconstructive Surgery*, vol. 95, no. 7, pp. 1165–1169, 1995.

[91] M. Dalstra, P. M. Cattaneo, and B. Melson, "Load transfer of miniscrews for orthodontic anchorage," *Orthodontics*, vol. 1, pp. 53–62, 2004.

[92] R. Kanomi, "Mini-implant for orthodontic anchorage," *Journal of Clinical Orthodontics*, vol. 31, no. 11, pp. 763–767, 1997.

[93] E. J. W. Liou, B. C. J. Pai, and J. C. Y. Lin, "Do miniscrews remain stationary under orthodontic forces?" *American Journal of Orthodontics & Dentofacial Orthopedics*, vol. 126, no. 1, pp. 42–47, 2004.

[94] R. Herman and J. B. Cope, "Miniscrew implants: IMTEC mini ortho implants," *Seminars in Orthodontics*, vol. 11, no. 1, pp. 32–39, 2005.

[95] S. Othman, E. Haugen, and P. Gjermo, "The effect of chlorhexidine supplementation in a periodontal dressing," *Acta Odontologica Scandinavica*, vol. 47, no. 6, pp. 361–366, 1989.

[96] M. A. Sanchez-Garces and C. Gay-Escoda, "Peri-implantitis," *Medicina Oral, Patologia Oral y Cirugia Bucal*, vol. 9, supplement, pp. 63–69, 2004.

[97] A. Costa, G. Pasta, and G. Bergamaschi, "Intraoral hard and soft tissue depths for temporary anchorage devices," *Seminars in Orthodontics*, vol. 11, no. 1, pp. 10–15, 2005.

[98] B. Murray, N. McGuinness, P. Biagioni, P. Hyland, and P. J. Lamey, "A comparative study of the efficacy of Aphtheal in the management of recurrent minor aphthous ulceration," *Journal of Oral Pathology and Medicine*, vol. 34, no. 7, pp. 413–419, 2005.

Hindawi Publishing Corporation
International Journal of Biomaterials
Volume 2012, Article ID 369063, 6 pages
doi:10.1155/2012/369063

Review Article

Clinical Management of Implant Prostheses in Patients with Bruxism

Osamu Komiyama,[1] Frank Lobbezoo,[2] Antoon De Laat,[3] Takashi Iida,[1] Tsuyoshi Kitagawa,[4] Hiroshi Murakami,[4] Takao Kato,[4] and Misao Kawara[1]

[1] *Department of Oral Function and Rehabilitation, Nihon University School of Dentistry at Matsudo, 2-870-1 Sakaecho-nishi, Matsudo 271-8587, Japan*
[2] *Department of Oral Kinesiology, Academic Centre for Dentistry Amsterdam (ACTA), University of Amsterdam and VU University Amsterdam, Gustav Mahlerlaan 3004, 1066 1081 LA Amsterdam, The Netherlands*
[3] *Department of Oral Health Sciences KU Leuven and Department of Dentistry, University Hospitals KU Leuven, Kapucijnenvoer 7, 3000 Leuven, Belgium*
[4] *Department of Oral Implantology, Nihon University School of Dentistry at Matsudo, 2-870-1 Sakaecho-nishi, Matsudo 271-8587, Japan*

Correspondence should be addressed to Osamu Komiyama, komiyama.osamu@nihon-u.ac.jp

Received 27 January 2012; Revised 2 April 2012; Accepted 15 April 2012

Academic Editor: Yo Shibata

Copyright © 2012 Osamu Komiyama et al. This is an open access article distributed under the Creative Commons Attribution License, which permits unrestricted use, distribution, and reproduction in any medium, provided the original work is properly cited.

There is general agreement that excessive stress to the bone-implant interface may result in implant overload and failure. Early failure of the implant due to excessive loading occurs shortly after uncovering the implant. Excess load on a final restoration after successful implant integration can result in physical failure of the implant structure. Many clinicians believe that overload of dental implants is a risk factor for vertical peri-implant bone loss and/or may be detrimental for the suprastructure in implant prostheses. It has been documented that occlusal parafunction, such as, bruxism (tooth grinding and clenching) affects the outcome of implant prostheses, but there is no evidence for a causal relation between the failures and overload of dental implants. In spite of this lack of evidence, often metal restorations are preferred instead of porcelain for patients in whom bruxism is presumed on the basis of tooth wear. The purpose of this paper is to discuss the importance of the occlusal scheme used in implant restorations for implant longevity and to suggest a clinical approach and occlusal materials for implant prostheses in order to prevent complications related to bruxism.

1. Introduction

The most important factor in implant longevity as a factor for clinically successful implant treatment is the formation of a direct interface between the implant and the bone, without intervening soft tissue, a process called "osseointegration". Osseointegrated dental implants represent an advance in modern odontology, which has become a great option for the rehabilitation of missing single teeth in partially or totally edentulous patients. Despite the very high success rates [1], complications associated with implant treatment may occur. Early loading failure may affect 2% to 6% of implants, and as many as 15% of restorations fail as a result of this problem [2, 3]. Excess load on a final restoration after successful implant integration can result in failure of the implant itself [4]. Therefore, it is important to clarify the risk factors for failure of implant prostheses in order to further improve the good success rate.

The consequences of overload of dental implants can be divided into two groups: biological and biomechanical complications [5]. Biological complications can be divided into early failures and late failures [6]. In case of early failures, osseointegration was insufficient: the implant is lost before the first prosthetic loading. Late biological failures are characterized by pathological bone loss after full osseointegration was obtained at an earlier stage [7]. Late biological implant failures are associated with overload. Some insight into bone physiology is needed for a proper understanding of these

mechanisms [8–11]. In case of biomechanical complications, one or more components of an implant system fail, for example, fracture of an implant itself, loosening or fracture of connecting screws or abutment screws, loosening or excessive wear of mesostructural components in overdentures, and excessive wear or fracture of suprastructural porcelain or acrylic teeth [12, 13].

Bruxism is a movement disorder of the masticatory system that is expressed, among others, by tooth grinding and clenching, during sleep as well as during wakefulness [14, 15]. Especially, sleep bruxism is a repetitive sleep movement disorder characterized by rhythmic masticatory muscle activity (RMMA) at a frequency of approximately 1 Hz and by occasional tooth grinding. It is reported that during light sleep, most episodes of sleep bruxism (SB) are observed in relation to brief cardiac and brain reactivations termed "micro-arousals". RMMA is secondary to a sequence of events in relation to sleep microarousals: as a result of the increase in autonomic sympathetic activity, the heart and brain are activated in the minutes and seconds, respectively, before the onset of activity in the suprahyoid muscles and finally, RMMA occurs in the jaw-closing masseter and temporalis muscles [16]. Since SB is controlled by the central nervous system [17], it may be difficult to prevent the occurrence of bruxism events.

Clinical trials regarding the influence of bruxism on implant prostheses are scarce. Brägger et al. [18] recognized a causal relation between bruxism and fracture of the suprastructure, but they could not show the relation between bruxism and failure of the implant itself. On the other hand, Engel et al. [19] suggested that bruxism never affected the marginal bone loss of the dental implant. From these studies, it is difficult to conclude that bruxism is a risk factor for dental implants. Since most of the clinical research in dental implants excluded subjects with bruxism, there are only few research data on the influence of bruxism on dental implant outcome, and there is still no scientific evidence for a causal relation between bruxism and implant failure.

In this paper, the relation between occlusion and overload of dental implants is described, and the available evidence for a possible cause-and-effect relationship between bruxism and implant failure is discussed. Further, the possibility of clinical management of implant prostheses using an alteration of occlusal materials in the suprastructure and night guards in patients with bruxism is being presented.

2. Occlusal Considerations for Implant Prostheses

Taylor et al. suggested that since mastication is a side-to-side action that does not lend itself to axial loading of teeth or implants in the jaws, the damaging effects of bruxism are created through lateral friction between the occlusal surfaces of maxilla and mandible [20]. The attachment of natural teeth through periodontal ligaments and osseointegrated implants with a rigid bone contact in the jaw presents a significantly different environment, and this needs consideration. A natural tooth can be intruded about 50 μm by a light force (20 N) compared to only 2 μm for an osseointegrated implant [21]. In an animal study, Miyata et al. investigated the relationship between occlusal overload and peri-implant tissue and suggested that peri-implant bone resorption occurred under occlusal overload [22–24]. On the other hand, Heitz-Mayfield et al. demonstrated that a period of 8 months of excessive occlusal load on titanium implants did not result in loss of osseointegration or marginal bone loss when compared with nonloaded implants in animal study [25]. However, much of oral and masticatory function seems to be similar in natural and implant-supported dentitions [26–28]. The periodontal ligament is lost after tooth extraction, but most of its functional role as related to occlusion and mastication seems to be taken over by other mechanisms, such as, muscle spindles, mechanoreceptors in the temporomandibular joints [29]. Since successful long-term results of implant prostheses have been reported repeatedly, it may be concluded that the variety of methods related to occlusal morphology used in fixed prosthodontics on natural teeth are equally acceptable for rehabilitation on dental implants. The simple principles described for conventional prosthodontics may therefore be followed also for implant prostheses [21]. A literature review concluded that the occlusal scheme for an implant prosthesis should be designed to decrease cuspal interferences, centralize forces along the long axis, and minimize lateral forces; that is, it should be like that of a similar prosthesis on a natural dentition [30].

Since the occlusal perception level is higher for implant prostheses than for natural teeth, complaints of implant patients should be carefully considered when checking their occlusion. It is established that the lack of periodontal receptors leads to impaired fine motor control of the mandible in implant patients [31]. However, early studies concluded that the functional clinical capacity of patients with implant prostheses was almost equal to or approaching that of dentate subjects [32]. A study showing that the tactile sensibility of single-tooth implants opposing natural teeth was similar to that of pairs of opposing natural teeth led to the conclusion that the implants can be integrated in the stomatognathic control circuit [33].

3. Bruxism as Occlusal Risk Factors

In 1996, Lavigne et al. [34] proposed sleep bruxism research diagnostic criteria (SB-RDC) for polysomnographic recording, as follows: (1) a history of frequent tooth grinding occurring at least 3 nights per week for the preceding 6 months, as confirmed by a sleep partner; (2) clinical presence of tooth wear; (3) masseter muscle hypertrophy; (4) report of jaw muscle fatigue or tenderness in the morning. Bruxism is frequently considered an aetiological factor for temporomandibular disorders (TMDs), tooth wear (e.g., attrition), loss of periodontal support, and failure of dental restorations, although conflicting evidence for many of these purported aetiological relationships can be found in the literature [35–40]. Bruxism has also been suggested to cause excessive (occlusal) load of dental implants and

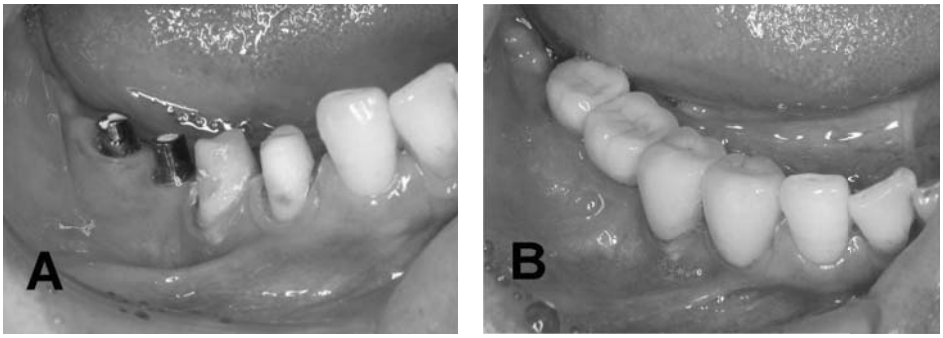

(a) (b)

Figure 1: Porcelain has become the primary occlusal material for single-tooth and partial fixed implant restorations.

their suprastructures, ultimately resulting in bone loss around the implants or even in implant failure. Therefore, bruxism is often considered a cause of concern or even a contraindication for implant treatment. In addition, many researchers use bruxism as an exclusion criterion for the selection of their participants in clinical studies concerning treatment modalities with dental implants [5].

Bruxism, other oral parafunctions, fractures of natural teeth resulting from occlusal forces, and lateral occlusal contacts on the implant prostheses were listed as important risk factors for dental implants and their suprastructures [41]. In a study of 379 patients who had used implant prostheses for many years, occlusal wear had no statistically significant impact on vertical peri-implant bone loss [19]. It was presupposed that occlusal wear was closely related to bruxism, and thus bruxism did not seem to be a risk factor for the examined variables. Tooth wear does not represent the actual/current bruxism status. It must be emphasized, of course, that bruxism is not the only cause of tooth wear and in fact is not a major factor [42]. A review of literature on dental implants in patients with bruxing habits concluded that, so far, studies on bruxism and implant failure do not yield consistent results [43]. However, a careful approach was recommended, although it was admitted that these recommendations were "experience based," not evidence based [21].

As many clinicians still have the impression that there is some relevance in these risk factors, it may be prudent to exercise caution, perform careful clinical control, and acknowledge the need for occlusal adjustments of the suprastructure in all implant patients [21]. When alarm signals are found, for example, repeated loosening or fracture of abutment screws and fracture of veneering material, a careful analysis of potential reasons for these signals should follow with the aim to modify the situation and reduce excessive risks [41].

4. Occlusal Material for the Suprastructure in Implant Prostheses

In the past decades, for implant prostheses, it was strongly recommended to use a shock-absorbing material, such as, acrylic resin on top of the superstructure, in order to protect the implant-bone interface [21]. Based on biomechanical analyses, acrylic resin denture teeth were therefore predominantly used during the initial years of dental implant use [44]. However, biomechanical calculations do not always stand the test in the clinic. In a clinical study on five subjects using fixed prostheses with either acrylic resin or porcelain occlusal surfaces, masticatory forces were recorded while the subjects chewed various foods. No differences related to tooth material could be detected in the load rates [45]. In a study covering 6 years, the use of porcelain instead of composite resin as occlusal material had no influence on the marginal bone height around the implants [46]. These findings can be interpreted as a support for the use of porcelain as occlusal material because no serious biological consequences of the hard material were reported. Furthermore, the most common complications of implant prostheses have been related to fractures of the acrylic resin of the prostheses [47]. Wear of acrylic occlusal surfaces increased substantially with time, according to a 15-year followup of fixed implant-supported prostheses in the edentulous maxilla [48].

In current clinical practice, porcelain has become the primary occlusal material for single-tooth and partial fixed implant prostheses (Figure 1). It is generally agreed that ceramic occlusal surfaces provide superior esthetics and wear resistance [21]. Regarding full-arch fixed prostheses on implants, metal ceramic prostheses are sometimes presented in clinical reports, but in many centers acrylic resin teeth continue to be the material of choice. In removable types of implant prostheses, for example, overdentures, polymer teeth are the most common ones [49]. Although there is no evidence regarding the preferred restorative materials in implant prosthesis for patients with bruxism, some clinicians prefer metal restorations and not porcelain to protect the implant prostheses in patients with bruxism, especially for second molar teeth in the maxilla (Figure 2). Evidently, more clinical trials are needed to provide evidence for these recommendations. More recently, framework or crowns in zirconia was also developed in this field. However, in a clinical trial on fractured dental zirconia implants, Gahlert et al. reported that "the patient with the fracture of the 4 mm diameter zirconia implant was adversely affected by strong

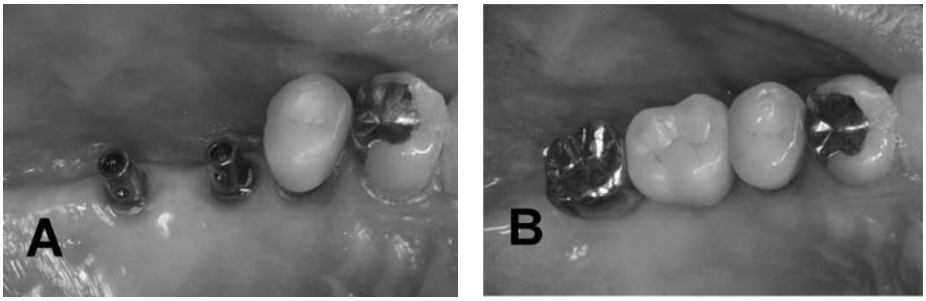

(a) (b)

Figure 2: Although there is no evidence regarding the preferred restorative materials in implant prosthesis for the patients with bruxism, some clinicians applied non porcelain but metal restorations to protect the implant prostheses in patients with bruxism, especially for second molar teeth in the maxilla (since there is no esthetic problem).

bruxism" [50]. Recently, some investigators demonstrated zirconia as a new dental implant material [51–53]. The development of new dental implant material might change the relationship between fractured dental implants and bruxism.

5. Night Guard and Pharmacological Approach for Bruxism

A night guard fabricated for the maxillary teeth can be a useful tool to evaluate the influence of the occlusion scheme and its relationship to nocturnal bruxism [4, 54]. Occlusal schemes and designs of fixed and removable implant prostheses must satisfy the requirements for an innocuous vertical loading of dental implants. Parafunctional habits (clenching or grinding) can transmit forces to the supporting bone that may result in destructive lateral stresses and overloading. The consequences of nocturnal parafunctional habits may be prevented by acrylic resin night guards [55]. A hard stabilization splint for nightly use (night guard) contributes to optimally distributing and vertically redirecting forces that go with nocturnal teeth grinding and clenching [5]. A night guard that promotes even occlusal contacts around the arch in centric-related occlusion can be helpful to prevent fractures of implant prostheses. This device may be fabricated with 0.5- to 1-mm colored acrylic resin on the occlusal surface. If the patient wears this device for 1 month, the consequences or intensity of the bruxism habit may be directly observed. If the colored acrylic is not worn through, the parafunction was not excessive [4]. As examples, when partial implant prosthesis is present in the maxilla, the night guard is hollowed out at the implant sites so no occlusal force is transmitted to the implant prostheses. When the partial restoration is in the mandible, the occluding surface of the guard is relieved over the implant prostheses so no occlusal force is transmitted to the implants. A soft material may also be placed around the crowns for stress relief and to decrease the impact force on the crowns (Figure 3). In this field, future clinical trials on possible new materials should be planned to investigate the protection of implant prostheses from bruxism.

Figure 3: A night guard may be one of the possible solutions to prevent overloading of the suprastructure of implant prostheses. Soft material also could be used for night guards.

On the other hand, some investigators proposed a pharmacological approach for bruxism patients with implant prostheses [56, 57], especially in cases where oral implants failed as a probable consequence of severe, polysomnographically confirmed sleep bruxism. As the patient had the wish to be reimplanted after this failure, the operators decided to try diminishing the frequency of bruxism and duration first. The selected management strategies, the administration of low doses of the dopamine D1/D2 receptor agonist pergolide finally resulted in a substantial and lasting reduction in the bruxism outcome measures under study.

6. Conclusion

Only little research has focused upon the clinical approach to protect implant prostheses from bruxism. The presented results do not reflect a high level of scientific evidence and may need modification when new research results or new dental implant materials appear. It is a fact that clinicians feel that the overload caused by bruxism may result in failure of implant supported prostheses. Following the recent developments with the introduction of immediate or early loading, the clinical management of bruxism will become an important subject for implant prostheses. The lack of well-designed clinical trials regarding the consequence of bruxism on implant prostheses poses a serious problem. At present, expert opinion and cautionary approaches are still

considered the best available sources for suggesting good practice indicators. There is an urgent need for those actively engaged in clinical research centers and university research institutes to provide evidence on whether the subjective feeling of clinicians regarding the approach of bruxism in implant patients is correct or not.

References

[1] R. Adell, B. Eriksson, U. Lekholm, P. I. Brånemark, and T. Jemt, "Long-term follow-up study of osseointegrated implants in the treatment of totally edentulous jaws," *The International Journal of Oral & Maxillofacial Implants*, vol. 5, no. 4, pp. 347–359, 1990.

[2] C. E. Misch, "Density of bone: effect on treatment plans, surgical approach, healing, and progressive boen loading," *The International Journal of Oral Implantology*, vol. 6, no. 2, pp. 23–31, 1990.

[3] T. Jernt, B. Lindén, and U. Lekholm, "Failures and complications in 127 consecutively placed fixed partial prostheses supported by Brånemark implants: from prosthetic treatment to first annual checkup," *The International Journal of Oral & Maxillofacial Implants*, vol. 7, no. 1, pp. 40–44, 1992.

[4] C. E. Misch, "The effect of bruxism on treatment planning for dental implants," *Dentistry Today*, vol. 21, no. 9, pp. 76–81, 2002.

[5] F. Lobbezoo, J. E. I. G. Brouwers, M. S. Cune, and M. Naeije, "Dental implants in patients with bruxing habits," *Journal of Oral Rehabilitation*, vol. 33, no. 2, pp. 152–159, 2006.

[6] M. S. Tonetti and J. Schmid, "Pathogenesis of implant failures," *Periodontology 2000*, vol. 4, pp. 127–138, 1994.

[7] T. Albrektsson, G. Zarb, and A. R. Eriksson, "The long-term efficacy of currently used dental implants: a review and proposed criteria of success," *The International Journal of Oral & Maxillofacial Implants*, vol. 1, no. 1, pp. 11–25, 1986.

[8] J. B. Brunski, "In vivo bone response to biomechanical loading at the bone/dental-implant interface," *Advances in Dental Research*, vol. 13, pp. 99–119, 1999.

[9] S. J. Hoshaw, J. B. Brunski, and G. V. B. Cochran, "Mechanical overloading of Branemark implants affects interfacial bone modeling and remodeling," *Journal of Oral Surgery*, vol. 9, pp. 345–360, 1994.

[10] F. Isidor, "Loss of osseointegration caused by occlusal load of oral implants: a clinical and radiographic study in monkeys," *Clinical Oral Implants Research*, vol. 7, no. 4, pp. 143–152, 1996.

[11] F. Isidor, "Histological evaluation of peri-implant bone at implants subjected to occlusal overload or plaque accumulation," *Clinical Oral Implants Research*, vol. 8, no. 1, pp. 1–9, 1997.

[12] T. Berglundh, L. Persson, and B. Klinge, "A systematic review of the incidence of biological and technical complications in implant dentistry reported in prospective longitudinal studies of at least 5 years," *Journal of Clinical Periodontology*, vol. 29, no. 3, pp. 197–212, 2002.

[13] C. Göthberg, T. Bergendal, and T. Magnusson, "Complications after treatment with implant-supported fixed prostheses: a retrospective study," *International Journal of Prosthodontics*, vol. 16, no. 2, pp. 201–217, 2003.

[14] AASM, *International Classification of Sleep Disorders*, American Academy of Sleep Medicine, Westchester, NY, USA, 2nd edition, 2005.

[15] J. P. Okeson, *Orofacial Pain. Guidelines for Assessment, Diagnosis, and Management*, Quintessence Publishing, Chicago, Ill, USA, 1996.

[16] G. J. Lavigne, N. Huynh, T. Kato et al., "Genesis of sleep bruxism: motor and autonomic-cardiac interactions," *Archives of Oral Biology*, vol. 52, no. 4, pp. 381–384, 2007.

[17] F. Lobbezoo and M. Naeije, "Bruxism is mainly regulated centrally, not peripherally," *Journal of Oral Rehabilitation*, vol. 28, no. 12, pp. 1085–1091, 2001.

[18] U. Brägger, S. Aeschlimann, W. Bürgin, C. H. F. Hämmerle, and N. P. Lang, "Biological and technical complications and failures with fixed partial dentures (FPD) on implants and teeth after four to five years of function," *Clinical Oral Implants Research*, vol. 12, no. 1, pp. 26–34, 2001.

[19] E. Engel, G. Gomez-Roman, and D. Axmann-Krcmar, "Effect of occlusal wear on bone loss and periotest value of dental implants," *International Journal of Prosthodontics*, vol. 14, no. 5, pp. 444–450, 2001.

[20] T. D. Taylor, J. Wiens, and A. Carr, "Evidence-based considerations for removable prosthodontic and dental implant occlusion: a literature review," *Journal of Prosthetic Dentistry*, vol. 94, no. 6, pp. 555–560, 2005.

[21] T. Haraldson, G. E. Carlsson, and B. Ingervall, "Functional state, bite force and postural muscle activity in patients with osseointegrated oral implant bridges," *Acta Odontologica Scandinavica*, vol. 37, no. 4, pp. 195–206, 1979.

[22] T. Miyata, Y. Kobayashi, H. Araki, Y. Motomura, and K. Shin, "The influence of controlled occlusal overload on peri-implant tissue: a histologic study in monkeys," *International Journal of Oral and Maxillofacial Implants*, vol. 13, no. 5, pp. 677–683, 1998.

[23] T. Miyata, Y. Kobayashi, H. Araki, T. Ohto, and K. Shin, "The influence of controlled occlusal overload on peri-implant tissue. Part 3: a histologic study in monkeys," *International Journal of Oral and Maxillofacial Implants*, vol. 15, no. 3, pp. 425–431, 2000.

[24] T. Miyata, Y. Kobayashi, H. Araki, T. Ohto, and K. Shin, "The influence of controlled occlusal overload on peri-implant tissue. Part 4: a histologic study in monkeys," *International Journal of Oral and Maxillofacial Implants*, vol. 17, no. 3, pp. 384–390, 2002.

[25] L. J. Heitz-Mayfield, B. Schmid, C. Weigel et al., "Does excessive occlusal load affect osseointegration? An experimental study in the dog," *Clinical Oral Implants Research*, vol. 15, no. 3, pp. 259–268, 2004.

[26] D. Lundgren, L. Laurell, H. Falk, and T. Bergendal, "Occlusal force pattern during mastication in dentitions with mandibular fixed partial dentures supported on osseointegrated implants," *The Journal of Prosthetic Dentistry*, vol. 58, no. 2, pp. 197–203, 1987.

[27] H. Falk, "On occlusal forces in dentitions with implant-supported fixed cantilever prostheses," *Swedish Dental Journal. Supplement*, vol. 69, pp. 1–40, 1990.

[28] M. Abarca, D. van Steenberghe, C. Malevez, and R. Jacobs, "The neurophysiology of osseointegrated oral implants: a clinically underestimated aspect," *Journal of Oral Rehabilitation*, vol. 33, no. 3, pp. 161–169, 2006.

[29] G. E. Carlsson, "Dental occlusion: modern concepts and their application in implant prosthodontics," *Odontology*, vol. 97, no. 1, pp. 8–17, 2009.

[30] M. R. Wood and S. G. Vermilyea, "A review of selected dental literature on evidence-based treatment planning for dental

implants: report of the Committee on Research in Fixed Prosthodontics of the Academy of Fixed Prosthodontics," *Journal of Prosthetic Dentistry*, vol. 92, no. 5, pp. 447–462, 2004.

[31] M. Trulsson, "Sensory and motor function of teeth and dental implants: a basis for osseoperception," *Clinical and Experimental Pharmacology and Physiology*, vol. 32, no. 1-2, pp. 119–122, 2005.

[32] S. Lundqvist and T. Haraldson, "Occlusal perception of thickness in patients with bridges on osseointegrated oral implants," *Scandinavian Journal of Dental Research*, vol. 92, no. 1, pp. 88–95, 1984.

[33] N. Enkling, C. Nicolay, K. H. Utz, P. Jöhren, G. Wahl, and R. Mericske-Stern, "Tactile sensibility of single-tooth implants and natural teeth," *Clinical Oral Implants Research*, vol. 18, no. 2, pp. 231–236, 2007.

[34] G. J. Lavigne, P. H. Rompré, and J. Y. Montplaisir, "Sleep bruxism: validity of clinical research diagnostic criteria in a controlled polysomnographic study," *Journal of Dental Research*, vol. 75, no. 1, pp. 546–552, 1996.

[35] G. J. Lavigne, P. H. Rompré, J. Y. Montplaisir, and F. Lobbezoo, "Motor activity in sleep bruxism with concomitant jaw muscle pain: a retrospective pilot study," *European Journal of Oral Sciences*, vol. 105, no. 1, pp. 92–95, 1997.

[36] F. Lobbezoo and G. J. Lavigne, "Do bruxism and temporomandibular disorders have a cause-and-effect relationship?" *Journal of Orofacial Pain*, vol. 11, no. 1, pp. 15–23, 1997.

[37] M. T. John, H. Frank, F. Lobbezoo, M. Drangsholt, and K. E. Dette, "No association between incisal tooth wear and temporomandibular disorders," *Journal of Prosthetic Dentistry*, vol. 87, no. 2, pp. 197–203, 2002.

[38] G. J. Lavigne, T. Kato, A. Kolta, and B. J. Sessle, "Neurobiological mechanisms involved in sleep bruxism," *Critical Reviews in Oral Biology and Medicine*, vol. 14, no. 1, pp. 30–46, 2003.

[39] C. Hirsch, M. T. John, F. Lobbezoo, J. M. Setz, and H. G. Schaller, "Incisal tooth wear and self-reported temporomandibular disorder pain in children and adolescents," *International Journal of Prosthodontics*, vol. 17, no. 2, pp. 151–156, 2004.

[40] F. Lobbezoo, J. van der Zaag, C. M. Visscher, and M. Naeije, "Oral kinesiology: a new postgraduate programme in the Netherlands," *Journal of Oral Rehabilitation*, vol. 31, no. 3, pp. 192–198, 2004.

[41] D. Manfredini and F. Lobbezoo, "Relationship between bruxism and temporomandibular disorders: a systematic review of literature from 1998 to 2008," *Oral Surgery, Oral Medicine, Oral Pathology, Oral Radiology and Endodontology*, vol. 109, no. 6, pp. e26–e50, 2010.

[42] A. Johansson, A. K. Johansson, R. Omar, and G. E. Carlsson, "Rehabilitation of the worn dentition," *Journal of Oral Rehabilitation*, vol. 35, no. 7, pp. 548–566, 2008.

[43] F. Lobbezoo, J. van der Zaag, and M. Naeije, "Bruxism: its multiple causes and its effects on dental implants—an updated review," *Journal of Oral Rehabilitation*, vol. 33, no. 4, pp. 293–300, 2006.

[44] R. Skalak, "Biomechanical considerations in osseointegrated prostheses," *The Journal of Prosthetic Dentistry*, vol. 49, no. 6, pp. 843–848, 1983.

[45] J. A. Hobkirk and K. J. Psarros, "The influence of occlusal surface material on peak masticatory forces using osseointegrated implant-supported prostheses," *The International Journal of Oral & Maxillofacial Implants*, vol. 7, no. 3, pp. 345–352, 1992.

[46] I. Naert, M. Quirynen, D. van Steenberghe, and P. Darius, "A six-year prosthodontic study of 509 consecutively inserted implants for the treatment of partial edentulism," *The Journal of Prosthetic Dentistry*, vol. 67, no. 2, pp. 236–245, 1992.

[47] B. Carlson and G. E. Carlsson, "Prosthodontic complications in osseointegrated dental implant treatment," *The International Journal of Oral & Maxillofacial Implants*, vol. 9, no. 1, pp. 90–94, 1994.

[48] T. Jemt and J. Johansson, "Implant treatment in the edentulous maxillae: a 15-year follow-up study on 76 consecutive patients provided with fixed prostheses," *Clinical Implant Dentistry and Related Research*, vol. 8, no. 2, pp. 61–69, 2006.

[49] J. S. Feine and G. E. Carlsson, Eds., *Implant over Dentures: The Standard of Care for Edentulous Patients*, Quintessence, Chicago, Ill, USA, 2003.

[50] M. Gahlert, D. Burtscher, I. Grunert, H. Kniha, and E. Steinhauser, "Failure analysis of fractured dental zirconia implants," *Clinical Oral Implants Research*, vol. 23, pp. 287–293, 2011.

[51] B. Al-Amleh, K. Lyons, and M. Swain, "Clinical trials in zirconia: a systematic review," *Journal of Oral Rehabilitation*, vol. 37, no. 8, pp. 641–652, 2010.

[52] M. Karl, F. Graef, and M. Wichmann, "Strain development of implant-supported fixed prostheses copy milled from zirconia ceramic," *International Journal of Prosthodontics*, vol. 24, pp. 479–481, 2011.

[53] J. Abduo, K. Lyons, N. Waddell, V. Bennani, and M. Swain, "A comparison of fit of CNC-milled titanium and zirconia frameworks to implants," *Clinical Implant Dentistry and Related Research*. In press.

[54] M. L. Perel, "Parafunctional habits, nightguards, and root form implants," *Implant Dentistry*, vol. 3, no. 4, pp. 261–263, 1994.

[55] T. Tosun, C. Karabuda, and C. Cuhadaroglu, "Evaluation of sleep bruxism by polysomnographic analysis in patients with dental implants," *International Journal of Oral and Maxillofacial Implants*, vol. 18, no. 2, pp. 286–292, 2003.

[56] J. van der Zaag, F. Lobbezoo, P. G. G. L. van der Avoort, D. J. Wicks, H. L. Hamburger, and M. Naeije, "Effects of pergolide on severe sleep bruxism in a patient experiencing oral implant failure," *Journal of Oral Rehabilitation*, vol. 34, no. 5, pp. 317–322, 2007.

[57] F. Lobbezoo, J. van der Zaag, M. K. A. van Selms, H. L. Hamburger, and M. Naeije, "Principles for the management of bruxism," *Journal of Oral Rehabilitation*, vol. 35, no. 7, pp. 509–523, 2008.

Hindawi Publishing Corporation
International Journal of Biomaterials
Volume 2012, Article ID 743465, 6 pages
doi:10.1155/2012/743465

Research Article

MC3T3-E1 Cells on Titanium Surfaces with Nanometer Smoothness and Fibronectin Immobilization

Tohru Hayakawa,[1] Eiji Yoshida,[1] Yoshitaka Yoshimura,[2] Motohiro Uo,[3] and Masao Yoshinari[4]

[1] *Department of Dental Engineering, Tsurumi University School of Dental Medicine, 2-1-3 Tsurumi, Tsurumi-ku, Yokohama 230-8501, Japan*
[2] *Department of Molecular Cell Pharmacology, Hokkaido University Graduate School of Dental Medicine, Kita 13, Nishi 7, Kita-ku, Sapporo 060-8586, Japan*
[3] *Advanced Biomaterials, Division of Oral Health Sciences, Department of Restorative Sciences, Graduate School of Medical and Dental Sciences, Tokyo Medical and Dental University, 1-5-45, Yushima, Bunkyo-ku, Tokyo 113-8549, Japan*
[4] *Division of Oral Implants Research, Oral Health Science Center, Tokyo Dental College, 1-2-2 Masago, Mihama-ku, Chiba 261-8502, Japan*

Correspondence should be addressed to Tohru Hayakawa, hayakawa-t@tsurumi-u.ac.jp

Received 14 February 2012; Accepted 24 March 2012

Academic Editor: Yasuhiro Tanimoto

Copyright © 2012 Tohru Hayakawa et al. This is an open access article distributed under the Creative Commons Attribution License, which permits unrestricted use, distribution, and reproduction in any medium, provided the original work is properly cited.

The present study was aimed to evaluate the viability and total protein contents of osteoblast-like cells on the titanium surface with different surface mechanical treatment, namely, nanometer smoothing (Ra: approximately 2.0 nm) and sandblasting (Ra: approximately 1.0 μm), and biochemical treatment, namely, with or without fibronectin immobilization. Fibronectin could be easily immobilized by tresyl chloride-activation technique. MC3T3-E1 cells were seeded on the different titanium surfaces. Cell viability was determined by MTT assay. At 1 day of cell culture, there were no significant differences in cell viability among four different titanium surfaces. At 11 days, sandblasted titanium surface with fibronectin immobilization showed the significantly highest cell viability than other titanium surface. No significant differences existed for total protein contents among four different titanium surfaces at 11 days of cell culture. Scanning electron microscopy observation revealed that smoothness of titanium surface produced more spread cell morphologies, but that fibronectin immobilization did not cause any changes of the morphologies of attached cells. Fibronectin immobilization provided greater amount of the number of attached cells and better arrangement of attached cells. In conclusion, the combination of sandblasting and fibronectin immobilization enhanced the cell viability and fibronectin immobilization providing better arrangements of attached cells.

1. Introduction

Various mechanical and chemical surface modifications of titanium dental implants, such as blasting, alkaline treatment, or hydroxyapatite coating, have been reported for improving the bone response during healing process [1–4]. Some reported the effectiveness of the surface coating or immobilization with cell adhesive protein, such as, fibronectin (FN) or laminin, for enhancing cell attachment, cell spreading, and cell activity [5, 6].

For biochemical surface treatment, several methods for covalent immobilization of cell adhesive proteins have been reported. Silane coupling reagents have been widely used for the immobilization of cell adhesive proteins [7–10]. On the contrary, Hayakawa et al. reported an easy and simple method for the immobilization of cell adhesive proteins onto a titanium surface, which was named the tresyl chloride-activated method [11, 12]. This method was a modified version of the method reported by Nilsson and Mosbach [13]. Tresyl chloride (2,2,2-trifluoroethanesulfonyl chloride) is a liquid. Hayakawa et al. applied tresyl chloride directly on the titanium surface without the use of any solvent and found the basic hydroxyl groups of the titanium surface reacted with tresyl chloride [11, 12]. Cell adhesive protein could be easily immobilized onto titanium surface through ionic interaction as shown in Figure 1, which was confirmed by quarts-crystal

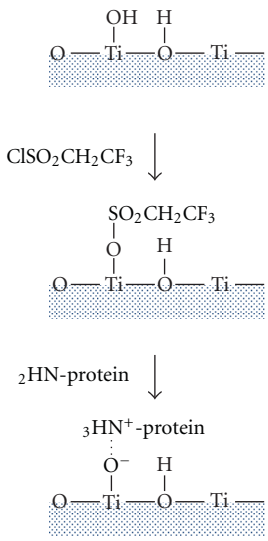

Figure 1: Presumed mechanism for fibronectin immobilization using tresyl chloride-activated technique.

microbalance-dissipation measurements [14]. Fibronectin-, collagen-, and fibronectin-derived peptides could be easily immobilized onto a titanium surface. Gene expression of osteoblast-like cells was monitored on titanium immobilized with fibronectin or fibronectin-derived GRGDSP peptide and it was found that the expression levels of some genes related to the mineralization process, for example, bone sialoprotein and osteomodulin, were upregulated [15–17].

Roughness of a titanium surface also influenced the bone response after the implantation. Many studies have shown that a rougher surface provided better bone formation or osteoconduction compared with a smooth surface [18]. However, the issues of optimal surface roughness and superficial morphology are still controversial and need to be clarified. Larsson et al. reported that differences of surface roughness between Ra = 30.3 μm (machined) and Ra = 2.9 nm (electropolishing) varied the amount of bone after 6 weeks of implantation in rabbit cortical bone but not after 1 year of implantation [19]. Wu et al. investigated human fetal osteoblastic cell behavior on titanium surfaces with different roughness [20]. They reported that the roughest plasma-sprayed surface (Ra = 33 nm) exhibited the highest number of cell attachment cells and ALP activity. However, they also reported that the ALP level of the polished surface with nanometer smoothness (Ra = 6 nm) was much higher than that of the satin- (Ra = 0.83 μm) and grit-blasted (Ra = 11 μm) groups at 16 days of cell culture.

Previously we investigated the influence of two different surface roughness, namely, nanometer smoothing (Ra: approximately 2.0 nm) and sandblasting (Ra: approximately 1.0 μm), as well as biochemical treatment, namely, fibronectin immobilization using tresyl chloride-activated technique, of a titanium surface on osteoblast-like cell behavior [21]. It was reported that the nanometer-smooth surface was beneficial for the differentiation of MC3T3-E1 cells and that FN immobilization provided better arrangement of attached cells.

In the present study, we aimed to evaluate cell viability of MC3T3-E1 and total protein content on the above-mentioned four different titanium surfaces, as a next series of our experiments. Cell viability was determined by MTT assay. The morphologies of attached cell were observed by scanning electron microscope (SEM).

2. Materials and Methods

2.1. Nanometer-Smoothing and Sandblasting of Titanium Surface. Commercially pure titanium disk (ϕ = 15 mm × 1.0 mm, JIS, Japan Industrial Specification H 4600, 99.9 mass% Ti, Furuuchi Chemical Corp., Tokyo) was used. Nanometer-smooth titanium surface (Ti-smooth) was prepared by polishing with diamond slurry with diamond particle diameters of 6 μm, 3 μm, and finally 1 μm using a rapping machine (Rapping machine 12 in, TDC, Corp., Miyagi, Japan). After polishing, the specimen was cleaned with ethanol. Sandblasted surface (Ti sand) was prepared by sandblasting with alumina powder (50 μm) at 5 atmospheric pressures for 5 s. After sandblasting, the specimen was cleaned ultrasonically with acetone-distilled water mixture and was then cleaned with 10 wt% HF and 5 wt% HNO_3 aqueous mixture for 20 s to remove any remaining alumina powder. Finally, the sandblasted specimen was cleaned ultrasonically again with acetone-distilled water mixture.

The surface roughness of nanometer-smooth titanium disk, which was determined with Talysurf CCI3000 (0.35 mm length and 12 nm pitch, Ametek Co., Ltd. Tokyo, Japan), was 2.0 ± 0.9 nm, and that of sandblasted titanium disk determined with SURFCOM-30A (Tokyo Seimitsu, Japan, 4 mm scale length and 0.8 mm pt.) was 1.0 ± 0.7 μm. Five specimens of each type were measured.

2.2. FN Immobilization. FN immobilization on the titanium was performed in accordance with previous reports [11, 12] Ti smooth and Ti sand disks were completely covered with tresyl chloride (Fluka, Buchs, Switzerland) and then stored at 37°C for two days. Tresyl chloride is a liquid with a boiling point of 140-141°C. Afterwards, tresylated titanium disks were washed with double-distilled water followed by double-distilled water-acetone solution (50 : 50) and then dried and stored in a desiccator.

Human plasma fibronectin (Harbor Bio-Products, MA, USA) was dissolved in phosphate-buffered saline (PBS) solution (pH 7.4) at a concentration of 100 μg/mL for cell attachment assay. Tresylated titanium disks were immersed in the fibronectin-PBS solution for 24 hours at 37°C and then rinsed with double-distilled water. Finally, the titanium disks were dried with a gentle stream of dry air and stored in a desiccator. Thus, fibronectin-immobilized Ti smooth (Ti smooth/FN) and Ti sand (Ti-sand/FN) disks were prepared. The FN immobilization was confirmed by an X-ray photoelectron spectroscope (XPS; Axis Ultra, Kratos Analytical, UK), which was equipped with a monochromatized AlKα X-ray source operated at 15 kV and 15 mA. The binding energy scale for each spectrum was calibrated against the C1s peak at 284.8 eV. An N1s peak of amide bonds in fibronectin was detected at 399.9 eV.

2.3. Cell Culture. Murine osteoblastic MC3T3-E1 cells (Riken Cell Bank no. RCB1126, Ibaraki, Japan) were used. The cells were cultured in α·MEM (Invitrogen, MD, USA) supplemented with 10% heat-inactivated fetal bovine serum, 66.7 μg/mL kanamycin sulfate, and 284 μM L-ascorbic acid 2-phosphate at 37°C in a humidified atmosphere of 95% air and 5% CO_2. Subsequently, the cells were cultured to subconfluence in 100 mm standard dishes (Falcon, Becton-Dickinson Labware, Franklin Lakes, NJ, USA) and transferred to Bioflex collagen I-coated 24-well plates (Falcon) after treatment with 0.25% trypsin/EDTA (Invitrogen, MD, USA). The culture medium was changed every three days. Classical medium without any bone differentiation components was employed in the preset study for evaluating the influence of fibronectin immobilization and surface roughness on the cell behavior [22, 23].

Four different surfaces, that are, Ti smooth, Ti smooth/FN,Ti sand, and Ti sand/FN were evaluated by cell assay. Each titanium disk was sterilized with ethyleneoxide gas.

2.4. MTT Assay. MC3T3-E1 cells were seeded on each titanium disc in 24-well plates at a density of 5×10^4 cells/cm^2 and incubated for 11 days. The culture medium was changed every three days. Cell viability was determined by (3-(4,5-di-methylthiazol-2-yl)-2,5-diphenyltetrazolium bromide (MTT) assay by using ViaLight Plus Kit (Lonza Group Ltd, Basel, Switzerland). At predetermined time intervals (1 and 11 days), attached cells were rinsed with PBS and 200 μL of culture medium was added. Then, 200 μL of the cell lysis reagent was added, and cells were incubated in the orbital shaker for 10 min at 600 rpm, and 100 μL of cell medium was transferred to a white plate. Afterwards, 100 μL of ATP Monitoring Reagent Plus was added, and the plate was incubated for 2 min in the dark condition (inside the luminometer) before the measurement. Measurement was taken with the plate reader (Wallac 1420 ARVOsx, PerkinElmer, Inc., MA, USA). Four runs were performed and four specimens were analyzed for each substrate and each period.

2.5. Total Protein Content. MC3T3-E1 cells were seeded on each titanium disc in 24-well plates at a density of 5×10^4 cells/cm^2 and incubated for 11 days. To determine the total cellar protein, BCA Protein Assay kit (Thermo Fisher Scientific K.K. MA, USA) was used. 200 μL of the cell lysis reagent was added to each well, and then 10 μL of each specimen was pipette and 90 μL of cell lysis buffer was added into a 96-well plate. 100 μL of the reagent (micro BCA kit; Thermo Fisher Scientific Inc., MA, USA) was added to each well and was mixed. The enzyme reactions were conducted for 30 min at 37°C, and absorbency at 570 nm was immediately measured using a plate reader (Bio Rad model 550, Bio-Rad Laboratories, Inc. CA, USA). Four runs were performed and four specimens were analyzed for each substrate.

2.6. SEM Observation. After 1 day of cell culture, titanium disks were rinsed thoroughly in PBS, mounted on a piece of cork, and fixed in 2.5% glutaraldehyde in phosphate buffer (pH 7.4). Following fixation, disks were dehydrated through a graded series of ethanol (50, 60, 70, 80, 90, 95, and 100%) and then dried with tetramethylsilane. After ion coating with gold, the morphology of the cells was observed using a scanning electron microscope (S4000, HITACHI, Tokyo, Japan) at an accelerating voltage of 5 kV.

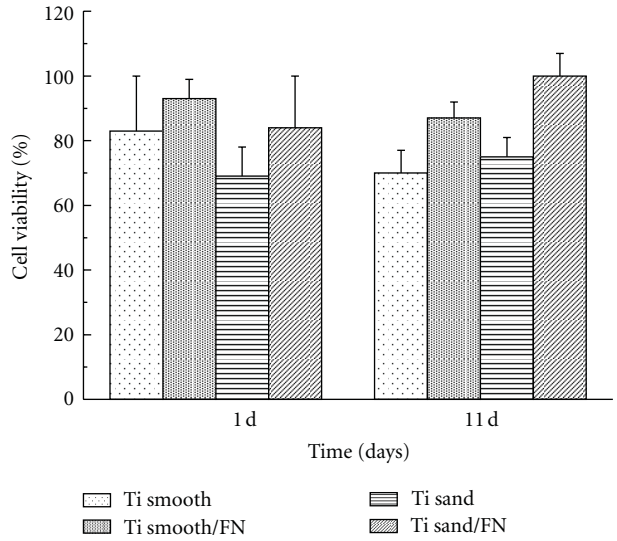

Figure 2: Cell viability determined by MTT assay.

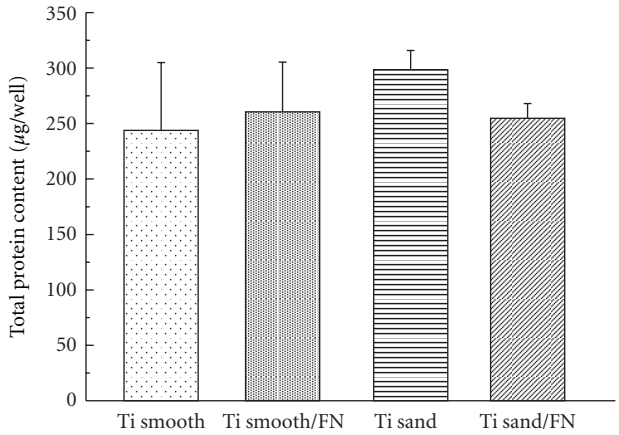

Figure 3: Total protein contents.

2.7. Statistics. Significant differences were determined by one-way analysis of variance (ANOVA) using GraphPad software (Graphpad Prism, GraphPad Software Inc., San Diego, California, USA). Statistical significance was set at $P < 0.05$.

3. Results

The results of MTT assay are shown in Figure 2. At 1 day of cell culture, there were no significant differences among four different titanium surfaces. At 11 days, Ti sand/FN showed the significantly highest cell viability than

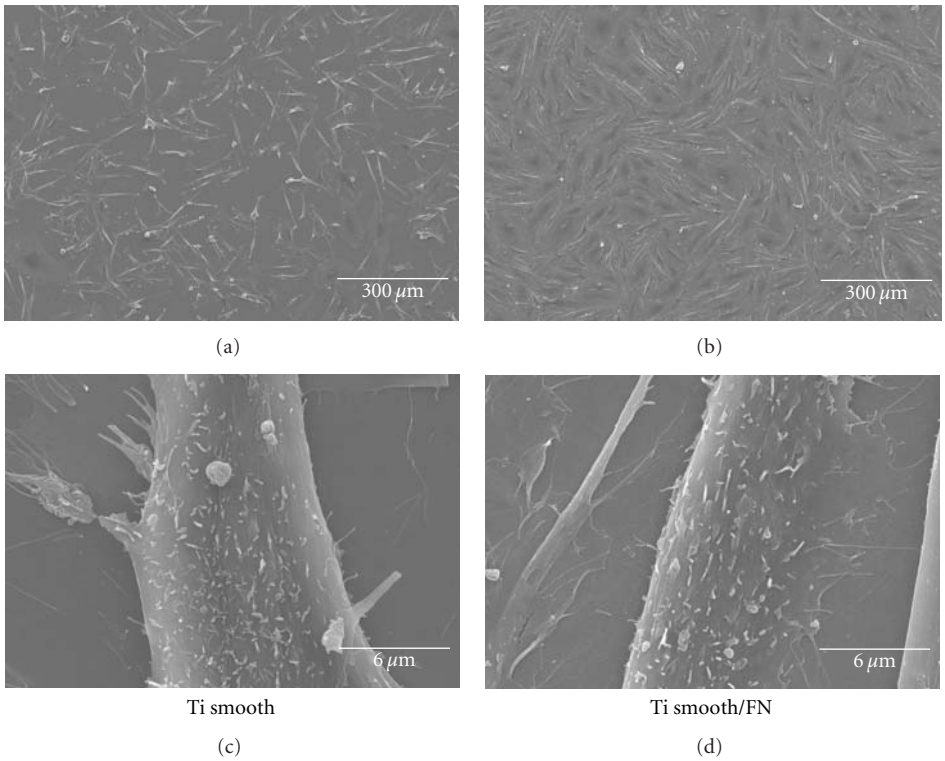

Figure 4: SEM views of MC3T3-E1 cells cultured on Ti smooth and Ti smooth/FN titanium disk at 1 day of culture.

Ti sand, no significant differences were detected between Ti smooth/FN and Ti smooth. Between 1 day and 11 days of cell culture, there were no significant differences for each titanium surface.

Figure 3 shows the results of measurement of total protein contents at 11 days. No significant differences existed for total protein contents among four different titanium surfaces.

Figures 4 and 5 show the SEM views of attached cells after 1 day of cell culture. Smoothness of titanium surface affected the cell morphologies. On the other hand, FN immobilization did not have any influence on the morphologies of attached cells but did have some influence on the number of attached cells.

Cells attached on nanometer smooth titanium (Ti smooth, Ti smooth/FN) showed the flat shape with a large and thin cytoplasmic layer and with numerous filopodia. The filopodia was extending from the cell body to the titanium surface and higher magnification indicated the presence of short-fiber-like structure, which is presumed to be microvilli. Comparing Ti smooth and Ti smooth/FN, Ti smooth/FN surface showed more attached cells and attached cells showed better arrangement on Ti smooth/FN surface rather than on Ti smooth (Figure 3).

Attached cells on sandblasted surface (Ti sand and Ti sand/FN) were slightly less spread than on nanometer smooth surface (Ti smooth, Ti smooth/FN). Some of them had a globular appearance, especially cell on Ti sand/FN. More globular structure was observed on Ti sand/FN and higher magnification clearly showed the globular structure of attached cell (Figure 4).

4. Discussion

In this study, we evaluated cell viability and total protein contents of MC3T3-E1 cells on four different titanium surfaces, Ti smooth, Ti smooth/FN, Ti sand, and Ti sand/FN. The influences of mechanical treatment (nanometer smoothing and sandblasting) and biochemical treatment (with and without fibronectin immobilization) of a titanium surface were investigated.

Previously, we monitored DNA amounts, ALP activity, octeocalcin production and mineralization behavior to four different surfaces same as the present study [21]. It revealed that surface roughness enhanced the differentiation of MC3T3-E1 but not FN immobilization.

The cell viability for Ti sand/FN showed greater cell viability than that for Ti sand. Although the reason is not clear, the combination of sandblasting and FN immobilization provided better cell viability. Only FN immobilization did not affect cell viability.

Pugdee et al. reported that significantly more MC3T3-E1 cells attached to FN-immobilized titanium disk than to untreated titanium disk at 30 min after cell seeding [16]. However, the present study showed no remarkable enhancement of cell attachment by FN immobilization, which was determined by total protein contents. It is presumed that the controversial results were caused by the difference of cell assay time, 30 min versus 11 days and the difference of number of seeded cells, 1×10^5 versus 5×10^4 cells/cm^2. FN is a major extracellular matrix protein, and cultured cells produce FN by themselves during cell assay. It concluded that



Figure 5: SEM views of MC3T3-E1 cells cultured on Ti sand and Ti sand/FN titanium disk at 1 day of culture.

FN immobilization only enhanced the initial cell attachment, not proliferation.

Cell on Ti sand/FN showed the highest cell viability, but not the highest total protein contents. It is suggested that the activities and/or morphologies of cells on Ti sand/FN were influenced by the combination of surface roughness and FN immobilization. The details of the mechanism are indistinct.

SEM observation appeared that more attached cells were present on the Ti smooth/FN surface than on Ti smooth. Moreover, well-arranged cells could be observed on Ti smooth/FN. This was corresponded with the previous results [21]. It is presumed that cells can recognize immobilized FN on titanium surface. Therefore, the arrangement of attached cells is controlled by the presence of immobilized FN.

Mineralization induction medium was not used in the present cell assay experiments. Classical medium without any bone differentiation components was employed in the preset study for evaluating the influence of fibronectin immobilization and surface roughness on the cell behavior [22, 23].

FN could be easily immobilized on both nanometersmooth and sandblasted titanium surfaces by our originally developed method, namely, the tresyl chloride-activation technique [11, 12]. The advantage of the tresyl chloride-activation technique is its simplicity. The titanium surface needs no pretreatment, such as passive oxidation, alkaline treatment. For example, Nanci et al. immobilized alkaline phosphatase or albumin to titanium [8]. First they treated titanium surface with a mixture of sulfuric acid and hydrogen peroxide to reproduce titanium oxide surface layer and then applied-silane-coupling agents to oxide titanium layer for the immobilization of proteins. Another advantage of tresyl chloride-activation technique is that any types of proteins and cytokine such as BMP or TGF-β can be immobilized on titanium. The influence of the immobilization of other types of proteins or cytokines, for example, laminin or BMP, on the cell behaviors should be further investigated.

Acknowledgments

This study was supported in part by Grants-in-Aid for Scientific Research (B) (23390453) from the Japan Society for the Promotion of Science. We are grateful to TDC Corporation for their help in preparing nanometer-smooth titanium surface.

References

[1] J. L. Ong and D. C. N. Chan, "Hydroxyapatite and their use as coatings in dental implants: a review," *Critical Reviews in Biomedical Engineering*, vol. 28, no. 5-6, pp. 667–707, 2000.

[2] K. Nishio, M. Neo, H. Akiyama et al., "The effect of alkali- and heat-treated titanium and apatite-formed titanium on osteoblastic differentiation of bone marrow cells," *Journal of Biomedical Materials Research*, vol. 52, pp. 652–661, 2000.

[3] D. Buser, N. Broggini, M. Wieland et al., "Enhanced bone apposition to a chemically modified SLA titanium surface," *Journal of Dental Research*, vol. 83, no. 7, pp. 529–533, 2004.

[4] R. Junker, A. Dimakis, M. Thoneick, and J. A. Jansen, "Effects of implant surface coatings and composition on

bone integration: a systematic review," *Clinical Oral Implants Research*, vol. 20, no. 4, pp. 185–206, 2009.

[5] S. Bierbaum, U. Hempel, U. Geissler et al., "Modification of Ti6Al4V surfaces using collagen I, III, and fibronectin. II. Influence on osteoblast responses," *Journal of Biomedical Materials Research A*, vol. 67, pp. 431–438, 2003.

[6] R. Beutner, J. Michael, B. Schwenzer, and D. Scharnweber, "Biological nano-functionalization of titanium-based biomaterial surfaces: a flexible toolbox," *Journal of the Royal Society Interface*, vol. 7, no. 1, pp. S93–S105, 2010.

[7] K. Endo, "Chemical modification of metallic implant surfaces with biofunctional proteins (Part 1). Molecular structure and biological activity of a modified NiTi alloy surface.," *Dental materials journal*, vol. 14, no. 2, pp. 185–198, 1995.

[8] A. Nanci, J. D. Wuest, L. Peru et al., "Chemical modification of titanium surfaces for covalent attachment of biological molecules," *Canadian Association of Radiologists Journal*, vol. 49, no. 1, pp. 324–335, 1998.

[9] A. Cacchioli, F. Ravanetti, A. Bagno, M. Dettin, and C. Gabbi, "Human vitronectin-derived peptide covalently grafted onto titanium surface improves osteogenic activity: a pilot in vivo study on rabbits," *Tissue Engineering A*, vol. 15, no. 10, pp. 2917–2926, 2009.

[10] M. Dettin, T. Herath, R. Gambaretto et al., "Assessment of novel chemical strategies for covalent attachment of adhesive peptides to rough titanium surfaces: XPS analysis and biological evaluation," *Journal of Biomedical Materials Research A*, vol. 91, no. 2, pp. 463–479, 2009.

[11] T. Hayakawa, M. Yoshinari, and K. Nemoto, "Direct attachment of fibronectin to tresyl chloride-activated titanium," *Journal of Biomedical Materials Research A*, vol. 67, no. 2, pp. 684–688, 2003.

[12] T. Hayakawa, M. Yoshinari, M. Nagai, M. Yamamoto, and K. Nemoto, "X-ray photoelectron spectroscopic studies of the reactivity of basic terminal OH of titanium towards tresyl chloride and fibronectin," *Biomedical Research*, vol. 24, no. 5, pp. 223–230, 2003.

[13] K. Nilsson and K. Mosbach, "Tresyl chloride-activated supports for enzyme immobilization," *Methods in Enzymology*, vol. 135, pp. 65–78, 1987.

[14] T. Hayakawa, M. Yoshinari, and K. Nemoto, "Quartz-crystal microbalance-dissipation technique for the study of initial adsorption of fibronectin onto tresyl chloride-activated titanium," *Journal of Biomedical Materials Research B*, vol. 73, pp. 271–276, 2005.

[15] T. Hayakawa, M. Nagai, M. Yoshinari, M. Makimura, and K. Nemoto, "Cell-adhesive protein immobilization using tresyl chloride-activation technique for the enhancement of initial cell attachment," *Journal of Oral Tissue Engineering*, vol. 2, pp. 14–24, 2004.

[16] K. Pugdee, Y. Shibata, N. Yamamichi et al., "Gene expression of MC3T3-E1 Cells on fibronectin-immobilized titanium using tresyl chloride activation technique," *Dental Materials Journal*, vol. 26, no. 5, pp. 647–655, 2007.

[17] N. Yamamichi, K. Pugdee, W. J. Chang et al., "Gene expression monitoring in osteoblasts on titanium coated with fibronectin-derived peptide," *Dental Materials Journal*, vol. 27, no. 5, pp. 744–750, 2008.

[18] A. Wennerberg and T. Albrektsson, "Effects of titanium surface topography on bone integration: a systematic review," *Clinical Oral Implants Research*, vol. 20, no. 4, pp. 172–184, 2009.

[19] C. Larsson, L. Emanuelsson, P. Thomsen et al., "The 13th European Conference on Biomaterials in Goteborg 1997: Bone response to surface modified titanium implants—studies on the tissue response after 1 year to machined and electropolished implants with different oxide thicknesses," *Journal of Materials Science: Materials in Medicine*, vol. 8, no. 12, pp. 721–729, 1997.

[20] Y. Wu, J. P. Zitelli, K. S. TenHuisen, X. Yu, and M. R. Libera, "Differential response of Staphylococci and osteoblasts to varying titanium surface roughness," *Biomaterials*, vol. 32, no. 4, pp. 951–960, 2011.

[21] E. Yoshida, Y. Yoshimura, M. Uo, M. Yoshinari, and T. Hayakawa, "Influence of nanometer smoothness and fibronectin immobilization of titanium surface on MC3T3-E1 cell behavior," *Journal of Biomedical Materials Research A*, vol. 100A, no. 6, pp. 1556–1564, 2012.

[22] H. Sudo, H. A. Kodama, and Y. Amagai, "In vitro differentiation and calcification in a new clonal osteogenic cell line derived from newborn mouse calvaria," *Journal of Cell Biology*, vol. 96, no. 1, pp. 191–198, 1983.

[23] Y. Kuboki, A. Kudo, M. Mizuno, and M. Kawamura, "Time-dependent changes of collagen cross-links and their precursors in the culture of osteogenic cells," *Calcified Tissue International*, vol. 50, no. 5, pp. 473–480, 1992.