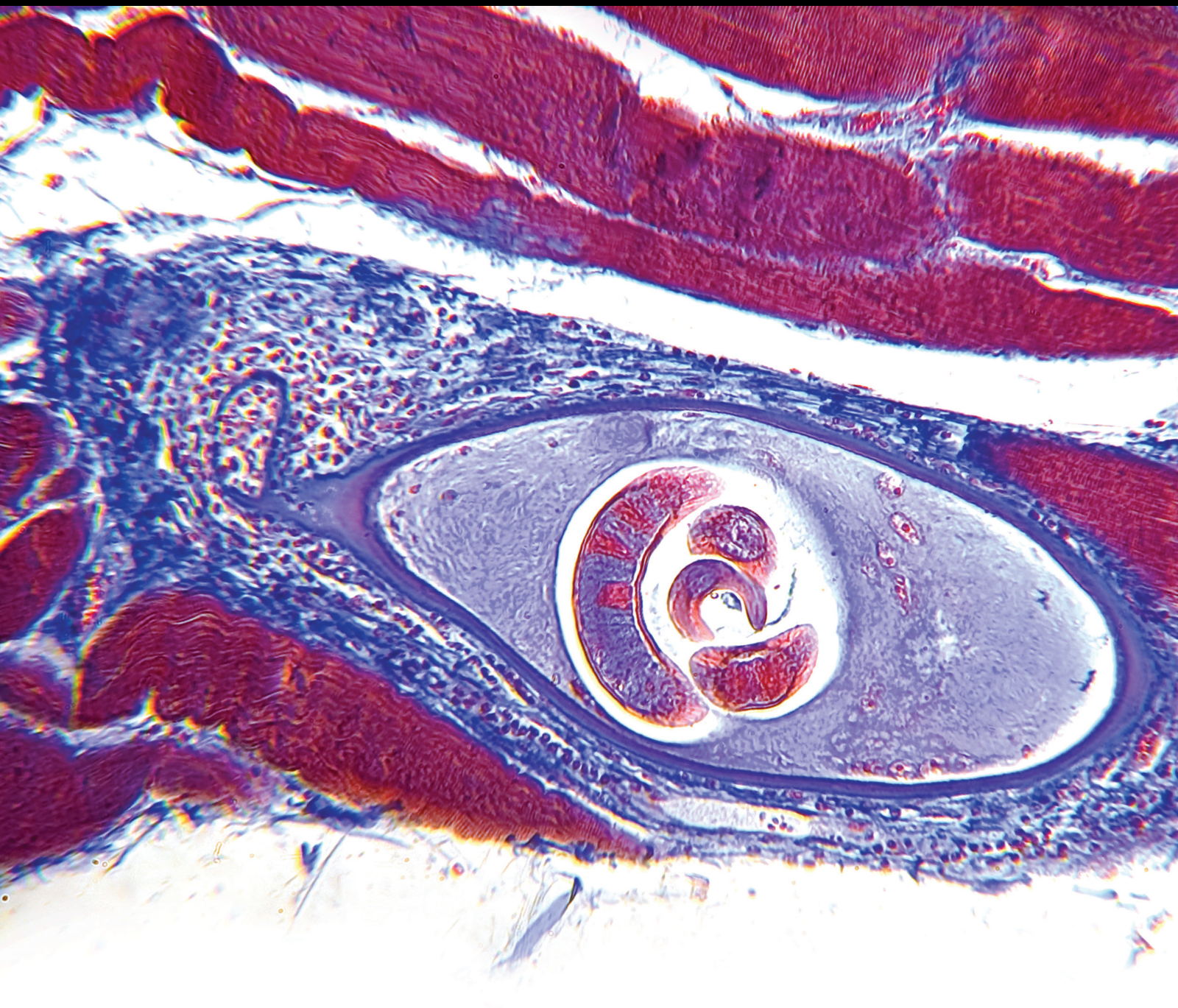


Advances in Endoscopic Treatment of Surgical Complications

Lead Guest Editor: Eduardo Rodrigues-Pinto

Guest Editors: Fauze Maluf-Filho and Diogo Moura





Advances in Endoscopic Treatment of Surgical Complications

Gastroenterology Research and Practice

Advances in Endoscopic Treatment of Surgical Complications

Lead Guest Editor: Eduardo Rodrigues-Pinto


Guest Editors: Fauze Maluf-Filho and Diogo Moura





Copyright © 2023 Hindawi Limited. All rights reserved.

This is a special issue published in "Gastroenterology Research and Practice." All articles are open access articles distributed under the Creative Commons Attribution License, which permits unrestricted use, distribution, and reproduction in any medium, provided the original work is properly cited.

Chief Editor

Michel Kahaleh , USA

Associate Editors

Riccardo Casadei, Italy
Piero Chirletti, Italy
Giovanni D. De Palma , Italy
Per Hellström , Sweden
Wandong Hong, China
Amosy M'Koma , USA
Michele Manigrasso , Italy
Haruhiko Sugimura , Japan



Academic Editors

Gian Luigi Adani, Italy
Ramesh P Arasaradnam , United Kingdom
Jose Celso Ardengh , Brazil
Jean-Francois Beaulieu , Canada
Robert Benamouzig, France
Mattia Berselli , Italy
Hubert E. Blum, Germany
Valérie Bridoux, France
Davide Campana , Italy
Claudia Campani, Italy
Roberto Caronna , Italy
Andrew S. Day , New Zealand
Gianfranco Delle Fave, Italy
Aldona Dlugosz , Sweden
Maria P. Dore , Italy
Werner A. Draaisma, The Netherlands
Peter V. Draganov , USA
Rami Eliakim, Israel
Daiming Fan , China
Fabio Farinati, Italy
Stephen Fink , USA
Francesco Franceschi, Italy
Walter Fries , Italy
Nicola Funel , Italy
Andrea C. Gardini , Italy
Paolo Gionchetti, Italy
Lukas J.A.C. Hawinkels , The Netherlands
Hauke S. Heinzow, Germany
Brenda J. Hoffman, USA
Ralf-Dieter Hofheinz , Germany
Martin Hubner , Switzerland
Satoru Kakizaki, Japan

Mitsuro Kanda, Japan
Vikram Kate , India
Spiros D. Ladas , Greece
Greger Lindberg, Sweden
Fei Luo, China
Palash Mandal, India
Fariborz Mansour-ghanaei , Iran
Luigi Marano , Italy
Fabio Marra , Italy
Gabriela Melen-Mucha , Poland
Paolo Mercantini, Italy
Mousa Mohammadnia-Afrouzi, Iran
Agata Mulak , Poland
Masanao Nakamura , Japan
Robert Odze, USA
Massimo Pancione , Italy
Francesco Panzuto , Italy
Vincenzo Pilone, Italy
Duc Quach , Vietnam
Carlo Ratto, Italy
Mentore Ribolsi, Italy
Chiara Ricci , Italy
Claudio Ricci, Italy
Tamar Ringel-Kulka, USA
Fausto Rosa , Italy
Paul A. Rufo , USA
Shomei Ryozaawa, Japan
Muhammad W. Saif, USA
Eiji Sakai , Japan
Yusuke Sato , Japan
Francesco Selvaggi , Italy
Maida Sewitch , Canada
Keith Tolman, USA
Tatsuya Toyokawa , Japan
Konstantinos Triantafyllou , Greece
Kazuhiko Uchiyama, Japan
Eric Van Cutsem, Belgium
Shu-yuan Xiao , China
Naohisa Yoshida , Japan
A. Zerbi , Italy

Contents

Technical Review on Endoscopic Treatment Devices for Management of Upper Gastrointestinal Postsurgical Leaks

Renato Medas  and Eduardo Rodrigues-Pinto 

Review Article (16 pages), Article ID 9712555, Volume 2023 (2023)

Review Article

Technical Review on Endoscopic Treatment Devices for Management of Upper Gastrointestinal Postsurgical Leaks

Renato Medas ^{1,2} and Eduardo Rodrigues-Pinto ^{1,2}

¹Gastroenterology Department, Centro Hospitalar São João, Porto, Portugal

²Faculty of Medicine of the University of Porto, Porto, Portugal

Correspondence should be addressed to Eduardo Rodrigues-Pinto; edu.gil.pinto@gmail.com

Received 12 August 2022; Revised 20 October 2022; Accepted 25 November 2022; Published 12 June 2023

Academic Editor: Eiji Sakai

Copyright © 2023 Renato Medas and Eduardo Rodrigues-Pinto. This is an open access article distributed under the Creative Commons Attribution License, which permits unrestricted use, distribution, and reproduction in any medium, provided the original work is properly cited.

Upper gastrointestinal postsurgical leaks are challenging to manage and often require radiological, endoscopic, or surgical intervention. Nowadays, endoscopy is considered the first-line approach for their management, however, there is no definite consensus on the most appropriate therapeutic approach. There is a wide diversity of endoscopic options, from close-cover-divert approaches to active or passive internal drainage approaches. Theoretically, all these options can be used alone or with a multimodality approach, as each of them has different mechanisms of action. The approach to postsurgical leaks should always be tailored to each patient, taking into account the several variables that may influence the final outcome. In this review, we discuss the important developments in endoscopic devices for the treatment of postsurgical leaks. Our discussion specifically focuses on principles and mechanism of action, advantages and disadvantages of each technique, indications, clinical success, and adverse events. An algorithm for endoscopic approach is proposed.

1. Introduction

Upper gastrointestinal (UGI) postsurgical leaks (PSLs), defined as abnormal communications between the intraluminal and extraluminal compartments because of a defect in the integrity of the gastrointestinal wall, are devastating complications of surgery. Their occurrence negatively impacts postoperative outcomes, as they are the strongest independent risk factor for postoperative mortality [1]. They also delay oral feeding initiation, increase length of stay, risk of anastomotic stricture, and risk of re-operation up to 60% [2].

Frequency of UGI PSL is higher in cervical anastomosis than in intrathoracic anastomosis [2, 3], and in oncologic leaks than in bariatric leaks (esophagectomy: 8–26% [4], 3–12% after total gastrectomy: 3–12% [5]; Roux-en-Y gastric bypass (RYGB): 0.7–5%; sleeve gastrectomy (SG): 1–2% [6, 7]) (Figure 1). Leaks may occur immediately post-surgery or, more commonly, several weeks later. Acute leaks are usually related to technical issues, while delayed leaks often reflect healing insufficiencies due to ischemia at the staple-line or anastomosis [8–10].

PSLs are challenging to manage and often require radiological, endoscopic, or surgical intervention [11]. Their management should be based on several factors, with patient stability and time from surgery being probably the most important [11]. Historically, PSLs were managed either by rescue surgery, when the defect was present within the first 7–10 days, or a watch-and-wait strategy followed by secondary surgery if symptoms persisted. In stable patients, conservative and radiological interventions lead to highly variable rates of spontaneous closure, ranging from 16% to 46% [6, 12]. In patients who undergo rescue or redo surgery, mortality increases to 15–30%, with recurrence occurring in 13–33% of these patients with an added mortality of 9–30% [13]. Cost of care also has a 10-fold increase in these patients.

Nowadays, endoscopy is considered the first-line approach for the management of PSL [14, 15], as it seems to be associated with an improved outcome and better quality of life [16]. Recent studies have demonstrated the safety and efficacy of endoscopic interventions to manage transmural defects as first-line therapy (Table 1) instead of conventional modalities

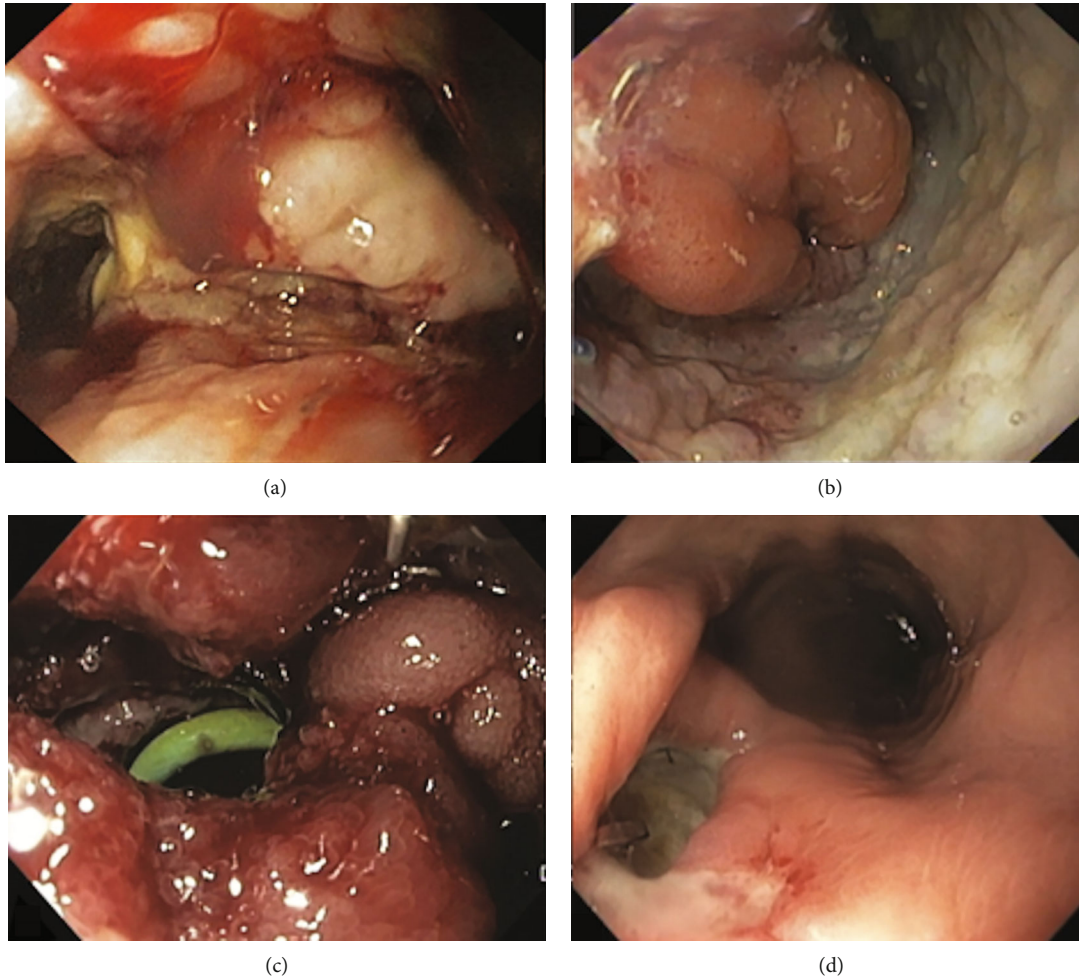


FIGURE 1: Endoscopic images of post-esophagectomy leak (a), post-gastrectomy leak (b), post-gastric bypass leak (c), and post-sleeve leak (d).

TABLE 1: Clinical success rates of different endoscopic techniques in the management of upper gastrointestinal postsurgical leaks.

Endoscopic technique	Clinical success rate	
	Oncologic leaks	Bariatric leaks
Stents	81–87% [41–43]	65–100% [41, 44–55]
OTSC	66–73% [65, 66]	67% [67]
Suture		27% [72]
Tissue sealants	56–97%* [75, 77–79]	
CSDO	77.3% [81]	
EVT	67–100% [92–94]	
EID	76–86% [16, 100, 101]	
Endoscopic septotomy	70–85% [11, 105–107]	

*Frequently used as an adjuvant of other techniques.

OTSC: over-the-scope clip; CSDO: cardiac septal defect occluder; EVT: endoscopic vacuum therapy; EID: endoscopic internal drainage.

to either avert surgery or optimize patients for definitive future surgery [17]. However, there is no definite consensus on the most appropriate therapeutic approach in the management of PSL. Due to lack of an algorithmic endoscopic

approach, these interventions are often applied in a step-wise manner or an institutional expertise-dependent manner [18].

The approach to a PSL should focus on clinical presentation, characteristics, and chronicity of the leak, correcting the underlying physiologic defect that predisposed and perpetuated the leak, minimizing the risk of chronic fistula formation, preserving the patient's ability to have enteral nutrition, and minimizing the use of costly, less effective endoscopic accessories and endoscopies.

Multiple endoscopic sessions are often required, and the strategy must be continually adapted based on the patient's anatomy, physiology, and response to therapy. The lack of defined criteria, such as size of the leak or existence of a wound cavity, poses a challenge for the choice of the best endoscopic treatment strategy.

Considering the multiplicity of endoscopic therapeutic options available and the need of tailoring each treatment, we aim to provide a technical review of the endoscopic devices available for the treatment of PSL, summarize the best options for each clinical situation, and propose an algorithm for endoscopic approach.




FIGURE 2: Different examples of endoscopic devices available for treatment of postsurgical leaks. Esophageal self-expandable metal stent and “bariatric stent” (a); different types of over-the-scope clips teeth configurations (b); cardiac septal defect occluder (c); two double plastic pigtail stents (d); polyurethane foam sponge of endoscopic vacuum therapy (e); and endoscopic suture system (f).

2. Leaks Specificities

Anatomic and physiologic factors, apart from technical errors, are responsible for the development of leaks. Intrinsic esophageal anatomy with the lack of an esophageal serosa and the negative pressure within the thoracic cavity may contribute to the development of post-esophagectomy leaks [19]. Sufficient blood supply [20] and adequate tension on the anastomosis site [20, 21] are essential for proper healing.

While foreign body material (staples, sutures, percutaneous drains) hampers proper healing, downstream obstruction distal to the surgical anastomosis, such as anastomotic strictures [22], narrowing at the incisura angularis or twisted/kinked stomach [22, 23] results in a higher pressure proximally, predisposing to a leak at the area of least resistance. Evidence about the effect of the extent and dosage of neoadjuvant chemoradiation or anastomotic techniques with the lowest leakage rates remains controversial [19, 24].

Most post-SG leaks (>90%) and RYGB leaks occur at the angle of His where the staple-line meets the gastroesophageal junction [25, 26], an area of intense intragastric pressure, thin gastric wall, susceptibility to ischemia owing to the single blood supply to the gastric pouch, as well as relative dysmotility. However, SG leaks may occur anywhere along the length of the sleeve at the staple-line. RYGB leaks may occur also at the gastrojejunal anastomosis, blind loop, jejunojejunal anastomosis, or remnant stomach.

3. Endoscopic Armamentarium

Endoscopic techniques (Figure 2) for PSL closure include (Table 2):

- (1) Close-cover-divert approaches (primary techniques): use of suturing devices, over-the-scope clips (OTSCs), tissue sealants, cardiac septal defect occluder (CSDO), or self-expandable metal stents (SEMSs).

- (2) Active or passive internal drainage approaches (secondary techniques): endoscopic internal drainage (EID), endoscopic vacuum therapy (EVT), or septotomy with or without pneumatic dilation.

In recent years, leak management has started to fall in the close-cover-divert approach versus the active or passive internal drainage approach.

3.1. Stents. Endoscopic stents are cylindrical devices used to preserve or re-establish luminal patency [27]. For PSL, the role of a stent is to seal the leak and divert gastrointestinal contents away from the site of leakage, enabling an early resume of enteral feeding [28] (Figure 3). This is an off-label use of these devices. Selection of the ideal stent requires an understanding of stent technology, such as stent's type, dimensions, and degree of foreshortening, as well as location and features of the targeted defect.

Recent esophageal SEMSs are usually made of nitinol, an alloy of nickel and titanium, allowing flexibility for placement at sharp angles [29, 30]. Esophageal SEMS can be partially (PC) or fully covered (FC). The silicon coating completely covering the FC-SEMS is intended to easily remove the stent, but this advantage is overshadowed by the higher migration risk (up to 30%). PC-SEMS may be preferable to FC-SEMS as tissue hyperplasia forms at the uncovered terminal ends of the stent, creating a watertight seal around the stent and decreasing the risk of migration. The major drawback of PC-SEMS is the difficulty of stent removal [31], however, this can be overcome using auxiliary techniques, such as argon plasma coagulation (APC) [32], inversion of the stent by its distal end [33], or the *stent-in-stent* technique [34, 35]. Stent dwell time is highly variable and may range from 2 to 12 weeks [36], even though median time to achieve healing is usually 4–8 weeks [37].

Self-expandable plastic stents (SEPS) consist of a polyester body covered with silicone to prevent tissue ingrowth

TABLE 2: Summary of endoscopic treatment devices for management of upper gastrointestinal postsurgical leaks.

Type	Device	Advantages	Disadvantages
Primary closure techniques	Over-the-scope clips	Useful for small leaks [68, 76]	Frequent need of combined techniques [75, 76]
	Tissue sealants	Extensively available in most centers [62] Ease of use [62]	Less effective for larger and chronic leaks [68] Less effective for larger and chronic leaks [72]
	Endoscopic suture	Useful for small leaks [70]	Not widely available [72] Requires experienced endoscopist [72] Poor clinical success [72]
	Cardiac septal occluded	Useful for leaks with associated fistulas [81]	Less effective for larger leaks [81] Requires experienced endoscopist [82]
	Self-expandable metal stent	Early enteral nutrition [27] Widely available in most centers Allow simultaneous dilation if concomitant stricture is present [28, 29]	Frequent but transitory symptoms after stent placement (nausea, vomiting, and/or retrosternal discomfort) [34] Multiple endoscopic sessions (larger leaks) [60] Stent migration risk despite fixation [37] No consensus about best stent type [41–43]
	Endoscopic vacuum therapy	Combines drainage and sealing [18] No need for percutaneous drain [84] Possibility of closure of larger and chronic defects [85]	Transnasal tube in situ for at least 3–4 weeks [90] Multiple endoscopic procedures every 3–4 days (sponge exchange) [90] Late enteral nutrition (total parenteral nutrition or jejunostomy is needed) [91]
Secondary closure techniques	Endoscopic internal drainage	No need for percutaneous drain [100]	Long period till leak closure [100]
		Early oral feeding [16]	Complementary techniques may be needed (necrosectomy/endoscopic ultrasound guided drainage for complex collections) [102–104]
		Early hospital discharge [16]	
	Endoscopic septostomy	No need for percutaneous drain [21] Option in chronic refractory leaks [105]	Multiple endoscopic procedures may be required [21] Risk for perforation and/or bleeding [108]

and polyester braids on the surface to prevent stent migration. Despite SEPS effectiveness in sealing transmural defects, they also have propensity for migration [38] and require mounting on a delivery system before deployment, making the process complicated and time consuming when compared with SEMS, which are ready for use [29]. Thus, SEPS use has largely been replaced by SEMS.

Biodegradable stents (BDSs) are absorbable stents that degrade within 6–24 weeks. Since degradation is accelerated by acid exposure, acid-suppressive therapy may be warranted in certain situations [39]. BDSs negate the inconvenience of stent removal; however, the severity of tissue hyperplasia cannot be accurately predicted [40] and may result in dysphagia and stenosis that requires dilation in approximately 50% of cases [31]. In addition, radial force of BDS is weaker when compared to SEMS [41].

Three systematic reviews comparing the use of PC-SEMS, FC-SEMS, and SEPS in oncologic leaks and perforations [42–44] reported a clinical success of 81–87% without differences among stent types. Despite the non-negligible rate of SEMS-related adverse events (AEs), most of them

are usually mild and can be managed conservatively. Nausea, vomiting, and abdominal discomfort are common and usually transient, but severe stent intolerance has been reported, leading to early stent removal. Severe bleeding and perforation may also occur [35, 42–45], but high rate of migration stands as the major drawback. Regarding bariatric leaks, leak closure rates and AEs rates range from 65% to 100% and 14% to 86%, respectively, with migration being the most frequent AE, with rates of 5–67% [42, 45–56]. Recent reports using specifically long and larger designed stents (“bariatric stents”) show similar success rates without significant differences in migration rate when compared to conventional stents [45, 57].

Longer delays until stent placement [58], persistent leakage after initial stent [59], leaks of the proximal esophagus, stents traversing the gastroesophageal junction, defects larger than 6 cm, and distal conduit leaks [60] are associated with higher probability of treatment failure in oncologic leaks. Regarding bariatric leaks, defects larger than 1 cm [61] and longer delays between leak development and stenting also negatively influence endoscopic outcomes [42, 46, 62].

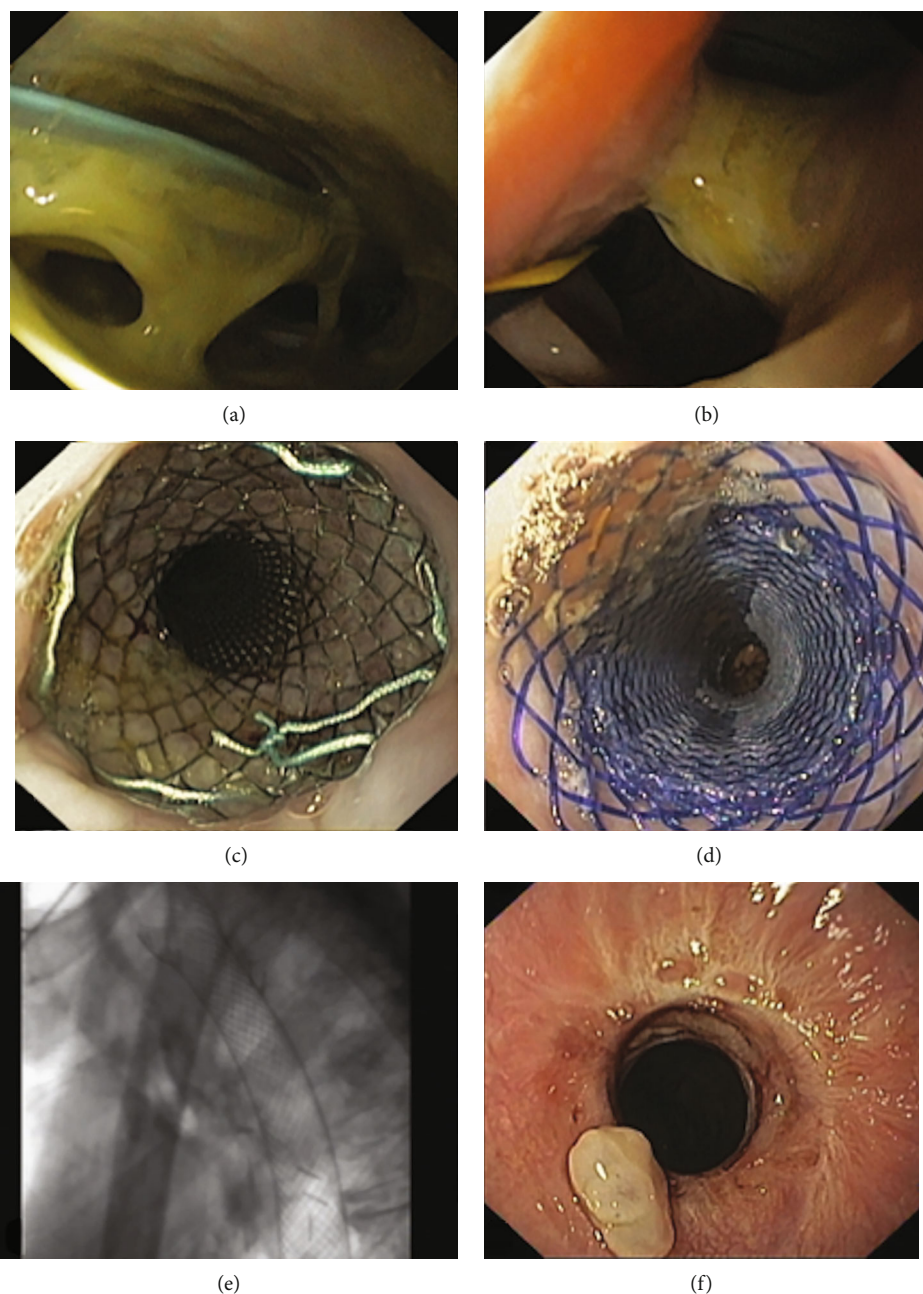


FIGURE 3: Endoscopic image of a post-total gastrectomy anastomotic leak occupying nearly 50% of the luminal circumference (a). Leak defect and efferent limb with a guidewire in place to guide sent placement (b). Examples of a fully covered self-expandable metal stent (c) and a biodegradable stent (d), which can be used for leak diversion. Fluoroscopic image after SEMS placement (e). Stent-induced stricture at the previous location of the proximal stent flange after stent removal (f).

3.2. Over-the-Scope Clips. OTSC is a memory-shape nitinol clip, with a “bear claw” configuration and a powerful compression force, loaded onto a transparent cap that is mounted at the tip of the endoscope [63]. They are available on various diameters (OTSC caps of 11, 12, and 14 mm internal diameters) and lengths (3 and 6 mm cap depth), as well as three types of teeth configuration, which include the blunt or atraumatic type (A type), the traumatic type with short pointed teeth (T type), and the traumatic type with long pointed teeth (GC type) [64]. The set-up and deployment of the OTSC are similar to a variceal band ligator, as the cap

pulls in the target tissue or defect using vacuum suction. Auxiliary devices, like the tri-prong anchor retraction device (if the tissue is indurated and scarred) or “twin grasper” forceps (to approximate the opposite edges of a pliable gaping defect), may facilitate efficient pulling of the entire defect into the cap [64].

Placement of the OTSC may be challenging due to limited access, restricted mobility, and suboptimal alignment with the target lesion. A misdeployed clip makes subsequent repair very difficult. If misdeployment occurs, OTSC may be removed with high power APC (with the potential for

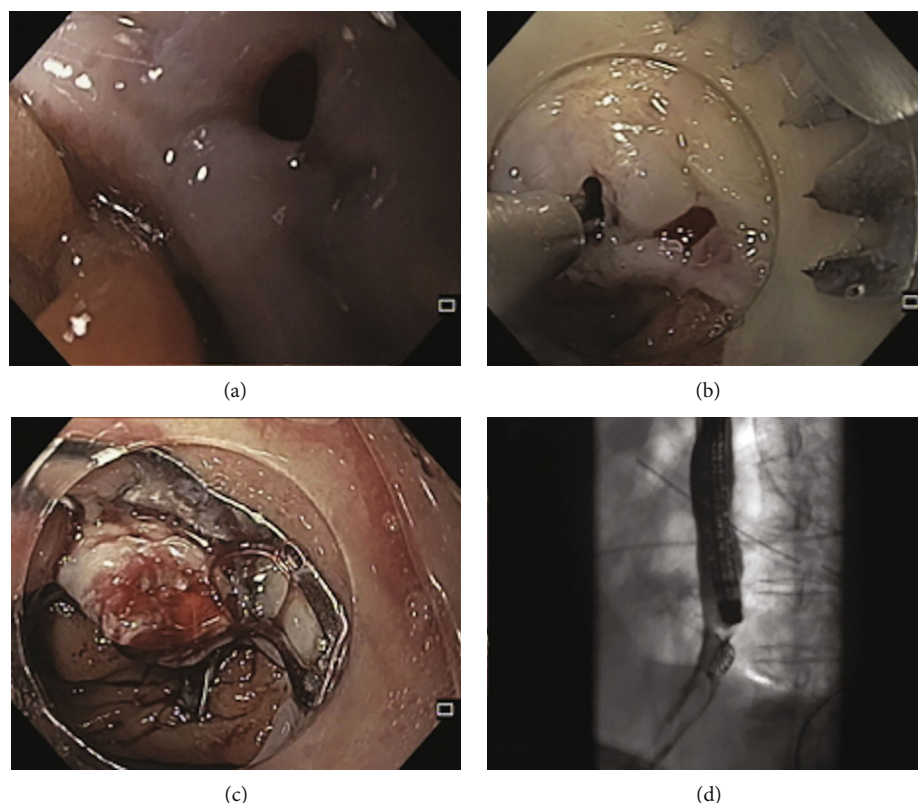


FIGURE 4: Endoscopic image of a 3 mm leak orifice after total gastrectomy (a), closed with a 12 mm over-the-scope clip (OTSC) after retracting the tissue margins with an anchoring device and suction of the defect into the applicator cap (b, c). Fluoroscopic image showing OTSC correctly placed, without leakage (d).

transmural burn injury and delayed perforation), or with a dedicated device (remOVE system, Ovesco, Tübingen, Germany) based on a fast and efficient direct current [65]. Application of ice-cold normal saline on the clip for 1 minute, to lower the mechanical resistance of the nitinol frame prior to its extraction by a standard grasping forceps, has also been reported [66].

Closure of large defect that requires more than one OTSC may not be effective as the concave configuration of these clips results in a gap between two closely placed clips. Another caveat during placement is inadvertent entrapment of the auxiliary devices during deployment, if not fully retracted into the cap. OTSC placement requires care, as surrounding healthy and pliable tissue can easily be suctioned inadvertently into the cap and, if passed unrecognized, result in incomplete luminal closure following clip deployment.

OTSCs should be used in situations where the tissue margins are still malleable and the entire target defect can be suctioned or retracted into the cap (Figure 4). They are usually reserved for completion closure of large anastomotic leaks that have been reduced by other measures until the defect size is small enough to be amenable for OTSC closure.

Clinical success ranges between 66–73% for oncologic leaks [67, 68] and 67% for post-bariatric leaks [69]. Unfortunately, success rate of post-esophagectomy leaks is below 33%, probably due to the anatomical features of the esophagus (narrow lumen). Clinical success is higher when OTSC is

used within 1 week of diagnosis, if applied as primary therapy and if the defect has minimal inflammation or low level of fibrosis [67, 70, 71]. Larger defects (>13 mm) and necrotic or soft margins are associated with increasing failure rates [70].

3.3. Endoscopic Suturing. Presently, most experience is limited to the OverStitch device (Apollo Endosurgery, Austin, Texas), which requires a single or double channel therapeutic gastroscope and familiarity with the multistep process associated with activation of the device. The suturing system enables placement of polypropylene or polydioxanone sutures in an interrupted or continuous fashion without the need to remove the endoscope for suture reloading [64]. Accessories, such as the helix device, can be used to anchor and retract tissue into the suturing arm to facilitate suture placement.

The recently developed X-Tack Endoscopic HeliX Tacking System, a Through-the-scope (TTS) suture-based device, allows closure of large, wide, and irregularly shaped defects, without the need for instrument withdrawal from the patient [72]. The tacks are screwed into healthy target tissue adjacent to the defect or stent, followed by approximation of the margins by successive gathering of the tacks with applied suture tension and placement of a final cinch to secure the construct [72, 73].

Available data on endoscopic suture are limited, and results are not satisfactory, since the largest study reported a clinical success of only 27% in leak closure [74].

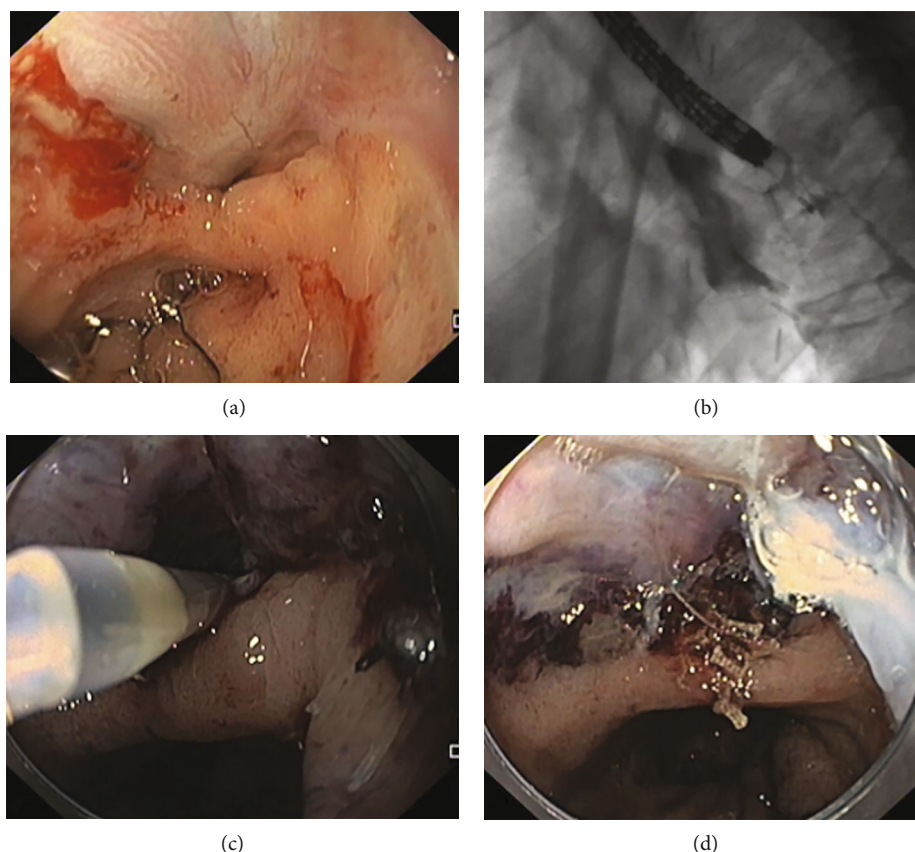


FIGURE 5: Endoscopic image of a 4 mm anastomotic leak after Ivor-Lewis esophagectomy (a), with associated fistula (b), closed after tissue sealant and vicryl mesh placement (c, d).

3.4. Tissue Sealants. Tissue compatible glues are either derivative of proteins involved in coagulation or glue such as cyanoacrylate. Fibrin glue, which consists of human fibrinogen and thrombin combined with antifibrinolytic agents, is the most commonly used sealant. It is a tissue-compatible adhesive that mechanically occludes the wall defect and promotes wound healing by inducing cellular response to tissue damage and forming matrix-building strands [75]. Although fibrin glue contains antifibrinolytic agents, accelerated degradation particularly in the setting of gastrointestinal contents or infection remains a concern and, therefore, fibrin glue is considered a poor scaffolding material. Owing to these concerns, recent studies have evaluated infill materials, such as absorbable Vicryl mesh or Surgisis (Biodesign, Cook Medical Inc, Bloomington MA) [76].

Cyanoacrylate, a synthetic glue working as a mechanical sealant, has high adhesive and high antibacterial properties and thus is suitable for application in infectious sites. It is eliminated by hydrolysis after 1–6 months [77]; however, the poor mechanical properties of the film, brittle nature, possible proinflammatory effect as well as the risk of damage of the endoscope because of its rapid polymerization make cyanoacrylate a second-choice method [78].

Clinical success of glue sealants is highly variable, ranging from 55.7% to 96.8% [77, 79–81]. Glue sealants are frequently used as an adjuvant to other techniques, making difficult to evaluate its efficacy as primary treatment [77, 78]. It might be more

suitable for small leaks (<15 mm) or residual small collections after the use of other techniques [78]. Complete leak closure might require multiple sealant applications or the use of vicryl plugs to improve effectiveness (Figure 5) [79].

3.5. Cardiac Septal Defect Occluder. The Amplatzer CSDO (St. Jude Medical, Plymouth, MN) is a self-expandable double-disc (“double umbrella”) closure device made of a shape-memory nitinol wire mesh with interlaced polyester, which promotes occlusion and tissue ingrowth [82]. It can easily be recaptured and redeployed for optimal placement. There are two types of CSDO, the atrial septal and the ventricular septal defect closure devices; both are available in different sizes, including disc diameter (from 9 to 54 mm), waist length, and waist diameter (from 4 to 38 mm). To select the adequate CSDO size, estimation of fistula orifice can be made by the ability to pass the gastroscope through the orifice. Whenever possible, waist size should be adjusted to fistula diameter to ensure a tight seal. In addition, a device diameter at least 50% larger than the fistula orifice helps to optimize the seal [83].

The delivery system sheath size ranges from 5 to 12 French (Fr) with a tip angle of 45 and 180 degrees and with a length from 60 to 80 cm, precluding to be used TTS channel of most available gastroscopes. To overcome this limitation, CSDO can be delivered over a guidewire under direct endoscopic visualization with or without

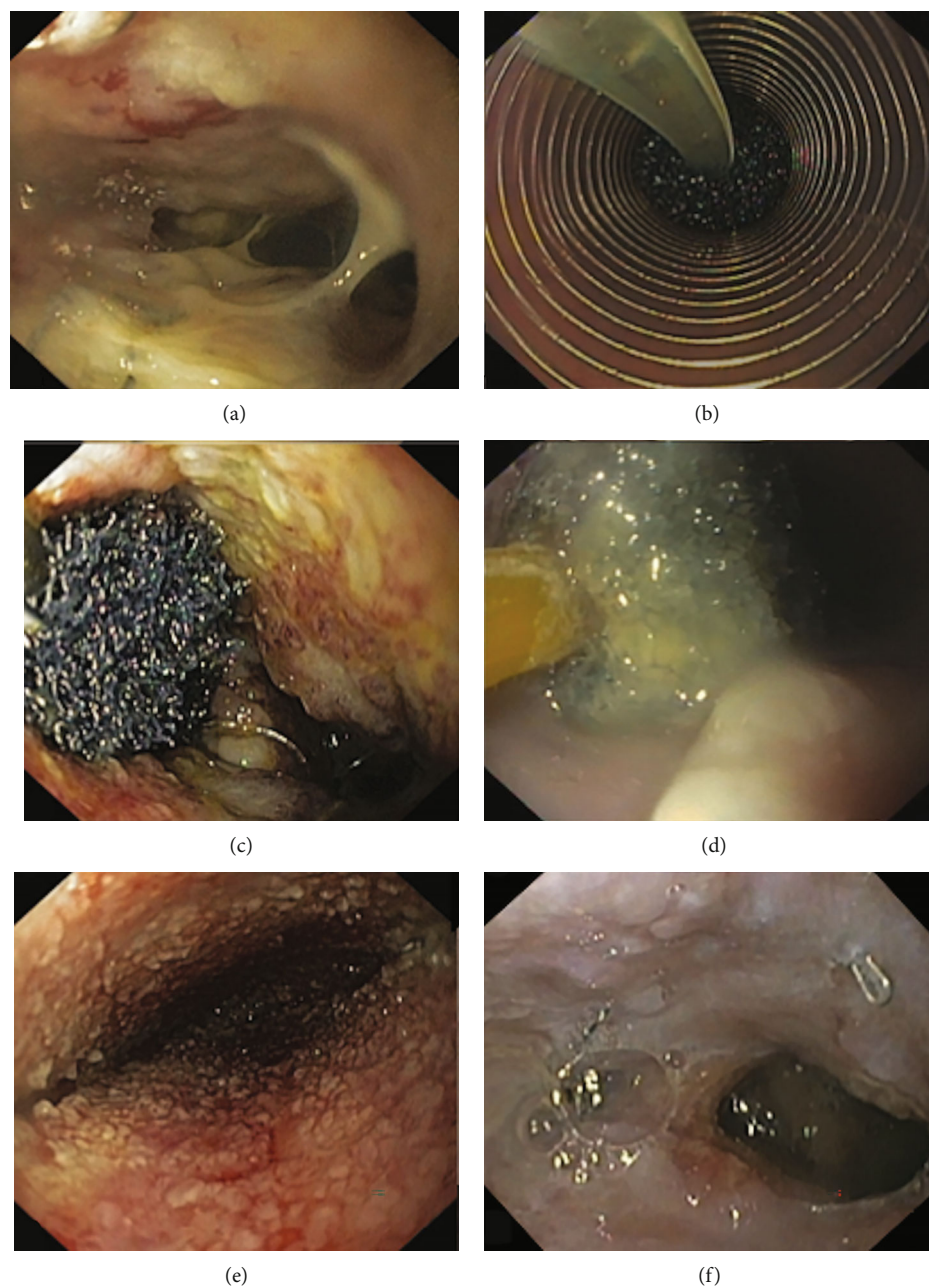


FIGURE 6: Endoscopic image of a severe anastomotic leak after Ivor-Lewis esophagectomy (a). An overtube (b) was used to assist in the placement of a polyurethane sponge well deep in the mediastinal cavity (intracavitary EVT) (c). EVT sponge during scheduled replacement after 3 days in place (d), with progressive decrease of cavity dimensions and granulation tissue formation (e). Complete closure of the anastomotic defect was achieved (f).

fluoroscopy guidance or can be separated from the delivery system and loaded to an adapted endoscopic biliary catheter (7–10 Fr) to enable enough length to be deployed TTS channel. To load the CSDO into the biliary catheter, a pediatric biopsy forceps can be placed down the catheter to grab and back-load the stent [84].

During the deployment, the distal flange is first released into the GI lumen or the fistula tract (if advanced from the skin or the endoscope, respectively) and then,

after confirmation of adequate positioning, the proximal flange is released [85].

A systematic review [83] reported a technical success rate of 100% and a clinical success of 77.27%. The largest available study [84] reported a clinical success of 90.7%. Fistula chronicity and previous treatment were associated with increased rates of fistula closure. AEs may occur in up to 23%, mostly migration and, more rarely, fistula enlargement [84].

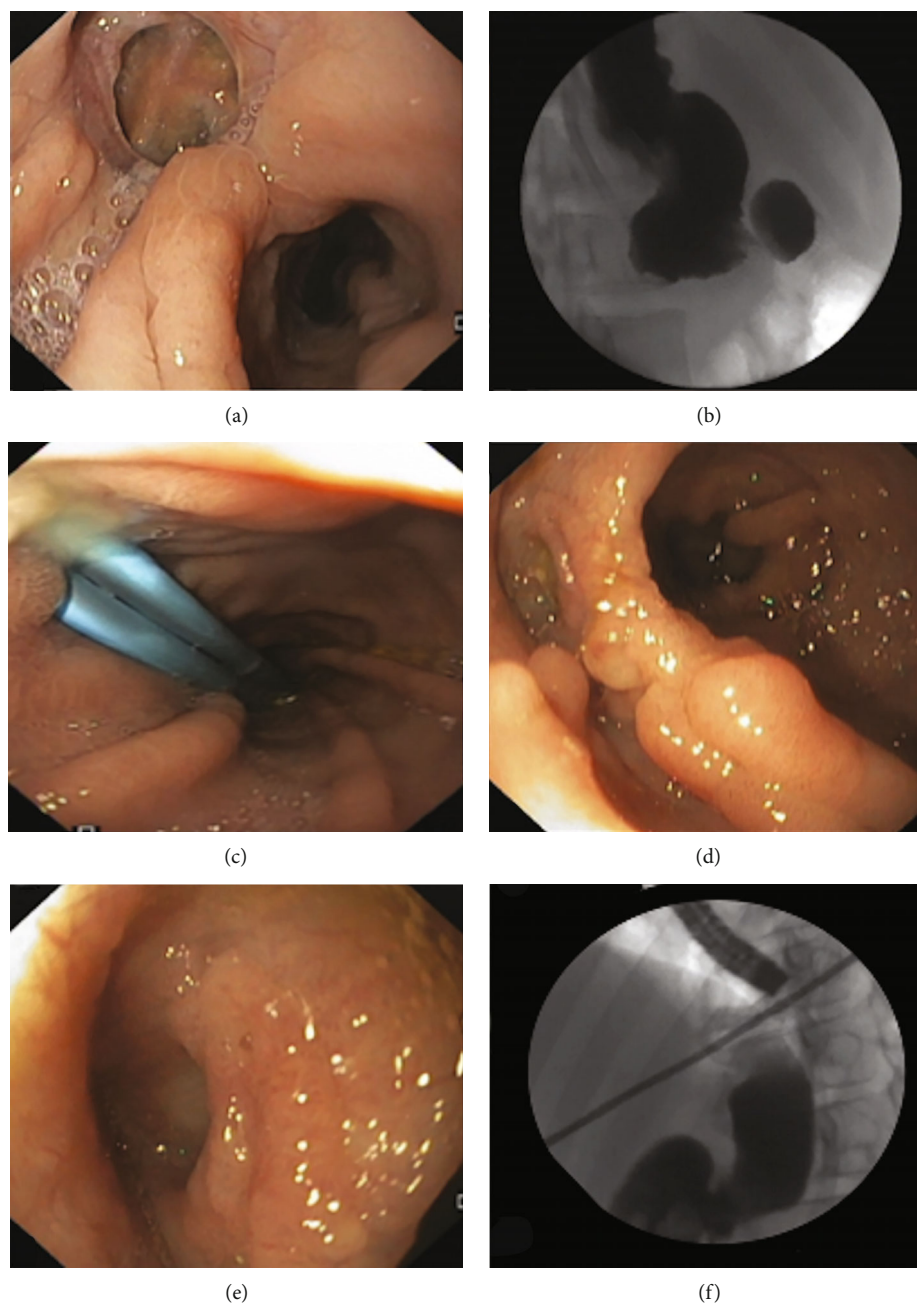


FIGURE 7: Endoscopic image of a 12 mm anastomotic leak after sleeve gastrectomy (a), with an associated perigastric collection (b). Two plastic double pigtail stents were placed across the leak orifice to internally drain the collection (c). At the end of treatment, a pseudodiverticulum formation in the previous anastomotic leak location could be seen (d, e), and successful closure of the defect was achieved (f).

3.6. Endoscopic Vacuum Therapy. EVT consists in a negative pressure system that promotes wound healing by draining inflammatory exudates and secretions, decreasing bacterial contamination, and promoting neovascularization and granulation tissue with subsequent epithelialization (Figure 6) [19, 86]. In EVT, a polyurethane foam sponge, slightly smaller than the wound's dimensions and geometry (to allow collapse and subsequent closure), is attached at the tip of a polyvinyl chloride suction tube using sutures applied at the proximal and distal ends of the sponge [87–89]. At

every endoscopic session, the sponge size should be tailored to the new wound size dimensions.

The two most common techniques used to place the sponge are the back-pack method (dragging the sponge drainage system parallel to the endoscope using an endoscopic forceps) and the overtube method (pushing the sponge down through the tube) [87–91]. If the wound cavity has a narrow opening, it can be endoscopically dilated to facilitate placement of the sponge. However, if the extraluminal cavity is small, the sponge may be placed intraluminally

TABLE 3: Risk factors associated with endoscopic treatment failure.

Endoscopic technique	Risk factors for treatment failure
Stents	Delay until stent placement [57]
	Persistent leakage after first stent placement [58]
	Proximal esophagus leak [59]
	Larger defect (>60 mm—oncologic; >10 mm—bariatric) [59, 60]
	Stent crossing the gastroesophageal junction [59]
OTSC	Distal conduit leak [59]
	Larger defect (>13 mm) [68]
	Necrotic or soft margins [68]
	Post-esophagectomy leak [65, 66]
EVT	Neoadjuvant chemotherapy [96]
	Rescue application [96]
	Intraluminal sponge placement [96]
EID	Delay until treatment [14]
	Larger leak [14]
	Sepsis [14]
	Gastrobronchial fistula [14]
Endoscopic septotomy	Previous OTSC use [14]
	Persistent stricture below the leak [21]

OTSC: over-the-scope clip; EVT: endoscopic vacuum therapy; EID: endoscopic internal drainage.

adjacent to the cavity. Negative continuous pressures of 100–125 mm Hg are usually selected [90, 91].

After initial placement of the EVT system, the sponge is changed regularly every 3–4 days for intracavitary sponges (to prevent granulation tissue ingrowth that makes the removal of the sponge difficult) and up to 1-week interval for intraluminal sponges [92], until satisfactory cavity closure is achieved. During this process, the sponge should be changed from its initial intracavitary location to an intraluminal one, and subsequently removed once the cavity has reduced to a radius <1 cm and a depth <2 cm, with formation of a pseudodiverticulum or a rather small opening, which can later be closed using, for example, an OTSC. With the concomitant use of antibiotics and adequate nutritional support through tube feeding, defect closure using the EVT technique can generally be achieved within 15–30 days [93].

Clinical success ranges from 66.7% to 100% [94–96]. Regarding oncologic leaks, clinical success is higher for gastrectomy leaks comparing to esophagectomy leaks (90% vs. 79.5%) [97]. Neoadjuvant treatment, rescue application, and intraluminal location are risk factors for EVT failure [98]. Other limitations associated with EVT should be considered. First, a transnasal tube must remain in situ for at least 3–4 weeks. Second, multiple endoscopic sessions are required. Third, an anatomically difficult to access cavity due to its narrow opening needs endoscopic dilatation (with potential for AEs), whereas a small cavity warrant placement

of the sponge intraluminally, which may be less efficient at absorbing secretions and collapsing the cavity [93].

EVT-related AEs (4.1–12%) are usually minor and related to mild bleeding upon sponge exchange, sponge dislodgement, and discomfort or distress from repeated procedures [99]. Stricture formation after EVT, secondary to vigorous formation of granulation tissue, may occur, requiring endoscopic dilation [100]. Rarely, major events like bleeding from sponge erosion into small or major cardiovascular structures, rupture of the descending aorta, or bronchoesophageal fistula formation may occur [90, 95, 101].

3.7. Endoscopic Internal Drainage. The rationale of EID with deployment of one or more pigtail plastic stents (or nasocystic catheters in cases of large collections requiring lavage to eliminate pus and debris [16]) across the leak orifice is to internally drain fluid collections, leading to progressive reduction in leak size until it eventually becomes a virtual cavity (Figure 7) [102]. Meanwhile, a foreign body reaction in the edges of the leak is triggered by the pigtail stents, promoting re-epithelialization and leak closure, resulting in an all-in-one procedure without the need of further treatment. A residual small cavity like a pseudodiverticulum is common at the end of the process without any clinical repercussion [103]. In addition to stenting, debridement (endoscopic necrosectomy) may also be needed in cases of infected collections containing necrotic tissue [104–106]. Downstream stenosis in the gastric lumen should be treated if present, to reduce the intragastric procedure.

The appropriate time interval for stent exchange or oral diet resumption remains to be defined. While stent exchange may be performed on a regular basis (i.e., every 2–6 weeks, until healing is achieved), to avoid stent obstruction, allow necrosectomy, and stimulate tissue granulation [103], others remove the stents 4 months after complete clinical resolution [16], even though in most patients successfully treated, stents often migrate spontaneously. Oral diet is usually started in the first 24–48 hours after confirming clinical improvement with EID [16] or following confirmation of collection reduction in CT scan [103].

Clinical success of EID ranges from 78–86% with a median time to leak closure up to 115 days [16, 102, 103]. Discomfort, ulceration, dysphagia, and splenic hematoma are rare EID-related AEs [16]. When combined with surgery cleansing, EID allows early removal of surgical drainage preventing chronic fistula tract formation [107]. Longer delays between diagnosis and treatment, larger leaks, sepsis, presence of gastrobronchial fistula, and previous OTSC deployment are risk factors for treatment failure [14].

3.8. Endoscopic Septotomy. This procedure derives from the endoscopic treatment for Zenker diverticulum. The principle behind this technique relates to higher intraluminal pressure within the sleeve compared with the perigastric cavity, promoting flow of contents through the leak. Endoscopic septotomy aims to equalize these pressures by cutting the “septum” between the perigastric cavity and the gastric lumen, using APC or a needle knife, allowing internal drainage of the leak, and deviation of oral intake. The cut should

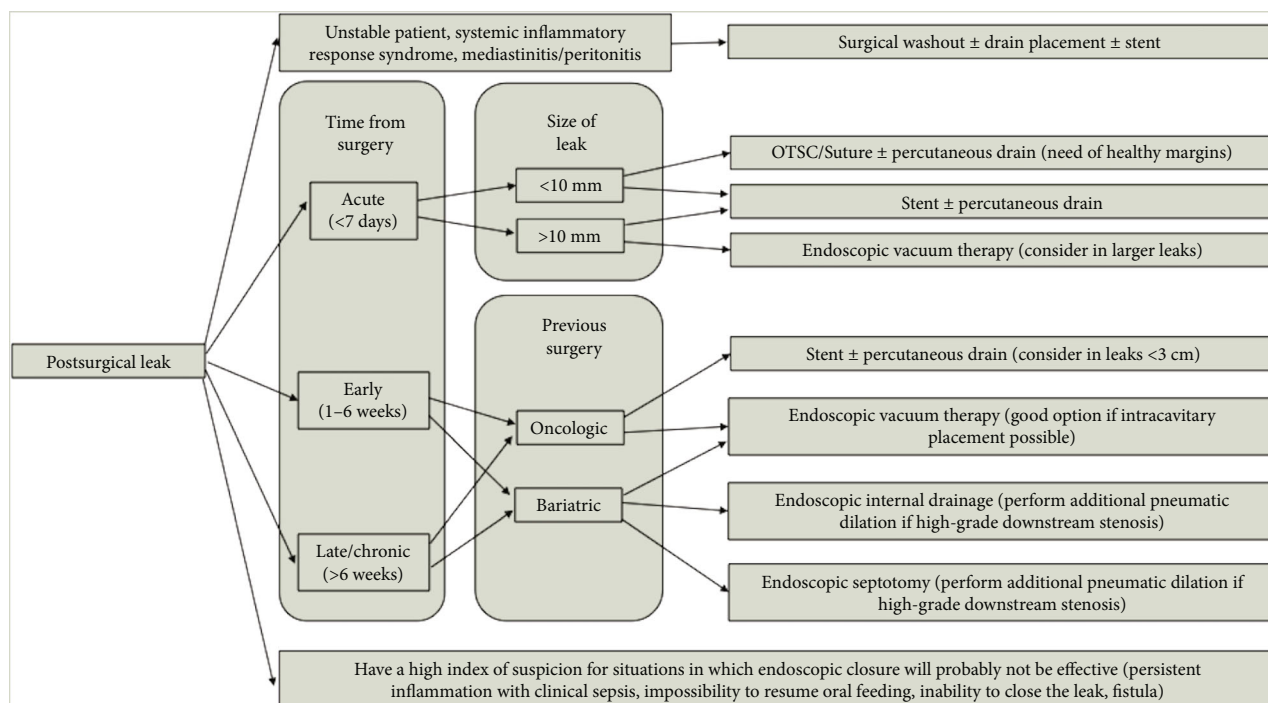


FIGURE 8: Endoscopic algorithm for management of postsurgical leaks. Combined treatment with simultaneous or sequential use of several endoscopic methods should always be considered.

not exceed the bottom of the perigastric cavity. If a downstream stenosis in the gastric lumen is present, it should be treated as well, similarly to EID. Multiple endoscopic procedures may be required with more pseudo-septum being incised each time to achieve successful healing [22].

Endoscopic septotomy may be used as first-line or salvage therapy with clinical success ranging from 70% to 85% [11, 107–109]. Bleeding and perforation should be taken as potential AEs [110].

4. Discussion

Therapeutic endoscopy plays a major role in the management of PSL, offering an effective treatment alternative to repeat surgery [110]. Despite this, there is wide variation in the management of these patients, even among experts in the field, particularly concerning difficult-to-treat patients. Proper selection of patients is critical for favourable outcomes, and the approach to UGI PSL should always be tailored to the single patient. So, it requires a personalized and multidisciplinary approach, comprising a close collaboration between interventional endoscopist, radiologist, and surgeon, allowing PSL management with high clinical success rate and low rate of morbidity and mortality [111, 112].

A single therapy, or a combination of different techniques, can be used for PSL treatment. In fact, most patients may benefit from a multimodal approach. However, leak resolution seems to reach a plateau between third and fourth endoscopic techniques used [113]. Despite no definitive consensus on the definition of endoscopic failure, persistent inflammation with clinical sepsis, and impossibility to resume oral feeding should be considered (Table 3) [114].

Inability to close the leak with time, especially after 4 months of treatment, should also prompt consideration of therapeutic alternatives, namely surgery [114].

It is important to highlight that surgery still has a key role in addressing PSL, both at the initial stages (allowing irrigation and drainage of intrathoracic or intra-abdominal collections) and at later stages if endoscopic treatment is not successful. Outcomes of salvage surgical procedures may be exaggerated due to selection bias, as patients are generally sicker or have failed multiple previous therapies [115].

To summarize, when approaching PSL, the following principles should be considered (Figure 8):

- (i) Referral of leaks for endoscopic treatment should be as soon as possible.
- (ii) In patients whose condition is unstable, with acute leaks and systemic inflammatory response syndrome or mediastinitis/peritonitis, surgical wash-out with or without drain placement is mandatory and should not be delayed. Concurrent endoscopic management with stent placement may also be effective in this setting, before the formation of an organized collection.
- (iii) Combined treatment with simultaneous or sequential use of several endoscopic methods may be optimal.
- (iv) Symptomatic and small (<10 mm) acute leaks, with healthy defect margins, may be considered for stenting, OTSC, or suture. Stenting may be a better option for intrathoracic leaks, while OTSC

and suture may be more suitable for intra-abdominal leaks.

- (v) For acute lesions with nonviable margins or size >10–15 mm, stenting or EVT can be considered. EVT might be a superior tool for the management of cervical leaks, larger leaks (>3 cm), and chronic leaks.
- (vi) EID may be considered for the management of subacute or chronic post-bariatric leaks with an organized walled-off collection. If this fails, EVT should be considered.
- (vii) Endoscopic septotomy may be performed in late or chronic sleeve leaks with organized walled-off collections, especially if failure of other techniques.
- (viii) In patients with post-SG leaks with high-grade downstream stenosis, additional pneumatic dilation with a balloon is required.
- (ix) In the setting of associated collections, if closure techniques are used, external drainage is required. EID and EVT allow early removal of external drainage preventing chronic fistula tract formation.
- (x) OTSCs and tissue sealants may be considered for closure of residual small collections after the use of other techniques.
- (xi) Have a high index of suspicion for situations in which endoscopic closure will probably not be effective. These situations include persistent inflammation with clinical sepsis, impossibility to resume oral feeding, inability to close the leak (especially after 4 months of treatment), and formation of enterocutaneous or enteropleural fistulas.

Data Availability

Data supporting this research article are available from the corresponding author or first author on reasonable request.

Consent

Publish consent was obtained from the patients regarding endoscopic figures.

Conflicts of Interest

The author(s) declare(s) that they have no conflicts of interest.

Authors' Contributions

Conception and design: Eduardo Rodrigues-Pinto. Literature review and drafting of the article: Eduardo Rodrigues-Pinto and Renato Medas. Critical revision of the article for

important intellectual content and final approval: Eduardo Rodrigues-Pinto.

References

- [1] N. S. Buttar, "Minimally invasive endoscopic approaches to manage postsurgical leaks: time to recognize the finger in the dike," *Gastrointestinal Endoscopy*, vol. 93, no. 6, pp. 1300–1303, 2021.
- [2] M. Messenger, M. Warlaumont, F. Renaud et al., "Recent improvements in the management of esophageal anastomotic leak after surgery for cancer," *European Journal of Surgical Oncology*, vol. 43, no. 2, pp. 258–269, 2017.
- [3] T. Lerut, W. Coosemans, G. Decker, P. De Leyn, P. Naftaux, and D. van Raemdonck, "Anastomotic complications after esophagectomy," *Digestive Surgery*, vol. 19, no. 2, pp. 92–98, 2002.
- [4] N. S. Blencowe, S. Strong, A. G. McNair et al., "Reporting of short-term clinical outcomes after esophagectomy: a systematic review," *Annals of Surgery*, vol. 255, no. 4, pp. 658–666, 2012.
- [5] H. Lang, P. Piso, C. Stukenborg, R. Raab, and J. Jähne, "Management and results of proximal anastomotic leaks in a series of 1114 total gastrectomies for gastric carcinoma," *European Journal of Surgical Oncology*, vol. 26, no. 2, pp. 168–171, 2000.
- [6] R. Gonzalez, M. G. Sarr, C. D. Smith et al., "Diagnosis and contemporary management of anastomotic leaks after gastric bypass for obesity," *Journal of the American College of Surgeons*, vol. 204, no. 1, pp. 47–55, 2007.
- [7] M. P. Morales, B. W. Miedema, J. S. Scott, and R. A. de la Torre, "Management of postsurgical leaks in the bariatric patient," *Gastrointestinal Endoscopy Clinics of North America*, vol. 21, no. 2, pp. 295–304, 2011.
- [8] A. Al-Kurd, R. Grinbaum, A. Abubeih, A. Verbner, A. Kupietzky, and I. Mizrahi, "Not all leaks are created equal: a comparison between leaks after sleeve gastrectomy and Roux-En-Y gastric bypass," *Obesity Surgery*, vol. 28, no. 12, pp. 3775–3782, 2018.
- [9] S. M. Griffin, P. J. Lamb, S. M. Dresner, D. L. Richardson, and N. Hayes, "Diagnosis and management of a mediastinal leak following radical oesophagectomy," *The British Journal of Surgery*, vol. 88, no. 10, pp. 1346–1351, 2001.
- [10] R. Souto-Rodríguez and M. V. Alvarez-Sánchez, "Endoluminal solutions to bariatric surgery complications: a review with a focus on technical aspects and results," *World Journal of Gastrointestinal Endoscopy*, vol. 9, no. 3, pp. 105–126, 2017.
- [11] A. Abou Rached, M. Basile, and H. El Masri, "Gastric leaks post sleeve gastrectomy: review of its prevention and management," *World Journal of Gastroenterology*, vol. 20, no. 38, pp. 13904–13910, 2014.
- [12] R. J. Rosenthal, A. A. Diaz, D. Arvidsson, R. S. Baker, N. Basso, and D. Bellanger, "International Sleeve Gastrectomy Expert Panel Consensus Statement: best practice guidelines based on experience of >12,000 cases," *Surgery for Obesity and Related Diseases*, vol. 8, no. 1, pp. 8–19, 2012.
- [13] G. Dionigi, R. Dionigi, F. Rovera et al., "Treatment of high output entero-cutaneous fistulae associated with large abdominal wall defects: single center experience," *International Journal of Surgery*, vol. 6, no. 1, pp. 51–56, 2008.

- [14] D. Lorenzo, T. Guilbaud, J. M. Gonzalez et al., "Endoscopic treatment of fistulas after sleeve gastrectomy: a comparison of internal drainage versus closure," *Gastrointestinal Endoscopy*, vol. 87, no. 2, pp. 429–437, 2018.
- [15] L. W. Thornblade, A. M. Cheng, D. E. Wood et al., "A nationwide rise in the use of stents for benign esophageal perforation," *The Annals of Thoracic Surgery*, vol. 104, no. 1, pp. 227–233, 2017.
- [16] S. Bouchard, P. Eisendrath, E. Toussaint, O. Le Moine, A. Lemmers, and M. Arvanitakis, "Trans-fistulary endoscopic drainage for post-bariatric abdominal collections communicating with the upper gastrointestinal tract," *Endoscopy*, vol. 48, no. 9, pp. 809–816, 2016.
- [17] J. X. Cai, M. A. Schweitzer, and V. Kumbhari, "Endoscopic management of bariatric surgery complications," *Surgical Laparoscopy, Endoscopy and Percutaneous Techniques*, vol. 26, no. 2, pp. 93–101, 2016.
- [18] M. Tachezy, S. H. Chon, I. Rieck et al., "Endoscopic vacuum therapy versus stent treatment of esophageal anastomotic leaks (ESOLEAK): study protocol for a prospective randomized phase 2 trial," *Trials*, vol. 22, no. 1, p. 377, 2021.
- [19] M. Fabbì, E. R. C. Hagens, M. I. van Berge Henegouwen, and S. S. Gisbertz, "Anastomotic leakage after esophagectomy for esophageal cancer: definitions, diagnostics, and treatment," *Diseases of the Esophagus*, vol. 34, no. 1, pp. 1–14, 2021.
- [20] M. Schietroma, E. M. Cecilia, F. Carlei, F. Sista, G. De Santis, and F. Piccione, "Prevention of anastomotic leakage after total gastrectomy with perioperative supplemental oxygen administration: a prospective randomized, double-blind, controlled, single-center trial," *Annals of Surgical Oncology*, vol. 20, no. 5, pp. 1584–1590, 2013.
- [21] L. Marano, R. Porfidia, M. Pezzella et al., "Clinical and immunological impact of early postoperative enteral immunonutrition after total gastrectomy in gastric cancer patients: a prospective randomized study," *Annals of Surgical Oncology*, vol. 20, no. 12, pp. 3912–3918, 2013.
- [22] G. Baretta, J. Campos, S. Correia et al., "Bariatric postoperative fistula: a life-saving endoscopic procedure," *Surgical Endoscopy*, vol. 29, no. 7, pp. 1714–1720, 2015.
- [23] J. A. Evans, V. R. Muthusamy, R. D. Acosta et al., "The role of endoscopy in the bariatric surgery patient," *Gastrointestinal Endoscopy*, vol. 81, no. 5, pp. 1063–1072, 2015.
- [24] A. Umemura, K. Koeda, A. Sasaki et al., "Totally laparoscopic total gastrectomy for gastric cancer: literature review and comparison of the procedure of esophagojejunostomy," *Asian Journal of Surgery*, vol. 38, no. 2, pp. 102–112, 2015.
- [25] D. Fuks, P. Verhaeghe, O. Brehant et al., "Results of laparoscopic sleeve gastrectomy: a prospective study in 135 patients with morbid obesity," *Surgery*, vol. 145, no. 1, pp. 106–113, 2009.
- [26] M. Gagner, C. Hutchinson, and R. Rosenthal, "Fifth International Consensus Conference: current status of sleeve gastrectomy," *Surgery for Obesity and Related Diseases*, vol. 12, no. 4, pp. 750–756, 2016.
- [27] S. Varadarajulu, S. Banerjee, B. Barth et al., "Enteral stents," *Gastrointestinal Endoscopy*, vol. 74, no. 3, pp. 455–464, 2011.
- [28] J. C. Bakken, L. M. Wong Kee Song, P. C. de Groen, and T. H. Baron, "Use of a fully covered self-expandable metal stent for the treatment of benign esophageal diseases," *Gastrointestinal Endoscopy*, vol. 72, no. 4, pp. 712–720, 2010.
- [29] E. Dabizzi and P. G. Arcidiacono, "Update on enteral stents," *Current Treatment Options in Gastroenterology*, vol. 14, no. 2, pp. 178–184, 2016.
- [30] K. Ishii, T. Itoi, A. Sofuni et al., "Endoscopic removal and trimming of distal self-expandable metallic biliary stents," *World Journal of Gastroenterology*, vol. 17, no. 21, pp. 2652–2657, 2011.
- [31] W. Wei, A. Ramaswamy, R. de la Torre, and B. W. Miedema, "Partially covered esophageal stents cause bowel injury when used to treat complications of bariatric surgery," *Surgical Endoscopy*, vol. 27, no. 1, pp. 56–60, 2013.
- [32] P. Yimcharoen, H. M. Heneghan, N. Tariq, S. A. Brethauer, M. Kroh, and B. Chand, "Endoscopic stent management of leaks and anastomotic strictures after foregut surgery," *Surgery for Obesity and Related Diseases*, vol. 7, no. 5, pp. 628–636, 2011.
- [33] A. Fischer, D. Bausch, and H. J. Richter-Schrag, "Use of a specially designed partially covered self-expandable metal stent (PSEMS) with a 40-mm diameter for the treatment of upper gastrointestinal suture or staple line leaks in 11 cases," *Surgical Endoscopy*, vol. 27, no. 2, pp. 642–647, 2013.
- [34] M. M. Hirdes, P. D. Siersema, M. H. Houben, B. L. Weusten, and F. P. Vleggaar, "Stent-in-stent technique for removal of embedded esophageal self-expanding metal stents," *The American Journal of Gastroenterology*, vol. 106, no. 2, pp. 286–293, 2011.
- [35] A. Murino, M. Arvanitakis, O. Le Moine, D. Blero, J. Devière, and P. Eisendrath, "Effectiveness of endoscopic management using self-expandable metal stents in a large cohort of patients with post-bariatric leaks," *Obesity Surgery*, vol. 25, no. 9, pp. 1569–1576, 2015.
- [36] M. Di Leo, R. Maselli, E. C. Ferrara, L. Poliani, S. Al Awadhi, and A. Repici, "Endoscopic management of benign esophageal ruptures and leaks," *Current Treatment Options in Gastroenterology*, vol. 15, no. 2, pp. 268–284, 2017.
- [37] R. K. Freeman, A. J. Ascoti, M. Dake, and R. S. Mahidhara, "An assessment of the optimal time for removal of esophageal stents used in the treatment of an esophageal anastomotic leak or perforation," *The Annals of Thoracic Surgery*, vol. 100, no. 2, pp. 422–428, 2015.
- [38] J. M. Buscaglia, S. Ho, A. Sethi, C. J. Dimaio, S. Nagula, and S. N. Stavropoulos, "Fully covered self-expandable metal stents for benign esophageal disease: a multicenter retrospective case series of 31 patients," *Gastrointestinal Endoscopy*, vol. 74, no. 1, pp. 207–211, 2011.
- [39] J. L. Tokar, S. Banerjee, B. A. Barth et al., "Drug-eluting/biodegradable stents," *Gastrointestinal Endoscopy*, vol. 74, no. 5, pp. 954–958, 2011.
- [40] V. Lorenzo-Zúñiga, V. Moreno-de-Vega, I. Marín, and J. Boix, "Biodegradable stents in gastrointestinal endoscopy," *World Journal of Gastroenterology*, vol. 20, no. 9, pp. 2212–2217, 2014.
- [41] J. S. Park, S. Jeong, and D. H. Lee, "Recent advances in gastrointestinal stent development," *Clinical Endoscopy*, vol. 48, no. 3, pp. 209–215, 2015.
- [42] B. V. Dasari, D. Neely, A. Kennedy et al., "The role of esophageal stents in the management of esophageal anastomotic leaks and benign esophageal perforations," *Annals of Surgery*, vol. 259, no. 5, pp. 852–860, 2014.
- [43] S. K. Kamarajah, J. Bundred, G. Spence, A. Kennedy, B. V. M. Dasari, and E. A. Griffiths, "Critical appraisal of the impact of oesophageal stents in the management of oesophageal

- anastomotic leaks and benign oesophageal perforations: an updated systematic review,” *World Journal of Surgery*, vol. 44, no. 4, pp. 1173–1189, 2020.
- [44] P. G. van Boeckel, A. Sijbring, F. P. Vleggaar, and P. D. Siersema, “Systematic review: temporary stent placement for benign rupture or anastomotic leak of the oesophagus,” *Alimentary Pharmacology and Therapeutics*, vol. 33, no. 12, pp. 1292–1301, 2011.
 - [45] H. M. Shehab, S. M. Hakky, and K. A. Gawdat, “An endoscopic strategy combining mega stents and over-the-scope clips for the management of post-bariatric surgery leaks and fistulas (with video),” *Obesity Surgery*, vol. 26, no. 5, pp. 941–948, 2016.
 - [46] W. Alazmi, S. Al-Sabah, D. A. Ali, and S. Almazeedi, “Treating sleeve gastrectomy leak with endoscopic stenting: the Kuwaiti experience and review of recent literature,” *Surgical Endoscopy*, vol. 28, no. 12, pp. 3425–3428, 2014.
 - [47] S. H. Blackmon, R. Santora, P. Schwarz, A. Barroso, and B. J. Dunkin, “Utility of removable esophageal covered self-expanding metal stents for leak and fistula management,” *The Annals of Thoracic Surgery*, vol. 89, no. 3, pp. 931–937, 2010, discussion 936–7.
 - [48] P. Eisendrath, M. Cremer, J. Himpens, G. B. Cadière, O. Le Moine, and J. Devière, “Endotherapy including temporary stenting of fistulas of the upper gastrointestinal tract after laparoscopic bariatric surgery,” *Endoscopy*, vol. 39, no. 7, pp. 625–630, 2007.
 - [49] H. El Mourad, J. Himpens, and J. Verhofstadt, “Stent treatment for fistula after obesity surgery: results in 47 consecutive patients,” *Surgical Endoscopy*, vol. 27, no. 3, pp. 808–816, 2013.
 - [50] S. Eubanks, C. A. Edwards, N. M. Fearing et al., “Use of endoscopic stents to treat anastomotic complications after bariatric surgery,” *Journal of the American College of Surgeons*, vol. 206, no. 5, pp. 935–938, 2008, discussion 938–9.
 - [51] S. Fishman, M. Shnell, N. Gluck, S. Meirsdorf, S. Abu-Abeid, and E. Santo, “Use of sleeve-customized self-expandable metal stents for the treatment of staple-line leakage after laparoscopic sleeve gastrectomy,” *Gastrointestinal Endoscopy*, vol. 81, no. 5, pp. 1291–1294, 2015.
 - [52] B. J. Leenders, A. Stronkhorst, F. J. Smulders, G. A. Nieuwenhuijzen, and L. P. Gilissen, “Removable and repositionable covered metal self-expandable stents for leaks after upper gastrointestinal surgery: experiences in a tertiary referral hospital,” *Surgical Endoscopy*, vol. 27, no. 8, pp. 2751–2759, 2013.
 - [53] A. Orive-Calzada, Á. Calderón-García, A. Bernal-Martínez et al., “Closure of benign leaks, perforations, and fistulas with temporary placement of fully covered metal stents: a retrospective analysis,” *Surgical Laparoscopy, Endoscopy and Percutaneous Techniques*, vol. 24, no. 6, pp. 528–536, 2014.
 - [54] N. Quezada, C. Maiz, D. Daroch et al., “Effect of early use of covered self-expandable endoscopic stent on the treatment of postoperative stapler line leaks,” *Obesity Surgery*, vol. 25, no. 10, pp. 1816–1821, 2015.
 - [55] T. Southwell, T. H. Lim, and R. Ogra, “Endoscopic therapy for treatment of staple line leaks post-laparoscopic sleeve gastrectomy (LSG): experience from a large bariatric surgery Centre in New Zealand,” *Obesity Surgery*, vol. 26, no. 6, pp. 1155–1162, 2016.
 - [56] M. R. van Wezenbeek, M. M. de Milliano, S. W. Nienhuijs, P. Friederich, and L. P. Gilissen, “A specifically designed stent for anastomotic leaks after bariatric surgery: experiences in a tertiary referral hospital,” *Obesity Surgery*, vol. 26, no. 8, pp. 1875–1880, 2016.
 - [57] T. C. C. Boerlage, G. P. M. Houben, M. J. M. Groenen et al., “A novel fully covered double-bump stent for staple line leaks after bariatric surgery: a retrospective analysis,” *Surgical Endoscopy*, vol. 32, no. 7, pp. 3174–3180, 2018.
 - [58] H. El II, T. F. Imperiale, D. K. Rex, D. Ballard, K. A. Kesler, and T. J. Birdas, “Treatment of esophageal leaks, fistulae, and perforations with temporary stents: evaluation of efficacy, adverse events, and factors associated with successful outcomes,” *Gastrointestinal Endoscopy*, vol. 79, no. 4, pp. 589–598, 2014.
 - [59] S. Persson, I. Rouvelas, K. Kumagai et al., “Treatment of esophageal anastomotic leakage with self-expanding metal stents: analysis of risk factors for treatment failure,” *Endoscopy International Open*, vol. 4, no. 4, pp. E420–E426, 2016.
 - [60] R. K. Freeman, A. J. Ascoti, T. Giannini, and R. J. Mahidhara, “Analysis of unsuccessful esophageal stent placements for esophageal perforation, fistula, or anastomotic leak,” *The Annals of Thoracic Surgery*, vol. 94, no. 3, pp. 959–965, 2012, discussion 964–5.
 - [61] M. Nedelcu, T. Manos, A. Cotirlet, P. Noel, and M. Gagner, “Outcome of leaks after sleeve gastrectomy based on a new algorithm addressing leak size and gastric stenosis,” *Obesity Surgery*, vol. 25, no. 3, pp. 559–563, 2015.
 - [62] C. A. Puig, T. M. Waked, T. H. Baron Sr., L. M. Wong Kee Song, J. Gutierrez, and M. G. Sarr, “The role of endoscopic stents in the management of chronic anastomotic and staple line leaks and chronic strictures after bariatric surgery,” *Surgery for Obesity and Related Diseases*, vol. 10, no. 4, pp. 613–617, 2014.
 - [63] A. Kirschniak, T. Kratt, D. Stüker, A. Braun, M. O. Schurr, and A. Königsrainer, “A new endoscopic over-the-scope clip system for treatment of lesions and bleeding in the GI tract: first clinical experiences,” *Gastrointestinal Endoscopy*, vol. 66, no. 1, pp. 162–167, 2007.
 - [64] A. Baruah, L. M. W. Kee Song, and N. S. Buttar, “Endoscopic management of fistulas, perforations, and leaks,” *Techniques in Gastrointestinal Endoscopy*, vol. 17, no. 4, pp. 178–188, 2015.
 - [65] M. Bauder, B. Meier, K. Caca, and A. Schmidt, “Endoscopic removal of over-the-scope clips: clinical experience with a bipolar cutting device,” *United European Gastroenterology Journal*, vol. 5, no. 4, pp. 479–484, 2017.
 - [66] A. Arezzo, A. Bullano, H. Fischer, and M. Morino, “The way to remove an over-the-scope-clip (with video),” *Gastrointestinal Endoscopy*, vol. 77, no. 6, pp. 974–975, 2013.
 - [67] Y. Haito-Chavez, J. K. Law, T. Kratt et al., “International multicenter experience with an over-the-scope clipping device for endoscopic management of GI defects (with video),” *Gastrointestinal Endoscopy*, vol. 80, no. 4, pp. 610–622, 2014.
 - [68] H. Kobara, H. Mori, N. Nishiyama et al., “Over-the-scope clip system: a review of 1517 cases over 9 years,” *Journal of Gastroenterology and Hepatology*, vol. 34, no. 1, pp. 22–30, 2019.
 - [69] P. Rogalski, A. Swidnicka-Siergiejko, J. Wasielica-Berger et al., “Endoscopic management of leaks and fistulas after bariatric surgery: a systematic review and meta-analysis,” *Surgical Endoscopy*, vol. 35, no. 3, pp. 1067–1087, 2021.
 - [70] A. F. Hagel, A. Naegel, A. S. Lindner et al., “Over-the-scope clip application yields a high rate of closure in gastrointestinal perforations and may reduce emergency surgery,” *Journal of Gastrointestinal Surgery*, vol. 16, no. 11, pp. 2132–2138, 2012.

- [71] P. Mercky, J. M. Gonzalez, E. Aimore Bonin et al., "Usefulness of over-the-scope clipping system for closing digestive fistulas," *Digestive Endoscopy*, vol. 27, no. 1, pp. 18–24, 2015.
- [72] A. Hernandez, N. B. Marya, T. Sawas, E. Rajan, N. M. Gades, and W. K. Song, "Gastrointestinal defect closure using a novel through-the-scope helix tack and suture device compared to endoscopic clips in a survival porcine model (with video)," *Endoscopy International Open*, vol. 9, no. 4, pp. E572–e577, 2021.
- [73] A. Hernandez-Lara, A. Garcia de Paredes, E. Rajan, and A. C. Storm, "Step-by-step instruction: using an endoscopic tack and suture device for gastrointestinal defect closure," *VideoGIE*, vol. 6, no. 6, pp. 243–245, 2021.
- [74] R. Z. Sharaiha, N. A. Kumta, E. M. DeFilippis et al., "A large multicenter experience with endoscopic suturing for management of gastrointestinal defects and stent anchorage in 122 patients: a retrospective review," *Journal of Clinical Gastroenterology*, vol. 50, no. 5, pp. 388–392, 2016.
- [75] G. Bonanomi, J. M. Prince, F. McSteen, P. R. Schauer, and G. G. Hamad, "Sealing effect of fibrin glue on the healing of gastrointestinal anastomoses: implications for the endoscopic treatment of leaks," *Surgical Endoscopy*, vol. 18, no. 11, pp. 1620–1624, 2004.
- [76] F. Maluf-Filho, F. Hondo, B. Halwan, M. S. de Lima, J. H. Giordano-Nappi, and P. Sakai, "Endoscopic treatment of Roux-en-Y gastric bypass-related gastrocutaneous fistulas using a novel biomaterial," *Surgical Endoscopy*, vol. 23, no. 7, pp. 1541–1545, 2009.
- [77] K. Kotzampassi and E. Eleftheriadis, "Tissue sealants in endoscopic applications for anastomotic leakage during a 25-year period," *Surgery*, vol. 157, no. 1, pp. 79–86, 2015.
- [78] R. Vilallonga, J. Himpens, B. Bosch, S. van de Vrande, and J. Bafort, "Role of percutaneous glue treatment after persisting leak after laparoscopic sleeve gastrectomy," *Obesity Surgery*, vol. 26, no. 7, pp. 1378–1383, 2016.
- [79] G. Böhm, A. Mossdorf, C. Klink et al., "Treatment algorithm for postoperative upper gastrointestinal fistulas and leaks using combined vicryl plug and fibrin glue," *Endoscopy*, vol. 42, no. 7, pp. 599–602, 2010.
- [80] E. Lippert, F. H. Klebl, F. Schweller et al., "Fibrin glue in the endoscopic treatment of fistulae and anastomotic leakages of the gastrointestinal tract," *International Journal of Colorectal Disease*, vol. 26, no. 3, pp. 303–311, 2011.
- [81] V. D. Plat, B. T. Bootsma, N. van der Wielen et al., "The role of tissue adhesives in esophageal surgery, a systematic review of literature," *International Journal of Surgery*, vol. 40, pp. 163–168, 2017.
- [82] D. T. H. de Moura, A. C. B. Dantas, I. B. Ribeiro et al., "Status of bariatric endoscopy-what does the surgeon need to know? A review," *World Journal of Gastrointestinal Surgery*, vol. 14, no. 2, pp. 185–199, 2022.
- [83] D. T. H. De Moura, A. Baptista, P. Jirapinyo, E. G. H. De Moura, and C. Thompson, "Role of cardiac septal occluders in the treatment of gastrointestinal fistulas: a systematic review," *Clinical Endoscopy*, vol. 53, no. 1, pp. 37–48, 2020.
- [84] A. Baptista, D. T. Hourneaux De Moura, P. Jirapinyo, E. G. Hourneaux De Moura, A. Gelrud, and M. Kahaleh, "Efficacy of the cardiac septal occluder in the treatment of post-bariatric surgery leaks and fistulas," *Gastrointestinal Endoscopy*, vol. 89, no. 4, pp. 671–679.e1, 2019.
- [85] D. T. Hourneaux de Moura, P. Jirapinyo, K. E. Hathorn, and C. C. Thompson, "Use of a cardiac septal occluder in the treatment of a chronic GI fistula: what should we know before off-label use in the GI tract?," *VideoGIE*, vol. 4, no. 3, pp. 114–117, 2019.
- [86] P. Vikatmaa, V. Juutilainen, P. Kuukasjärvi, and A. Malmivaara, "Negative pressure wound therapy: a systematic review on effectiveness and safety," *European Journal of Vascular and Endovascular Surgery*, vol. 36, no. 4, pp. 438–448, 2008.
- [87] F. Kuehn, L. Schiffmann, B. M. Rau, and E. Klar, "Surgical endoscopic vacuum therapy for anastomotic leakage and perforation of the upper gastrointestinal tract," *Journal of Gastrointestinal Surgery*, vol. 16, no. 11, pp. 2145–2150, 2012.
- [88] G. Loske and C. Müller, "Endoscopic vacuum-assisted closure of upper intestinal anastomotic leaks," *Gastrointestinal Endoscopy*, vol. 69, no. 3, pp. 601–602, 2009, author reply 602.
- [89] J. Wedemeyer, A. Schneider, M. P. Manns, and S. Jackobs, "Endoscopic vacuum-assisted closure of upper intestinal anastomotic leaks," *Gastrointestinal Endoscopy*, vol. 67, no. 4, pp. 708–711, 2008.
- [90] M. Ahrens, T. Schulte, J. Egberts et al., "Drainage of esophageal leakage using endoscopic vacuum therapy: a prospective pilot study," *Endoscopy*, vol. 42, no. 9, pp. 693–698, 2010.
- [91] R. Weidenhagen, W. H. Hartl, K. U. Gruetzner, M. E. Eichhorn, F. Spelsberg, and K. W. Jauch, "Anastomotic leakage after esophageal resection: new treatment options by endoluminal vacuum therapy," *The Annals of Thoracic Surgery*, vol. 90, no. 5, pp. 1674–1681, 2010.
- [92] B. Schniewind, C. Schafmayer, M. Both, A. Arlt, A. Fritscher-Ravens, and J. Hampe, "Ingrowth and device disintegration in an intralobar abscess cavity during endosponge therapy for esophageal anastomotic leakage," *Endoscopy*, vol. 43, no. 43 Suppl 2 UCTN, pp. E64–E65, 2011.
- [93] R. Mennigen, N. Senninger, and M. G. Laukoetter, "Novel treatment options for perforations of the upper gastrointestinal tract: endoscopic vacuum therapy and over-the-scope clips," *World Journal of Gastroenterology*, vol. 20, no. 24, pp. 7767–7776, 2014.
- [94] M. Bludau, H. F. Fuchs, T. Herbold et al., "Results of endoscopic vacuum-assisted closure device for treatment of upper GI leaks," *Surgical Endoscopy*, vol. 32, no. 4, pp. 1906–1914, 2018.
- [95] M. G. Laukoetter, R. Mennigen, P. A. Neumann et al., "Successful closure of defects in the upper gastrointestinal tract by endoscopic vacuum therapy (EVT): a prospective cohort study," *Surgical Endoscopy*, vol. 31, no. 6, pp. 2687–2696, 2017.
- [96] T. Schorsch, C. Müller, and G. Loske, "Endoscopic vacuum therapy of perforations and anastomotic insufficiency of the esophagus," *Chirurg*, vol. 85, no. 12, pp. 1081–1093, 2014.
- [97] G. Tavares, F. Tustumi, L. S. Tristão, and W. M. Bernardo, "Endoscopic vacuum therapy for anastomotic leak in esophagectomy and total gastrectomy: a systematic review and meta-analysis," *Diseases of the Esophagus*, vol. 34, no. 5, pp. 1–11, 2021.
- [98] D. H. Jung, C. W. Huh, Y. W. Min, and J. C. Park, "Endoscopic vacuum therapy for the management of upper GI leaks and perforations: a multicenter retrospective study of factors associated with treatment failure (with video)," *Gastrointestinal Endoscopy*, vol. 95, no. 2, pp. 281–290, 2022.

- [99] S. M. Chan, K. K. Y. Auyeung, S. F. Lam, P. W. Y. Chiu, and A. Y. B. Teoh, "Current status in endoscopic management of upper gastrointestinal perforations, leaks and fistulas," *Digestive Endoscopy*, vol. 34, no. 1, pp. 43–62, 2022.
- [100] J. R. Watkins and A. S. Farivar, "Endoluminal therapies for esophageal perforations and leaks," *Thoracic Surgery Clinics*, vol. 28, no. 4, pp. 541–554, 2018.
- [101] D. J. Pournaras, R. H. Hardwick, P. M. Safranek et al., "Endoluminal vacuum therapy (E-Vac): a treatment option in oesophagogastric surgery," *World Journal of Surgery*, vol. 42, no. 8, pp. 2507–2511, 2018.
- [102] J. M. Gonzalez, D. Lorenzo, T. Guilbaud, T. Bège, and M. Barthet, "Internal endoscopic drainage as first line or second line treatment in case of postsleeve gastrectomy fistulas," *Endoscopy International Open*, vol. 6, no. 6, pp. E745–e750, 2018.
- [103] G. Donatelli, J. L. Dumont, F. Cereatti et al., "Treatment of leaks following sleeve gastrectomy by endoscopic internal drainage (EID)," *Obesity Surgery*, vol. 25, no. 7, pp. 1293–1301, 2015.
- [104] T. Gupta, A. Lemmers, D. Tan, M. Ibrahim, O. Le Moine, and J. Devière, "EUS-guided transmural drainage of postoperative collections," *Gastrointestinal Endoscopy*, vol. 76, no. 6, pp. 1259–1265, 2012.
- [105] T. Bège, O. Emungania, V. Vitton et al., "An endoscopic strategy for management of anastomotic complications from bariatric surgery: a prospective study," *Gastrointestinal Endoscopy*, vol. 73, no. 2, pp. 238–244, 2011.
- [106] A. Lemmers, D. M. Tan, M. Ibrahim, P. Loi, D. De Backer, and J. Closset, "Transluminal or percutaneous endoscopic drainage and debridement of abscesses after bariatric surgery: a case series," *Obesity Surgery*, vol. 25, no. 11, pp. 2190–2199, 2015.
- [107] G. Donatelli, J. M. Catheline, J. L. Dumont et al., "Outcome of leaks after sleeve gastrectomy based on a new algorithm addressing leak size and gastric stenosis," *Obesity Surgery*, vol. 25, no. 7, pp. 1258–1260, 2015.
- [108] M. Gjeorgjieviski, Z. Imam, M. S. Cappell, L. H. Jamil, and M. Kahaleh, "A comprehensive review of endoscopic management of sleeve gastrectomy leaks," *Journal of Clinical Gastroenterology*, vol. 55, no. 7, pp. 551–576, 2021.
- [109] D. Hughes, I. Hughes, and A. Khanna, "Management of staple line leaks following sleeve gastrectomy—a systematic review," *Obesity Surgery*, vol. 29, no. 9, pp. 2759–2772, 2019.
- [110] J. M. Campos, F. C. Ferreira, A. F. Teixeira, J. S. Lima, R. C. Moon, and M. A. D'Assunção, "Septotomy and balloon dilation to treat chronic leak after sleeve gastrectomy: technical principles," *Obesity Surgery*, vol. 26, no. 8, pp. 1992–1993, 2016.
- [111] P. Eisendrath and J. Devière, "Digestive leaks: an approach tailored to both indication and anatomy," *Endoscopy International Open*, vol. 4, no. 6, pp. E652–E653, 2016.
- [112] J. Swinnen, P. Eisendrath, J. Rigaux, L. Kahegeshe, A. Lemmers, and O. Le Moine, "Self-expandable metal stents for the treatment of benign upper GI leaks and perforations," *Gastrointestinal Endoscopy*, vol. 73, no. 5, pp. 890–899, 2011.
- [113] E. Rodrigues-Pinto, P. Pereira, B. Sousa-Pinto et al., "Retrospective multicenter study on endoscopic treatment of upper GI postsurgical leaks," *Gastrointestinal Endoscopy*, vol. 93, no. 6, pp. 1283–1299.e2, 2021.
- [114] E. Rodrigues-Pinto, A. Repici, G. Donatelli et al., "International multicenter expert survey on endoscopic treatment of upper gastrointestinal anastomotic leaks," *Endoscopy International Open*, vol. 7, no. 12, pp. E1671–e1682, 2019.
- [115] A. Z. Fernandez Jr., E. J. DeMaria, D. S. Tichansky, J. M. Kellum, L. G. Wolfe, and J. Meador, "Experience with over 3,000 open and laparoscopic bariatric procedures: multivariate analysis of factors related to leak and resultant mortality," *Surgical Endoscopy*, vol. 18, no. 2, pp. 193–197, 2004.