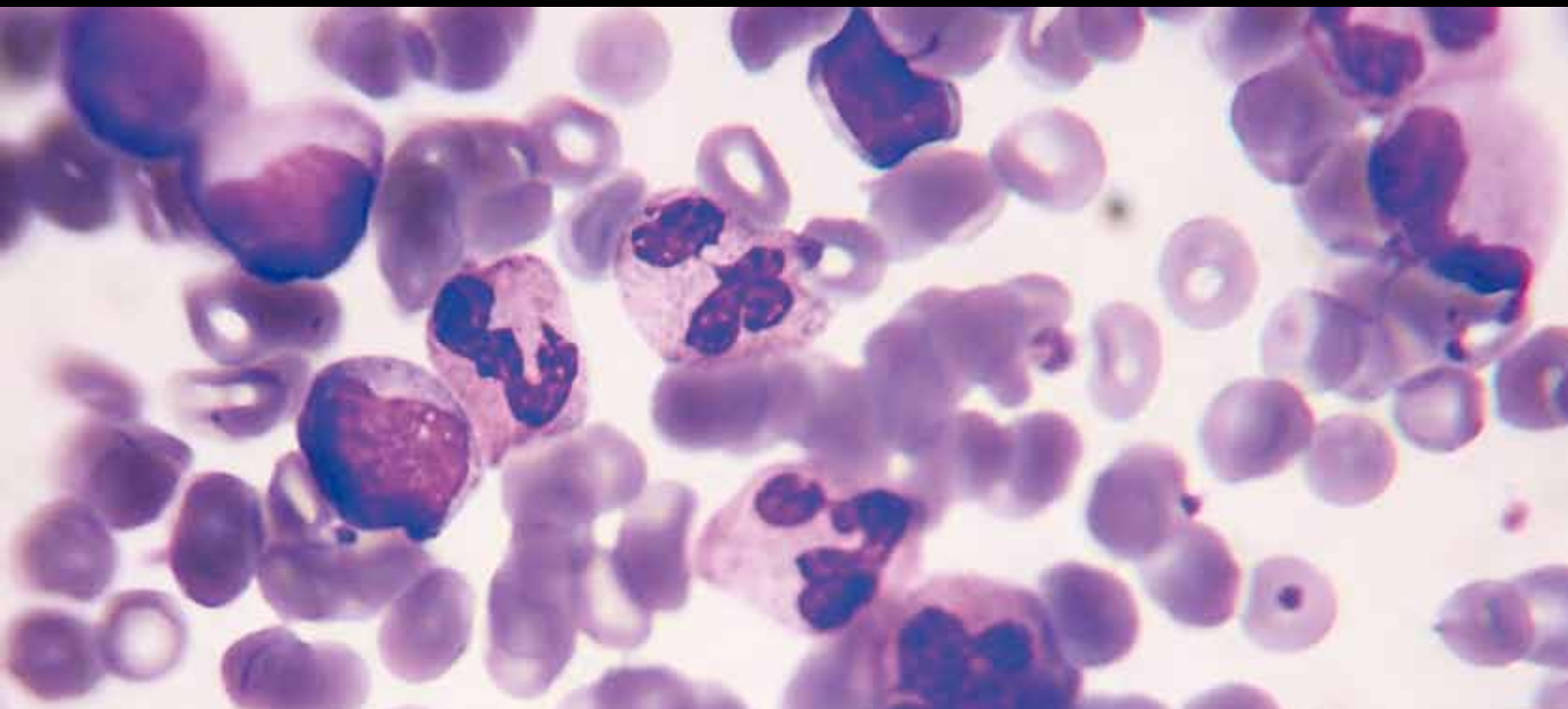


Pathological and Immunological Developments in Behcet's Disease

Guest Editors: Umit Tursen, Gamze Piskin, Torello Lotti,
and Fereydoun Davatchi





Pathological and Immunological Developments in Behcet's Disease

Pathological and Immunological Developments in Behcet's Disease

Guest Editors: Umit Tursen, Gamze Piskin, Torello Lotti,
and Fereydoun Davatchi



Copyright © 2012 Hindawi Publishing Corporation. All rights reserved.

This is a special issue published in "Pathology Research International." All articles are open access articles distributed under the Creative Commons Attribution License, which permits unrestricted use, distribution, and reproduction in any medium, provided the original work is properly cited.

Editorial Board

Fadi W. Abdul-Karim, USA
Pablo A. Bejarano, USA
Stephen M. Bonsib, USA
Allen Burke, USA
Runjan M. Chetty, Canada
Oscar W. Cummings, USA
Helmut Denk, Austria
Hala El-Zimaity, Canada
Evan R. Farmer, USA
Chris D. M. Fletcher, USA
Anthony John Freemont, UK
Bertha Garcia, Canada
Thomas J. Giordano, USA
Stefan G. Hubscher, UK
Naila Kayani, Pakistan
Michael Koss, USA

Anand Shreeram Lagoo, USA
C. Soon Lee, Australia
H. A. Lehr, Switzerland
Helen Liapis, USA
Youhua Liu, USA
Teri A. Longacre, USA
Gregory MacLennan, USA
R. Montironi, Italy
Wolter J. Mooi, The Netherlands
George L. Mutter, USA
Werner Paulus, Germany
S. Pervez, Pakistan
Maria M. Picken, USA
Phillip Ruiz, USA
Thomas Schaffner, Switzerland
Vinod B. Shidham, USA

Gad Singer, Switzerland
P. J. Slootweg, The Netherlands
Paul E. Swanson, USA
Steven R. Tahan, USA
Ming Teh, Singapore
Luigi Terracciano, Switzerland
Ka F. To, Hong Kong
Piero Tosi, Italy
Gary Tse, Hong Kong
J. van den Tweel, The Netherlands
P. J. Van Diest, The Netherlands
Marco Volante, Italy
Hanlin L. Wang, USA
Elizabeth Wiley, USA
I-Tien Yeh, USA
Anjana V. Yeldandi, USA

Contents

Pathological and Immunological Developments in Behcet's Disease, Umit Tursen, Gamze Piskin, Torello Lotti, and Fereydoun Davatchi
Volume 2012, Article ID 305780, 2 pages

Development of Immunopathogenesis Strategies to Treat Behçets Disease, Osman Köse
Volume 2012, Article ID 261989, 7 pages

Animal Models in Behçet's Disease, Ozlem Yildirim
Volume 2012, Article ID 273701, 8 pages

Potential Infectious Etiology of Behçet's Disease, Massimiliano Galeone, Roberta Colucci, Angelo Massimiliano D'Erme, Silvia Moretti, and Torello Lotti
Volume 2012, Article ID 595380, 4 pages

Behcet's Disease and Endocrine System, Onur Ozhan and Kerem Sezer
Volume 2012, Article ID 827815, 3 pages

Clinical and Pathological Manifestations with Differential Diagnosis in Behçet's Disease, Aysin Kokturk
Volume 2012, Article ID 690390, 9 pages

Pathologic Features of Behçet's Disease in the Tubuler Gut, Tuba Kara and Duygu Düşmez Apa
Volume 2012, Article ID 216254, 6 pages

Histopathological Evaluation of Behçet's Disease and Identification of New Skin Lesions, Özgür Gündüz
Volume 2012, Article ID 209316, 7 pages

Genetics of Behçet's Disease, Tamer İrfan Kaya
Volume 2012, Article ID 912589, 6 pages

New Evidence-Based Treatment Approach in Behçet's Disease, Erkan Alpsoy
Volume 2012, Article ID 871019, 11 pages

Pathophysiology of the Behçet's Disease, Ümit Trsen
Volume 2012, Article ID 493015, 11 pages

Diagnosis/Classification Criteria for Behcet's Disease, Fereydoun Davatchi
Volume 2012, Article ID 607921, 5 pages

Musculoskeletal Findings in Behcet's Disease, Ali Bicer
Volume 2012, Article ID 653806, 5 pages

Editorial

Pathological and Immunological Developments in Behcet's Disease

Umit Tursen,¹ Gamze Piskin,² Torello Lotti,³ and Fereydoun Davatchi⁴

¹ Department of Dermatology, Mersin Medical School, University of Mersin, 33079, Mersin, Turkey

² Department of Dermatology, Bovenij Ziekenhuis, Statenjachtstraat 1, 1034 CS Amsterdam, Postbus 37610, 1030 BD Amsterdam, The Netherlands

³ Department of Dermatology, University of Florence, Via della Pergola 60, 50132 Florence, Italy

⁴ Rheumatology Research Center, Shariati Hospital, Kargar Avenue, Tehran 144114, Iran

Correspondence should be addressed to Umit Tursen, utursen@mersin.edu.tr

Received 9 February 2012; Accepted 9 February 2012

Copyright © 2012 Umit Tursen et al. This is an open access article distributed under the Creative Commons Attribution License, which permits unrestricted use, distribution, and reproduction in any medium, provided the original work is properly cited.

Behcet's disease is a rare form of vasculitis that may have systemic multiorgan involvement. Behcet's disease was first defined by Hulusi Behcet, a Turkish Professor of Dermatology, in 1937 as a triad of recurrent aphthous stomatitis, genital aphthae, and relapsing uveitis. As this disease can be fatal, an immediate medical treatment is mandatory. So far there is no specific pathological testing or technique available for the diagnosis of the disease, although the International Study Group criteria for the disease are of good sensitivity and specificity. However, quite a portion of patients are misdiagnosed or have been delayed diagnosis. During the ensuing 65 years, multiple systemic associations of the disease including articular, vascular, gastrointestinal, cardiopulmonary, and neurologic involvement have become increasingly apparent. Although the etiology and pathogenesis is not clearly defined, genetic predisposition, infections, and immunological dysfunctions have been implicated. Behcet's disease has been reported worldwide but has a distinct geographic distribution, with highest prevalences in countries along with the ancient silk route. Although much has been learned during recent years on the pathogenesis and treatment of the disease, it is still an important cause of morbidity and mortality in areas where it is prevalent.

The entitled "*Musculoskeletal findings in Behcet's disease*" addresses the musculoskeletal findings of Behcet's disease, the relationship between Behcet's disease and spondyloarthropathy disease complex, and the status of bone metabolism in patients with Behcet's disease.

Professor Fereydoun Davatchi presents us the new diagnosis/classification criteria for Behcet's disease. The author finds that ICBBD criteria have better sensitivity and accuracy than ISG. In the paper is entitled "*Pathophysiology of Behcet's disease*", and we think that there is some clinical evidence suggesting that emotional stress and hormonal alterations can influence the course and disease activity of BD. Professor Erkan Alpsoy presents that the new evidence-based treatment is mainly based on the suppression of inflammatory attacks of the disease using immunomodulatory and immunosuppressive agents. In this paper, current state of knowledge regarding the therapeutic approaches is outlined. To provide a rational framework for selecting the appropriate therapy along with the various treatment choices, a stepwise, symptom-based, evidence-based algorithmic approach was developed. The fifth paper entitled "*Genetics of Behcet's disease*" describes HLA and non-HLA genetic association studies in BD. In recent years, several genomewide association studies and genetic polymorphism studies have also found new genetic associations with BD, which may have a supplementary role in disease susceptibility and/or severity. The paper entitled "*Histopathological evaluation of Behcet's disease and identification of new different skin lesions*" proposes that there has been an increase in the studies focusing on the histopathological aspects of Behcet's disease diagnostic mucocutaneous lesions. Their results emphasize the value of histopathology and direct immunofluorescence (DIF) in the differential diagnosis of Behcet's disease.

Tuba Kara and Duygu Dusmez Apa discuss the pathologic features of BD in the tubular gut. Professor Aysin

Kokturk describes that the differential diagnosis depends on a careful evaluation of the medical history and meticulous physical examination to detect concomitant systemic manifestations. Sometimes, some laboratory test may help establish the diagnosis. Subspecialty referral to ophthalmology, rheumatology, neurology, and gastroenterology should be considered when indicated. The paper about BD and endocrine system shows that the available data suggest that there is an increased susceptibility to insulin resistance in patients with BD. And also the authors indicate that not only anterior hypophysis functions but also posterior hypophysis functions can be affected. As BD is a disease of autoimmune process, it may be possible that adrenal insufficiency or alterations in the cortisol levels could be expected.

The article entitled "*Potential infectious etiology of Behcet's disease*" indicates that an infectious agent could operate through molecular mimicry, and subsequently the disease could be perpetuated by an abnormal immune response to an autoantigen in the absence of ongoing infection. Potential bacteria are *Saccharomyces cerevisiae*, mycobacteria, *Borrelia burgdorferi*, *Helicobacter pylori*, *Escherichia coli*, *Staphylococcus aureus*, and *Mycoplasma fermentans*, but the most commonly investigated microorganism is *Streptococcus sanguinis*. The relationship between streptococcal infections and Behcet's disease is suggested by clinical observations that an unhygienic oral condition is frequently noted in the oral cavity of Behcet's disease patients. Several viral agents, including herpes simplex virus-1, hepatitis C virus, parvovirus B19, cytomegalovirus, Epstein-Barr virus, and varicella zoster virus, may also have some role.

Professor Ozlem Yildirim shows that animal models allow for a more effective investigations into BD. The paper entitled "*Development of immunopathogenesis strategies to treat Behcet's disease*" finds that understanding of the new pathogenic mechanisms based on molecular structure of the disease helps us in improving the novel therapeutic modalities.

Umit Tursen
Gamze Piskin
Torello Lotti
Fereydoun Davatchi

Review Article

Development of Immunopathogenesis Strategies to Treat Behçet's Disease

Osman Köse

Department of Dermatology, School of Medicine, Gülhane Military Medical Academy, Tevfik Saglam Street No. 1, 06018 Ankara, Turkey

Correspondence should be addressed to Osman Köse, drosmankose@yahoo.com

Received 8 August 2011; Accepted 25 January 2012

Academic Editor: Ümit Tursen

Copyright © 2012 Osman Köse. This is an open access article distributed under the Creative Commons Attribution License, which permits unrestricted use, distribution, and reproduction in any medium, provided the original work is properly cited.

Behçet disease is a chronic relapsing vasculitis with unclear etiology and immunopathogenesis. Antigenic stimuli, antigen presenting cells, T cells, monocyte, and neutrophil and endothelial cells are major parts of the pathology of the disease. Understanding of the new pathogenic mechanisms based on molecular structure of the disease helps us in improving the novel therapeutic modalities. These drugs target specific and nonspecific inhibition of the immun system. These therapies include biologic agents, new topical and systemic immunosuppressants, tolerizing agents, and immunoablation. Novel treatment will be promising to treat the especially recalcitrant cases to conventional therapy. In this paper, new aspect of the immunopathogenesis of Behçet's diseases and novel treatment modalities will be discussed.

1. Introduction

Behçet disease (BD) is a vasculitis that, characterized by recurrent aphthous stomatitis, genital ulcers, skin lesions, relapsing uveitis, articular, neurologic, urogenital, vascular, intestinal, and pulmonary manifestations [1–3]. BD has been reported worldwide but has a distinct geographic distribution, with highest prevalences in countries such as Turkey, Iran, and Japan which are place on silk road. Although much has been learned during recent years on the pathogenesis and treatment of the disease, the etiology and pathogenesis of BD have not been fully clarified [4, 5]. Symptoms of the disease are considered to be based on the correlation between the genetic intrinsic factors and the triggering extrinsic factors, because more than 60% of BD patients are associated with HLA-B 51. Immune-mediated mechanisms play a major role in the pathogenesis of the disease, and inflammatory mediators are also involved [4–6]. Nowadays, recent investigations have made clear explanations about the pathogenesis of the disease. The hypersensitivity of T lymphocytes to different types of antigens plays a crucial role in the pathogenesis [3–6].

The present paper overviews an update on the immunopathogenesis of BD and also novel treatment based on pathogenesis.

2. Immunopathogenesis of Behçet's Disease

BD is an inflammatory disorder characterized mainly by mucocutaneous findings and uveitis. However, it can be present with other cutaneous symptoms such as pseudofolliculitis, erythema nodosum, and pyoderma gangrenosum [2–5]. It can be present with articular, neurological, pulmonary, intestinal manifestations other than classical triad. The close relationship between the genetic and triggering external factors is thought to be present in the pathogenesis of BD [3, 4]. The immunopathogenesis of BD is shown in Figure 1. Critical region for BD in the human major histocompatibility complex (MHC) gene could be pinpointed to a 46 kb segment between the MHC class I gene and HLA-B51 gene [5].

2.1. Heat Shock Proteins (HSP). HSP, which essentially scavenge denatured intracellular proteins, are supposed to be induced by microorganisms and mammalian tissues under

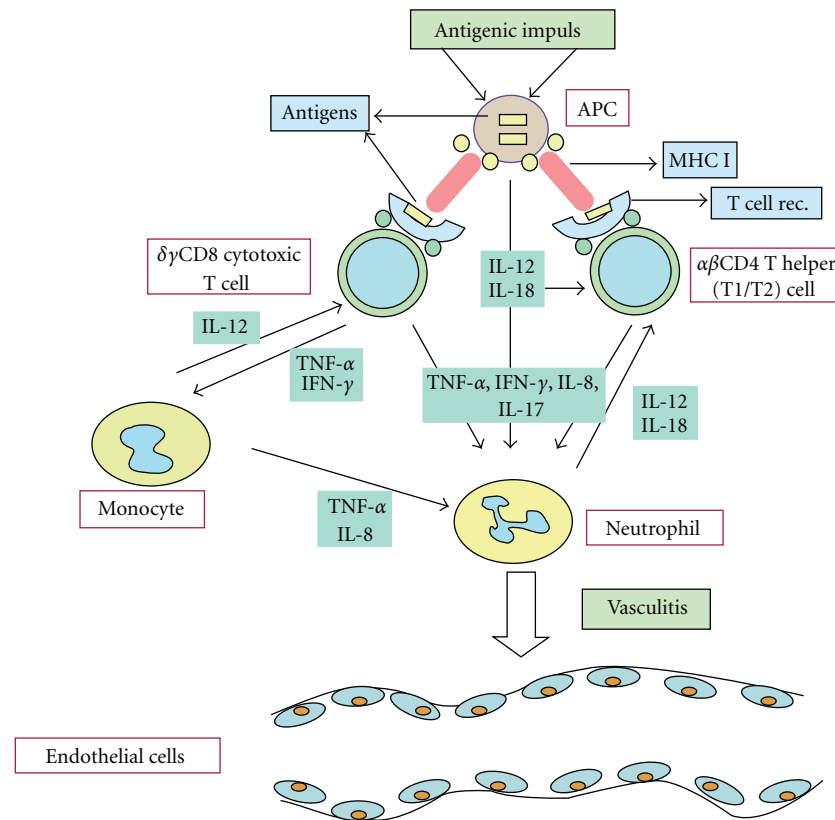


FIGURE 1: The immunopathogenesis of Behçet's diseases.

a variety of stressful conditions, and they may be involved in the pathogenesis of some autoimmune diseases [5]. The serum levels of IgA antibodies to mycobacterial Hsp-65, which cross reacts with selected strains of *S. Sanguinis*, are increased significantly. These HSP presented by APCs can directly stimulate α , beta T cells, and $\gamma\delta$ +T cells which play important roles in the oral mucosal immunity as the first defense against microorganisms. Altered expression of Hsp-60 was found in ulcerative lesions of BD and RAS suggesting that HSP-60 has an association with the etiology or chronicity of these inflammatory lesions [7].

2.2. APCs (Antigen Presenting Cells). APC is specialized cell that helps fight off foreign substances that enter the body. Different types of antigens include viruses, bacteria, heat shock protein, and endothelial antigens that stimulate the APC. These cells send out signals to T cells (other immune system cells) when an antigen enters the body [6]. Antigen presentation stimulates T cells to become either "cytotoxic" CD8+ cells or "helper" CD4+ cells. Cytotoxic cells directly attack other cells carrying certain foreign or abnormal molecules on their surfaces. Helper T cells, or Th cells, coordinate immune responses by communicating with other cells. Dysfunction of the APC is responsible for T-cell hypersensitivity. And also this reaction expresses delayed type hypersensitivity mediated by interleukins such as IL-12 and IL-18 in the cutaneous lesions [4].

2.3. Neutrophils. These cells are the main elements of the innate immunity. Meanwhile, cytokines and chemokines secreted from APCs and T cells induce the neutrophil hyperactivation. Hyperactivity of the neutrophils is a major part of the immunological abnormalities observed in BD [5, 6, 8]. Activated neutrophils secrete some cytokines which prime themselves and also stimulate Th1 cells. Th1 lymphocytes have a major role in immunopathogenesis of BD [6, 8].

2.4. $\gamma\delta$ +T Cells. $\gamma\delta$ +T cells, which are important of mucosal immunity have an crucial role. Activity of the BD increases with high level of $\gamma\delta$ +T cells in circulation and mucosal lesions. CD+8 $\gamma\delta$ +T cells rather than CD4+ T cells were activated in vivo in Behçet's patients [3, 6, 8]. In our study, expression of the $\gamma\delta$ +T cells in oral ulcers from BD patients were studied. It was found heterogeneous expression of the $\gamma\delta$ +T cells throughout the epithelium and in connective tissue around the ulcer base [9].

2.5. Proinflammatory Cytokines. It was claimed that tumor necrosis factor (TNF) α gene is closely linked to the HLA-B 51 gene, in view of the major role played by this proinflammatory cytokine in BD [3, 6, 8]. An overproduction of proinflammatory cytokines from cellular resources appears to be responsible for the inflammatory reaction in BD, with interferon- γ , TNF- α , IL-6, IL-8, and IL-12 being higher in patients with BD. T-cell-produced cytokines, including

interleukin (IL)-2, tumor necrosis factor (TNF)- α , interferon (IFN)- γ , IL-12 and IL-18, are elevated and probably contribute to neutrophil and endothelial cell activation. And also IL-12, and IL-18, which are mainly produced by APCs, regulate the neutrophil function and may play important role in the skewing of immune response [4, 8].

2.6. Th17 Cells. It was reported a marked increase in Th17 cell numbers and a decreased frequency of CD4 (+) forkhead box protein 3 positive Treg cells in the peripheral blood of patients with active BD [8–12]. Th17/Th1 ratio was elevated in BD patients with uveitis or folliculitis compared to those without it [11]. Th17 cells regulate inflammation via production of distinct cytokines such as IL-17. There is growing evidence that Th17 cells are pathological in many human autoimmune and inflammatory diseases [8–12]. Th17 cells represent a new subset of Th cells, which mainly produce IL-17A-F, IL-22, and TNF- α . IL-6 and TGF- β induce the differentiation of Th17 cells from naive T cells. Hamzoui et al. found high level of TBX 21 (Th1), RORC (Th17) and Foxp3 (Treg) in neuro-BD. They postulated Th1 and Th17 mRNA expressions involving a possible impairment of Treg cells [13].

2.7. IL-21. Geri et al. demonstrated the presence of the IL-21 and IL 17-A producing T cells within the cerebrospinal fluid, brain parenchyma inflammatory infiltrates, and intracerebral blood vessels from patients with active BD and central nervous system involvement. The stimulation of CD(+) T cells with IL-21 increased Th17 and Th1 differentiation and decreased the frequency of Treg cells. IL-21 represents a promising target for novel therapy in BD [14]. Jiang et al. found strong association of a single-nucleotide polymorphism of IL-23R with BD. The results suggested that IL-23R is predisposing genotypes for BD [15].

2.8. VEGF. In other study, VEGF (vascular endothelial growth factor) was measured in the cerebrospinal fluid in neuro-BD and was found significantly increased. They speculated that VEGF may be associated with the increased percentages of CD4 cell subpopulation [16].

2.9. Vitamin D. Serum vitamin D concentrations and BD activity were investigated. Active BD was associated with lower serum vitamin D levels. These results showed that low levels of vitamin D were associated with a decrease in Treg cells and a skewing of the Th1/Th2 balance towards Th1 [17].

2.10. Histopathology. Histopathogenesis of this disease, characterized by systemic perivascularitis, with presence of early neutrophil infiltration, endothelial cell swelling, and fibrinoid necrosis [1–3]. Prominent neutrophil infiltration is seen in all early mucocutaneous lesions. Recurrent aphthous ulceration, skin pathergy reaction, nodular cutaneous lesion, and also ocular lesion show this type of histopathologic pattern [3, 4].

3. Novel Treatment of Behçet's Diseases Based on Immunopathogenesis

In general, BD patients have been treated for suppressing the symptoms. Conventional therapeutic approaches suppress the activity of the leucocytes (antiinflammatory) and lymphocytes (immunosuppressive) in T-cell-mediated diseases, for the suppression of the immune system. Generally, BD patients have been treated with the antisymptomatic drugs as follows; immunosuppressants such as nonsteroid anti-inflammatory agents, steroids, colchicine, cyclosporine-A. [1, 3, 4]. Meanwhile, the treatment of BD therapy remains still empirical, but nowadays new insights into BD immunopathogenesis have led to novel therapeutic approaches [18–20]. On the other hand, HSP seems to play an important role in the pathogenesis of BD. The probability of a new therapy for BD should be as the immune tolerance utilizing the peptides of HSP.

3.1. Biologic Agents. Clinical and laboratory observations suggested an important role of TNF-mediated process in the pathogenesis of BD [21–25]. During the last ten-year period, 3 licenced TNF antagonists drugs such as infliximab (chimeric anti-TNF- α monoclonal antibody), adalimumab (humanized anti-TNF- α monoclonal antibody) and etanercept (fusion protein human p75 TNF- α receptor IgG1) are increasingly used off-label for patients with BD.

Off-label use of antitumor necrosis factor (TNF) agents for BD is increasing. It was found 88, 12 and 13 primary articles on infliximab, etanercept, and adalimumab, reporting on 325, 37, and 28 patients, respectively [21]. Increased levels of TNF, soluble TNF receptors, and TNF-producing cells were found in the peripheral blood of patients with active disease. Among inflammatory cytokine-related genes, TNF blockade reduced expression of IL-1 receptor type 2, interferon γ receptors, IL-6, IL-6 receptors, and IL-17 receptors [22]. It was found that infliximab is capable of interfering with $\gamma\delta$ +T cell function in BD characterized by dysregulated cell-mediated immunity [23]. Overall, the majority of patients treated with either infliximab, etanercept, or adalimumab showed improvement of their mucocutaneous manifestations [21].

3.2. Anti-TNF Agents

3.2.1. Infliximab. Infliximab most frequently has been used in BD [24–31]. The dosing regimen for Infliximab was 5 mg/kg IV at weeks 0, 2, 6, and every 8 weeks thereafter [24] and most of these patients were treated with infliximab; remission of oral ulcers, genital ulcers, erythema nodosum, and other skin lesions were noticed in 91%, 96%, 81%, and 77% of them, respectively. A rapid and dramatic improvement of visual acuity and decrease of ocular inflammation starting 24 hours after infliximab was reported [24, 25]. And also long-term effects of repetitive infliximab infusions had positive results regarding the prevention of ocular relapses and tapering of immunosuppressive therapy [25]. Infliximab was used extensively in entero-Behçet, neuro Behçet, and mucocutaneous BD resistant to conventional therapy [26,

27]. Infliximab showed satisfactory results in patients with progressive neuro-BD in different clinical study [25–27]. Experience with infliximab for vascular involvement is limited to case reports. But response to this drug was impressive, with resolution of symptoms within days and improvement of laboratory and imaging findings [29]. But in some cases of BD, TNF blockers are not enough for suppressing the symptoms of the BD. In one series, the combination of infliximab and methotrexate brings about long-term alleviation of entero-BD and excellent tolerability. [31]

3.2.2. Etanercept. Etanercept was administered subcutaneously (SC) in a dose of 25 mg twice a week or 50 mg once a week. Etanercept was found successful in sustaining remission for mucocutaneous findings in significantly more patients than placebo [32–34]. Using the etanercept for ocular involvement was found in small case series. Etanercept was found effective in more than half of patients treated with etanercept [32, 33]. Isolated patients with central nervous system involvement were treated with etanercept with favorable results [32, 34].

3.2.3. Adalimumab. Adalimumab was administered SC as 40 mg every 15 days [21]. Using the etanercept and adalimumab for ocular involvement was found in small case series. Complete remission was achieved in all patients treated with adalimumab. 3 patients with gastrointestinal involvement have been treated successfully with adalimumab [34, 35]. On the other hand, few patients with central nervous system involvement were treated with adalimumab with good results [36]. In large clinical study, a total of 69 patients with BD have been treated with infliximab. But seventeen of these (25%) have been switched to adalimumab for lack or loss of efficacy or infusion reactions. It can be postulated that patients with BD showing a scarce response or adverse events to infliximab may successfully be treated with adalimumab [37].

There is enough published experience to suggest that TNF blockade represents an important therapeutic advancement for patients with severe and resistant, or intolerant, to standard immunosuppressive regimens BD.

3.2.4. Rituximab. Rituximab is a chimeric monoclonal antibody that acts against the specific B cell antigen, CD 20. Rituximab was found effective in retinal vasculitis and ocular manifestations in BD [38, 39]. Twenty patients of with intractable ocular lesions of BD were randomized to a rituximab or cytotoxic drugs such as methotrexate, prednisone, and cyclophosphamide [38]. Rituximab was found effective in ocular lesions of the diseases [38, 39].

3.2.5. Campath 1-H. Campath 1-h is a humanized anti-CD52 antibody. The CD52 antigen is present on lymphocytes and macrophages, but the predominant effect of anti-CD52 antibody therapy (CAMPATH 1-H) is T-cell depletion. Lockwood et al. explored the therapeutic response to lymphocyte depletion with a humanized anti-CD 52 antibody in active

BD. This drug will be a potential alternative treatment for refractory BD [40].

3.2.6. Tocilizumab. Tocilizumab is a humanized anti-interleukin 6 receptor antibody. Tocilizumab binds both to soluble and to membrane-bound IL-6 receptor [41, 42]. Evidences showed that IL-6 has a crucial role in the neuroimmunology of neuro-Behçet diseases. Therefore inhibition of IL-6 signaling could be a new therapeutic regimen for Neuro-Behçet diseases [41]. Tocilizumab was used in 47 year old female with refractory BD. Excellent results were obtained for 1 year. This experience indicates that tocilizumab may constitute a therapeutic option for refractory BD [42].

3.2.7. Gevokizumab. Gevokizumab (XOMA-052) is an Ig G2 humanized monoclonal antibody against human IL-1 β , for the potential treatment of BD. In future, this drug will be candidate for the treatment of uveitis in patients with the vasculitic diseases such as BD [43].

3.2.8. Rilonacept and Canakinumab. Two new orphan medicines, Rilonacept (Regeneron) and Canakinumab (Ilaris), are a human anti-IL-1 β monoclonal antibody. Their mode of action are based on the neutralization of IL-1 β signaling, resulting in suppression of inflammation in patients with disorders of autoinflammation. [44, 45]. IL-1 β is one of the major cytokines implicated in the pathogenesis of many inflammatory-associated diseases. IL-1 β is, therefore, becoming a focus for the development of new anti-inflammatory drug products [44]. Reports from clinical trials suggest that two drugs were well tolerated in most patients and no serious adverse effects were observed [45].

3.3. Tolerization Therapy. Heat shock proteins (HSPs) are synthesized when cells are exposed to nonspecific stimuli such as trauma, heat, and infection HSP has played major role in pathogenesis of BD. Tolerance induction has been used for the treatment of autoimmune uveitis [18, 20]. Within HSP-60, the 336–351 sequence has been shown to induce uveitis when administered subcutaneously. Oral administration of the 336–351 peptide linked to recombinant cholera B-toxin B subunit (CTB) was found effective in inhibiting the development of uveitis. There were not observed adverse effects during the therapy. Tolerization could become an appealing therapeutic option because of its lack of side effects and the possibility of the use of other treatment modalities [19, 20].

3.4. Immunoablation. Immunoablation with autologous hematopoietic cell transplantation has shown some effectiveness in the treatment of autoimmune diseases. Myeloablative chemotherapy with immunosuppressive drugs followed by autologous transplantation of T-cell-depleted hematopoietic stem cells was found to be safe and effective in BD [18]. Especially in some cases resistant to immunosuppressive drugs, immunoablations could be alternative treatment modalities to control BD [20].

3.5. Other Drugs

3.5.1. Rebamipide. Rebamipide can be used for oral aphthous ulcers in BD. This drug inhibits free radicals derived from activated neutrophils and decreases the inhibiting inflammatory cytokine [45, 46]. Matsuda et al. used the rebamipide in a multicenter, double-blind, placebo-controlled study 35 patients with BD were randomized 300 mg/day or placebo for 12–24 weeks. In this study, rebamipide was well tolerated and significantly improved the recurrent aphthous stomatitis [46]. In a recent study, Bang et al. used rebamipide plus colchicine versus colchicine in the treatment to BD-like mice. They found that rebamipide helped the function of colchicine to improve the Herpes simplex virus-induced BD symptoms by inhibiting the expression of NADPH oxidase in a vivo mouse model [47].

3.5.2. Immunomodulators. Tacrolimus and pimecrolimus are macrolide antiinflammatory drugs with potent immunosuppressive activity [48–51]. Tacrolimus is used for its capacity to inhibit T-cell cytokines, such as IL-2, IL-4, and TNF- α . Oral and topical tacrolimus were used to treat the intestinal and ocular BD [47, 48]. On the other hand, in a clinical trial, topical pimecrolimus cream plus colchicine tablets versus colchicine tablets were used in the treatment of genital ulcers in BD. Pimecrolimus cream shortens the pain duration in genital ulcers [50]. In another clinical study, pimecrolimus versus placebo was used in genital ulcer of BD and also pimecrolimus was found safe and efficient in the treatment of genital ulcers, by accelerating the healing [51].

3.5.3. Mycophenolate Sodium. Mycophenolic acid (MPA) is a potent, selective, and reversible inhibitor of inosine monophosphate dehydrogenase and adenosine deaminase. Enteric-coated mycophenolate sodium (EC-MPS), monosodium salt of MPA, allows delayed release of MPA into the small intestine, and it is associated with less adverse effects [52]. Ten patients received enteric-coated formulation of mycophenolate sodium in a standard dose of 720 mg twice daily for six months. Treatment with EC-MPS leads to significant decrease in BD activity. Side effects were mild and did not lead to discontinuation of therapy [53].

3.5.4. Mycophenolate Mofetil. It was presented that 4 cases with parenchymal neuro-BD, where used immunosuppressive drugs could not be continued to intolerance or inefficacy. These patients benefited well from mycophenolate mofetil. The benefit was sustained during 3–7 years of follow-up [54].

References

- [1] S. Hirohata and H. Kikuchi, "Behçet's disease," *Arthritis Research and Therapy*, vol. 5, no. 3, pp. 139–146, 2003.
- [2] O. Köse, "Diagnosis and differential diagnosis in Behçet's disease," *Turkderm Deri Hastalıkları ve Frengi Arsivi*, vol. 43, supplement 2, pp. 87–91, 2009.
- [3] I. Krause and A. Weinberger, "Behçet's disease," *Current Opinion in Rheumatology*, vol. 20, no. 1, pp. 82–87, 2008.
- [4] F. Kaneko, A. Togashi, S. Saito et al., "Behçet's disease," *Clinical and Developmental Immunology*, vol. 2011, Article ID 681956, 2011.
- [5] C. Mendoza-Pinto, M. García-Carrasco, M. Jiménez-Hernández et al., "Etiopathogenesis of Behçet's disease," *Autoimmunity Reviews*, vol. 9, no. 4, pp. 241–245, 2010.
- [6] V. D. Kapsimali, M. A. Kanakis, G. A. Vaiopoulos, and P. G. Kaklamanis, "Etiopathogenesis of Behçet's disease with emphasis on the role of immunological aberrations," *Clinical Rheumatology*, vol. 29, no. 11, pp. 1211–1216, 2010.
- [7] E. Deniz, U. Guc, N. Buyukbabani, and A. Gul, "HSP 60 expression in recurrent oral ulcerations of Behçet's disease," *Oral Surgery, Oral Medicine, Oral Pathology, Oral Radiology and Endodontology*, vol. 110, no. 2, pp. 196–200, 2010.
- [8] S. Pay, İ. Şimşek, H. Erdem, and A. Dinç, "Immunopathogenesis of Behçet's disease with special emphasis on the possible role of antigen presenting cells," *Rheumatology International*, vol. 27, no. 5, pp. 417–424, 2007.
- [9] O. Köse, J. Stewart, A. Waseem, A. Lalli, and F. Fortune, "Expression of cytokeratins, adhesion and activation molecules in oral ulcers of Behçet's disease," *Clinical and Experimental Dermatology*, vol. 33, no. 1, pp. 62–69, 2008.
- [10] H. Direskeneli, H. Fujita, and C. A. Akdis, "Regulation of TH17 and regulatory T cells in patients with Behçet disease," *Journal of Allergy and Clinical Immunology*, vol. 128, no. 3, pp. 665–666, 2011.
- [11] J. Kim, J. A. Park, E. Y. Lee, Y. J. Lee, Y. W. Song, and E. B. Lee, "Imbalance of Th17 to Th1 cells in Behçet's disease," *Clinical and Experimental Rheumatology*, vol. 28, no. 4, supplement 60, pp. S16–S19, 2010.
- [12] K. Hamzaoui, "Th17 cells In Behçet's disease: a new immunoregulatory axis," *Clinical and Experimental Rheumatology*, vol. 29, no. 4, supplement 67, pp. S71–S76, 2011.
- [13] K. Hamzaoui, A. Borhani Haghighi, I. B. Ghorbel, and H. Houman, "RORC and Foxp3 axis in cerebrospinal fluid of patients with Neuro-Behçet's Disease," *Journal of Neuroimmunology*, vol. 233, no. 1-2, pp. 249–253, 2011.
- [14] G. Geri, B. Terrier, M. Rosenzweig et al., "Critical role of IL-21 in modulating T H17 and regulatory T cells in Behçet disease," *Journal of Allergy and Clinical Immunology*, vol. 128, no. 3, pp. 655–664, 2011.
- [15] Z. Jiang, P. Yang, S. Hou et al., "IL-23R gene confers susceptibility to Behçet's disease in a Chinese Han population," *Annals of the Rheumatic Diseases*, vol. 69, no. 7, pp. 1325–1328, 2010.
- [16] K. Hamzaoui, K. Ayed, M. Hamza, and A. Hamzaoui, "VEGF and mRNA VEGF expression in CSF from Behçet's disease with neurological involvement," *Journal of Neuroimmunology*, vol. 213, no. 1-2, pp. 148–153, 2009.
- [17] K. Hamzaoui, I. B. Dhifallah, E. Karray, F. H. Sassi, and A. Hamzaoui, "Vitamin D modulates peripheral immunity in patients with Behçet's disease," *Clinical and Experimental Rheumatology*, vol. 28, no. 4, supplement 60, pp. S50–S57, 2010.
- [18] I. Alexoudi, V. Kapsimali, A. Vaiopoulos, M. Kanakis, and G. Vaiopoulos, "Evaluation of current therapeutic strategies in Behçet's disease," *Clinical Rheumatology*, vol. 30, no. 2, pp. 157–163, 2011.
- [19] N. Pipitone, I. Olivieri, F. Cantini, G. Triolo, and C. Salvarani, "New approaches in the treatment of Adamantiades-Behçet's disease," *Current Opinion in Rheumatology*, vol. 18, no. 1, pp. 3–9, 2006.
- [20] M. H. Houman and K. Hamzaoui, "Promising new therapies for Behçet's disease," *European Journal of Internal Medicine*, vol. 17, no. 3, pp. 163–169, 2006.

- [21] A. Arida, K. Fragiadaki, E. Giavri, and P. Sfikakis, "Anti-TNF agents for Behçet's disease: analysis of published data on 369 patients," *Seminars in Arthritis and Rheumatism*, vol. 41, no. 1, pp. 61–70, 2011.
- [22] H. Keino, T. Watanabe, W. Taki, and A. A. Okada, "Effect of infliximab on gene expression profiling in Behçet's disease," *Investigative Ophthalmology & Visual Science*, vol. 52, no. 10, pp. 7681–7686, 2011.
- [23] A. Accardo-Palumbo, A. R. Giardina, F. Ciccica et al., "Phenotype and functional changes of V γ 9/V δ 2 T lymphocytes in Behçet's disease and the effect of infliximab on V γ 9/V δ 2 T cell expansion, activation and cytotoxicity," *Arthritis Research and Therapy*, vol. 12, no. 3, article R109, 2010.
- [24] N. R. Benitah, L. Sobrin, and G. N. Papaliodis, "The use of biologic agents in the treatment of ocular manifestations of Behçet's disease," *Seminars in Ophthalmology*, vol. 26, no. 4-5, pp. 295–303, 2011.
- [25] M. Accorinti, M. P. Pirraglia, M. P. Paroli, R. Priori, F. Conti, and P. Pivetti-Pezzi, "Infliximab treatment for ocular and extraocular manifestations of Behçet's disease," *Japanese Journal of Ophthalmology*, vol. 51, no. 3, pp. 191–196, 2007.
- [26] N. E. Aikawa, C. Gonçalves, C. A.A. Silva, C. Gonçalves, E. Bonfá, and J. F. De Carvalho, "Late response to anti-TNF- α therapy in refractory mucocutaneous lesions of Behçet's disease," *Rheumatology International*, vol. 31, no. 8, pp. 1097–1099, 2011.
- [27] N. Markomichelakis, E. Delicha, S. Masselos, K. Fragiadaki, P. Kaklamanis, and P. P. Sfikakis, "A single infliximab infusion vs corticosteroids for acute panuveitis attacks in Behçet's disease: a comparative 4-week study," *Rheumatology*, vol. 50, no. 3, Article ID keq366, pp. 593–597, 2011.
- [28] A. Borhani Haghighi, A. Safari, M. A. Nazarinia, Z. Habibagahi, and S. Shenavandeh, "Infliximab for patients with neuro-Behçet's disease: case series and literature review," *Clinical Rheumatology*, vol. 30, no. 7, pp. 1007–1012, 2011.
- [29] S. Iwata, K. Saito, K. Yamaoka et al., "Effects of anti-TNF- α antibody infliximab in refractory entero-Behçet's disease," *Rheumatology*, vol. 48, no. 8, pp. 1012–1013, 2009.
- [30] G. Almozni and E. Ben-Chetrit, "Infliximab for the treatment of resistant oral ulcers in Behçet's disease: a case report and review of the literature," *Clinical and Experimental Rheumatology*, vol. 25, no. 4, supplement 45, pp. S–99, 2007.
- [31] S. Iwata, K. Saito, K. Yamaoka et al., "Efficacy of combination therapy of anti-TNF- α antibody infliximab and methotrexate in refractory entero-Behçet's disease," *Modern Rheumatology*, vol. 21, no. 2, pp. 184–191, 2011.
- [32] L. Cantarini, I. Tinazzi, P. Caramaschi, F. Bellisai, A. Brogna, and M. Galeazzi, "Safety and efficacy of etanercept in children with juvenile-onset Behçet's disease," *International Journal of Immunopathology and Pharmacology*, vol. 22, no. 2, pp. 551–555, 2009.
- [33] V. Curigliano, M. Gioviale, C. Fonnesu et al., "Efficacy of etanercept in the treatment of a patient with Behçet's disease," *Clinical Rheumatology*, vol. 27, no. 7, pp. 933–936, 2008.
- [34] M. F. Zhang, C. Zhao, X. Wen, H. Du, and Y. Zhao, "The short-term efficacy and safety treatment study of recurrent uveitis in Behçet disease with etanercept," *Chinese Journal of Ophthalmology*, vol. 46, no. 2, pp. 145–150, 2010.
- [35] A. Bawazeer, L. H. Raffa, and Nizamuddin, "Clinical experience with adalimumab in the treatment of ocular Behçet disease," *Ocular Immunology and Inflammation*, vol. 18, no. 3, pp. 226–232, 2010.
- [36] C. De Cassan, B. De Vroey, C. Dussault, E. Hachulla, S. Buche, and J. F. Colombel, "Successful treatment with adalimumab in a familial case of gastrointestinal Behçet's disease," *Journal of Crohn's and Colitis*, vol. 5, no. 4, pp. 364–368, 2011.
- [37] I. Olivieri, P. Leccese, S. D'Angelo et al., "Efficacy of adalimumab in patients with Behçet's disease unsuccessfully treated with infliximab," *Clinical and Experimental Rheumatology*, vol. 29, no. 4, supplement 67, pp. S54–S57, 2011.
- [38] F. Davatchi, H. Shams, M. Rezaipoor et al., "Rituximab in intractable ocular lesions of Behçet's disease; randomized single-blind control study (pilot study)," *International Journal of Rheumatic Diseases*, vol. 13, no. 3, pp. 246–252, 2010.
- [39] S. Sadreddini, H. Noshad, M. Molaeeafard, and R. Noshad, "Treatment of retinal vasculitis in Behçet's disease with rituximab," *Modern Rheumatology*, vol. 18, no. 3, pp. 306–308, 2008.
- [40] C. M. Lockwood, G. Hale, H. Waldman, and D. R. W. Jayne, "Remission induction in Behçet's disease following lymphocyte depletion by the anti-CD52 antibody CAMPATH 1-H," *Rheumatology*, vol. 42, no. 12, pp. 1539–1544, 2003.
- [41] A. Borhani Haghighi and A. Safari, "Tocilizumab may be a potential addition to our weapons against neuro-Behçet's disease," *Medical Hypotheses*, vol. 71, no. 1, pp. 156–157, 2008.
- [42] T. Hirano, N. Ohguro, S. Hohki et al., "A case of Behçet's disease treated with a humanized anti-interleukin-6 receptor antibody, tocilizumab," *Modern Rheumatology*. In press.
- [43] J. Geiler and M. F. McDermott, "Gevokizumab, an anti-IL-1 β mAb for the potential treatment of type 1 and 2 diabetes, rheumatoid arthritis and cardiovascular disease," *Current Opinion in Molecular Therapeutics*, vol. 12, no. 6, pp. 755–769, 2010.
- [44] E. A. Dubois, R. Rissmann, and A. F. Cohen, "Riloncept and canakinumab," *British Journal of Clinical Pharmacology*, vol. 71, no. 5, pp. 639–641, 2011.
- [45] E. Dhimolea, "Canakinumab," *MAbs*, vol. 2, no. 1, pp. 3–13, 2010.
- [46] T. Matsuda, S. Ohno, S. Hirohata et al., "Efficacy of rebamipide as adjunctive therapy in the treatment of recurrent oral aphthous ulcers in patients with Behçet's disease: a randomised, double-blind, placebo-controlled study," *Drugs in R and D*, vol. 4, no. 1, pp. 19–28, 2003.
- [47] D. Bang, B. Choi, H. J. Kwon, E. S. Lee, S. Lee, and S. Sohn, "Rebamipide affects the efficiency of colchicine for the herpes simplex virus-induced inflammation in a Behçet's disease mouse model," *European Journal of Pharmacology*, vol. 598, no. 1–3, pp. 112–117, 2008.
- [48] K. Matsumura, H. Nakase, and T. Chiba, "Efficacy of oral tacrolimus on intestinal Behçet's disease," *Inflammatory Bowel Diseases*, vol. 16, no. 2, pp. 188–189, 2010.
- [49] F. N. Yalçındağ, F. Batioğlu, and Ö. Özdemir, "Penetration of topically applied tacrolimus into the aqueous humor in Behçet's disease," *Annals of Ophthalmology*, vol. 39, no. 1, pp. 15–17, 2007.
- [50] O. Köse, A. Dinç, and I. Şimşek, "Randomized trial of pimecrolimus cream plus colchicine tablets versus colchicine tablets in the treatment of genital ulcers in Behçet's disease," *Dermatology*, vol. 218, no. 2, pp. 140–145, 2009.
- [51] C. Chams-Davatchi, B. Barikbin, F. Shahram et al., "Pimecrolimus versus placebo in genital aphthous ulcers of Behçet's disease: a randomized double-blind controlled trial," *International Journal of Rheumatic Diseases*, vol. 13, no. 3, pp. 253–258, 2010.
- [52] J. H. Kappen, P. B. F. Mensink, W. Lesterhuis et al., "Mycophenolate sodium: effective treatment for therapy-refractory intestinal Behçet's disease, evaluated with enteroscopy," *American Journal of Gastroenterology*, vol. 103, no. 12, pp. 3213–3214, 2008.

- [53] O. Köse, I. Şimşek, and S. Pay, "Mycophenolate sodium in the treatment of mucocutaneous Behçet's diseases," *International Journal of Dermatology*, vol. 50, no. 7, pp. 895–896, 2011.
- [54] E. Shugaiv, E. Tüzün, M. Mutlu, A. Kiyat-Atamer, M. Kurtuncu, and G. Akman-Demir, "Mycophenolate mofetil as a novel immunosuppressant in the treatment of neuro-Behçet's disease with parenchymal involvement: presentation of four cases," *Clinical and Experimental Rheumatology*, vol. 29, no. 4, supplement 67, pp. S64–S67, 2011.

Review Article

Animal Models in Behçet's Disease

Ozlem Yildirim

Department of Ophthalmology, Faculty of Medicine, Mersin University, 33070 Mersin, Turkey

Correspondence should be addressed to Ozlem Yildirim, dryildirimoz@hotmail.com

Received 26 August 2011; Revised 3 November 2011; Accepted 4 November 2011

Academic Editor: Ümit Tursen

Copyright © 2012 Ozlem Yildirim. This is an open access article distributed under the Creative Commons Attribution License, which permits unrestricted use, distribution, and reproduction in any medium, provided the original work is properly cited.

Behçet's disease is a chronic, recurrent, multisystemic, inflammatory disorder affecting mainly the oral and urogenital mucosa and the uveal tract. Although the etiology and pathogenesis of Behçet's disease are unknown, numerous etiologies have been proposed, including environmental, infectious, and immunological factors; an autoimmune basis, characterized by circulating immune complexes and complement activation, has gained increasing acceptance. To test and understand immunopathogenesis of Behçet's disease, animal models were developed based on environmental pollutants, bacterial and human heat shock protein derived peptides, and virus injections. Using these animal models separately and/or concurrently allows for a more effective investigation into Behçet's disease. Animal models developed in the last 10 years aim at the development of efficient and safe treatment options.

1. Introduction

Behçet's disease (BD) is a chronic, multisystemic, inflammatory disorder and is characterized by mucocutaneous, ocular, arthritic, vascular, gastrointestinal, and central nervous system involvement. The disease has a chronic course with periodic exacerbations and progressive deterioration [1].

Since the dermatologist Dr. Hulusi Behçet [2] comprehensively described this disease involving multisystemic organs in 1937, the etiology of BD has still remained unclear. Various hypotheses have been proposed centering on viral infection, autoimmune disease, streptococcal-related antigens, specific alleles of the human major histocompatibility complex, genetic factors, and hazardous chemicals [3–7]. The history and recent developments in the immunopathogenesis of BD are reviewed and discussed in this paper.

2. Short History

Viral infection has long been postulated as one of the etiologic and triggering factors. Hulusi Behçet proposed that the disease was caused by a special virus. Although he was unable to demonstrate one, he had observed intracellular inclusion-like forms in smears from the hypopyon of the anterior chamber and aphthae [2]. In 1953, Sezer [8] was the first to isolate the virus from ocular fluid and serially cultivate it in

chorioallantoic membrane of fertile eggs. He inoculated the material from the ocular fluid of patients into brains of mice. Inoculated mice showed manifestation such as roughening of the coat, inactivity or hyperactivity, tremor, circling, paralysis, encephalitis, thrombophlebitis, and swelling. Evans et al. [9] isolated the virus from the eye and brain of a patient who died of the disease. Mortada and Imam [10] found inclusion bodies from scrapings of the scrotal and buccal ulcers, as well as from the hypopyon fluid. When the fluid from the scrapings of scrotal and buccal ulcers and hypopyon was inoculated into the chorioallantoic membrane of 10-day-old chick embryos and incubated for 2 days, whitish plaques were seen. These plaques showed inclusion bodies exactly like those seen in scrapings. The filtrates from plaques were inoculated intracerebrally into 3-week-old white Swiss mice. Seventeen out of 21 mice died while 5 control mice inoculated with saline remaining alive.

Eglin et al. [11] using method of in situ hybridization, detected RNA complementary to herpes simplex virus (HSV) type 1 in the mononuclear cells of patients with BD. HSV type 1 DNA was detected in the whole blood by Bonass et al. [12] with dot blotting technique. Denman and colleagues [13] detected HSV DNA with southern hybridization using Eco R1 digested DNA from the peripheral blood mononuclear cells of patients with BD. In 1991, Studd et al. [14] detected HSV-1 DNA by polymerase chain reaction (PCR) in

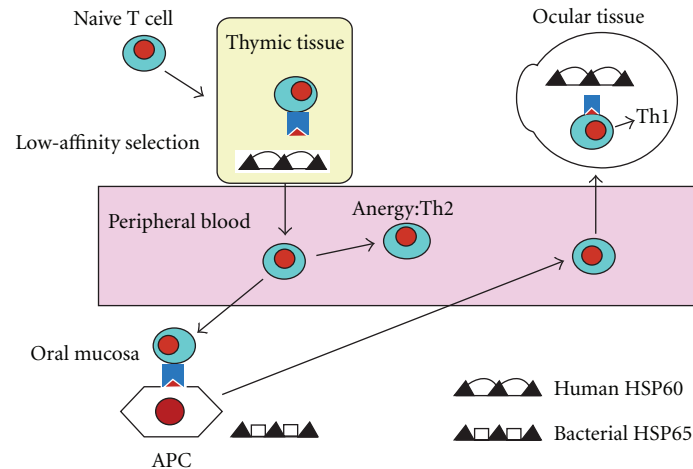


FIGURE 1: Role of bacterial and human heat shock protein (HSP) 60/65 as T cell antigens in Behçet's disease. APC: antigen presenting cells.

peripheral blood leukocytes of BD patients with recurrent oral ulcers.

Lee et al. [15] tried to detect HSV DNA in saliva of patients with BD, and to evaluate whether the presence of HSV in saliva is associated with the presence of an intraoral ulcer, and to investigate any possible relationships between HSV and BD using PCR. The results from saliva showed that almost 40% patients were positive for HSV DNA, compared to 14% of healthy controls.

Lee and colleagues [16] investigated the relationship of intestinal ulceration of BD and HSV. PCR results were all positive in specimens of patients with BD. Bang et al. [17] experimented to detect HSV DNA from ulcerative genital tissue of patients with BD. They applied 8 cases and all showed HSV bands. From these reports, we can conclude that there is a relationship between HSV DNA and ulceration of various epithelial tissue of BD.

3. Animal Models Aiming to Elucidate the Immunopathogenesis of Behçet's Disease

Animal models are very important and necessary in most fields of research. Many investigators have tried to develop an animal model for use in BD. In 1979, Hori and colleagues [4] created typical BD-like lesions in Pitman-Moor's strain, miniature swine treated with agricultural chemicals such as organophosphate, organochloride, and inorganic copper. The total number of animals used for the development of an animal model by Hori and colleagues was 8. Though all of the experimental animals showed BD-like symptoms after a 1-year administration of the chemicals, it is not feasible to breed such a large group for use in other experimental design.

Heat shock protein (hsp) has also been implicated in the pathogenesis of several human and experimentally induced autoimmune diseases such as BD, both as target antigens and as intracellular chaperones involved in peptide binding to HLA antigens [18] (Figure 1). Lehner et al. [19] reported that uveitis could be induced in Lewis rats by 4 peptides derived

from the sequence of the mycobacterial 65 kD hsp, which stimulate specifically TCR $\gamma\delta$ lymphocyte from patients with BD and human 65 kD hsp derived peptides. Lehner groups' Lewis rats showed only single eye symptom. Patients' symptoms of BD are multiple, chronic, or recurrent. If additional symptoms were to appear in hsp derived peptide stimulated Lewis rats, this animal model would be more useful.

Before using the ICR mouse strain, Sohn et al. tried guinea pig and Sprague-Dawley rat models. They used subcutaneous injections in back skin and the scrotum, intramuscular injections in the tongue, and a direct swab on the eyeball. Using these methods, no symptoms similar to BD appeared. They thought that the key point for success was the correct identification of the route of infection of HSV. The route of HSV infection is an important factor affecting multi-systemic expressions of the symptoms.

In 1998, Sohn et al. [20] experimented to develop an animal model for use in BD using HSV infection which was hypothesized to be one of the etiologic or triggering factors in BD by Lee et al. [15, 16]. To test the HSV infection hypothesis and to develop an animal model, ICR mice were inoculated with HSV. Using method of Hirata and colleagues [21], the earlobes of 258 mice of ICR strain, aged 5 to 6 weeks, were scratched with a needle, then inoculated with 1.0×10^6 plaque forming units (pfu)/mL of HSV type 1 (KOS strain) solution. As a control, 30 mice were inoculated in the same site with a culture medium. Four weeks later, a second inoculation was performed using the same methods, followed by 16 weeks of observation. The mice inoculated with HSV manifested changes 3 to 4 days after the first inoculation. The signs that appeared most rapidly and commonly were partial hair loss in the face region and erythema on the scratched earlobe. Other common symptoms were skin ulceration of the earlobes, scruff, and genitalia and eye symptoms including keratitis, conjunctivitis, and uveitis. Mice with relatively severe symptoms showed poor general condition and soon died. Some mice did not show any visible symptoms, but appeared to be in poor general condition, they also died. After the second inoculation, arthritis, oral and genital ulcers, and

keratitis were the main symptoms. These symptoms were generally more severe than those appearing after the initial inoculation. Two or more symptoms in one mouse were considered an indication of a BD-like syndrome. After the induced infection, 86 mice (33.3%) died, 77 (29.8%) showed BD-like symptoms, and 95 (36.8%) had a healthy normal appearance or a single symptom. The symptoms included skin ulcers on the earlobe, scruff, abdomen, back, or face (57.1%); eye symptoms (39.0%); partial hair loss (33.8%); genital ulcer (19.5%); bullae (11.7%); arthritis (5.2%); gastrointestinal ulcer (5.2%); tongue ulcer (3.9%). The induced BD-like symptoms were similar to the clinical manifestations of ulcers, uveitis, and arthritis which have been significant in diagnosing BD in patients. Aside from hair loss, the most frequent symptoms affecting mice were skin ulcers, eye symptoms, and genital ulcers. The frequency of these symptoms were similar to that of patients with BD.

The PCR was used to detect HSV DNA sequences in DNA extracted from the lesions of mice with BD-like symptoms. The methods were almost the same as those used in the patient experiment. HSV DNA sequences were detected in the lesional skin and gastrointestinal track, but not in normal healthy skin area. Abdominal skin lesions stained with hematoxylin and eosin showed that many inflammatory cells had accumulated around the blood vessel. Vasculitis was also common in intestinal, oral, earlobular, and genital epithelial lesions. These findings were very similar to typical morphological changes in human BD [22]. These experiments proved that it was possible to induce BD-like symptoms such as ulceration and vascular inflammation in ICR mice by inoculating them with HSV. For this reason, many researchers have used this animal model to understand the etiopathogenesis of BD and efficiency and safety of newly developed drugs in BD.

In 1978, Ohno and Sugiura [23] reported an association between human leukocyte antigen (HLA) and BD in Japan. Then, several authors have presented evidence of an HLA association with, and HLA B51, one of the split antigens of HLA B5, was found to be the most strongly associated genetic marker [24–26]. To pursue the correlation between viral infection and genetic factors in the development of the disease, several inbred mouse strains—B10.BR, B10.RIII, C57BL/6, C3H/He, and Balb/c—which had different haplotypes of major histocompatibility complex (MHC), were inoculated with HSV type 1 (KOS strain) using the method of Sohn and coworkers [27]. BD-like symptoms appeared in B10.BR, B10.RIII, and C57BL/6 as in the case of ICR mouse strain previously reported by authors as a BD mouse model [20]. These mouse strains manifested single or multiple symptoms. Manifestations of oral, genital, skin ulcers, uveitis, and arthritis, that are clinically significant for the diagnosis of BD in patients appeared. The lesions spontaneously healed and recurred repeatedly. According to the revised Japanese criteria [28], the manifestations in mice were classified into major and minor symptoms. Among these symptoms, having more than two symptoms (including and above one major and one minor symptom) were diagnosed as BD-like symptoms. The mice with a single symptom were classified as the normal group. More than 40% of B10.BR,

B10.RIII, and C57BL/6 showed BD-like symptoms, compared to 2% of C3H/He and Balb/c. Inbred mice with different haplotype of the H-2 region showed similar incidence rates of BD-like symptoms except C3H/He and Balb/c strains. The results from these inbred mouse strains in induction of BD-like symptoms are more important than MHC association.

Although viral infection has long been postulated as a contributing factor in the etiology of BD, and viral involvement has been demonstrated, viral infection alone is not sufficient to explain the pathogenesis of BD. Some evidence suggests that immunologic abnormalities are also important. Sohn and coworkers [29] attempted to determine whether inactivation of macrophages influences the development of BD and whether related cytokines play a role in the modulation of BD symptoms. As previously described, an animal model was developed by using ICR mice [20]. HSV-1 inoculation was done twice 10 days apart, which was followed by 16 weeks of observation. Mice with ≥ 1 major and 1 minor symptom were classified as having BD. Liposome-encapsulated clodronate (lip-Cl₂MDP) was injected intravenously in mice to inactivate their macrophages. Animals treated with HSV combined with lip-Cl₂-MDP had a lower incidence of BD-like symptoms than did those treated with HSV alone. These results suggest that macrophages may play an important role in the development of this disease. Macrophage deletion did not seem to affect mortality in 2 groups. The suppression of the development of BD-like symptoms was correlated with the induction of interleukin (IL-) 4 expression in mouse. When the Th2 adjuvant ovalbumin-(OVA-) alum was injected into mice with BD-like symptoms, their cutaneous symptoms improved. Adoptive transfer with splenocytes from OVA-alum injected mice also resulted in improvement. These findings suggest that up-regulated Th2 cytokine expression induced by macrophage inactivation may be closely related to the development, deterioration, and improvement of BD induced by HSV.

Neutrophil activation is one of the immunopathogenesis aspects of BD. Neutrophils have a pivotal role in innate immune responses. As typical BD lesions such as pustular folliculitis, pathergy reactions, and hypopyon have significant neutrophil infiltrations, neutrophil functions and activation status have been investigated [30]. There are conflicting reports of increased, normal, or decreased basal and fMLP stimulated superoxide productions, phagocytosis, chemotaxis, and neutrophil-endothelial adhesion in BD. In HLA-transgenic mic presumed model for BD, the only abnormality seen is increased superoxide release in response to fMLP. High superoxide responses were also present in HLA-B51+ patients and healthy controls in the same study.

In the etiology and pathogenesis of BD, immunological factors, an autoimmune basis, characterized by circulating immune complexes and complement activation, has gained increasing acceptance and significance. Previous work demonstrated the presence of antibodies to guinea-pig oral mucosal cells by immunofluorescence [31]. Another work has demonstrated oligoclonal T-cell expansion in patients with BD, suggesting an antigen-driven immune response

[32]. Immunisation with retinal S antigen or interphotoreceptor retinoid binding protein (IRBP) causes an experimental autoimmune uveoretinitis that resembles some human uveitic conditions [33, 34]. In vivo or in vitro sensitised, S antigen or IRBP specific T cells transferred to naive animals induce experimental autoimmune uveoretinitis [35]. On the other hand, Yamamoto and coworkers found that patients with BD with uveitis exhibited the highest and the most frequent positive responses to S antigen and IRBP, as well as to peptide M, a main uveitogenic site of S antigen [36]. Then, another study showed that patients with BD without uveitis did not differ in their responses to S antigen from the responses in the control group [37]. Yet, more responders to IRBP were observed in the patients group without uveitis (35%) than in the control group (14%), although their responses were lower than the responses observed in patients with uveitis. The presence of lymphocyte responses to retinal antigens in patients with BD without uveitis might indicate a preclinical stage of ocular involvement. Thus, these data support the idea that autoimmunity to retinal specific antigens may play a role in the ocular inflammation in BD.

Immunological responses to four T-cell and B-cell epitopes have been identified within the mycobacterial 65-kDa hsp in patients BD [38]. The four mycobacterial T-cell epitopes show significant homology with the human 60-kDa mitochondrial hsp [39]. Some groups have found T-cell proliferative responses to human hsp60 and peptides derived from it [40], others have found antibodies to *Yersinia* derived hsp60 [41]. Lehner [42] have characterized gamma-delta T-cells reactive against several peptides of human hsp60 in patients with BD. In 1994, Stanford et al. [43] investigated mycobacterial and homologous human hsp T-cell peptide epitopes specific for T lymphocytes in BD for their pathogenicity in Lewis rat. The potential pathogenicity of eight peptides and two controls was assessed by administering the peptides in enriched Freund's adjuvant into the footpads of male Lewis rats. In this study, they have shown that ocular signs may be induced in Lewis rats by injecting synthetic peptides derived from the sequences of the mycobacterium tuberculosis 65-kd hsp, and with greater frequency by using the homologous human hsp peptides. Mild or moderate clinical disease in these animals appears to be more common in the anterior segment of the eye. But, clinical involvement of the mouth, skin, external genitalia, joints, or the neurological system was not observed. The peptides that are most frequently recognized by T lymphocytes from patients with ocular type of BD (136–150 and 336–351) produced the highest incidence of disease in the experimental rats. Then, in 1998, Hu et al. [44] showed that human 60-kDa hsp-derived peptide 336–351, which is specific in stimulating T cell responses in BD, induced uveitis in Lewis rats when administered orally and nasally. The mucosal route of induction of uveitis is more likely to mimic the clinical situation, in which hsp of oral microorganisms, such as streptococci, may elicit immune responses which cross-react with mucosal hsp and initiate pathological changes [38]. Besides, the experiments to prevent the development of uveitis by oral or nasal administration of peptide have failed. In addition, administration of monoclonal antibody against CD8 or CD4 revealed that,

whereas monoclonal antibody against CD8 enhanced uveitis, against CD4 suppressed uveitis. Thus, CD4 cells mediate whereas CD8 cells suppress the development of uveitis.

Based on these studies, Mor and colleagues [45] initiated a study to seek target antigens associated with the tissues involved that might be pathogenic in laboratory animals. They tested patient sera for the presence of antibodies to antigens found in lysates various tissues. They identified a subset of patients with immune reactivity to a 37-kDa antigen present in the skin, tongue, vagina, muscle, and heart rat tissue. In-gel digestion and mass spectrometry revealed the antigen to be α -tropomyosin. To test whether induction of autoimmunity to a α -tropomyosin might be pathogenic, Lewis rats were immunized with bovine α -tropomyosin in complete Freund's adjuvant (CFA). The immunized rats developed lesions in the uveal tract and skin, with features of BD. Control rats injected with PBS/CFA emulsion did not develop uveitis or skin inflammation.

4. Animal Models Designed to Investigate the Efficiency of Newly Developed Drugs

Animal models have been used for evaluating the efficiency of newly developed drugs as well as investigating the disease's etiopathogenesis. The BD-like mouse model, developed by Sohn et al. has been found to show immunological abnormalities [27, 29], and thus is a valuable tool to study the effect of various therapeutic drugs. Treatment with the antiviral agent aciclovir has failed to alleviate the frequency and severity of orogenital ulceration and or other disease features in BD [46]. Sohn and coworkers [47] administered famciclovir, an antiviral compound that acts against HSV, varicella-zoster virus, and hepatitis B virus, in the HSV-induced BD mouse model, to demonstrate the efficiency of famciclovir. Using the HSV-induced BD mouse model [20], famciclovir was administered variously before and after inoculation of from the day of lesion occurrence, with appropriate controls. Ulceration of the mouth and genital skin and eye involvement were monitored. In addition, spleen cytokine expression was measured by PCR. Pretreatment or concurrent treatment with famciclovir did not attenuate the occurrence of BD symptoms. However, administration of famciclovir from the day of lesion occurrence was effective in about 60% of mice with single symptom and 40% of those with BD symptoms and preventing recurrence. But recurrence rate was higher in BD mice. Oral and genital ulcers did not recur, contrasting with skin ulceration and eye involvement which recurred despite administration of famciclovir. Therefore, the overall rate of improvement in BD was lower than the rate in cases showing only a single symptom. To determine whether or not the improvement of symptoms by famciclovir correlated with the expression of cytokines, RT-PCR was performed on the spleens of improved and relapsed mice after administration of famciclovir. IL-2 was expressed in relapsed mice that had areas of ulcerated skin, while it was not expressed in the improved mice. Interferon-(IFN-) γ was always expressed and was not related to the improvement of ulceration. IL-4 and IL-10 were not expressed at any

time following administration of famciclovir. These findings suggest that famciclovir might be a candidate for controlled clinical trials in the human form of BD.

In another study, thalidomide was administered in order to understand the mechanism for the improvement in symptoms in BD-like mice [48]. Despite its inherent teratogenic risk, thalidomide has proven to be of clinical use in a small number of immunological disease, including BD [49]. However, the mechanism of action of thalidomide in patients with BD remains poorly understood. In this study, a BD-like mouse produced by HSV inoculation, previously published by Sohn et al. [20] was used. ICR mice were inoculated twice with HSV over a 10-day period. Thalidomide (100 μ g) was orally administered to ten BD-like mice for five consecutive days. Placebo was administered to ten BD-like mice in an identical manner. Eight out of ten thalidomide-treated mice showed improvement in skin ulceration, bullae and crusting, and intestinal and genital symptoms. The control group, treated with PBS instead of thalidomide, did not show any change in their BD-like symptoms. The mice were sacrificed on the 6th day, and the spleens were subjected to RT-PCR, FACS, western blot, and immunohistochemical analysis. Tumor necrosis factor-(TNF-) α , macrophage inflammatory protein-(MIP-) 1 α , perforin, and Fas were influenced by thalidomide treatment. These results suggest that thalidomide can attenuate HSV-induced BD-like symptoms in mice through the downregulation of TNF- α ($P < 0.005$) and the upregulation of MIP-1 α ($P < 0.005$), perforin ($P < 0.05$), and Fas receptor ($P < 0.1$).

Beneficial therapeutic effects have been reported for colchicine, thalidomide, cyclosporin A, IFN- γ , and systemic corticosteroids in the treatment of BD. The nucleoside analog gemcitabine (2',2'-difluorodeoxycytidine, dFdC) is a new significant immunosuppressive agent that may be useful not only in graft-versus-host disease but also in autoimmune diseases. dFdC is a nucleoside analog affecting the pyrimidine pathway. Sohn et al. designed the study in order to examine the effects and side effects of gemcitabine on skin lesions of HSV-induced BD-like mouse model [50]. For the dose-escalation study, healthy ICR mice were treated intraperitoneally with dFdC over 5 consecutive days. For the efficacy study, ICR mice were inoculated with HSV as described earlier and classified as having BD according to a revised Japanese classification [20], and then 18 BD mice were randomly assigned to placebo, 0.06, or 0.12 μ g of dFdC/day over 5 days, applied intraperitoneally. Serum levels of IL-4, IL-6, IL-10, IFN- γ , and TNF- α were determined using enzyme-linked immunosorbent assay. After application of 3 μ g of dFdC over 5 days, alanine aminotransferase increased ($P = 0.032$), but all other kidney and liver parameters were unchanged. In BD-like mice, soon after 5 days of dFdC treatment, cutaneous manifestations ameliorated by more than 60% ($P = 0.017$), depending on the dFdC dose applied but not in the control mice. There was no significant change in cytokine levels after 5 days of dFdC treatment compared to pretreatment levels but only a trend toward reduced IL-10 under dFdC treatment ($P = 0.135$), and none of the cytokine levels correlated with response to treatment. Moreover, dFdC shows promising

effects to improve cutaneous lesions in the HSV-induced BD-like mouse model. In this animal model, effects of dFdC on cytokine profile remained inconclusive.

In recent years, other options of the treatment of BD are biologic agents. TNF- α is a potent paracrine and endocrine mediator of inflammatory and immune functions. TNF- α overexpression has been implicated in acute and chronic inflammatory diseases, such as septic shock, bowel disease, Crohn's disease, rheumatoid arthritis, atopic dermatitis, psoriasis, and BD [51]. TNF- α is produced primarily in T cells, polymorphonuclear cells (PMNs), dendritic cells, and macrophages [52]. In macrophages, TNF- α gene expression is induced by physical, chemical, and biologic stimuli that include ischemia, trauma, irradiation, viruses, bacteria, tumor cells, complement, and cytokines. Rapidly supplanting antisense methods [53, 54]. RNA interference (RNAi) is a recently discovered process that utilizes either endogenous or exogenous, double-stranded RNAs to inhibit expression of genes in a highly sequence specific manner. In mammals, RNAi can be invoked by introducing short (19–21 nucleotide), double-stranded RNA oligonucleotides, referred to as small interfering (siRNAs), or silencing RNA molecules, of a sequence complementary to that of the target gene. The siRNAs are bound by an RNA inducing silencing complex in the cytoplasm and silence the expression of the target mRNA. Therefore, RNAi offers promise as a novel therapeutic device and in addition may be used as a tool in functional genomics studies to elucidate genes controlling disease pathways [55]. To inhibit the expression of TNF- α , Choi et al. [56] used siRNAs to reduce over expression of TNF- α in vitro in cell cultures and in vivo BD-like mouse model for amelioration of chronic inflammation. Male ICR mice were infected with HSV-1, as previously described [20]. TNF- α siRNA was injected intraperitoneally twice with 1-week interval. To compare the efficacy of TNF- α siRNA versus an anti-TNF- α antibody, Infliximab, and TNF- α receptor, etanercept were administered to symptomatic mice with inflamed tissue, which were subsequently observed for 2 weeks. Infliximab, at 150 μ g/mouse (5 mg/kg), was intravenously injected only once. Etanercept (25 μ g/mouse, 50 mg/60 kg) was injected subcutaneously twice per week. Other BD mice were treated with scrambled siRNA or were untreated as negative controls. Intraperitoneal delivery of TNF- α siRNA effectively decreased BD symptoms in 18 of 32 cases (56.3%). Scrambled siRNA treatment decreased BD symptoms in 2 of 19 cases (10.5%). Infliximab was effective in 11 of 27 cases (40.7%) and Etanercept was also effective in 9 of 25 cases (36.0%) at the end of the second week after treatment. TNF- α siRNA reduced serum levels of TNF- α (1.57 ± 0.43 pg/mL), compared to levels in mice not injected (84.02 ± 24.59 pg/mL) ($P < 0.01$) or scramble injected (118.89 ± 20.08 pg/mL) ($P < 0.01$). A significant reduction in TNF- α level was observed as early as 24 h after treatment, and the level did not recover until 2 weeks after treatment, thus demonstrating an immediate, potent, and lasting biologic effect of siRNA treatment. After single injection of TNF- α siRNA, improvement of BD symptoms showed at 9 ± 7 th day on average, contrary, in infliximab-injected group, improvement was apparent at 15 ± 4 th day after injection ($P < 0.05$).

Choi et al. [56] show that siRNA can be employed to inhibit cytokine gene expression in an in vivo disease mouse model. This inhibition may, therefore, be attributed to the improvement of inflammatory symptoms.

TNF- α plays a central role in a variety of inflammatory responses [57]. TNF- α and adhesion molecules have been shown to be upregulated in BD patients [58, 59]. In addition, downregulation of TNF- α using anti-TNF- α antibody (infliximab) was found to suppress various BD symptoms including sight-threatening panuveitis [60] and intestinal ulcers in patients [61] and mice [62]. Another TNF- α blocker, etanercept, is also known to be an effective therapeutic agent for BD patients [62] and mice [56]. To test for possible anti-TNF- α and anti-inflammatory activities, Choi et al. [63] administered synthesized pyridine compound derivatives (SK94, SK126) from a natural lead source to mice. Lipopolysaccharide-(LPS-) induced TNF- α production was analyzed in the endothelial cells, Raw 264.7 cells, and serum of normal mice after treatment with SK compounds. ICR mice were inoculated with HSV as described earlier and classified as having BD according to a revised Japanese classification [20]. SK compounds (1 mg) or thalidomide (50 μ g) were orally administered to five to ten BD-like mice for five consecutive days. Placebo was administered to ten BD mice in an identical manner. The results of the present study that pyridine compound derivatives can downregulate the expression of TNF- α and adhesion molecules in normal mice. Furthermore, these compound downregulated TNF- α and adhesion molecules in BD mice and ameliorated the symptoms. Orally administered SK compounds were found to be able to effectively downregulate the serum level of TNF- α in LPS treated Balb/c mice and BD mice. Additionally, SK126 more efficiently downregulated the serum level of TNF- α , soluble intercellular adhesion molecule-1 (sICAM-1), and soluble E-selectin when compared to thalidomide in BD mice. SK126 and SK94 more efficiently downregulated sICAM-1, soluble vascular cell adhesion molecule-1 (sVCAM-1), and soluble E-selectin when compared to thalidomide in the sera of BD mice and it downregulated soluble E-selectin when compared to the thalidomide treated group in the spleen tissues of BD mice. SK126 and SK94 decreased monocyte chemoattractant protein-1 (MCP-1) in the spleen tissues of BD mice. The change in the severity score of SK94-treated BD mice was similar to that of the thalidomide treated-group. The decreasing inclination of severity score was steeper in the SK126-treated group than the thalidomide-treated group, which demonstrates that SK126 more effectively improves BD symptoms than thalidomide. Overall, SK126 is more effective and safer than thalidomide and more convenient than infliximab or etanercept as a treatment for BD. The downregulated cell adhesion molecules and TNF- α were correlated with the amelioration of BD symptoms in mice. These findings suggest that SK compounds can be used as therapeutic agents to reduce the levels of TNF- α and adhesion molecules during the treatment of inflammatory disease, especially through oral administration.

In conclusion, although many human and animal studies have been made to clarify etiology and pathogenesis of BD since the disease was first described in 1937, the disease's

etiopathogenesis is still controversial. Animal models developed so far has been insufficient to describe both the clinical aspects and etiopathogenesis of the disease. An ideal animal model has not been developed yet. Therefore patient reports issued in the literature related to BD provide more valuable information compared to experimental studies. Besides these animal models may helped to determine the disease's efficient and safe treatment alternatives. Better characterisation of pathogenic immune cell subsets, systematic and local antigens, and abnormal cell-activation mechanisms may help in the future to develop more specific and less toxic immunotherapeutic approaches to the still unsatisfactory treated BD.

References

- [1] T. Shimizu, G. E. Ehrlich, G. Inaba, and K. Hayashi, "Behçet disease (Behçet syndrome)," *Seminars in Arthritis and Rheumatism*, vol. 8, no. 4, pp. 223–260, 1979.
- [2] H. Behçet, "Ueber rezidivierende, aphthöse durch ein Virus verursachte Geschwüre am Mund, am Auge und an den Genitalen," *Dermatol Wochenschr*, vol. 105, pp. 1152–1157, 1937.
- [3] K. Namba, T. Ueno, and M. Okita, "Behçet's disease and streptococcal infection," *Japanese Journal of Ophthalmology*, vol. 30, no. 4, pp. 385–401, 1986.
- [4] Y. Hori, S. Miyazawa, and S. Nishiyama, "Experimental Behçet's disease and ultrastructural X-ray microanalysis of pathological tissues," *Journal of Dermatology*, vol. 6, no. 1, pp. 31–37, 1979.
- [5] T. Lehner, "Behçet's syndrome and autoimmunity," *British Medical Journal*, vol. 1, no. 538, pp. 465–467, 1967.
- [6] S. Ohno, E. Nakayama, and S. Sugiura, "Specific histocompatibility antigens associated with Behçet's disease," *American Journal of Ophthalmology*, vol. 80, no. 4, pp. 636–641, 1975.
- [7] T. Lehner, K. I. Welsh, and J. R. Batchelor, "The relationship of HLA-B and DR phenotypes to Behçet's syndrome, recurrent oral ulceration and the class of immune complexes," *Immunology*, vol. 47, no. 4, pp. 581–587, 1982.
- [8] F. N. Sezer, "The isolation of a virus as the cause of Behçet's disease," *American Journal of Ophthalmology*, vol. 36, no. 3, pp. 301–315, 1953.
- [9] A. D. Evans, C. A. Pallis, and J. D. Spillane, "Involvement of the nervous system in Behçet's syndrome: report of three cases and isolation of virus," *The Lancet*, vol. 273, no. 6991, pp. 349–353, 1957.
- [10] A. Mortada and I. Z. Imam, "Virus aetiology of Behçet's disease," *British Journal of Ophthalmology*, vol. 48, no. 5, pp. 250–259, 1964.
- [11] R. P. Eglin, T. Lehner, and J. H. Subak-Sharpe, "Detection of RNA complementary to herpes-simplex virus in mononuclear cells from patients with Behçet's syndrome and recurrent oral ulcers," *The Lancet*, vol. 2, no. 8312, pp. 1356–1361, 1982.
- [12] W. A. Bonass, J. A. Bird-Stewart, M. A. Chamberlain, and I. W. Halliburton, "Molecular studies in Behçet's syndrome," in *Recent Advances in Behçet's Disease*, T. Lehner, Ed., pp. 37–41, Royal Society of Medical Services, London, UK, 1986.
- [13] A. M. Denman, B. K. Pelton, W. Hylton, R. G. Palmer, and R. Topper, "Herpes simplex virus and the rheumatic diseases," *Rheumatology International*, vol. 9, no. 3–5, pp. 143–146, 1989.
- [14] M. Studd, D. J. McCance, and T. Lehner, "Detection of HSV-1 DNA in patients with Behçet's syndrome and in patients with

- recurrent oral ulcers by the polymerase chain reaction," *Journal of Medical Microbiology*, vol. 34, no. 1, pp. 39–43, 1991.
- [15] S. Lee, D. Bang, Y. H. Cho, E. S. Lee, and S. Sohn, "Polymerase chain reaction reveals herpes simplex virus DNA in saliva of patients with Behçet's disease," *Archives of Dermatological Research*, vol. 288, no. 4, pp. 179–183, 1996.
 - [16] E.-S. Lee, S. Lee, D. Bang et al., "Herpes simplex virus detection by polymerase chain reaction in intestinal ulcer of patients with Behçet's disease," *Journal of Investigative Dermatology*, vol. 101, no. 3, p. 474, 1993.
 - [17] D. Bang, K. H. Yoon, H. G. Chung, E. H. Choi, E. S. Lee, and S. Lee, "Epidemiological and clinical features of Behçet's disease in Korea," *Yonsei Medical Journal*, vol. 38, no. 6, pp. 428–436, 1997.
 - [18] W. N. Jarjour, B. D. Jefferies, J. S. Davis et al., "Antibodies to human stress proteins. A survey of various rheumatic and other inflammatory diseases," *Arthritis Rheumatology*, vol. 34, no. 9, pp. 1133–1138, 1991.
 - [19] T. Lehner, T. Shinnick, M. R. Stanford et al., "T and B cell epitope mapping with heat shock protein peptides in Behçet's disease and induction of uveitis in rats," in *Behçet's Disease*, pp. 19–27, Elsevier Science, Amsterdam, The Netherlands, 1993.
 - [20] S. Sohn, E.-S. Lee, D. Bang, and S. Lee, "Behçet's disease-like symptoms induced by the Herpes simplex virus in ICR mice," *European Journal of Dermatology*, vol. 8, no. 1, pp. 21–23, 1998.
 - [21] Y. Hirata, T. Sugita, K. Gyo, and N. Yanagihara, "Experimental vestibular neuritis induced by herpes simplex virus," *Acta Otolaryngologica*, no. 503, pp. 79–81, 1993.
 - [22] S. I. Chun, W. P. D. Su, and S. Lee, "Histopathologic study of cutaneous lesions in Behçet's syndrome," *Journal of Dermatology*, vol. 17, no. 6, pp. 333–341, 1990.
 - [23] S. Ohno and S. Sugiura, "HLA antigens and Behçet's disease," *Nippon Ganka Gakkai Zasshi*, vol. 82, no. 2, pp. 95–98, 1978.
 - [24] S. Ohno, M. Onguchi, S. Hirose et al., "Close association of HLA-Bw51 with Behçet's disease," *Archives of Ophthalmology*, vol. 100, no. 9, pp. 1455–1458, 1982.
 - [25] N. Mizuki, H. Inoko, N. Mizuki et al., "Human leukocyte antigen serologic and DNA typing of Behçet's disease and its primary association with B51," *Investigative Ophthalmology and Visual Science*, vol. 33, no. 12, pp. 3332–3340, 1992.
 - [26] N. Mizuki, S. Ohno, H. Tanaka et al., "Association of HLA-B51 and lack of association of class II alleles with Behçet's disease," *Tissue Antigens*, vol. 40, no. 1, pp. 22–30, 1992.
 - [27] S. Sohn, E.-S. Lee, and S. Lee, "The correlation of MHC haplotype and development of Behçet's disease-like symptoms induced by herpes simplex virus in several inbred mouse strains," *Journal of Dermatological Science*, vol. 26, no. 3, pp. 173–181, 2001.
 - [28] Y. Mizushima, G. Inaba, Y. Mimura et al., "Diagnostic criteria for Behçet's disease in 1987, and guideline for treating Behçet's disease," *Saishin Igaku*, vol. 43, pp. 391–393, 1988.
 - [29] S. Sohn, E.-S. Lee, H. J. Kwon, S. I. Lee, D. Bang, and S. Lee, "Expression of Th2 cytokines decreases the development of and improves Behçet's disease-like symptoms induced by herpes simplex virus in mice," *Journal of Infectious Diseases*, vol. 183, no. 8, pp. 1180–1186, 2001.
 - [30] T. Sakane, M. Takeno, N. Suzuki, and G. Inaba, "Behçet's disease," *The New England Journal of Medicine*, vol. 341, no. 17, pp. 1284–1291, 1999.
 - [31] A. M. Klok, J. de Vries, A. Rothova et al., "Antibodies against ocular and oral antigens in Behçet's disease associated with uveitis," *Current Eye Research*, vol. 8, no. 9, pp. 957–962, 1989.
 - [32] H. Direskeneli, E. Eksioğlu-Demiralp, A. Kibaroglu, S. Yavuz, T. Ergun, and T. Akoglu, "Oligoclonal T cell expansions in patients with Behçet's disease," *Clinical and Experimental Immunology*, vol. 117, no. 1, pp. 166–170, 1999.
 - [33] R. B. Nussenblatt, T. Kuwabara, F. M. de Monasterio, and W. B. Wacker, "S-antigen uveitis in primates. A new model for human disease," *Archives of Ophthalmology*, vol. 99, no. 6, pp. 1090–1092, 1981.
 - [34] S. Hirose, T. Kuwabara, and R. B. Nussenblatt, "Uveitis induced in primates by interphotoreceptor retinoid-binding protein," *Archives of Ophthalmology*, vol. 104, no. 11, pp. 1698–1702, 1986.
 - [35] M. Mochizuki, T. Kuwabara, and C. McAllister, "Adoptive transfer of experimental autoimmune uveoretinitis in rats. Immunopathogenic mechanisms and histologic features," *Investigative Ophthalmology and Visual Science*, vol. 26, no. 1, pp. 1–9, 1985.
 - [36] J. H. Yamamoto, B. Wiggert, G. J. Chader et al., "Cellular immune responsiveness of Japanese uveitis patients to retinal antigens and their uveitogenic peptides," in *Ocular Immunology Today*, M. Usui, S. Ohno, and K. Aoki, Eds., pp. 357–360, Elsevier, Amsterdam, The Netherlands, 1990.
 - [37] J. H. Yamamoto, M. Minami, G. Inaba, K. Masuda, and M. Mochizuki, "Cellular autoimmunity to retinal specific antigens in patients with Behçet's disease," *British Journal of Ophthalmology*, vol. 77, no. 9, pp. 584–589, 1993.
 - [38] T. Lehner, E. Lavery, R. Smith, R. van der Zee, Y. Mizushima, and T. Shinnick, "Association between the 65-kilodalton heat shock protein, *Streptococcus sanguis*, and the corresponding antibodies in Behçet's syndrome," *Infection and Immunity*, vol. 59, no. 4, pp. 1434–1441, 1991.
 - [39] S. Jindal, A. K. Dudani, B. Singh, C. B. Harley, and R. S. Gupta, "Primary structure of a human mitochondrial protein homologous to the bacterial and plant chaperonins and to the 65-kilodalton mycobacterial antigen," *Molecular and Cellular Biology*, vol. 9, no. 5, pp. 2279–2283, 1989.
 - [40] T. Sakane, "New perspective on Behçet's disease," *International Reviews of Immunology*, vol. 14, no. 1, pp. 89–96, 1997.
 - [41] T. Tanaka, N. Yamakawa, H. Yamaguchi et al., "Common antigenicity between *Yersinia enterocolitica*-derived heat-shock protein and the retina, and its role in uveitis," *Ophthalmic Research*, vol. 28, no. 5, pp. 284–288, 1996.
 - [42] T. Lehner, "The role of heat shock protein, microbial and autoimmune agents in the aetiology of Behçet's disease," *International Reviews of Immunology*, vol. 14, no. 1, pp. 21–32, 1997.
 - [43] M. R. Stanford, E. Kasp, R. Whiston et al., "Heat shock protein peptides reactive in patients with Behçet's disease are uveitogenic in Lewis rats," *Clinical and Experimental Immunology*, vol. 97, no. 2, pp. 226–231, 1994.
 - [44] W. Hu, A. Hasan, A. Wilson et al., "Experimental mucosal induction of uveitis with the 60-kDa heat shock protein-derived peptide 336–351," *European Journal of Immunology*, vol. 28, no. 8, pp. 2444–2455, 1998.
 - [45] F. Mor, A. Weinberger, and I. R. Cohen, "Identification of alpha-tropomyosin as a target self-antigen in Behçet's syndrome," *European Journal of Immunology*, vol. 32, no. 2, pp. 356–365, 2002.
 - [46] U. M. Davies, R. G. Palmer, and A. M. Denman, "Treatment with acyclovir does not affect orogenital ulcers in Behçet's syndrome: a randomized double-blind trial," *British Journal of Rheumatology*, vol. 27, no. 4, pp. 300–302, 1988.
 - [47] S. Sohn, D. Bang, E. S. Lee, H. J. Kwon, S. I. Lee, and S. Lee, "Experimental studies on the antiviral agent famciclovir in Behçet's disease symptoms in ICR mice," *British Journal of Dermatology*, vol. 145, no. 5, pp. 799–804, 2001.

- [48] E. S. Lee, Y. A. Kim, H. J. Kwon, D. Bang, S. Lee, and S. Sohn, "Thalidomide upregulates macrophage inflammatory protein-1 α in a herpes simplex virus-induced Behçet's disease-like animal model," *Archives of Dermatological Research*, vol. 296, no. 4, pp. 175–181, 2004.
- [49] V. Hamuryudan, C. Mat, S. Saip et al., "Thalidomide in the treatment of the mucocutaneous lesions of the Behçet syndrome: a randomized, double-blind, placebo-controlled trial," *Annals of Internal Medicine*, vol. 128, no. 6, pp. 443–450, 1998.
- [50] S. Sohn, M. Lutz, H. J. Kwon, G. Konwalinka, S. Lee, and M. Schirmer, "Therapeutic effects of gemcitabine on cutaneous manifestations in an Adamantiades-Behçet's disease-like mouse model," *Experimental Dermatology*, vol. 13, no. 10, pp. 630–634, 2004.
- [51] C. K. Edwards, "Drug discovery and development for inflammatory diseases," *Expert Opinion on Therapeutic Targets*, vol. 8, no. 2, pp. 151–163, 2004.
- [52] S. Wasmuth, D. Bauer, Y. Yang, K. P. Steuhl, and A. Heiligenhaus, "Topical treatment with antisense oligonucleotides targeting tumor necrosis factor- α in herpetic stromal keratitis," *Investigative Ophthalmology and Visual Science*, vol. 44, no. 12, pp. 5228–5234, 2003.
- [53] R. M. Schifflers, M. C. Woodle, and P. Scaria, "Pharmaceutical prospects for RNA interference," *Pharmaceutical Research*, vol. 21, no. 1, pp. 1–7, 2004.
- [54] P. D. Zamore, "Ancient pathways programmed by small RNAs," *Science*, vol. 296, no. 5571, pp. 1265–1269, 2002.
- [55] R. M. Schifflers, J. Xu, G. Storm, M. C. Woodle, and P. V. Scaria, "Effects of treatment with small interfering RNA on joint inflammation in mice with collagen-induced arthritis," *Arthritis and Rheumatism*, vol. 52, no. 4, pp. 1314–1318, 2005.
- [56] B. Choi, Y. Hwang, H. J. Kwon et al., "Tumor necrosis factor alpha small interfering RNA decreases herpes simplex virus-induced inflammation in a mouse model," *Journal of Dermatological Science*, vol. 52, no. 2, pp. 87–97, 2008.
- [57] P. H. van der Meide and H. Schellekens, "Cytokines and the immune response," *Biotherapy*, vol. 8, no. 3-4, pp. 243–249, 1996.
- [58] N. Sayinalp, O. I. Özcebe, O. Özdemir, I. C. Haznedaroğlu, S. Dündar, and S. Kirazlı, "Cytokines in Behçet's disease," *Journal of Rheumatology*, vol. 23, no. 2, pp. 321–322, 1996.
- [59] O. Kose, J. Stewart, A. Waseem, A. Lalli, and F. Fortune, "Expression of cytokeratins, adhesion and activation molecules in oral ulcers of Behçet's disease," *Clinical and Experimental Dermatology*, vol. 33, no. 1, pp. 62–69, 2008.
- [60] P. P. Sfikakis, P. G. Theodossiadis, C. G. Katsiari, P. Kaklamanis, and N. N. Markomichelakis, "Effect of infliximab on sight-threatening panuveitis in Behçet's disease," *The Lancet*, vol. 358, no. 9278, pp. 295–296, 2001.
- [61] J. H. Ju, S. K. Kwok, S. H. Seo, C. H. Yoon, H. Y. Kim, and S. H. Park, "Successful treatment of life-threatening intestinal ulcer in Behçet's disease with infliximab: rapid healing of Behçet's ulcer with infliximab," *Clinical Rheumatology*, vol. 26, no. 8, pp. 1383–1385, 2007.
- [62] L. Cantarini, I. Tinazzi, P. Caramaschi, F. Bellisai, A. Brogna, and M. Galeazzi, "Safety and efficacy of etanercept in children with juvenile-onset Behçet's disease," *International Journal of Immunopathology and Pharmacology*, vol. 22, no. 2, pp. 551–555, 2009.
- [63] B. Choi, J. Kim, E. S. Lee, D. Bang, and S. Sohn, "Synthesized pyridine compound derivatives decreased TNF alpha and adhesion molecules and ameliorated HSV-induced inflammation in a mouse model," *European Journal of Pharmacology*, vol. 657, no. 1–3, pp. 167–172, 2011.

Review Article

Potential Infectious Etiology of Behçet's Disease

Massimiliano Galeone, Roberta Colucci, Angelo Massimiliano D'Erme, Silvia Moretti, and Torello Lotti

Department of Dermatological Sciences, University of Florence, Florence 50129, Italy

Correspondence should be addressed to Massimiliano Galeone, massigale@hotmail.com

Received 24 August 2011; Accepted 24 October 2011

Academic Editor: Ümit Tursen

Copyright © 2012 Massimiliano Galeone et al. This is an open access article distributed under the Creative Commons Attribution License, which permits unrestricted use, distribution, and reproduction in any medium, provided the original work is properly cited.

Behçet's disease is a multisystem inflammatory disorder characterized by recurrent oral aphthous ulcers, genital ulcers, uveitis, and skin lesions. The cause of Behçet's disease remains unknown, but epidemiologic findings suggest that an autoimmune process is triggered by an environmental agent in a genetically predisposed individual. An infectious agent could operate through molecular mimicry, and subsequently the disease could be perpetuated by an abnormal immune response to an autoantigen in the absence of ongoing infection. Potential bacterial are *Saccharomyces cerevisiae*, mycobacteria, *Borrelia burgdorferi*, *Helicobacter pylori*, *Escherichia coli*, *Staphylococcus aureus*, and *Mycoplasma fermentans*, but the most commonly investigated microorganism is *Streptococcus sanguinis*. The relationship between streptococcal infections and Behçet's disease is suggested by clinical observations that an unhygienic oral condition is frequently noted in the oral cavity of Behçet's disease patients. Several viral agents, including herpes simplex virus-1, hepatitis C virus, parvovirus B19, cytomegalovirus, Epstein-Barr virus and varicella zoster virus, may also have some role.

1. Introduction

Behçet's disease is a multisystem inflammatory disorder characterized by recurrent oral aphthous ulcers, genital ulcers, uveitis, and skin lesions and generally presents with remissions and exacerbations. It can frequently involve the joints, gastrointestinal tract, and central nervous system [1, 2].

2. Epidemiology

Behçet's disease is most prevalent along the "Silk Road," an ancient trading route between the Mediterranean and East Asia, where it is a major cause of morbidity. In Turkey, the country with the highest incidence of the disease, the prevalence is estimated to be between 110 and 420 per 100,000, whereas that in Japan is 13–20 per 100,000, and the prevalence in the UK and USA is estimated at 1–2 per 100,000. The typical age of onset is in the third or fourth decade of life and the male-to-female ratio varies with ethnic origin [1, 3, 4].

The study of migrant populations led to interesting epidemiological findings. Individuals from endemic areas

who have immigrated to areas with low prevalence of the disease have an intermediate risk for developing the disease, which points that environment has some role in Behçet's disease. Turkish individuals who have emigrated to Germany have a significantly lower risk of disease than individuals of Turkish origin living in Turkey, although their risk remains higher than that of the native German population. Similarly, the disease is virtually unknown in Japanese immigrants to Hawaii, mainland USA, or South America despite a high prevalence in Japan [5, 6].

3. Pathogenesis

The cause of Behçet's disease remains unknown, but epidemiologic findings suggest that an autoimmune process is triggered by an infectious or environmental agent (possibly local to a geographic region) in a genetically predisposed individual [7, 8]. Whatever the stimulus is, the target tissue seems to be the small blood vessels, with various consequences of either vasculitis and/or thrombosis in many organ systems [9].

The genetic susceptibility is strongly associated with the presence of the HLA-B51 allele, with a stronger association in

Turkish and Japanese patients in comparison to Caucasians. The unusual geographic distribution of Behçet's disease and its close association with HLA-B51 may be the strongest indicator that certain genes are directly responsible for Behçet's disease or of indirectly promoting the characteristics of the underlying inflammatory changes. Other genes located outside the HLA region have been also proposed, including genes of coagulation factor V, intercellular adhesion molecule-1 (ICAM-1), and endothelial nitric oxide synthetase [10–12].

As is the case of other autoimmune diseases, there is interest in an infectious etiology. Although there is no information supporting the role of a single microorganism as the specific cause, a problem with dysregulation in innate immunity, with an altered response to more than one infectious agent, is a generally accepted theory. An infectious agent could operate through molecular mimicry. This mimicked interaction or false signalling could attract the inflammatory cells into the field of action, and this may in turn result in vasculitis. Subsequently, the disease could be perpetuated by an abnormal immune response to an autoantigen in the absence of ongoing infection [13].

A viral cause was first postulated by Behçet in 1937 [14]. Evidence of ongoing infection with a variety of viral agents has been sought. However, often there is only a history of previous infection and/or seropositivity [2]. Although herpetiform ulcers are unusual, herpes simplex virus-1 (HSV-1) is currently the most common virus associated with Behçet's disease. HSV DNA and serum antibodies against the virus have been found in a higher proportion of patients with Behçet's disease than in controls, and circulating immune complexes with the HSV-1 antigen have been reported. HSV DNA has been demonstrated in the genital and intestinal ulcers, but not in oral ulcers. However, anti-HSV immunity is also common in normal subjects, and results about therapeutic effects of antiviral treatment in Behçet's disease are scarce and controversial [15, 16]. Several other viral agents, including hepatitis C virus, parvovirus B19, cytomegalovirus, Epstein-Barr virus, and varicella zoster virus, may also have some role [17–21].

Potential bacteria are a variety of streptococcal antigens, *Saccharomyces cerevisiae*, mycobacteria, *Borrelia burgdorferi*, *Helicobacter pylori*, *Escherichia coli*, *Staphylococcus aureus*, *Mycoplasma fermentans* [22–27]. The infectious model is also supported by observations that oral ulcers precede the establishment of disease by months or years and disease relapses are frequent. Thus, oral microbial flora have long been implicated in the pathogenesis. The most commonly investigated microorganism is *Streptococcus*. The relationship between streptococcal infections and Behçet's disease is suggested by clinical observations that an unhygienic oral condition including periodontitis, decayed teeth, and chronic tonsillitis is frequently noted in the oral cavity of Behçet's disease patients [28]. It is not clear that the predisposition of the patients is correlated with streptococcal infection, but the uncommon oral *Streptococcus sanguinis* serotypes (called KTH-1) and antibodies against the bacteria are significantly increased in the oral flora and serum, respectively, of patients with the disease compared with

healthy controls [29]. The patients show strong delayed-type cutaneous hypersensitivity reactions against streptococcal antigens in skin tests and sometimes Behçet's disease symptoms were provoked by skin injection of the antigens [30]. The new criteria included hypersensitivity skin reactions against streptococci in the diagnosis as one of the references and the levels of disease severity of Behçet's disease patients [31]. *S. sanguinis* antigens share a sequence of amino acids with one of the protein classes of the cellular membranes called heat shock proteins (HSPs), which are expressed above the cellular membrane in response to physiological shocks and microbial stimulus [12]. Thus, HSPs are possible candidate antigen for Behçet's disease. Particularly, the peptides of 65 kDa (HSP-65) derived from the bacteria show considerable homology with those of the human 60 kDa (HSP-60). Moreover, mycobacterial and human HSPs have over 50% in sequence homology [32]. Studies have shown that *S. sanguis* and HSP 60/65 kDa activate $\gamma\delta$ T cells in Behçet's disease patients but not controls. It is suggested that, following the bacterial stimulus, mucous cells express HSPs which are antigenic and reactive antimucous T cells in susceptible individuals (molecular mimicry model) [30]. As for the most other autoimmune disorders, the Th1-type polarization is predominant in Behçet's disease [7]. $\gamma\delta$ T lymphocytes have a role in the immune response to infections and in autoimmunity by recognizing bacteria-derived and autologous antigens. Patients with Behçet's disease have increased numbers of activated $\gamma\delta$ T cells (in circulation and in mucosal lesions), which produce inflammatory cytokines, including IFN- γ , TNF- α , and IL-8. Culture of $\gamma\delta$ T lymphocytes from Behçet's disease patients proliferates in response to mycobacterial HSP-derived peptides and in response to products from microorganisms in oral ulcers [11, 33]. Complex interactions between T cells, antigen presenting cells, (APCs) and neutrophils are involved in the immune pathogenesis of Behçet's disease. Neutrophils are hyperactive in Behçet's disease, with increased chemotaxis, phagocytosis, superoxide production and myeloperoxidase expression and produce several cytokines [34]. Behçet's disease lesions might be induced with vascular reaction or lymphocytic vasculitis as the immunological reaction by the APCs expressing the *S. sanguinis* antigens [30]. Moreover, the amino acid sequence of the peptides of Bes-1, a gene derived from oral *S. sanguinis*, shows more than 60% similarity to the human intraocular ganglion peptide, Brn-3b. These results suggest that Bes-1 might be an inducer for the retinal and neural involvement possible in Behçet's disease patients [35].

Pustular skin lesions are often not sterile and may contain *Staphylococcus aureus* and *Prevotella* species. Whether these pustules are secondarily infected or whether the infections play a pathogenic role in the development of pustular lesions remains to be determined [36].

Anti-*S. cerevisiae* antibodies (ASCAs) may be especially common in intestinal Behçet's disease and are also increased in healthy relatives of patients, according to the study by Choi et al. who evaluated whether ASCA expression is associated with clinical findings at diagnosis and the clinical course of intestinal Behçet's disease and found that the ASCA-positive rate was 44.3% in intestinal Behçet's disease but was

not related to clinical findings at diagnosis and cumulative relapse rates [37].

Mycoplasmas are known to exhibit molecular mimicry to eukaryotic structures that may modulate immune responses [27, 38].

4. Therapeutic Implications

Antiseptic agents and antibiotics are used to control microbial contamination and secondary infection [39]. Chlorhexidine gel and triclosan have been shown to reduce the number, pain severity, and duration of aphthous ulcers [40, 41].

Antibiotics, especially tetracycline, has been widely used in oral ulcers of Behçet's disease for years. Tetracycline mouthwash decreases pain severity and duration of oral ulcers. Minocycline mouthwashes as compared to topical tetracycline rinses resulted in significantly improved pain control, by reducing the severity and duration of pain [42]. Minocycline reduces not only the growth of oral streptococci, but also suppresses interleukins production from T cells [43]. The effect of penicillin on mucocutaneous lesions and arthritis has been examined in two different studies, and it was found that prophylactic penicillin treatment reduced both the mucocutaneous lesions and the arthritis episodes. Other studies also showed that combination therapy, 1200000 units of benzathine-penicillin injected monthly plus 1 mg of oral colchicine daily for 4 months, was effective to suppress Behçet's disease symptoms, compared to colchicine monotherapy [44–46].

Acyclovir is not effective in the treatment of oral and genital ulceration [47].

5. Conclusion

The role of microorganisms in the pathogenesis of Behçet's disease has long been investigated, and there are ample data on several microorganisms. However, none of these infectious agents have been proved to cause Behçet's disease. Thus, a complex immune response might be generated to a group of microorganisms that share common antigens rather than to an infection due to a specific single microorganism.

Disclosure

The authors confirm that the paper is an original work and that it has not been published and is not under consideration elsewhere.

Authors' Contribution

All of the authors participated in the preparation of the paper.

Conflict of Interests

The authors have no financial obligations or conflict of interests to declare.

References

- [1] T. Sakane, M. Takeno, N. Suzuki, and G. Inaba, "Behçet's disease," *New England Journal of Medicine*, vol. 341, no. 17, pp. 1284–1291, 1999.
- [2] S. E. Marshall, "Behçet's disease," *Best Practice and Research: Clinical Rheumatology*, vol. 18, no. 3, pp. 291–311, 2004.
- [3] A. Idil, A. Gürler, A. Boyvat et al., "The prevalence of Behçet's disease above the age of 10 years: the results of a pilot study conducted at the park primary health care center in Ankara, Turkey," *Ophthalmic Epidemiology*, vol. 9, no. 5, pp. 325–331, 2002.
- [4] G. Azizlerli, A. A. Köse, R. Sarica et al., "Prevalence of Behçet's disease in Istanbul, Turkey," *International Journal of Dermatology*, vol. 42, no. 10, pp. 803–806, 2003.
- [5] C. C. Zouboulis, I. Kötter, D. Djawari et al., "Epidemiological features of Adamantiades-Behçet's disease in Germany and in Europe," *Yonsei Medical Journal*, vol. 38, no. 6, pp. 411–422, 1997.
- [6] T. Hirohata, M. Kuratsune, A. Nomura, and S. Jimi, "Prevalence of Behçet's syndrome in Hawaii. With particular reference to the comparison of the Japanese in Hawaii and Japan," *Hawaii Medical Journal*, vol. 34, no. 6, pp. 244–246, 1975.
- [7] S. Pay, I. Şimşek, H. Erdem, and A. Dinç, "Immunopathogenesis of Behçet's disease with special emphasis on the possible role of antigen presenting cells," *Rheumatology International*, vol. 27, no. 5, pp. 417–424, 2007.
- [8] A. Kulaber, I. Tugal-Tutkun, P. Sibel et al., "Pro-inflammatory cellular immune response in Behçet's disease," *Rheumatology International*, vol. 27, no. 12, pp. 1113–1118, 2007.
- [9] A. Kalayciyan and C. C. Zouboulis, "An update on Behçet's disease," *Journal of the European Academy of Dermatology and Venerology*, vol. 21, no. 1, pp. 1–10, 2007.
- [10] D. H. Verity, J. E. Marr, S. Ohno, G. R. Wallace, and M. R. Stanford, "Behçet's disease, the silk road and HLA-B51: historical and geographical perspectives," *Tissue Antigens*, vol. 54, no. 3, pp. 213–220, 1999.
- [11] D. Mendes, M. Correia, M. Barbedo et al., "Behçet's disease—a contemporary review," *Journal of Autoimmunity*, vol. 32, no. 3–4, pp. 178–188, 2009.
- [12] C. Mendoza-Pinto, M. García-Carrasco, M. Jiménez-Hernández et al., "Etiopathogenesis of Behçet's disease," *Autoimmunity Reviews*, vol. 9, no. 4, pp. 241–245, 2010.
- [13] S. Yurdakul and H. Yazici, "Behçet's syndrome," *Best Practice and Research: Clinical Rheumatology*, vol. 22, no. 5, pp. 793–809, 2008.
- [14] H. Behçet, "Über rezidivierende, aphthous durch ein virus verursachte geschwüre am mund, am auge und an den genitalien," *Dermatol Wochenschi*, vol. 105, pp. 1152–1157, 1937.
- [15] H. Direskeneli, "Behçet's disease: infectious aetiology, new autoantigens, and HLA-B51," *Annals of the Rheumatic Diseases*, vol. 60, no. 11, pp. 996–1002, 2001.
- [16] V. G. Kaklamani, G. Vaiopoulos, and P. G. Kaklamani, "Behçet's disease," *Seminars in Arthritis and Rheumatism*, vol. 27, no. 4, pp. 197–217, 1998.
- [17] N. Ilter, E. Senol, M. A. Gürrer, and M. O. Oztaş, "Behçet's disease and HCV infection," *International Journal of Dermatology*, vol. 39, no. 5, pp. 396–397, 2000.
- [18] S. Kiraz, M. A. Oztürk, I. Ertenli, and M. Calgüneri, "Parvovirus B19 infection in Behçet's disease," *Annals of the Rheumatic Diseases*, vol. 60, no. 8, pp. 814–815, 2001.
- [19] A. Sun, J. G. Chang, C. L. Kao et al., "Human cytomegalovirus as a potential etiologic agent in recurrent aphthous ulcers and

- Behçet's disease," *Journal of Oral Pathology and Medicine*, vol. 25, no. 5, pp. 212–218, 1996.
- [20] A. Sun, J. G. Chang, C. T. Chu, B. Y. Liu, J. H. Yuan, and C. P. Chiang, "Preliminary evidence for an association of Epstein-Barr virus with pre-ulcerative oral lesions in patients with recurrent aphthous ulcers or Behçet's disease," *Journal of Oral Pathology and Medicine*, vol. 27, no. 4, pp. 168–175, 1998.
 - [21] S. Akdeniz, M. Harman, S. Atmaca, and N. Akpolat, "The seroprevalence of varicella zoster antibodies in Behçet's and other skin diseases," *European Journal of Epidemiology*, vol. 18, no. 1, pp. 91–93, 2003.
 - [22] T. Lehner, E. Lavery, R. Smith, R. van der Zee, Y. Mizushima, and T. Shinnick, "Association between the 65-kilodalton heat shock protein, *Streptococcus sanguis*, and the corresponding antibodies in Behçet's syndrome," *Infection and Immunity*, vol. 59, no. 4, pp. 1434–1441, 1991.
 - [23] I. Krause, Y. Monselise, G. Milo, and A. Weinberger, "Anti-saccharomyces cerevisiae antibodies—a novel serologic marker for Behçet's disease," *Clinical and Experimental Rheumatology*, vol. 20, no. 4, pp. S21–S24, 2002.
 - [24] E. Isogai, H. Isogai, S. Kotake et al., "Detection of antibodies against *Borrelia burgdorferi* in patients with uveitis," *American Journal of Ophthalmology*, vol. 112, no. 1, pp. 23–30, 1991.
 - [25] O. Avci, E. Ellidokuz, I. Simşek, B. Büyükgebiz, and A. T. Güneş, "Helicobacter pylori and Behçet's disease," *Dermatology*, vol. 199, no. 2, pp. 140–143, 1999.
 - [26] Z. Amoura, M. Guillaume, S. Caillat-Zucman, B. Wechsler, and J. C. Piette, "Pathophysiology of Behçet's disease," *La Revue de Médecine Interne*, vol. 27, no. 11, pp. 843–853, 2006.
 - [27] C. C. Zouboulis, J. R. Turnbull, and P. F. Mühlrad, "Association of mycoplasma fermentans with adamantiades-Behçet's disease," *Advances in experimental medicine and biology*, vol. 528, pp. 191–194, 2003.
 - [28] G. Mumcu, N. Inanc, S. Yavuz, and H. Direskeneli, "The role of infectious agents in the pathogenesis, clinical manifestations and treatment strategies in Behçet's disease," *Clinical and Experimental Rheumatology*, vol. 25, supplement 45, no. 4, pp. S27–S33, 2007.
 - [29] K. Yoshikawa, S. Kotake, Y. Sasamoto, S. Ohno, and H. Matsuda, "Close association of *Streptococcus sanguis* and Behçet's disease," *Nihon Ganka Gakkai Zasshi*, vol. 95, no. 12, pp. 1261–1267, 1991.
 - [30] F. Kaneko, N. Oyama, H. Yanagihori, E. Isogai, K. Yokota, and K. Oguma, "The role of streptococcal hypersensitivity in the pathogenesis of Behçet's disease," *European Journal of Dermatology*, vol. 18, no. 5, pp. 489–498, 2008.
 - [31] M. S. Kurokawa and N. Suzuki, "Behçet's disease," *Clinical and Experimental Medicine*, vol. 4, no. 1, pp. 10–20, 2004.
 - [32] T. Lehner, "The role of heat shock protein, microbial and autoimmune agents in the aetiology of Behçet's disease," *International Reviews of Immunology*, vol. 14, no. 1, pp. 21–32, 1997.
 - [33] I. Bank, M. Duvdevani, and A. Livneh, "Expansion of $\gamma\delta$ T-cells in Behçet's disease: role of disease activity and microbial flora in oral ulcers," *Journal of Laboratory and Clinical Medicine*, vol. 141, no. 1, pp. 33–40, 2003.
 - [34] M. Zierhut, N. Mizuki, S. Ohno et al., "Immunology and functional genomics of Behçet's disease," *Cellular and Molecular Life Sciences*, vol. 60, no. 9, pp. 1903–1922, 2003.
 - [35] M. Xiang, L. Zhou, Y. W. Peng, R. L. Eddy, T. B. Shows, and J. Nathans, "Brn-3b: a POU domain gene expressed in a subset of retinal ganglion cells," *Neuron*, vol. 11, no. 4, pp. 689–701, 1993.
 - [36] G. Hatemi, H. Bahar, S. Uysal et al., "The pustular skin lesions in Behçet's syndrome are not sterile," *Annals of the Rheumatic Diseases*, vol. 63, no. 11, pp. 1450–1452, 2004.
 - [37] C. H. Choi, T. I. Kim, B. C. Kim et al., "Anti-saccharomyces cerevisiae antibody in intestinal Behçet's disease patients: relation to clinical course," *Diseases of the Colon and Rectum*, vol. 49, no. 12, pp. 1849–1859, 2006.
 - [38] E. Jacobs, A. Bartl, K. Oberle, and E. Schiltz, "Molecular mimicry by *Mycoplasma pneumoniae* to evade the induction of adherence inhibiting antibodies," *Journal of Medical Microbiology*, vol. 43, no. 6, pp. 422–429, 1995.
 - [39] E. Alpsoy, "Behçet's disease: treatment of mucocutaneous lesions," *Clinical and Experimental Rheumatology*, vol. 23, no. 4, pp. 532–539, 2005.
 - [40] A. B. Skaare, B. B. Herlofson, and P. Barkvoll, "Mouthrinses containing triclosan reduce the incidence of recurrent aphthous ulcers (RAU)," *Journal of Clinical Periodontology*, vol. 23, no. 8, pp. 778–781, 1996.
 - [41] E. Alpsoy and A. Akman, "Behçet's disease: an algorithmic approach to its treatment," *Archives of Dermatological Research*, vol. 301, no. 10, pp. 693–702, 2009.
 - [42] M. Gorsky, J. B. Epstein, S. Rabenstein, H. Elishoov, and N. Yarom, "Topical minocycline and tetracycline rinses in treatment of recurrent aphthous stomatitis: a randomized cross-over study," *Dermatology Online Journal*, vol. 13, no. 2, p. 1, 2007.
 - [43] F. Kaneko, N. Oyama, and A. Nishibu, "Streptococcal infection in the pathogenesis of Behçet's disease and clinical effects of minocycline on the disease symptoms," *Yonsei Medical Journal*, vol. 38, no. 6, pp. 444–454, 1997.
 - [44] M. Calgüneri, S. Kiraz, I. Ertenli, M. Benekli, Y. Karaarslan, and I. Çelik, "The effect of prophylactic penicillin treatment on the course of arthritis episodes in patients with Behçet's disease: a randomized clinical trial," *Arthritis and Rheumatism*, vol. 39, no. 12, pp. 2062–2065, 1996.
 - [45] M. Çalgüneri, I. Ertenli, S. Kiraz, M. Erman, and I. Çelik, "Effect of prophylactic benzathine penicillin on mucocutaneous symptoms of Behçet's disease," *Dermatology*, vol. 192, no. 2, pp. 125–128, 1996.
 - [46] M. M. Al-Waiz, K. E. Sharquie, M. H. A-Qaissi, and R. K. Hayani, "Colchicine and benzathine penicillin in the treatment of Behçet disease: a case comparative study," *Dermatology Online Journal*, vol. 11, no. 3, p. 3, 2005.
 - [47] U. M. Davies, R. G. Palmer, and A. M. Denman, "Treatment with acyclovir does not affect orogenital ulcers in Behçet's syndrome: a randomized double-blind trial," *British Journal of Rheumatology*, vol. 27, no. 4, pp. 300–302, 1988.

Review Article

Behcet's Disease and Endocrine System

Onur Ozhan and Kerem Sezer

Division of Endocrinology and Metabolism, Department of Internal Medicine, School of Medicine, Mersin University, 33079 Mersin, Turkey

Correspondence should be addressed to Onur Ozhan, ozhanonur@yahoo.com

Received 23 August 2011; Accepted 27 October 2011

Academic Editor: Ümit Tursen

Copyright © 2012 O. Ozhan and K. Sezer. This is an open access article distributed under the Creative Commons Attribution License, which permits unrestricted use, distribution, and reproduction in any medium, provided the original work is properly cited.

Behcet's disease (BD) is a chronic disease which is characterized by recurrent oral aphthous ulcerations, recurrent genital ulcerations, skin eruptions, ocular involvements and other various systemic manifestations as well as systemic vasculitis. Endocrine involvement in BD regarding various systems can be seen. Hypophysis is one of the best and dense vascularized organs of the body, thus it is likely that it can be affected by BD. Not only anterior hypophysis functions, but posterior hypophysis functions as well can be affected. As BD is a disease of autoimmune process, it may be possible that adrenal insufficiency or alterations in the cortisol levels could be expected. Another concern is whether or not there is insulin resistance in patients with BD. The available data suggests that there is an increased susceptibility to insulin resistance in patients with BD.

1. Introduction

Behcet's disease (BD) is a chronic disease which is characterized by recurrent oral aphthous ulcerations, recurrent genital ulcerations, skin eruptions, ocular involvements, and other various systemic manifestations as well as systemic vasculitis [1]. Endocrine involvement in BD regarding various systems can be seen. Here with this paper we have tried to review the literature in terms of BD "effects" on endocrine system.

2. Behcet's Disease and Hypophysis

Hypophysis is one of the best and densest vascularized organs of the body, thus it is likely that it can be affected by BD [2]. There are several studies regarding this fact in the literature. In one of these studies, Akdeniz et al. had studied the baseline and stimulated thyroid functions in BD. They recruited 30 patients consisting of 17 males and 13 females and 30 control subjects to their study. Thyroid function tests baseline and TSH levels at the 20th and 60th minutes after the administration of TRH were evaluated. In conclusion they stated that thyroid functions were normal in patients with BD; however, TRH stimulation was found to be decreased [3]. In another study where thyroid functions were evaluated, Aksu et al.,

found that thyroid function tests were within normal range in patients with BD; however, they did not assess the TRH-stimulated TSH levels [4]. Posterior hypophysis functions can also be affected in patients with BD which can represent itself with diabetes insipidus. Even though this entity is a rare feature of BD, there are several case reports being reported in the literature. In one of these, Khiari et al. reported that a 47-year-old man presented with oral and genital ulcers, skin lesions, and polyarthralgia. Two years after his first application he started to suffer from right uveitis and central diabetes insipidus without dysfunction of the anterior pituitary [5]. In another case report Szymajda et al., from USA, reported a 32-year-old man with diplopia and severe headaches who had transverse sinus thrombosis at the same time. They also stated that the patient was suffering from recurrent mouth and genital ulcers for more than 3 months before his application. During his hospitalization, the patient was reported having polyuria, polydipsia, hypernatremia, and hypotonic urine which were the stigmata of diabetes insipidus. After the diagnosis, desmopressin was started and improvement in clinical status was achieved. As the mechanism of this pathology, vasculitis was accused [6]. Jin-No et al. [7], Otsuka et al. [8], and Hamza et al. [9], have studies also regarding the relationship between BD and diabetes insipidus.

Another interesting question which has been a concern for recent years is: does prolactin levels have effect on the activation of BD? There are some studies available in the literature regarding this subject. In one of these studies Çil et al. found no significant difference in terms of hormone levels between the Behcet and control groups [10]. However in another study, Proença et al. reported that serum prolactin levels were significantly higher in BD patients versus controls [11]. Another study by Atasoy et al. also had declared that patients with active BD had higher serum prolactin levels than the inactive and control groups. In their study prolactin levels in patients with active BD differed significantly from the healthy control subjects [12]. Nevertheless, a study which was conducted by Houman et al., found that the mean prolactin level in the BD group (mean = 13.76, SD = 6.82), was higher than the control group (mean = 10.13, SD = 5.46) with no statistically significant difference. Also the mean prolactin levels in all subgroups of patients with BD were higher than normal, but no statistically significant difference was shown between these subgroups [13]. The exact mechanisms of why prolactin is increased in BD remains unclear; however, there are some facts which has been suggested responsible. Prolactin has been shown to be an important modulator of cellular and humoral immunity which may play a role in the pathogenesis of several autoimmune diseases such as rheumatoid arthritis [14–16]. Increased prolactin levels and disease activity of systemic lupus erythematosus have been found to be associated with each other as well [17]. In this context, since BD is also a rheumatic disease of autoimmune basis, it might be suggested that prolactin levels could be elevated.

3. Behcet's Disease and Adrenal Glands

As BD is a disease of autoimmune process, it may be possible that adrenal insufficiency or alterations in the cortisol levels could be expected. Taking this fact into consideration Colak et al. had conducted a study investigating the effects of low- (1 microg; LDT) and standard- (250 microg; SDT) dose ACTH stimulation tests on adrenal cortex functions in patients with Behcet's disease; 18 patients with BD and 15 controls were recruited to this study. Both the patient and control groups were administered 1 microgram and 250 micrograms of ACTH, respectively, with 3-day intervals in between and responses of cortisol at the 0th, 30th, and 60th minutes after the administration of ACTH were evaluated. They found that there was no statistically significant difference between basal cortisol levels of BD and the control group; however, cortisol levels in the 60th minute of LDT were significantly low in patients with Behcet as compared to the control group. The peak cortisol responses to LTD were found to be decreased in Behcet's group as well. In this context they suggested that hypothalamopituitary axis is partially suppressed in BD [18]. A case report by Sánchez Sobrino et al., from Spain reports a longstanding Behcet's patient developing adrenal insufficiency, caused by isolated corticotropin deficiency. In this sense they reviewed the literature for the possible mechanisms of hypothalamic-pituitary injury in BD [19].

4. Behcet's Disease and Insulin Resistance

Another concern and studied subject is whether or not there is insulin resistance in patients with BD. In one of these studies Kim et al., evaluated this subject. They recruited 82 BD patients and 89 healthy controls to the study and measured the resistin and adiponectin levels at the time of enrolment along with the HOMA-IR evaluation with fasting plasma glucose and insulin levels. As their result they declared that there is an increased susceptibility to insulin resistance in patients with BD as compared to the controls and resistin could be an independent factor for this resistance [20]. In another study where peripheral insulin resistance was assessed with hyperinsulinemic-euglycaemic glucose clamp technique, Erdem et al., from Turkey, found that patients with BD exhibit peripheral insulin resistance which was thought to be because of inflammation and endothelial dysfunction [21].

5. Conclusion

With this review we have tried to have a look at what has been studied and evaluated in the literature regarding the relationship between BD and certain endocrine subjects via PubMed. As it may be seen, the available data is not too much. Since BD is a disease of autoimmunity and many diseases related with endocrinology have autoimmunity basis, we believe that further studies should be performed to understand if BD and at least some endocrine diseases interact with each other.

References

- [1] T. Sakane, M. Takeno, N. Suzuki, and G. Inaba, "Behcet's disease," *New England Journal of Medicine*, vol. 341, no. 17, pp. 1284–1291, 1999.
- [2] D. C. Aron, C. V. Finding, and J.B. Thyrell, "Hypothalamus and pituitary gland," in *Basic and Clinical Endocrinology*, F. S. Greenspan and D. G. Gardner, Eds., pp. 106–176, McGraw-Hill, New York, NY, USA, 7th edition, 2004.
- [3] S. Akdeniz, S. Colak, A. K. Tuzcu, M. Bahceci, and M. Harman, "Baseline and stimulated thyroid functions in Behcet's disease," *Journal of the European Academy of Dermatology and Venereology*, vol. 20, no. 7, pp. 878–879, 2006.
- [4] K. Aksu, F. Oksel, G. Keser et al., "Thyroid functions in Behcet's disease," *Clinical Endocrinology*, vol. 50, no. 3, pp. 406–407, 1999.
- [5] K. Khiari, L. Cherif, I. Hadj Ali et al., "Central diabetes insipidus with Behcet disease. A case report," *Annales d'Endocrinologie*, vol. 64, no. 6, pp. 426–427, 2003.
- [6] A. Szymajda, M. S. Eledrisi, R. Patel, G. Chaljub, E. Cepeda, and P. Kaushik, "Diabetes insipidus as a consequence of neurologic involvement in Behcet's syndrome," *Endocrine Practice*, vol. 9, no. 1, pp. 33–35, 2003.
- [7] M. Jin-No, T. Fujii, Y. Jin-No, Y. Kamiya, M. Okada, and M. Kawaguchi, "Central Diabetes Insipidus with Behcet's Disease," *Internal Medicine*, vol. 38, no. 12, pp. 995–999, 1999.
- [8] F. Otsuka, T. Amano, T. Ogura, and Z. Ota, "Diabetes insipidus with Behcet's disease," *Lancet*, vol. 346, no. 8988, pp. 1494–1495, 1995.
- [9] M. Hamza, S. Chamaki, and R. Boukris, "Diabetes insipidus in a case of Behcet's disease with neurologic manifestations," *Presse Medicale*, vol. 18, no. 35, p. 1755, 1989.

- [10] A. P. Çil, A. A. Karabulut, and M. Koçak, "Assessment of ovarian stromal artery Doppler characteristics and serum hormone levels in patients with Behçet disease," *Diagnostic and Interventional Radiology*, vol. 16, no. 4, pp. 288–292, 2010.
- [11] H. Proença, C. Ferreira, M. Miranda, A. Castanheira-Dinis, and M. Monteiro-Grillo, "Serum prolactin levels and Behçet disease," *European Journal of Ophthalmology*, vol. 17, no. 3, pp. 404–407, 2007.
- [12] M. Atasoy, S. Karatay, K. Yildirim, M. Kadi, T. Erdem, and K. Senel, "The relationship between serum prolactin levels and disease activity in patients with Behcet's disease," *Cell Biochemistry and Function*, vol. 24, no. 4, pp. 353–356, 2006.
- [13] H. Houman, I. Ben Ghorbel, M. Lamoum et al., "Prolactin levels in Behcet's disease: no correlation with disease manifestations and activity," *Annales de Medecine Interne*, vol. 152, no. 3, pp. 209–211, 2001.
- [14] P. M. Reber, "Prolactin and immunomodulation," *American Journal of Medicine*, vol. 95, no. 6, pp. 637–644, 1993.
- [15] M. Neidhart, "Prolactin in autoimmune diseases," *Proceedings of the Society for Experimental Biology and Medicine*, vol. 217, no. 4, pp. 408–419, 1998.
- [16] I. C. Chikanza, "Prolactin and neuroimmunomodulation: in vitro and in vivo observations," *Annals of the New York Academy of Sciences*, vol. 876, pp. 119–130, 1999.
- [17] L. J. Jara, C. Gomez-Sanchez, L. H. Silveira, P. Martinez-Osuna, F. B. Vasey, and L. R. Espinoza, "Hyperprolactinemia in systemic lupus erythematosus: association with disease activity," *American Journal of the Medical Sciences*, vol. 303, no. 4, pp. 222–226, 1992.
- [18] R. Colak, Y. Ozkan, S. U. Cengiz, Y. Saral, B. C. Kandi, and I. Halifeoglu, "A comparison between the effects of low (1 μ g) and standard dose (250 μ g) ACTH stimulation tests on adrenal cortex functions with Behçet's disease," *Journal of the European Academy of Dermatology and Venereology*, vol. 20, no. 6, pp. 721–725, 2006.
- [19] P. Sánchez Sobrino, C. P. Fernández, J. L.L. Ferreira, B. M. Gil, R. P. Carballeira, and R. V. García-Mayor, "Behçet disease with isolated ACTH deficiency," *Endocrinología y Nutrición*, vol. 56, no. 9, pp. 463–466, 2009.
- [20] S. K. Kim, J. Y. Choe, S. H. Park, S. W. Lee, G. H. Lee, and W. T. Chung, "Increased insulin resistance and serum resistin in Korean patients with Behcet's disease," *Archives of Medical Research*, vol. 41, no. 4, pp. 269–274, 2010.
- [21] H. Erdem, A. Dinc, S. Pay, I. Simsek, and M. Turan, "Peripheral insulin resistance in patients with Behçet's disease," *Journal of the European Academy of Dermatology and Venereology*, vol. 20, no. 4, pp. 391–395, 2006.

Review Article

Clinical and Pathological Manifestations with Differential Diagnosis in Behçet's Disease

Aysin Kокturk

Department of Dermatology, Faculty of Medicine, Mersin University, Zeytinlibahçe 33079, Mersin, Turkey

Correspondence should be addressed to Aysin Kокturk, aysinkokturk@yahoo.com

Received 26 August 2011; Accepted 13 October 2011

Academic Editor: Ümit Tursen

Copyright © 2012 Aysin Kокturk. This is an open access article distributed under the Creative Commons Attribution License, which permits unrestricted use, distribution, and reproduction in any medium, provided the original work is properly cited.

Behçet's disease is a multisystemic inflammatory disease of unknown etiology which usually occurs as a trait of symptoms: aphthous stomatitis, genital ulcerations, and ocular disease. At the beginning of the disease the diagnosis is uncertain because of various clinical manifestations and a long period up to the full clinical picture manifestation. Since neither the laboratory data nor the histopathological signs are truly pathognomonic in Behçet's disease, the differential diagnosis depends on a careful evaluation of the medical history and meticulous physical examination to detect concomitant systemic manifestations. Sometimes, some laboratory test may help establish the diagnosis. Subspecialty referral to ophthalmology, rheumatology, neurology, and gastroenterology should be considered when indicated.

1. Introduction

Behçet's disease (BD) is a multisystemic inflammatory process of unknown etiology, characterized by relapsing episodes of oral aphthous ulcers, genital ulcers, other skin lesions, and ocular lesions. The Turkish dermatologist Hulusi Behçet first described the disease in 1937, as the triad of recurrent oral aphthous ulcers, genital ulcers, and uveitis [1]. It can affect nearly every system and organ including ocular, cardiovascular, gastrointestinal, renal, pulmonary, urologic, and central nervous systems and the joints [1–4].

It affects people mainly between the ages of 20 to 40. Both genders are usually equally affected [2, 3]. However different male-to-female ratio was recorded in some countries: there is a male predominance in Middle Eastern countries, such as Iraq, Jordan, Saudi Arabia, and Lebanon, while a female predominance is seen in the USA and Britain [4–8].

Because there are no specific diagnostic laboratory tests or histopathologic findings, the diagnosis of the disease relies on clinical criteria and often takes several years to establish a definitive diagnosis after the appearance of the initial manifestations. Manifestations of BD are not consistent among patients. Clinical phenotypes are very heterogeneous and evolution of the disease vary due to ethnic, geographical, and individual differences.

Moreover, the initial manifestations and the combination of clinical symptoms are very heterogeneous from patient to patient, even within the same ethnic group. Some patients present with only mucocutaneous symptoms, while some suffer from systemic involvement causing serious complications.

As there are no pathognomonic clinical findings, various diagnostic criteria and classifications have been proposed during the years. According to criteria of International Study Group which was proposed in 1990, the presence of oral aphthous ulcerations and two of the following clinical manifestations is required for the diagnosis of BD: recurrent genital ulcerations, skin lesions such as erythema Nodosum-Like lesions, papulopustular lesions, ocular involvement, and positive pathergy test [9] (Table 1).

The most common presenting symptoms of the disease are mucocutaneous features [10–12]. Recurrent oral aphthous ulcerations and genital ulcerations are the most common.

Other skin lesions, such as erythema Nodosum-Like lesions, papulopustular lesions, superficial thrombophlebitis, pathergy reaction, pyoderma gangrenosum-like lesions, Sweet's syndrome-like lesions, and erythema multiforme can be observed in about 80% of the patients with BD [2, 10, 11, 13]. In addition, extragenital ulcers, palpable purpura,

TABLE 1: International Study Group criteria for the diagnosis of Behçet's disease [9].

Recurrent oral ulceration	Minor/major aphthous or herpetiform ulcer observed by the physician or patient which recurred at least three times in one 12-month period
Plus two of the following:	
Recurrent genital ulceration	Aphthous ulcer or scarring observed by the physician or patient
Eye lesions	Anterior/posterior uveitis, cells in the vitreous on slit-lamp examination or retinal vasculitis observed by an ophthalmologist
Cutaneous lesions	Erythema nodosum observed by physician or patient, pseudofolliculitis or papulopustular lesions, or acneiform nodules observed by physician in postadolescent patients not receiving corticosteroids
Positive pathergy test	Interpreted by the physician at 24–48 h

hemorrhagic bullae, furuncles, abscesses, perniolike lesions, and subungual infarctions, can also be seen less commonly in BD [2, 11].

Prognosis depends on the clinical involvement and the disease may result in considerable morbidity and mortality. Loss of visual acuity and neurological disease are major causes of morbidity and disability. Involvement of nervous, gastrointestinal, and large vascular systems may be lethal or can leave irreversible deficits.

Severe clinical course and systemic involvement are observed when early onset of the disease is present [2, 11, 14]. Male sex and HLA B₅₁ positivity are also associated with more severe disease [2, 10, 11].

Disease course usually gets better with the passage of time with decrease in mortality rate.

2. Mucocutaneous Manifestations of Behçet's Disease

2.1. Recurrent Oral Aphthous Ulcers. Recurrent oral aphthous ulcers (ROAUs) are a sine qua non feature of BD according to the International Study Group criteria [9].

Oral aphthous ulcers frequently the first manifestation of BD recurring at least 3 times a year. It characteristically precede by many years the onset of other manifestations. They may be single or multiple and can occur after local trauma and dental intervention. The ulcer covered with grayish-white pseudo membrane or central necrotic base with round and sharp erythematous border is termed as punched-out ulcer. The ulcers are usually so painful that the patient is unable to eat during the attack. However, some patients with BD may paradoxically report no painful symptoms during active disease, despite the existence of extensive oral ulceration. The most commonly involved sites of ulcers are gingival, buccal and labial mucosa, and tongue

TABLE 2: Systemic conditions presenting with aphthous-like lesions.

Behçet's disease
Gastrointestinal disorders
Nutritional/Heamatological deficiencies
Heamatological diseases
MAGIC syndrome
Reiter syndrome
PFAPA syndrome
Sarkoidoz
Drug reactions

although they can also appear in the soft and hard palate, oropharynx, and tonsils [12, 15, 16].

Minor ulcers (<1 cm in diameter) are the most (80%–85%) common form of ROAU. They are shallow, small ulcers, 1–5 in numbers, moderately painful, and heal without scarring in 4–14 days [10, 17]. Major ulcers, less common form, may be more painful and heal with scarring in 2–6 week. Herpetiform ulcers, the least common form, are numerous small (2–3 mm) and painful ulcers which may become coalescent. Uncommonly, patients may present with a mixed pattern.

ROAU of BD should be differentiated from those of recurrent oral ulcers due to other causes.

The common causes of oral ulcer are trauma, recurrent aphthous stomatitis (RAS), infections (herpes simplex, syphilis, HIV, herpangina, primer herpetic gingivostomatitis, and hand-foot-mouth disease), mucocutaneous disease (lichen planus, erythema multiforme), immunobullous disease (pemphigus), squamous cell carcinoma, cyclic neutropenia, drugs, and systemic disorders [12, 16, 18]. Systemic conditions presenting with “aphthous-like” lesions, including BD, have been shown in Table 2: oral ulcers may be a part of systemic lupus erythematosus, MAGIC syndrome, Reiter's syndrome, and Sweet's syndrome, or may be secondary to hematinic/nutritional deficiencies (iron, vitamin and B12, folic acid, Coeliac disease) and hematological diseases (cyclic neutropenia, lymphoma) [12, 15]. The ulcers of oral mucosa can be seen in inflammatory bowel disease, especially in Crohn's disease and, to a lesser extent, in ulcerative colitis.

In addition to a complete anamnesis and detailed review of systems, some laboratory tests such as Tzanck smear, polymerase-chain-reaction-based (PCR) assays, complete blood count, determination of serum B12, folate, and iron levels, and sometimes histopathologic examination may help diagnosis in cases with such lesions.

In some situation, the clinical presentation of the oral ulcers of some diseases is different from that of ROAU of BD, like those in systemic lupus erythematosus: oral ulcers seen in this disease have irregular and slitlike appearance. The lesions tend to occur on the palate and often heal with a scar. Similarly, mucocutaneous lesions of Reiter's syndrome may include red patches or superficial painless mucosal erosions. The ulcers in the inflammatory bowel diseases are more likely to manifest as other types of oral ulceration. In Crohn's

disease, the oral lesion are deep fissures, and they appear as linear ulcers.

However oral ulcers, which due to other causes, are usually indistinguishable clinically from the ROAU of BD like those in RAS. RAS is a common oral mucosal condition, characterized by recurrent bouts of one or several shallow, rounded, or ovoid, painful ulcers, that recur at intervals of a few days or up to 2-3 months [16]. The minor aphthous lesions of RAS, which are most common form, often occur in the anterior part of the mouth though they can be seen at any site of oral mucosa. Although ROAU of BD cannot be distinguished clinically from common ulcers of RAS, clinical observation suggest that patients with BD tend to have more ulcers with more frequent crops, more painful and wider, and longer duration than those with RAS [18]. The patients with BD are more frequently presented with major aphthae than the patients with RAS [19]. ROAUs in BD appear to be associated with increased tissue oedema and to have an intensely erythematous border. In addition, involvement of the soft palate and oropharynx is more common in BD than in RAS [10, 17, 18].

Most patients with RAS will not develop associated disease. However, because ROAUs of BD are the most common presenting manifestation and may precede the diagnosis of BD by 6-7 years as the only manifestation, the differential diagnosis of BD must be considered in the case of any new clinical problem appear in patients with RAS. Similarly, patients with complex aphthosis also must be monitored at intervals using clinical criteria for evolution into BD. Complex aphthosis is the term used to describe the patients who have constant presence of multiple oral ulcers, or recurrent oral and genital ulcers, without systemic manifestations of BD.

Histopathologic examination of oral ulcers in BD has a nonspecific pathology with a variable infiltrate of lymphocytes, macrophages, and neutrophils at the base of the ulcer. Leukocytoclastic and lymphocytic vasculitis may be seen if the inflammation is severe [20].

Reimer et al. showed that there are no difference between direct IF on oral aphthae in RAS compared to BD [21]. They found that, compared to nonaphthous oral lesions, oral aphthae of BD and RAS are characterized by C3 deposition in the vessel walls. IgM deposits also were detected in vessel walls in some patients in both groups.

2.2. Genital Ulcers. Genital ulcers (GU) are the second most commonly observed initial manifestation in BD which occur in about 80–90% of patients. They resemble oral aphthous ulcerations but are larger and deeper and have more irregular border [12, 13, 22, 23]. GU frequently heal by scarring.

They occur usually on the scrotum in males and on the vulva in females, which are most common in labia. In males, the shaft and glans penis may also be affected. Perineal, perianal, and groin lesions can occur in both sexes [10].

In females, vaginal and cervical lesions may be seen and may be associated with vaginal discharge. GU tend to be larger and deeper in female patients and sometimes lead to perforations. Large GU, frequently leave a scar, whereas small ulcers, especially those on the minor labia may heal

without leaving a mark [2, 10, 11, 24]. Because ulcers are occasionally asymptomatic, patient assessment should include examination of genitalia for ulcers and scarring, even when symptoms are absent.

Histopathologic feature of GU of BD similar to that of ROAU.

Genital ulcerations should be differentiated from venereal diseases such as syphilis, chancroid, and herpes simplex virus infection. Fix drug eruption, erythema multiforme, erosive lichen planus, otoimmun bullous dermatoses must be considered in the differential diagnosis. Recurrent genital ulcerations may also be seen in Munchausen syndrome, hypereosinophilic syndrome, myelodysplastic syndrome, tuberculosis cutis, and acquired immune deficiency syndrome [3, 4, 11].

2.3. Papulopustular Lesions. Papulopustular lesions or acne-like lesions may appear at any location and they are morphologically similar to adolescent acne. They are (28–96%) the most common cutaneous manifestation, and their distribution is more widespread than adolescent acne, affecting face, limbs, trunk, and buttocks [15, 22]. Diri et al. showed that papulopustular lesions are seen more frequently in patients with BD with arthritis [25].

The papulopustular lesions of Behçet's disease are located more often on the lower part of the body, while the lesions of adolescent acne are seen more frequently on the upper part. In addition, the pathogenesis of papulopustular lesions of Behçet's disease is different from those of acne vulgaris. According to some authors, papulopustular lesions of BD are a vasculitis, while acne vulgaris is a sebaceous gland disorder under hormonal factors. On the other hand, a controversy exists as to the histopathologic features of papulopustular lesions [12, 26–29]. These lesions are generally nonspecific also histopathologically as well as being clinically according to some authors. They advised that follicular lesions, showing suppurative folliculitis or perifollicular infiltration should be excluded, and only lesions with vessel-based and neutrophilic histologic findings should be considered as papulopustular lesions of BD [27].

Alpsoy et al. pointed out that the detection of nonfollicular lesions over the trunk or extremities, with the support of histopathologic and/or immunofluorescence studies, increases the specificity of these lesions [26]. Papulopustular lesions were included in the International Study Group Criteria as a result of their 70% sensitivity and 76% specificity; whereas some authors stated that papulopustular lesions exhibiting vessel-based neutrophilic reaction and follicle-based lesions are both features of Behçet's disease, and any papulopustular lesions, including follicular acneiform lesions, should be regarded as features of Behçet's disease [12, 28]. Boyvat considering this argument, pointed out that papulopustular lesions of BD which have nonspecific features may create problems in the diagnosis of Behçet's disease because they are extremely common also in the general population [12].

2.4. Erythema Nodosum-Like Lesions. The prevalence of erythema Nodosum-Like lesions was reported as 15–78% with

a higher frequency in females [2, 11, 16, 30]. The lesions are tender erythematous nodules predominantly affect the lower limbs, although they can also appear at other sites, including the upper extremities, buttocks, and less commonly on the face and neck [2, 11, 15]. Often, they have more erythema and edema around the lesions than the classic erythema nodosum [31]. The lesions do not ulcer. They heal within a few weeks and usually leave a hyperpigmentation after healing [10, 15]. Recurrence is common.

Histopathological findings of erythema Nodosum-Like lesions have been reported as leukocytoclastic vasculitis, neutrophilic vascular reaction, lymphocytic vasculitis, lymphohistiocytic septal/lobular panniculitis, granulomatous panniculitis, or acute necrotizing panniculitis [30, 32, 33]. In a study, evaluating histopathological features of the nodular lesions of BD and erythema nodosum associated with other systemic diseases, it has been found that septal panniculitis, lymphocyte-predominating infiltrate in the subcutis, absence of vasculitis, and necrosis were in favor of erythema nodosum, while neutrophil-predominated infiltrate in the subcutis was more common in BD [34]. Some authors have emphasized that early lesions show a leukocytoclastic vasculitis or a neutrophilic vascular reaction, whereas older lesions have a lymphocytic vasculitis [10, 15, 26, 27].

2.5. Superficial Thrombophlebitis. Superficial phlebitis, which is one of the characteristics of BD, appears as painful subcutaneous nodule or stringlike hardening with reddening of the overlying skin, predominantly located on the lower extremities [2, 35]. It is segmental and can present in a characteristic migratory pattern. Although it is transient, which disappears in a few days, it has a tendency to recur. Superficial thrombophlebitis has been reported to be present in 2.2–20% of Behçet patients with higher prevalence in males [2, 10, 11]. Vena saphena magna is the most affected vein.

It can be differentiated from erythema Nodosum-Like lesions, which may be similar clinically, by dermal ultrasonography [36]: erythema Nodosum-Like lesions are hyperechoic on sonography, while the lesions of superficial thrombophlebitis are hypoechoic.

It is important that, because of the relationship between superficial thrombophlebitis and deep venous thrombosis, close monitoring is required for the vascular systemic disease.

On histopathologic examination, organized thrombus is observed in the vein lumen. Fibrous thickening of the vein wall and sometimes infiltration of mononuclear cells may be seen [12].

2.6. Pathergy Test. Pathergy is the term used to describe hyperreactivity of the skin that occurs in response to any intracutaneous injection or needle prick, characterized by the formation of a sterile pustule or erythematous small papule after 24–48 hours [11]. In addition to skin pathergy test, some authors described oral pathergy test [37, 38]. The test is more strongly positive in male patients than in female [2, 39, 40].

Pathergy test is usually positive at the active phase of BD, though positivity is not associated with disease severity and

the age of onset of BD [41]. Positivity of the test varies with geographical location: in the Mediterranean and Middle/Far Eastern countries, there is a high-pathergy positivity (40–98%) [2, 10, 11, 30]. While a positive pathergy test is an important parameter in the diagnosis of BD in these countries, the diagnostic value of the test is limited by its low sensitivity in Western countries [42, 43].

There are controversies about the histopathology of the pathergy reaction. Some authors found mixed infiltration, while others reported neutrophilic infiltration with leukocytoclastic vasculitis [40, 44].

2.7. Extracutaneous Ulcers. Extracutaneous ulcers are uncommon (3%). They are 20 to 30 mm in diameter with a yellowish necrotic base. The ulcers are recurrent and occur mainly on the internal part of the thighs, in the inguinal and axillary regions, but can affect neck, inframammary and perianal areas, breast, legs, and interdigital area of the feet [2, 10, 12, 15]. Extragenital ulcers look like aphthous ulcers and commonly heal leaving a round atrophic scar. They are common in children with Behçet's disease [10, 45]. In some cases, vasculitis had been described [45].

2.8. Sweet's Syndrome-Like Lesions. Sweet's syndrome-like lesions are rarely seen in patients with Behçet disease and, if present, are usually fewer in number [46]. They are seen as painful erythematous nodules and plaques, associated with fever and leucocytosis. Sometimes, they may be pustular. Sweet Syndrome-like lesions can be seen on the face, neck, and extremities.

The lesions demonstrate neutrophilic infiltration, or perivascular and periadnexal inflammatory infiltrate of lymphocytes, histiocytes, and neutrophils in the dermis. In some cases, vasculitis may also be seen [30, 46–48].

3. Systemic Involvement in Behçet Disease

3.1. Ocular Involvement. Ocular involvement in BD is frequent (28.9–80%) and is an important cause of morbidity [49]. The highest prevalence rate of the disease has been reported from Turkey and Japan [3, 4, 14]. The disease is more frequent in males than females, and males tend to have a worse visual prognosis [2, 11]. The mean age at onset of uveitis is between 20 and 30 years in male and 30 years in female patients [50].

Ocular manifestations are usually bilateral and typically occur 2 or 3 years after the onset of the disease. It may be the presenting manifestation of the disease in 10–20% of cases [4, 50].

It was shown that the delay between the first manifestation and eye involvement may be as long as 14 years [51]. Ocular involvement carries a poor visual prognosis despite therapeutic intervention [4, 50]. The estimated risk of blindness at 5 years ranges from 15 to 25% [50].

The characteristic ocular feature is relapsing uveitis as anterior, posterior, or panuveitis, and retinal vasculitis. Anterior uveitis is frequently observed in females, whereas panuveitis is commonly encountered in males [4, 52].

Anterior uveitis with hypopyon, which has the picture of inflammatory white exudate forming a visible layer of cells in the anterior chamber is a characteristic sign of ocular BD. Hypopyon is observed only in about one-third of patients because it is transient [15, 42]. It usually disappears before the patient is seen by the physician.

The typical ocular involvement has a course with attack and remission. A single attack usually cures spontaneously without producing any sequela. When attacks become successive, they may produce sequela. The remission usually occurs so slowly that before the lesion improves, a new attack recurs which leads to severe sequelae such as synechia, cataract, and less frequently glaucoma. Successive attacks can also produce iris atrophy, atrophic retina, optic atrophy, macular degeneration, retinal veins occlusion, optic neuritis, phthisis bulbi, and loss of vision or blindness [4, 50, 53–55]. Other ocular manifestations in BD include iridocyclitis, keratitis, scleritis, episcleritis, vitritis, vitreous haemorrhage, retinal neovascularization, optic neuritis, and chorioretinal scars. However, conjunctivitis are not considered a usual feature of BD. Posterior uveitis and retinal vasculitis are the main causes for the loss of vision.

Clinical symptoms and signs include hyperemia, blurred vision, photophobia, lacrimation, floaters, periorbital, or global pain [4].

Intraocular inflammation associated with BD should be differentiated from other infectious or noninfectious causes. Uveitis may occur as a result of many conditions. A variety of infectious diseases including toxoplasmosis, herpesviruses, syphilis, tuberculosis, Lyme disease, cat scratch disease, and Whipple's disease must be ruled out by appropriate testing [4]. Development of PCR-based assays and safer methods for sampling of ocular fluids have increased the ability to diagnose infectious causes of uveitis. One of the most difficult differential diagnosis of BD is viral retinitis with anterior segment involvement. The intraocular fluids should be subjected to culture, PCR, and immunohistochemical tests for the detection of a possible viral etiology. Serologic tests for syphilis and a chest radiograph which is a useful screen for tuberculosis (and also for sarcoidosis) may be useful.

Uveitis may occur in the context of a variety of inflammatory diseases, including inflammatory bowel disease, Vogt-Koyanagi-Harada syndrome, and multiple sclerosis. Other causes of uveitis are intraocular tumors, in particular, intraocular lymphoma and reactions to medications such as cidofovir and rifabutin. Anterior uveitis and iridocyclitis in BD should also be differentiated from idiopathic uveitis, ankylosing spondylitis, Reiter syndrome, tubulointerstitial nephritis, Kawasaki disease, and sarcoidosis [4, 54].

The differential diagnosis further includes specific ocular inflammatory conditions, including Fuchs heterochromic iridocyclitis characterized by unilateral anterior uveitis with diagnostic corneal and iris changes; the “white dot syndromes” which are characterized by round white lesions involving choroid and/or retina and pars planitis characterized by a “snow bank” of inflammatory debris on the inferior pars plana.

3.2. Neurological Involvement. Neurological involvement occurs in 5–10% of patients in BD. It is an important manifestation of BD because of its severe morbidity and increased mortality. It usually appears within 5 years after the onset of the disease and is more frequent in men. Central nervous system is more frequently involved than the peripheral nervous system [56, 57]. There are two types of neurological involvement: parenchymal and Nonparenchymal.

Parenchymal brain disease is more common (approximately 80%) in BD, which mainly affects the brainstem and/or basal ganglia but spinal cord lesions and hemisphere lesions may also occur. The classic manifestation is a meningoencephalitis.

All forms of neurologic manifestations have been reported in the patients with BD including headache, seizures, brainstem syndromes, cerebellar syndromes, diencephalic dysfunction, benign intracranial hypertension, ataxia, aphasia, pseudobulbar palsy, cranial nerve palsies, hemiplegia, myelopathy, and mononeuritis multiplex. Cerebellar and sensory symptoms and signs, sphincter disturbances, and behavioural changes may also be observed. Among them, pyramidal tract signs are the most frequently observed manifestations [58–60].

Some of the symptoms such as stroke, epilepsy, brain tumor, movement disorder, acute meningeal syndrome, and optic neuropathy may also be seen less commonly.

Nonparenchymal disease includes dural sinus thrombosis, arterial vasculitis, and aseptic meningitis [56]. Venous sinus thrombosis is the most frequent vascular manifestation in Nonparenchymal disease followed by cortical cerebral veins thrombosis. Other vascular manifestations include intracranial and extracranial aneurysm. In most cases, veins are much more likely to be affected than arteries.

The most common neurologic symptom among patients with Nonparenchymal disease is headache which is caused by intracranial hypertension due to dural sinus thrombosis. Cerebral venous thrombosis may result in stroke. Stroke-like symptoms such as confusion, weakness, and dizziness may also occur.

Dural sinus thrombosis has a relatively benign prognosis in comparison to parenchymal involvement [3, 58, 59]. Involvement of parenchyma and a high protein or cell count in cerebrospinal fluid examination imply a worse prognosis in BD [15].

The differential diagnosis of neurological involvement of BD may include many diseases of the central nervous system. One of them is multiple sclerosis. Although MRI findings are distinctive in typical neurological involvement, when the predominant lesion is in the periventricular white matter, it is difficult to discriminate from the lesions of multiple sclerosis.

Other than multiple sclerosis, central nervous system infection (especially when there are cerebrospinal fluid pleocytosis and fever), cerebrovascular disease, brain tumours, and compressive myelopathy should be considered in the differential diagnosis of neuro-Behçet's disease.

Neurologic involvement of BD disease must be considered in the differential diagnosis of stroke in young adults, movement disorders, intracranial sinovenous occlusive diseases and intracranial hypertension, and other neurologic

syndromes. Imaging studies and/or cerebrospinal fluid analysis may be helpful in some cases [61–63]. MRI differentiates parenchymal lesions from the Nonparenchymal forms [63]. Diffusion-weighted imaging may be useful in the case of stroke-like episodes, revealing an increase in the diffusion coefficient in BD lesions. The clinical similarity between successive attacks may also be helpful for diagnosing BD. Cerebrospinal fluid glucose determination may be a useful parameter to differentiate central nervous system involvement in BD from other diseases, particularly infections [63, 64].

Histopathological studies, investigating central nervous system involvement, have mainly demonstrated that there is a perivascular lymphocytic infiltration with areas of necrosis in BD [64–67]. It is uncertain whether the areas of necrosis are caused by vasculitis or inflammatory infiltrate around the small vessels.

Riera-Mestre et al. have found perivascular lymphocytic infiltration with reactive astrogliosis, but no frank vasculitis in the brain biopsy specimens in their study [64]. They suggest that the absence of endothelial degeneration supports a perivascular inflammatory process rather than frank vasculitis.

3.3. Gastrointestinal Involvement. The frequency of gastrointestinal system involvement is variable in different countries [4, 15]. In Japan and Korea, the prevalence of gastrointestinal system involvement is higher (15–45%) than that in the Middle East and Mediterranean [15, 68, 69]: gastrointestinal manifestations occur in one-third of Japanese patients, while in Turkey and Israel, the prevalence is about 0–5% [2, 49]. There is no significant difference in the frequency of gastrointestinal involvement between male and female [2, 11].

Gastrointestinal system manifestations can occur throughout the gastrointestinal tract, from the esophagus to the anus. The ulcers are most commonly found in the terminal ileum, followed by the caecum and other parts of the colon [70]. The ileocaecal ulcers have a distinct tendency to perforate. They may lead to symptoms of abdominal pain, diarrhea, or constipation and proctorrhagia as well as the acute abdomen, which can be caused by perforation of ulcers [31, 71].

Gastritis, peptic ulcers, abdominal pain, dyspepsia, vomiting, and diarrhea may be due to stomach and small intestine ulcers, while dysphagia, retrosternal pain, and hematemesis are due to esophageal ulcers.

The differential diagnosis of BD from inflammatory bowel disease is sometimes difficult and challenging. The main differential diagnosis of lower intestinal lesions is with Crohn's disease. Both diseases have the same ulceration. It was shown that ulcers in BD were usually round or oval, while in Crohn's disease, they were essentially longitudinal. If there is a longitudinal ulcer in BD, the disease has focal distribution, otherwise if distribution is segmental or diffuse, it is Crohn's disease [31, 72]. In addition to ulcers, granuloma formation in intestinal lesions suggests Crohn's disease, which is not seen in BD [73]. The association of RAS with coeliac disease is well established. It has been suggested

that up to 5% of patients with RAS have gluten-sensitive enteropathy [16, 74].

3.4. Articular Involvement. Articular involvement is seen in approximately 30–70% of BD and may be the first manifestation of the disease in about 16.5% of them [2]. It affects commonly knees, ankles, wrists, and elbows [2, 11]. Articular involvement is observed in the form of arthralgia, arthritis, and synovitis. Arthralgia is mainly of inflammatory type. Joint disease, which can be symmetrical, usually mono- or oligoarticular and heals in few weeks, but may take several weeks or months to heal. It is usually transient, nonerosive, and nondeforming. Chronic or polyarticular arthritis and osteonecrosis can be seen occasionally. Ankylosing spondylitis is not seen in BD for some authors, while for others it is related to BD [3, 31]. Sacroiliitis and involvement of the spine are not among the common manifestations of BD, which can serve as differential diagnosis for Reiter's syndrome.

Articular involvement may be confused with seronegative arthropathies, rheumatoid arthritis, and psoriatic arthritis. When the joint manifestations are acute and transient, the disease resembles rheumatic fever. Chronic and polyarticular form, which is exceptional, mimics rheumatoid arthritis. However, the articular changes of rheumatoid arthritis are destructive in character [75]. Synovial fluid analysis and synovial biopsies may help diagnosis by determining the cell type which may differentiate arthritis of BD from the rheumatoid arthritis. Serological abnormalities are seen in inflammatory arthropathies. Seronegative arthropathies have mainly psoriasiform skin lesions, aortic insufficiency, frequent axial involvement and peripheral enthesopathies, and sacroiliitis.

3.5. Vascular. BD is a systemic vasculitis affecting virtually all types and sizes of vessels. The prevalence of vascular involvement is about 1.8–33% and was found higher in male patients than females [2, 4, 31].

Venous system involvement is more common than arterial system involvement. Venous involvement results in both superficial thrombophlebitis and deep venous thrombosis. Venous thrombosis affects extremities, mainly lower limbs. Large vein thrombosis is less frequent than deep vein thrombosis of limbs. It involves mainly superior and inferior vena cava, but may also affect mesenteric, portal, hepatic, splenic, renal, dural sinus, jugular, subclavian axillary, and iliac veins. Occlusion of suprahepatic veins, which is rare, causes a Budd-Chiari syndrome, leading to mortality [76, 77]. In addition to Budd-Chiari syndrome, thromboses of the superior and inferior vena cava and of dural sinuses are associated with a poor prognosis [15, 77, 78]. Hughes-Stovin syndrome should be differentiated from BD in which deep venous thrombosis, often involving the vena cava, is seen accompanied by single or multiple pulmonary arterial aneurysms.

Arterial lesions are less frequently observed in Behçet patients. Arterial involvement includes thrombosis, aneurysms, and pulse weakness and affects pulmonary, iliac, popliteal, femoral, and carotid arteries. Pulmonary arterial aneurysms,

which occur in 1% of patients, have a high mortality rate. The main symptom is haemoptysis, and these patients usually have associated thrombophlebitis and deep venous thrombosis [3].

The arterial involvement in BD resembles those of Takayasu's arteritis, including aneurysm formation and arterial occlusion. It is suggested that arterial involvement of BD may result from neutrophilic vasculitis, which targets the vasa vasorum [79]. Accordingly, on histopathological studies, it was demonstrated that the number of vasa vasorum infiltrated with neutrophils and lymphocytes was significantly increased in vasculo-Behçet's disease compared with that in Takayasu's arteritis and other inflammatory aneurysms [79].

3.6. Pulmonary Involvement. Pulmonary involvement is rare in BD (0.7–7%) [2]. It has a higher frequency in males than females [2, 11].

Pulmonary manifestations have different etiology: vasculitis, embolism, fibrosis, pleurisy, and infection. The manifestations are mainly related to vasculitis of the pulmonary arteries, veins, and septal capillaries. Pulmonary vascular involvement can lead to aneurysm formation (aortic or pulmonary artery aneurysm), thrombotic occlusion, (mainly in the vena cava), haemorrhage, pleural effusion, pulmonary infarct, and focal or diffuse pulmonary fibrosis. Aneurysms are more common than thrombosis and tend to be multiple [31]. Although venous system involvement is more common than arterial system involvement, rupture of an arterial aneurysm is a significant cause of mortality in BD. The most common and predominant symptom of pulmonary arterial aneurysm is haemoptysis.

It must be known that detection of a pulmonary aneurysm in the setting of a vasculitic illness is highly suggestive of BD, which is found rarely in other forms of vasculitis [17, 80].

3.7. Cardiac Involvement. Cardiac involvement is uncommon in BD. Multiple case reports can be found in the literature on cardiac manifestations, describing every form of cardiac involvement such as myocarditis, valvular lesions, pericarditis, ventricular aneurysms, intracardiac thrombosis, coronary vasculitis, and many others [15, 81]. Currently, it was shown that atherosclerosis is probably not increased in Behçet's disease, unlike rheumatoid arthritis and systemic lupus erythematosus [2, 3, 82].

3.8. Genitourinary System Involvement. Renal involvement is not frequent in BD and is usually transient. Sometimes they may become chronic. Hematuria, proteinuria, leukocyturia, and rarely cast may be seen in the patients with renal involvement of BD. Urethritis is not a feature of BD that may facilitate to distinguish it from Reiter's syndrome [17, 31].

Orchitis and epididymitis can also occur in patients with BD [31]. They have a low tendency for recurrence. The attack of epididymitis may be a painful or a painless swelling, but the attack of orchitis, which affects both testicles, is painful. Attacks last for few days or weeks.

References

- [1] H. Behçet, "Über rezidivierende Aphthosen durch ein virus verursachte Geschwüre am Mund, am Auge und an den Genitalien," *Dermatologische Wochenschrift*, vol. 105, pp. 1152–1157, 1937.
- [2] U. Tursen, A. Gurler, and A. Boyvat, "Evaluation of clinical findings according to sex in 2313 Turkish patients with Behçet's disease," *International Journal of Dermatology*, vol. 42, no. 5, pp. 346–351, 2003.
- [3] S. Yurdakul and H. Yazici, "Behçet's syndrome," *Best Practice and Research: Clinical Rheumatology*, vol. 22, no. 5, pp. 793–809, 2008.
- [4] C. Evereklioglu, "Current concepts in the etiology and treatment of Behçet disease," *Survey of Ophthalmology*, vol. 50, no. 4, pp. 297–350, 2005.
- [5] A. Hamdan, W. Mansour, I. Uthman, A. F. Masri, F. Nasr, and T. Arayssi, "Behçet's disease in Lebanon: clinical profile, severity and two-decade comparison," *Clinical Rheumatology*, vol. 25, no. 3, pp. 364–367, 2006.
- [6] Z. S. Al-Rawi, K. E. Sharquie, and S. J. Khalifa, "Behçet's disease in Iraqi patients," *Annals of the Rheumatic Diseases*, vol. 45, no. 12, pp. 987–990, 1986.
- [7] M. M. Al-Aboosi, M. A. L. Salem, A. Saadeh et al., "Behçet's disease: clinical study of Jordanian patients," *International Journal of Dermatology*, vol. 35, no. 9, pp. 623–625, 1996.
- [8] A. N. Al-Dalaan, S. R. Al Balaa, K. El Ramahi et al., "Behçet's disease in Saudi Arabia," *Journal of Rheumatology*, vol. 21, no. 4, pp. 658–661, 1994.
- [9] International Study Group for Behçet's Disease, "Criteria for diagnosis of Behçet's disease," *The Lancet*, vol. 335, no. 8697, pp. 1078–1080, 1990.
- [10] A. Gurler, A. Boyvat, and U. Tursen, "Clinical manifestations of Behçet's disease: an analysis of 2147 patients," *Yonsei Medical Journal*, vol. 38, no. 6, pp. 423–427, 1997.
- [11] E. Alpsoy, C. Zouboulis, and G. E. Ehrlich, "Mucocutaneous lesions of Behçet's disease," *Yonsei Medical Journal*, vol. 48, no. 4, pp. 573–585, 2007.
- [12] A. Boyvat, "Mucocutaneous manifestations of Behçet's disease," *Turkderm Deri Hastaliklari ve Frengi Arsivi*, vol. 43, supplement 2, pp. 42–47, 2009.
- [13] M. Önder and M. A. Güreş, "The multiple faces of Behçet's disease and its aetiological factors," *Journal of the European Academy of Dermatology and Venereology*, vol. 15, no. 2, pp. 126–136, 2001.
- [14] G. Azizlerli, A. A. Köse, R. Sarica et al., "Prevalence of Behçet's disease in Istanbul, Turkey," *International Journal of Dermatology*, vol. 42, no. 10, pp. 803–806, 2003.
- [15] D. Mendes, M. Correia, M. Barbedo et al., "Behçet's disease—a contemporary review," *Journal of Autoimmunity*, vol. 32, no. 3–4, pp. 178–188, 2009.
- [16] E. A. Field and R. B. Allan, "Review article: oral ulceration—etiopathogenesis, clinical diagnosis and management in the gastrointestinal clinic," *Alimentary Pharmacology and Therapeutics*, vol. 18, no. 10, pp. 949–962, 2003.
- [17] M. T. Keogan, "Clinical immunology review series: an approach to the patient with recurrent orogenital ulceration, including Behçet's syndrome," *Clinical and Experimental Immunology*, vol. 156, no. 1, pp. 1–11, 2009.
- [18] D. M. G. Main and M. A. Chamberlain, "Clinical differentiation of oral ulceration in Behçet's disease," *British Journal of Rheumatology*, vol. 31, no. 11, pp. 767–770, 1992.
- [19] I. Krause, Y. Rosen, I. Kaplan et al., "Recurrent aphthous stomatitis in Behçet's disease: clinical features and correlation

- with systemic disease expression and severity," *Journal of Oral Pathology and Medicine*, vol. 28, no. 5, pp. 193–196, 1999.
- [20] S. I. Chun, W. P. Su, and S. Lee, "Histopathologic study of cutaneous lesions in Behçet's syndrome," *Journal of Dermatology*, vol. 17, no. 6, pp. 333–341, 1990.
 - [21] G. Reimer, L. Luckner, and O. P. Hornstein, "Direct immunofluorescence in recurrent aphthous ulcers and Behçet's disease," *Dermatologica*, vol. 167, no. 6, pp. 293–298, 1983.
 - [22] E. Alpsoy, L. Donmez, A. Bacanlı, C. Apaydin, and B. Butun, "Review of the chronology of clinical manifestations in 60 patients with Behçet's disease," *Dermatology*, vol. 207, no. 4, pp. 354–356, 2003.
 - [23] J. V. Ghate and J. L. Jorizzo, "Behçet's disease and complex aphthosis," *Journal of the American Academy of Dermatology*, vol. 40, no. 1, pp. 1–18, 1999.
 - [24] M. C. Mat, N. Goksugur, B. Engin, S. Yurdakul, and H. Yazici, "The frequency of scarring after genital ulcers in Behçet's syndrome: a prospective study," *International Journal of Dermatology*, vol. 45, no. 5, pp. 554–556, 2006.
 - [25] E. Diri, C. Mat, V. Hamuryudan, S. Yurdakul, N. Hizli, and H. Yazici, "Papulopustular skin lesions are seen more frequently in patients with Behçet's syndrome who have arthritis: a controlled and masked study," *Annals of the Rheumatic Diseases*, vol. 60, no. 11, pp. 1074–1076, 2001.
 - [26] E. Alpsoy, S. Uzun, A. Akman, M. Alpaslan Acar, H. R. Memişoğlu, and E. Başarant, "Histological and immunofluorescence findings of non-follicular papulopustular lesions in patients with Behçet's disease," *Journal of the European Academy of Dermatology and Venereology*, vol. 17, no. 5, pp. 521–524, 2003.
 - [27] J. L. Jorizzo, J. L. Abernethy, W. L. White et al., "Mucocutaneous criteria for the diagnosis of Behçet's disease: an analysis of clinicopathologic data from multiple international centers," *Journal of the American Academy of Dermatology*, vol. 32, no. 6, pp. 968–976, 1995.
 - [28] T. Ergun, O. Gürbüz, G. Doğusoy, C. Mat, and H. Yazici, "Histopathologic features of the spontaneous pustular lesions of Behçet's syndrome," *International Journal of Dermatology*, vol. 37, no. 3, pp. 194–196, 1998.
 - [29] S. Kienbaum, C. H. C. Zouboulis, M. Waibel et al., "Papulopustular skin lesions in Adamantiades-Behçet's disease show a similar histopathological pattern as the classical mucocutaneous manifestations," in *Behçet's Disease: Proceedings of the 6th International Conference on Behçet's Disease*, P. Godeau and B. Wechsler, Eds., pp. 331–336, Elsevier Science, Amsterdam, The Netherlands, 1993.
 - [30] E. S. Lee, D. Bang, and S. Lee, "Dermatologic Manifestation of Behçet's Disease," *Yonsei Medical Journal*, vol. 38, no. 6, pp. 380–389, 1997.
 - [31] F. Davatchi, F. Shahram, C. Chams-Davatchi et al., "Behçet's disease: from east to west," *Clinical Rheumatology*, vol. 29, no. 8, pp. 823–833, 2010.
 - [32] B. Kim and P. E. LeBoit, "Histopathologic features of erythema nodosum-like lesions in Behçet disease: a comparison with erythema nodosum focusing on the role of vasculitis," *American Journal of Dermatopathology*, vol. 22, no. 5, pp. 379–390, 2000.
 - [33] S. I. Chun, W. P. D. Su, S. Lee, and R. S. Rogers, "Erythema nodosum-like lesions in Behçet's syndrome: a histopathologic study of 30 cases," *Journal of Cutaneous Pathology*, vol. 16, no. 5, pp. 259–265, 1989.
 - [34] C. Demirkesen, N. Tüzüner, C. Mat et al., "Clinicopathologic evaluation of nodular cutaneous lesions of Behçet syndrome," *American Journal of Clinical Pathology*, vol. 116, no. 3, pp. 341–346, 2001.
 - [35] Y. Yazici, S. Yurdakul, and H. Yazici, "Behçet's syndrome," *Current Rheumatology Reports*, vol. 12, no. 6, pp. 429–435, 2010.
 - [36] H. Yazici, "The lumps and bumps of Behçet's syndrome," *Autoimmunity Reviews*, vol. 3, supplement 1, pp. S53–S54, 2004.
 - [37] U. Gül and M. Gönül, "Oral and genital pathergy in Behçet's disease," *Dermatology*, vol. 215, no. 1, pp. 80–81, 2007.
 - [38] K. E. Sharquie, A. Al-Araji, and A. Hatem, "Oral pathergy test in Behçet's disease," *British Journal of Dermatology*, vol. 146, no. 1, pp. 168–169, 2002.
 - [39] H. Yazici, Y. Tuzun, and A. B. Tanman, "Male patients with Behçet's syndrome have stronger pathergy reactions," *Clinical and Experimental Rheumatology*, vol. 3, no. 2, pp. 137–141, 1985.
 - [40] J. L. Jorizzo, A. R. Solomon, and T. Cavallo, "Behçet's syndrome. Immunopathologic and histopathologic assessment of pathergy lesions is useful in diagnosis and follow-up," *Archives of Pathology and Laboratory Medicine*, vol. 109, no. 8, pp. 747–751, 1985.
 - [41] H. K. Chang and K. S. Cheon, "The clinical significance of a pathergy reaction in patients with Behçet's disease," *Journal of Korean Medical Science*, vol. 17, no. 3, pp. 371–374, 2002.
 - [42] S. E. Marshall, "Behçet's disease," *Best Practice and Research: Clinical Rheumatology*, vol. 18, no. 3, pp. 291–311, 2004.
 - [43] P. G. Davies, J. N. Fordham, and J. R. Kirwan, "The pathergy test and Behçet's syndrome in Britain," *Annals of the Rheumatic Diseases*, vol. 43, no. 1, pp. 70–73, 1984.
 - [44] S. Haim, J. D. Sobel, R. Friedman Birnbaum, and C. Lichtig, "Histological and direct immunofluorescence study of cutaneous hyperreactivity in Behçet's disease," *British Journal of Dermatology*, vol. 95, no. 6, pp. 631–636, 1976.
 - [45] G. Azizlerli, G. Ozarmagan, C. Ovul, R. Sarica, and S. O. Mustafa, "A new kind of skin lesion in Behçet's disease: extragenital ulcerations," *Acta Dermato-Venereologica*, vol. 72, no. 4, p. 286, 1992.
 - [46] S. K. Karadogan, E. B. Başkan, G. Alkan et al., "Generalized sweet syndrome lesions associated with behet disease: a true association or simply co-morbidity?" *American Journal of Clinical Dermatology*, vol. 10, no. 5, pp. 331–335, 2009.
 - [47] M. S. Lee and R. S. C. Barnetson, "Sweet's syndrome associated with Behçet's disease," *Australasian Journal of Dermatology*, vol. 37, no. 2, pp. 99–101, 1996.
 - [48] O. Oğuz, S. Serdaroglu, Y. Tüzün, N. Erdogan, H. Yazici, and H. Savaskan, "Acute febrile neutrophilic dermatosis (Sweet's syndrome) associated with Behçet's disease," *International Journal of Dermatology*, vol. 31, no. 9, pp. 645–646, 1992.
 - [49] L. Y. Wang, D. B. Zhao, J. Gu, and S. M. Dai, "Clinical characteristics of Behçet's disease in China," *Rheumatology International*, vol. 30, no. 9, pp. 1191–1196, 2010.
 - [50] D. Saadoun, N. Cassoux, B. Wechsler et al., "Ocular manifestations of Behçet's disease," *Revue de Medecine Interne*, vol. 31, no. 8, pp. 545–550, 2010.
 - [51] D. H. Verity, J. E. Marr, S. Ohno, G. R. Wallace, and M. R. Stanford, "Behçet's disease, the Silk Road and HLA-B51: historical and geographical perspectives," *Tissue Antigens*, vol. 54, no. 3, pp. 213–220, 1999.
 - [52] I. Tugal-Tutkun, S. Onal, R. Altan-Yaycioglu, H. Huseyin Altunbas, and M. Urgancioglu, "Uveitis in Behçet disease: an analysis of 880 patients," *American Journal of Ophthalmology*, vol. 138, no. 3, pp. 373–380, 2004.

- [53] U. Elgin, N. Berker, and A. Batman, "Incidence of secondary glaucoma in Behçet disease," *Journal of Glaucoma*, vol. 13, no. 6, pp. 441–444, 2004.
- [54] U. Kurumety, A. A. Okada, M. Usui, and N. A. Rao, "Behçet's syndrome," in *Ophthalmology*, M. Yanoff and J. S. Duker, Eds., pp. 1–4, Mosby, London, UK, 1999.
- [55] N. Kitaichi, A. Miyazaki, M. R. Stanford, H. Chams, D. Iwata, and S. Ohno, "Ocular features of Behçet's disease: an international collaborative study," *British Journal of Ophthalmology*, vol. 91, no. 12, pp. 1579–1582, 2007.
- [56] G. Akman-Demir, P. Serdaroglu, B. Taşçi, and Neuro-Behçet Study Group, "Clinical patterns of neurological involvement in Behçet's disease: evaluation of 200 patients," *Brain*, vol. 122, no. 11, pp. 2171–2181, 1999.
- [57] J. M. S. Pearce, "Neurological symptoms of Adamantiades-Behçet's syndrome," *Journal of Neurology, Neurosurgery and Psychiatry*, vol. 77, no. 8, pp. 956–957, 2006.
- [58] S. Hirohata and H. Kikuchi, "Behçet's disease," *Arthritis Research and Therapy*, vol. 5, no. 3, pp. 139–146, 2003.
- [59] P. Serdaroglu, "Behçet's disease and the nervous system," *Journal of Neurology*, vol. 245, no. 4, pp. 197–205, 1998.
- [60] D. Kidd, A. Steuer, A. M. Denman, and P. Rudge, "Neurological complications in Behçet's syndrome," *Brain*, vol. 122, no. 11, pp. 2183–2194, 1999.
- [61] P. Brissaud, L. Laroche, A. de Gramont, and M. Krulik, "Digital angiography for the diagnosis of dural sinus thrombosis in Behçet's disease," *Arthritis and Rheumatism*, vol. 28, no. 3, pp. 359–360, 1985.
- [62] K. M. El-Ramahi and M. Z. Al-Kawi, "Papilloedema in Behçet's disease: value of MRI in diagnosis of dural sinus thrombosis," *Journal of Neurology Neurosurgery and Psychiatry*, vol. 54, no. 9, pp. 826–829, 1991.
- [63] G. Akman-Demir, "Behçet hastalığında nörolojik tutulum," *Turkderm*, vol. 43, supplement 2, pp. 61–64, 2009.
- [64] A. Riera-Mestre, S. Martínez-Yelamos, A. Martínez-Yelamos, I. Ferrer, R. Pujol, and A. Vidaller, "Clinicopathologic features and outcomes of neuro-Behçet disease in Spain: a study of 20 patients," *European Journal of Internal Medicine*, vol. 21, no. 6, pp. 536–541, 2010.
- [65] M. G. Hadfield, F. Aydin, H. R. Lippman, W. S. Kubal, and K. M. Sanders, "Neuro-Behçet's disease," *Clinical Neuropathology*, vol. 15, no. 5, pp. 249–255, 1996.
- [66] S. Lakhnpal, K. Tani, and J. T. Lie, "Pathologic features of Behçet's syndrome: a review of Japanese autopsy registry data," *Human Pathology*, vol. 16, no. 8, pp. 790–795, 1985.
- [67] Y. Arai, S. Kohno, Y. Takahashi, Y. Miyajima, and Y. Tsutusi, "Autopsy case of neuro-Behçet's disease with multifocal neutrophilic perivascular inflammation," *Neuropathology*, vol. 26, no. 6, pp. 579–585, 2006.
- [68] T. Sakane, M. Takeno, N. Suzuki, and G. Inaba, "Behçet's disease," *The New England Journal of Medicine*, vol. 341, no. 17, pp. 1284–1291, 1999.
- [69] S. Yurdakul, N. Tüzüner, I. Yurdakul, V. Hamuryudan, and H. Yazici, "Gastrointestinal involvement in Behçet's syndrome: a controlled study," *Annals of the Rheumatic Diseases*, vol. 55, no. 3, pp. 208–210, 1996.
- [70] U. Korman, M. Cantasdemir, S. Kurugoglu et al., "Enteroclysis findings of intestinal Behçet disease: a comparative study with Crohn disease," *Abdominal Imaging*, vol. 28, no. 3, pp. 308–312, 2003.
- [71] F. Davatchi, F. Shahram, C. Chams, H. Chams, and A. Nadji, "Behçet's disease," *Acta Medica Iranica*, vol. 43, no. 4, pp. 233–242, 2005.
- [72] C. R. Lee, W. H. Kim, Y. S. Cho et al., "Differentiation of intestinal Behçet's Disease and Crohn's disease by colonoscopic findings," in *Behçet's Disease*, D. Bang, E. Lee, and S. Lee, Eds., p. 384, Design Mecca Publishing, Seoul, South Korea, 2000.
- [73] B. E. Sands, "From symptom to diagnosis: clinical distinctions among various forms of intestinal inflammation," *Gastroenterology*, vol. 126, no. 6, pp. 1518–1532, 2004.
- [74] M. M. Ferguson, D. Wray, and H. A. Carmichael, "Coeliac disease associated with recurrent aphthae," *Gut*, vol. 21, no. 3, pp. 223–226, 1980.
- [75] R. Tunes and M. Santiago, "Behçet's syndrome: literature review," *Current Rheumatology Reviews*, vol. 5, no. 1, pp. 64–82, 2009.
- [76] Y. Bayraktar, E. Özaslan, and D. H. Van Thiel, "Gastrointestinal manifestations of Behçet's disease," *Journal of Clinical Gastroenterology*, vol. 30, no. 2, pp. 144–154, 2000.
- [77] I. B. Ghorbel, R. Ennaifer, M. Lamoum, M. Khanfir, M. Miled, and M. H. Houman, "Budd-Chiari syndrome associated with Behçet's disease," *Gastroenterologie Clinique et Biologique*, vol. 32, no. 3, pp. 316–320, 2008.
- [78] V. Hamuryudan, T. Er, E. Seyahi et al., "Pulmonary artery aneurysms in Behçet syndrome," *American Journal of Medicine*, vol. 117, no. 11, pp. 867–870, 2004.
- [79] M. Kobayashi, M. Ito, A. Nakagawa et al., "Neutrophil and endothelial cell activation in the vasa vasorum in vasculo-Behçet disease," *Histopathology*, vol. 36, no. 4, pp. 362–371, 2000.
- [80] M. Yamato, J. W. Lecky, K. Hiramatsu, and E. Kohda, "Takayasu arteritis: radiographic and angiographic findings in 59 patients," *Radiology*, vol. 161, no. 2, pp. 329–334, 1986.
- [81] C. Gürgün, E. Ercan, C. Ceyhan et al., "Cardiovascular involvement in Behçet's disease," *Japanese Heart Journal*, vol. 43, no. 4, pp. 389–398, 2002.
- [82] I. Krause and A. Weinberger, "Behçet's disease," *Current Opinion in Rheumatology*, vol. 20, no. 1, pp. 82–87, 2008.

Review Article

Pathologic Features of Behçet's Disease in the Tubular Gut

Tuba Kara and Duygu Düşmez Apa

Department of Pathology, School of Medicine, Mersin University, 33010 Mersin, Turkey

Correspondence should be addressed to Tuba Kara, karabacaktuba@hotmail.com

Received 13 July 2011; Accepted 4 September 2011

Academic Editor: Ümit Tursen

Copyright © 2012 T. Kara and D. Düşmez Apa. This is an open access article distributed under the Creative Commons Attribution License, which permits unrestricted use, distribution, and reproduction in any medium, provided the original work is properly cited.

Behçet's disease (BD) is a vasculitic disorder of relapsing acute inflammation characterized by recurrent oral ulcers, genital ulcers, uveitis, and skin lesions. The disease also affects other organs, including joints, the nervous system, blood vessels, and gastrointestinal (GI) system may also be involved and the lower GI tract is the mostly involved part, leading to severe morbidity. The frequency of GI involvement in BD varies among different ethnic groups. Although 50–60% of Japanese patients have GI disease, these manifestations are rare in patients from Mediterranean countries. The gastrointestinal manifestations of BD usually appear 4.5–6 years after the onset of the oral ulcers. The intestinal lesions are usually resistant to medical treatment and recur after surgery. The elementary lesion is aphthous ulcer. Deep, round or oval ulcers with a punched-out appearance tend to perforate easily, so that many patients require urgent operation.

1. Introduction

Behçet's Disease (BD) is a chronic rheumatic disease, in which unpredictable inflammatory episodes of orogenital and ocular inflammation (or ulceration) are induced by the body's overreactive immune system, was first reported in 1937 by Hulusi Behçet.

Patients with incomplete form of Behçet's syndrome without ocular involvement, according to Morita et al., had been well described in the Japanese population [1]. Countries with a high prevalence of BD cluster along the ancient silk road from Eastern Asia to the Mediterranean Basin.

Young adults between the second and fourth decades of life are mainly affected [2]. In children, this type of BD occurs very rarely, usually as the perianal aphthous lesions that appear to be a specific feature of childhood BD [3].

Behçet's disease is more common and more severe in men than in women in the ancient Silk Road countries, whereas in Western Europe and the USA, it is equivalent between the sexes or more common in women [2]. Populations has yielded interesting epidemiological findings: Turkish individuals who have emigrated to Germany have a significantly lower risk of disease than individuals of Turkish origin living in Turkey, although their risk remains higher than that of the native German population.

The most plausible environmental trigger is an infectious agent, for that reason evidence of viral infection has been sought. Increased rates of anti-Saccharomyces cerevisiae antibodies (ASCAs); which are recently proposed serologic markers of disease and commonly associated with Crohn's disease (CD), were previously reported by several studies in BD [4]. However these antibodies are present in 44% of BD patients who have intestinal involvement of the disease, compared with 3% in patients without gastrointestinal symptoms [5]. Alternatively, BD may be primarily autoimmune in origin [4]. Various genetic markers have been identified, especially regarding tumor necrosis factor- α (TNF- α) and various proinflammatory cytokine polymorphisms. Recent reports have focused on the TNF- ∞ gene, which is closely linked to the HLA-B51 gene, in view of the major role played by this proinflammatory cytokine in BD. In the Turkish population, the TNF- ∞ 1031C allele was associated with susceptibility to Behçet's disease [5].

Pathologically the disease is characterized by vasculitis targeting the vasa vasorum and other small blood vessels, which is usually lymphocytic and affects veins more than arteries, although occasionally there may be more necrotizing inflammation with leucocytoclasia. Fibrinoid necrosis may be present in involved veins and venules [6]. There is intense inflammation around the vasa vasorum, resulting in

destruction of the media and fibrous thickening of the intima and adventitia. Pseudoaneurysms are the most common arterial manifestations, mainly involving the aorta, the pulmonary, and femoral arteries [2]. While thrombophlebitis of the superficial and deep veins is common in BD, thrombosis and aneurysms of the large arteries in the abdominal cavity are rare but lead to death [7].

Diagnostic criteria of BD are defined by the 1990 International Study Group for BD. Recurrent oral ulceration must be present along with two of the followings: genital ulcerations, typical eye lesions, typical skin lesions, or positive pathergy test [2–5].

2. Gastrointestinal Manifestations of Behçet's Disease

The gastrointestinal manifestations of BD usually appear 4.5–6 years after the onset of the oral ulcers [3]. The most frequently affected site in GI system is the ileocecal region, with extension into the ascending colon. Common clinical symptoms include abdominal pain, diarrhea, and bleeding, similar to those of inflammatory bowel disease [8]. The frequencies of GI involvement vary among different ethnic groups. In Japan and Korea, the prevalence of GI involvement is higher (50–60%), whereas in Turkey and Israel the prevalence is much lower (0–5%) [9, 10]. In the series of 2313 BD patients of Tursen et al. GI involvement was found in 31 patients (1.4%) [11]. Intestinal involvement in BD is rare but important because it is one of the most common causes of fatality, and severe morbidity during the course of the disease [9]. Intestinal BD can be diagnosed if a patient shows typical ulcer in the small or large intestine, and if systemic manifestations meet the diagnostic criteria of BD [12]. The genetic and environmental factors influence the frequencies, but the series so far reported included only small numbers of cases and were not standardized [13].

GI symptoms are often caused by nonspecific ulcers. While all patients develop oral lesions, it is the presenting manifestation in about 70% of patients [2]. However, these lesions are not pathognomonic of BD and can be seen in a variety of other clinical conditions such as anemia, avitaminosis, viral infections, inflammatory bowel disease, and Reiter syndrome. The oral ulcers of BD are aphthous or herpetiform, and occur at least three times a year in the absence of other clinical explanations for the ulcers [3]. The lesions are punched-out ulcers with rolled or overhanging edges and a necrotic base, surrounded by an erythematous rim. They are generally painful and heal with little scarring, with or without treatment [2]. Moreover, the recurrent oral ulcerations of BD tend to be multiple and usually involve the soft palate and oropharynx [3]. Smoking may decrease the severity of ulceration in BD. Histologically, there is vasculitis with an infiltration of monocytes and lymphocytes early in the disease and neutrophils in older lesions. Additional findings are fibrinoid necrosis, endothelial swelling, and a perivascular infiltrate in both early and late lesions [2].

Esophageal involvement is uncommon. However, upper GI involvement may be underestimated because endoscopic

examination is not performed routinely in BD and there are few clinical trials investigating the upper GI tract in BD [14]. Since the first case of esophageal ulceration of this syndrome was presented by Brodie and Ochsner in 1973, to date, less than 50 cases of Behçet's patients with esophageal ulcers have been reported worldwide [15]. Houman et al. studied 23 patients with BD (four with upper GI symptoms) and found endoscopic, manometric, and/or microscopic abnormalities in 14 patients; histopathologic abnormalities were found in only five patients. They concluded that the prevalence of esophageal involvement in BD was high but these findings were not confirmed by other studies [14]. It usually involves the middle part of the esophagus, causing substernal pain, dysphagia, and occasionally hematemesis, although diffuse esophagitis and stenosis have also been reported [2, 15]. The esophageal ulcerations in BD can be single or multiple, and are often associated with ulcers in other parts of the gastrointestinal tract. Esophageal lesions reported to occur in patients with BD are (1) linear, oval, or round ulcerations similar to those that are present in the mouth, (2) ulcers or fistula that communicate with adjacent organs such as trachea, (3) luminal strictures, a pseudomembranous esophagitis, and (4) "downhill," or classical, esophageal varices associated with either superior vena caval obstruction or portal hypertension due to portal vein thrombosis [3]. In addition, serious complications such as stricture, bleeding, or perforations have been rarely described [15]. Histology is nonspecific, showing lymphocytic or neutrophilic infiltration rather than vasculitis. The lesions may be resistant to treatment with a proton pump inhibitor but resolve with corticosteroids. Since BD is treated with immunosuppressive agents, viral, or candida esophagitis should be excluded [2].

The stomach is the least frequently involved part of the GI tract. An exception is the surprisingly high number of Taiwanese patients with BD (45%) who have gastric or duodenal ulcers [2]. Ning-Seng et al. found a close relationship between A2/B46/Cw1 (or A11/B46/Cw1) genotype and the development of gastric/duodenal ulcers [16]. Aphthous ulcers are the most common finding however there may be pyloric stenosis due to edematous hypertrophy of the pyloric ring or a Dieulafoy's ulcer [2]. Two studies assessing the frequency of *Helicobacter pylori* (*H. pylori*) infection in Turkish patients with BD have been reported with an urease positivity rate of 65% in the first and 85% in the second report and the presence of *H. pylori* correlated with the disease activity, manifested as the presence of gastrointestinal complaints or endoscopic findings [3]. In their study, Çakmak et al. suggest that the prevalence of upper GI abnormalities in BD is high and may occur in asymptomatic patients, but that abnormalities are not specific for BD. Therefore, routine endoscopy and screening for *H. pylori* infection may not be necessary in asymptomatic patients [17]. In one report, treatment of *H. pylori* diminished the oral and genital ulcers. Furthermore gastric pathogen *H. pylori* produces heat shock proteins which is thought to play a role in the etiopathogenesis of BD and may cause ulcers in the GI tract [18].

The intestinal lesions of BD occur in two forms: mucosal inflammation and ischemia/infarction. The clinical presentation of intestinal BD is similar to that of CD, which shares

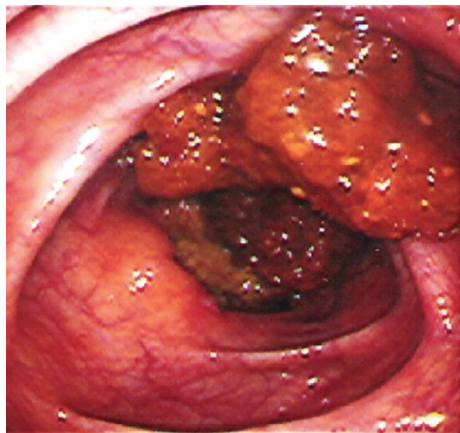


FIGURE 1: Endoscopically detected pseudopolyps in small intestine mucosa (with permission of Dr. O Sezgin).

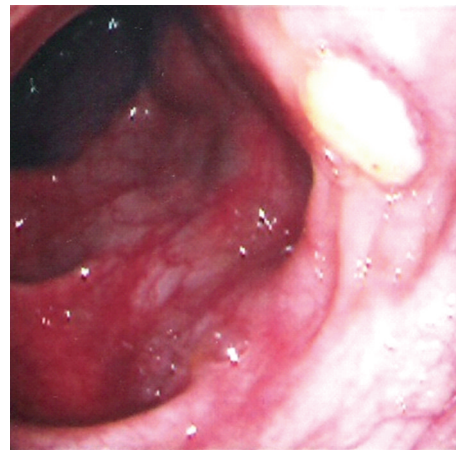


FIGURE 2: Endoscopically detected ulcers in small intestine mucosa (with permission of Dr. O Sezgin).

many extraintestinal features such as oral lesions, uveitis, and arthritis. The other stigmata of BD may appear later than the gastrointestinal features. Thus, in areas of the world where BD is common ileocolitis should be followed closely for the other major stigma of BD and should be assumed to be a manifestation of idiopathic inflammatory bowel disease [3].

The small intestine is the most frequently involved extraoral part of the gastrointestinal tract in cases of BD. The lesions are most commonly found in the terminal ileum, particularly in the area of lymphoid aggregates and Peyer's patches, and the cecum, and less frequently in the colon. Rectal and anal involvement is quite rare. Intestinal lesions are located on the antimesenteric side [19]. Ileocecal involvement in cases of BD is common in Japan and Turkey, while colonic involvement is the usual pattern in Europe and North America [3]. Isolated involvement of the ileum is not uncommon in BD. Ileal visualization should be performed at colonoscopic examination in clinical practice to document the intestinal involvement. Most of the patients with BD have inflammation in the ileum, even in the absence of visible lesions [13]. The most common colonoscopic findings are localized single or multiple ulcers in the ileocecal region, with only 4% having a diffuse distribution of lesions (Figures 1, and 2). The ulcers may be aphthous or, alternatively, deep and round with a punched-out appearance. They are usually localized but multiple in number and may resolve with medical therapy. Longitudinal ulcers are rare. Fissuring and linear ulcers up to 5 cm long may also be present. Enlarging or newly formed ulcers coexist with healed ulcers. They have a tendency to irregularly undermine surrounding tissues. Edema-like swelling with crater formation around the ulcer margins produces a characteristic "collar-stud" appearance [20]. Adjacent to larger ulcers there are often smaller aphtoid ulcers. BD is particularly characterized by adjacent macroscopically normal-appearing mucosa [6]. Multiple superficial ulcers located predominantly in the terminal ileum in Turkish patients differ from the single, large, deep ulcers with distinct borders described in the Far East. By the way, intestinal perforations may occur more commonly in Far

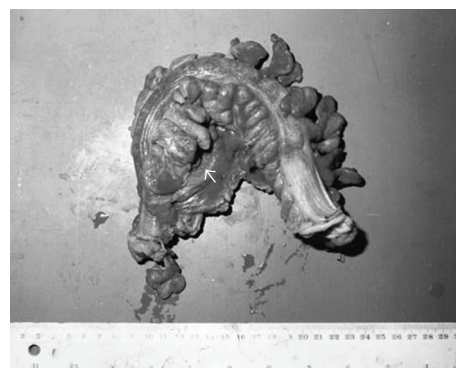

FIGURE 3: Macroscopic specimen showing hemorrhagic areas on the serosal surface and perforation (arrow) (with permission of Dr. DS Arici).

East patients than West [12, 19, 21] (Figure 3) [22]. The exact perforation mechanism in intestinal BD is not clear, but there are several hypotheses. First, typical large, discrete, and excavated ulcers penetrate, resulting in perforation. Second, bowel dilatation may lead to perforation. Third, long-term steroid use may be associated with the development of bowel perforation. J. Chou et al. reported a series of 22 patients with multiple intestinal perforations [23].

The colonic ulcers in BD have been classified as volcano-type, geographic, and aphthous. Volcano-type ulcers were defined as well-demarcated deeply penetrating ulcers with nodular margins, converging folds, or pseudopolyps. Geographic-type ulcers were defined as shallow ulcers with sharp edges, while aphthous-type ulcers were small, punched-out shallow ulcers. Volcano-type ulcers had a less favorable response to medical treatment, more frequent requirement for surgery, and more frequent recurrences than the other two types [2]. Histologically, vasculitis of the small veins and venules is common in cases of intestinal BD. It is characterized by a lymphocytic infiltrate (Figures 4, and 5) [22]. However, chronic nonspecific (sometimes transmural

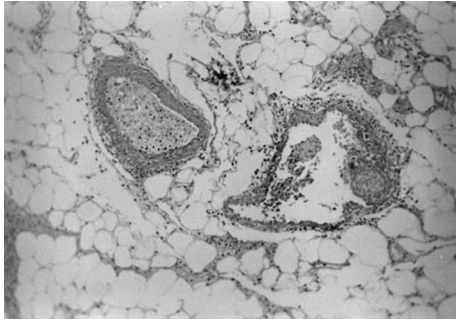


FIGURE 4: Histopathologic examination showed nonspecific inflammatory cell infiltration surrounding the vessels (HE $\times 25$) (with permission of Dr. DS Arici).

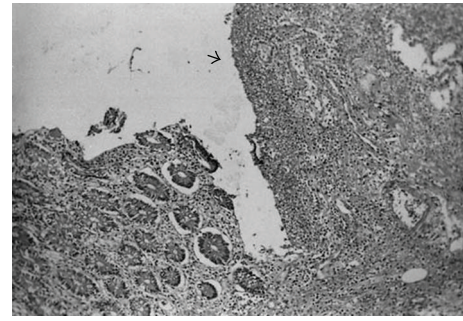


FIGURE 5: Mucosal ulceration (H&E $\times 10$) (with permission of Dr. DS Arici).

and granulomatous) inflammation with a normal intervening mucosal area may make it difficult to distinguish BD from CD. Focal colitis has been documented in colorectal biopsies obtained from patients with BD but without visual or clinical evidence of rectal involvement demonstrable by either endoscopic or radiologic examinations.

The abdominal complaints that lead to surgical intervention are abdominal pain (92%), an abdominal mass (21%), and/or melena (17%) [3]. Histopathologically, Behçet's ulcers contain nonspecific chronic inflammation, and the submucosal connective tissue appears disrupted. Granulomas are absent. The mucosa around the ulcers is usually normal in appearance [20]. The presence of focal ulcers, fistulae, and strictures and the ileocecal location may mimic CD. Since the histologic features are nonspecific, one must rely on the clinician to suggest the diagnosis. Just like the case reported by Jarrahnnejad et al., the patient can be misdiagnosed as having ulcerative colitis until pathological diagnosis of vasculitis is determined [20, 24]. However, Kim et al. suggest that inflammatory bowel diseases and Behçet's disease may be closely related and part of a spectrum of disease rather than distinct disease entities [25].

There may also be perienteric infiltration, mild lymphadenopathy, mesenteric vascular engorgement, mild splenomegaly, and minimal ascites. Complications of bowel perforation and peritonitis occur more commonly in patients with a thickened bowel wall and severe perienteric infiltration rather than those with polypoid lesions. Although many patients with BD have abdominal pain similar to appendicitis, the distinction can often be made with CT scanning. MRI also demonstrates bowel wall thickening and increased enhancement as well as extraluminal manifestations such as mesenteric infiltration around the involved bowel. Indium-111-labeled leukocytes can demonstrate localization in an area of inflammation [2].

2.1. Pancreas. A patient with BD can develop features consistent with either acute or chronic pancreatitis. Other etiologic factors for pancreatitis such as gallstone, alcohol, trauma, hyperlipidemia, and an infectious disease process should be ruled out before accepting the case as being related to BD. Biochemical evidence of pancreatitis can occur in

the absence of either sonographic or computer tomographic findings and is a relatively common occurrence in cases of BD [2]. Acute pancreatitis may respond to corticosteroids.

2.2. Liver. The most common hepatic complication of BD is Budd-Chiari syndrome (BCS). BCS is an uncommon form of portal hypertension caused by obstruction of the hepatic venous outflow usually due to thrombi in the hepatic veins. The main clinical features are hepatomegaly, leg edema, ascites, and venous dilatation over the trunk. The radiologic and liver biopsy findings confirm the diagnosis and provide information for the selection of appropriate medical, interventional, or surgical therapies. Because vasculitis is a major pathologic component of BD, hepatic vein vasculitis and BCS occur often in cases of BD. However, with no histologic evidence of vasculitis, a case of bile duct inflammation resembling small duct primary sclerosing cholangitis has been also reported.

The study of Bayraktar et al. is the largest series in the literature, consisting of 14 cases of BD-associated BCS. Based on this experience, it appears as if BCS is a relatively frequent complication of BD that accounts for 42.4% of the cases of BCS with recognizable underlying disease in Turkey. In most patients with BD and BCS, the IVC, as well as the hepatic veins, is involved. The clinical course of BCS in BD is poor [3]. The major determinant of survival is the extent of the vascular thrombosis in the IVC. BD may also contribute to development of cavernous transformation of the portal vein, portal vein thrombosis with splenomegaly, and superior vena cava thrombosis.

The other hepatobiliary conditions reported to occur in cases of BD are hepatomegaly due to fatty liver or congestion, cirrhosis, acute hepatitis, chronic hepatitis, cholelithiasis, acute cholecystitis, toxic hepatitis, hepatic abscess, primary biliary cirrhosis, and hepatocellular carcinoma. Acute liver failure and rapid death were found in one-third of patients in one series. Münke et al., suggested an association between BD and chronic hepatitis C [26]. Subsequently, Oğuz et al. reported a 0.45% prevalence of anti-HCV antibodies in a series of 224 cases of BD in Turkey [27]. They stated that this finding is similar to the prevalence of anti-HCV that occurs in healthy subjects and is much lower than

the prevalence in hemodialysis patients (51%) [3]. Rare cases include a hepatic artery aneurysm causing hemobilia as well as pyelphlebitis and septic thrombophlebitis of the portal vein. Type AA amyloidosis complicates BD and presents most often as diarrhea and malabsorption. It mainly involves the GI tract and the kidneys with proteinuria that progresses to nephrosis and renal failure. It has a 50% mortality rate after an average duration of 3.4 years.

3. Differential Diagnosis

Behçet's disease should be considered in the differential diagnosis in patients with recurrent orogenital ulcerations and enterocolitis with a nonspecific histological feature [28].

3.1. Crohn's Disease. The diagnosis of Behçet disease requires the presence of recurrent oral ulceration. Other helpful clinical features include ocular involvement, arthritis, erythema nodosum, and recurrent genital ulceration. Unfortunately, some of these may also be present in CD [20]. While granuloma formation is a pathologic hallmark of CD, it is not a characteristic lesion of BD just like cobblestoning and there is less inflammation surrounding ulcer in BD compared to CD [12]. Longitudinal ulcers and granulomas tend to be uncommon in Behçet's colitis. Naganuma et al. reported intestinal Behçet's disease with longitudinal ulcers and noncaseating granuloma [29]. The most characteristic pathologic feature of BD is the finding of deep ulcers associated with vasculitis, usually a venulitis [12]. The intestinal wall is of normal thickness, unlike the rigid, narrowed segments seen in CD. In addition, fistula formation and intestinal perforation tend to occur early in BD as compared to CD where they occur in a later course of the disease. Free perforation is rare in cases of CD but can occur in BD. Korman et al. found that in CD, but not in BD, enteroclysis, a radiologic examination of choice in the detection of pathologic changes in small bowel that shows the site and extension of the involvement, mucosal abnormalities, complications, and recurrences, findings were more severe, and cases generally were in the advanced stage when compared with the duration of both diseases [9]. Scalloping, ulceronodular patterns, and complications such as abscess formation are not observed in intestinal BD, therefore certain EC findings are helpful in differentiating BD from CD.

3.2. Steroid and Nonsteroid Anti-Inflammatory Drug-Induced Damage. Steroid and nonsteroid anti-inflammatory drug-(NSAID-) induced damage involves primarily proximal large intestine and occurs in various forms including colitis, colonic ulcers, pseudomembranous colitis, collagenous colitis, bleeding, and perforation, while aphthous ulceration is very rare. NSAIDs may occasionally cause small intestinal perforation, ulcers, and strictures that require surgery. The patient's clinical history is important since many patients with BD use steroids to control their disease. The ulcers that occur in cases of BD differ from steroid-induced ulcers both in size and appearance. Steroid-induced ulcer is usually single while the ulcers of BD seen in long-term steroid treatment

are characterized by multiple perforations. In one study, the frequency of intestinal perforation in patients with BD on steroids was 41%. Also in cases of BD without a history of steroid use, intestinal perforation can occur in up to 33% of the patients [12].

3.3. Ulcerative Colitis. The ileocecal region is the most frequently involved location in colonic BD. However, in ulcerative colitis the disease usually starts in the rectum and moves to the right colon, and also the ulcers are deeper in BD than ulcerative colitis [12]. Furthermore, HLA-B51 has never been reported in association with ulcerative colitis. Rather significant association with B52 and DR2 with UC has been reported [30].

3.4. Amebiasis. Differentiation of amebiasis and BD is important in the Middle East where both were frequently occur. Endoscopically, the disease is diffuse in both conditions, and the mucosa is hyperemic and is characterized by deep ulcers. But the presence of an amoeba in a fresh stool specimen is the best way to differentiate the two conditions [12].

4. Prognosis and Treatment

Prognosis of BD runs a chronic, unpredictable course with exacerbations and remissions which decrease in frequency and severity over time. Death is mainly due to major vessel disease and neurological involvement. The prognosis is poor for young males. Treatment of BD is usually palliative and symptomatic. The preferred treatments are combined drug therapy with any or all of the following: steroids, NSAIDs, immunosuppressives, and cytotoxic agents [20]. Complete remission is achieved in 38% of patients with intestinal BD after 8 weeks of medical treatment. Surgery is the other modality of treatment. Recurrence occurs in 49% of patients in 5 years, especially those with intestinal perforation or fistula formation. Recurrent lesions occur at or near the anastomoses in 1% of patients. Of those who undergo surgery, 75% recur within 2 years and are associated with a higher rate of complications such as ocular and ileal lesions than the nonsurgical group. The incidence of postoperative recurrence is less in those with normal intraoperative endoscopy than those with lesions seen. High rate of recurrent disease is observed especially in patients of Western or Chinese origin [15]. The histologic features of recurrent disease resemble the primary disease.

References

- [1] H. Morita, S. Kawai, O. Kobori, N. Ohya, M. Sumiya, and T. Dohi, "Incomplete form of Behçet's colitis in Japan: is it a distinct entity?" *The American Journal of Gastroenterol*, vol. 90, no. 3, pp. 523–524, 1995.
- [2] E. C. Ebert, "Gastrointestinal manifestations of behçet's Disease," *Digestive Diseases and Sciences*, vol. 54, no. 2, pp. 201–207, 2009.
- [3] Y. Bayraktar, E. Özasan, and D. H. Van Thiel, "Gastrointestinal manifestations of Behcet's disease," *Journal of Clinical Gastroenterology*, vol. 30, no. 2, pp. 144–154, 2000.

- [4] S. E. Marshall, "Behçet's disease," *Best Practice and Research: Clinical Rheumatology*, vol. 18, no. 3, pp. 291–311, 2004.
- [5] I. Krause and A. Weinberger, "Behçet's disease," *Current Opinion in Rheumatology*, vol. 20, no. 1, pp. 82–87, 2008.
- [6] D. Day, "Inflammatory disorders of the small intestine," in *Morson and Dawson's Gastrointestinal Pathology*, pp. 272–324, Blackwell, Malden, Mass, USA, 4th edition, 2007.
- [7] Y. K. Hong and W. H. Yoo, "Massive gastrointestinal bleeding due to the rupture of arterial aneurysm in Behçet's disease: case report and literature review," *Rheumatology International*, vol. 28, no. 11, pp. 1151–1154, 2008.
- [8] J. H. Cheon, D. S. Han, J. Y. Park et al., "Development, validation, and responsiveness of a novel disease activity index for intestinal Behçet's disease," *Inflammatory Bowel Diseases*, vol. 17, no. 2, pp. 605–613, 2011.
- [9] U. Korman, M. Cantasdemir, S. Kurugoglu et al., "Enteroclysis findings of intestinal Behçet disease: a comparative study with Crohn disease," *Abdominal Imaging*, vol. 28, no. 3, pp. 308–312, 2003.
- [10] S. Yurdakul, N. Tüzünler, I. Yurdakul, V. Hamuryudan, and H. Yazici, "Gastrointestinal involvement in Behçet's syndrome: a controlled study," *Annals of the Rheumatic Diseases*, vol. 55, no. 3, pp. 208–210, 1996.
- [11] U. Tursen, A. Gurler, and A. Boyvat, "Evaluation of clinical findings according to sex in 2313 Turkish patients with Behçet's disease," *International Journal of Dermatology*, vol. 42, no. 5, pp. 346–351, 2003.
- [12] C. M. Moon, J. H. Cheon, J. K. Shin et al., "Prediction of free bowel perforation in patients with intestinal Behçet's disease using clinical and colonoscopic findings," *Digestive Diseases and Sciences*, vol. 55, no. 10, pp. 2904–2911, 2010.
- [13] S. Köklü, O. Yüksel, L. Onur et al., "Ileocolonic involvement in Behçet's disease: endoscopic and histological evaluation," *Digestion*, vol. 81, no. 4, pp. 214–217, 2010.
- [14] M. H. Houman, I. B. Ghorbel, M. Lamoum et al., "Esophageal involvement in Behçet's disease," *Yonsei Medical Journal*, vol. 43, no. 4, pp. 457–460, 2002.
- [15] S. W. Yi, J. H. Cheon, J. H. Kim et al., "The prevalence and clinical characteristics of esophageal involvement in patients with Behçet's disease: a single center experience in Korea," *Journal of Korean Medical Science*, vol. 24, no. 1, pp. 52–56, 2009.
- [16] L. Ning-Sheng, L. Ruay-Sheng, and T. Kuo-Chih, "High frequency of unusual gastric/duodenal ulcers in patients with Behçet's disease in Taiwan: a possible correlation of MHC molecules with the development of gastric/duodenal ulcers," *Clinical Rheumatology*, vol. 24, no. 5, pp. 516–520, 2005.
- [17] S. K. Çakmak, A. Çakmak, Ü. Gül, M. Sulaimanov, P. Bingöl, and M. S. Hazinedaroğlu, "Upper gastrointestinal abnormalities and *Helicobacter pylori* in Behçet's disease," *International Journal of Dermatology*, vol. 48, no. 11, pp. 1174–1176, 2009.
- [18] O. Avcı, E. Ellidokuz, I. Şimşek, B. Büyükgöbeç, and A. T. Güneş, "*Helicobacter pylori* and Behçet's disease," *Dermatology*, vol. 199, no. 2, pp. 140–143, 1999.
- [19] K. Karakaya, M. Comert, and G. Numanoglu, "Multiple perforations along the transverse colon as a rare presentation of intestinal behcet's disease: a case report," *Clinics*, vol. 64, no. 12, pp. 1231–1233, 2009.
- [20] A. E. Noffsinger, G. N. Stemmermann, P. E. Lantz, P. G. Isaacson, and M. Cecilia, "The nonneoplastic small intestine," in *Gastrointestinal Pathology: An Atlas and Text*, C. M. Fenoglio-Preiser, Ed., pp. 275–471, Williams & Wilkins, Philadelphia, Pa, USA, 3rd edition, 2008.
- [21] C. M. Dowling, A. D. K. Hill, C. Malone et al., "Colonic perforation in Behçet's syndrome," *World Journal of Gastroenterology*, vol. 14, no. 42, pp. 6578–6580, 2008.
- [22] M. Turan, M. Şen, A. Koyuncu, C. Aydin, and S. Arici, "Sigmoid colon perforation as an unusual complication of Behçet's syndrome: report of a case," *Surgery Today*, vol. 33, no. 5, pp. 383–386, 2003.
- [23] S. J. Chou, V. T. K. Chen, H. C. Jan, M. A. Lou, and Y. M. Liu, "Intestinal Perforations in Behçet's disease," *Journal of Gastrointestinal Surgery*, vol. 11, pp. 508–514, 2007.
- [24] P. Jarrahejad, S. Gadeballi, E. Zurkovsky et al., "Behçet's disease: a rare cause of lower gastrointestinal bleeding," *International Journal of Colorectal Disease*, vol. 21, no. 8, pp. 856–858, 2006.
- [25] E. S. Kim, W. C. Chung, K. M. Lee et al., "A case of intestinal Behçet's disease similar to Crohn's colitis," *Journal of Korean Medical Science*, vol. 22, no. 5, pp. 918–922, 2007.
- [26] H. Münke, F. Stockmann, and G. Ramadori, "Possible association between Behçet's syndrome and chronic hepatitis C virus infection," *New England Journal of Medicine*, vol. 332, no. 6, pp. 400–401, 1995.
- [27] A. Oğuz, F. Sametoğlu, and S. Erdoğan, "More on hepatitis C and Behçet's syndrome," *New England Journal of Medicine*, vol. 333, no. 5, pp. 322–323, 1995.
- [28] F. H. Ng, T. C. Cheung, K. C. Chow et al., "Repeated intestinal perforation caused by an incomplete form of Behçet's syndrome," *Journal of Gastroenterology and Hepatology*, vol. 16, no. 8, pp. 935–939, 2001.
- [29] M. Naganuma, Y. Iwao, K. Kashiwagi, S. Funakoshi, H. Ishii, and T. Hibi, "A case of Behçet's disease accompanied by colitis with longitudinal ulcers and granuloma," *Journal of Gastroenterology and Hepatology*, vol. 17, no. 1, pp. 105–108, 2002.
- [30] T. Kobashigawa, H. Okamoto, J. Kato et al., "Ulcerative colitis followed by the development of Behçet's disease," *Internal Medicine*, vol. 43, no. 3, pp. 243–247, 2004.

Review Article

Histopathological Evaluation of Behçet's Disease and Identification of New Skin Lesions

Özgür Gündüz

Department of Dermatology, Faculty of Medicine, Kırıkkale University, 71100 Kırıkkale, Turkey

Correspondence should be addressed to Özgür Gündüz, gunduzozgur@windowslive.com

Received 17 June 2011; Accepted 16 August 2011

Academic Editor: Ümit Tursen

Copyright © 2012 Özgür Gündüz. This is an open access article distributed under the Creative Commons Attribution License, which permits unrestricted use, distribution, and reproduction in any medium, provided the original work is properly cited.

Behçet's disease (BD) is a multisystemic, relapsing inflammatory disorder with an obscure etiology and pathogenesis. Diagnosis depends on the clinician's ability to identify a group of nonspecific mucocutaneous lesions, which also manifest in a number of other diseases. In recent years, there has been an increase in the studies focusing on the histopathological aspects of Behçet's disease diagnostic mucocutaneous lesions. Their results emphasize the value of histopathology and direct immunofluorescence (DIF) in the differential diagnosis of Behçet's disease.

1. Introduction

After seventy-four years, since Dr. Hulusi Behçet had published his classic paper describing the three major signs [1], BD are still an enigma for clinicians and researchers. Almost all aspects of BD is a source of debate and even its diagnostic criteria, classification, and pathogenesis are controversial [2–4].

In the last two decades, extensive studies have been conducted to reveal the nature of BD. In the light of these studies, BD is now recognized as a chronic, multisystemic vasculitis [2, 5–7]. Whether this vasculitis is a result of autoimmunity is controversial [2, 3], but there is increasing evidence indicating the possible role of immunologic mechanisms in the pathogenesis. Evaluation of lesion-free skin and mucocutaneous lesions of patients with BD patients by DIF reveals immunoreactant deposits on the vessel walls [8–11]. Also, elevated serum levels of several proinflammatory cytokines (IL-1, IL-4, IL-6, TNF- α , etc.) have been reported in these patients [12]. A special subgroup of T lymphocytes ($\gamma\delta$ T lymphocytes), which play an important role in mucosal immunity, are found to be present in the increased numbers in circulation and mucosal lesions of patients [13]. Several research groups found out that cultured $\gamma\delta$ T lymphocyte cells proliferate when stimulated with mycobacterial heat shock proteins and products of several oral pathogen microorganisms [13, 14].

Correlation between the hyperactive state of neutrophils and BD activity is another well-known fact. The underlying mechanism is unknown. Antigen-presenting cell and T-lymphocyte-derived cytokines and chemokines are believed to be responsible for neutrophils hyperreactivity [15].

BD is mostly encountered in the Mediterranean and Middle and Far East countries, Turkey having the highest prevalence with 80–420 cases/100.000 [3, 16].

Genetic studies show statistically significant association with HLA-B51 [17, 18].

Antiendothelial antigens are another immunological anomaly found in BD patients, but there is no solid evidence for their participation in the pathogenesis [19].

Considering available information, it is no surprise that most of the working hypotheses for the BD pathogenesis point out an external factor (an infectious or regional pathogen, i.e., Parvovirus B19 [20], *Helicobacter pylori* [21], *Streptococcus sanguis* [22], etc.). This factor probably stimulates an abnormal immune reaction, during which certain types of lymphocytes are stimulated and neutrophils reach a hyperreactive state in the people with a genetic predisposition. Diagnosis of BD depends on the presence of several clinical findings. These findings are defined by the International Study Group (ISG) of Behçet's Disease and published in 1990 [23] (Table 1). Major weak points of ISG criteria are the occasional long intervals between

TABLE 1: Diagnostic criteria of Behçet's disease defined by International Study Group.

Mucocutaneous lesions	Description
Recurrent oral ulceration	Minor, aphthous, major aphthous, or herpetiform ulceration observed by physician or patient that recurred at least 3 times in one 12-month period
Plus 2 of the following criteria:	
Recurrent genital ulceration	Aphthous ulceration or scarring observed by physician or patient
Eye lesions	Anterior uveitis, posterior uveitis, cells in vitreous on slit lamp examination, or retinal vasculitis observed by ophthalmologist
Cutaneous lesions	Erythema nodosum, pseudofolliculitis, papulopustular lesions, or acneiform nodules observed by physician in postadolescent patients not receiving corticosteroid treatment
Positive pathergy test	Read by physician at 24 to 48 hours

manifestations of mucocutaneous lesions with the diagnostic value and lack of their specificity. Similar lesions may manifest in an extensive number of diseases (e.g., papulopustular lesions, erythema nodosum). Knowledge of histopathological features of BD mucocutaneous lesions may be beneficial for differential and early diagnosis.

2. Aphthous Oral Ulcers

Aphthous oral mucosa ulcers (AOUs) are usually the initial clinical manifestation [4, 24]. Ideguchi et al. evaluated 412 BD patients' hospital records covering 16 years follow-up data [4]. The result of this study revealed that in some cases AOU had proceeded 10 years a definitive diagnosis. Unfortunately, AOUs are neither specific nor rare. Similar ulcers may be observed during the course of several systemic or local diseases, including inflammatory bowel diseases (Crohn), Sweet syndrome, cyclic neutropenia, and herpes infections. If recognized by clinician, other clinical manifestations of this disease may enable a quick differential diagnosis.

Regardless of the concurrent disease, morphologies of AOU are similar. An AOU has sharp borders surrounded by an erythematous rim and a base covered with yellow-white coloured pseudomembrane. AOUs are classified into three groups according to ulcer diameter, but these three morphological forms are recognized as parts of the same spectrum.

- (1) Minor aphthae are shallow mucosal ulcers with a diameter <10 mm, which may be found in groups, usually on nonkeratinized section of oral mucosa (lateral sides and ventral surface of tongue, mouth floor).
- (2) Major aphthous ulcers have similar morphologies, but they have larger diameter (>10 mm), are deeper than the minor variants, and tend to heal with scarring.
- (3) Herpetiform aphthae are pinpoint shaped, very small and shallow mucosal ulcers and tend to occur in crops. Sometimes they may converge and form large ulcers with irregular borders.

Several pathogenetic mechanisms for aphthous ulcers have been proposed such as T-cell-mediated immunologic reactions, inhibition of mucosal healing by cytokines, nutritional

(vitamin B₁₂, folic acid) deficiencies, and viral or bacterial assault, but neither of these are proven.

To include oral aphthous ulcers in the diagnostic criteria of BD, at minimum three episodes should be observed in one year. Since a definitive BD diagnosis requires the other mucocutaneous features to develop, patients may undergo a long prediagnostic interval, manifesting only oral aphthae. Recurrent aphthous stomatitis (RAS), the most common type of oral aphthae [25–28], affects nearly one quarter of the world population [1] and runs a similar course to the prediagnostic phase of BD, providing a diagnostic challenge for the clinician. RAS patients, regardless the intensity of the mucosal disease, do not develop any other systemic symptoms. In recent years, many studies evaluating morphological, histopathological, and immunohistochemical features of RAS and BD have been published [8, 25]. Oh et al. compared the clinical features of RAS and BD and found minor differences [25]. According to this study, BD patients tend to manifest more major aphthae on their oral mucosa, and involvement of more than two sites was more common in BD. Also, exacerbation of oral aphthae during the premenstrual period was more frequent in BD patients. But these results are not definitive for differential diagnosis, and researchers stated that RAS patients should be followed up for potential manifestation of BD [25].

Due to AOU tendency to spontaneous healing and well-known morphology, biopsies are rarely performed, and, due to similar histopathological features of all variants of aphthous oral ulcers, histopathological examination has a limited value in the differential diagnosis. Lymphocytes, macrophages, and neutrophils are observed at the base of an AOU [29]. The infiltrate is more pronounced around the vessels. Although classified as vasculitis, some studies report that most mucocutaneous lesions in BD do not present typical characteristics of an actual vasculitis [7]. Fibrinoid necrosis in the vessel walls is reported to be very rare [5]. At the periphery of the ulcer base, the infiltrate may penetrate into the epidermis. Some recently published direct immunofluorescence (DIF) studies report IgM and C₃ deposits in perivascular region with or without granular C₃ deposits at the dermoepidermal junction in the perilesional skin of AOU in Behçet's disease patients [8, 25]. Also in another study, Wilhelmsen et al. evaluated perilesional skin of 23 RAS patients with direct immunofluorescence and

TABLE 2: An overview of the reported histopathological and immunofluorescence features of Behçet's disease common mucocutaneous lesions.

Mucocutaneous lesions	Reported histopathological features
Recurrent oral Aphthae	Lymphocytes, macrophages, neutrophils at the base of the ulcer, sometimes penetrating epidermis at the periphery
	Similar infiltrate at the perivascular regions in dermis fibrinoid necrosis of vessel walls (rare)
	Also granular IgM and C ₃ deposits in dermoepidermal junction and in perivascular regions (in RAS, no deposits of immunoreactants) [30]
Genital ulceration	Similar histopathological features to oral aphthae
Erythema-nodosum-like lesions	Neutrophilic vasculitis
	Lymphocytic vasculitis
	Necrobiosis
	IgM deposits at the vessel walls [40]
Pathergy reaction	Perivascular infiltrate of mononuclear cells
	Vasculitis (neutrophilic, leukocytoclastic) (+/-)
	Presence of mast Cells.
	IgM, IgA, and C ₃ deposits
Papulopustular lesions	Intraepidermal pustules, spongiosis, neutrophil/lymphocyte exocytosis, and basal keratinocyte vacuolization,
	Edema in dermis, lymphohistiocytic/neutrophilic inflammatory infiltration between collagen fibers, and perivascular areas
	Vasculitis (+/-)
Thrombophlebitis	Thrombi in the vessel lumen
	Perivascular infiltrate of mononuclear cells

found out the immunocomplexes to be absent [30]. Clinical significance of this study requires to be validated by other studies. If validated, this finding may be of utmost value in the differential diagnosis of RAS and BD (see Table 2).

3. Genital Ulcers

Genital ulcers manifest in the majority of BD patients [31, 32]. Usually larger than oral aphthae, genital ulcers of BD have similar clinical features. Most common places for genital ulceration are the scrotum and the shaft of the penis in men and the major and minor labia in women. Genital ulcers have irregular borders, are deeper than oral aphthae, and heal with scarring and occasionally causing fistulae extending to the urethra or bladder. Borders of genital ulcers are surrounded by an erythematous rim and fibrinous material, and whitish-yellow pseudomembranes can be found on the ulcer base. Observation of genital ulcers or remaining scars is of diagnostic value.

Many sexually transmitted diseases (STDs) manifest with genital ulcers, but usually, most STD diagnoses can easily be established with physical examination findings (i.e., lymphadenopathies—bubo formation in chancroid, lack of pain in syphilitic ulcer fever, and malaise). Also, direct observation of pathogenic microorganisms obtained via swaps by Wright, Giemsa stains and cultures for the suspected pathogens from ulcer bases usually make the histopathological evaluation inessential. Histopathology of genital ulcers is similar to that of the oral aphthae. The same mixed infiltrate consisting of neutrophils, lymphocytes, and

macrophages is ever-present at the ulcer base. In conclusion, diagnosis of Behçet's disease genital ulcers is a diagnosis of exclusion (see Table 2).

4. Extragenital Ulcers

In some BD patients, cutaneous ulcerations similar to aphthous lesions are reported on different locations other than oral mucosa and external genitalia. Legs, neck [33], and interdigital areas are some of the reported sites. Extragenital ulcers are seen in about 3% of BD patients and observed usually in children [34, 35]. A typical extragenital ulcer is a small, circumscribed, shallow ulcer with a red rim and yellow or grey base. These ulcers may persist for weeks and can be very painful. Due to their infrequency, there are few case reports and fewer studies evaluating these ulcers. Azizlerli et al. reported vasculitis in four cases [33] (see Table 2).

5. Erythema-Nodosum-Like Lesions

Nodular lesions located on the lower extremities resembling erythema nodosum are frequently seen in Behçet's disease patients. Erythema-nodosum-like lesions (ENLs) are rather common [36]. ENLs manifest mostly in females. Other than lower extremities, ENLs are reported on face and neck [31]. ENLs do not ulcerate and heal in 2-3 weeks. The main difference between erythema nodosum and ENL is the existence of vasculitis and necrobiosis in the latter. Nodular vasculitis is another condition, which may resemble ENL

and can be distinguished by the presence of granulomas and lymphocytic infiltration of subcutis.

There are conflicting results concerning the nature of the vasculitis. Two research groups, Chun et al. [37] and Kim and LeBoit [38], reported “lymphocytic vasculitis” as the dominant pattern. On the other hand, observation of “neutrophilic vasculitis” patterns was also reported [4, 39]. Pathogenesis of ENL vasculitis is unknown. Kaneko et al. [40] reported IgM deposits in the vessel walls in the lesional skin. Some authors believe this vasculitis to be a secondary event to lymphocytic infiltration [37]; others [41] proposed ENL vasculitis as a primary vasculitis (see Table 2).

6. Pathergy Reaction

The term “pathergy” is used to define the cutaneous hyper-reactivity to minimal trauma. A positive pathergy reaction in BD is characterized by an erythematous, indurated papule at the site of trauma, which usually evolves into a sterile pustule. Pathergy is one of the diagnostic criteria for BD and accepted as a sign for the active disease. Neutrophilic dermatoses (pyoderma gangrenosum, Sweet syndrome, and erythema elevatum diutinum) are also known for positive pathergy reaction. In this conditions, especially in pyoderma gangrenosum (PG), positive pathergy may have different manifestations. Pathergy in PG may describe development of the new skin lesions, the exacerbation of the existing ones following a minor skin trauma, or rapid enlargement of PG after debridement [42, 43]. Pathergy positivity is also reported in chronic myeloid leukemia (CML) patients [42].

The underlying mechanism of pathergy is unknown, and test positivity differs between different countries. Pathergy positivity is observed more frequently in the Mediterranean peninsula and Japan [31].

Results of the histopathological studies of pathergy in BD are conflicting. The only consensus on this subject is the presence of an infiltrate consisting of mononuclear cells around dermal vessels at the pathergy site. Some studies revealed the neutrophils as the major constituent of the infiltrate [44], while research groups found percentage of neutrophils relatively low [45]. There are also conflicting results in regard to vasculitis in pathergy of BD. Jorizzo et al. reported leukocytoclastic vasculitis [46]. Ergun et al. studied the change in the histopathological features of pathergy in BD patients and failed to observe a vasculitic pattern [47].

Presence of mast cells at the pathergy site is another histopathological feature worth of mentioning [42, 48]. Degranulation of mast cells is suggested to play a role in the pathergy [42, 49].

In 2009, Kose published a paper evaluating IgG, IgM, IgA, and C₃ deposits in 108 BD patients by direct immunofluorescence, 44 of the skin samples were obtained from positive pathergy sites, and high deposition rates of IgM, IgA, and C₃ were found [8], indicating a probable underlying autoimmune mechanism (see Table 2).

7. Papulopustular Lesions (PPLs)

Papulopustular lesions (PPLs) are the most common cutaneous manifestation of BD [31, 32]. PPLs are observed on the trunk, face, and extremities. ISG criteria concerning PPLs define them as “pseudofolliculitis or papulopustular lesions; or acneiform nodules observed by physician in postadolescent patients not receiving corticosteroid treatment” and do not clarify the exact nature of lesions. ISG definition of PPL refers to papular lesions on an erythematous base and progressing to sterile pustules [50], but papulopustular lesions of acne are also consistent with this definition, rendering this criteria impractical in the BD diagnosis during the adolescence period.

To determine whether a papulopustular eruption is a part of BD complex is probably the most challenging part of the diagnostic process. Some authors propose that nonfollicular lesions located in other than face are more specific for Behçet’s disease [31] and some propose exclusion of PPL from the diagnostic criteria due to its vague definition [50]. Despite the increasing number of studies evaluating the histopathological features of PPL, the exact nature of PPL is still needed to be established.

The results of these histopathological studies are also contradictory. Certain study results indicate the presence of vasculitis [5, 31, 32, 50] in the histopathological sections and suggest that the term “pseudofolliculitis” is a misnomer and that it should be dropped [5, 31], while some authors report perifolliculitis or suppurative folliculitis observed during the histopathological evaluations and consider histopathological sections of little help in the differential diagnosis [51]. More recent studies support the role of vasculitis in the evolution of Behçet’s disease papulopustular lesions [5, 10, 31]. Intraepidermal pustules, spongiosis, neutrophil or lymphocyte exocytosis, basal keratinocyte vacuolization, edema in dermis, lymphohistiocytic or neutrophilic inflammatory infiltration between collagen fibers and perivascular areas, fibrin deposition within vessel walls, endothelial swelling, and erythrocyte extravasation are reported as the histopathological features of Behçet’s disease PPL [10]. To further clarify the presence of vasculitis, PPLs were evaluated by immunofluorescence [8, 9, 11]. A study by İlknur et al. failed to find any difference between the direct immunofluorescence findings of eighteen Behçet’s disease patients and sixteen patients with bacterial folliculitis and five patients with acne [9]. In other two studies [8, 11] (seventeen and one hundred eight patients, resp.) immunoreactant deposition in the lesional and nonlesional skin of the BD patients was evaluated and significant deposition, especially IgM in the lesional skin was reported, supporting the immune-mediated vasculitis hypothesis (see Table 2).

8. Thrombophlebitis

Behçet’s disease may also affect major vessels. Although there are conflicting views about the presence of an actual vasculitis in the mucocutaneous lesions of BD, actual vasculitis of major vessels is well documented [7, 31]. Involvement of any vessel is possible, but venous system seems to be the

primary target [52, 53] and subcutaneous thrombophlebitis is reported to be the most frequent in the venous involvement [31]. Exact pathogenesis is unknown, but Th-1 type inflammatory response is suspected just as in other vasculitides like Wegener Granulomatosis and temporal arteritis. Unlike other primary vasculitides, major vascular involvement of BD predominantly affects males [7].

Subcutaneous thrombophlebitis is another common cutaneous manifestation of BD. Erythematous, tender nodules occur on the site of venous involvement. Consistent with the size of the affected vessel, an erythematous, linear hardening can also be palpated. During an activation period, several separate nodules may manifest consecutively on different localizations since multiple vascular segments may be involved, so BD must always be included in the differential diagnosis of "superficial migratory thrombophlebitis." Superficial thrombophlebitis may also herald the coexisting major vessel vasculitis and thrombotic condition [54, 55]. Histopathology of superficial thrombophlebitis is nonspecific. A thrombi in the vascular lumen and concomitant perivascular infiltrate consisting of mononuclear cells are the classical histopathological features (see Table 2).

9. Rare Cutaneous Lesions

There is an increasing number of reports about other coexistent cutaneous lesions in Behçet's disease patients. Among these are; erythema-multiforme-like lesions [56], polyarteritis nodosa-like lesions [57], pernio-like lesions [58], Sweet syndrome [59], necrotizing folliculitis [60], and necrotizing cutaneous small vessel vasculitis. Since reports of similar cases are so rare, association between BD and these skin lesions is not clear and they can be coincidental [31]. No extraordinary histopathological findings in these cases were reported.

Abnormalities observed in nailfold capillaroscopy are an intriguing and recently defined aspect of BD. Unlike the aforementioned cutaneous lesions, abnormalities in the periungual vessels were observed in relatively large patient populations. Movasat et al. described enlarged capillaries (26%), hemorrhages (16%) in the nail folds of 128 patients with BD [61], and suggested high blood pressure due to Behçet's disease major vessel involvement as the probable underlying factor.

10. Conclusion

Diagnosis of BD still depends of the clinician's ability to recognize various, nonspecific mucocutaneous lesions and this nonspecific character of lesions may be a major problem during the diagnostic process (e.g., whether the papulopustular lesions of a patient with recurrent AOU belong to diagnostic criteria). In recent years, histopathological and immunohistochemical evaluation of BD mucocutaneous lesions of B has become focus of many research groups, aiming to enhance the diagnostic value of these lesions. Although there are some contradictory reports, there are increasing reports supporting an underlying immune-mediated vasculitis in

the BD mucocutaneous lesions. Leukocytoclastic vasculitis, fibrinoid necrosis of postcapillary venules, or perivascular neutrophilic accumulations are some of the reported patterns in the early stages of the cutaneous lesions [31]. In conclusion, for the differential diagnosis of mucocutaneous lesions of BD (e.g., recurrent oral aphthae, papulopustular eruptions), immunofluorescence methods seem promising.

References

- [1] H. Behçet, "Über rezidivierende, aphthöse, durch ein virus verursachte Geschwüre am Mund, am Auge und an den Genitalien," *Dermatologische Wochenschrift*, vol. 105, pp. 1152–1157, 1937.
- [2] V. D. Kapsimali, M. A. Kanakis, G. A. Vaiopoulos, and P. G. Kaklamanis, "Etiopathogenesis of Behçet's disease with emphasis on the role of immunological aberrations," *Clinical Rheumatology*, vol. 29, pp. 1211–1216, 2010.
- [3] A. Gül, M. İnanc, L. Öcal, O. Aral, and M. Koniçe, "Familial aggregation of Behçet's disease in Turkey," *Annals of the Rheumatic Diseases*, vol. 59, no. 8, pp. 622–625, 2000.
- [4] H. Ideguchi, A. Suda, M. Takeno, and A. Ueda, "Behçet disease: evolution of clinical manifestations," *Medicine*, vol. 90, no. 2, pp. 125–132, 2011.
- [5] J. L. Jorizzo, J. L. Abernethy, W. L. White et al., "Mucocutaneous criteria for the diagnosis of Behçet's disease: an analysis of clinicopathologic data from multiple international centers," *Journal of the American Academy of Dermatology*, vol. 32, no. 6, pp. 968–976, 1995.
- [6] K. R. Chen, Y. Kawahara, S. Miyakawa, and T. Nishikawa, "Cutaneous vasculitis in Behçet's disease: a clinical and histopathologic study of 20 patients," *Journal of the American Academy of Dermatology*, vol. 36, no. 5, pp. 689–696, 1997.
- [7] M. Melikoglu, E. Kural-Seyahi, K. Tascilar, and H. Yazici, "The unique features of vasculitis in Behçet's syndrome," *Clinical Reviews in Allergy and Immunology*, vol. 35, no. 1-2, pp. 40–46, 2008.
- [8] A. A. Kose, "Direct immunofluorescence in Behçet's disease: a controlled study with 108 cases," *Yonsei Medical Journal*, vol. 50, no. 4, pp. 505–511, 2009.
- [9] T. İlknur, U. Pabuççoğlu, C. Akın, B. Lebe, and A. T. Gunes, "Histopathologic and direct immunofluorescence findings of the papulopustular lesions in Behçet's disease," *European Journal of Dermatology*, vol. 16, no. 2, pp. 146–150, 2006.
- [10] G. Kalkan, A. S. Karadag, H. M. Astarci, G. Akbay, H. Ustun, and M. Eksioğlu, "A histopathological approach: when papulopustular lesions should be in the diagnostic criteria of Behçet's disease?" *Journal of the European Academy of Dermatology and Venereology*, vol. 23, no. 9, pp. 1056–1060, 2009.
- [11] E. Alpsoy, S. Uzun, A. Akman, M. Alpaslan Acar, H. R. Memişoğlu, and E. Başarant, "Histological and immunofluorescence findings of non-follicular papulopustular lesions in patients with Behçet's disease," *Journal of the European Academy of Dermatology and Venereology*, vol. 17, no. 5, pp. 521–524, 2003.
- [12] A. Kulaber, I. Tugal-Tutkun, S. P. Yentür et al., "Pro-inflammatory cellular immune response in Behçet's disease," *Rheumatology International*, vol. 27, no. 12, pp. 1113–1118, 2007.
- [13] I. Bank, M. Duvdevani, and A. Livneh, "Expansion of $\gamma\delta$ T-cells in Behçet's disease: role of disease activity and microbial

- flora in oral ulcers," *Journal of Laboratory and Clinical Medicine*, vol. 141, no. 1, pp. 33–40, 2003.
- [14] A. Hasan, F. Fortune, A. Wilson et al., "Role of $\gamma\delta$ T cells in pathogenesis and diagnosis of Behçet's disease," *The Lancet*, vol. 347, no. 9004, pp. 789–794, 1996.
 - [15] S. Pay, I. Şimşek, H. Erdem, and A. Dinç, "Immunopathogenesis of Behçet's disease with special emphasize on the possible role of antigen presenting cells," *Rheumatology International*, vol. 27, no. 5, pp. 417–424, 2007.
 - [16] N. Cakir, E. Dervis, O. Benian et al., "Prevalence of Behçet's disease in rural western Turkey: a preliminary report," *Clinical and Experimental Rheumatology*, vol. 22, no. 4, supplement 24, pp. S53–S55, 2004.
 - [17] T. I. Kaya, H. Dur, U. Tursen, and A. Gurler, "Association of class I HLA antigens with the clinical manifestations of Turkish patients with Behçet's disease," *Clinical and Experimental Dermatology*, vol. 27, no. 6, pp. 498–501, 2002.
 - [18] J. Zervas, G. Vayopoulos, N. Sakellaropoulos, P. Kaklamanis, and P. Fessas, "HLA antigens and Adamantiades-Behçet's disease (A-BD) in Greeks," *Clinical and Experimental Rheumatology*, vol. 6, no. 3, pp. 277–280, 1988.
 - [19] A. Dinc, T. Takafuta, D. Jiang, M. Melikoglu, G. Saruhan-Direskeneli, and S. S. Shapiro, "Anti-endothelial cell antibodies in Behçet's disease," *Clinical and Experimental Rheumatology*, vol. 21, no. 4, supplement, pp. S27–S30, 2003.
 - [20] E. B. Baskan, E. Yilmaz, H. Saricaoglu et al., "Detection of parvovirus B19 DNA in the lesional skin of patients with Behçet's disease," *Clinical and Experimental Dermatology*, vol. 32, no. 2, pp. 186–190, 2007.
 - [21] O. Ersoy, R. Ersoy, O. Yayar, H. Demirci, and S. Tatlican, "H pylori infection in patients with Behçet's disease," *World Journal of Gastroenterology*, vol. 13, no. 21, pp. 2983–2985, 2007.
 - [22] F. Kaneko, N. Oyama, and A. Nishibu, "Streptococcal infection in the pathogenesis of Behçet's disease and clinical effects of minocycline on the disease symptoms," *Yonsei Medical Journal*, vol. 38, no. 6, pp. 444–454, 1997.
 - [23] B. Wechsler, F. Davatchi, Y. Mizushima et al., "Criteria for diagnosis of Behçet's disease," *The Lancet*, vol. 335, no. 8697, pp. 1078–1080, 1990.
 - [24] A. Pandrea, A. Rudinskaya, B. Klein, and T. Krebs, "What does it take to diagnose Behçet disease?" *Journal of Clinical Rheumatology*, vol. 13, no. 1, pp. 31–34, 2007.
 - [25] S. H. Oh, E. C. Han, J. H. Lee, and D. Bang, "Comparison of the clinical features of recurrent aphthous stomatitis and Behçet's disease," *Clinical and Experimental Dermatology*, vol. 34, no. 6, pp. e208–e212, 2009.
 - [26] J. A. Ship, "Recurrent aphthous stomatitis: an update," *Oral Surgery, Oral Medicine, Oral Pathology, Oral Radiology, and Endodontology*, vol. 81, pp. 141–147, 1996.
 - [27] S. D. Vincent and G. E. Lilly, "Clinical, historic, and therapeutic features of aphthous stomatitis: literature review and open clinical trial employing steroids," *Oral Surgery Oral Medicine and Oral Pathology*, vol. 74, no. 1, pp. 79–86, 1992.
 - [28] R. S. Rogers III, "Recurrent aphthous stomatitis in the diagnosis of Behçet's disease," *Yonsei Medical Journal*, vol. 38, no. 6, pp. 370–379, 1997.
 - [29] F. Kaneko, Y. Takahashi, R. Muramatsu et al., "Natural killer cell numbers and function in peripheral lymphoid cells in Behçet's disease," *British Journal of Dermatology*, vol. 113, no. 3, pp. 303–312, 1985.
 - [30] N. S. W. Wilhelmsen, R. Weber, and I. D. Miziara, "The role of immunofluorescence in the physiopathology and differential diagnosis of recurrent aphthous stomatitis," *Brazilian Journal of Otorhinolaryngology*, vol. 74, no. 3, pp. 331–336, 2008.
 - [31] E. Alpsoy, C. Zouboulis, and G. E. Ehrlich, "Mucocutaneous lesions of Behçet's disease," *Yonsei Medical Journal*, vol. 48, no. 4, pp. 573–585, 2007.
 - [32] E. Alpsoy, L. Dönmez, A. Bacanlı, C. Apaydin, and B. Butun, "Review of the chronology of clinical manifestations in 60 patients with Behçet's disease," *Dermatology*, vol. 207, no. 4, pp. 354–356, 2003.
 - [33] G. Azizlerli, G. Ozarmagan, C. Ovul, R. Sarica, and S. O. Mustafa, "A new kind of skin lesion in Behçet's disease: extragenital ulcerations," *Acta Dermato-Venereologica*, vol. 72, no. 4, p. 286, 1992.
 - [34] K. Krüger, K. Fritz, V. Daniel, and C. C. Zouboulis, "Juvenile Adamantiades-Behçet's disease with diminished response to stimulation with anti-CD3 monoclonal antibody," *Hautarzt*, vol. 48, no. 4, pp. 258–261, 1997.
 - [35] R. Treudler, C. E. Orfanos, and C. C. Zouboulis, "Twenty-eight cases of juvenile-onset Adamantiades-Behçet disease in Germany," *Dermatology*, vol. 199, no. 1, pp. 15–19, 1999.
 - [36] C. C. Zouboulis, "Epidemiology of Adamantiades-Behçet's disease," *Annales de Medecine Interne*, vol. 150, no. 6, pp. 488–498, 1999.
 - [37] S. I. Chun, W. P. D. Su, S. Lee, and R. S. Rogers, "Erythema nodosum-like lesions in Behçet's syndrome: a histopathologic study of 30 cases," *Journal of Cutaneous Pathology*, vol. 16, no. 5, pp. 259–265, 1989.
 - [38] B. S. Kim and P. E. LeBoit, "Erythema nodosum-like lesions in Behçet's disease: is vasculitis the main pathological feature?" *Journal of Cutaneous Pathology*, vol. 25, p. 500, 1998.
 - [39] C. Demirkesen, N. Tüzüner, C. Mat et al., "Clinicopathologic evaluation of nodular cutaneous lesions of Behçet syndrome," *American Journal of Clinical Pathology*, vol. 116, no. 3, pp. 341–346, 2001.
 - [40] F. Kaneko, Y. Takahashi, Y. Muramatsu, and Y. Miura, "Immunological studies on aphthous ulcer and erythema nodosum-like eruptions in Behçet's disease," *British Journal of Dermatology*, vol. 113, no. 3, pp. 303–312, 1985.
 - [41] B. Kim and P. E. LeBoit, "Histopathologic features of erythema nodosum-like lesions in Behçet disease: a comparison with erythema nodosum focusing on the role of vasculitis," *American Journal of Dermatopathology*, vol. 22, no. 5, pp. 379–390, 2000.
 - [42] A. Varol, O. Seifert, and C. D. Anderson, "The skin pathergy test: innately useful?" *Archives of Dermatological Research*, vol. 302, no. 3, pp. 155–168, 2010.
 - [43] K. Wolff and G. Stingl, "Pyoderma gangrenosum," in *Fitzpatrick's Dermatology in General Medicine*, I. M. Freeberg, A. Eisen, K. Wolff et al., Eds., pp. 969–976, McGraw Hill, New York, NY, USA, 2003.
 - [44] A. Gilhar, G. Winterstein, H. Turani, J. Landau, and A. Etzioni, "Skin hyperreactivity response (pathergy) in Behçet's disease," *Journal of the American Academy of Dermatology*, vol. 21, no. 3 I, pp. 547–552, 1989.
 - [45] A. Gul, S. Esin, N. Dilsen, M. Konice, H. Wigzell, and P. Biberfeld, "Immunohistology of skin pathergy reaction in Behçet's disease," *British Journal of Dermatology*, vol. 132, no. 6, pp. 901–907, 1995.
 - [46] J. L. Jorizzo, A. R. Solomon, and T. Cavallo, "Behçet's syndrome. Immunopathologic and histopathologic assessment of pathergy lesions is useful in diagnosis and follow-up," *Archives of Pathology and Laboratory Medicine*, vol. 109, no. 8, pp. 205–214, 1985.

- [47] T. Ergun, O. Gürbüz, J. Harvell, J. Jorizzo, and W. White, "The histopathology of pathergy: a chronologic study of skin hyperreactivity in Behcet's disease," *International Journal of Dermatology*, vol. 37, no. 12, pp. 929–933, 1998.
- [48] S. Haim, J. D. Sobel, R. Friedman Birnbaum, and C. Lichtig, "Histological and direct immunofluorescence study of cutaneous hyperreactivity in Behcet's disease," *British Journal of Dermatology*, vol. 95, no. 6, pp. 631–636, 1976.
- [49] C. Lichtig, S. Haim, and A. Gilhar, "Mast cells in Behcet's disease: ultrastructural and histamine content studies," *Dermatologica*, vol. 162, no. 3, pp. 167–174, 1981.
- [50] E. Alpsay, M. Aktekin, H. Er, Ç. Durusoy, and E. Yilmaz, "A randomized, controlled and blinded study of papulopustular lesions in Turkish Behcet's patients," *International Journal of Dermatology*, vol. 37, no. 11, pp. 839–842, 1998.
- [51] T. Ergun, O. Gürbüz, G. Doğusoy, C. Mat, and H. Yazici, "Histopathologic features of the spontaneous pustular lesions of Behcet's syndrome," *International Journal of Dermatology*, vol. 37, no. 3, pp. 194–196, 1998.
- [52] Y. Koc, I. Gullu, G. Akpek et al., "Vascular involvement in Behcet's disease," *Journal of Rheumatology*, vol. 19, no. 3, pp. 402–410, 1992.
- [53] R. Sarica-Kucukoglu, A. Akdag-Kose, M. Kayabali et al., "Vascular involvement in Behcet's disease: a retrospective analysis of 2319 cases," *International Journal of Dermatology*, vol. 45, no. 8, pp. 919–921, 2006.
- [54] K. T. Calamia, M. Schirmer, and M. Melikoğlu, "Major vessel involvement in Behcet's disease: an update," *Current Opinion in Rheumatology*, vol. 23, no. 1, pp. 24–31, 2011.
- [55] R. Tunc, E. Keyman, M. Melikoglu, I. Fresko, and H. Yazici, "Target organ associations in Turkish patients with Behcet's disease: a cross sectional study by exploratory factor analysis," *Journal of Rheumatology*, vol. 29, no. 11, pp. 2393–2396, 2002.
- [56] E. S. Lee, D. Bang, and S. Lee, "Dermatologic manifestation of Behcet's disease," *Yonsei Medical Journal*, vol. 38, no. 6, pp. 380–389, 1997.
- [57] Y. H. Liao, G. H. Hsiao, and C. H. Hsiao, "Behcet's disease with cutaneous changes resembling polyarteritis nodosa," *British Journal of Dermatology*, vol. 140, no. 2, pp. 368–369, 1999.
- [58] F. Cantini, C. Salvarani, L. Niccoli et al., "Behcet's disease with unusual cutaneous lesions," *Journal of Rheumatology*, vol. 25, no. 12, pp. 2469–2472, 1998.
- [59] O. Oğuz, S. Serdaroglu, Y. Tüzün, N. Erdoğan, H. Yazici, and H. Savaskan, "Acute febrile neutrophilic dermatosis (Sweet's syndrome) associated with Behcet's disease," *International Journal of Dermatology*, vol. 31, no. 9, pp. 645–646, 1992.
- [60] S. Trad, D. Saadoun, S. Barete, C. Frances, J. C. Piette, and B. Wechsler, "Necrotizing folliculitis in Behcet's disease," *Revue de Medecine Interne*, vol. 30, no. 3, pp. 268–270, 2009.
- [61] A. Movasat, F. Shahram, P. E. Carreira et al., "Nailfold capillaroscopy in Behcet's disease, analysis of 128 patients," *Clinical Rheumatology*, vol. 28, no. 5, pp. 603–605, 2009.

Review Article

Genetics of Behçet's Disease

Tamer İrfan Kaya

Department of Dermatology, Faculty of Medicine, Mersin University, 33079 Mersin, Turkey

Correspondence should be addressed to Tamer İrfan Kaya, tikaya@mersin.edu.tr

Received 6 July 2011; Accepted 15 August 2011

Academic Editor: Ümit Tursen

Copyright © 2012 Tamer İrfan Kaya. This is an open access article distributed under the Creative Commons Attribution License, which permits unrestricted use, distribution, and reproduction in any medium, provided the original work is properly cited.

Behçet's disease (BD) is a systemic inflammatory disorder characterized mainly by recurrent oral and genital ulcers and eye involvement. Although the pathogenesis remains poorly understood, a variety of studies have demonstrated that genetic predisposition is a major factor in disease susceptibility. Peculiar geographical distribution of BD along the ancient Silk Road has been regarded as evidence supporting genetic influence. The observed aggregation of BD in families of patients with BD is also supportive for a genetic component in its etiology. HLA-B51 (B510101 subtype) is the most strongly associated genetic marker for BD in countries on the Silk Road. In recent years, several genome-wide association studies and genetic polymorphism studies have also found new genetic associations with BD, which may have a supplementary role in disease susceptibility and/or severity. The author reviewed the HLA and non-HLA genetic association studies.

1. Introduction

Behçet's disease (BD) is a complex syndrome characterized mainly by recurrent oral aphthous ulcers, genital ulcerations, and ocular involvement. This triple-symptom complex was first described by Hulusi Behçet, a Turkish dermatologist, as a separate disease entity. Later, other associated clinical features were described [1, 2]. Although the aetiology is still obscure, BD is believed to be triggered by environmental factors such as microbial agents in individuals with a particular genetic background. Interactions of genetic and environmental factors in BD patients may underlie pathogenic processes, which may influence the development of the disease and modify its course. The prevalent distribution in a specific geographical area, the close association with HLA-B51 in different ethnic groups, and the familial clustering of BD are hallmarks accounting for the strong contribution of a genetic background [2, 3]. Here we review the current knowledge of the genetic basis of BD and their implications in pathogenesis of BD and summarize the important findings in Table 1.

2. Geographical Distribution

The prevalence of BD is known to be high in Japan, China, Turkey, and the Mediterranean and the Middle Eastern countries. It is hypothesized that this geographical distribution of BD from Japan to the Middle East and

the Mediterranean basin correlates with the distribution of HLA-B51 by old nomadic or Turkish tribes via the ancient Silk Road. This peculiar geographical distribution have been regarded as evidence supporting genetic influence on the pathogenesis of BD [1, 4, 5]. The highest prevalence rates of BD were reported from Turkey as 420/100.000 in Istanbul, 380/100.000 in a rural area in northern Turkey, and 110/100.000 in Ankara [6–8]. Usually prevalence rates between %7/100.000 and %30/100.000 were reported in Middle East, Mediterranean, and Far East countries [1, 9]. It is rarely seen in Western and Northern Europe and United States, for example, its prevalence reported 2,26/100.000 in Germany and 5,2/100.000 in the United States [10, 11]. In sub-Saharan Africa, Australasia, and among Amerindians the disease is rare or almost absent [9]. The prevalence of BD in Berlin was reported to be the highest among Lebanese (101.3/100 000) and Turkish (77.3/100 000) people, while the lowest prevalence was reported among Germans (1.4/100 000) [12]. These findings suggest that BD prevalence is mostly dependent on ethnic origin and genetic factors rather than environmental factors [9, 12].

3. HLA-B51 and Other HLA Genes Associated with BD

HLA-B51, one of the split antigens of HLA-B5, has been found to be the most accurate genetic marker for BD to date

TABLE 1: Findings supporting the genetic background of Behçet's disease.

Studies	Findings/associations
Epidemiology	Geographical distribution: from Japan to the Middle East and the Mediterranean basin
Ethnic origin	Prevalence in Berlin: high in Lebanese and Turks and low in Germans
HLA	HLA-B51 (B510101 subtype)
Genome-wide association studies	(i) MHC Class I region: HLA-B51 (B5101)
	(ii) Non-HLA regions: IL10 region and region between IL23R and IL12RB2
	(iii) Chromosome regions: 6q25-26, 12p12-13
Familial aggregation	(i) In patients with pediatric onset
	(ii) Autosomal-recessive Mendelian mode of inheritance in a pediatric subgroup
Twin concordance studies	High concordances in monozygotic twins
Gene polymorphism studies	Inconsistent and weak associations, further investigations are needed for definitive conclusions

in different ethnic groups. However, its contribution to the overall genetic BD susceptibility was estimated about to be 20% [13]. The HLA-B51 is frequent in BD patients, with a range of 40–80% in ethnic groups including Turkish, European, and Asian populations from the Middle East to the Far East, whereas it can be as low as 13% among white patients in western countries [3, 9]. And in our study, we observed HLA-B51 in 46 (54.1%) of our 85 Turkish patients [1]. In general, the strongest correlation between BD and HLA-B51 is seen among populations with a high incidence of HLA-B51 and BD, and the weakest correlation is seen in populations where BD and HLA-B51 are rare [1, 9]. In a recent meta-analysis of 4,800 patients with BD and 16,289 controls from 78 independent studies, the pooled odds ratio (OR) of HLA-B51/B5 allele carriers to develop BD compared with noncarriers was found to be 5.78 (95% CI 5.00–6.67). They found that the pooled rates of HLA-B51/B5-positive BD cases varied across geographic locations, but interestingly the relative risk increases associated with this allele appeared to be fairly even for different ethnic populations [14].

There are more than 89 different subtypes of HLA-B51, and HLA-B5101 is the major suballele associated with BD in all the populations studied. HLA-B5108 was also found to be associated with BD in the Middle Eastern, Italian, Spanish, Greek, Turkish, and German patients. Oppositely, it has been suggested that HLA-B5107 might be negatively associated with BD in the Turkish and German populations [3, 9]. Recently, Y. Takemoto et al. investigated *HLA-B5101* gene from Japanese, Turkish, Jordanian, and Iranian patients and found that all the patients have B510101 suggesting that the susceptibility to BD was conferred by the B510101 subtype and not by any genes in linkage disequilibrium with HLA-B51 [15]. Accordingly, Amerindian populations, known to carry a high frequency of HLA-B51 but having no BD incidence, are known to carry the highest frequencies of nonsusceptible HLA-B510201 allele [9, 16].

In our study, we also investigated the association of HLA class I alleles with the manifestations of BD. We found that BD patients with HLA-B51 antigen are almost four times more likely to have thrombophlebitis than patients without it. We also found some less significant associations:

decreased HLA-B35 frequency in patients with thrombophlebitis, increased HLA-A29 and decreased HLABw6 frequency in patients with ocular involvement, decreased HLA-Cw2 frequency in patients with erythema nodosum, and decreased HLA-Cw7 frequency in patients with genital ulceration [1]. Zouboulis et al. also found that both superficial thrombophlebitis and deep thrombosis significantly were more frequent in HLA-B5-positive BD patients compared with HLA-B5-negative patients. They did not observe any other association between the class I HLA antigens and manifestations of BD [17]. Alekberova et al. found superficial thrombophlebitis statistically more frequent in HLA-B5-positive BD patients [18]. However, Muftuoglu et al. observed no HLA allele association with thrombophlebitis, ocular involvement, arthritis, and erythema nodosum in BD patients [19].

The pathogenetic role of HLA-B51 in BD has yet to be elucidated. However, HLA-B51 molecule itself may be responsible, at least in part, for neutrophil hyperfunction in BD, since HLA-B51-transgenic mice show enhanced neutrophil function as seen in BD patients, although these mice did not develop the symptoms of BD [20]. Because a primary role of HLA class I antigens such as HLA-B51 is to present endogenous peptides to CD8+ T cells, the lack of the disease phenotype in this mouse model can be explained by the absence of an triggering microbial or injury-related peptide that would activate the disease-relevant CD8+ T cells. MICA (9-mer peptide AAAAIFVI) is a stress-inducible antigenic peptide, and it is one of the many triggering candidates of BD. Yasuoka et al. showed that only HLA-B51-positive BD patients with active disease showed a MICA-mediated cytotoxicity and they also showed that this specific T cell response was lost after the BD-related symptoms disappeared [21]. Superoxide production by neutrophils was also reported to be increased in HLA-B51-positive individuals [22]. These findings suggest that HLA-B51 could be associated with neutrophil hyperfunction in BD.

Several other HLA class I and class II alleles including HLA-A26, HLA-B15, HLA-B5701, HLA-B2702, HLA-B3901, HLA-B52, HLA-B56, Cw1, Cw14, Cw15, Cw16, HLA-DRB104, and HLA-DRB107 have been described to be

associated with BD in different populations. Positive and negative associations with nonclassical HLA-E, HLA-F, and HLA-G polymorphisms were also detected in Korean and Japanese patients. But because of their low incidence or the small size of investigated populations, mostly significance levels have been weak and most of them were achieved in single studies only. Therefore, they are generally not considered to give primary susceptibility to the disease. In addition, since there is strong linkage disequilibrium within the MHC region it is not clear whether these associations cause susceptibility to BD or they have a linkage disequilibrium with HLA-B51. Among these associations HLA-A26, HLA-B15, and HLA-B5701 were found to be independently associated with BD [1, 3, 9, 23–25].

The *MHC class I chain-related gene A (MIC-A)* was also regarded as a candidate for BD genetic susceptibility. Several studies have demonstrated associations between MIC-A009, MIC-A006, MIC-A6 TM, and BD. However, these associations appear to be the result of a strong linkage disequilibrium of MIC-A with HLA-B51, so today they are not considered as the primary susceptibility genes for BD [9, 26].

4. Genome-Wide Association Studies (GWASs)

GWAS can facilitate new unbiased biologic insights into disease pathogenesis, and they can provide more definite answers for the cause of the diseases of complex genetic trait when performed in large groups and confirmed in different populations. The first GWAS was relatively small and was reported in Turkish BD patients: Fei et al. identified genetic associations between BD and single-nucleotide polymorphisms (SNPs) in KIAA1529, CPVL, LOC100129342, UBASH3B, and UBAC2 (OR = 2.04, 2.26, 1.84, 1.71, and 1.61, resp.). Interestingly, none of these five susceptibility loci had been associated with BD before. The functions of two are not known, and the genes *UBASH3B* and *UBAC2* both contain a UBA, suggesting that both gene products are involved in the ubiquitination pathway. *CPVL* gene encodes for a carboxypeptidase that cleaves a single amino acid from the carboxy terminus of proteins or peptides [27].

Remmers et al. performed a GWAS with 311,459 SNPs in 1215 BD patients and 1278 healthy controls from Turkey. They confirmed HLA-B51 association and identified a second, independent association within the MHC Class I region. In addition, the results of the meta-analysis including a total of 2430 cases and 2660 controls established associations with the interleukin10 (IL10) variant (OR: 1.45) and with a variant located between the *IL23 receptor* (IL23R) and *IL12 receptor β2* (IL12RB2) genes (OR: 1.28) [28]. Recently, Mizuki et al. performed a similar GWAS using a larger sample pool using 500, 568 SNPs in 612 Japanese individuals with BD and 740 unaffected controls, and the HLA-B region showed the most significant association with BD (rs4959053, $P = 1.8 \times 10^{-26}$). They also detected genome-wide significant associations outside the HLA complex, at $P = 2.7 \times 10^{-8}$ for rs12119179, which is located in the 47 kb intergenic region between IL23R and IL12RB2. The second strongest region of association they found was rs1554286, located within

the intron 3 of IL10 ($P = 8.0 \times 10^{-8}$) [29]. The results of these 2 large GWASs provide cross-validation of these two non-HLA regions, IL10 and IL23R-IL12RB2 associations in two distinct populations. IL23 is a heterodimeric pro-inflammatory cytokine that has been shown to stimulate T helper cell proliferation and increase the production of inflammatory cytokines such as IL1, IL6, IL17, and TNFα. IL10 is a potent suppressor of inflammatory cytokines such as IL1, IL6, IL12, TNFα and IFNγ and inhibits T cell and NK cell activation [29].

Meguro et al. also performed a GWAS in BD among 23,465 microsatellites, and 6 best positively associated microsatellites (of a total of 147) (D3S0186i, D6S0014i, D6S0032i, 536G12A, D12S0645i, and D22S0104i) with BD were identified. New studies are needed to identify the importance of these microsatellites in the pathogenesis of BD. They also performed a class I HLA analysis. They found HLA-B5101 as the strongest susceptibility allele for the development of BD. Interestingly, among the HLA-B5101-negative patients, HLA-A26 was found to be the most strongly associated allele with BD (allele: 25.9% versus 10.6%, OR = 2.96). Significantly increased incidences of HLA-F010101 and HLA-G010102 in patients with BD probably result from linkage disequilibrium with HLA-A26 [30]. In previous studies, HLA-A26 was significantly associated with BD in Japanese, Taiwanese, and Greek populations. On the contrary, in Ireland, Italy, and Turkey, HLA-A26 was increased in healthy controls compared with patients with BD, but not significantly [30]. Karasneh et al. performed a whole-genome linkage analysis with 395 microsatellite markers and identified 16 potential loci for BD, 1p36, 4p15, 5q12, 5q23, 6p22–24, 6q16, 6q25–26, 7p21, 10q24, 12p12–13, 12q13, 16q12, 16q21–23, 17p13, 20q12–13, and Xq26–28 with the strongest evidence seen for 12p12–13 and 6p22–24 [31]. Two chromosome regions were consistent with the regions of two BD susceptibility markers, 536G12A and D12S0645i, which were located on 6q25.1 and 12p12.1, which were found by Meguro et al. in their genome-wide association study [30].

5. Familial Aggregation

Familial aggregation has been also regarded as an evidence supporting the genetic predisposition to BD and has been reported in 1–18% of the patients, mostly of Turkish, Israeli and Korean origin, and it is increased in patients with juvenile disease and is especially manifest in families of probands carrying HLA B51. The familial aggregation of BD has been observed in different ethnic groups with a variable frequency. It is higher in Turks (18.2%), Koreans (15.4%), and Jews (13.2%) than in Chinese (2.6%), Japanese (2.2%), and Europeans (1%) [3, 32–34].

Analysis of a small group of multicase families did not demonstrate any particular Mendelian inheritance pattern [35]. However, a recent study provided evidence of an autosomal-recessive Mendelian mode of inheritance in a pediatric BD subgroup suggesting that genetic load might be higher in children with BD than in adults [36]. A genetic anticipation, in the form of earlier disease onset in the children of the affected parents, has also been observed in a group of Turkish

families. The expansion of unstable trinucleotide repeats has been proposed as the genetic basis of the defect in familial cases [37]. Treudler et al. observed that juvenile-onset disease was characterized by an increase in familial cases (25% versus 8% in patients with adult onset; $P = .047$) [38]. Laghmari et al. evaluated clinical characteristics of BD in Moroccan children, and they reported the familial disease in 30.7% of their cases, which is the highest familial aggregation rate reported so far [39]. I. Koné-Paut reported that 13 of the 106 pediatric patients (12.3%) and 9 of the 399 nonpediatric patients (2.2%) had relatives affected by BD. This excess of familial cases in the pediatric group compared with the nonpediatric group was found to be significant ($P < .0001$). They also found that the mean age of attaining criteria in familial cases (17.95 years) was significantly lower than in sporadic cases (27.28 years; $P < .0001$), and they proposed the inclusion of familial history in the definition of pediatric BD [40].

Akpolat et al. evaluated 27 patients with familial BD in 12 families. Among the 137 patients they studied, the rate of familial form of BD was 8.7%. Vascular involvement was 7.4% (2/27) in the familial group, while it was 28.8% (36/125) in patients without the familial form of the disease ($P < 0.01$). They also observed a high rate of (68%) HLA-B51 positivity in the familial form [33]. Recurrence most commonly occurs between siblings, but also there are mother/son, mother/daughter, father/son, father/daughter, cousin/cousin and uncle/nephew cases [3]. The sibling recurrence risk of BD was reported to be 4.2% in Turkey, and the recurrence risk ratio (λ_s) was estimated to be 11.4–52.5 in Turkish populations [41]. In familial BD, the HLA-B51 positivity is much more frequent than in sporadic cases, being 68–83.3% in Turkish studies. The HLA-B51 homozygosity is common in familial cases [33, 42].

Twin concordance studies are frequently being used for estimating the role of genetic factors in the pathogenesis of multifactorial diseases. In a recent twin study of Masatlioglu et al., the pairwise concordance rate for BD was 2/6 for monozygotic twins and 1/8 for dizygotic twins. In this study genetic effects accounted for 41% of the phenotypic variance for BD among twins. The higher concordances for BD in monozygotic twins compared with dizygotic twins suggests genetic predisposition [43]. In addition, there are two reports of monozygotic twins concordant for BD [43, 44]. In one of these twins reports both patients interestingly showed intestinal BD; however, they were HLA-B51 negative [44]. In the other report, the twin brothers were both HLA-B51 positive and developed the disease at the same age [45]. There is also one report of a pair of HLA-B51-negative monozygotic twins discordant for BD in the literature [46].

6. Immunogenetics and Gene Polymorphism Studies

Cytokine-mediated immunity plays a crucial role in the pathogenesis of various immunologically mediated diseases. It has been suggested that polymorphisms of genes involved in immunopathogenesis of diseases combining with environmental factors may be important in the development of these

diseases. Several genes such as *IL* genes (*IL-1A*, *IL-1B*, *IL-1 receptor antagonist*, *IL-2*, *IL-6*, *IL-10*, *IL-12B promoter*, *IL-17F*, *IL-18*, *IL-23R* genes), *tumor necrosis factor* (TNF) genes, *transporter associated with antigen processing* (TAP) gene, *intercellular adhesion molecule-1* (ICAM-1) gene, *endothelial nitric oxide synthase* (eNOS) gene, *glutathione S-transferase* gene, *N-acetyltransferase* gene, and *vascular endothelial growth factor* (VEGF) gene polymorphisms have been related to BD susceptibility. However, in these studies significance levels were mostly weak, most of them were achieved in single studies and if there are multiple studies the results are mostly conflicting. For example, eNOS gene polymorphism was reported to be associated with BD susceptibility in Italian and Korean, but not in Turkish and Japanese patients. Therefore their role in BD pathogenesis is not clear, and further investigations are needed for definitive conclusions [3, 47–52].

Thrombosis is a common complication of BD and the pathogenic mechanism of thrombotic tendency in BD is not well known. The role of procoagulant polymorphisms and mutations has also been investigated in BD. As *platelet membrane glycoprotein* gene polymorphisms have been identified as risk factors for thrombosis we investigated the association of the *platelet glycoprotein Ia C807T/G873A* gene polymorphism and thrombosis in BD and we found that the risk of thrombosis is significantly higher in patients who have 807TT and 807CT genotypes than in patients who have 807CC genotype [53]. Associations of factor V Leiden and *prothrombin* gene mutations with BD were confirmed in some studies, but not in others [3, 54, 55]. We also investigated the association between the factor V Leiden and *prothrombin* gene mutations with BD and we found a significantly high prevalence of the *prothrombin* gene mutation in patients with BD patients than in control subjects [56].

Here we review the current knowledge of the genetic basis of BD. However, it has been evident that there are similarities and differences in BD susceptibility loci across ethnic groups. Therefore, efforts to identify ethnic-specific genetic factors or disease-causing variants are needed for the genetic dissection of BD.

References

- [1] T. I. Kaya, H. Dur, U. Tursen, and A. Gurler, "Association of class I HLA antigens with the clinical manifestations of Turkish patients with Behçet's disease," *Clinical and Experimental Dermatology*, vol. 27, no. 6, pp. 498–501, 2002.
- [2] H. Behçet, "Über rezidivierende, aphthöse durch ein virus verursachte geschwüre am mund, am auge und an der genitalen," *Dermatologische Wochenschrift*, vol. 105, pp. 1152–1157, 1937.
- [3] P. Fietta, "Behçet's disease: familial clustering and immunogenetics," *Clinical and Experimental Rheumatology*, vol. 23, no. 4, supplement 38, pp. S96–S105, 2005.
- [4] S. Ohno, M. Onguchi, and S. Hirose, "Close association of HLA-Bw51 with Behçet's disease," *Archives of Ophthalmology*, vol. 100, no. 9, pp. 1455–1458, 1982.
- [5] D. Mendes, M. Correia, M. Barbedo et al., "Behçet's disease—a contemporary review," *Journal of Autoimmunity*, vol. 32, no. 3–4, pp. 178–188, 2009.

- [6] G. Azizlerli, A. A. Köse, R. Sarica et al., "Prevalence of Behçet's disease in Istanbul, Turkey," *International Journal of Dermatol-ogy*, vol. 42, no. 10, pp. 803–806, 2003.
- [7] S. Yurdakul, I. Gunaydin, Y. Tuzun et al., "The prevalence of Behçet's syndrome in a rural area in northern Turkey," *Journal of Rheumatology*, vol. 15, no. 5, pp. 820–822, 1988.
- [8] A. Idil, A. Gürler, A. Boyvat et al., "The prevalence of Behçet's disease above the age of 10 years: the results of a pilot study conducted at the Park Primary Health Care Center in Ankara, Turkey," *Ophthalmic Epidemiology*, vol. 9, no. 5, pp. 325–331, 2002.
- [9] M. Piga and A. Mathieu, "Genetic susceptibility to Behçet's disease: role of genes belonging to the MHC region," *Rheumatology*, vol. 50, no. 2, pp. 299–310, 2011.
- [10] K. T. Calamia, F. C. Wilson, M. Icen, C. S. Crowson, S. E. Gabriel, and H. M. Kremers, "Epidemiology and clinical characteristics of behçet's disease in the us: a population-based study," *Arthritis Care and Research*, vol. 61, no. 5, pp. 600–604, 2009.
- [11] C. C. Zouboulis, I. Kötter, D. Djawari et al., "Epidemiological Features of Adamantiades-Behçet's Disease in Germany and in Europe," *Yonsei Medical Journal*, vol. 38, no. 6, pp. 411–422, 1997.
- [12] N. G. Papoutsis, M. B. Abdel-Naser, A. Altenburg et al., "Prevalence of Adamantiades-Behçet's disease in Germany and the municipality of Berlin: results of a nationwide survey," *Clinical and Experimental Rheumatology*, vol. 24, no. 5, p. S125, 2006.
- [13] A. Gl, A. H. Hajeer, J. Worthington, J. H. Barrett, W. E. R. Ollier, and A. J. Silman, "Evidence for linkage of the HLA-B locus in Behçet's disease, obtained using the transmission Prevalence test," *Arthritis and Rheumatism*, vol. 44, no. 1, pp. 239–240, 2001.
- [14] M. De Menthon, M. P. LaValley, C. Maldini, L. Guillevin, and A. Mahr, "HLA-B51/B5 and the risk of Behçet's disease: a systematic review and meta-analysis of case-control genetic association studies," *Arthritis Care and Research*, vol. 61, no. 10, pp. 1287–1296, 2009.
- [15] Y. Takemoto, T. Naruse, K. Namba et al., "Re-evaluation of heterogeneity in HLA-B510101 associated with Behçet's disease," *Tissue Antigens*, vol. 72, no. 4, pp. 347–353, 2008.
- [16] D. Middleton, L. Menchaca, H. Rood, and R. Komerofsky, "New allele frequency database: <http://www.allelefrequencies.net/>," *Tissue Antigens*, vol. 61, no. 5, pp. 403–407, 2003.
- [17] C. Zouboulis, P. Buttner, D. Djawari et al., "HLA-Class I antigens in German patients with Adamantiades-Behçet's disease and correlation with clinical manifestations," in *Behçet's Disease*, P. Godeau and B. Wechsler, Eds., pp. 175–180, Elsevier, Amsterdam, The Netherlands, 1993.
- [18] Z. S. Alekberova, V. I. Madanat, I. S. Polianskaia, and T. B. Prokaeva, "The HLA-B5 immunogenetic marker in Behçet's disease," *Terapevticheskii Arkhiv*, vol. 65, no. 5, pp. 12–14, 1993.
- [19] A. U. Muftuoglu, H. Yazici, and S. Yurdakul, "Behçet's disease: Lack of correlation of clinical manifestations with HLA antigens," *Tissue Antigens*, vol. 17, no. 2, pp. 226–230, 1981.
- [20] M. Takeno, A. Kariyone, N. Yamashita et al., "Excessive function of peripheral blood neutrophils from patients with Behçet's disease and from HLA-B51 transgenic mice," *Arthritis and Rheumatism*, vol. 38, no. 3, pp. 426–433, 1995.
- [21] H. Yasuoka, Y. Okazaki, Y. Kawakami et al., "Autoreactive CD8+ cytotoxic T lymphocytes to major histocompatibility complex class I chain-related gene A in patients with Behçet's disease," *Arthritis and Rheumatism*, vol. 50, no. 11, pp. 3658–3662, 2004.
- [22] A. Sensi, R. Gavioli, S. Spisani et al., "HLA B51 antigen associated with neutrophil hyper-reactivity," *Disease Markers*, vol. 9, no. 6, pp. 327–331, 1991.
- [23] N. Mizuki, S. Ohno, H. Ando et al., "A strong association between HLA-B(5)101 and Behçet's disease in Greek patients," *Tissue Antigens*, vol. 50, no. 1, pp. 57–60, 1997.
- [24] I. Pirim, M. Atasoy, M. Ikbali, T. Erdem, and C. Aliagaoglu, "HLA class I and class II genotyping in patients with Behçet's disease: a regional study of eastern part of Turkey," *Tissue Antigens*, vol. 64, no. 3, pp. 293–297, 2004.
- [25] K. S. Park, J. S. Park, J. H. Nam, D. Bang, S. Sohn, and E. S. Lee, "HLA-E0101 and HLA-G010101 reduce the risk of Behçet's disease," *Tissue Antigens*, vol. 69, no. 2, pp. 139–144, 2007.
- [26] N. Mizuki, M. Ota, Y. Katsuyama et al., "Association analysis between the MIC-A and HLA-B alleles in Japanese patients with Behçet's disease," *Arthritis and Rheumatism*, vol. 42, no. 9, pp. 1961–1966, 1999.
- [27] Y. Fei, R. Webb, B. L. Cobb, H. Direskeneli, G. Saruhan-Direskeneli, and A. H. Sawalha, "Identification of novel genetic susceptibility loci for Behçet's disease using a genome-wide association study," *Arthritis Research and Therapy*, vol. 11, no. 3, article R66, 2009.
- [28] E. F. Remmers, F. Cosan, Y. Kirino et al., "Genome-wide association study identifies variants in the MHC class I, IL10, and IL23R-IL12RB2 regions associated with Behçet's disease," *Nature Genetics*, vol. 42, no. 8, pp. 698–702, 2010.
- [29] N. Mizuki, A. Meguro, M. Ota et al., "Genome-wide association studies identify IL23R-IL12RB2 and IL10 as Behçet's disease susceptibility loci," *Nature Genetics*, vol. 42, no. 8, pp. 703–706, 2010.
- [30] A. Meguro, H. Inoko, M. Ota et al., "Genetics of Behçet disease inside and outside the MHC," *Annals of the Rheumatic Diseases*, vol. 69, no. 4, pp. 747–754, 2010.
- [31] J. Karasneh, A. Gül, W. E. Ollier, A. J. Silman, and J. Worthington, "Whole-genome screening for susceptibility genes in multicase families with Behçet's disease," *Arthritis and Rheumatism*, vol. 52, no. 6, pp. 1836–1842, 2005.
- [32] C. C. Zouboulis, "Epidemiology of Adamantiades-Behçet's disease," *Annales de Medecine Interne*, vol. 150, no. 6, pp. 488–498, 1999.
- [33] T. Akpolat, Y. Koç, I. Yeniay et al., "Familial Behçet's disease," *The European journal of medicine*, vol. 1, no. 7, pp. 391–395, 1992.
- [34] J. L. Villanueva, J. Gonzalez-Dominguez, R. Gonzalez-Fernandez, J. L. Prada, J. Pena, and R. Solana, "HLA antigen familial study in complete Behçet's syndrome affecting three sisters," *Annals of the Rheumatic Diseases*, vol. 52, no. 2, pp. 155–157, 1993.
- [35] S. Bird and J. A. Stewart, "Genetic analysis of families of patients with Behçet's syndrome: data incompatible with autosomal recessive inheritance," *Annals of the Rheumatic Diseases*, vol. 45, no. 4, pp. 265–268, 1986.
- [36] N. Molinari, I. Koné Paut, R. Manna, J. Demaille, J. P. Daures, and I. Touitou, "Identification of an autosomal recessive mode of inheritance in paediatric Behçet's families by segregation analysis," *American Journal of Medical Genetics*, vol. 122, no. 2, pp. 115–118, 2003.
- [37] I. Fresko, M. Soy, V. Hamuryudan et al., "Genetic anticipation in Behçet's syndrome," *Annals of the Rheumatic Diseases*, vol. 57, no. 1, pp. 45–48, 1998.
- [38] R. Treudler, C. E. Orfanos, and C. C. Zouboulis, "Twenty-eight cases of juvenile-onset Adamantiades-Behçet disease in Germany," *Dermatology*, vol. 199, no. 1, pp. 15–19, 1999.

- [39] M. Laghmari, A. Karim, F. Allali et al., "Childhood Behçet's disease: clinical and evolutive aspects. About 13 cases," *Journal Francais d'Ophthalmologie*, vol. 25, no. 9, pp. 904–908, 2002.
- [40] I. Koné-Paut, I. Geisler, B. Wechsler et al., "Familial aggregation in Behçet's disease: high frequency in siblings and parents of pediatric probands," *Journal of Pediatrics*, vol. 135, no. 1, pp. 89–93, 1999.
- [41] A. Gül, M. Inanc, L. Ocal, O. Aral, and M. Konice, "Familial aggregation of Behçet's disease in Turkey," *Annals of the Rheumatic Diseases*, vol. 59, no. 8, pp. 622–625, 2000.
- [42] A. Gül, F. A. Uyar, M. Inanc et al., "Lack of association of HLA-B*51 with a severe disease course in Behçet's disease," *Rheumatology*, vol. 40, no. 6, pp. 668–672, 2001.
- [43] S. Masatlioglu, E. Seyahi, E. Tahir Turanli et al., "A twin study in Behçet's syndrome," *Clinical and Experimental Rheumatology*, vol. 28, no. 4, supplement 60, pp. S62–S66, 2010.
- [44] T. Kobayashi, Y. Sudo, S. Okamura et al., "Monozygotic twins concordant for intestinal Behçet's disease," *Journal of gastroenterology*, vol. 40, no. 4, pp. 421–425, 2005.
- [45] V. Hamuryudan, S. Yurdakul, F. Ozbakir, H. Yazici, and H. Hekim, "Monozygotic twins concordant for Behçet's syndrome," *Arthritis and Rheumatism*, vol. 34, no. 8, pp. 1071–1072, 1991.
- [46] A. Gül, M. Inanc, L. Ocal, O. Aral, M. Carin, and M. Konice, "HLA-B51 negative monozygotic twins discordant for Behçet's Disease," *British Journal of Rheumatology*, vol. 36, no. 8, pp. 922–923, 1997.
- [47] S. Yilmaz and K. A. Cimen, "Familial Behçet's disease," *Rheumatology International*, vol. 30, no. 8, pp. 1107–1109, 2010.
- [48] U. Tursen, L. Tamer, G. Eskandari et al., "Glutathione S-transferase polymorphisms in patients with Behçet's disease," *Archives of Dermatological Research*, vol. 296, no. 4, pp. 185–187, 2004.
- [49] I. Krause and A. Weinberger, "Behçet's disease," *Current Opinion in Rheumatology*, vol. 20, no. 1, pp. 82–87, 2008.
- [50] H. Yanagihori, N. Oyama, K. Nakamura, N. Mizuki, K. Oguma, and F. Kaneko, "Role of IL-12B promoter polymorphism in Adamantiades-Behçet's disease susceptibility: an involvement of Th1 immunoreactivity against *Streptococcus sanguinis* antigen," *Journal of Investigative Dermatology*, vol. 126, no. 7, pp. 1534–1540, 2006.
- [51] W. C. Jang, Y. H. Nam, Y. C. Ahn et al., "Interleukin-17F gene polymorphisms in Korean patients with Behçet's disease," *Rheumatology International*, vol. 29, no. 2, pp. 173–178, 2008.
- [52] Z. Jiang, P. Yang, S. Hou et al., "IL-23R gene confers susceptibility to Behçet's disease in a Chinese Han population," *Annals of the Rheumatic Diseases*, vol. 69, no. 7, pp. 1325–1328, 2010.
- [53] G. Polat, G. Eskandari, T. I. Kaya et al., "Association of the platelet glycoprotein Ia C807T/G873A gene polymorphism and thrombosis in behçet patients," *Haematologia*, vol. 32, no. 2, pp. 121–128, 2002.
- [54] A. Gül, U. Özbek, C. Öztürk, M. Inanç, M. Koniçe, and T. Özcelik, "Coagulation factor V gene mutation increases the risk of venous thrombosis in Behçet's disease," *British Journal of Rheumatology*, vol. 35, no. 11, pp. 1178–1180, 1996.
- [55] C. Salvarani, K. Calamia, M. Silingardi, A. Ghirarduzzi, and I. Olivieri, "Thrombosis associated with the prothrombin G → A20210 mutation in Behçet's disease," *Journal of Rheumatology*, vol. 27, no. 2, pp. 515–516, 2000.
- [56] U. Tursen, T. I. Kaya, G. Eskandari et al., "Association of factor V Leiden and prothrombin gene mutation with Behçet's disease," *Archives of Dermatological Research*, vol. 293, no. 10, pp. 537–539, 2001.

Review Article

New Evidence-Based Treatment Approach in Behçet's Disease

Erkan Alpsoy

Department of Dermatology and Venerology, Akdeniz University School of Medicine, 07059 Antalya, Turkey

Correspondence should be addressed to Erkan Alpsoy, ealpsoy@akdeniz.edu.tr

Received 20 June 2011; Accepted 1 August 2011

Academic Editor: Ümit Tursen

Copyright © 2012 Erkan Alpsoy. This is an open access article distributed under the Creative Commons Attribution License, which permits unrestricted use, distribution, and reproduction in any medium, provided the original work is properly cited.

Behçet's disease (BD) is a chronic, relapsing, and debilitating systemic vasculitis of unknown aetiology with the clinical features of mucocutaneous lesions, ocular, vascular, articular, neurologic, gastrointestinal, urogenital, and pulmonary involvement. The disease is much more frequent along the ancient "Silk Route" extending from Eastern Asia to the Mediterranean basin, compared with Western countries. The disease usually starts around the third or fourth decade of life. Male sex and a younger age of onset are associated with more severe disease. Although the treatment has become much more effective in recent years, BD is still associated with severe morbidity and considerable mortality. The main aim of the treatment should be the prevention of irreversible organ damage. Therefore, close monitoring, early, and appropriate treatment is mandatory to reduce morbidity and mortality. The treatment is mainly based on the suppression of inflammatory attacks of the disease using immunomodulatory and immunosuppressive agents. In this paper, current state of knowledge regarding the therapeutic approaches is outlined. To provide a rational framework for selecting the appropriate therapy along the various treatment choices, a stepwise, symptom-based, evidence-based algorithmic approach was developed.

1. Introduction

Behçet's disease (BD) is a chronic, relapsing, and debilitating systemic vasculitis of unknown aetiology with the clinical features of mucocutaneous lesions, ocular, vascular, articular, neurologic, gastrointestinal, urogenital, and pulmonary involvement [1]. BD usually starts around the third or fourth decade of life. Recent epidemiologic surveys [2–4] suggest that sex distribution is roughly equal. The disease is particularly prevalent in "Silk Route" populations but has global distribution. The prevalence of the disease is 14–20 per 100 000 along the Silk route [5]. Turkey has the highest prevalence. Azizlerli et al. from Istanbul reported the prevalence of the disease to be nearly 1/250 of the population aged 12 or older [2]. BD is rarely seen in western countries. The prevalence of the disease in England is less than 1/100 000 [5, 6]. This marked geographic variation of BD can be explained by the genetic basis of the disease and/or environmental triggers. The diagnosis is based on clinical criteria, as there is no pathognomonic test. Although several immunological abnormalities have been demonstrated, the exact mechanism of the inflammatory changes occurring remains to be elucidated. The most probable hypothesis is

that of an inflammatory reaction set off by infectious agents such as herpes simplex virus 1 or *Streptococcus* spp. or by an autoantigen such as heat shock proteins in genetically predisposed individuals [7–9].

Mucocutaneous lesions figure prominently in the presentation and diagnosis and may be considered the hallmarks of BD. Oral ulcers (OUs), genital ulcers (GUs), and cutaneous lesions together with ocular lesions and arthropathy are the most frequent features of the disease in all countries. Mucocutaneous lesions often precede other manifestations. Therefore, their recognition may permit earlier diagnosis and treatment, with salutary results [5]. OUs are characterized by recurrent and painful ulcerations of the oral mucosa. They are identical to aphthae in appearance, but they tend to be more frequent and multiple. The most common sites are the mucous membranes of the lips, buccal mucosa, tongue, and soft palate. GUs are similar in appearance and course to OUs, but may not recur as often. They are usually deeper than the OUs and have a scarring tendency. The labia is the most frequently involved site in females and scrotum in males. Relapsing bipolar oral and genital ulcers are strongly evocative of BD [5]. Papulopustular lesions (PPLs)

are sterile, folliculitis, or acne-like lesions on erythematous base which appear as a papule and in the course of a 24–48 hours become pustule. Trunk and the lower limbs are the most common locations [10]. Erythema nodosum (EN) is mostly seen in females and occur in about one-third of all patients. They have a typical clinical presentation with bilateral, pretibial, painful, and hot erythematous nodules. Other cutaneous lesions such as Sweet's syndrome-like, pyoderma gangrenosum-like, erythema multiforme-like lesions, extragenital ulcers, and palpable purpura can be seen during the course of the disease [1, 5, 11]. The skin pathergy test is a nonspecific skin hyperreactivity, induced by needle prick. The test positivity is defined as the development of a papule or pustule at the needle-prick site at 48 h. It is more strongly positive among males. Test positivity varies between geographic areas and has been reported to be high especially in Japan and the Mediterranean Sea countries (50–70%) [5].

Ocular involvement is a serious complication of BD and is characterized by repeated, explosive inflammatory attacks that may lead to visual loss in almost 15% of eyes. Panuveitis is the most frequent ocular lesion in BD. Anterior uveitis, posterior uveitis, and retinal vasculitis are the other main ocular manifestations. They are bilateral in most of the patients [12]. Articular involvement is characterized by nonerosive and nondeforming arthritis which often presents with monoarticular pattern, although asymmetrical polyarthritis can occur. The articular involvement is usually transient in nature with episodes lasting from a few days to weeks [13]. The disease is a systemic vasculitis affecting arteries and veins of various sizes. Venous system is the major affected site, and subcutaneous thrombophlebitis is, indeed, the most frequent type of venous involvement. Thromboses of the inferior vena cava and superior vena cava, dural sinuses, and Budd-Chiari syndrome can also be seen and are associated with poor prognosis. Pulmonary arterial aneurysm is rare; however, it is important cause of mortality [14]. Neurological involvement is relatively rare, but one of the most serious complications of the disease due to its grave prognosis. Parenchymal involvement including brainstem involvement, hemispheric manifestations, spinal cord lesions, and meningoencephalitis is seen in the majority of patients (80%). Dural sinus thrombi presenting with headaches and papilledema appear in 20% of patients with neurological involvement and have a more benign course [15]. Gastrointestinal involvement is characterized by aphthous-like mucosal ulcers occurring predominantly in the ileocaecal region, although it can occur throughout the gastrointestinal tract [16].

BD runs a chronic course with unpredictable exacerbations and remissions. In a recent multicenter study [17], we aimed retrospectively to determine the occurrence of the symptoms in chronological order. We also evaluated the influence of the treatment and followup on the clinical severity and tried to obtain the factors determining the severe organ involvement in 661 patients. OUs were the most common manifestation (100%) followed by GUs (85.3%), PPLs (55.4%), EN (44.2%), skin pathergy reaction (37.8%), and articular (33.4%) and ocular involvement (29.2%). OUs were the most common onset manifestation (88.7%)

which was followed by GUs (14.2%), EN (5.7%), and ocular involvement (4.2%). The duration between the onset symptom and the fulfilment of diagnostic criteria was calculated to be 4.3 ± 5.7 years. The frequency of ocular involvement and GUs was significantly higher in patients whose disease onset was less than 40 years. GUs, ocular involvement, PPLs, thrombophlebitis, and skin pathergy reaction were found to be significantly higher in males. The clinical severity of the disease showed a significant increase in noncompliant treatment group compared with compliant group with the passage of time. Our study showed that mucocutaneous lesions are the hallmarks of the disease, and especially OUs precede other manifestations. Male sex and a younger age of onset are associated with more severe disease.

Each or any combination of mucocutaneous, articular, and ocular symptoms of the disease may have significant pain or loss in function, or both. Besides considerable morbidity, the disease confers an increased mortality, mainly due to large vessel (especially pulmonary arterial) and neurologic involvement as well as bowel perforation. In general, mortality ratios as well as mucocutaneous and articular manifestations tend to decrease significantly with the passage of time. Both the onset of eye disease and its greatest damage are usually within the first few years of disease onset. A recent study [14] has shown that neurologic and large vessel involvements are exceptions, and they can have their onset late (5–10 years) during the disease course. In our multicenter study [17], in addition to these involvements, gastrointestinal involvement was also found to be a late manifestation of the disease. Therefore, all these results stress the importance of vigilance in long-term surveillance of patients with BD. Close monitoring and appropriate treatments are mandatory to decrease the morbidity and mortality of the disease since the disease shows a continuous activity.

2. Treatment

Treatment of the disease has become much more effective in recent years because of advances in understanding the pathogenesis the underlying disease and availability of a wide spectrum of therapeutic agents. Although several effective treatments currently exist, none of them result in a cure of the disease and some are associated with significant side effects. The choice of treatment is generally based on the clinical presentation and the site affected. However, the main aim of the treatment should be the prevention of irreversible organ damage, especially, during the early, active phase of the disease. Close monitoring and appropriate treatment may control and change the course of the disease. It is wise to remember that especially male patients and those with early onset disease are associated with more severe presentations including major vessel disease, ocular, gastrointestinal, and neurological involvement and, therefore, require more aggressive treatment [18].

This paper overviews the current state of knowledge regarding the therapeutic approaches for BD. Based on the mainly controlled studies and personal experience in clinical practice and basic research in this field, a stepwise,

symptom-based, evidence-based algorithmic approach for the management of BD was proposed. This approach might enable clinicians to rationalize and further increase the selection of the most appropriate therapy among numerous treatment options [18].

2.1. Topical Treatment. The majority of experience in the treatment of OUs comes from the studies performed in patients with recurrent aphthous stomatitis (RAS). As we mentioned before, OUs of BD are identical to RAS in appearance. Therefore, therapeutic remedies related with RAS, to some extent, can be applied to OUs of BD.

Although controlled studies are still lacking, the efficacy of topical *corticosteroids* is indisputable based on their favorable and widespread use. Topical corticosteroids suppress the inflammation associated with the formation of aphthae, and they are effective on both OUs and GUs especially when they are used in the early stage of these lesions. They reduce the pain severity and healing duration. Triamcinolone acetonide as cream 0.1% in Orabase or spray, prednisolone tablets in 20 mL water as rinse four times daily like those of dexamethasone elixir (0.5 mg/5 mL) can be used for OUs. Potent corticosteroid creams alone or in conjunction with antiseptics are also effective in GUs. Major OUs or GUs can be treated by intralesional triamcinolone, 5–10 mg/mL. Topically applied corticosteroid eye drops may also be used in mild attacks of anterior and intermediate uveitis together with mydriatics or cycloplegic agents [19]. *Antimicrobial agents* including antiseptic agents and antibiotics are used to control microbial load [1]. Two controlled studies with antiseptic agents, listerine mouth rinse [20], and chlorhexidine gel [21] in RAS noted the effectiveness on the pain severity and duration. Triclosan, a broad-spectrum antibacterial agent has been shown to reduce the number of aphthous ulcers in a double-blind cross-over study in RAS patients [22]. Antibiotics, especially tetracycline has been widely used in OUs of BD for years. Tetracycline mouthwash (250 mg capsules dissolved in 5 mL of water or flavored syrup and held in the mouth for about 2 minutes before swallowing four times daily) decrease pain severity and duration of OUs. A double-blind trial of tetracycline suspension showed significant reductions in ulcer duration, size, and pain in RAS patients [23]. A recent study [24] assessed 0.2 percent minocycline and 0.25 percent tetracycline aqueous solution mouthwash in patients with RAS in a clinical randomized crossover trial. Minocycline mouthwashes as compared to topical tetracycline rinses resulted in significantly improved pain control, by reducing the severity and duration of pain. Cephalexin [25] and penicillin G [26] have also been reported to be effective antibiotics. *Sucralfate* (1 g/5 mL), 4 times daily, for 3-month duration as mouthwash, decreases significantly the frequency, healing time, and pain of OUs and healing time and pain of GUs. The effectiveness of the sucralfate on the OUs frequency and healing time continue during the posttreatment period in decreasing order [27]. This compound binds to ulcerated tissue and forms a barrier and augments ulcer healing. Recent controlled studies suggest that *pimecrolimus*, a topical immunomodulator, twice a day seems to be safe and efficient in the treatment

of genital ulcers, by accelerating the healing process and shortening the pain duration [28, 29]. *Amlexanox* accelerate the healing and decreases the pain severity of oral ulcers. It has anti-inflammatory and antiallergic activities [30, 31]. Amlexanox is used in oral paste (5%) 4 times daily (after meals and at bedtime) for 4–10 days. *Anti-inflammatory agents* (benzydamine, diclofenac), *anaesthetics* (lidocaine 2–5%, mepivacaine 1.5%, tetracaine 0.5–1% gels, or mucosal ointments), and *silver nitrate*, in general reduce the pain severity of aphthous lesions [5, 32, 33]. Recently, beneficial effects of *colony stimulating factor* on the healing duration and pain severity of OUs and GUs have been reported by our group [34].

In addition to the above-mentioned treatment approaches to OUs, patients should be advised to maintain good daily oral hygiene [35]. These patients should avoid irritating agents such as acid, crusty, hard, spicy, or salty nutrients and alcoholic beverages. EN is treated topically like classic EN. *Wet dressings* such as aluminium acetate 3–5% (Burow's solution) can be applied in early stage of these lesions. This approach is also helpful for the treatment of superficial thrombophlebitis. All therapy should be combined with rest in bed.

2.2. Systemic Treatment

2.2.1. Corticosteroids. Corticosteroids have been widely used almost for all lesions of the disease. The compound is an effective choice especially in mucocutaneous lesions, acute uveitis, and neurologic disease. They can be given as monotherapy or in combination with other drugs such as colchicine, interferon (IFN)- α , cyclosporine, or azathioprine. However, in a recent randomized, placebo-controlled study of 86 patients who had active mucocutaneous lesions without eye and major organ involvement, low dose depot steroid (40 mg of methylprednisolone acetate every 3 weeks) was only found to be helpful in controlling EN, especially among females [36]. However, this result does not mean the compound is not effective in daily and/or higher doses. On the other hand, the well-known side effect profile limits their long-term use, and more corticosteroids do not improve the long-term outcome.

2.2.2. Colchicine. Colchicine inhibits the enhanced chemotactic activity of neutrophils. Promising results with colchicine (0.5–2 mg/d p.o.) have been reported especially in mucocutaneous and articular findings. The first placebo-controlled study suggested that the drug is effective only for EN and arthralgia [37]. Yurdakul et al., in a randomized placebo-controlled study [38], revisited the issue and have shown that colchicine reduces the occurrence of GUs, EN, and arthritis among women and the occurrence of arthritis among men. Although oligozoospermia, amenorrhea, or dysmenorrhea, malaise, hair loss, gastrointestinal complaints (nausea, vomiting, diarrhea), and hematologic side effects are recorded as the main adverse effects of colchicine, Yurdakul et al. [38] reported no significant difference between the groups.

Recently, Davatchi et al. [39], in a large cohort of BD patients (169 patients without major organ involvement), reevaluated the efficacy of colchicine. In this randomized, double-blind, controlled crossover trial, the overall disease activity index and OUs, GUs, PPLs, and EN improved significantly with colchicine. There was not any significant difference between the results for males and females.

2.2.3. Benzathine Penicillin. Calguneri et al. [40] have found that the combined use of colchicine and benzathine penicillin (1.2 MU/3 weeks) treatment more effective than colchicine alone. Combined treatment was effective in reducing frequency and duration of OUs and EN and the frequency of GUs. Combined treatment also significantly reduced the number of arthritis episodes and prolonged the duration of episode-free time compared with the colchicine-alone group. Recently Al-Waiz et al. [41] showed that combined use of colchicine (1 g/d) and benzathine penicillin (1.2 MU/m) is more effective in decreasing clinical manifestation index, the numerical sum of the clinical features, than in either drug alone.

2.2.4. Rebamipide. In a double-blind, placebo-controlled study of 35 BD patients, having as the main symptom OUs, Matsuda et al. [42] used rebamipide (300 mg/day) for 3 to 6 months. They reported that the rate of moderate or marked improvement in OUs count and pain was 36% in the placebo group and 65% in the drug group. Authors concluded that rebamipide may be useful in the treatment and prevention of recurrences of OUs. No significant adverse effect has been reported.

2.2.5. Zinc Sulfate. In a recent controlled study of 32 patients, Sharquie et al. [43] evaluated the efficacy of zinc sulfate in a double-blind, crossover study and reported an improvement in the clinical manifestations index of mucocutaneous lesions without any side effect.

2.2.6. Dapsone. Dapsone also inhibits the enhanced chemotactic activity of neutrophils and can be used as an alternative compound to colchicine. In a double-blind, crossover study of 20 patients, Sharquie et al. reported significant reductions in the number, duration, and frequency of OUs and number of GUs in dapsone-treated patients. This compound also showed a significant decrease in the frequency of EN and PPLs. Arthritis and epididymitis were also significantly suppressed by dapsone, but the effect of the compound on arthralgia failed to reach the level of statistical significance [44]. Hemolytic anemia and methemoglobinemia, which can be severe in patients with glucose-6-phosphate dehydrogenase deficiency, are the main side effects, which may significantly limit their use.

Despite the encouraging results of the last three studies, a limited number of patients included, and a relatively short follow-up periods were the main limitations.

2.2.7. Thalidomide. The drug selectively inhibits TNF- α synthesis. In a randomised, double blind, placebo-controlled

study with 63 patients, a remission of OUs, GUs, and PPLs was detected in 22% of the patients over 8 weeks. During the 6-month treatment 30% of the patients remained free of lesions. Thalidomide therapy, however, was associated with exacerbation of EN [45]. In addition, the effects of the drug are temporary, and discontinuation of the treatment results in recurrence of the OUs and GUs. The effectiveness of the thalidomide is lost about 20 days after discontinuation of the drug. Neurological side effects and teratogenic risk of thalidomide limit the clinical application.

2.2.8. Azathioprine. Azathioprine, an important disease-modifying compound, shows an anti-inflammatory effect by suppressing both cellular and humoral immune responses. In a randomised, double-blind, placebo-controlled study [46] of 73 patients, azathioprine has been found to be an effective choice in OUs and GUs besides ocular inflammation and arthritis. Azathioprine was significantly better than placebo in preventing the development of new eye disease. Therefore, the authors concluded that the drug can be used prophylactically to prevent the eye involvement in young, male patients presenting with severe mucocutaneous lesions. Myelotoxicity, gastrointestinal complaints, immunosuppression, opportunistic infections, and hepatotoxicity are the main side effects.

2.2.9. Cyclophosphamide. Cyclophosphamide is the fast-acting alkylating agent. It has been found as a beneficial therapeutic agent for eye disease and systemic vasculitis (neurologic involvement and arterial aneurysms). In a double-blind crossover study [47], it has been shown that the combination of cyclophosphamide and corticosteroid therapy is superior to corticosteroid therapy alone in eye involvement. Myelosuppression, pulmonary fibrosis, renal toxicity, hemorrhagic cystitis, infertility, malignancy, and alopecia are the major adverse effects of cyclophosphamide. Due to the severe toxicity, cyclophosphamide should be selected in cases with clinically significant disease who are refractory to other agents.

2.2.10. Cyclosporin A. Cyclosporin A (CyA) is an immunosuppressant agent which selectively inhibits T lymphocytes. The drug is capable of markedly ameliorating uveitis as well as mucocutaneous lesions. CyA is still one of the most effective agents for the treatment of uveitis which reduces the frequency of ocular exacerbations and improves visual acuity. In a controlled study of 96 patients with recurrent uveitis, CyA (10 mg/kg/d) has been shown to be superior to colchicine (1 mg/d) in decreasing frequency and severity of ocular attacks [48]. In the study of BenEzra et al. [49], CsA was more effective than conventional therapy (prednisolone, chlorambucil) in decreasing the active ocular inflammatory processes and arresting the deterioration of visual acuity. However, conventional therapy was superior to CsA in controlling OUs, GUs, and arthritis. Elidan et al. [50] reported that CyA is significantly better than conventional therapy (prednisolone, chlorambucil) at improving hearing loss. Five of 20 Behçet patients under CyA therapy demonstrated

improvement in their hearing loss. In a comparative study [51], a significant improvement in visual acuity during the first 6 months in CyA (5 mg/kg/d) group compared with cyclophosphamide (1000 mg/mo) was observed. However, this favorable effect of CyA was not sustained in the followup of patients up to 24 months. In another controlled trial [52], 26 patients treated with CyA with a dose of 5 mg/kg/d have been compared with 50 patients receiving conventional therapy, systemic corticosteroid alone or combined with azathioprine. CyA treatment was found to be more effective in reducing OUs, GUs, cutaneous lesions, thrombophlebitis as well as articular symptoms and neurologic symptoms. Therefore, CyA is also an effective alternative for mucocutaneous lesions; however, it should be reserved for the most severe cases because of its significant long-term adverse effects such as renal failure, hypertension, neurologic toxicity, and hirsutism. It is wise to remember that neurological manifestations occur more frequently in BD patients under CyA treatment [53].

2.2.11. Interferon- α . In recent years, the increasing evidence suggests that interferon (IFN)- α is an effective alternative in the treatment of BD. The mode of action of IFN- α in BD is still unknown. However, their antiviral and immunomodulatory effects appear to be the possible mechanisms. In a randomised, double-blind, placebo-controlled study [54], we have shown that IFN- α 2a treatment is an effective alternative particularly for the management of mucocutaneous lesions, and its effect decreases gradually after the cessation of treatment. IFN- α 2a treatment decreased significantly the duration and pain of OUs and the frequency of GUs and PPLs. Although not significant, the mean frequency and duration of EN, thrombophlebitis, and articular symptoms also showed a decrease. Hamuryudan et al. [55], in their 48-week open, self-controlled trial, reported that IFN- α 2b significantly reduced the mean number of arthritis attacks.

IFN- α has also been employed in cases of sight-threatening refractory uveitis with promising results. Kötter et al. in their open-label, prospective study [56] used IFN- α 2a in 50 patients at a dose of 6 million IU (MIU) daily, tapered according to a preset schedule. The authors concluded that IFN- α 2a is effective in ocular BD, leading to significant improvement of vision and complete remission of ocular vasculitis in the majority of the patients. Tugal-Tutkun et al. [57] evaluated the IFN- α treatment in 44 patients with uveitis unresponsive to conventional immunosuppressive therapy. Although the overall response rate was 91%, complete response rate (36.4%) was lower than that of the study of Kötter et al. In a newer study, Onal et al. [58] investigated the long-term efficacy and safety of low dose (3.0 MIU daily for 14 days, maintenance dose, 3 MIU 3 times per week for 24 months) therapy of IFN- α 2a in 37 patients with refractory Behçet panuveitis unresponsive to conventional immunosuppressive therapy. During maintenance therapy, IFN- α 2a controlled uveitis in 35 patients (95%). In 15 patients (41%), a maintenance dosage of 3 MIU 3 times per week controlled uveitis without any relapse. Remission rate after discontinuation of IFN- α 2a therapy was 76% by 3 months. Therapeutic response rate

differences of ocular BD with IFN- α treatment among the respected studies might have been caused by the different patient populations studied and the different dose schedules. Nevertheless, taken together, IFN- α 2a seems to be able to control and achieve remission of uveitis in most patients with refractory ocular BD.

The primary side effects of IFN- α therapy are flulike symptoms (fever, chills, headache, fatigue, myalgia, etc.) that start a few hours after the initiation of the therapy and continue less than a day. We use oral acetaminophen (paracetamol) 1000 mg orally before injections and 500 mg after 6 hours during the first weeks of the therapy to decrease these side effects. Nausea, vomiting, anorexia, diarrhea, loss of weight, hematologic changes, transient raising of hepatic transaminases are seen less frequently. Psychiatric side effects and depression are limiting factors for use of IFN- α .

2.2.12. Anti-TNF- α Agents. Several pieces of evidence indicate that TNF- α plays a critical role in the pathogenesis of BD, and so far, three anti-TNF- α compounds, infliximab, adalimumab, and etanercept, have shown favourable results on preliminary tests. Almost all trials reported encouraging results for recalcitrant mucocutaneous lesions besides ocular and gastrointestinal symptoms, arthritis, and cerebral vasculitis. Anti-TNF- α treatment suppresses almost all manifestations of the disease with an immediate and dramatic response. It also reduces the dosage of immunosuppressors. Therefore, when the disease is associated with vital organ involvement, especially in young male patients, anti-TNF- α agents can also be used because of their potential to improve the survival and prognosis.

The majority of current data related with infliximab comes from the uncontrolled, open studies, small case series, and case reports. The main 3 prospective studies performed by Sfrikakis et al. [59], Ohno et al. [60], and Tugal-Tutkun et al. [61] concentrated on the eye disease and reported promising results. Besides these studies, many small case series and case reports suggest that patients with mucocutaneous lesions, gastrointestinal symptoms, arthritis and cerebral vasculitis exhibit rapid and good responses to infliximab [62]. Recently, adalimumab, a fully humanised anti-TNF- α antibody, has also been reported to be an effective alternative [63].

Melikoglu et al. [64] conducted the first controlled study of anti-TNF- α compound, etanercept. In a double-blind, placebo-controlled study of 40 male patients, authors reported that etanercept (25 mg twice a week for 4 week) is effective in suppressing most of the mucocutaneous lesions. The drug had a clear effect on OUs and nodular lesions, and the response was as early as the first week. There was a significant decrease in the mean numbers of OUs and nodular lesions as well as PPLs.

A recent position paper concluded that infliximab is recommended as an add-on therapy for severe BD, refractory or intolerant to traditional immunosuppressive regimens. Moreover, a single infusion of infliximab (5 mg/kg) can be used as a first-line agent for sight-threatening, bilateral posterior eye segment inflammation, because the fast onset of response is critical to prevent fixed retinal lesions, and

therefore, permanent visual loss. In case when ocular relapses are not controlled by azathioprine and/or cyclosporin, maintenance therapy with 5 mg/kg doses of infliximab every 6–8 weeks could be used for 2 years, provided no relapses occur between intervals [62].

However, the high cost, the need for injections, troublesome toxic side effects, and the inability to cure the disease are the main limitations for widespread acceptance of anti-TNF- α as a first-line choice for the management of BD. Optimal dosage and the long-term consequences are still important questions for anti-TNF- α agents to be answered. It still needs further controlled studies in large series.

Adverse effects of anti-TNF- α agents include infection (sinusitis, pharyngitis, bronchitis, and urinary tract infections, reactivation of tuberculosis), autoimmune reactions (e.g., lupuslike syndrome), lymphoproliferative disorders, delayed hypersensitivity reactions, and neurologic, cardiac, and gastrointestinal symptoms.

2.2.13. Rituximab. Rituximab is a chimeric monoclonal antibody against CD20, a B-cell differentiation marker. Recently, Davatchi et al. [65] used rituximab in their randomized single-blind controlled study. Twenty patients were randomized to a rituximab group (in two 1000 mg courses, 15-day interval) or cytotoxic combination therapy group. Patients with rituximab group were also given methotrexate (15 mg/weekly) with prednisolone (0.5 mg/kg per day). The cytotoxic combination therapy group received pulse cyclophosphamide (1000 mg/monthly), azathioprine (2–3 mg/kg per day), and prednisolone (0.5 mg/kg per day). The authors concluded that rituximab was efficient in severe ocular manifestations of BD, and total adjusted disease activity index improved significantly after 6 months with rituximab, but not with cytotoxic combination therapy group.

2.2.14. Other Systemic Treatment Approaches. Several open studies of *methotrexate* (7.5–20 mg/1x week p.o. over 4 weeks) have reported the induction of an improvement of a severe mucocutaneous involvement [66] as well as neurological [67, 68] and ocular involvement [69]. Methotrexate is not recommended in pregnancy and lactation, and severe bone marrow depression, liver dysfunction, acute infections, renal insufficiency, and mucositis are important side effects of the drug. *Mycophenolate mofetil* (MMF) was found to be safe and effective in controlling cystoid macular oedema and in reducing the uveitis relapse rate in patients not responding to traditional immunosuppressants [70]. On the other hand, an open study reported no benefit in mucocutaneous disease [71]. MMF is generally well tolerated; the most common side effects involve gastrointestinal and genitourinary symptoms. Other reported less frequent adverse events include neurologic, cutaneous, cardiorespiratory, and metabolic reactions. Rarely, severe leukopenia has also been reported. *Autologous hematopoietic stem cell transplantation* has recently been reported as a successful treatment option for severe/refractory patients with intestinal [72], pulmonary [73], and neurologic [74] involvements. Open studies with *Pentoxifylline* reported good results on mucocutaneous

symptoms. However, recurrences occurred in all patients after discontinuation of treatment. Pentoxifylline has also been described as alternative treatments for ocular lesions in few patients with BD [75, 76]. *Sulfasalazine* (2–4 gr/day) was reported to be an effective choice for the treatment of gastrointestinal involvement [77].

2.3. Surgical Treatment. Although various treatment modalities appear, surgical intervention often is indicated for arterial aneurysms. In patients with recurrent or massive hemoptysis, surgery may be necessary. Endovascular treatment for pseudoaneurysms due to BD seems to be an effective choice when the disease activity is strictly controlled with immunosuppressive therapy [78, 79]. In other serious consequences, such as gastrointestinal bowel perforation, enterocutaneous fistula formation, thrombotic obstruction in large-caliber vessels, cardiac involvement, and complications of eye involvement such as glaucoma, vitreous opacities, surgery may also be the only possible remedy [19, 80].

3. Evidenced-Based Algorithmic Treatment Approach in Behçet's Disease

Activity spectrum of systemic therapeutic agents on BD in randomized, controlled studies is summarized in Table 1. A stepwise, symptom-based, algorithmic approach, mainly based on controlled studies and our clinical experience in this field, is summarized below and in Tables 2–6.

3.1. Mucocutaneous Disease. Colchicine should be the first choice in the treatment of GUs and/or EN, especially in female patients [38]. If it is not effective or patient is male, colchicine can be combined with benzathine penicillin [40, 41]. In the presence of OUs with or without other mucocutaneous lesions, this combination should also be the starting point.

Short-term corticosteroids in combination with other drugs such as colchicine can be used as alternatives in the treatment of acute attacks of mucocutaneous lesions [18]. Dapsone can also be used at this stage as an effective compound [44]. Patients with severe mucocutaneous disease or those who are unresponsive to the respected treatments can be treated with azathioprine [46]. Thalidomide [45] is an effective choice. However, because of potential side effects, it should be used cautiously in selected patients. It is wise to keep in mind that EN worsens during thalidomide treatment.

Rebamipide [42], zinc sulfate [43], and Pentoxifylline [75] can be used as 3rd-line treatment choices. However, there is still a need for well-organised newer studies for these agents. In severe cases and/or unresponsive cases to the other treatments, methotrexate [66], cyclosporin [52], and biologicals such as IFN [54] and anti-TNF- α agents [62, 64] can be used to control the disease.

Antimicrobial agents [20–26], sucralfate [27] and corticosteroids [19] especially in OUs, and pimecrolimus [28, 29] in GUs can be selected as 1st-line topical treatment choices. Anti-inflammatory agents, amlexanox, anaesthetics,

TABLE 1: Activity spectrum of systemic therapeutic agents on Behçet's disease in randomized, controlled studies.

Treatment	Dose	Indication and reference
Corticosteroids versus placebo	40 mg/every 3 w	Decrease the frequency of EN in women [36]
	1–2 mg/d	Decreases the frequency of EN and effective on arthralgia [37] Reduces the occurrence of GUs, EN, and arthritis in women and the occurrence of arthritis in men [38]
Colchicine versus placebo	1 mg/d	Decrease in overall disease activity index and significant improvement in OUs, GUs, PPLs, and EN [39]
Colchicine versus Colchicine + Benzathine penicillin	1–2 mg/d; 1.2 MU/3 w	Combined treatment more effective in reducing frequency of arthritic episodes, duration and frequency of OUs and EN, and the frequency of GUs [40]
Colchicine versus Benzathine penicillin versus Colchicine + Benzathine penicillin	1 mg/d; 1.2 MU/mo	Combined use of colchicine and benzathine penicillin treatment more effective than colchicine or penicillin alone [41]
Rebamipide versus placebo	300 mg/d	Reduces the number of OUs and pain [42]
Zinc sulfate versus placebo	300 mg/d	Significant improvement in the clinical manifestations index of mucocutaneous lesions [43]
Dapsone versus placebo	100 mg/d	Effective on the number, healing time and frequency of OUs, number of GUs, and frequency of EN and PPLs. Suppresses arthritis and epididymitis [44]
Thalidomide versus placebo	100–300 mg/d	Sustained remission of OUs, GUs, and PPLs [45]
Azathioprine versus placebo	2,5 mg/kg/d	Reduces the occurrence of OUs, GUs, arthritis, and ocular symptoms. Prevents the development of new eye disease [46]
Cyclophosphamide + Corticosteroids versus Corticosteroids	1 g/m ² /mo	Combined treatment of CCP and corticosteroids more effective in eye disease than corticosteroids alone [47]
Cyclosporin A versus Colchicine	10 mg/kg/d	CyA more effective on the severity and frequency of OUs, GUs, and PPLs. Superior to colchicine in decreasing the frequency and severity of ocular attacks [48]
Cyclosporin A versus conventional treatments (prednisolon, chlorambucil)	10 mg/kg/d	CsA more effective than conventional therapy in ocular disease, however, conventional therapy superior to CyA in controlling OUs, GUs, and arthritis [49]
Cyclosporin A versus conventional treatments (prednisolon, chlorambucil)	10 mg/kg/d	Improvement of hearing loss in 25% of patients receiving CyA treatment [50]
Cyclosporin A versus Cyclophosphamide	5 mg/kg/d	A significant improvement in VA during the first 6 months in CyA group compared with CCP [51]
Cyclosporin A versus conventional treatments (prednisolon, Azathioprine)	5 mg/kg/d	CyA more effective than conventional therapy in OUs, GUs, cutaneous lesions, thrombophlebitis as well as articular and neurologic symptoms [52]
Interferon- α versus placebo	6 MU/d-3 x/w	Effective on pain and healing time of OUs and frequency of GUs and PPLs. Also helpful in decreasing frequency and duration of EN, TFB, and articular symptoms [54]
Etanercept versus placebo	25 mg/d-2 x/w	Reduces the occurrence of OUs, nodular skin lesions, and PPLs [64]
Rituximab versus cytotoxic combination therapy	2 1000-mg courses (15-day interval)	A significant improvement in total adjusted disease activity index in rituximab group [65]

d: day; EN: erythema nodosum; GUs: genital ulcers; Mo: month; OUs: oral ulcers; PPLs: papulopustular lesions; TFB: thrombophlebitis; VA: visual acuity; w: week.

TABLE 2: Summary of evidence-based algorithmic treatment for mucocutaneous Behçet's disease.

1st line	*Topical: Antimicrobial agents, Sucralfate, Corticosteroids, Pimecrolimus Systemic: Colchicine, Colchicine + Benzathine penicillin
2nd line	*Topical: Anti-inflammatory agents, Amlexanox Systemic: Corticosteroids, Dapsone, Azathioprine, Thalidomide
3rd line	*Topical: Anaesthetics, Silver nitrate Systemic: Zinc sulfate, Rebamipide, Pentoxifylline, Methotrexate, Cyclosporine-A, IFN- α , Anti-TNF- α

* Since the effectiveness of topical treatment is generally limited to the application area, it should almost always be associated with systemic therapy.

TABLE 3: Summary of evidence-based algorithmic treatment for articular Behçet's disease.

1st line	Colchicine, Colchicine + Benzathine penicillin, or anti-inflammatory analgesics
2nd line	Azathioprine, Corticosteroids
3rd line	Methotrexate, Salazopyrine, IFN- α , Anti-TNF- α

TABLE 4: Summary of evidence-based algorithmic treatment for ocular Behçet's disease.

1st line	*Topical: corticosteroids + mydriatics \pm cycloplegic agents Systemic: Corticosteroids, Cyclosporine-A, Azathioprine
2nd line	IFN- α , Anti-TNF- α
3rd line	Methotrexate, Mycophenolate mofetil, Cyclophosphamide, Rituximab

* Topical treatment as a sole agent should be restricted to those who has mild uveitis (anterior uveitis).

TABLE 5: Summary of evidence-based algorithmic treatment for Vasculo-Behçet disease.

1st line	Corticosteroids, Azathioprine, Cyclophosphamide,
2nd line	Anti-TNF- α
3rd line	Anticoagulation, Antiplatelets

and silver nitrate [30–33] are other alternatives for topical treatment of mucocutaneous lesions. However, it is very important to ensure for clinician that topical treatment, with a great possibility, has only local effects and should almost always be associated with systemic therapy.

Evidenced based algorithmic treatment approach for mucocutaneous Behçet's disease is summarized in Table 2.

3.2. Articular Disease. Evidenced-based algorithmic treatment approach for articular Behçet's disease is summarized in Table 3.

Colchicine should be the first choice [37, 38]. Additional use of benzathine penicillin or anti-inflammatory analgesics can be the next step [40, 41].

In unresponsive cases, azathioprine [46] can be an alternative. Low dose corticosteroids, and even intraarticular corticosteroid injections in monoarticular involvement, can also be used as 2nd-line treatment [77, 81].

Although controlled studies are still lacking, methotrexate and salazopyrine are used successfully in the clinical practice [77]. IFN- α [55] and anti-TNF- α agents [62] are the other alternatives.

3.3. Ocular Disease. Evidenced-based algorithmic treatment approach for ocular Behçet's disease is summarized in Table 4.

Ocular involvement requires special attention and usually aggressive treatment since it has the highest morbidity. In mild uveitis such as anterior uveitis, topically applied corticosteroid eye drops together with mydriatics

TABLE 6: Summary of evidence-based algorithmic therapy for Neuro-Behçet's disease.

1st line	Corticosteroids
2nd line	Azathioprine, cyclophosphamide, Anti-TNF- α , IFN- α
3rd line	Methotrexate, Anticoagulation

TABLE 7: Summary of evidence-based algorithmic therapy for gastrointestinal Behçet's disease.

1st line	Sulfasalazine, corticosteroids
2nd line	Azathioprine
3rd line	Anti-TNF- α

or cycloplegic agents can often control the disease [19]. Systemic corticosteroids should be the next step. It is wise to remember that systemic corticosteroids are also used in acute inflammatory ocular attacks of posterior uveitis, panuveitis, and retinal vasculitis [18]. Systemic corticosteroids should be used in brief courses for long term because of well-known side effect profile. Unresponsive cases, those with posterior uveitis, or those who develop chronic, steroid-dependent intraocular inflammation (given the deleterious effects of chronic steroid administration to the eye) require more aggressive treatment. Immunosuppressives such as azathioprine [46] and cyclosporine [48, 49, 51] are the main choices. Cyclosporine together with corticosteroids can be used effectively. Azathioprine and cyclosporine can also be combined in those patients whose eye disease is refractory to treatment [18].

As we mentioned before, IFN- α or anti-TNF- α treatments can be used in case when the immunosuppressives do not control the disease [82].

Methotrexate, MMF, cyclophosphamide, and rituximab can be used in selected patients as a 3rd-line therapy [47, 65, 69, 70].

In the most severe cases with retinal vasculitis or macular involvement, CyA or anti-TNF- α treatments can be combined with azathioprine and corticosteroids. Cyclophosphamide and IFN- α with or without corticosteroids are other alternatives for the treatment of severe eye disease [18].

3.4. Severe Disease. Although several promising therapies are evolving, the treatment of severe disease is not entirely satisfactory and treatment of those remains predominantly empirical. Severe disease has relatively lower incidence. Because of the limited number of patients enrolled in studies in this area statistical comparisons were usually not made. These factors make recommendation of individual treatments difficult for these involvements.

Evidenced-based algorithmic treatment approach of Behçet's disease with large vessel, neurologic, and gastrointestinal involvement is summarized in Tables 5–7.

3.4.1. Large Vessel Involvements. In the presence of deep vein thromboses, azathioprine can be used. In severer cases with inferior vena cava or superior vena cava syndrome and Budd-Chiari syndrome cyclophosphamide as monthly

pulse treatment should be added to the treatment. It is unclear the effectiveness of additional use of antiplatelets or anticoagulation [18, 77, 81, 82].

In arterial involvement, corticosteroids together with cyclophosphamide are generally preferred to control the disease. Anticoagulation should not be given in the presence of pulmonary arterial aneurysm because of the danger of bleeding [77, 81, 82]. Anti-TNF- α agents, especially infliximab, can be alternative [18].

Surgery may be necessary in life-threatening conditions such as growing aneurysm, acute rupture [81].

3.4.2. Neurologic Involvements. In parenchymal involvement, corticosteroids (100 mg/d or 1 g 5 days as pulse treatment) should be the first choice. Azathioprine is usually combined with corticosteroids. In severe or unresponsive cases, cyclophosphamide can be given additionally [83]. Anti-TNF- α agents and IFN- α are other new effective alternative agents [19]. Methotrexate is another treatment alternative [67, 68].

In venous sinus thrombosis corticosteroids with or without immunosuppressives are the main treatment approaches. In this situation additional use of anticoagulation is also suggested [81, 83].

3.4.3. Gastrointestinal Disease. Sulfasalazine and corticosteroids seem to be the 1st-line treatment options [77]. Azathioprine can be used effectively in unresponsive cases. Anti-TNF- α treatments, especially infliximab, seem to be new and effective alternative. Surgery should be selected in those patients with perforation and intractable bleeding [18, 81].

In conclusion, treatment of BD has become much more effective in recent years. Due to recent advances in understanding the pathogenesis of the underlying disease and availability of a wide spectrum of therapeutic agents, alleviation of most symptoms, control of the disease, and, even, modification of the course of the disease are now possible.

References

- [1] E. Alpsoy, "Behçet's disease: treatment of mucocutaneous lesions," *Clinical and Experimental Rheumatology*, vol. 23, no. 4, pp. 532–539, 2005.
- [2] G. Azizlerli, A. A. Köse, R. Sarica et al., "Prevalence of Behçet's disease in Istanbul, Turkey," *International Journal of Dermatology*, vol. 42, no. 10, pp. 803–806, 2003.
- [3] A. Gürler, A. Boyvat, and U. Türsen, "Clinical manifestations of Behçet's disease: an analysis of 2147 patients," *Yonsei Medical Journal*, vol. 38, no. 6, pp. 423–427, 1997.
- [4] C. C. Zouboulis, I. Kötter, D. Djawari et al., "Epidemiological features of Adamantiades-Behçet's disease in Germany and in Europe," *Yonsei Medical Journal*, vol. 38, no. 6, pp. 411–422, 1997.
- [5] E. Alpsoy, C. Zouboulis, and G. E. Ehrlich, "Mucocutaneous lesions of Behçet's disease," *Yonsei Medical Journal*, vol. 48, no. 4, pp. 573–585, 2007.
- [6] M. A. Chamberlain, "Behçet's syndrome in 32 patients in Yorkshire," *Annals of the Rheumatic Diseases*, vol. 36, no. 6, pp. 491–499, 1977.
- [7] A. Akman, N. Sallakci, H. Kacaroglu et al., "Relationship between periodontal findings and the TNF- α Gene 1031T/C polymorphism in Turkish patients with Behçet's disease," *Journal of the European Academy of Dermatology and Venereology*, vol. 22, no. 8, pp. 950–957, 2008.
- [8] N. S. Ekin, E. Alpsoy, A. A. Karakas, S. B. Yilmaz, and O. Yegin, "IL-17A has an important role in the acute attacks of Behçet's disease," *Journal of Investigative Dermatology*, vol. 130, no. 8, pp. 2136–2138, 2010.
- [9] A. Akman and E. Alpsoy, "Behçet's disease: current aspects in the etiopathogenesis," *Turkderm-Archives of the Turkish Dermatology and Venereology*, vol. 43, supplement 2, pp. 32–38, 2009.
- [10] E. Alpsoy, M. Aktekin, H. Er, C. Durusoy, and E. Yilmaz, "A randomized, controlled and blinded study of papulopustular lesions in Turkish Behçet's patients," *International Journal of Dermatology*, vol. 37, no. 11, pp. 839–843, 1998.
- [11] E. Alpsoy, L. Donmez, A. Bacanli, C. Apaydin, and B. Butun, "Review of the chronology of clinical manifestations in 60 patients with Behçet's disease," *Dermatology*, vol. 207, no. 4, pp. 354–356, 2003.
- [12] I. Tugal-Tutkun, S. Onal, R. Altan-Yaycioglu, H. Huseyin Altunbas, and M. Urgancioglu, "Uveitis in Behçet disease: an analysis of 880 patients," *American Journal of Ophthalmology*, vol. 138, no. 3, pp. 373–380, 2004.
- [13] S. Yurdakul, V. Hamuryudan, and H. Yazici, "Behçet syndrome," *Current Opinion in Rheumatology*, vol. 16, no. 1, pp. 38–42, 2004.
- [14] E. Kural-Seyahi, I. Fresko, N. Seyahi et al., "The long-term mortality and morbidity of Behçet syndrome: a 2-decade outcome survey of 387 patients followed at a dedicated center," *Medicine*, vol. 82, no. 1, pp. 60–76, 2003.
- [15] A. Siva, A. Altintas, and S. Saip, "Behçet's syndrome and the nervous system," *Current Opinion in Neurology*, vol. 17, no. 3, pp. 347–357, 2004.
- [16] T. Sakane, M. Takeno, N. Suzuki, and G. Inaba, "Behçet's disease," *The New England Journal of Medicine*, vol. 341, no. 17, pp. 1284–1291, 1999.
- [17] E. Alpsoy, L. Donmez, M. Onder et al., "Clinical features and natural course of Behçet's disease in 661 cases: a multicentre study," *The British Journal of Dermatology*, vol. 157, no. 5, pp. 901–906, 2007.
- [18] E. Alpsoy and A. Akman, "Behçet's disease: an algorithmic approach to its treatment," *Archives of Dermatological Research*, vol. 301, no. 10, pp. 693–702, 2009.
- [19] E. Alpsoy and A. Akman, "Treatment of Behçet's disease," *Therapy*, vol. 3, no. 1, pp. 139–151, 2006.
- [20] T. F. Meiller, M. J. Kutcher, C. D. Overholser, C. Niehaus, L. G. DePaola, and M. A. Siegel, "Effect of an antimicrobial mouthrinse on recurrent aphthous ulcerations," *Oral Surgery Oral Medicine and Oral Pathology*, vol. 72, no. 4, pp. 425–429, 1991.
- [21] M. Addy, R. Carpenter, and W. R. Roberts, "Management of recurrent aphthous ulceration. A trial of chlorhexidine gluconate gel," *The British Dental Journal*, vol. 141, no. 4, pp. 118–120, 1976.
- [22] A. B. Skaare, B. B. Herlofson, and P. Barkvoll, "Mouthrinses containing triclosan reduce the incidence of recurrent aphthous ulcers (RAU)," *Journal of Clinical Periodontology*, vol. 23, pp. 778–781, 1996.
- [23] E. A. Graykowski and A. Kingman, "Double-blind trial of tetracycline in recurrent aphthous ulceration," *Journal of Oral Pathology*, vol. 7, no. 6, pp. 376–382, 1978.

- [24] M. Gorsky, J. B. Epstein, S. Rabenstein, H. Elishoov, and N. Yarom, "Topical minocycline and tetracycline rinses in treatment of recurrent aphthous stomatitis: a randomized cross-over study," *Dermatology Online Journal*, vol. 13, no. 2, article 1, 2007.
- [25] D. Bang, "Treatment of Behçet's disease," *Yonsei Medical Journal*, vol. 38, no. 6, pp. 401–410, 1997.
- [26] A. R. Kerr, C. A. Drexel, and A. I. Spielman, "The efficacy and safety of 50 mg penicillin G potassium troches for recurrent aphthous ulcers," *Oral Surgery, Oral Medicine, Oral Pathology, Oral Radiology & Endodontics*, vol. 96, pp. 685–694, 2003.
- [27] E. Alpsay, H. Er, C. Durusoy, and E. Yilmaz, "The use of sucral-fate suspension in the treatment of oral and genital ulceration of Behçet's disease: a randomized, placebo-controlled, double-blind study," *Archives of Dermatology*, vol. 135, no. 5, pp. 529–532, 1999.
- [28] C. Chams-Davatchi, B. Barikbin, F. Shahram et al., "Pimecrolimus versus placebo in genital aphthous ulcers of Behçet's disease: a randomized double-blind controlled trial," *International Journal of Rheumatic Diseases*, vol. 13, no. 3, pp. 253–258, 2010.
- [29] O. Köse, A. Dinç, and I. Şimşek, "Randomized trial of pimecrolimus cream plus colchicine tablets versus colchicine tablets in the treatment of genital ulcers in Behçet's disease," *Dermatology*, vol. 218, no. 2, pp. 140–145, 2009.
- [30] W. H. Binnie, F. A. Curro, A. Khandwala, and R. G. Van Inwegen, "Amlexanox oral paste: a novel treatment that accelerates the healing of aphthous ulcers," *Compendium of Continuing Education in Dentistry*, vol. 18, no. 11, pp. 1116–1124, 1997.
- [31] R. O. Greer Jr., J. E. Lindenmuth, T. Juarez, A. Khandwala, and G. E. Kaugars, "A double-blind study of topically applied 5% amlexanox in the treatment of aphthous ulcers," *Journal of Oral and Maxillofacial Surgery*, vol. 51, no. 3, pp. 243–248, 1993.
- [32] R. J. Conklin and B. Blasberg, "Common inflammatory diseases of the mouth," *International Journal of Dermatology*, vol. 30, no. 5, pp. 323–335, 1991.
- [33] M. A. Saxen, W. T. Ambrosius, Al-K. F. Rehemtula, A. L. Russell, and G. J. Eckert, "Sustained relief of oral aphthous ulcer pain from topical diclofenac in hyaluronan: a randomized, double-blind clinical trial," *Oral Surgery, Oral Medicine, Oral Pathology, Oral Radiology & Endodontics*, vol. 84, pp. 356–361, 1997.
- [34] A. Bacanlı, O. Yerebakan, B. Parmaksizoglu, E. Yilmaz, and E. Alpsay, "Topical granulocyte colony-stimulating factor for the treatment of oral and genital ulcers of patients with Behçet's disease," *Journal of the European Academy of Dermatology and Venerology*, vol. 20, no. 8, pp. 931–935, 2006.
- [35] A. Akman, H. Kacaroglu, L. Donmez, A. Bacanlı, and E. Alpsay, "Relationship between periodontal findings and Behçet's disease: a controlled study," *Journal of Clinical Periodontology*, vol. 34, no. 6, pp. 485–491, 2007.
- [36] C. Mat, S. Yurdakul, S. Uysal et al., "A double-blind trial of depot corticosteroids in Behçet's syndrome," *Rheumatology*, vol. 45, no. 3, pp. 348–352, 2006.
- [37] E. Aktulga, M. Altac, and A. Muftuoglu, "A double blind study of colchicine in Behçet's disease," *Haematologica*, vol. 65, no. 3, pp. 399–402, 1980.
- [38] S. Yurdakul, C. Mat, Y. Tuzun et al., "A double-blind trial of colchicine in Behçet's syndrome," *Arthritis and Rheumatism*, vol. 44, no. 11, pp. 2686–2692, 2001.
- [39] F. Davatchi, B. Sadeghi Abdollahi, A. Tehrani Banihashemi et al., "Colchicine versus placebo in Behçet's disease: randomized, double-blind, controlled crossover trial," *Modern Rheumatology*, vol. 19, no. 5, pp. 542–549, 2009.
- [40] M. Çalgüneri, I. Ertenli, S. Kiraz, M. Erman, and I. Çelik, "Effect of prophylactic benzathine penicillin on mucocutaneous symptoms of Behçet's disease," *Dermatology*, vol. 192, no. 2, pp. 125–128, 1996.
- [41] M. M. Al-Waiz, K. E. Sharquie, M. H. A-Qaissi, and R. K. Hayani, "Colchicine and benzathine penicillin in the treatment of Behçet disease: a case comparative study," *Dermatology Online Journal*, vol. 11, no. 3, article 3, 2005.
- [42] T. Matsuda, S. Ohno, S. Hirohata et al., "Efficacy of rebamipide as adjunctive therapy in the treatment of recurrent oral aphthous ulcers in patients with Behçet's disease: a randomised, double-blind, placebo-controlled study," *Drugs in R and D*, vol. 4, no. 1, pp. 19–28, 2003.
- [43] K. E. Sharquie, R. A. Najim, W. S. Al-Dori, and R. K. Al-Hayani, "Oral zinc sulfate in the treatment of Behçet's disease: a double blind cross-over study," *Journal of Dermatology*, vol. 33, no. 8, pp. 541–546, 2006.
- [44] K. E. Sharquie, R. A. Najim, and A. R. Abu-Raghif, "Dapsone in Behçet's disease: a double-blind, placebo-controlled, cross-over study," *Journal of Dermatology*, vol. 29, no. 5, pp. 267–279, 2002.
- [45] V. Hamuryudan, C. Mat, S. Saip et al., "Thalidomide in the treatment of the mucocutaneous lesions of the Behçet's syndrome: a randomized, double-blind, placebo-controlled trial," *Annals of Internal Medicine*, vol. 128, no. 6, pp. 443–450, 1998.
- [46] H. Yazici, H. Pazarli, C. G. Barnes et al., "A controlled trial of azathioprine in Behçet's syndrome," *The New England Journal of Medicine*, vol. 322, no. 5, pp. 281–285, 1990.
- [47] F. Davatchi, F. Shahram, H. Chams, and M. Akbarian, "Pulse cyclophosphamide (PCP) for ocular lesions of Behçet's disease: double blind crossover study," *Arthritis & Rheumatism*, vol. 42, p. S320, 1999.
- [48] K. Masuda, A. Nakajima, A. Urayama, K. Nakae, M. Kogure, and G. Inaba, "Double-masked trial of cyclosporin versus colchicine and long-term open study of cyclosporin in Behçet's disease," *The Lancet*, vol. 1, no. 8647, pp. 1093–1096, 1989.
- [49] D. BenEzra, E. Cohen, T. Chajek et al., "Evaluation of conventional therapy versus cyclosporine A in Behçet's syndrome," *Transplantation Proceedings*, vol. 20, no. 3, pp. 136–143, 1988.
- [50] J. Elidan, E. Cohen, H. Levi, and D. Benezra, "Effect of cyclosporine A on the hearing loss in Behçet's disease," *Annals of Otolaryngology and Laryngology*, vol. 100, no. 6, pp. 464–468, 1991.
- [51] Y. Ozyazgan, S. Yurdakul, H. Yazici et al., "Low dose cyclosporin A versus pulsed cyclophosphamide in Behçet's syndrome: a single masked trial," *The British Journal of Ophthalmology*, vol. 76, no. 4, pp. 241–243, 1992.
- [52] S. H. Assaad-Khalil, "Low-dose cyclosporin in Behçet's disease: follow-up controlled study with emphasis on extraocular manifestations and neuro-Behçet's disease," in *Behçet's Disease: Basic and Clinical Aspects*, J. D. O'Duffy and E. Kokmen, Eds., pp. 603–612, Marcel Dekker, New York, NY, USA, 1991.
- [53] I. Kötter, I. Günaydin, M. Batra et al., "CNS involvement occurs more frequently in patients with Behçet's disease under cyclosporin A (CSA) than under other medications—results of a retrospective analysis of 117 cases," *Clinical Rheumatology*, vol. 25, no. 4, pp. 482–486, 2006.

- [54] E. Alpsoy, C. Durusoy, E. Yilmaz et al., "Interferon alfa-2a in the treatment of Behçet disease: a randomized placebo-controlled and double-blind study," *Archives of Dermatology*, vol. 138, no. 4, pp. 467–471, 2002.
- [55] V. Hamuryudan, F. Moral, S. Yurdakul et al., "Systemic interferon α 2b treatment in Behçet's syndrome," *Journal of Rheumatology*, vol. 21, no. 6, pp. 1098–1100, 1994.
- [56] I. Kötter, M. Zierhut, A. K. Eckstein et al., "Human recombinant interferon alpha-2a for the treatment of Behçet's disease with sight threatening posterior or panuveitis," *The British Journal of Ophthalmology*, vol. 87, no. 4, pp. 423–431, 2003.
- [57] I. Tugal-Tutkun, E. Guney-Tefekli, and M. Urgancioglu, "Results of interferon-alfa therapy in patients with Behçet uveitis," *Graefe's Archive for Clinical and Experimental Ophthalmology*, vol. 244, pp. 1692–1695, 2006.
- [58] S. Onal, H. Kazokoglu, A. Koc et al., "Long-term efficacy and safety of low-dose and dose-escalating interferon alfa-2a therapy in refractory Behçet uveitis," *Archives of Ophthalmology*, vol. 129, no. 3, pp. 288–294, 2011.
- [59] P. P. Sfikakis, P. H. Kaklamanis, A. Elezoglou et al., "Infliximab for recurrent, sight-threatening ocular inflammation in adamantiades-Behçet disease," *Annals of Internal Medicine*, vol. 140, no. 5, pp. 404–406, 2004.
- [60] S. Ohno, S. Nakamura, S. Hori et al., "Efficacy, safety, and pharmacokinetics of multiple administration of infliximab in Behçet's disease with refractory uveoretinitis," *Journal of Rheumatology*, vol. 31, no. 7, pp. 1362–1368, 2004.
- [61] I. Tugal-Tutkun, A. Mudun, M. Urgancioglu et al., "Efficacy of infliximab in the treatment of uveitis that is resistant to treatment with the combination of azathioprine, cyclosporine, and corticosteroids in Behçet's disease: an open-label trial," *Arthritis and Rheumatism*, vol. 52, no. 8, pp. 2478–2484, 2005.
- [62] P. P. Sfikakis, N. Markomichelakis, E. Alpsoy et al., "Anti-TNF therapy in the management of Behçet's disease—review and basis for recommendations," *Rheumatology*, vol. 46, no. 5, pp. 736–741, 2007.
- [63] B. Mushtaq, T. Saeed, R. D. Situnayake, and P. I. Murray, "Adalimumab for sight-threatening uveitis in Behçet's disease," *Eye*, vol. 21, no. 6, pp. 824–825, 2007.
- [64] M. Melikoglu, I. Fresko, C. Mat et al., "Short-term trial of etanercept in Behçet's disease: a double blind, placebo controlled study," *Journal of Rheumatology*, vol. 32, no. 1, pp. 98–105, 2005.
- [65] F. Davatchi, H. Shams, M. Rezaipoor et al., "Rituximab in intractable ocular lesions of Behçet's disease; randomized single-blind control study (pilot study)," *International Journal of Rheumatic Diseases*, vol. 13, no. 3, pp. 246–252, 2010.
- [66] J. L. Jorizzo, W. L. White, C. M. Wise, M. D. Zanolli, and E. F. Sherertz, "Low-dose weekly methotrexate for unusual neutrophilic vascular reactions: cutaneous polyarteritis nodosa and Behçet's disease," *Journal of the American Academy of Dermatology*, vol. 24, no. 6, pp. 973–978, 1991.
- [67] H. Kikuchi, K. Aramaki, and S. Hirohata, "Low dose MTX for progressive neuro-Behçet's disease. A follow-up study for 4 years," *Advances in Experimental Medicine and Biology*, vol. 528, pp. 575–578, 2003.
- [68] H. Suda, "Low-dose weekly methotrexate therapy for progressive neuro-Behçet's disease," *Nihon Rinsho Meneki Gakkai kaish*, vol. 22, no. 1, pp. 13–22, 1999.
- [69] F. Davatchi, F. Shahram, H. Chams et al., "High dose methotrexate for ocular lesions of Behçet's disease. Preliminary short-term results," *Advances in Experimental Medicine and Biology*, vol. 528, pp. 579–584, 2003.
- [70] P. Neri, C. Mariotti, L. Cimino, L. Mercanti, and A. Giovannini, "Long-term control of cystoid macular oedema in non-infectious uveitis with Mycophenolate Mofetil," *International Ophthalmology*, vol. 29, no. 3, pp. 127–133, 2009.
- [71] Y. D. Adler, U. Mansmann, and C. C. Zouboulis, "Mycophenolate mofetil is ineffective in the treatment of mucocutaneous Adamantiades-Behçet's disease," *Dermatology*, vol. 203, no. 4, pp. 322–324, 2001.
- [72] G. Rossi, A. Moretta, and F. Locatelli, "Autologous hematopoietic stem cell transplantation for severe/refractory intestinal Behçet's disease," *Blood*, vol. 103, no. 2, pp. 748–750, 2004.
- [73] B. Maurer, M. Hensel, R. Max, C. Fiehn, A. D. Ho, and H. M. Lorenz, "Autologous haematopoietic stem cell transplantation for Behçet's disease with pulmonary involvement: analysis after 5 years of follow up," *Annals of the Rheumatic Diseases*, vol. 65, no. 1, pp. 127–129, 2006.
- [74] A. De Cata, D. Intiso, M. Bernal et al., "Prolonged remission of neuro-Behçet's disease following autologous transplantation," *International Journal of Immunopathology and Pharmacology*, vol. 20, no. 1, pp. 91–96, 2007.
- [75] K. Yasui, K. Ohta, M. Kobayashi, T. Aizawa, and A. Komiyama, "Successful treatment of Behçet disease with pentoxifylline," *Annals of Internal Medicine*, vol. 124, no. 10, pp. 891–893, 1996.
- [76] R. Oliveira-Soares, J. P. Freitas, P. Sousa Ramalho, and F. Guerra Rodrigo, "Treatment with pentoxifylline in Behçet's disease," *Journal of the European Academy of Dermatology and Venereology*, vol. 16, no. 2, pp. 181–182, 2002.
- [77] M. Can and H. Direskeneli, "Musculo-skeletal and vascular involvement in Behçet's disease," *Turkderm-Archives of the Turkish Dermatology and Venerology*, vol. 43, supplement 2, pp. 54–60, 2009.
- [78] A. A. Aroussi, M. Redai, F. El Ouardi, and B. E. Mehadji, "Bilateral pulmonary artery aneurysm in Behçet syndrome: report of two operative cases," *Journal of Thoracic and Cardiovascular Surgery*, vol. 129, no. 5, pp. 1170–1171, 2005.
- [79] B. K. Koo, W. H. Shim, Y. S. Yoon et al., "Endovascular therapy combined with immunosuppressive treatment for pseudoaneurysms in patients with Behçet's disease," *Journal of Endovascular Therapy*, vol. 10, no. 1, pp. 75–80, 2003.
- [80] M. Soyly, N. Demircan, and A. Pelit, "Pars plana vitrectomy in ocular Behçet's disease," *International Ophthalmology*, vol. 24, no. 4, pp. 219–223, 2001.
- [81] I. Alexoudi, V. Kapsimali, A. Vaiopoulos, M. Kanakis, and G. Vaiopoulos, "Evaluation of current therapeutic strategies in Behçet's disease," *Clinical Rheumatology*, vol. 30, no. 2, pp. 157–163, 2011.
- [82] G. Hatemi, A. Silman, D. Bang et al., "EULAR recommendations for the management of Behçet's disease: report of a task force of the European Standing Committee for International Clinical Studies Including Therapeutics (ESCISIT)," *Annals of the Rheumatic Diseases*, vol. 67, pp. 1656–1662, 2008.
- [83] A. Akman-Demir, "Neurologic involvement in Behçet's disease," *Turkderm-Archives of the Turkish Dermatology and Venerology*, vol. 43, supplement 2, pp. 61–64, 2009.

Review Article

Pathophysiology of the Behçet's Disease

Ümit Türsen

Department of Dermatology, School of Medicine, Mersin University, Zeytinlibahce, 33079 Mersin, Turkey

Correspondence should be addressed to Ümit Türsen, utursen@mersin.edu.tr

Received 26 May 2011; Revised 21 July 2011; Accepted 23 July 2011

Academic Editor: Fereydoun Davatchi

Copyright © 2012 Ümit Türsen. This is an open access article distributed under the Creative Commons Attribution License, which permits unrestricted use, distribution, and reproduction in any medium, provided the original work is properly cited.

Behçet's disease (BD) is a multisystemic disease of unknown etiology characterized by chronic relapsing oral-genital ulcers and uveitis. Multiple systemic associations including articular, gastrointestinal, cardiopulmonary, neurologic, and vascular involvement are also observed in BD. Although the etiopathogenesis of the disease remains unknown, increased neutrophil functions such as chemotaxis, phagocytosis, and excessive production of reactive oxygen species (ROS), including superoxide anion, which may be responsible for oxidative tissue damage seen in BD, and also immunological alterations, T lymphocyte abnormalities in both subpopulation and function have been considered to be correlated with the etiopathogenesis of BD. There is some clinical evidence suggesting that emotional stress and hormonal alterations can influence the course and disease activity of BD.

1. Introduction

Behçet's disease (BD) is a recurrent systemic inflammatory disorder characterized by four major symptoms consisting of oral aphthous ulcers, ocular lesions, skin lesions, and genital ulcerations. Although many studies have been conducted on the etiopathogenesis of the disease, exact mechanisms have not yet been fully understood [1]. Multiple systemic associations including articular, gastrointestinal, cardiopulmonary, neurologic, and vascular involvement are also observed in BD [1, 2]. Although the etiopathogenesis of the disease remains unknown, increased neutrophil functions such as chemotaxis, phagocytosis, and excessive production of reactive oxygen species (ROS), including superoxide anion, which may be responsible for oxidative tissue damage seen in BD, and also immunological alterations, T lymphocyte abnormalities in both subpopulation and function have been considered to be correlated with the etiopathogenesis of BD. It was postulated that Behçet's disease is an autoimmune disease. Systemic manifestations such as articular, gastrointestinal, and neurologic manifestations are not associations with the disease. They are different involvements due to the disease [3, 4]. There is also some clinical evidence suggesting that emotional stress and hormonal alterations can influence the course and disease activity of BD [5–7].

2. Immune System Dysregulations

The immunopathogenesis that is currently postulated is shown in Figure 1. Primarily, hypersensitivity of T cells ($\alpha\beta$ T cells and $\gamma\delta$ -T cells) to multiple antigens appears to play a critical role in the pathogenesis. The activation of monocytes subsequent to T-cell activation through CD40–CD154 interactions as well as a variety of T-cell-derived cytokines (IFN- γ and TNF- α) may result in the production of IL-12, which leads to the shift to Th1 responses. In consequence of abnormal T-cell activation, neutrophil activation may be triggered by cytokines such as IL-8, IL-17, IFN- γ , and TNF- α . Whereas the roles of costimulation molecules have not been fully explored in Behçet's disease, the presence of anti-CTLA-4 antibody has been reported in a fraction of Behçet's disease patients. Although the presence of this antibody might be possibly involved in abnormal T-cell responses, the antibody might be produced only as a secondary phenomenon of recurrent T-cell activation in Behçet's disease [7, 8].

3. Cellular and Humoral Immunology

Although cellular activity is increased in the peripheral blood of BD patients, reports of neonatal BD cases in the children of affected women also suggest a role for humoral factors. Indeed, various cytokine profiles and

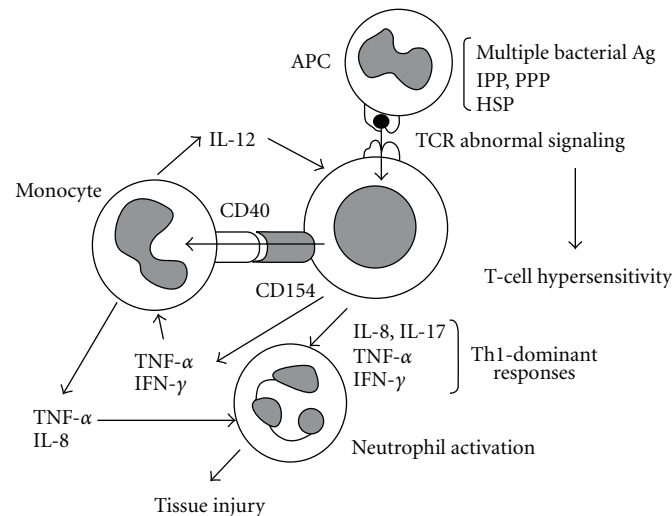


FIGURE 1: Proposed model of the pathogenesis in Behçet's disease. Ag: antigen; APC: antigen-presenting cells; HSP: heat shock protein; IFN: interferon; IL: interleukin; IPP: isoprenyl pyrophosphate; PPP: prenyl pyrophosphate; TCR: T-cell receptor; Th1: T-helper cells type 1; TNF- α : tumor necrosis factor α .

elevated lymphocyte populations have been demonstrated in BD with an imbalance between Th1- and Th2-phenotype lymphocyte components of the immune response. However, as T lymphocytes are particularly responsive to antigens of viral or bacterial pathogens, the skew is therefore suggested toward Th1-phenotype lymphocyte response followed by an infiltration into the affected regions [7, 8].

3.1. Th1-Phenotype Lymphocytes. Th1-phenotype lymphocytes that produce proinflammatory mediators called cytokines, such as IL-2, IL-6, IL-8, IL-12, IL-18, TNF- α , and IFN- γ are increased in patients with BD [7].

3.2. Th2-Phenotype Lymphocytes. Th2 cytokines have responses precisely opposite to those of reactions elicited by Th1. The results regarding the Th2-phenotype lymphocytes and cytokines are controversial. Some studies have shown decreased levels of CD8 T lymphocytes, IL-4, and IL-10, whereas some others demonstrated increased CD8 T-lymphocyte populations as well as increased serum concentrations of IL-4, IL-6, IL-10, and IL-13, indicating a reduced circulating CD4/CD8 ratio [7].

3.3. Immunoglobulins, Immune Complexes, and Anticardiolipins. Enhanced cell-mediated cytotoxicity with demonstrated circulating immune complex response (usually antigen-antibody complexes) against oral mucosal antigens, especially during an exacerbation period, supports the presence of both Th1 and Th2 types of immune reaction in BD. These immune complexes may be priming factors that trigger the disease with a recruitment of some immune cells to the site of inflammation that are present in the sera of more than one-half of BD patients [7].

3.4. Neutrophils, Monocytes, and Complements. There is a generalized derangement of the lymphocyte and neutrophil

populations during the course of BD, which is characterized by elevated peripheral white blood cell count, activated monocytes, increased neutrophil motility with infiltration into the cutaneous and ocular lesions, and increased circulating proteins such as C3, C4, C5, IgA, Haptoglobin, and orosomucoid [9]. Active monocytes produce a number of proinflammatory cytokines, such as IL-1, IL-6, IL-8, TNF- α , and granulocyte-macrophage colony stimulating factor (GM-CSF), and these cytokines contribute to neutrophil activation by their augmented interactions with endothelial cells, causing tissue damage possibly by priming neutrophils [10]. Indeed, various hyperfunctions of neutrophils in peripheral blood such as chemotaxis, active oxygen production, and phagocytosis with infiltration into the lesion sites have all been implicated during the course of active BD [11]. Moreover, leukocyte adhesion molecules such as P and L selectins, Mac-1, and CD4 are expressed on peripheral leukocytes and participate in the cascade of leukocyte chemotaxis and adhesion, indicating the presence of immune system activation in BD [12]. Plasma myeloperoxidase (MPO) activity, representing neutrophil activation, and biomarkers of oxidative stress reflecting protein oxidation, such as the levels of advanced oxidation protein products (AOPPs), have been found to be increased in BD patients, especially in active disease [13]. This suggests again the activated neutrophils in the etiopathogenesis of BD.

3.5. Heat Shock Proteins in BD. Heat shock protein (HSP) is a small, ubiquitous stress-related streptococcal antigen that can be induced by infections, trauma, heat, UV-B, hypoxia, cold, and cytotoxic prostaglandins [14]. Anti-HSP-65 antibodies cross-reactive with oral mucosal homogenates and oral streptococci have been reported in BD. T-cell antigen receptor (TCR) $\gamma\delta$ -T lymphocytes are important in first-line defense that allows T cells to recognize a wide range of antigens as well as in regulation of Th1-Th2 responses,

and HSP itself activates these subsets of cells known as the CD4 and $\gamma\delta$ -T lymphocytes that do not require peptide-MHC I or II association for stimulation. Likewise, microbial HSP-65-derived peptides and their mammalian counterpart HSP-60, both of which cause autoimmunity with 60% of sequence homology, have recently been demonstrated to stimulate lymphoproliferative response in BD patients [14, 15].

Recent developments in the innate immune system with the description of toll-like receptors (TLRs) and HSP-60 as a ligand for TLR-2 and TLR-4 suggest also the role of HSP-60 as an endogenous “danger” signal to the immune system with rapid inflammatory cytokine release and the enhancement of adaptive Th1-type responses [16]. Although contradictory results have been reported for peripheral blood TCR $\gamma\delta$ -T lymphocyte counts, HSPs have pathophysiologically been suggested in BD because increased T- and B-cell responses against these autoantigens are observed in different ethnic populations in BD [17]. Therefore, these cells as well as HSPs may participate during the course of ocular and mucocutaneous BD because of the following: (1) antibodies against bacterial or human HSP-60/65 are capable of cross-reacting with retinal antigens; (2) exposure to exogenous or endogenous HSPs results in the proliferation of peripheral T lymphocytes of ocular BD patients directed against both the target and retinal antigens; (3) lesional skin of BD contains increased numbers of both HSP-60 and TCR $\gamma\delta$ -T lymphocytes; (4) $\gamma\delta$ -T lymphocyte is present in tissue specimens whereas HSP-65 expression is abundantly upregulated in epidermal regions of active skin lesions such as erythema nodosum and mucocutaneous lesions of patients with BD; finally (5) elevated HSPs upregulate the expression of the MICA locus in BD patients lying adjacent to the HLA-B5101 locus [18, 19]. Moreover, increased TCR- $\gamma\delta$ -T lymphocytes is normally cultured from inflamed vitreous and have been detected in cerebrospinal fluid (CSF) and bronchoalveolar lavage of patients with active BD. Furthermore, subcutaneous inoculation or oral administration of HSP-derived peptide induces experimental uveitis [20]. Taken together, BD seems to result from heightened responsiveness to bacterial antigens in genetically susceptible hosts. In other words, streptococcal HSP epitopes may reach the submucosa of the mouth ulcers and elicit an inflammatory reaction through upregulated HSP expression by minor injuries, which stimulate self-HSP-60 reactive clones, suggesting different local HSP responsive T-lymphocyte repertoire from that of peripheral blood. This, in turn, may serve as a local antigen with augmentation of inflammatory reaction.

3.6. Oxidative Stress, Antioxidative Defense, and Trace Elements in BD. In spite of unknown aetiology, it is now accepted that reactive oxygen species produced by neutrophils may be related to the pathogenesis of BD. Not only increased malondialdehyde and superoxide dismutase levels but also decreased glutathione peroxidase activities in erythrocytes were observed in patients with BD [21]. Toxic compounds such as pesticides and insecticides have been incriminated in BD. Recently, Aynacioglu et al. showed that N-acetyltransferase 2*5B allele was slightly higher in patients

with BD. This enzyme contributes to drug and toxic compound metabolism [22]. Excessive superoxide anion (O_2^-) production and raised ADA activity (a marker of activated neutrophil function, chemotaxis, and phagocytosis), as well as hydrogen peroxide- (H_2O_2 -) induced hydroxyl radical (OH) and malondialdehyde productions have been demonstrated in BD patients, suggesting neutrophil-mediated immunity and increased amount of reactive oxygen species (ROS) production, especially in the exacerbation period [23]. Indeed, neutrophils of active BD patients are much more vulnerable to oxidative injury than those from inactive patients. On the other hand, endogenous free radical scavenging enzymes, such as superoxide dismutase, glutathione peroxidase, and catalase, have been found to be decreased in patients with BD [24]. This clearly results in insufficient disposal of O_2^- and H_2O_2 and, therefore, limited enzymatic adaptation to ROS with circulating prooxidants in such patients [25]. As activated T lymphocytes cause neutrophil hyperfunction with overproduction of NO, O_2^- , H_2O_2 , OH, and singlet oxygen (1O_2) that is one of main ROS-generation system in BD patients, the increased production of ADA and LPO system confirms aggravated lymphocyte function and ROS production, suggesting a possible new and simple biochemical activity marker for ADA in BD. Therefore, the interplay between ADA, O_2^- , NO, and peroxyxynitrite anion in the vascular wall of BD patients is likely to cause antioxidant enzyme depletion, oxidative LPO and, therefore, deteriorated oxidant/antioxidant equilibrium, creating a condition known as oxidative stress [26]. Trace elements function as cofactors to antioxidant enzymes. Erythrocyte selenium, plasma iron, manganese, and zinc levels are decreased, whereas plasma copper, erythrocyte zinc, and manganese levels are elevated in patients with BD. In addition, the plasma concentrations of powerful nonenzymatic antioxidants such as vitamins A, C, E, and β -carotene are lower in such patients [27, 28].

3.7. Endothelial Cells, Nitric Oxide, and Related New Inflammatory Molecules. Behçet disease is characterized by vasculitis and endothelial cell dysfunction. Nitric oxide (NO), endothelium-derived relaxing factor, is a free oxygen radical that is produced by endothelial cells upon stimulation by immunologic, infectious, and inflammatory stimuli, such as cytokines, INF- γ , lipopolysaccharides, and endotoxin [29]. It is an important mediator of uveal inflammation, and NO synthase activity has experimentally been demonstrated in the uveal tissue [30]. Recently, evidence is accumulating for the role of NO during the course of BD. Serum nitrite and nitrate concentrations as an indicator of recent NO production have been found to be decreased in BD patients [31], and three recent studies have shown that Glu-Asp298 polymorphisms of endothelial NO synthase gene are associated with BD susceptibility [32]. In another study, serum, erythrocyte, and synovial NO have been demonstrated in BD [33]. NO concentrations are increased in BD patients and associated with disease activity. Similar results have been obtained by various investigators supporting this finding [34]. In addition, aqueous humor NO levels have been reported to be increased in uveitic BD patients [35].

Increased serum levels of NO may be explained by various molecules that have recently been implicated during the course of BD. First, homocysteine, which is found to be elevated in BD [36], enhances NO synthesis from endothelial cells, induces the expression of chemoattractants by oxygen free radicals, and is the potent inducer for IL-6, IL-8, and TNF- α [37]. Because increased levels of proinflammatory cytokines by endothelial cells, neutrophils, and macrophages have well been established during the course of BD [38], homocysteine- and cytokine-induced overproduction of NO by immunocompetent cells may pathophysiologically be related with BD and uveitis due to NO-generating cells such as the endothelium, neutrophils, and macrophages, resulting in oxidative stress with self-propagating LPO in such patients [39]. Elevated NO levels, in turn, may compensate these effects of homocysteine by its adhesion-inhibitory properties. Second, another endothelium-specific cytokine, vascular endothelial growth factor, is produced by macrophages, activated human neutrophils, monocytes, and vascular endothelial cells and potently stimulates angiogenesis, endothelium-dependent vasodilatation, and NO production by its receptors located on the systemic and retinal vascular endothelial cells [40]. Indeed, inflammation and proinflammatory cytokines induce VEGF expression and VEGF itself upregulates NO synthase expression in endothelial cells, inducing large amount of NO production and leukocyte mobilization [41]. Because serum VEGF levels have been found to be increased in BD patients and correlated with ocular disease with demonstrated VEGF gene polymorphisms [42], VEGF may therefore have contributed to the elevated NO levels along with an additional risk factor for the development of retinal vaso-occlusive disease and neovascularization, resulting in poor visual outcome in such patients. Finally, leptin, a product of the recently cloned *ob* gene, is expressed in human vasculature and endothelial cells and plays a crucial role during inflammation, and impaired endothelial function reverses after leptin replacement [43]. TNF increases serum leptin levels in human, and leptin itself directly enhances the release of NO from endothelial cells, suggesting an autocrine or paracrine modulator role [44]. Because serum leptin levels have been demonstrated to be higher in acute-phase response as well as in BD patients [45], the pathophysiological significance of homocysteine-cytokine-VEGF-leptin-NO cascade should further be investigated in detail during the course of BD.

4. The Role of Stress Factors and Stress Hormones in BD

4.1. Hypothalamo-Pituitary Adrenal Axis in Behçet's Disease. Dysfunction of the hypophysis gland in both humans and animals was shown to be associated with several autoimmune diseases [46, 47]. As in other chronic autoimmune diseases, there may be some changes in cortisol levels due to adrenal tiredness associated with long-term stress in Behçet's disease. Colak et al. observed that cortisol values in the 60th minute were significantly lower in Behçet's disease patients than in the control group after 1 μ g ACTH stimulation test.

In this study, when peak cortisol responses to low-dose test were compared between patient and control groups, a significant decrease was found in the patient group. When peak cortisol responses to low-dose test and standard-dose test were compared in the patient group, peak cortisol responses to low-dose test were found significantly lower than those to standard-dose test. Comparison of under the curve cortisol responses between patient and control groups showed that under the curve value was significantly lower between 30th and 60th minutes in low-dose test in the patient group than in the control group. When percentage increase values of cortisol responses to low-dose test were compared between patient and control groups, the 60th minute value in the patient group was found significantly lower than that in the control group [48]. Autoimmune diseases develop when endocrine changes caused by various stresses like infection, together with some regulatory defects, affect autoreactive cells and exceed the critical threshold that leads to autoimmunity [49]. The most common cause of primary adrenal cortex failure is autoimmune adrenalitis that results in bilateral adrenal atrophy. Clinical signs of adrenal failure are not seen until at least 90% of the adrenocortical tissue is destroyed. The rate of the copresence of diseases having autoimmune events in their pathogenesis is high. Primary adrenal failure, which is an autoimmune disease, may accompany Behçet's disease, for the aetiopathogenesis of which autoimmunity is held responsible [50]. There are some studies assessing adrenal functions in the other autoimmune diseases including rheumatoid arthritis, systemic lupus erythematosus, and Sjögren's syndrome [51–55]. There is a partial dysfunction that can be revealed by LDT in Behçet's syndrome patients [48]. It was concluded that hypothalamo-pituitary adrenal axis was partially suppressed in Behçet's disease and that occult adrenal failure should be carefully considered in case of acute stress.

4.2. Sex Hormones in BD. While this paper has focused on the HPA axis and glucocorticoids and their role in susceptibility to inflammatory disease, estrogen is known to play an extremely important role in immune modulation and contributes to the approximately two- to tenfold higher ratio of most autoimmune diseases in females of all species [56]. Ovariectomy has been shown to reduce, while replacement of estrogen reconstitutes, this differential susceptibility to experimental inflammatory arthritis in rodents [57]. Furthermore, gender, menstrual cycle, and estrogen replacement therapy have all been shown to affect HPA axis and immune function in human studies [58].

4.3. Activation of Neutrophils by Testosterone in Behçet's Disease. To determine the putative role of testosterone on neutrophil activity exhibited by patients with BD, peripheral blood neutrophils were examined in vitro before and after treatment with testosterone. Yavuz et al. analysed peripheral blood neutrophils of 49 patients with BD, 33 patients with ankylosing spondylitis, 8 female patients with hirsutism, and 31 healthy individuals. They indicated that gender differences were striking not only in the mean oxidative burst response but also in the rate of apoptosis. Male BD patients manifested

increased burst response before testosterone treatment compared with females. Consistent with oxidative burst results, baseline percentages of CD66b- and CD16-expressing cells were greater in male BD patients. A decreased apoptosis ratio was observed using PhiPhilux and PI staining in BD patients. This was especially significant in male compared to female BD patients. BD itself rather than the gender was found to be the most important predictor of this altered apoptosis ratio in BD determined by linear regression analysis [59]. These results suggested that a contribution of testosterone to the BD pathogenesis could not be ruled out.

4.4. Prolactin (PRL) and Other Sex Hormones in BD. Prolactin acts as a neuroendocrine modulator of both skin epithelial growth and the skin immune system. Moreover, it was proposed that PRL forms a “PRL circuit” between the skin and the central nervous system [60]. This concept can now be readily integrated into current views on the multilevel neuroendocrine-immune communication along the “brain-skin axis” in health and disease [61]. Inspired by this hypothesis, PRL and PRL-receptors expression have now been demonstrated in several cutaneous cell populations, including keratinocytes, fibroblasts, sweat glands, and sebaceous glands. In addition, PRL and PRL-receptors expression has also been identified in the key cellular protagonists of the skin immune system [62].

The results regarding the PRL levels in BD are controversial. Some studies have shown increased levels of PRL, whereas some others demonstrated decreased and normal levels of PRL in BD [63–66]. Karakus et al. indicated that PRL levels of male patients having ocular involvement had lower levels of inactive group, while female patients having ocular involvement had lower levels of DHEA-S compared to the active group. They found that no other remarkable hormonal difference including FSH, LH, T3, T4, TSH was observed among Behçet’s patients [67]. Gül et al. found that mean total testosterone levels of BD patients were significantly lower than those of healthy controls; however, patients with BD and increased 17-OH-progesterone levels only had normal total testosterone levels. And they also indicated more commonly 21-hydroxylase gene mutations and deficiency in BD [68]. Mat et al. found that androgen receptor density in scrotal skin of BD was normal [69]. In some studies, it has been suggested that there is a correlation between high serum prolactin levels and activation of certain autoimmune diseases. Hyperprolactinemia, which has the potential to exacerbate autoimmunity, may coexist with BD [70]. For many years, bromocriptine, a D1 and D2 dopamine receptor agonist, has been the standard medicine for hyperprolactinemic patients. That there was a beneficial effect of low-dose cyclosporine plus bromocriptine combination therapy on autoimmune human uveitis may indicate the role of prolactin in the pathogenesis of BD [70].

4.5. Neuropeptides in Behçet’s Disease. Recently, the association between stressful life events and various dermatologic diseases is explained by the concept of neuro-immune-cutaneous system [71]. It was reported that neuropeptides, especially substance P (SP) and calcitonin-gene-related

peptide (CGRP), and neurotrophins such as nerve growth factor (NGF) affect the pathogenesis of skin disorders like atopic dermatitis and psoriasis vulgaris [72, 73]. Taking into account inflammatory responses that occur during emotional stress in BD patients, it seems likely that neurogenic mediators may be associated with BD. Jang et al. observed that strong immunoreactivity of SP and NGF was seen in the epidermis, panniculitis lesion, and vasculitis lesion of BD patients. However, CGRP levels were decreased in BD patients [74]. Aki et al. noted that SP in the active BD period was significantly higher than controls whereas that of inactive BD was not. SP in active BD was significantly higher than in inactive BD. And also they found that CGRP during both active and inactive periods of BD was significantly higher than controls, and CGRP in active BD was significantly higher than in inactive BD. They think that the increased SP and CGRP found in active BD may be associated with BD pathogenesis through the increase in expression of cellular adhesion molecules, IL-8 release, and neutrophil chemotaxis [75]. Endothelial cells have specific receptors for SP and CGRP. These neuropeptides influence endothelial cell functions through their receptors. SP and CGRP have several effects that can play a role in the pathogenesis of vasculitis, via endothelial cells and neutrophils. The aforementioned effects of SP and CGRP on vasodilatation, vascular permeability, and endothelial-associated inflammation suggest that they may have a role in vasculitic events [76]. In conclusion, an increase in serum SP and CGRP levels in BD was found in different studies. This suggests that the neuropeptides may be contributing to BD pathogenesis by affecting vasculitic events.

4.6. Natriuretic Peptides in Behçet’s Disease. Natriuretic peptides (NPs) maintain an important endocrine-paracrine influence over many vascular parameters. NPs have a fundamental role in cardiovascular remodeling, volume homeostasis, and the response to ischemia. Moreover, the NP level is associated with cardiac problems such as heart failure and thromboembolism [77, 78]. Cardiovascular involvement in BD includes coronary arteritis, coronary artery aneurysm, myocarditis, pericarditis, acute myocardial infarction, silent myocardial ischemia, intracardiac thrombus, heart failure, vasculitis, venous occlusions, arterial aneurysms, and/or arterial occlusions [79]. Yağci et al. studied serum atrial natriuretic peptide (ANP), brain natriuretic peptide (BNP), and C-type natriuretic peptide (CNP) levels in Behçet’s patients with active and inactive period. Serum ANP concentrations of the BD patients in the active subgroup were significantly lower than those of the healthy controls. In this study, when compared with healthy controls, serum BNP levels were found to be significantly higher in both the active and inactive BD subgroups. When the study groups were evaluated on the basis of CNP levels, the active BD subgroup had significantly decreased CNP levels in comparison with the inactive and control groups [80]. ANP has been linked to the immune system, and it regulates the balance between TH1 and TH2 responses [81–83]. It may be supposed that decreased CNP levels in the patients may be one of the consequences of the endothelial dysfunction in BD.

TABLE 1: Key stress protagonists in the BD.

Stress mediators, hormones, and cells	Main biological effect	In BD
Hormones of the HPA axis (CRH, ACTH, glucocorticoids)	Activate mast cells Upregulate production of IL-4, IL-6, IL-10, and IL-13 Inhibit the production of IL-12, IFN- γ , and TNF- α by antigen-presenting cells and T-helper 1 cells	Partial HPA axis dysfunction [10].
Prolactin	Participates in early and late T-cell activating events; contributes to a proinflammatory and apoptosis-prone environment	Increased, decreased, or normal [26–29].
Sex hormones	Immune modulation, affect HPA axis	Activation of neutrophils by testosterone, lower levels of DHEA-S (ocular BD), increased 17-OH-progesterone, testosterone, estradiol, FSH, LH, T3, T4, and normal TSH levels and androgen receptor density in scrotal skin, increased 21-hydroxylase gene mutations [30–32].
Substance P	Induces inflammation Induces lymphocyte proliferation Activates mast cells	Higher levels in active BD, strong immunoreactivity of SP in vasculitic skin lesions [39, 45].
CGRP	Inhibits proliferation and IL-2 release of T lymphocytes under immune challenges Activates mast cells, induces vascular permeability	Increased or decreased levels in BD [45, 52].
NGF, NEP, neuropeptide degrading enzyme	Promotes “crosstalk” between neuronal and immune cells Acts as autocrine and paracrine factor in the development and regulation of immune cells Promotes monocyte and macrophage migration through vascular endothelium Activates mast cells	Strong immunoreactivity in vasculitic skin lesions, Decreased NGF levels in inactive BD (Ocular-BD) [39, 52].
Natriuretic peptides	Endocrine-paracrine influence over many vascular parameters including fluid and electrolyte balance, vasodilatation, smooth muscle proliferation, and the reactivity of immune cells.	Lower ANP concentrations in active BD, higher serum BNP levels in BD, decreased CNP levels in active BD [56].
Heat shock proteins	Activates CD4 and $\gamma\delta$ -T lymphocytes	Antibodies against bacterial or human HSP-60/65 are capable of cross-reacting with retinal antigens Exposure to HSPs results in the proliferation of peripheral T lymphocytes of ocular BD patients Lesional skin of BD contains increased numbers of both HSP-60 and TCR $\gamma\delta$ -T lymphocytes $\gamma\delta$ -T lymphocyte is present in tissue specimens, whereas HSP-65 expression is abundantly upregulated in epidermal regions of active skin lesions Elevated HSPs upregulate the expression of the MICA locus in BD patients [68, 69].
Oxidative stress	Activate neutrophil function, chemotaxis, and phagocytosis	Excessive superoxide anion production, raised ADA activity, hydrogen peroxide-induced hydroxyl radical, and malondialdehyde productions [71, 75]
Antioxidative defense	Free radical scavenging	Decreased superoxide dismutase, glutathione peroxidase, and catalase levels [71].
Trace elements and vitamins	Cofactors to antioxidant enzymes Nonenzymatic antioxidants	Decreased erythrocyte selenium, plasma iron, manganese, and zinc levels, increased plasma copper, erythrocyte zinc, and manganese levels, lower plasma concentrations of vitamins A, C, E, and β -carotene [77, 78].

TABLE 1: Continued.

Stress mediators, hormones, and cells	Main biological effect	In BD
Neutrophils, monocytes, and complements	Produce a number of proinflammatory cytokines, chemotaxis, active oxygen production, and phagocytosis Innate immune system activation	Hyperfunctions of neutrophils, leukocyte adhesion molecules including P and L selectins, Mac-1 and CD4 expression on peripheral leukocytes, increased plasma myeloperoxidase activity, elevated peripheral white blood cell count, activated monocytes, increased neutrophil motility, and circulating proteins including C3, C4, C5 [79].
Nitric oxide	Free oxygen radical	Decreased serum nitrite and nitrate concentrations, and Glu-Asp298 polymorphisms of endothelial NO synthase gene, increased NO concentration [85–90].
Psychological factors	Regulate the immune system at regional, local, and systemic levels	More depression and anxiety scores, affected quality of life [85–88].

4.7. Stress Management in BD. The interaction between the physical and psychological factors seems reasonable in the experience of a BD. Numerous studies have provided a strong basis for considering the role of psychosocial factors on the course the rheumatic disease. Gur et al. established that arthropathy was one of the common manifestations of BD. Arthritis in BD affects considerably patients' pain levels and quality of life [84]. Koçak et al. conclude that depressive mood according to the BDI scale correlates with the sexual status of BD patients, and this may be because of the depressive effect of BD as a chronic disease [85]. Taner et al. observed that patients with BH had more depression and anxiety scores than in psoriatic patients [86]. Uğuz et al. observed that concurrent major depression had a negative impact on quality of life of BD patients and that quality of life was negatively correlated with the severity of depressive symptoms. Behçet's disease was a multisystemic inflammatory disorder associated with high levels of depressive symptoms and lower quality of life [87].

Psychological/psychiatric interventions could usefully be included in the normal Behçet's patients assessment, as it should both improve patient care and be cost effective. Counseling and psychotropic medications can benefit patients with depression or anxiety related to their skin problems, and consultation with a dermatologist and, in some cases, a psychiatrist can be beneficial. The effect of skin diseases is considerable and underappreciated. Physicians applying the biopsychosocial model to skin diseases will be rewarded with improved therapeutic alliances and with grateful patients who experience improved quality of life [88].

No specific pharmacological interventions are as yet available to prevent or treat stress triggered skin disorders in humans. However, based on the wealth of data that has recently accumulated in this field, reasonable pharmacological treatment options are slowly coming into sight. Abrogation of mast-cell activation seems to be a promising approach in this endeavor, but, to date, few if any clinically available molecules can effectively inhibit mast-cell activation. Disodium cromoglycate was shown to inhibit rodent mast cells but was a very weak inhibitor of mast-cell cytokine release [89]. Increasing recent evidence indicates that certain

flavonols, such as quercetin, are powerful inhibitors of both prestored and newly synthesized mediators from human mast cells [90]. The combination of such flavonoids with proteoglycans, such as chondroitin sulphate, appears to provide synergistic efficacy by inhibiting both activation and secretion of mast cells [91]. Appropriate CRH-R antagonists, when available, might also provide a unique therapeutic approach in skin conditions precipitated or worsened by stress [92]. Further, the prototypic stress-associated neuropeptide SP may be blocked by the application of a high-affinity neurokinin-1 receptor antagonist [93]. Thus, neurokinin-1 receptor antagonists might be useful in alleviating stress-induced hair loss and skin inflammation. NGF receptor p75 antagonists also deserve systematic exploration as candidate "antistress" drugs in the treatment of stress-triggered or stress-aggravated skin disorders, such as psoriasis and stress-induced telogen effluvium [94]. However, one evidently must be very cautious in translating results from murine models to humans. No specific pharmacological intervention—other than antidepressants and anxiolytics—is currently clinically available to manage selectively the impact of psychological stress on skin disorders in humans. However, reasonable pharmacological treatment options are coming into sight. Mast cells could be prominent targets of CRH and related peptides, contributing to neurogenic inflammation; it is therefore reasonable to propose the use of CRHR antagonists. CRHR antagonists (e.g., antalarmin or astressin) would be one class of molecules that could be tested by local administration in the model systems described, especially because higher CRHR-1 gene expression was documented in contact dermatitis [94]. Folate supplementation may be useful for BD patients with hyperhomocysteinemia. And also nonenzymatic antioxidants such as vitamins A, C, E, and carotene, trace elements including selenium, plasma iron, manganese, and zinc might be useful in patients with BD, if they are low [78] (see Table 1).

5. Conclusion

However, an adaptive immune system is also crucial in BD, with possibly both external (streptococcal, superantigens)

and internal (heat-shock- or organ-specific proteins) antigens driving the pathogenic tissue T-cell infiltrations. Better characterisation of pathogenic immune cell subsets, systemic and local antigens, and abnormal cell-activation mechanisms may help in the future to develop more specific and less toxic immunotherapeutic approaches to the still unsatisfactorily treated BD. There is some clinical evidence suggesting that hormonal alterations can influence the course and disease activity of BD. Behçet's experts should become far more attentive to the effect of psychological stress on skin disorders, not only for the benefit of their patients but also because the skin serves as a very clinically relevant model system for exploring the neuroimmunology of peripheral and central stress responses.

References

- [1] U. Tursen, A. Gurler, and A. Boyvat, "Evaluation of clinical findings according to sex in 2313 Turkish patients with Behçet's disease," *International Journal of Dermatology*, vol. 42, no. 5, pp. 346–351, 2003.
- [2] A. Gurler, A. Boyvat, and U. Tursen, "Clinical manifestations of Behçet's disease: an analysis of 2147 Patients," *Yonsei Medical Journal*, vol. 38, no. 6, pp. 423–427, 1997.
- [3] N. A. Ateş, U. Tursen, L. Tamer et al., "Glutathione S-transferase polymorphisms in patients with drug eruption," *Archives of Dermatological Research*, vol. 295, no. 10, pp. 429–433, 2004.
- [4] L. Tamer, U. Tursen, G. Eskandari et al., "N-acetyltransferase 2 polymorphisms in patients with Behçet's disease," *Clinical and Experimental Dermatology*, vol. 30, no. 1, pp. 56–60, 2005.
- [5] G. Koptagel Ilal, O. Tuncer, G. Enbiyaoglu, and Z. Bayramoglu, "A psychosomatic investigation of Behçet's disease," *Psychotherapy and Psychosomatics*, vol. 40, no. 1–4, pp. 263–271, 1983.
- [6] P. Sánchez Sobrino, C. P. Fernández, J. L. L. Ferreira, B. M. Gil, R. P. Carballeira, and R. V. García-Mayor, "Behçet disease with isolated acth deficiency," *Endocrinología y Nutrición*, vol. 56, no. 9, pp. 463–466, 2009.
- [7] U. Tursen, "Activation markers in Behçet's disease," *Turkderm*, vol. 43, pp. 74–86, 2009.
- [8] S. Hirohata and H. Kikuchi, "Behçet's disease," *Arthritis Research and Therapy*, vol. 5, no. 3, pp. 139–146, 2003.
- [9] K. Saglam, A. Serce, M. Yilmaz et al., "Trace elements and antioxidant enzymes in Behçet's disease," *Rheumatology International*, vol. 22, no. 3, pp. 93–96, 2002.
- [10] A. Erel, E. Özsoy, G. Biberoglu et al., "Serum levels of vitamins A, C, and E, β -carotene, selenium, and zinc in patients with Behçet's disease: a controlled study," *Biological Trace Element Research*, vol. 95, no. 2, pp. 97–105, 2003.
- [11] J. L. Mege, N. Dilsen, V. Sanguedolce et al., "Overproduction of monocyte derived tumor necrosis factor α , interleukin (IL) 6, IL-8 and increased neutrophil superoxide generation in Behçet's disease. A comparative study with familial Mediterranean fever and healthy subjects," *The Journal of Rheumatology*, vol. 20, no. 9, pp. 1544–1549, 1993.
- [12] S. Şahin, R. Lawrence, H. Direskeneli, V. Hamuryudan, H. Yazici, and T. Akoğlu, "Monocyte activity in Behçet's disease," *Rheumatology*, vol. 35, no. 5, pp. 424–429, 1996.
- [13] Ş. Şahin, T. Akoglu, H. Direskeneli, L. S. Şen, and R. Lawrence, "Neutrophil adhesion to endothelial cells and factors affecting adhesion in patients with Behçet's disease," *Annals of the Rheumatic Diseases*, vol. 55, no. 2, pp. 128–133, 1996.
- [14] E. V. Maytin, "Heat shock proteins and molecular chaperones: implications for adaptive responses in the skin," *Journal of Investigative Dermatology*, vol. 104, no. 4, pp. 448–455, 1995.
- [15] T. Lehner, "The role of heat shock protein, microbial and autoimmune agents in the aetiology of Behçet's disease," *International Reviews of Immunology*, vol. 14, no. 1, pp. 21–32, 1997.
- [16] T. Lehner, E. Lavery, R. Smith, R. Van Der Zee, Y. Mizushima, and T. Shinnick, "Association between the 65-kilodalton heat shock protein, *Streptococcus sanguis*, and the corresponding antibodies in Behçet's syndrome," *Infection and Immunity*, vol. 59, no. 4, pp. 1434–1441, 1991.
- [17] Y. Imamura, M. S. Kurokawa, H. Yoshikawa et al., "Involvement of Th1 cells and heat shock protein 60 in the pathogenesis of intestinal Behçet's disease," *Clinical and Experimental Immunology*, vol. 139, no. 2, pp. 371–378, 2005.
- [18] S. Kaneko, N. Suzuki, N. Yamashita et al., "Characterization of T cells specific for an epitope of human 60-kD heat shock protein (hsp) in patients with Behçet's disease (BD) in Japan," *Clinical and Experimental Immunology*, vol. 108, no. 2, pp. 204–212, 1997.
- [19] T. Tanaka, N. Yamakawa, H. Yamaguchi et al., "Common ntigenicity between *Yersinia enterocolitica*-derived heat-shock protein and the retina, and its role in uveitis," *Ophthalmic Research*, vol. 28, no. 5, pp. 284–288, 1996.
- [20] M. R. Stanford, E. Kasp, R. Whiston et al., "Heat shock protein peptides reactive in patients with Behçet's disease are uveitogenic in Lewis rats," *Clinical and Experimental Immunology*, vol. 97, no. 2, pp. 226–231, 1994.
- [21] S. Taysi, I. Kocer, R. Memisogullari, and A. Kiziltunc, "Serum oxidant/antioxidant status in patients with Behçet's disease," *Annals of Clinical and Laboratory Science*, vol. 32, no. 4, pp. 377–382, 2002.
- [22] A. S. Aynacioglu, A. Bozkurt, M. Nacak et al., "N-acetyltransferase polymorphism in patients with Behçet's disease," *European Journal of Clinical Pharmacology*, vol. 57, no. 9, pp. 659–662, 2001.
- [23] T. Yoshida, M. Tanaka, A. Sotomatsu, K. Okamoto, and S. Hirai, "Serum of Behçet's disease enhances superoxide production of normal neutrophils," *Free Radical Research*, vol. 28, no. 1, pp. 39–44, 1998.
- [24] K. Kose, C. Yazici, N. Cambay, O. Ascioglu, and P. Dogan, "Lipid peroxidation and erythrocyte antioxidant enzymes in patients with Behçet's disease," *Tohoku Journal of Experimental Medicine*, vol. 197, no. 1, pp. 9–16, 2002.
- [25] M. Y. B. Çimen, T. I. Kaya, G. Eskandari, U. Tursen, G. Ikizoglu, and U. Atik, "Oxidant/antioxidant status in patients with recurrent aphthous stomatitis," *Clinical and Experimental Dermatology*, vol. 28, no. 6, pp. 647–650, 2003.
- [26] M. Calis, F. Ates, C. Yazici et al., "Adenosine deaminase enzyme levels, their relation with disease activity, and the effect of colchicine on adenosine deaminase levels in patients with Behçet's disease," *Rheumatology International*, vol. 25, no. 6, pp. 452–456, 2005.
- [27] M. Önder and M. A. Güreş, "The multiple faces of Behçet's disease and its aetiological factors," *Journal of the European Academy of Dermatology and Venereology*, vol. 15, no. 2, pp. 126–136, 2001.
- [28] C. Yazici, K. Köse, M. Çalış, M. Demir, M. Kirnap, and F. Ateş, "Increased advanced oxidation protein products in Behçet's

- disease: a new activity marker?" *British Journal of Dermatology*, vol. 151, no. 1, pp. 105–111, 2004.
- [29] H. Moshage, "Nitric oxide determinations: much ado about NO⁺-thing?" *Clinical Chemistry*, vol. 43, no. 4, pp. 553–556, 1997.
 - [30] D. J. Parks, M. K. Cheung, C. C. Chan, and F. G. Roberge, "The role of nitric oxide in uveitis," *Archives of Ophthalmology*, vol. 112, no. 4, pp. 544–546, 1994.
 - [31] A. Örem, B. Vanizor, G. Çimşit, E. Kiran, O. Değer, and M. Malkoç, "Decreased nitric oxide production in patients with Behçet's disease," *Dermatology*, vol. 198, no. 1, pp. 33–36, 1999.
 - [32] C. Salvarani, L. Boiardi, B. Casali et al., "Endothelial nitric oxide synthase gene polymorphisms in Behçet's disease," *The Journal of Rheumatology*, vol. 29, no. 3, pp. 535–540, 2002.
 - [33] C. Evereklioglu, M. Çekmen, A. Özkiriş, L. Karabaş, and M. Çaliş, "The pathophysiological significance of red blood cell nitric oxide concentrations in inflammatory Behçet's disease," *Mediators of Inflammation*, vol. 12, no. 4, pp. 255–256, 2003.
 - [34] S. Kiraz, I. Ertenli, M. Çalgüneri et al., "Interactions of nitric oxide and superoxide dismutase in Behçet's disease," *Clinical and Experimental Rheumatology*, vol. 19, no. 5, pp. S25–S29, 2001.
 - [35] G. Yilmaz, S. Sizmaz, E. D. Yilmaz, S. Duman, and P. Aydin, "Aqueous humor nitric oxide levels in patients with Behçet disease," *Retina*, vol. 22, no. 3, pp. 330–335, 2002.
 - [36] H. Er, C. Evereklioglu, T. Cumurcu et al., "Serum homocysteine level is increased and correlated with endothelin-1 and nitric oxide in Behçet's disease," *British Journal of Ophthalmology*, vol. 86, no. 6, pp. 653–657, 2002.
 - [37] U. Ikeda, M. Ikeda, S. Minota, and K. Shimada, "Homocysteine increases nitric oxide synthesis in cytokine-stimulated vascular smooth muscle cells," *Circulation*, vol. 99, no. 9, pp. 1230–1235, 1999.
 - [38] T. Hirano, "Interleukin-6 and its relation to inflammation and disease," *Clinical Immunology and Immunopathology*, vol. 62, no. 1, pp. S60–S65, 1991.
 - [39] J. V. Ghate and J. L. Jorizzo, "Behçet's disease and complex aphthosis," *Journal of the American Academy of Dermatology*, vol. 40, no. 1, pp. 1–18, 1999.
 - [40] M. Xiong, G. Elson, D. Legarda, and S. J. Leibovich, "Production of vascular endothelial growth factor by murine macrophages: regulation by hypoxia, lactate, and the inducible nitric oxide synthase pathway," *American Journal of Pathology*, vol. 153, no. 2, pp. 587–598, 1998.
 - [41] H. Takagi, G. L. King, N. Ferrara, and L. P. Aiello, "Hypoxia regulates vascular endothelial growth factor receptor KDR/Flk gene expression through adenosine A2 receptors in retinal capillary endothelial cells," *Investigative Ophthalmology and Visual Science*, vol. 37, no. 7, pp. 1311–1321, 1996.
 - [42] C. Salvarani, L. Boiardi, B. Casali et al., "Vascular endothelial growth factor gene polymorphisms in Behçet's disease," *The Journal of Rheumatology*, vol. 31, no. 9, pp. 1785–1789, 2004.
 - [43] B. Winters, Z. Mo, E. Brooks-Asplund et al., "Reduction of obesity, as induced by leptin, reverses endothelial dysfunction in obese (Lep(ob)) mice," *Journal of Applied Physiology*, vol. 89, no. 6, pp. 2382–2390, 2000.
 - [44] M. S. Zumbach, M. W. J. Boehme, P. Wahl, W. Stremmel, R. Ziegler, and P. P. Nawroth, "Tumor necrosis factor increases serum leptin levels in humans," *Journal of Clinical Endocrinology and Metabolism*, vol. 82, no. 12, pp. 4080–4082, 1997.
 - [45] A. G. W. Moses, N. Dowidar, B. Holloway, I. Waddell, K. C. H. Fearon, and J. A. Ross, "Leptin and its relation to weight loss, ob gene expression and the acute-phase response in surgical patients," *British Journal of Surgery*, vol. 88, no. 4, pp. 588–593, 2001.
 - [46] G. Dickstein, C. Schechner, W. E. Nicholson et al., "Adrenocorticotropin stimulation test: effects of basal cortisol level, time of day, and suggested new sensitive low dose test," *Journal of Clinical Endocrinology and Metabolism*, vol. 72, no. 4, pp. 773–778, 1991.
 - [47] R. N. Clayton, "Short Synacthen test versus insulin stress test for assessment of the hypothalamo-pituitary-adrenal axis: controversy revisited," *Clinical Endocrinology*, vol. 44, no. 2, pp. 147–149, 1996.
 - [48] R. Colak, Y. Ozkan, S. U. Cengiz, Y. Saral, B. C. Kandi, and I. Halifeoglu, "A comparison between the effects of low (1 µg) and standard dose (250 µg) ACTH stimulation tests on adrenal cortex functions with Behçet's disease," *J EADV*, vol. 20, no. 6, pp. 721–725, 2006.
 - [49] G. P. Chrousos and I. J. Elenkov, "Interactions of the endocrine and immune systems," in *Endocrinology*, L. J. De Groot and J. L. Jameson, Eds., pp. 571–586, Saunders, Philadelphia, Pa, USA, 4th edition, 2001.
 - [50] W. Arlt and B. Allolio, "Adrenal insufficiency," *The Lancet*, vol. 361, no. 9372, pp. 1881–1893, 2003.
 - [51] C. Jorgensen, N. Bressot, C. Bologna, and J. Sany, "Dysregulation of the hypothalamo-pituitary axis in rheumatoid arthritis," *The Journal of Rheumatology*, vol. 22, no. 10, pp. 1829–1833, 1995.
 - [52] J. Rovensky, J. Bakošová, J. Koška, L. Kšinantová, D. Ježová, and M. Vigaš, "Somatotropic, lactotropic and adrenocortical responses to insulin-induced hypoglycemia in patients with rheumatoid arthritis," *Annals of the New York Academy of Sciences*, vol. 966, pp. 263–270, 2002.
 - [53] M. A. Gutierrez, M. E. Garcia, J. A. Rodriguez, S. Rivero, and S. Jacobelli, "Hypothalamic-pituitary-adrenal axis function with active rheumatoid arthritis: a controlled study using insulin hypoglycemia stress test and prolactin stimulation," *The Journal of Rheumatology*, vol. 26, pp. 277–281, 1999.
 - [54] M. A. Gutiérrez, M. E. Garcia, J. A. Rodriguez, S. Rivero, and S. Jacobelli, "Hypothalamic-pituitary-adrenal axis function and prolactin secretion in systemic lupus erythematosus," *Lupus*, vol. 7, no. 6, pp. 404–408, 1998.
 - [55] E. O. Johnson, P. G. Vlachoyiannopoulos, F. N. Skopouli, A. G. Tzioufas, and H. M. Moutsopoulos, "Hypofunction of the stress axis in Sjögren's syndrome," *The Journal of Rheumatology*, vol. 25, pp. 1508–1514, 1998.
 - [56] R. G. Lahita, "The role of sex hormones in systemic lupus erythematosus," *Current Opinion in Rheumatology*, vol. 11, no. 5, pp. 352–356, 1999.
 - [57] S. A. Ahmed, W. J. Penhale, and N. Talal, "Sex hormones, immune responses, and autoimmune diseases. Mechanisms of sex hormone action," *American Journal of Pathology*, vol. 121, no. 3, pp. 531–551, 1985.
 - [58] K. Bork, B. Fischer, and G. Dewald, "Recurrent episodes of skin angioedema and severe attacks of abdominal pain induced by oral contraceptives or hormone replacement therapy," *American Journal of Medicine*, vol. 114, no. 4, pp. 294–298, 2003.
 - [59] S. Yavuz, G. Ozilhan, Y. Elbir, A. Tolunay, E. Eksioğlu-Demiralp, and H. Direskeneli, "Activation of neutrophils by testosterone in Behçet's disease," *Clinical and Experimental Rheumatology*, vol. 25, no. 4, pp. S-46–S-51, 2007.
 - [60] R. Paus, "Does prolactin play a role in skin biology and pathology?" *Medical Hypotheses*, vol. 36, no. 1, pp. 33–42, 1991.

- [61] Y. Poumay, G. Jolivet, M. R. Pittelkow et al., "Human epidermal keratinocytes upregulate expression of the prolactin receptor after the onset of terminal differentiation, but do not respond to prolactin," *Archives of Biochemistry and Biophysics*, vol. 364, no. 2, pp. 247–253, 1999.
- [62] K. Foitzik, E. A. Langan, and R. Paus, "Prolactin and the skin: a dermatological perspective on an ancient pleiotropic peptide hormone," *Journal of Investigative Dermatology*, vol. 129, no. 5, pp. 1071–1087, 2009.
- [63] M. Atasoy, S. Karatay, K. Yildirim, M. Kadi, T. Erdem, and K. Senel, "The relationship between serum prolactin levels and disease activity in patients with Behcet's disease," *Cell Biochemistry and Function*, vol. 24, no. 4, pp. 353–356, 2006.
- [64] K. C. Apaydin, Y. Duranoglu, Y. Özgürel, and O. Saka, "Serum prolactin levels in Behcet's disease," *Japanese Journal of Ophthalmology*, vol. 44, no. 4, pp. 442–445, 2000.
- [65] H. Houman, I. Ben Ghorbel, M. Lamoum et al., "Prolactin levels in Behcet's disease: no correlation with disease manifestations and activity," *Annales de Medecine Interne*, vol. 152, no. 3, pp. 209–211, 2001.
- [66] G. Keser, F. Oksel, G. Ozgen, K. Aksu, and E. Doganavsargil, "Serum prolactin levels in Behcet's Syndrome," *Clinical Rheumatology*, vol. 18, pp. 351–352, 1999.
- [67] S. Karakus, O. Ozcebe, H. Demiroglu, D. Ozatli, Y. Buyukasik, and I. Haznedaroglu, "Evaluation of plasma hormone levels in Behcet's disease," in *Proceedings of the 9th International Conference on Behcet's Disease*, D. Bang, E. S. Lee, and S. Lee, Eds., p. 549, Seoul, Korea, 2000.
- [68] N. Gül, A. Gül, F. Alagöl et al., "The role of 21-hydroxylase deficiency in the pathogenesis of Behcet's disease," in *Proceedings of the 9th International Conference on Behcet's Disease*, D. Bang, E. S. Lee, and S. Lee, Eds., p. 625, Seoul, Korea, 2000.
- [69] C. Mat, C. Demirkesen, Ö. A. Çökerler et al., "receptors density in scrotal skin of Behcet's Disease," in *Proceedings of the 9th International Conference on Behcet's Disease*, D. Bang, E. S. Lee, and S. Lee, Eds., pp. 646–648, Seoul, Korea, 2000.
- [70] H. S. F. M. Proença, C. Ferreira, M. Miranda, A. Castanheira-Dinis, and M. Monteiro-Grillo, "Serum prolactin levels and Behcet disease," *European Journal of Ophthalmology*, vol. 17, no. 3, pp. 404–407, 2007.
- [71] P. C. Arck, A. Slominski, T. C. Theoharides, E. M. J. Peters, and R. Paus, "Neuroimmunology of stress: skin takes center stage," *Journal of Investigative Dermatology*, vol. 126, no. 8, pp. 1697–1704, 2006.
- [72] A. Reich, A. Orda, B. Wiśnicka, and J. C. Szepietowski, "Plasma concentration of selected neuropeptides in patients suffering from psoriasis," *Experimental Dermatology*, vol. 16, no. 5, pp. 421–428, 2007.
- [73] J. Salomon and E. Baran, "The role of selected neuropeptides in pathogenesis of atopic dermatitis," *Journal of the European Academy of Dermatology and Venereology*, vol. 22, no. 2, pp. 223–228, 2008.
- [74] Y. H. Jang, S. Lee, and E. S. Lee, "Role of neuropeptides in Behcet's disease in relation to clinical activity," *Journal of Dermatological Science*, vol. 41, no. 1, pp. 77–79, 2006.
- [75] T. Aki, Y. Karıncaoglu, M. Seyhan, and K. Batcioglu, "Serum substance P and calcitonin gene-related peptide levels in Behcet's disease and their association with disease activity," *Clinical and Experimental Dermatology*, vol. 31, no. 4, pp. 583–587, 2006.
- [76] A. Al-Dalaan, S. Al-Sedairy, S. Al-Balaa et al., "Enhanced interleukin 8 secretion in circulation of patients with Behcet's disease," *The Journal of Rheumatology*, vol. 22, no. 5, pp. 904–907, 1995.
- [77] A. M. Vollmar, "The role of atrial natriuretic peptide in the immune system," *Peptides*, vol. 26, no. 6, pp. 1086–1094, 2005.
- [78] A. Ahluwalia, R. J. MacAllister, and A. J. Hobbs, "Vascular actions of natriuretic peptides—cyclic GMP-dependent and -independent mechanisms," *Basic Research in Cardiology*, vol. 99, no. 2, pp. 83–89, 2004.
- [79] U. Tursen, B. Ulubas, T. I. Kaya, H. Pekdemirt, and G. İkizoglu, "Cardiac complications in Behcet's disease," *Clinical and Experimental Dermatology*, vol. 27, pp. 651–653, 2002.
- [80] R. Yağı, Y. Totan, E. Özlük, H. Özyurt, G. Akbay, and M. Eksioğlu, "Serum levels of natriuretic peptides in patients with Behcet's disease," *Clinical Rheumatology*, vol. 27, no. 9, pp. 1153–1158, 2008.
- [81] T. J. Wang, M. G. Larson, D. Levy et al., "Plasma natriuretic peptide levels and the risk of cardiovascular events and death," *The New England Journal of Medicine*, vol. 350, no. 7, pp. 655–663, 2004.
- [82] K. Aiura, M. Ueda, M. Endo, and M. Kitajima, "Circulating concentrations and physiologic role of atrial natriuretic peptide during endotoxic shock in the rat," *Critical Care Medicine*, vol. 23, no. 11, pp. 1898–1906, 1995.
- [83] T. Maack, M. Suzuki, F. A. Almeida et al., "Physiological role of silent receptors of atrial natriuretic factor," *Science*, vol. 238, no. 4827, pp. 675–678, 1987.
- [84] A. Gur, A. J. Sarac, Y. K. Burkan, K. Nas, and R. Cevik, "Arthropathy, quality of life, depression, and anxiety in Behcet's disease: relationship between arthritis and these factors," *Clinical Rheumatology*, vol. 25, no. 4, pp. 524–531, 2006.
- [85] M. Koçak, M. M. Başar, G. Vahapoğlu, H. C. Mert, and S. Güngör, "The effect of behcet's disease on sexual function and psychiatric status of premenopausal women," *Journal of Sexual Medicine*, vol. 6, no. 5, pp. 1341–1348, 2009.
- [86] E. Taner, B. Coşar, S. Burhanoglu, E. Calikoğlu, M. Onder, and Z. Arikan, "Depression and anxiety in patients with Behcet's disease compared with that in patients with psoriasis," *International Journal of Dermatology*, vol. 46, no. 11, pp. 1118–1124, 2007.
- [87] F. Uğuz, R. Dursun, N. Kaya, and A. Savas Cilli, "Quality of life in patients with Behcet's disease: the impact of major depression," *General Hospital Psychiatry*, vol. 29, no. 1, pp. 21–24, 2007.
- [88] H. S. Capoor and C. M. E. R. Payne, "Does psychological intervention help chronic skin conditions?" *Postgraduate Medical Journal*, vol. 74, no. 877, pp. 662–664, 1998.
- [89] S. B. Seo, S. J. Park, S. T. Park et al., "Disodium cromoglycate inhibits production of immunoglobulin E," *Immunopharmacology and Immunotoxicology*, vol. 23, no. 2, pp. 229–237, 2001.
- [90] M. W. Martin, A. J. O'Sullivan, and B. D. Gomperts, "Inhibition by cromoglycate and some flavonoids of nucleoside diphosphate kinase and of exocytosis from permeabilized mast cells," *British Journal of Pharmacology*, vol. 115, no. 6, pp. 1080–1086, 1995.
- [91] T. C. Theoharides and L. Bielory, "Mast cells and mast cell mediators as targets of dietary supplements," *Annals of Allergy, Asthma and Immunology*, vol. 93, no. 2, pp. S24–S34, 2004.
- [92] P. C. Arck, B. Handjiski, E. Hagen, R. Joachim, B. F. Klapp, and R. Paus, "Indications for a 'brain-hair follicle axis (BHA)': inhibition of keratinocyte proliferation and up-regulation of keratinocyte apoptosis in telogen hair follicles by stress and substance P," *The FASEB Journal*, vol. 15, no. 13, pp. 2536–2538, 2001.
- [93] P. C. Arck, B. Handjiski, A. Kuhlmei et al., "Mast cell deficient and neurokinin-1 receptor knockout mice are protected from

stress-induced hair growth inhibition,” *Journal of Molecular Medicine*, vol. 83, no. 5, pp. 386–396, 2005.

- [94] L. Wang, M. Million, J. Rivier et al., “CRF receptor antagonist astressin-B reverses and prevents alopecia in CRF over-expressing mice,” *PLoS One*, vol. 6, no. 2, article 16377, 2011.

Review Article

Diagnosis/Classification Criteria for Behcet's Disease

Fereydoun Davatchi

Behcet's Unit, Rheumatology Research Center, Shariati Hospital, Tehran University of Medical Sciences, Tehran 14117, Iran

Correspondence should be addressed to Fereydoun Davatchi, fddh@davatchi.net

Received 10 June 2011; Accepted 23 June 2011

Academic Editor: Ümit Tursen

Copyright © 2012 Fereydoun Davatchi. This is an open access article distributed under the Creative Commons Attribution License, which permits unrestricted use, distribution, and reproduction in any medium, provided the original work is properly cited.

Historical Background. The ISG criteria for Behcet's, created in 1990, have excellent specificity, but lack sensitivity. The International Criteria for Behcet's Disease (ICBD) was created in 2006, as replacement to ISG. The aim of this study was to compare their performance. *ISG and ICBD Criteria.* For ISG oral aphthosis is mandatory. The presence of any two of the following (genital aphthosis, skin lesions, eye lesions, and positive pathergy test) will diagnose/classify the patient as BD. For ICBD, vascular lesions were added, while oral aphthosis is no more mandatory. Getting 3 or more points diagnose/classify the patient as BD (genital aphthosis 2 points, eye lesions 2 points, and the remaining each one point). *Performance and Comparison of ISG and ICBD.* Their sensitivity, specificity, and accuracy (percent agreement), were tested in three independent cohort of patients from Far-East (China), Middle-East (Iran), and Europe (Germany). The sensitivity for ISG was respectively 65.4%, 78.1%, 83.7% and for ICBD 87%, 98.2%, and 96.5%. The specificity for ISG was 99.2%, 98.8%, 89.5% and for ICBD 94.1%, 95.6%, and 73.7%. The accuracy for ISG was 74.2%, 85.5%, 85.5% and for ICBD 88.9%, 97.3%, and 89.5%. *Conclusion.* ICBD has better sensitivity, and accuracy than ISG.

1. Historical Background

Although Behcet's Disease (BD) is relatively a young disease (described in 1937), it has already 16 sets of diagnosis/classification criteria. The first of them was proposed by Curth in 1946, less than 10 years after the description of the disease [1]. It was followed by Hewitt et al. in 1969 [2], Mason and Barnes in 1969 [3], Hewitt et al. revised in 1971 [4], Japan in 1972 [5], Hubault and Hamza in 1974 [6], O'Duffy in 1974 [7], Chen in 1980 [8], Dilsen et al. in 1986 [9], Japan revised in 1988 [10], International Study Group (ISG) in 1990 [11], Iran in 1993 [12], Classification Tree in 1993 [13], Dilsen revised in 2000 [14], Korea in 2003 [15, 16], and the International Criteria for Behcet's Disease (ICBD) in 2006 [17–19].

The ISG criteria were created in 1990 to bring a consensus on one set of criteria by the collaboration of France, Iran, Japan, Tunisia, Turkey, UK, and USA. With the sensitivity of ISG criteria being low [12, 20–25], during the first International Workshop of Behcet's Disease in Kuhtai (Austria), it was decided to create an international team to evaluate the performance of ISG criteria and to compare it with the existing BD criteria and revise it if necessary.

The ITR-ICBD team was founded in 2004 with the participation of 27 countries (Austria, Azerbaijan, China, Egypt, France, Germany, Greece, India, Iran, Iraq, Israel, Italy, Japan, Jordan, Libya, Morocco, Pakistan, Portugal, Russia, Saudi Arabia, Singapore, Spain, Taiwan, Thailand, Tunisia, Turkey, and USA). The International Criteria for Behcet's Disease (ICBD) were presented to the International Conference of Behcet's Disease in Lisbon (Portugal) in 2006. Originally it had two formats, like the Iranian criteria. Later, it was decided to keep only the traditional format [17–19]. The ICBD were presented to the 2007 World Congress of Dermatology in Argentina and to 2009 ACR congress of Rheumatology in the USA [19].

2. ISG and ICBD Criteria

The ISG criteria [11] use 5 items. Two items are mucous membrane manifestations. They are oral aphthosis (OA) and genital aphthosis (GA). The third item is skin manifestations, comprising pseudofolliculitis (PF) and erythema nodosum (EN). The fourth item is ocular manifestations. They are anterior uveitis (AU), posterior uveitis (PU), and retinal

vasculitis (RV). The fifth item is the presence of pathergy phenomenon (PP). It is detected by the pathergy test [26–30]. In ISG criteria, the presence of OA is mandatory. Two other items from the 4 remaining (GA, skin, eye, PP) are necessary to classify a patient as having BD.

For the international criteria, the ICBD [17–19], vascular manifestations (VMs) have been added to the 5 items of ISG criteria, because they are one of the characteristics of BD, and were used in many criteria before the advent of ISG (Mason and Barnes, Hewitt, Hubault and Hamza, Dilsen, Japan revised, and Dilsen revised criteria). VM is defined as superficial phlebitis, deep vein thrombosis, large vein thrombosis, arterial thrombosis, and aneurysm. Therefore, ICBD use six items: OA, GA, skin (PF, EN), eye lesions (AU, PU, RV), VM, and PP. In the ICBD, genital aphthous lesions and eye lesions have more diagnostic value than the others. They get each 2 points. The other 4 items (OA, skin, VM, PP) get one point each. A patient has to get 3 or more points to be diagnosed/classified as having BD.

3. Performance and Comparison of ISG and ICBD

Many ways and methods can be used to evaluate the performance of a criteria set. The most common used are sensitivity, specificity, and accuracy. Other methods are the positive predictive value, the negative predictive value, the positive likelihood ratio, the negative likelihood ratio, the diagnostic odds ratio, and Youden's index [35–39].

Sensitivity is the number of BD patients correctly classified (diagnosed) by the criteria. It is expressed as percentage (number of diagnosed BD patients, divided by the total number of BD patients, and then multiplied by 100) [35]. The sensitivity of ISG in their cohort of 886 patients was 92% [11]. The 95% confidence interval (95% CI) was 90% to 93.6%. The sensitivity of ICBD in their cohort of 2556 BD patients was 96.1% (95% CI 95.3–96.8). By chi-square test the difference between the two sets of criteria is statistically significant ($\chi^2 = 23.439$, $P < 0.001$). The sensitivity of ISG in the ICBD cohort of patients was 82.4% (95% CI 80.9–83.9).

It is important to look at the sensitivity of the two criteria in independent cohort of patients. Three studies validated the ICBD in their cohort of patients: Germany in 2008 [31], China in 2008 [32], and Iran in 2010 [33]. The sensitivity of ISG was, respectively, 83.7% (95% CI 74.3–90.1), 65.4% (95% CI 60.2–70.5), and 78.1% (95% CI 77–79.1). The sensitivity of ICBD was, respectively, 96.5% (95% CI 89.7–99.2), 87% (95% CI 82.8–90.2), and 98.2% (95% CI 97.8–98.5).

Table 1 shows the sensitivity of ISG in different cohort of patients from different parts of world [11, 12, 17–24, 31–33].

Specificity is the number of non-BD patients, correctly recognized as not having BD. It is expressed as percentage (number of non-BD patients correctly recognized as not having BD, divided by the total number of non-BD patients, then multiplied by 100) [35]. The specificity of ISG criteria in their own cohort of patients was 97% (95% CI 90.8–99.3). However, the number of control patients was only

TABLE 1: Sensitivity of different classification/diagnosis criteria.

Study	Reference	Number	Criteria	Sensitivity	
				%	95% CI
ISG 1990	[11]	886	ISG	92	90.0–93.6
			ICBD	—	—
Iran 1993	[12, 13]	2069	ISG	86.2	84.6–87.6
			ICBD	—	—
China 1996	[20]	79	ISG	—	—
			ICBD	—	—
APLAR 1998	[21]	216	ISG	72.2	65.9–77.8
			ICBD	—	—
Russia 2000	[22]	105	ISG	79.8	71.2–86.6
			ICBD	—	—
USA 2000	[23]	164	ISG	75.6	68.4–81.6
			ICBD	—	—
India 2004	[24]	50	ISG	72	58.2–82.6
			ICBD	—	—
Singapore 2004	[24]	37	ISG	46	31.1–61.6
			ICBD	—	—
China 2004	[24]	98	ISG	81	71.6–87.3
			ICBD	—	—
Korea 2004	[24]	1454	ISG	58	55.4–60.5
			ICBD	—	—
Iran 2004	[24]	4900	ISG	82	80.9–83.0
			ICBD	—	—
ICBD 2006	[17–19]	2556	ISG	82.4	80.9–83.8
			ICBD	96.1	95.3–96.8
Germany 2008	[31]	86	ISG	83.7	74.3–90.1
			ICBD	96.5	89.7–99.2
China 2008	[32]	322	ISG	65.4	60.2–70.5
			ICBD	87	82.8–90.2
IRAN 2010	[33]	6128	ISG	78.1	77.0–79.1
			ICBD	98.2	97.8–98.5

95% CI: 95% confidence interval.

97, and all other control patients having oral aphthosis were discarded from the original cohort of control patients [34]. The specificity of ICBD in their cohort of patients was 88.7% (95% CI 86.8–90.4). The specificity of ISG and ICBD in Germany, China, and Iran was, respectively, 89.5%, 99.2% and 98.8% (ISG), and 73.7%, 94.1%, and 95.6% (ICBD). Table 2 shows the specificity of different criteria in different studies.

Accuracy or percent agreement is the ability of the criteria to correctly recognize BD patients from the non-BD patients. It is also expressed by percentage (number of diagnosed BD patients + number of non-BD patients correctly recognized as not having BD, divided by the total number of BD patients + total number of non-BD patients, and then multiplied by 100) [35]. The accuracy of ISG in their own cohort of patients was 92% (95% CI 90.1–93.5). The accuracy of ICBD in their own cohort of patients was 93.8% (95% CI 93–94.5). The accuracy of ISG and ICBD in Germany, China, and Iran was, respectively, 85.5%, 7402% and 85.5% (ISG),

TABLE 2: Specificity of different classification/diagnosis criteria.

Study	Reference	Number	Criteria	Specificity	
				%	95% CI
ISG 1990	[11]	97	ISG	97.0	90.8–99.3
			ICBD	—	—
Iran 1993	[12, 13]	1540	ISG	97.5	96.6–98.2
			ICBD	—	—
China 1996	[20]	35	ISG	79.8	63.7–90.1
			ICBD	—	—
APLAR 1998	[21]	145	ISG	99.3	95.7–100
			ICBD	—	—
Russia 2000	[22]	233	ISG	99.8	98.0–100
			ICBD	—	—
ICBD 2006	[17–19]	1163	ISG	96.0	94.6–96.9
			ICBD	88.7	86.8–90.4
Germany 2008	[31]	38	ISG	89.5	75.1–96.3
			ICBD	73.7	57.8–85.1
China 2008	[32]	118	ISG	99.2	94.8–100
			ICBD	94.1	88.0–97.3
IRAN 2010	[33]	3400	ISG	98.8	98.4–99.1
			ICBD	95.6	94.8–96.2

95% CI: 95% confidence interval.

TABLE 3: Accuracy of different classification/diagnosis criteria.

Study	Reference	Number	Criteria	Accuracy	
				%	95% CI
ISG 1990	[11]	983	ISG	92	90.1–93.5
			ICBD	—	—
Iran 1993	[12, 13]	3609	ISG	91	90.0–91.9
			ICBD	—	—
China 1996	[20]	114	ISG	79.8	71.4–86.2
			ICBD	—	—
APLAR 1998	[21]	361	ISG	85.8	81.9–89.1
			ICBD	—	—
Russia 2000	[22]	338	ISG	89.8	86.2–92.7
			ICBD	—	—
ICBD 2006	[17–19]	3719	ISG	86.7	85.6–87.7
			ICBD	93.8	93.0–94.5
Germany 2008	[31]	124	ISG	85.5	78.1–90.7
			ICBD	89.5	82.7–93.8
China 2008	[32]	450	ISG	74.2	70.0–78.0
			ICBD	88.9	85.6–91.5
IRAN 2010	[33]	9528	ISG	85.5	84.8–86.2
			ICBD	97.3	97.0–97.6

95% CI: 95% confidence interval.

and 89.5%, 88.9%, and 97.3% (ICBD). Table 3 shows the accuracy of different criteria in different studies.

Positive predictive value (PPV) demonstrates the probability that the positive test be true positive. PPV is more influenced by specificity than sensitivity. A criteria set with 90% sensitivity and 90% specificity will have a PPV of 90. If sensitivity increases to 95, PPV will improve to 90.5%,

while if specificity increases to 95%, PPV will improve to 94.8%. PPV is also greatly influenced by the prevalence of the disease. Taking the above example, the PPV remains the same (90) in a dedicated BD clinic, where 50% of patients have BD and 50% are controls (patients mimicking BD but are not true BD). In the general population, with a prevalence of 80 for 100,000 inhabitants, the PPV becomes only 0.72. Therefore the results calculated in a specific setting cannot be used in another setting [33]. The PPV was higher for ISG than ICBD criteria in the 3 independent set of patients; however, the difference was very small in the Iranian patients, only 2.8% (Table 4).

Negative predictive value (NPV) indicates the probability of a negative test to be a true negative. The NPV also is influenced by the prevalence of the disease. On the contrary of PPV, the NPV is more influenced by sensitivity than specificity. It is also highly influenced by the prevalence of the disease [33].

Positive likelihood ratio (PLR) demonstrates the odds of having the disease. If PLR is superior to 5, it means that the test is related to the disease. It is highly influenced by specificity, as is the PPV. It is why the PLR is much higher for ISG criteria than ICBD (Table 4). Higher PLR for ISG means that, if ISG is positive, the chance of having BD is very high, but unfortunately ISG was negative in around 18% of subjects, in the 3 independent sets (Table 1).

Negative likelihood ratio (NLR) shows the odds of not having the disease. It is highly influenced by the sensitivity, as for the NPV. It has therefore better values for ICBD than for ISG criteria (Table 4). The high NLR for ICBD means that, if ICBD are negative, there are little chances for the patient to have BD (only 2% error rate for the Iranian patients: Table 4).

Diagnostic odds ratio (DOR) is a new way to show how much a test is reliable, like combining the PLR and NLR results. If DOR is 1, it means the test (criteria) does not discriminate between the patient and the control. The power of discrimination increases with higher values of DOR. The DOR of ISG is 294 and of ICBD is 1185 in the Iranian patients, demonstrating the high discriminative power of ICBD over ISG (Table 4).

Youden's index (YI) is a rather old (1950) and simple calculation, combining the results of sensitivity and specificity, to show the performance of the diagnosis criteria. The result goes from zero to one. The more the result approaches 1, the higher the performance of the test is. The ideal is one, meaning a sensitivity and a specificity of 100%. A sensitivity and a specificity of 90% will give a YI of 0.8. The YI of ISG is inferior to ICBD in China and Iran (Table 4).

4. Conclusion

ICBD are the latest diagnosis/classification criteria, created by the participation of 27 countries from different parts of the world. The large number of Behcet's disease patients and control patients, from inside and outside of the Silk Road, assures the variability needed to create an international criteria that can work in any country with different ethnicities.

TABLE 4: Predictive value, likelihood ratio, diagnostic odds ratio, and Youden's index.

Study	Reference	Criteria	PPV	NPV	PLR	NLR	DOR	YI
ISG 1990	[11]	ISG	96.8	92.4	30.7	0.08	371.8	0.89
		ICBD	—	—	—	—	—	—
Iran 1993	[12, 13]	ISG	97.2	87.6	34.5	0.14	243.6	0.84
		ICBD	—	—	—	—	—	—
APLAR 1998	[21]	ISG	99.0	78.1	103.1	0.28	368.4	0.71
		ICBD	—	—	—	—	—	—
Russia 2000	[22]	ISG	99.7	83.2	399	0.20	1971	0.80
		ICBD	—	—	—	—	—	—
ICBD 2006	[17–19]	ISG	95.4	84.5	20.6	0.18	112.4	0.78
		ICBD	89.5	95.8	8.5	0.04	193.4	0.85
Germany 2008	[31]	ISG	88.8	84.6	7.97	0.18	43.8	0.73
		ICBD	78.6	95.5	3.67	0.05	77.3	0.70
China 2008	[32]	ISG	98.8	74.1	81.7	0.35	234.4	0.65
		ICBD	93.6	87.9	14.7	0.14	106.7	0.81
IRAN 2010	[33]	ISG	98.5	81.9	65.1	0.22	294	0.77
		ICBD	95.7	98.2	22.3	0.02	1185	0.94

PPV: positive predictive value, NPV: negative predictive value, PLR: positive likelihood ratio, NLR: negative likelihood ratio, DOR: diagnostic odds ratio, and YI: Youden's index.

The validation of the criteria in the Far East, Middle-East, and Europe demonstrates its validity.

References

- [1] H. O. Curth, "Recurrent genito-oral aphthosis with hypopion (Behcet's syndrome)," *Archives of Dermatology*, vol. 54, pp. 179–196, 1946.
- [2] J. Hewitt, J. P. Escande, P. H. Laurent, and L. Perlemuter, "Critères de prévision du syndrome de Behçet," *Bulletin de la Société Française de Dermatologie et de Syphiligraphie*, vol. 76, pp. 565–568, 1969.
- [3] R. M. Mason and C. G. Barnes, "Behçet's syndrome with arthritis," *Annals of the Rheumatic Diseases*, vol. 28, no. 2, pp. 95–103, 1969.
- [4] J. Hewitt, J. P. Escande, and S. Manesse, "Revision of the diagnostic criteria of Behçet's syndrome," *La Presse Médicale*, vol. 79, no. 20, p. 901, 1971.
- [5] Behcet's Disease Research Committee of Japan, "Behçet's disease guide to the diagnosis of Behçet's disease (1972)," *Japanese Journal of Ophthalmology*, vol. 18, pp. 291–294, 1974.
- [6] A. Hubault and M. Hamza, "La maladie de Behçet en 1974," in *L'actualité Rhumatologique* 15, S. de Seze et al., Ed., pp. 43–55, Expansion Scientifique, Paris, France, 1974.
- [7] J. D. O'Duffy, "Critères proposés pour le diagnostic de la maladie de Behçet et notes thérapeutiques," *Revue de Médecine*, vol. 36, pp. 2371–2379, 1974.
- [8] S. P. Chen and X-Q. Zhang, "Some special clinical manifestations of Behçet's disease—report of illustrative cases and review of literature (author's transl)," *Chinese Journal of Internal Medicine*, vol. 19, no. 1, pp. 15–22, 1980.
- [9] N. Dilsen, M. Konice, and O. Aral, "Our diagnostic criteria of Behçet's disease—an overview," in *Recent Advances in Behçet's Disease*, T. Lehner and C. G. Barnes, Eds., vol. 103 of *International Congress and Symposium Series*, pp. 177–180, London Royal Society of Medicine Services, London, UK, 1986.
- [10] Y. Mizushima, "Recent research into Behçet's disease in Japan," *International Journal of Tissue Reactions*, vol. 10, no. 2, pp. 59–65, 1988.
- [11] International Study Group for Behçet's Disease, "Criteria for diagnosis of Behçet's disease," *Lancet*, vol. 335, no. 8697, pp. 1078–1080, 1990.
- [12] F. Davatchi, F. Shahram, M. Akbarian et al., "Accuracy of existing diagnosis criteria for Behçet's disease," in *Behçet's Disease*, B. Wechsler and P. Godeau, Eds., vol. 1037 of *Excerpta Medica International Congress Series*, pp. 225–228, Amsterdam, The Netherlands, 1993.
- [13] F. Davatchi, F. Shahram, M. Akbarian et al., "Classification tree for the diagnosis of Behçet's disease," in *Behçet's Disease*, B. Wechsler and P. Godeau, Eds., vol. 1037 of *Excerpta Medica International Congress Series*, pp. 245–248, Amsterdam, The Netherlands, 1993.
- [14] N. Dilsen, "About diagnostic criteria for Behçet's disease: our new proposal," in *Behçet's Disease*, D. Bang, E. S. Lee, and S. Lee, Eds., pp. 101–104, Design Mecca Publishing, Seoul, Korea, 2000.
- [15] H. K. Chang and S. Y. Kim, "Survey and validation of the criteria for Behçet's disease recently used in Korea: a suggestion for modification of the international study group criteria," *Journal of Korean Medical Science*, vol. 18, no. 1, pp. 88–92, 2003.
- [16] H. K. Chang, S. S. Lee, H. J. Bai et al., "Validation of the classification criteria commonly used in Korea and a modified set of preliminary criteria for Behçet's disease: a multi-center study," *Clinical and Experimental Rheumatology*, vol. 22, no. 4, pp. S21–S26, 2004.
- [17] International Team for the Revision of the International Criteria for Behçet's Disease, "Evaluation of the International Criteria for Behçet's disease (ICBD)," *Clinical and Experimental Rheumatology*, vol. 24, supplement 42, p. S13, 2006.
- [18] International Team for the Revision of the International Criteria for Behçet's Disease, "Revision of the International Criteria for Behçet's Disease (ICBD)," *Clinical and Experimental Rheumatology*, vol. 24, supplement 42, pp. S14–S15, 2006.

- [19] F. Davatchi, M. Schirmer, C. Zouboulis, S. Assad-Khalil, and K. T. Calamia, "on behalf International Team for the Revision of the International Criteria for Behcet's Disease," "Evaluation and Revision of the International Study Group Criteria for Behcet's Disease," in *Proceedings of the American College of Rheumatology Meeting*, Boston, Mass, USA, November 2007, abstract 1233.
- [20] Y. Dong, Q. Yao, and M. Wang, "Behcet's disease in China," in *Proceedings of the 8th APLAR Congress of Rheumatology*, p. S14, Melbourne, Australia, April 1996.
- [21] APLAR subcommittee for Behcet's Disease, "APLAR evaluation of Behcet's disease diagnosis criteria," *APLAR Journal of Rheumatology*, vol. 1, pp. 237–240, 1998.
- [22] T. Prokaeva, Z. Alekberova, T. Reshetnjak et al., "Evaluation of Behcet's disease diagnosis criteria: study from Russia," in *Behcet's Disease*, D. Bang, E. Lee, and S. Lee, Eds., pp. 598–603, Design Mecca Publishing, Seoul, Korea, 2000.
- [23] K. T. Calamia and F. Davatchi, "Sensitivity of diagnosis criteria in United States patients with Behcet's disease," in *Behcet's Disease*, D. Bang, E. Lee, and S. Lee, Eds., pp. 121–124, Design Mecca Publishing, Seoul, Korea, 2000.
- [24] F. Davatchi, F. Shahram, A. Kumar, Y. K. Cheng, C. T. Cheong, and A. Bendrups, "Comparative analysis of Behcet's disease in the APLAR region," *APLAR Journal of Rheumatology*, vol. 7, no. 1, pp. 38–43, 2004.
- [25] F. Davatchi, F. Shahram, M. Akbarian et al., "Behcet's disease-analysis of 3443 cases," *APLAR Journal of Rheumatology*, vol. 1, pp. 2–5, 1997.
- [26] P. Mansoori, C. Chams, F. Davatchi et al., "Pathergy phenomenon in Behcet's disease, new aspects," in *Rheumatology APLAR 1992*, A. R. Nasution, J. Darmawan, and H. Isbagio, Eds., pp. 111–113, Churchill Livingstone, Tokyo, Japan, 1992.
- [27] C. Chams-Davatchi, F. Davatchi, F. Shahram et al., "Longitudinal study of the Pathergy phenomenon in Behcet's disease," in *Behcet's Disease*, M. Hamza, Ed., pp. 356–358, Pub Adhoua, Tunisia, 1992.
- [28] F. Davatchi, C. Chams-Davatchi, F. Shahram et al., "Pathergy test in Behcet's disease: Change in incidence over the time," *APLAR Journal of Rheumatology*, vol. 10, no. 4, pp. 333–335, 2007.
- [29] F. Davatchi, C. Chams-Davatchi, and Z. Ghodsi, "Diagnostic value of pathergy test in Behcet's disease according to the change in incidence over the time," *Clinical Rheumatology*, vol. 30, no. 9, pp. 1151–1155, 2011.
- [30] F. Davatchi, F. Shahram, C. Chams-Davatchi et al., "How to deal with Behcet's disease in daily practice," *International Journal of Rheumatic Diseases*, vol. 13, no. 2, pp. 105–116, 2010.
- [31] A. Altenburg, N. G. Bonitsis, N. Papoutsis, M. Pasak, L. Krause, and C. C. Zouboulis, "Evaluation of diagnostic criteria including ICBD (2006) in Adamantiades-Behcet's disease patients in Germany," *Clinical Experimental Rheumatology*, vol. 26, supplement 50, p. S3, 2008.
- [32] Z. Zhang, W. Zhou, Y. Hao, Y. Wang, and Y. Dong, "Validation of the International criteria for Behcet's disease (ICBD) in China," *Clinical Experimental Rheumatology*, vol. 26, supplement 50, pp. S6–S7, 2008.
- [33] F. Davatchi, B. Sadeghi Abdollahi, and F. Shahram, "Validation of the international criteria for Behcet's disease in Iran," *International Journal of Rheumatic Diseases*, vol. 13, pp. 55–60, 2010.
- [34] International Study Group for Behcet's Disease, "Evaluation of diagnostic ("Classification") criteria in Behcet's disease: toward internationally agreed criteria," in *Behcet's Disease Basic and Clinical Aspects*, J. D. O'Duffy and E. Kokmen, Eds., pp. 11–39, Marcel dekker, New York, NY, USA, 1991.
- [35] M. Szklo and F. J. Nieto, *Epidemiology, Beyond the Basics*, Jones and Bartlett, Sudbury, Mass, USA, 2nd edition, 2007.
- [36] B. R. Kirshwood and J. A. S. C. Sterne, *Essential Medical Statistics*, Blackwell Science LTD, Malden, Mass, USA, 2nd edition, 2003.
- [37] A. S. Glas, J. G. Lijmer, M. H. Prins, G. J. Bonsel, and P. M. M. Bossuyt, "The diagnostic odds ratio: a single indicator of test performance," *Journal of Clinical Epidemiology*, vol. 56, no. 11, pp. 1129–1135, 2003.
- [38] H. C. Kraemer, "Reconsidering the odds ratio as a measure of 2×2 association in a population," *Statistics in Medicine*, vol. 23, no. 2, pp. 257–270, 2004.
- [39] W. J. Youden, "Index for rating diagnostic tests," *Cancer*, vol. 3, no. 1, pp. 32–35, 1950.

Review Article

Musculoskeletal Findings in Behcet's Disease

Ali Bicer

Department of Physical Medicine and Rehabilitation, Faculty of Medicine, Mersin University, Zeytinlibahce Street, 33079 Mersin, Turkey

Correspondence should be addressed to Ali Bicer, alibicer@mersin.edu.tr

Received 15 June 2011; Accepted 26 July 2011

Academic Editor: Ümit Tursen

Copyright © 2012 Ali Bicer. This is an open access article distributed under the Creative Commons Attribution License, which permits unrestricted use, distribution, and reproduction in any medium, provided the original work is properly cited.

Behcet's disease is a multisystem disease characterized by recurrent oral and genital ulcers, relapsing uveitis, mucocutaneous, articular, gastrointestinal, neurologic, and vascular manifestations. Rheumatologic manifestations may also occur in Behcet's disease, and arthritis and arthralgia are the most common musculoskeletal findings followed by enthesopathy, avascular necrosis, myalgia, and myositis. Although the main pathology of Behcet's disease has been known to be the underlying vasculitis, the etiology and exact pathogenesis of the disease are still unclear. Musculoskeletal findings of Behcet's disease, the relationship between Behcet's disease and spondyloarthropathy disease complex, and the status of bone metabolism in patients with Behcet's disease were discussed in this paper.

1. Introduction

Behcet's disease (BD) is a chronic and recurrent multisystemic disorder, mainly characterized by oral and genital aphthous ulcers, skin lesions, and uveitis, occasionally resulting from inflammation in central nervous and gastrointestinal system, lungs, kidneys, and joints [1]. Additionally, BD is described as a systemic, vasculitic disorder in which both arteries and veins of any kind of organ may involve [2]. The disease may be distributed worldwide, but it is more prevalent in Asian and Mediterranean regions [3].

The etiology and pathogenesis of BD still remain obscure. However, both genetic and environmental factors, such as microbial pathogens, have been proposed to initiate a congenital and/or acquired immune dysfunction that cause development of the clinical manifestations of the disease [4]. Musculoskeletal involvement in BD is one of the most frequent findings among the clinical manifestations. Table 1 summarizes the musculoskeletal findings of BD, found in the medical literature. Arthritis and arthralgia are the most common musculoskeletal findings of the disease [5]. Although the frequency of the arthritis has been increasing, it has not been yet included in any International Study Group (ISG) Criteria of BD [6]. Furthermore, it was also claimed that the disease could be classified into the spondyloarthropathy

(SpA) complex, because of the presence of sacroiliitis in BD and the clinical overlap between BD and some disease of the SpA complex [7]. On the other hand, the chronicity and factors involved in inflammatory process of the disease and the drugs used for the treatment of BD might have negative effects on bone remodeling, consequently resulting in osteoporosis in BD [8].

In this paper, musculoskeletal findings of BD, the relationship between BD and SpA disease complex, and osteoporosis were discussed.

2. Arthritis

Arthritis and arthralgia are the most common rheumatologic findings in BD and their prevalence varies between 40 and 70% [1, 5, 9]. Subjects with arthritis in BD predominantly present with recurrent, self-limited, nondeforming and nonerosive, inflammatory asymmetric mono-oligoarthritis, affecting most frequently the larger joints such as knees, wrists, ankles and elbows [1, 5, 6, 9, 10]. Erosive forms of arthritis in BD have been reported in only small number of cases, and the most effected locations are axial joint (sacroiliac), entheses (calcaneal), and peripheral joints such as metatarsophalangeal and interphalangeal joints of the feet

TABLE 1: Rheumatologic findings reported in medical literature.

Findings	Localization	Percentage (%)
Joint Involvement	Arthritis/Arthralgia	40–70 [9, 14]
	Knee, wrist, ankle, elbow, hand, feet	10–56 [9, 13]
	Sacroiliac	0–63 [15, 16]
	Manubrio-sternal, sterno-clavicular	Unknown [17]
Enthesopathy	Calcaneal and vertebral bone spurs	3–36 [7, 18]
Bone Mineral Density	Vertebral osteoporosis	Unknown [19]
Muscle Involvement	Myalgia or myositis	Unknown [10, 20]
	Fibromyalgia	9.3 [21]
Bone Infarct	Osteonecrosis	Unknown [22]

and intercarpal and metacarpophalangeal joints of the hand, wrist and knee [11, 12]. Clinical hand involvement in BD was investigated extensively in a study where the prevalence of hand involvement in the disease was found to be high [13]. They also found that the terminal phalangeal tuft resorption that might be related to a specific pattern, induced by the vasculitic process due to the repeated digital infarcts, and the rheumatoid-like hand findings were the most frequent hands in patients with BD.

The mechanism of arthritis is not fully understood, but inflammation and hyperemia (synovitis) are tried to be explained by vasculitis that constitutes the primary pathology in BD [23]. Synovial inflammation has been demonstrated in various reports where hypertrophy and hyperplasia of synovial lining cells, hypervascularity, subsynovial accumulation of inflammatory cells, and replacement of superficial zones of the synovial membrane by dense inflamed granulation tissue were described, without involvement of the deeper layers [5, 9, 24]. However, Moll et al. suggested that synovitis was characterized by large areas of hyperemic synovitis without villi or a distinctive vascular pattern in early untreated BD [25]. Cañete et al. stated that the polymorphonuclear neutrophil and lymphocytes, as important infiltrating cell populations, were found to be the indicators of cytotoxic molecules in early untreated synovitis in BD [26]. The authors also claimed that no evidence for neutrophilic vasculitis and no any other form of vessel pathology in the synovial pathology were detected.

Although there is no clear consensus on its etiology in terms of autoimmunity, some authors have declared that BD could be considered as an autoinflammatory disease due to the fact that both diseases may have the similar clinical characteristics [27]. However, investigations showed no evidence of increase in antibody concentration and T-cell-specific antigens in BD [28, 29].

BD is mostly diagnosed according to ISG Criteria for BD [30]. Although arthritis is seen in more than half of the subjects, it has not been considered among the ISG Criteria for BD. A possible explanation for this exception is that complaints about joints in society are very common, and, therefore, investigators ignore to consider these complaints or findings among the symptoms of the disease [6]. Since the laboratory findings in BD are nonspecific, its diagnosis is based exclusively on clinical evaluation of

subjects. A detailed clinical history and classic manifestation of nonerosive arthritis on physical examination is diagnostic for BD. However, the presence of destructive lesions may confuse the diagnosis of BD and lead to investigate for another cause of destructive lesions, such as rheumatoid arthritis, psoriatic arthritis, and ankylosing spondylitis (AS) [23]. In vast majority of the patients with BD, colchicine (1–2 mg/day) is the drug of choice for the management of nonerosive arthritis [5]. However, destructive arthritis covers a broad spectrum of therapeutic alternatives, including colchicine and nonsteroidal anti-inflammatory drugs at first-line treatment, local corticosteroid injections, and low-dose systemic corticosteroids [10, 23]. Azathioprine and tumor necrosis factor- α (TNF- α) blockers may have some beneficial effects in rare cases with resistant, longer-lasting, and disabling conditions [31].

3. Spondyloarthropathy and Behcet's Disease

One of the remarkable questions in the past was the inclusion of BD in SpA disease complex. Since some investigators have reported the high prevalence of sacroiliitis associated to BD, the coexistence of BD and AS, and the presence of clinical overlap between BD and some subgroup of SpA disease complex such as inflammatory bowel disease and Reiter's syndrome, they claimed that BD could be included in seronegative SpA group [7, 32, 33]. The issue of sacroiliitis associated with BD had been exclusively investigated, and the prevalence of sacroiliitis in BD was highly variable. Yazici et al. have stated that high prevalence of sacroiliitis, found in studies, may be due to the fact that most of the studies had no control groups. Moreover, they claimed that intra- and interobserver variability in interpreting the AP pelvis radiographs is high [34]. Some authors have found that the prevalence of sacroiliitis has not been different from that in general population [15, 34].

The diseases in SpA group have some similar common features. One of the most striking associations among the clinical characteristics in SpA complex is with the enthesitis, HLA-B27 antigen, eye involvement [7, 35]. Although there have been conflicting results for the prevalence of HLA-B27 in patients with BD, BD seems to be associated with HLA-B51 rather than HLA-B27 [7, 36]. There are also some

reports regarding the presence of acne-associated arthritis in a subgroup of patients with BD that may be considered within the broader concept of SpA disease complex [37]. Furthermore, Hatemi et al. have stated that the increased presence of enthesopathy in BD who also have acne and arthritis compared with that BD without arthritis supported the hypothesis that the BD having also acne and arthritis form a distinct cluster [35]. Findings of investigations regarding the prevalence of enthesopathy in BD are inconsistent. The prevalence of enthesopathy has been found to be higher (38%) in some clinical trials [9, 18], but lower rates (3.4%) has also been reported [7]. This wide variation in the reported frequency in BD was explained by the fact that radiography and physical examination were not sensitive methods for detecting enthesopathy and the differences in selected study groups [35]. On the other hand, the pattern of eye involvement is known to be different between SpA and BD. The uveitis of SpA mostly is in benign character, whereas uveitis in BD occasionally results in loss of vision [38].

Conclusively, the lack of clear association of HLA-B27 and BD, the disparity of the eye involvement in SpA and BD, and conflict reports on sacroiliitis and enthesitis in BD have complicated the enrollment of the BD into SpA disease complex.

4. Bone Metabolism

The chronicity and vasculitic background of the disease and the drugs for the treatment of BD suggest that bone metabolism might be affected negatively, which then leads to bone loss, resulting in osteoporosis in patients with BD [8]. Osteoporosis is a common disease characterized by a systemic impairment of bone mass and microarchitecture that causes fragility fractures [39]. The pathogenesis of osteoporosis is mainly considered as an imbalance of the remodeling process, and inflammatory molecules, such as proinflammatory cytokines, interleukins, and TNF- α play an important role to regulate bone metabolism [39, 40]. On the other hand, the primer pathology in BD is inflammatory process of small arteries and veins and thrombosis as a result of vasculitis of vasa vasorum [41]. Elevated levels of immunoglobulins, immune complexes, and complement and acute-phase proteins reveal that the immune system is also involved and activated in the disease process [42]. Investigations demonstrated that interleukins and TNF- α level have been found to be high in patients with BD [43, 44]. Additionally, Hamzaoui et al. reported that vitamin D insufficiency may modulate inflammatory mediators skewing the Th1/Th2 balance towards Th1 [45]. However, it is not known whether the chronic nature of the disease and these activated inflammatory molecules affect the bone remodeling or turnover in patients with BD [5, 9, 14].

There are limited numbers of clinical trial that reveal the status of bone metabolism and bone mineral density (BMD) in the medical literature, and findings in these investigations are in consistent [8, 19, 46]. First, the status of BMD was investigated in a study, where BMD measurements of lumbar spine and hip in BD showed similar results when compared

to those in healthy subjects [8]. Additionally, Tekin et al. stated that there was no significant relationship between arthritis and BMD, and bone turnover markers in patients with BD. The authors also declared that they found no statistically significant differences in BMD and bone turnover markers between BD and control groups [46]. Recently, conflicting with previous reports, Kirnap et al. have stated that they found significant differences in BMD values of lumbar spine and serum bone specific alkaline phosphatase between BD and healthy controls, indicating that BD can be a risk factor for osteoporosis in lumbar vertebra [19]. Despite these efforts, to what extent the BMD and bone remodeling in patients with BD are involved is still unknown. Further studies with larger study groups, especially relevant to bone turnover affecting the immunopathogenesis of bone metabolism and BMD in patients with BD should be considered.

In summary, the clinical characteristics of BD are the recurrent episodes of remission and the exacerbations of various symptoms including musculoskeletal complaints. Arthritis and arthralgia are the commonest rheumatologic findings in BD. However, rare musculoskeletal findings including osteonecrosis, myalgia, and fibromyalgia may also be associated with BD [20–22]. Findings relevant to bone metabolism is lacking. Studies regarding the prevalence and characteristics of musculoskeletal findings in patients with BD are still to be investigated.

References

- [1] B. J. Fessler, "Vasculitis and related diseases," in *Arthritis and Allied Conditions*, W. J. Koopman and L. W. Moreland, Eds., pp. 1835–1844, Lippincott Williams and Wilkins, Philadelphia, Pa, USA, 2005.
- [2] M. Onder and M. A. Gurer, "The multiple faces of Behcet's disease and its etiological factors," *Journal of the European Academy of Dermatology and Venereology*, vol. 15, pp. 126–136, 2001.
- [3] T. Sakane, M. Takeno, N. Suzuki, and G. Inaba, "Behcet's disease," *New England Journal of Medicine*, vol. 341, no. 17, pp. 1284–1291, 1999.
- [4] H. Ideguchi, A. Suda, M. Takeno, A. Ueda, S. Ohnu, and Y. Ishigatsubo, "Behcet's disease: evaluation of clinical manifestations," *Medicine*, vol. 90, pp. 125–132, 2011.
- [5] H. Yazici, S. Yurdakul, V. Hamuryudan, and I. Fresko, "Behcet's syndrome," in *Rheumatology*, J. H. Klippel and P. A. Dieppe, Eds., pp. 1665–1670, Mosby, London, UK, 2003.
- [6] A. Gur, A. J. Sarac, Y. K. Burkan, K. Nas, and R. Cevik, "Arthropathy, quality of life, depression, and anxiety in Behcet's disease: relationship between arthritis and these factors," *Clinical Rheumatology*, vol. 25, no. 4, pp. 524–531, 2006.
- [7] H. K. Chang, D. H. Lee, S. M. Jung et al., "The comparison between Behcet's disease and spondyloarthritides: does Behcet's disease belong to the spondyloarthropathy complex?" *Journal of Korean Medical Science*, vol. 17, no. 4, pp. 524–529, 2002.
- [8] A. Bicer, U. Tursen, T. I. Kaya et al., "Bone mineral density in patients with Behcet's disease," *Rheumatology International*, vol. 24, no. 6, pp. 355–358, 2004.

- [9] S. Yurdakul, H. Yazıcı, Y. Tuzun et al., "The arthritis of Behçet's disease: prospective study," *Annals of the Rheumatic Diseases*, vol. 42, pp. 505–515, 1983.
- [10] C. Ben Taarit, S. Turki, and H. Ben Maïz, "Rheumatologic manifestations of Behçet's disease: concerning 309 cases," *Revue de Medecine Interne*, vol. 22, no. 11, pp. 1049–1055, 2001.
- [11] M. Ait Ouazar and R. Niamane, "Erosive wrist arthritis: a rare manifestation of Behçet's disease," *Revue de Medecine Interne*, vol. 31, no. 7, pp. e15–e16, 2010.
- [12] N. Düzgün and A. Ateş, "Erosive arthritis in a patient with Behçet's disease," *Rheumatology International*, vol. 23, no. 5, pp. 265–267, 2003.
- [13] M. Yurtkuran, M. Yurtkuran, A. Alp et al., "Hand involvement in Behçet's disease," *Joint Bone Spine*, vol. 73, no. 6, pp. 679–683, 2006.
- [14] H. A. Kim, K. W. Choi, and Y. W. Song, "Arthropathy in Behçet's disease," *Scandinavian Journal of Rheumatology*, vol. 26, no. 2, pp. 125–129, 1997.
- [15] M. A. Chamberlain and R. J. H. Robertson, "A controlled study of sacroiliitis in Behçet's disease," *British Journal of Rheumatology*, vol. 32, no. 8, pp. 693–698, 1993.
- [16] N. Dilsen, M. Konice, and O. Aral, "Why Behçet's disease should be accepted as a seronegative arthritis," in *Recent Advances in Behçet's Disease*, T. Lehner and C. G. Barnes, Eds., pp. 281–284, Royal Society of Medicine Services, London, UK, 1986.
- [17] F. Crozier, J. Arlaud, P. Tourniaire et al., "Manubrio-sternal arthritis and Behçet's disease: report of 3 cases," *Journal de Radiologie*, vol. 84, no. 12 I, pp. 1978–1981, 2003.
- [18] N. Caporn, E. R. Higgs, P. A. Dieppe, and I. Watt, "Arthritis in Behçet's syndrome," *British Journal of Radiology*, vol. 56, no. 662, pp. 87–91, 1983.
- [19] M. Kirnap, M. Calis, N. Kaya, and S. Muhtaroglu, "Is the Behçet's disease a risk factor for osteoporosis and is relation to cytokines?" *Bratislavské Lekárske Listy*, vol. 111, no. 6, pp. 340–344, 2010.
- [20] M. Krämer, M. W. Baumgärtel, E. Neuen-Jacob, and P. Berlit, "Medication side effects or expression of underlying disease," *Zeitschrift für Rheumatologie*, vol. 67, no. 3, pp. 232–236, 2008.
- [21] S. Yavuz, I. Fresko, V. Hamuryudan, S. Yurdakul, and H. Yazıcı, "Fibromyalgia in Behçet's syndrome," *Journal of Rheumatology*, vol. 25, no. 11, pp. 2219–2220, 1998.
- [22] M. Jäger, F. Thorey, A. Wild, M. Voede, and R. Krauspe, "Osteonecrosis of Behçet's disease: diagnosis, therapy, and course," *Zeitschrift für Rheumatologie*, vol. 62, no. 4, pp. 390–394, 2003.
- [23] F. Frikha, S. Marzouk, N. Kaddour, M. Frigui, and Z. Bahloul, "Destructive arthritis in Behçet's disease: a report of eight cases and literature review," *International Journal of Rheumatic Diseases*, vol. 12, no. 3, pp. 250–255, 2009.
- [24] T. Gibson, R. Laurent, J. Highton, M. Wilton, M. Dyson, and R. Millis, "Synovial histopathology of Behçet's syndrome," *Annals of the Rheumatic Diseases*, vol. 40, pp. 376–381, 1981.
- [25] C. Moll, M. Bogas, J. A. Gómez-Puerta et al., "Macroscopic features of knee synovitis in early untreated Behçet disease and psoriatic arthritis," *Clinical Rheumatology*, vol. 28, no. 9, pp. 1053–1057, 2009.
- [26] J. D. Cañete, R. Celis, T. Noordenbos et al., "Distinct synovial immunopathology in Behçet disease and psoriatic arthritis," *Arthritis Research and Therapy*, vol. 11, no. 1, article R17, 2009.
- [27] H. Yazıcı and I. Fresko, "Behçet's disease and other autoinflammatory conditions: what's in a name?" *Clinical and Experimental Rheumatology*, vol. 23, no. 4, pp. S1–S2, 2005.
- [28] D. S. Gibson, J. Banha, D. Penque et al., "Diagnostic and prognostic biomarker discovery strategies for autoimmune disorders," *Journal of Proteomics*, vol. 73, no. 6, pp. 1045–1060, 2010.
- [29] A. Gül, "Behçet's disease as an autoinflammatory disorder," *Current Drug Targets*, vol. 4, no. 1, pp. 81–83, 2005.
- [30] B. Wechsler, F. Davatchi, Y. Mizushima et al., "Criteria for diagnosis of Behçet's disease," *Lancet*, vol. 335, no. 8697, pp. 1078–1080, 1990.
- [31] G. Hatemi, A. Silman, D. Bang et al., "EULAR recommendations for the management of Behçet disease," *Annals of the Rheumatic Diseases*, vol. 67, no. 12, pp. 1656–1662, 2008.
- [32] A. El Maghraoui, F. Tabache, A. Bezza et al., "A controlled study of sacroiliitis in Behçet's disease," *Clinical Rheumatology*, vol. 20, no. 3, pp. 189–191, 2001.
- [33] N. Dilsen, M. Konice, and O. Aral, "Why Behçet's disease should be accepted as a seronegative arthritis," in *Recent Advances in Behçet's Disease*, T. Lehner and C. G. Barnes, Eds., pp. 281–284, Royal Society of Medicine Services, London, UK, 1986.
- [34] H. Yazıcı, M. Tuzlaci, and S. Yurdakul, "A controlled survey of sacroiliitis in Behçet's disease," *Annals of the Rheumatic Diseases*, vol. 40, no. 6, pp. 558–559, 1981.
- [35] G. Hatemi, I. Fresko, K. Tascilar, and H. Yazıcı, "Increased enthesopathy among Behçet's syndrome patients with acne and arthritis: an ultrasonography study," *Arthritis and Rheumatism*, vol. 58, no. 5, pp. 1539–1545, 2008.
- [36] N. Sakly, R. Boumiza, S. Zrour-Hassen et al., "HLA-B27 and HLA-B51 determination in Tunisian healthy subjects and patients with suspected ankylosing spondylitis and Behçet's disease," *Annals of the New York Academy of Sciences*, vol. 1173, pp. 564–569, 2009.
- [37] E. Diri, C. Mat, V. Hamuryudan, S. Yurdakul, N. Hizli, and H. Yazıcı, "Papulopustular skin lesions are seen more frequently in patients with Behçet's syndrome who have arthritis: a controlled and masked study," *Annals of the Rheumatic Diseases*, vol. 60, no. 11, pp. 1074–1076, 2001.
- [38] B. L. Hazleman, "Rheumatic disorders of the eye and the various structures involved," *British Journal of Rheumatology*, vol. 35, no. 3, pp. 258–268, 1996.
- [39] T. D. Rachner, S. Khosla, and L. C. Hofbauer, "Osteoporosis: now and the future," *The Lancet*, vol. 377, no. 9773, pp. 1276–1287, 2011.
- [40] R. R. McLean, "Proinflammatory cytokines and osteoporosis," *Current Osteoporosis Reports*, vol. 7, no. 4, pp. 134–139, 2009.
- [41] B. Wechsler, L. T. Huong, C. De Gennes et al., "Arterial involvement in Behçet's disease. Report of 12 cases," *Revue de Medecine Interne*, vol. 10, no. 4, pp. 303–311, 1989.
- [42] J. L. Jorizzo, R. D. Hudson, and F. C. Schmalstieg, "Behçet's syndrome: immune regulation, circulating immune complexes, neutrophil migration, and colchicine therapy," *Journal of the American Academy of Dermatology*, vol. 10, no. 2, pp. 205–214, 1984.
- [43] C. Evereklioglu, H. Er, Y. Türköz, and M. Çekmen, "Serum levels of TNF- α , sIL-2R, IL-6, and IL-8 are increased and associated with elevated lipid peroxidation in patients with Behçet's disease," *Mediators of Inflammation*, vol. 11, no. 2, pp. 87–93, 2002.

- [44] M. O. Oztas, M. Onder, M. A. Gurer, N. Bukan, and B. Sancak, "Serum interleukin 18 and tumour necrosis factor- α levels are increased in Behcet's disease," *Clinical and Experimental Dermatology*, vol. 30, no. 1, pp. 61–63, 2005.
- [45] K. Hamzaoui, I. B. Dhifallah, E. Karray, F. H. Sassi, and A. Hamzaoui, "Vitamin D modulates peripheral immunity in patients with Behçet's disease," *Clinical and Experimental Rheumatology*, vol. 28, no. 4, pp. S50–S57, 2010.
- [46] N. S. Tekin, S. Ozdolap, S. Sarikaya, E. Esturk, and S. Gumustas, "Bone mineral density and bone turnover markers of patients with Behçet's disease," *Journal of the European Academy of Dermatology and Venereology*, vol. 21, no. 1, pp. 25–29, 2007.