Gastroenterology Research and Practice

Peritoneal Metastases

Guest Editors: Yutaka Yonemura, Yan Li, Paul H. Sugarbaker, and Pompiliu Piso

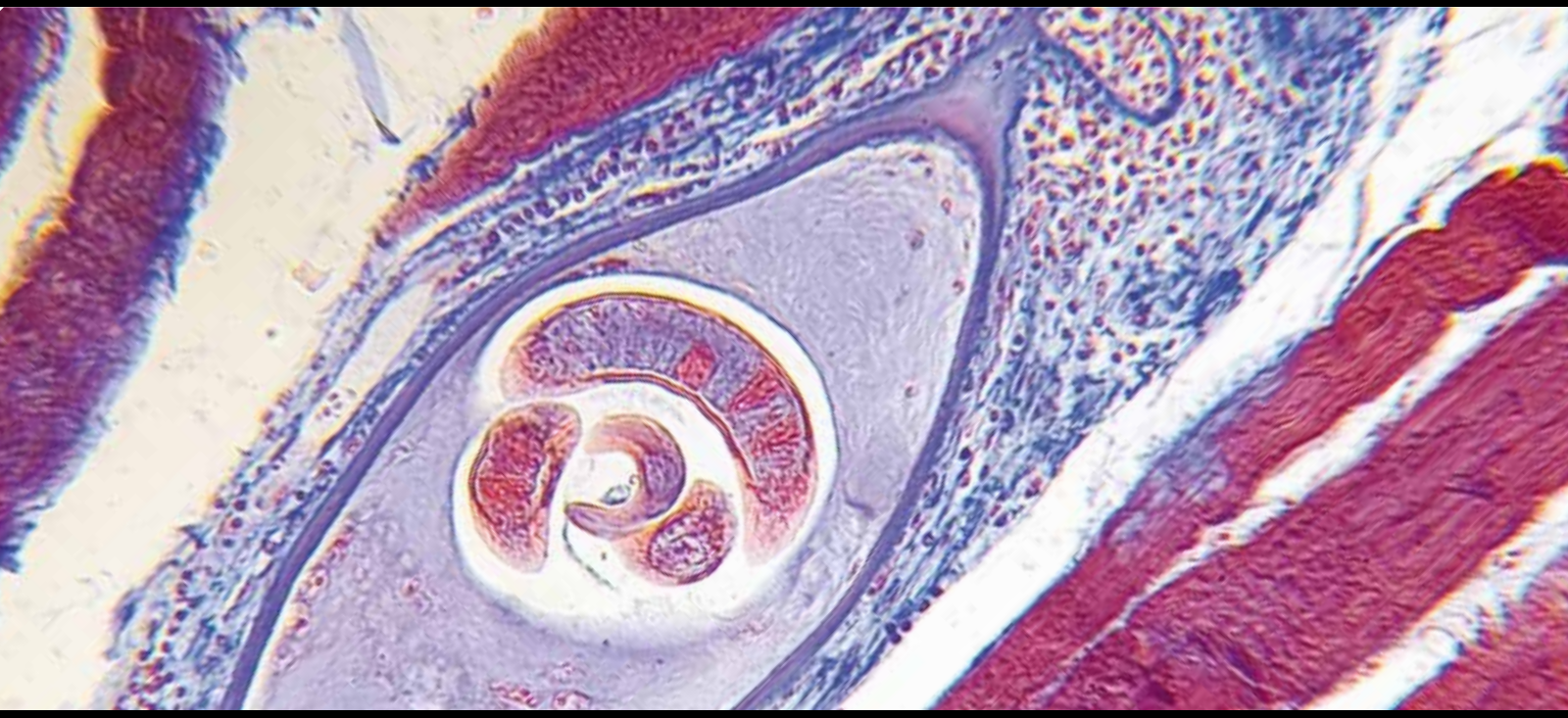

Peritoneal Metastases

Gastroenterology Research and Practice

Peritoneal Metastases

Guest Editors: Yutaka Yonemura, Yan Li, Paul H. Sugarbaker, and Pompiliu Piso

Editorial Board

Contents

Hindawi Publishing Corporation
Gastroenterology Research and Practice
Volume 2012, Article ID 695351, 2 pages
doi:10.1155/2012/695351

Editorial

Peritoneal Metastases

Yutaka Yonemura,[1] Yan Li,[2] Paul H. Sugarbaker,[3] and Pompiliu Piso[4]

[1] *Haruki-Moto-Machi, Kishiwada City, Osaka 596-0032, Japan*
[2] *Department of Oncology, Zhongnan Hospital of Wuhan University, No. 169, Donghu Road, Wuchang District Wuhan 430071, China*
[3] *Program in Surface Malignancy, Washington Hospital Center, 106 Irving St, NW, Washington, DC 20010, USA*
[4] *Chefarzt Klinik für Allgemein-und Viszeralchirurgie Krankenhaus Barmherzige Brüder, Regensburg Prüfeninger Straße 86, 93049 Regensburg, Germany*

Correspondence should be addressed to Yutaka Yonemura, y.yonemura@coda.ocn.ne.jp

Received 16 August 2012; Accepted 16 August 2012

In the past, peritoneal metastases (PM) were considered as a final stage of cancer, and patients were offered a palliative chemotherapy or at best supportive care. In the early 1990s, some surgeons developed a new therapeutic alternative based on the combined treatment. In this curative intent, the macroscopic disease was treated with cytoreductive surgery (CRS) followed by treating residual microscopic disease with a direct intraabdominal application of intraperitoneal chemotherapy using peroperative hyperthermic intraperitoneal chemotherapy (HIPEC) and/or under normothermia of early postoperative intraperitoneal chemotherapy (EPIC). In 2003, prolonged survival of patients affected by peritoneal metastases of colorectal origin with complete cytoreduction followed by HIPEC was reported in phase III prospective-randomized trial [1]. More recently, other groups have improved these results in PM of other origins. Finally, this strategy is now performed at many institutions. Recent studies show that CRS plus intraperitoneal chemotherapy applications confers a prolonged survival in patients with PM of colorectal, gastric, ovarian, and appendiceal neoplasms [1–3] and complete cytoreduction was the most important prognostic factor. In addition to this, volume of peritoneal metastasis (peritoneal cancer index; PCI), biological behavior, histopathological type and grade of tumor, and used chemotherapeutic agents were additional significant prognostic factors in patients with PM.

Besides these improvements, the long-term outcome of these patients is still not satisfied. Further studies need to be conducted with pharmacokinetics of chemotherapeutics and molecular biology studies to develop new therapeutic approaches in this comprehensive strategy.

This special issue of peritoneal metastases offers 18 papers, which consists of 3 papers about pharmacokinetics during intrapertieoneal chemotherapy, 3 about new methods of chemotherapy, 2 about mechanisms and treatment of pulmonary/pleural metastases from peritoneal metastases of appendiceal neoplasm, 3 about new surgical methods and concept, 3 about prevention of recurrence after CC-0 resection, 2 about laparoscopic diagnosis and treatment, and 2 about postoperative morbidity and mortality. These topics covered point to new directions in peritoneal metastases due to gastric, colorectal, appendiceal, and ovarian cancer.

Based on the present results, we have to continue our research and interventions to conquer this refractory disease.

I have to express my deep gratitude to all the guest editors and expert colleagues all over the world who contributed to the special issue.

Yutaka Yonemura
Yan Li
Paul H. Sugarbaker
Pompiliu Piso

References

[1] V. J. Verwaal, S. Van Ruth, E. De Bree et al., "Randomized trial of cytoreduction and hyperthermic intraperitoneal chemotherapy versus systemic chemotherapy and palliative surgery in patients with peritoneal carcinomatosis of colorectal cancer," *Journal of Clinical Oncology*, vol. 21, no. 20, pp. 3737–3743, 2003.

[2] Y. Yonemura, A. Elnemr, Y. Endou et al., "Effects of neoadjuvant intraperitoneal/systemic chemotherapy (bidirectional chemotherapy) for the treatment of patients with peritoneal metastasis from gastric cancer," *International Journal of Surgical Oncology*, vol. 2012, no. 2012, Article ID 148420, p. 8, 2012.

[3] P. H. Sugarbaker, "Epithelial appendiceal neoplasms," *Cancer Journal*, vol. 15, no. 3, pp. 225–235, 2009.

Hindawi Publishing Corporation
Gastroenterology Research and Practice
Volume 2012, Article ID 741202, 4 pages
doi:10.1155/2012/741202

Clinical Study

Laparoscopic Diagnosis and Laparoscopic Hyperthermic Intraoperative Intraperitoneal Chemotherapy for Pseudomyxoma Peritonei Detected by CT Examination

Masamitsu Hirano,[1] Yutaka Yonemura,[1,2,3] Emel Canbay,[2,3,4] Masumi Ichinose,[1] Tuyoshi Togawa,[1] Takayuki Matsuda,[1] Nobuyuki Takao,[1] and Akiyoshi Mizumoto[1]

[1] *Department of Surgery, Kusatsu General Hospital, 1660 Yabase-Cho, Shiga, Kusatsu City 5258585, Japan*
[2] *NPO Organization to Support Peritoneal Dissemination Treatment, 1-26 Harukimotomachi, Osaka, Kishiwada City 596-0032, Japan*
[3] *Department of Surgery, Kishiwada TokushuKai Hospital, 4-27-1 Kamori-Cho, Osaka, Kishiwada City 596-8522, Japan*
[4] *General Surgery Clinic, Derince Education and Research Hospital, 41900 Kocaeli, Turkey*

Correspondence should be addressed to Masamitsu Hirano, hirano@kusatsu-gh.or.jp

Received 2 March 2012; Revised 10 May 2012; Accepted 18 May 2012

Academic Editor: Paul H. Sugarbaker

Background. Patients with early stage of pseudomyxoma peritonei (PMP) are sometimes difficult to diagnose the primary sites and intraperitoneal spread of tumor and to perform a cytological study. *Methods*. Patients without a definitive diagnosis and with unknown extent of peritoneal spread of tumor underwent laparoscopy. Hyperthermic intraoperative intraperitoneal chemotherapy (HIPEC) was administered as part of the same intervention. The results of treatment were evaluated at the time of second-look laparotomy (SLL) as a subsequent intervention. *Results*. Eleven patients were managed by diagnostic laparoscopy followed by laparoscopic HIPEC (LHIPEC). The operation time of laparoscopic examination and LHIPEC was 177 ± 26 min (range 124–261 min). No intraoperative complication was experienced. The peritoneal carcinomatosis index (PCI) score by laparoscopic observation was 16.5 ± 6.4 (range 0–30). One patient with localized pseudomyxoma peritonei (PMP) mucocele did not received LHIPEC; the other 10 patients with peritoneal metastases (PM) were treated with LHIPEC. After LHIPEC, ascites disappeared in 2 cases and decreased in the amount in the other 8 cases. Nine patients underwent SLL and cytoreductive surgery (CRS) combined with HIPEC. The duration between LHIPEC and SLL ranged from 40 to 207 days (97 ± 40 days). The PCI at the SLL ranged from 4 to 27 (12.9 ± 7.1). The PCI at the time of SLL decreased as compared to PCI at the time of diagnostic laparotomy in 7 of 9 patients. Median follow-up period is 22 months (range 7–35). All 11 patients are alive. *Conclusion*. The early results suggest that laparoscopic diagnosis combined with LHIPEC is useful to determine the surgical treatment plan and reduce the tumor burden before definitive CRS at SLL.

1. Introduction

Pseudomyxoma peritonei (PMP) is an uncommon malignancy that is characterized with increases in abdominal girth due to massive accumulation of mucinous material throughout the peritoneal cavity [1, 2]. Frequency of PMP is reported as 1 to 2 per 1,000,000 population annually and 2 per 10,000 laparotomies. PMP develops in the peritoneal cavity by the perforation of mucinous material from malignant tumors from appendiceal (52%), ovarian (36%), colorectal (4%), and pancreatic (2%) origins [1, 2]. In the four largest reported series of 393 patients, immunohistochemistry techniques in women with both appendiceal and ovarian tumors favor an appendiceal primary in most cases [3].

Optimal treatment involves a combination of cytoreductive surgery (CRS) with hyperthermic intraperitoneal chemotherapy (HIPEC) [4, 5]. Computed tomography scanning (CT) and magnetic resonance imaging (MRI) are the optimal preoperative tools to determine the clinical stage [6].

Trocar placement for laparoscopic appendectomy

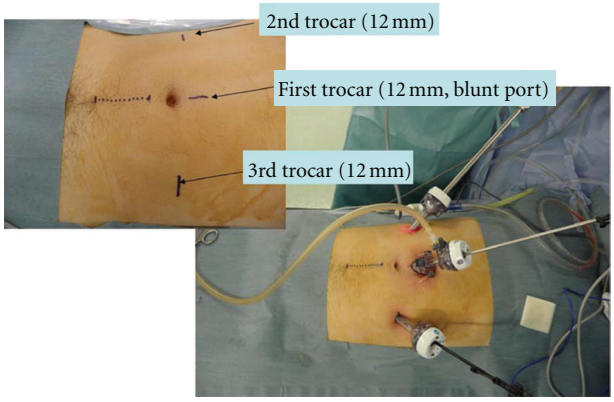

Figure 1

LHIPEC: laparoscopic HIPEC
(hyperthermic intraperitoneal chemotherapy)

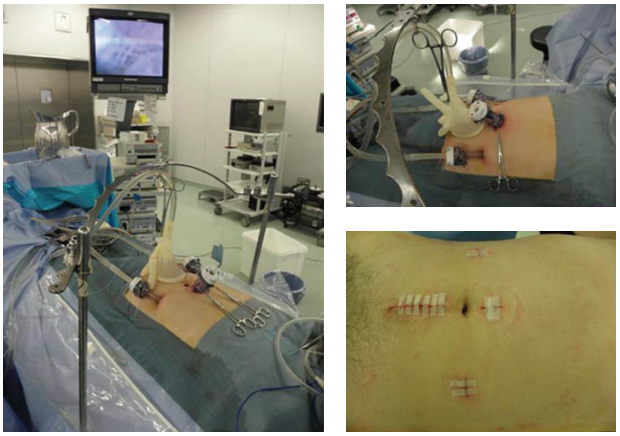

Figure 2

However, the diagnosis of primary tumors and distribution of peritoneal carcinomatosis (PC) are sometimes difficult in patients with small amount of peritoneal nodules and ascites.

In Japan annual checkup for health using the measurement of serum tumor marker levels, ultrasonography (US) or CT is commonly performed as a mass screening. As a result the patients with appendiceal cystadenoma or cystadenocarcinoma are detected in an early stage by the US/CT and/or increased serum tumor marker levels. These patients usually show a small amount of ascites in the pelvis, elevation of carcinoembryonic antigen (CEA), and/or swelling of appendix with localized perforation. Determination of the histologic grade of the appendiceal primary tumor and the distribution of the intraperitoneal mucinous tumor is essential to planning treatment in this group of patients. It may assist in avoiding overtreatment in that patients with appendiceal neoplasm without perforation are not necessary to treat CRS and HIPEC, and appendectomy plus sampling of the regional lymph nodes is believed as an optimal treatment [7].

In addition, the preoperative knowledge of tumor whether it is low-grade or high-grade mucinous adenocarcinoma is important to make a surgical treatment plan and to expect the prognosis of the patient.

For the patients who are suggested to have appendiceal neoplasm with small amount of PM or without perforation, we studied the effectiveness of diagnostic laparoscopy combined with HIPEC at the same intervention (LHIPEC) as an adjunct to the management of PMP.

2. Patients and Methods

From April 2009 to January 2012, 125 patients with appendiceal neoplasm were treated at the Peritoneal Surface Malignancy Center of the Kusatsu General Hospital. Among them, eleven patients without a determined diagnosis were referred to the center for further examination, because they have no definitive diagnosis or no information regarding the peritoneal distribution of the tumor (Table 1). Radiologically, they had small amount of extraappendiceal mucinous appendiceal ascites thought to be a localized pseudomyxoma peritonei. On CT examination, they had swollen appendix and small amount of ascites in the pelvis, but no omental cake nor large mass in the peritoneal cavity. All 11 patients did not have a definitive diagnosis, had received operation, but were suspected to have appendiceal neoplasm with mucinous ascites.

All patients received diagnostic laparoscopy (Figure 1). We used a 3-port configuration. A 12 mm blunt port was placed from the 2 cm longitudinal incision above the umbilicus. A second trocar (12 mm) was placed in the right upper quadrant, followed by a third trocar (12 mm) in the left lower quadrant. A 5 mm trocar was added if necessary in the left upper quadrant. The suction cannula was then used to evacuate the thick mucinous ascites, and samples were obtained for microbiologic cultures and cytology. Biopsy specimens were routinely obtained from peritoneum, omentum, and ovary. Spreading of the tumor in the entire abdominal cavity was evaluated using the peritoneal carcinomatosis index (PCI) based on the regions involved in the abdominal cavity and the sizes of the neoplastic nodules [3].

Appendectomy was performed, and the appendectomy specimen was evaluated histopathologically by frozen section. Following confirmation of the diagnosis, a longitudinal 5 cm midline incision was made to the lower abdomen for open laparotomy. Three drainage tubes (2 inlet tubes, 1 outlet tube) were placed for LHIPEC. The inside of the abdominal cavity was washed out with 10 liters of physiological saline solution to remove mucinous ascites, and hyperthermic intraperitoneal chemotherapy (HIPEC) was performed at 42°C to 43°C for 60 minutes adding 3 to 5 liters of the saline solution including 20 mg of mitomycin C and 100 mg of cisplatin (Figure 2).

Table 1: Profiles of patients.

Patient no.	Age	Sex	Chief complaints (initial symptoms)	Preoperative diagnosis	Diameter of appendix (mm)	CEA (<6.0 ng/mL)	CA19-9 (<37.0 U/mL)
1	59	Female	Abdominal distension	Suspicious PMP	18	24.5	143.9
2	54	Male	Lower abdominal pain	Suspicious PMP	64	11.3	79.2
3	49	Female	Lower abdominal mass	Suspicious PMP	32	5.1	49.2
4	54	Male	None (serum CEA elevation)	Appendiceal tumor	7	54	17.4
5	44	Female	Abdominal pain	Suspicious PMP	35	87.9	540.4
6	58	Female	None (abnormal findings on US)	Suspicious PMP	14	26.1	148.4
7	67	Male	Right inguinal mass and pain	Suspicious PMP	50	4.5	7.9
8	56	Female	None (abnormal findings on US)	Appendiceal tumor	22	3.1	36.6
9	63	Female	Lower abdominal distension	Suspicious PMP	25	2.1	18.5
10	42	Male	None (abnormal findings on CT)	Suspicious PMP	19	46.5	137.6
11	60	Female	None (abnormal findings on US)	Suspicious PMP	11	33.4	91.9

Table 2: Results of laparoscopic operation and secondary look laparotomy (cytoreductive surgery + HIPEC).

Patient no.	Procedures	Operative time (min)	PCI at LHIPEC	Hospital stay after ope. (days)	Postoperative complications	Postoperative serum CEA	Changes of ascites on CT	Period from LHIPEC to SLL (days)	PCI at SLL	Follow-up period (months)
1	LAp + LHIPEC	124	25	16	(−)	Normal	↓	165	5	35
2	LAp + LHIPEC	261	14	13	(−)	Normal	↓	55	4	33
3	LAp + LHIPEC	153	12	14	RDF	Normal	↓	207	23	26
4	LAp + LHIPEC	160	12	4	(−)	Decreased	Disappeared	42	8	29
5	LAp + LHIPEC	151	30	15	(−)	Decreased	↓	115	27	23
6	LAp + LHIPEC	189	25	13	(−)	Decreased	↓	84	11	23
7	LAp + LHIPEC	201	11	9	RDF	Normal	↓	94	7	18
8	LAp	148	0	6	(−)	(−)	(−)	(−)	(−)	(−)
9	LAp + LHIPEC	201	12	11	(−)	Normal	Disappeared	40	7	7
10	LAp + LHIPEC	189	21	8	(−)	Decreased	↓	(−)	(−)	(−)
11	LAp + LHIPEC	172	20	9	(−)	Elevated	↓	50	24	7

LAp: laparoscopic appendectomy.
LHIPEC: laparoscopic hyperthermic intraperitoneal chemotherapy.
PCI: peritoneal carcinomatosis index.
SLL: second look laparotomy.
RDF: renal dysfunction improved within 1 week.
No. 4: port site recurrence was revealed 10 months after LP1PEC.
No. 8: localized PMP (mucocele).

3. Results

In all 11 patients the ascites was found on CT accompanied by a swelling, a cystic mass, or thickening of the appendiceal wall. The mean maximum diameter of the appendix was 27.1 mm (range 7–64 mm), and three of them showed calcification. Serum CEA levels ranged from 2.1 to 87.9 ng/mL (25.6 ± 19.1); 7 patients showed a higher CEA and CA19-9 levels than normal (Table 1).

The operation time of laparoscopic examination and HIPEC was 177.2 ± 25.8 minutes (range, 124–261 minutes); blood loss was always less than 20 mL (Table 2). No intraoperative complication was experienced. The PCI score by laparoscopic observation was 16.5 ± 6.4 (range 0–30). After operation, two patients developed renal dysfunction, but it improved after the 7th postoperative day.

Ascites examined by CT disappeared in 2 cases and decreased in amount in the other 8 cases within 2 months after LHIPEC. Serum CEA levels of all cases decreased after LHIPEC and became in the normal range in 5 cases.

Nine patients underwent SLL and CRS combined with HIPEC. The duration between LHIPEC and SLL ranged from 40 to 207 days (97.4 ± 40.6 days). PCI at the SLL ranged from 4 to 27 (12.9 ± 7.1); PCI at the time of SLL had decreased as compared to that recorded at the time of LHIPEC in 7 of 9 patients. However, PCI of 2 patients (case 3, 11) in SLL was higher than those at LHIPEC. Median follow-up period is 22 months (range 7–35 months). All 11 patients are alive. One patient developed port site recurrence 10 months after LHIPEC. He underwent redo surgery and had small recurrence nodules on the spleen, right paracolic gutter, and port site on the right lower abdomen. All the

three sites of progressive disease were completely removed (Table 2).

4. Discussion

In general, PMP is treated with conventional open abdominal surgical procedure, because the metastases have already spread into the whole abdominal and pelvic space. The patients with advanced PMP have massive mucinous ascites, and the diagnosis can be made by CT, MRI, serum CEA levels, and cytological examination with abdominal paracentesis [6]. However, these modalities may not provide enough information to make a definitive treatment plan for the patient [1, 9]. Diagnostic laparoscopy provides a wide view of the whole abdominal cavity without a large incision [8, 10]. In addition, a pathological diagnosis from nodules on the peritoneal surface can be made during laparoscopy. The primary lesions of PMP are usually from a borderline malignancy of the appendix. The primary site is ovary, colon, and pancreas in 30% of all PMP cases [11]. The laparoscopic exploration is helpful for the definitive diagnosis of PMP in patients in whom a primary disease site is not identified [10].

In patients with ascites seen on radiologic studies who need a definitive diagnosis, laparoscopy is considered as a good diagnostic modality to determine the primary sites, dissemination of tumors, and histological diagnosis. Raj et al. and Kotani et al. [8, 12] performed laparoscopic-assisted surgery for patients with PMP, and they concluded that laparoscopic surgery allowed a wide area of observation within the abdominal cavity. Furthermore, a histological diagnosis of the appendiceal and ovarian tumor can be made after laparoscopic resection. The appendix should be examined histologically using immunohistochemistry, and the primary site of PMP and the histological grade can be obtained before SLL [13].

In the present study, PCI at SLL in 7 of 9 patients had decreased compared to that recorded at LHIPEC. Accordingly, LHIPEC may be effective to decrease PCI. In addition, serum CEA levels after LHIPEC significantly decreased as compared with those at LHIPEC. Since serum tumor marker levels correlate with the tumor burden [14], LHIPEC can decrease tumor volume. The present study suggests that laparoscopic diagnosis combined with LHIPEC is useful to determine the proper treatment and reduce the tumor burden before CRS at SLL.

References

[1] D. B. Gough, J. H. Donohue, A. J. Schutt et al., "Pseudomyxoma peritonei: long-term patient survival with an aggressive regional approach," *Annals of Surgery*, vol. 219, no. 2, pp. 112–119, 1994.

[2] B. J. Moran and T. D. Cecil, "The etiology, clinical presentation, and management of pseudomyxoma peritonei," *Surgical Oncology Clinics of North America*, vol. 12, no. 3, pp. 585–603, 2003.

[3] A. Mukherjee, A. Parvaiz, T. D. Cecil, and B. J. Moran, "Pseudomyxoma peritonei usually originates from the appendix: a review of the evidence," *European Journal of Gynaecological Oncology*, vol. 25, no. 4, pp. 411–414, 2004.

[4] J. Esquivel, R. Sticca, P. Sugarbaker et al., "Cytoreductive surgery and hyperthermic intraperitoneal chemotherapy in the management of peritoneal surface malignancies of colonic origin: a consensus statement," *Annals of Surgical Oncology*, vol. 14, no. 1, pp. 128–133, 2007.

[5] W. J. Mann, J. Wagner Jr., J. Chumas, and E. Chalas, "The management of pseudomyxoma peritonei," *Cancer*, vol. 66, no. 7, pp. 1636–1640, 1990.

[6] H. C. Yeh, M. K. Shafir, G. Slater, R. J. Meyer, B. A. Cohen, and S. A. Geller, "Ultrasonography and computed tomography in pseudomyxoma peritonei," *Radiology*, vol. 153, no. 2, pp. 507–510, 1984.

[7] K. A. Behranwala, T. Agarwal, D. El-Sharkawi, D. Shorvon, and A. Chang, "Laparoscopic resection of mucinous cystadenoma of appendix: a careful decision," *Surgical Laparoscopy, Endoscopy and Percutaneous Techniques*, vol. 16, no. 5, pp. 347–348, 2006.

[8] J. Raj, L. M. Urban, S. G. Remine, and P. K. Raj, "Laparoscopic management of pseudomyxoma peritonei secondary to adenocarcinoma of the appendix," *Journal of Laparoendoscopic and Advanced Surgical Techniques*, vol. 9, no. 3, pp. 299–303, 1999.

[9] M. Valle and A. Garofalo, "Laparoscopic staging of peritoneal surface malignancies," *European Journal of Surgical Oncology*, vol. 32, no. 6, pp. 625–627, 2006.

[10] T. Nozaki, K. Yasuda, A. Watanabe, and H. Fuse, "Laparoscopic management of urachal mucinous borderline tumor associated with pseudomyxoma peritonei," *Surgical Laparoscopy, Endoscopy and Percutaneous Techniques*, vol. 21, no. 3, pp. e152–e155, 2011.

[11] G. Liberale, P. Lemaitre, D. Noterman et al., "How should we treat mucinous appendiceal neoplasm? by laparoscopy or laparotomy?: a case report," *Acta Chirurgica Belgica*, vol. 110, no. 2, pp. 203–207, 2010.

[12] Y. Kotani, M. Shiota, M. Umemoto et al., "Laparoscopic mucin removal in patients with pseudomyxoma peritonei," *Journal of the Society of Laparoendoscopic Surgeons*, vol. 13, no. 2, pp. 203–206, 2009.

[13] N. C. Panarelli and R. K. Yantes, "Mucinous neoplasm of the appendix and peritoneum," *Archives of Pathology & Laboratory Medicine*, vol. 135, no. 10, pp. 1261–1266, 2011.

[14] Y. Kyoto, M. Momose, C. Kondo, M. Itabashi, S. Kameoka, and K. Kusakabe, "Ability of 18F-FDG PET/CT to diagnose recurrent colorectal cancer in patients with elevated CEA concentrations," *Annals of Nuclear Medicine*, vol. 24, no. 5, pp. 395–401, 2010.

Hindawi Publishing Corporation
Gastroenterology Research and Practice
Volume 2012, Article ID 635314, 8 pages
doi:10.1155/2012/635314

Research Article

Pulmonary Complications following Cytoreductive Surgery and Perioperative Chemotherapy in 147 Consecutive Patients

Vinicius Preti,[1,2] David Chang,[3] and Paul H. Sugarbaker[1]

[1] *Washington Cancer Institute, Washington Hospital Center, Washington, DC 20010, USA*
[2] *Erasto Gaertner Hospital, Rua Dr. Ovande do Amaral 201, 81520-060 Curitiba, PR, Brazil*
[3] *Westat, Rockville, MD 20850, USA*

Correspondence should be addressed to Paul H. Sugarbaker, paul.sugarbaker@medstar.net

Received 5 April 2012; Accepted 10 June 2012

Academic Editor: Yan Li

Cytoreductive surgery (CRS) with hyperthermic perioperative chemotherapy (HIPEC) has become a treatment option for selected patients with peritoneal metastases (PMs) from gastrointestinal malignancies. The purpose of this study is to evaluate our most recent data regarding pulmonary complications (respiratory distress, pleural effusion, and pneumonia) and attempt to identify risk factors associated with this management plan. This study includes the most recent 4-year experience with appendiceal and colorectal carcinomatosis patients treated in a uniform manner between January 1, 2006 and December 31, 2009. A prospective morbidity and mortality database was maintained and pulmonary adverse events were analyzed with special attention to subphrenic peritonectomy. There were 147 consecutive patients with a mean age of 49.9 years. Fourteen patients (10%) presented grades I–IV pulmonary complications for a total of 26 events. The peritonectomy of right upper quadrant was performed in 74% and right plus left in 49% of the patients. Statistically, there were no more pulmonary complications among patients submitted to peritoneal stripping of right or right and left hemidiaphragm as compared to no subdiaphragmatic peritonectomy ($P = 1.00$ and $P = 0.58$, resp.). In an analysis of 18 quantitative indicators and clinical variables with pulmonary adverse events, only blood replacement greater than six units showed a significant correlation ($P = 0.0062$). Pulmonary adverse events were observed in 10% of patients having CRS and HIPEC. Subphrenic peritonectomy was not a specific risk factor for developing these adverse events.

1. Introduction

Peritoneal metastases (PMs) are a cause of great morbidity and mortality in patients with gastrointestinal cancer. Problems related to the progression of PM are a frequent cause of the terminal event in these patients. A local-regional treatment that combines cytoreductive surgery (CRS) with hyperthermic perioperative chemotherapy (HIPEC) and early postoperative intraperitoneal chemotherapy (EPIC) has shown benefit in selected patients with peritoneal dissemination. This treatment has gained general acceptance for appendiceal mucinous neoplasms [1] and peritoneal mesothelioma [2] and now is finding additional applications in the management of colorectal cancer [3], gastric cancer [4], and ovarian cancer [5]. With increased experience, the morbidity and mortality have declined in several reports [6–8]. Smeenk and colleagues at The Netherlands Cancer Institute showed that over time their perioperative mortality could be diminished by 50%. Overall major morbidity was reduced from 71% between 1996 and 1998 to 34% between 2003 and 2006 [6]. Pulmonary complications are common after abdominal surgery and associated significantly with longer hospital stays [9]. The purpose of this study is to evaluate the incidence of pulmonary complications (respiratory distress, pleural effusion, and pneumonia) and to identify risk factors associated with pulmonary complications in the use of CRS and perioperative chemotherapy.

2. Patients and Methods

2.1. Patient Eligibility Criteria. This study includes our most recent 4-year experience with patients with appendiceal and colorectal PM treated in a uniform manner between January 1, 2006 and December 31, 2009. Institutional Review Board

Table 1: Classification of pulmonary adverse event by grade.

Adverse event	Grade I	Grade II	Grade III	Grade IV
Respiratory distress	Mild symptoms	Oxygen therapy or medications required	Endotracheal intubation	Tracheostomy required
Pleural effusion	Asymptomatic	Diuretics required	Thoracentesis required	Compromised, chest tube insertion
Pneumonia	Minimal symptoms	Antibiotics and respiratory therapy	Bronchoscopy	Intubation required

approval was obtained to collect and analyze these data. Patients with appendiceal and colorectal malignancy who received CRS combined with a standardized treatment with perioperative chemotherapy were included.

2.2. Cytoreductive Surgery and Hyperthermic Intraoperative Chemotherapy and Systemic Chemotherapy. The goal of surgery in these patients was to visibly clear the abdomen and pelvis of cancer nodules. This required a series of peritonectomy procedures and visceral resections [10]. Normal peritoneum or normal visceral structures were not resected. All patients received HIPEC in the operating room after the CRS but before intestinal anastomoses or repair of seromuscular tears was performed. The two drugs administered by the intraperitoneal route with heat were mitomycin C (15 mg/m^2) and doxorubicin (15 mg/m^2). Simultaneous intravenous 5-fluorouracil (400 mg/m^2) and leucovorin (20 mg/m^2) were administered as a rapid infusion over 6–8 minutes. HIPEC was given according to the Coliseum technique [10]. A heater circulator was used to maintain moderate hyperthermia within the abdomen and pelvis at 41–43°C.

2.3. Early Postoperative Intraperitoneal Chemotherapy. The EPIC 5-fluorouracil was withheld in patients who had a full course of oxaliplatin-based FOLFOX chemotherapy prior to surgery. The dose of EPIC 5-fluorouracil was 400 mg/m^2/day for women and 600 mg/m^2/day for men. It was infused via a Tenckhoff catheter over approximately 15 minutes for 4 days after surgery [10]. The dwell time for EPIC was 23 hours.

2.4. Perioperative Management. Patients received appropriate antibiotics within one hour prior to the abdominal incision and then throughout the cytoreductive procedure. A final dose of antibiotics was given just prior to closing the abdominal incision. No prophylactic antibiotics were given postoperatively. Patients were transferred directly to a surgical intensive care unit for monitoring and orotracheal extubation. All patients received postoperative intravenous feeding through the intrajugular vein for five postoperative days and then through a percutaneous central venous catheter (Vaxcel, Glen Falls, NY). Closed suction drains (Bard Closed Wound Suction and Silicon Drain, Covington, GA) remained in place in the abdomen and pelvis after surgery until drainage was below 50 mL per 24 hours from a single drain. Right-angle 28-French thoracostomy tubes (Deknatel, Floral Park, NY) were always used when a patient had a subphrenic peritonectomy; they were removed in the second postoperative week as drainage diminished to less than 50 mL per 24 hours.

2.5. Database for Morbidity/Mortality Assessment. The database was specially constructed to evaluate the adverse events including pulmonary complications (pleural effusion, respiratory distress, and pneumonia) in patients treated for PM from appendiceal and colorectal malignancy. The pulmonary adverse events which were scored grade I through grade IV are listed in Table 1.

2.6. Quantitative Prognostic Indicators. The extent of previous surgery was quantitated with the prior surgical score (PSS). Size and distribution of disease at the time of surgery were assessed with the peritoneal cancer index (PCI). The PCI was analyzed in three different ways: by four groups (0–10, 11–20, 21–30, and 31–39), by two groups A (0–20 versus 21+), and by two groups B (0–30 versus 31+). At the end of the cytoreductive surgery a completeness of cytoreduction score (CC-score) was recorded [11].

2.7. Clinical Variables. All data collection occurred on hospitalized patients; events that may have occurred after hospital discharge are not part of this analysis. Sixteen clinical variables were analyzed to assess factors predictive of pulmonary complications: gender, age (≤50 versus >50), primary cancer location (appendix versus colorectal), cancer grade (grade 1 versus grade 2-3), peritonectomy procedures (pelvic, right upper quadrant, left upper quadrant, omental bursa, anterior abdominal wall), number of peritonectomy procedures per patient (0–2 versus 3–5), visceral resections performed (omentectomy, splenectomy, rectosigmoid colon resection, right colon resection, hysterectomy, small bowel resection, transverse colon resection, and gastrectomy), visceral resections performed per patient (0–2 versus 3–7), types of anastomoses performed (esophagojejunal, small bowel, ileocolic, colocolic, and colorectal), number of anastomoses performed per patient (0–2 versus 3–5), ostomies performed (none, diverting ileostomy, and end ileostomy), blood replacement (none, 1–3 units, 4–6 units, >6 units), blood replacement (0–6 units versus >6 units), fresh frozen plasma replacement (none, 1–4 units, >4 units), time in the operating room in hours (0–6, 7–12, >12), and chemotherapy treatment (HIPEC only versus HIPEC plus EPIC).

Table 2: Demographic and clinical features.

Patients	
Male	68 (46%)
Female	79 (54%)
Age (years)	
Mean ± standard deviation	49.9 (8.7%)
Median	51 (27%)
Range	23–64
Primary cancer diagnosis	
Appendix	135 (92%)
Colorectal	12 (8%)
Completeness of cytoreduction	
Complete	125 (85%)
Incomplete	22 (15%)
Subphrenic peritonectomy	
Right	109 (74%)
Right and left	72 (49%)
Blood products	
None	39 (26.5%)
1–3 units	68 (46.3%)
4 or more	40 (27.2%)
Fresh frozen plasma	
None	80 (54%)
1–4 units	51 (34.7%)
5 or more	16 (10.9%)
Chemotherapy treatments	
HIPEC	82 (55.8%)
HIPEC + EPIC	65 (44.2%)

2.8. Statistics. Univariate methods by Fisher's exact test, chi-square and Cochran-Mantel-Haenszel statistics and multivariate method by logistical procedure were used to assess the association between adverse pulmonary events and the subphrenic peritonectomy procedure. Those prognostic indicators and clinical variables that were significantly correlated to the outcome (P value < 0.05) were then fitted into the logistic regression model for analysis of variances to assess the strength of the risk factors.

3. Results

3.1. Demographics and Clinical Features. Forty-six percent of patients were men and the mean age was 49.9 (±8.7). Peritoneal metastases from appendiceal cancer were present in 135 patients (92%) and PM from colon cancer in 12 (8%). The mean length of hospital day was 24 days. Complete cytoreduction was reported in 125 patients (85%). The right subphrenic peritonectomy was performed in 109 patients (74%) and right and left in 72 (49%). Seventy-six percent of patients required blood replacement and 46% required fresh frozen plasma transfusion. Hyperthermic perioperative chemotherapy was administered to 55.8% of patients and 44.2% received HIPEC + EPIC (Table 2).

3.2. Pulmonary Adverse Events. Fourteen patients (10%) presented grade II through grade IV pulmonary adverse events for a total of 23 events (Table 3).

3.3. Pleural Effusion. The most common event was pleural effusion with 10 events diagnosed (4.6%). Three patients were classified as grade II (diuretics required), 4 as grade III (thoracentesis required), and 3 as grade IV (chest tube insertion required).

3.4. Respiratory Distress. There were 9 respiratory distress events (4.2%). Two patients were classified as grade II cases (oxygen therapy or medications required), 5 as grade III (endotracheal intubation required), and 2 as grade IV (tracheostomy required). One patient died after a grade III respiratory distress followed by severe neutropenia. This was the only death among the 147 patients.

3.5. Pneumonia. There were 7 patients who developed pneumonia (3.2%). There were 3 grade I patients (minimal symptoms), 4 grade II patients (antibiotics and respiratory therapy required), and no grade III or IV patients (bronchoscopy or intubation required). These results are summarized in Table 3. Among the 4 grade II pneumonia patients, one presented pulmonary edema, one presented respiratory distress, and another one presented pleural effusion.

3.6. Analysis of Pulmonary Adverse Events by Subphrenic Peritonectomy. The patients were divided into groups with or without pulmonary complication and the impact of subphrenic peritonectomy was statistically determined. There is no difference in the incidence of pulmonary complication in the group submitted to peritoneal stripping of the right or right plus left hemidiaphragm and the group who did not have this dissection performed (Table 4).

3.7. Analysis of Pulmonary Adverse Events by Quantitative Prognostic Indicators and Clinical Variables. In univariate and multivariate analysis, the only risk factor was more than 6 blood units replacement. In the univariate analysis of blood replacement none, 1–3 units, 4–6 units and >6 units $P = 0.0349$. In the univariate analysis of blood replacement 0–6 units versus >6 units $P = 0.0062$ (Table 5).

In a multivariate analysis with logistic procedure, only blood replacement was identified as a risk factor for pulmonary complications ($P = 0.0030$).

4. Discussion

This study analyzed pulmonary complications in 147 consecutive patients at a single experienced peritoneal surface malignancy treatment center. It is the first paper to focus specifically on pulmonary complications after CRS and HIPEC. Identification of treatments-associated morbidity and mortality may help determine causation so that a reduction in complications may occur. Peritoneal metastases to the peritoneal surface of the right hemidiaphragm or

Table 3: Pulmonary adverse events grade I through grade IV. There was a total of 26 pulmonary adverse events in 14 patients.

Organ System	Absolute number/%	Grade I	Grade II-symptomatic and medical treatment	Grade III-invasive intervention	Grade IV-ICU care or return to operating room
Pleural effusion	10/4.6%	Asymptomatic 0%	Diuretics required 3/1.4%	Thoracentesis required 4/1.8%	Compromised, chest tube insertion 3/1.4%
Respiratory distress	9/4.2%	Mild symptom 0%	Oxygen therapy or medications required 2/0.9%	Endotracheal intubation 5/2.3%	Tracheostomy required 2/0.9%
Pneumonia	7/3.2%	Minimal symptoms 3/1.4%	Antibiotics and respiratory therapy 4/1.8%	Bronchoscopy 0%	Intubation required 0%

Table 4: Analysis of pulmonary adverse events (pleural effusion, respiratory distress, and pneumonia) by presence versus absence of subdiaphragmatic peritonectomy. *P* value based on Fisher's exact test.

		No pulmonary complication ($N = 133$)	Pulmonary complication occurred ($N = 14$)	Total	*P* value
RUQ + LUQ	No	69 (92%)	6 (8%)	75	*0.5826*
	Yes	64 (89%)	8 (11%)	72	
RUQ	No	35 (92%)	3 (8%)	38	*1.0000*
	Yes	98 (90%)	11 (10%)	109	

LUQ: left upper quadrant, RUQ: right upper quadrant.

right plus left hemidiaphragm were a common requirement of complete CRS. It was needed on the right in 74% of patients and right plus left in 49% of patients. Our hypothesis was that subphrenic peritonectomy would interfere with respiratory function postoperatively and thereby be associated with pulmonary adverse events. However, no relationship of peritoneal stripping of the right or right and left hemidiaphragm to pulmonary adverse events was evident.

In a recent report pulmonary complication was the second most common grade IV complications (16%) among our patients [12]. In a prior study of cytoreduction and HIPEC in nonappendiceal peritoneal metastases patients, it was the most common grade IV adverse event at 26% [13]. The incidence of grade I through IV pneumonia, pleural effusion, and respiratory distress of 10% is reported in this paper. Kusamura related 12% incidence of major complications and the most common cause of morbidity was anastomotic leak or intestinal perforation. Their second most common complication was the pulmonary [14].

Pleural effusion is a relatively common event described in many reports and it could be due to several factors. The stripping of the diaphragmatic peritoneum elicits a mechanical and thermal injury to the muscle. This trauma would promote with fluid access to the thorax from the abdomen of chemotherapy solution during HIPEC. Chéreau et al. showed a higher incidence of pleural effusion and other pulmonary complications in a group of ovarian cancer patients submitted to peritoneal diaphragmatic resection; they reported a greater number of patients requiring pleural drainage [15]. In this report, opening the pleura was required because of the carcinomatosis infiltration of the diaphragm; systematic pleural drainage was not performed routinely in these patients. Dowdy et al. also showed pleural effusion as their most common complication, with an incidence of 30% among 56 patients [16]. Stephens and colleagues related an incidence of 3% of pleural effusion among 200 patients submitted to peritonectomy and HIPEC [17]. The only predictor for the development of postoperative pleural effusion was entry into the pleural space at the time of diaphragm peritonectomy. Pleural drainage was routine in all our patients in an attempt to avoid pleural effusion. Nevertheless, pleural effusion remained the second most common respiratory event. In our patients, there is no statistical correlation that showed that stripping the diaphragm is a risk factor for pulmonary adverse events.

Postoperative infection is a high-risk factor in patients submitted to peritonectomy procedures and it is fundamental to recognize an infectious process at an early stage [18]. Among the infectious adverse effects, pneumonia ranged from 3.5 to 6.6% in recent series [13, 19]. In the past, Schmidt reported this incidence had reached up to 10% [20]. In this series, pneumonia occurred in 3.2% of our patients.

The morbidity and mortality have been reduced in several reports with increasing experience with CRS and HIPEC. Smeenk and colleagues reported a decrease in morbidity from 71.2 to 34% in an 8-year period in a multicentric analysis [6]. Muller and colleagues showed that it was possible to reduce the adverse effects by reducing inflammatory response, with intraoperative fluid restriction, intensified hyperglycemia management, and reducing the blood loss [21]. Mohamed and Moran demonstrated the importance of a learning curve in CRS and HIPEC to reduce the incidence of adverse effects. They defended the importance of teamwork and the presence of 2 experienced surgeons to support each other in the management of a

Table 5: Impact of quantitative prognostic indicators and clinical variables on pulmonary adverse events in 147 consecutive patients.

	Pulmonary Events I–IV Univariate analysis			Pulmonary Events I–IV Multivariate analysis	
	Yes $N = 14$	No $N = 133$	P value*/OR (95% CI)	Odds ratio	P value
Gender					
Male	6	62	0.7884		NT**
Female	8	71	1.2 (0.4, 3.5)		
Age					
≤50 year	7	65	0.9360		NT
>50 year	7	68	1.0 (0.3, 2.9)		
Location					
Appendix	13	122	1.0000		NT
Colorectal	1	11	0.9 (0.1, 7.1)		
Grade					
Grade 1	4	57	0.3021		NT
Grade 2–4	10	76	1.9 (0.6, 6.3)		
Prior surgical score					
0–2	13	120	1.0000		NT
3–5	1	13	0.7 (0.1, 5.9)		
Peritoneal cancer index (4 groups)					
0–10	1	30	reference		
11–20	4	36	0.3779 3.3 (0.4, 31.4)		NT
21–30	5	48	0.4060 3.1 (0.3, 28.1)		
31–39	4	19	0.1512 6.3 (0.7, 60.9)		
Peritoneal cancer index (2 groups A)					
0–20	5	66	0.3218		NT
21+	9	67	1.8 (0.6, 5.6)		
Peritoneal cancer index (2 groups B)					
0–30	10	114	0.2359		NT
31+	4	19	2.4 (0.7, 8.4)		
Completeness of cytoreduction					
Complete	10	115	0.2273		NT
Incomplete	4	18	2.6 (0.7, 9.0)		
Peritonectomy procedure					
Pelvic	13	110	0.4679 0.4 (0.1, 2.9)		NT
Right upper quadrant	11	98	1.0000 0.8 (0.2, 2.9)		NT
Left upper quadrant	8	64	0.5206 0.7 (0.2, 2.1)		NT
Omental bursa	10	60	0.0608 0.3 (0.1, 1.1)		NT
Anterior abd. wall	6	44	0.5553 0.7 (0.2, 2.0)		NT
Peritonectomy procedure per patient					
0–2	3	52	0.1938		NT
3–5	11	81	2.4 (0.6, 8.8)		

Table 5: Continued.

	Pulmonary Events I–IV Univariate analysis			Pulmonary Events I–IV Multivariate analysis	
	Yes $N = 14$	No $N = 133$	P value*/OR (95% CI)	Odds ratio	P value
Visceral resections performed					
Omentectomy	14	130	1.0000 NC**		NT
Splenectomy	11	73	0.0885 0.3 (0.1, 1.2)		NT
Rectosigmoid colon	7	50	0.3648 0.6 (0.2, 1.8)		NT
Right colon resection	7	63	0.8512 0.9 (0.3, 2.7)		NT
Hysterectomy	4	43	1.0000 1.2 (0.4, 4.0)		NT
Small bowel resection	2	27	0.7375 1.5 (0.3, 7.2)		NT
Transverse colon resection	3	17	0.4078 0.5 (0.1, 2.1)		NT
Gastrectomy	0	4	1.0000 NC		NT
Visceral resections performed per patient					
0–2	5	51	0.8471		NT
3–7	9	82	1.1 (0.4, 3.5)		
Anastomoses performed					
Esophagojejunal	0	2	1.0000 NC		NT
Small bowel	1	21	0.6945 2.4 (0.3, 19.6)		NT
Ileocolic	1	28	0.3038 3.5 (0.4, 27.6)		NT
Colocolic	0	3	1.0000 NC		NT
Colorectal	5	51	0.8471 1.1 (0.4, 3.5)		NT
Anastomoses performed per patient					
0–2	14	125	1.0000		NT
3–5	0	8	NC		
Ostomies performed					
None	9	95	reference		
Diverting ileostomy	3	27	0.7305 1.2 (0.3, 4.6)		NT
End ileostomy	2	11	0.3518 1.9 (0.4, 10.0)		NT
Blood replacement					
None	5	34	reference		
Blood 1–3	2	66	0.0966 0.2 (0.04, 1.1)		NT
Blood 4–6	4	31	1.0000 0.9 (0.2, 3.6)		NT
Blood >6	3	2	0.0349 10.2 (1.4, 76.9)	10.2 (1.4, 76.9)	*0.0030*

Table 5: Continued.

	Pulmonary Events I–IV Univariate analysis			Pulmonary Events I–IV Multivariate analysis	
	Yes $N = 14$	No $N = 133$	P value*/OR (95% CI)	Odds ratio	P value
Blood replacement					
Blood 0–6	11	131	Reference		
Blood >6	3	2	0.0062 17.9 (2.7,118.5)		
Fresh frozen plasma replacement					
None	7	73	reference		
Plasma 1–4	4	47	1.0000 0.9 (0.2, 3.2)		NT
Plasma >4	3	13	0.3627 2.4 (0.6, 10.5)		NT
Time in operating room (hours)					
0–6	0	10	Reference		
7–12	12	112	0.5986 NC		NT
>12	2	11	0.4862 NC		NT
Chemotherapy treatment					
HIPEC only	5	74	0.2128		NT
HIPEC plus EPIC	8	57	2.1 (0.6, 6.7)		
Unknown	2	1			

* Pearson Chi-square or Fisher's exact test if sparse distribution.
**NC means not calculated due to 0 count in any of the cells.
***NT means not tested in multivariate modeling due to nonsignificant univariate test.

multidisciplinary team and to confer regarding the rationale, indications, and the morbidity associated with this procedure. It is possible to perform peritonectomy and HIPEC with morbidity and mortality rates in line with those of other major oncologic procedures [7].

References

[1] P. H. Sugarbaker, "New standard of care for appendiceal epithelial neoplasms and pseudomyxoma peritonei syndrome?" *Lancet Oncology*, vol. 7, no. 1, pp. 69–76, 2006.

[2] T. D. Yan, L. Welch, D. Black, and P. H. Sugarbaker, "A systematic review on the efficacy of cytoreductive surgery combined with perioperative intraperitoneal chemotherapy for diffuse malignancy peritoneal mesothelioma," *Annals of Oncology*, vol. 18, no. 5, pp. 827–834, 2007.

[3] T. C. Chua, W. Liauw, and D. L. Morris, "Colorectal cancer: prevention and treatment of peritoneal metastases," in *Cytoreductive Surgery and Perioperative Chemotherapy For Peritoneal Surface Malignancy: Textbook and Video Atlas*, P. H. Sugarbaker, Ed., Cine-Med, Woodbury, Conn, USA, 2012.

[4] O. Glehen, Y. Yonemura, and P. H. Sugarbaker, "Prevention and treatment of peritoneal metastases from gastric cancer," in *Cytoreductive Surgery and Perioperative Chemotherapy For Peritoneal Surface Malignancy: Textbook and Video Atlas*, P. H. Sugarbaker, Ed., Cine-Med, Woodbury, Conn, USA, 2012.

[5] C. W. Helm, "Epithelial ovarian cancer with peritoneal metastases," in *Cytoreductive Surgery and Perioperative Chemotherapy For Peritoneal Surface Malignancy: Textbook and Video Atlas*, P. H. Sugarbaker, Ed., Cine-Med, Woodbury, Conn, USA, 2012.

[6] R. M. Smeenk, V. J. Verwaal, and F. A. N. Zoetmulder, "Learning curve of combined modality treatment in peritoneal surface disease," *British Journal of Surgery*, vol. 94, no. 11, pp. 1408–1414, 2007.

[7] F. Mohamed and B. J. Moran, "Morbidity and mortality with cytoreductive surgery and intraperitoneal chemotherapy: the importance of a learning curve," *Cancer Journal*, vol. 15, no. 3, pp. 196–199, 2009.

[8] S. A. Ahmad, J. Kim, J. J. Sussman et al., "Reduced morbidity following cytoreductive surgery and intraperitoneal hyperthermic chemoperfusion," *Annals of Surgical Oncology*, vol. 11, no. 4, pp. 387–392, 2004.

[9] V. A. Lawrence, S. G. Hilsenbeck, C. D. Mulrow, R. Dhanda, J. Sapp, and C. P. Page, "Incidence and hospital stay for cardiac and pulmonary complications after abdominal surgery," *Journal of General Internal Medicine*, vol. 10, no. 12, pp. 671–678, 1995.

[10] P. H. Sugarbaker, "Comprehensive management of peritoneal surface malignancy using cytoreductive surgery and perioperative intraperitoneal chemotherapy: the Washington Cancer Institute approach," *Expert Opinion on Pharmacotherapy*, vol. 10, no. 12, pp. 1965–1977, 2009.

[11] P. Jacquet and P. H. Sugarbaker, "Current methodologies for clinical assessment of patients with peritoneal carcinomatosis," *Journal of Experimental and Clinical Cancer Research*, vol. 15, no. 1, pp. 49–58, 1996.

[12] P. H. Sugarbaker, K. Van der Speeten, O. A. Stuart, D. Chang, and H. Mahteme, "Patient- and treatment-related variables, adverse events and their statistical relationship for treatment of peritoneal metastases," in *Cytoreductive Surgery and Perioperative Chemotherapy For Peritoneal Surface Malignancy: Textbook and Video Atlas*, P. H. Sugarbaker, Ed.

[13] T. D. Yan, L. Zappa, G. Edwards, R. Alderman, C. E. Marquardt, and P. H. Sugarbaker, "Perioperative outcomes of cytoreductive surgery and perioperative intraperitoneal chemotherapy for non-Appendiceal peritoneal carcinomatosis from a prospective database," *Journal of Surgical Oncology*, vol. 96, no. 2, pp. 102–112, 2007.

[14] S. Kusamura, R. Younan, D. Baratti et al., "Cytoreductive surgery followed by intraperitoneal hyperthermic perfusion: analysis of morbidity and mortality in 209 peritoneal surface malignancies treated with closed abdomen technique," *Cancer*, vol. 106, no. 5, pp. 1144–1153, 2006.

[15] E. Chéreau, M. Ballester, F. Selle et al., "Pulmonary morbidity of diaphragmatic surgery for stage III/IV ovarian cancer," *An International Journal of Obstetrics and Gynaecology*, vol. 116, no. 8, pp. 1062–1068, 2009.

[16] S. C. Dowdy, R. T. Loewen, G. Aletti, S. S. Feitoza, and W. Cliby, "Assessment of outcomes and morbidity following diaphragmatic peritonectomy for women with ovarian carcinoma," *Gynecologic Oncology*, vol. 109, no. 2, pp. 303–307, 2008.

[17] A. D. Stephens, R. Alderman, D. Chang et al., "Morbidity and mortality analysis of 200 treatments with cytoreductive surgery and hyperthermic intraoperative intraperitoneal chemotherapy using the coliseum technique," *Annals of Surgical Oncology*, vol. 6, no. 8, pp. 790–796, 1999.

[18] A. Capone, M. Valle, F. Proietti, O. Federici, A. Garofalo, and N. Petrosillo, "Postoperative infections in cytoreductive surgery with hyperthermic intraperitoneal intraoperative chemotherapy for peritoneal carcinomatosis," *Journal of Surgical Oncology*, vol. 96, no. 6, pp. 507–513, 2007.

[19] O. Glehen, D. Osinsky, E. Cotte et al., "Intraperitoneal chemohyperthermia using a closed abdominal procedure and cytoreductive surgery for the treatment of peritoneal carcinomatosis: morbidity and mortality analysis of 216 consecutive procedures," *Annals of Surgical Oncology*, vol. 10, no. 8, pp. 863–869, 2003.

[20] U. Schmidt, M. H. Dahlke, J. Klempnauer, H. J. Schlitt, and P. Piso, "Perioperative morbidity and quality of life in long-term survivors following cytoreductive surgery and hyperthermic intraperitoneal chemotherapy," *European Journal of Surgical Oncology*, vol. 31, no. 1, pp. 53–58, 2005.

[21] H. Müller, M. Hahn, L. Weller, and J. Simsa, "Strategies to reduce perioperative morbidity in cytoreductive surgery," *Hepato-Gastroenterology*, vol. 55, no. 86-87, pp. 1523–1529, 2008.

Hindawi Publishing Corporation
Gastroenterology Research and Practice
Volume 2012, Article ID 890450, 6 pages
doi:10.1155/2012/890450

Clinical Study

Adjuvant Bidirectional Chemotherapy with Intraperitoneal Pemetrexed Combined with Intravenous Cisplatin for Diffuse Malignant Peritoneal Mesothelioma

Lana Bijelic,[1] O. Anthony Stuart,[2] and Paul Sugarbaker[1]

[1] *Department of Surgery, Washington Hospital Center, 110 Irving Street, Washington, DC 20010, USA*
[2] *Medstar Health Research Institute, Washington, DC, USA*

Correspondence should be addressed to Lana Bijelic, lana.bijelic@medstar.net

Received 13 April 2012; Accepted 22 June 2012

Academic Editor: Yutaka Yonemura

Cytoreductive surgery (CRS) with heated intraoperative intraperitoneal chemotherapy (HIPEC) has emerged as optimal treatment for diffuse malignant peritoneal mesothelioma (DMPM) showing median survivals of 36–92 months. However, recurrences occur frequently even in patients undergoing optimal cytreduction and are often confined to the abdomen. We initiated a Phase II study of adjuvant intraperitoneal pemetrexed combined with intravenous cisplatin for patients undergoing CRS and HIPEC for DMPM. The treatment consisted of pemetrexed 500 mg/m^2 intraperitoneally and cisplatin 50 mg/m^2 intravenously given simultaneously on day 1 of every 21 day cycle for 6 cycles. The primary endpoint of the study was treatment related toxicity. From July 2007 until July 2009 ten patients were enrolled. Nine of 10 completed all 6 cycles of adjuvant treatment per protocol. The most common toxicities were fatigue, nausea and abdominal pain grade 1 or 2. There was one grade 3 toxicity consisting of a catheter infection. The median survival for all 10 patients was 33.5 months. Pharmacokinetic analysis of intraperitoneal pemetrexed showed a peritoneal to plasma area under the curve ratio of 70. Our study shows that adjuvant intravenous cisplatin and intraperitoneal pemetrexed can be used following CRS and HIPEC for DMPM with low morbidity.

1. Introduction

Malignant mesotheliomas are tumors arising from the lining of the pleural or peritoneal cavity. Of the estimated 2,500 cases of mesothelioma occurring in the United States annually, approximately 20% are peritoneal mesotheliomas. Peritoneal mesotheliomas are characterized by numerous tumor nodules covering the parietal and visceral serosal surfaces of the peritoneal cavity. Clinically, it usually presents with abdominal distention, ascites, and pain [1]. The natural history of peritoneal mesothelioma is that of rapid progression with fatal outcome without treatment. Mesothelioma remains confined to the serosal surface of the abdominal cavity in the majority of the patients [2, 3]. Treatment approaches have traditionally been largely unsuccessful in this disease and consisted of systemic chemotherapy with surgery employed for palliation of gastrointestinal symptoms. The median survivals with these strategies generally ranged from 9 to 14 months [4–6].

An alternative treatment strategy consisting of more aggressive surgery and local-regional chemotherapy aimed at complete eradication of the disease has emerged showing dramatically improved median survivals. Cytoreductive surgery (CRS) with heated intraoperative intraperitoneal chemotherapy (HIPEC) has been used in a number of centers worldwide showing median survivals of 36–92 months and has become the preferred therapy for eligible patients [7–12]. Yet, a significant proportion of patients with mesothelioma treated with this modality are not able to achieve complete cytoreduction and therefore need further treatment with chemotherapy. Even in patients who have a complete cytoreduction and HIPEC, recurrent disease is common and it usually occurs in the abdomen [13]. Pemetrexed is a multi-targeted antifolate agent that was shown in Phase III studies to significantly improve response rates in patients with advanced pleural and peritoneal malignant mesothelioma. Treatment was with systemic cisplatin combined with pemetrexed compared with systemic cisplatin alone [14, 15].

In this current study we prospectively assess the feasibility and toxicity of an adjuvant treatment with intraperitoneal pemetrexed combined with intravenous cisplatin in patients with malignant peritoneal mesothelioma who underwent CRS and HIPEC.

2. Methods

2.1. Patients. Patients with histologically proven diffuse malignant peritoneal mesothelioma who were candidates for CRS and HIPEC at our institution were offered participation in this Phase II study. Eligibility criteria included completion of the best possible surgical cytoreduction, performance status of 0–2, and adequate organ and marrow function. The study was approved by the institutional IRB and all patients signed an informed consent.

2.2. Treatment. This was a single-institution Phase II study of adjuvant intraperitoneal pemetrexed combined with intravenous cisplatin. The primary endpoint of the study was toxicity related to the adjuvant treatment. Secondary endpoint was survival at 2 years.

The treatment consisted of pemetrexed 500 mg/m^2 given intraperitoneally and cisplatin 50 mg/m^2 given intravenously simultaneously on day 1 of every 21-day cycle for 6 cycles. Pemetrexed was mixed in 1liter of peritoneal dialysis solution and administered through an implantable peritoneal port (Port-a-Cath, Smith Medical ASD Inc., St. Paul, MN, USA) placed at the time of cytoreductive surgery.

All patients received folic acid 1000 micrograms orally daily and vitamin B12 1000 micrograms intramuscularly every 9 weeks beginning 2 weeks before starting therapy and continued through the end of the last cycle of therapy. The patients also received dexamethasone orally on the day before, the day of, and the day after pemetrexed.

2.3. Peritoneal Port Placement and Maintenance. Peritoneal ports were placed at the time of CRS and HIPEC in all patients. Immediately prior to abdominal closure, the port was placed using the following technique: a 5 cm transverse incision was made lateral to the umbilicus on the left side overlying the lateral border of the rectus sheath. The tissues were dissected to the abdominal fascia and a small opening made in the fascia to accommodate the catheter that was placed in the abdomen with the tip directed at the pelvis. Blunt dissection was used to create a subcutaneous channel and pocket 10 cm cephalad to the skin incision where the port was positioned. A right angle noncoring needle (Gripper Plus, Smith Medical ASD Inc., St. Paul, MN, USA) was then used to access the port, secured, in position with sutures and left in place for 10 days during postoperative recovery to prevent port twisting.

2.4. Clinical Data Collection and Statistical Analysis. Details regarding the extent of peritoneal involvement by mesothelioma, completeness of cytoreduction, and HIPEC treatment received were recorded prospectively in the HIPEC database for all patients. Toxicities related to adjuvant treatment were prospectively recorded using the Common Toxicity Criteria for Adverse Events Version 3. Survival was defined as the time from cytoreductive surgery to the time of death from any cause. Patients who were alive at the time of last followup were censored on that date. Statistical analysis was performed using SPSS software.

3. High-Performance Liquid Chromatography (HPLC) Analysis of Plasma, Peritoneal Fluid, and Urine

3.1. Sampling. Prior to treatment a 3 mL reference sample of the chemotherapy solution was obtained along with a 3 mL sample of blood and urine. Subsequently, 3 mL aliquots of blood, peritoneal fluid, and urine were obtained at 15-minute intervals for one-hour and 30-minute intervals for an additional two hours in all patients. These samples were centrifuged to remove debris or red blood cells. The cell-free solutions were frozen and stored for high performance liquid chromatography (HPLC) analysis which was performed within one week.

Pemetrexed concentrations were determined using a modified version of the HPLC method as described by Neurnberg et al. [16]. Briefly, the HPLC system consisted of a Shimadzu LC7A instrument equipped with an SPD-6AV (UV-VIS) detector set at 295 nm and a C-R6a "Chromatopac" data processor (Shimadzu Instruments, Columbia, MD, USA). Chromatographic separation was accomplished on a C18 reversed phase column (Varian Associates, Walnut Creek, CA, USA). The mobile phase consisted of 28% acetonitrile in 0.1% orthophosphoric acid with 0.1% triethylamine. The flow rate was 1.2 mL/min and the sample injection volume was 50 μL.

All samples were thawed at room temperature before HPLC analysis. Peritoneal fluid samples were diluted appropriately with methanol. After thorough mixing the resulting solutions were filtered through 0.45 micron syringe filters prior to HPLC injection.

For plasma samples, a 500 μL sample was mixed with 10 volumes of chloroform-isopropanol (2 : 1) in 15 mL screw-capped polypropylene centrifuge tubes. After thorough mixing followed by centrifugation the lower organic phase was transferred to a clean polypropylene centrifuge tube and evaporated to dryness under a stream of N2 at 37°C. The residue was dissolved in 250 μL of methanol and filtered through a 0.45 micron syringe filter prior to HPLC injection.

3.2. Data Retrieval and Statistics. All data presented on the graphs are mean +1 standard deviation. Calculations of area under the curve (AUC) and subsequent AUC ratios were obtained using GraphPad Prism analyses (GraphPad Software, Inc., La Jolla, CA, USA).

4. Results

4.1. Demographic Features and Outcome of Cytoreductive Surgery. From July 2007 until July 2009, ten patients signed the informed consent and were enrolled in the Phase

Table 1: Demographic features and outcomes of cytoreductive surgery in ten patients undergoing adjuvant chemotherapy with intraperitoneal pemetrexed and intravenous cisplatin for diffuse malignant peritoneal mesothelioma.

	Number of patients
Total	10
Female	3
Male	7
Age	
Mean	51
Range	23–69
Peritoneal cancer index (PCI)	
Mean	24
Range	7–39
CC score	
CC 0/1	4
CC 2	4
CC 3	2
Visceral sparing cytoreduction	8
Colon resection	2

I/II study. All patients had histologically confirmed diffuse malignant peritoneal mesothelioma: 8/10 had epithelioid type while 2 had biphasic histology. All ten patients underwent CRS by the same surgeon and received HIPEC consisting of 50 mg/m^2 of cisplatin combined with 15 mg/m^2 of doxorubicin in 1.5 L/m^2 of peritoneal dialysis solution circulated for 90 minutes at 41–42.5°C. Nine of the 10 patients also received early postoperative intraperitoneal chemotherapy (EPIC) consisting of paclitaxel 20 mg/m^2 daily for 5 days starting on postoperative day 1. Table 1 summarizes the baseline characteristics of the patients and outcomes of CRS.

4.2. Bidirectional Adjuvant Chemotherapy. Nine of 10 patients were able to complete all 6 cycles of therapy without treatment delays or dosing modifications. One patient developed a catheter infection after cycle number 3 and required catheter removal. He was switched to intravenous pemetrexed and cisplatin for one cycle, then had a new peritoneal catheter placed and subsequently completed cycles 5 and 6 according to protocol. The most common observed toxicities were fatigue, nausea, and abdominal pain but were generally mild. The only Grade 3 toxicity was the above mentioned catheter infection. There were no deaths related to treatment and no hospitalizations due to treatment side effects. Table 2 summarizes the toxicities observed in the 10 patients enrolled.

4.3. Pharmacokinetics of Intraperitoneal Pemetrexed. In four patients the pharmacokinetics of intraperitoneal pemetrexed was studied on the first cycle of adjuvant treatment (Figure 1). The area under the curve of peritoneal fluid concentration times time was 84150 μgmL^{-1}. The area under the curve of plasma pemetrexed concentrations times time was 1250 μgmL^{-1}. The increased exposure of peritoneal surfaces to chemotherapy as compared to plasma (area under the curve ratio) was 70. The peak plasma concentration was 6.5 ± 3 μg/mL at 180 minutes.

Table 2: Toxicities observed in ten patients treated with adjuvant intraperitoneal pemetrexed combined with intravenous cisplatin following cytoreductive surgery and hyperthermic intraperitoneal chemotherapy for diffuse malignant peritoneal mesothelioma.

	Grade I-II	Grade III-IV
Nausea	5	0
Abdominal pain	5	0
Alopecia	2	0
Fatigue	6	0
Neutropenia	0	0
Thrombocytopenia	0	0
Catheter infection	0	1

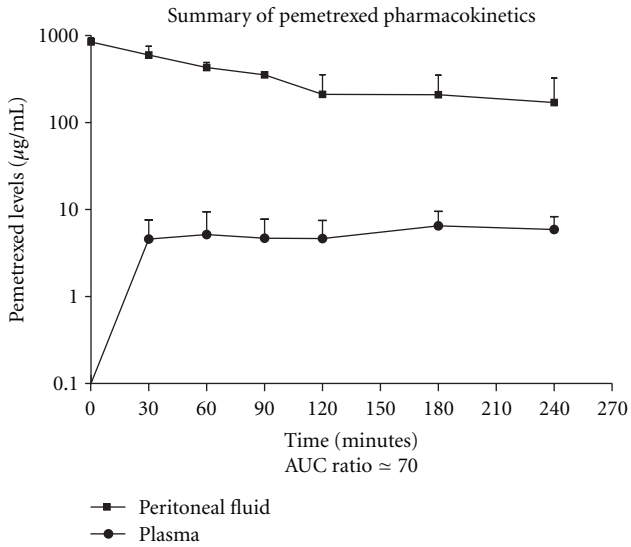

Figure 1: Concentration times time graph of pemetrexed in peritoneal fluid and plasma from four different pharmacologic studies. The AUC ratio of peritoneal fluid to plasma was 70. Peak plasma concentration was 0.05 (+0.02) μg/mL at 30 minutes.

In a single patient the first and final treatments with intraperitoneal pemetrexed were studied pharmacologically. The data is shown in Figure 2.

4.4. Follow-Up Data. After a median followup of 44 months, 4 patients have no evidence of disease, 2 are alive with disease, and 4 have died of disease. The median survival for all 10 patients is 33.5 months. With a median followup of 50 months in 6 living patients, no long term symptoms of peritoneal sclerosis have been observed.

5. Discussion

DMPM is a rare malignancy of the abdominal cavity characterized by extensive involvement of the peritoneal

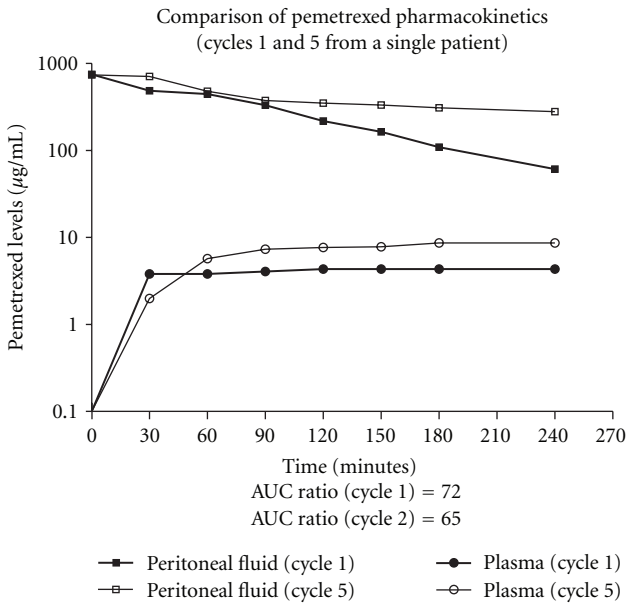

Figure 2: Concentration times time graph of intraperitoneal pemetrexed in peritoneal fluid and plasma in a single patient who had pharmacologic studies of the first and fifth cycle.

surfaces by tumor nodules. Due to the diffuse nature of the tumor, it has traditionally been considered not appropriate for surgical intervention and treated with palliative measures [17, 18]. The development of the peritonectomy procedures combined with HIPEC allowed many patients with malignant peritoneal mesothelioma to undergo a potentially curative treatment [18]. The results of cytoreductive surgery combined with HIPEC have been reported by several international centers showing significantly longer median survivals compared to historical results of treatment using palliative systemic chemotherapy with or without abdominal radiation [7–12, 18, 19]. Recently, the results of a multi-institutional registry of patients with DMPM treated with CRS and HIPEC at eight leading institutions over the last 20 years was published. Four hundred five patients were included and 46% were able to have a complete or near-complete cytoreduction [20]. The median survival was 53 months and 5-year survival was 47%. The prognostic factors associated with survival were epithelial histologic subtype, absence of lymph node metastasis, completeness of cytoreductive score, and HIPEC [17].

While this large registry data provides encouraging results overall, it also clearly shows that CRS and HIPEC are unlikely to be sufficient therapy in the majority of patients as only 46% were able to have a complete cytoreduction. Other experienced institutions have shown that even in the group of patients who receive a complete cytoreduction, local regional recurrence is common. Baratti et al. were able to achieve a complete or near-complete cytoreduction in 56 of 70 patients but despite that 38 developed recurrent disease including 11of 26 patients in the CC-0 group. Importantly, treatment failures were primarily confined to the abdominal cavity in the vast majority of patients [13].

Adjuvant treatment following CRS and HIPEC for patients with DMPM appears to be needed for the patients with high grade disease but there is no consensus regarding the optimal approach. Large randomized trials of palliative systemic therapy in mesothelioma have shown that combination therapy using cisplatin and pemetrexed has superior response rates and median survival compared to cisplatin alone [14]. Therefore, we designed our study to assess the feasibility of an adjuvant treatment plan using the current standard agents but administered regionally in order to achieve maximum benefit at the sites most at risk while minimizing systemic toxicity. In ongoing attempts to improve the local-regional control of peritoneal mesothelioma after CRS and HIPEC, we elected to explore in a Phase I/II study the intraperitoneal used of pemetrexed.

Pemetrexed is a multitargeted antifolate that inhibits dihydrofolate reductase, thymidylate synthase, and glycinamide ribonucleotide formyltransferase, key enzymes involved in purine and pyrimidine synthesis [21, 22]. With a molecular weight of 471.384, it is a drug expected to have a favorable profile for intraperitoneal administration based on the principles described by Dedrick et al. [23]. We have previously studied the pharmacokinetics of pemetrexed after intraperitoneal administration in a rat model showing a 24-fold increase in exposure of peritoneal surfaces to pemetrexed compared to intravenous administration [24]. Therefore, there is a strong pharmacologic and clinical rationale for choosing the intraperitoneal route for novel approaches to adjuvant treatment of peritoneal mesothelioma following CRS and HIPEC.

In this study, we confirmed that the exposure of peritoneal surfaces to adjuvant pemetrexed was 70 times greater than plasma exposure. This suggests a role for continued local-regional adjuvant treatment of peritoneal mesothelioma patients judged to be a high risk for recurrence after CRS and HIPEC. Peritoneal mesothelioma, a disease largely confined to the abdominal and pelvic space throughout its natural history is not the only disease to be treated by adjuvant bidirectional chemotherapy.

The intraperitoneal route for adjuvant chemotherapy in cancers with a high propensity for progression on peritoneal surfaces has been most extensively studied in ovarian cancer. The large Gynecologic Oncology Group 172 randomized trial showed a significant benefit in overall survival and progression-free survival for patients with optimally debulked stage III epithelial ovarian cancer treated with intraperitoneal and intravenous chemotherapy compared to patients treated with intravenous chemotherapy alone [25].

This has led to a more widespread use of intraperitoneal chemotherapy in the adjuvant setting but there is still significant resistance to fully integrate this route of administration into daily practice. In great part, this is due to concerns about potential complications and significant morbidity related to intraperitoneal chemotherapy administration and the intraperitoneal catheter. Catheter-associated complications were the primary cause for failure to complete all six cycles of therapy in the GOG 172 trial: 119 (58%) of patients did not complete all six cycles of chemotherapy in the study and of these and 40 (34%) failed because of catheter complications

[26]. Rectosigmoid colon resection was associated with failure to initiate intraperitoneal chemotherapy. In our study, only 1 significant catheter-related problem was observed: this was a catheter infection that required removal and a change to intravenous chemotherapy for one cycle. This patient also had a rectosigmoid colon resection as part of the cytoreductive surgery. It is possible that an increased risk of catheter infection is seen in patients who undergo rectosigmoid colon resection at the time of cytoreductive surgery because of possible contamination. Special attention should be given to the placement of the port in those circumstances.

The intraperitoneal administration of chemotherapy at the same dose used for systemic administration has been reported to be associated with few systemic side effects, due to differences in the pharmacokinetics [27]. This study is in accordance with this principle showing that few significant systemic toxicities were observed. Local-regional toxicities related to abdominal distention and discomfort at the time of administration were also low in our study. This is probably due to the fact that we kept the volume of the intraperitoneal chemotherapy solution at a moderate amount of 1 liter, which is well tolerated by most patients.

A single patient was studied pharmacologically on her first and sixth cycles of intraperitoneal pemetrexed. Maintenance of the pharmacologic advantage throughout the treatment was suggested by similar area under the curve ratios of both studies. Also, long-term followup of our patients up to four years does not suggest an intestinal fibrosis resulting from these intraperitoneal chemotherapy treatments.

At the initiation of this Phase I/II study, a dose escalation of intraperitoneal pemetrexed was planned. However, as the patient went on to complete all six cycles of treatment the fatigue they experienced did not suggest that a dose escalation was possible. A larger dose of chemotherapy, in our judgment, would have seriously jeopardized the completion of the protocol treatments. The regimen, as completed in these protocol patients, has now become the standard of care at our institution.

In summary, our study shows that an adjuvant protocol of combined intravenous and intraperitoneal chemotherapy can be successfully implemented for patients with peritoneal mesothelioma following CRS and HIPEC with low morbidity. Our practice of placing the intraperitoneal port at the end cytoreductive surgery was successful and only one significant catheter problem was observed. We recommend our regimen, tested as a multi-institutional adjuvant intraperitoneal pemetrexed combined with intravenous cisplatin adjuvant therapy, for patients with this rare cancer.

References

[1] Y. I. Z. Acherman, L. S. Welch, C. M. Bromley, and P. H. Sugarbaker, "Clinical presentation of peritoneal mesothelioma," *Tumori*, vol. 89, no. 3, pp. 269–273, 2003.

[2] K. H. Antman, R. H. Blum, and J. S. Greenberger, "Multimodality therapy for malignant mesothelioma based on a study of natural history," *American Journal of Medicine*, vol. 68, no. 3, pp. 356–362, 1980.

[3] A. M. Averbach and P. H. Sugarbaker, "Peritoneal mesothelioma: treatment approach based on natural history," *Cancer Treatment and Research*, vol. 81, pp. 193–211, 1996.

[4] E. Chailleux, G. Dabouis, D. Pioche et al., "Prognostic factors in diffuse malignant pleural mesothelioma. A study of 167 patients," *Chest*, vol. 93, no. 1, pp. 159–162, 1988.

[5] K. Antman, R. Shemin, L. Ryan et al., "Malignant mesothelioma: prognostic variables in a registry of 180 patients, the Dana-Farber Cancer Institute and Brigham and Women's Hospital experience over two decades, 1965–1985," *Journal of Clinical Oncology*, vol. 6, no. 1, pp. 147–153, 1988.

[6] K. S. Sridhar, R. Doria, W. A. Raub Jr., R. J. Thurer, and M. Saldana, "New strategies are needed in diffuse malignant mesothelioma," *Cancer*, vol. 70, no. 12, pp. 2969–2979, 1992.

[7] P. H. Sugarbaker, L. S. Welch, F. Mohamed, and O. Glehen, "A review of peritoneal mesothelioma at the Washington Cancer Institute," *Surgical Oncology Clinics of North America*, vol. 12, no. 3, pp. 605–621, 2003.

[8] T. D. Yan, E. A. Brun, A. Carlos, N. Haveric, D. Chang, and P. H. Sugarbaker, "Prognostic indicators for patients undergoing cytoreductive surgery and perioperative intraperitoneal chemotherapy for diffuse malignant peritoneal mesothelioma," *Annals of Surgical Oncology*, vol. 14, no. 1, pp. 41–49, 2007.

[9] A. L. Feldman, S. K. Libutti, J. F. Pingpank et al., "Analysis of factors associated with outcome in patients with malignant peritoneal mesothelioma undergoing surgical debulking and intraperitoneal chemotherapy," *Journal of Clinical Oncology*, vol. 21, no. 24, pp. 4560–4567, 2003.

[10] D. Nonaka, S. Kusamura, D. Baratti et al., "Diffuse malignant mesothelioma of the peritoneum: a clinicopathologic study of 35 patients treated locoregionally at a single institution," *Cancer*, vol. 104, no. 10, pp. 2181–2188, 2005.

[11] B. W. Loggie, R. A. Fleming, R. P. McQuellon, G. B. Russell, K. R. Geisinger, and E. A. Levine, "Prospective trial for the treatment of malignant peritoneal mesothelioma," *American Surgeon*, vol. 67, no. 10, pp. 999–1003, 2001.

[12] C. Brigand, O. Monneuse, F. Mohamed et al., "Peritoneal mesothelioma treated by cytoreductive surgery and intraperitoneal hyperthermic chemotherapy: results of a prospective study," *Annals of Surgical Oncology*, vol. 13, no. 3, pp. 405–412, 2006.

[13] D. Baratti, S. Kusamura, A. D. Cabras, P. Dileo, B. Laterza, and M. Deraco, "Diffuse malignant peritoneal mesothelioma: failure analysis following cytoreduction and hyperthermic intraperitoneal chemotherapy (HIPEC)," *Annals of Surgical Oncology*, vol. 16, no. 2, pp. 463–472, 2009.

[14] N. J. Vogelzang, J. J. Rusthoven, J. Symanowski et al., "Phase III study of pemetrexed in combination with cisplatin versus cisplatin alone in patients with malignant pleural mesothelioma," *Journal of Clinical Oncology*, vol. 21, no. 14, pp. 2636–2644, 2003.

[15] P. A. Jänne, A. J. Wozniak, C. P. Belani et al., "Open-label study of pemetrexed alone or in combination with cisplatin for the treatment of patients with peritoneal mesothelioma: outcomes of an expanded access program," *Clinical Lung Cancer*, vol. 7, no. 1, pp. 40–46, 2005.

[16] B. Nuernberg, M. Kohlbrenner, R. Faulkner, and D. Furst, "Rapid quantitation of methotrexate and its metabolites in human serum, urine and bile, using solid-phase extraction and high-performance liquid chromatography," *Journal of Chromatography*, vol. 487, no. 2, pp. 476–482, 1989.

[17] T. D. Yan, E. A. Brun, C. A. Cerruto, N. Haveric, D. Chang, and P. H. Sugarbaker, "Prognostic indicators for

patients undergoing cytoreductive surgery and perioperative intraperitoneal chemotherapy for diffuse malignant peritoneal mesothelioma," *Annals of Surgical Oncology*, vol. 14, no. 1, pp. 41–49, 2007.

[18] T. C. Chua, T. D. Yan, and D. L. Morris, "Peritoneal mesothelioma: current understanding and management," *Canadian Journal of Surgery*, vol. 52, no. 1, pp. 59–64, 2009.

[19] R. Hassan, R. Alexander, K. Antman et al., "Current treatment options and biology of peritoneal mesothelioma: Meeting summary of the first NIH peritoneal mesothelioma conference," *Annals of Oncology*, vol. 17, no. 11, pp. 1615–1619, 2006.

[20] T. D. Yan, M. Deraco, D. Baratti et al., "Cytoreductive surgery and hyperthermic intraperitoneal chemotherapy for malignant peritoneal mesothelioma: multi-institutional experience," *Journal of Clinical Oncology*, vol. 27, no. 36, pp. 6237–6242, 2009.

[21] R. M. Schultz, V. J. Chen, J. R. Bewley, E. F. Roberts, C. Shih, and J. A. Dempsey, "Biological activity of the multitargeted antifolate, MTA (LY231514), in human cell lines with different resistance mechanisms to antifolate drugs," *Seminars in Oncology*, vol. 26, no. 2, pp. 68–73, 1999.

[22] L. G. Mendelsohn, C. Shih, V. J. Chen, L. L. Habeck, S. B. Gates, and K. A. Shackelford, "Enzyme inhibition, polyglutamation, and the effect of LY231514 (MTA) on purine biosynthesis," *Seminars in Oncology*, vol. 26, supplement 6, no. 2, pp. 42–47, 1999.

[23] R. L. Dedrick, C. E. Myers, P. M. Bungay, and V. T. Devita, "Pharmacokinetic rationale for peritoneal drug administration in the treatment of ovarian cancer," *Cancer Treatment Reports*, vol. 62, no. 1, pp. 1–11, 1978.

[24] S. R. Pestieau, O. A. Stuart, and P. H. Sugarbaker, "Multitargeted antifolate (MTA): pharmacokinetics of intraperitoneal administration in a rat model," *European Journal of Surgical Oncology*, vol. 26, no. 7, pp. 696–700, 2000.

[25] D. K. Armstrong, B. Bundy, L. Wenzel et al., "Intraperitoneal cisplatin and paclitaxel in ovarian cancer," *New England Journal of Medicine*, vol. 354, no. 1, pp. 34–43, 2006.

[26] J. L. Walker, D. K. Armstrong, H. Q. Huang et al., "Intraperitoneal catheter outcomes in a phase III trial of intravenous versus intraperitoneal chemotherapy in optimal stage III ovarian and primary peritoneal cancer: a Gynecologic Oncology Group study," *Gynecologic Oncology*, vol. 100, no. 1, pp. 27–32, 2006.

[27] R. H. Sugarbaker, F. J. Gianola, and J. C. Speyer, "Prospective, randomized trial of intravenous versus intraperitoneal 5-fluorouracil in patients with advanced primary colon or rectal cancer," *Surgery*, vol. 98, no. 3, pp. 414–422, 1985.

Hindawi Publishing Corporation
Gastroenterology Research and Practice
Volume 2012, Article ID 163284, 6 pages
doi:10.1155/2012/163284

Research Article

Systemic Chemotherapy prior to Cytoreductive Surgery and HIPEC for Carcinomatosis from Appendix Cancer: Impact on Perioperative Outcomes and Short-Term Survival

Lana Bijelic,[1] Anjali S. Kumar,[2] O. Anthony Stuart,[3] and Paul H. Sugarbaker[1]

[1] *Section of Surgical Oncology, Department of Surgery, Washington Hospital Center, 110 Irving Street, Washington, DC 20010, USA*
[2] *Section of Colon and Rectal Surgery, Washington Hospital Center, 110 Irving Street, Washington, DC 20010, USA*
[3] *Medstar Health Research Institute, Washington Hospital Center, 110 Irving Street, Washington, DC 20010, USA*

Correspondence should be addressed to Lana Bijelic, lana.bijelic@medstar.net

Received 2 April 2012; Revised 31 May 2012; Accepted 31 May 2012

Academic Editor: Yan Li

Background and Objectives. Systemic chemotherapy administered prior to cytoreductive surgery and hyperthermic intraperitoneal chemotherapy (HIPEC) for peritoneal mucinous adenocarcinoma of appendiceal origin (PMCA) is associated with a significant rate of histological response. The impact of preoperative systemic chemotherapy (PSC) on intraperitoneal tumor burden, completeness of cytoreduction, and perioperative complications is unknown. *Methods*. We analyzed prospectively collected data from our HIPEC database. Thirty-four patients with PMCA were prospectively recruited and treated with PSC. Perioperative variables and survival in this group of patients were compared against 24 patients with PMCA who did not receive PSC. *Results*. Ten of 34 patients (29%) receiving PSC had a complete or near complete histological response. Patients receiving PSC had a lower peritoneal carcinomatosis index, required fewer peritonectomies and visceral resections, and achieved complete cytoreduction more frequently compared to patients with no preoperative chemotherapy. The incidence of perioperative complications and survival were not significantly different between the two groups. However, patients with complete histological response had better overall survival compared to patients without complete response. *Conclusions*. Preoperative systemic chemotherapy in appendix-originated PMCA is associated with a significant rate of histological response which may reduce the tumor burden, facilitate less aggressive and more complete CRS, and improve short-term survival in patients with a significant histological response.

1. Background

The use of neoadjuvant systemic chemotherapy prior to surgery for a primary, usually locally advanced, or metastatic malignancy has been extensively studied. The potential advantages of neoadjuvant chemotherapy include a reduction of tumor volume with a greater chance for complete surgical removal and organ preservation. The role of neoadjuvant chemotherapy or chemoradiation is well established in breast, rectal, and to a lesser extent, esophageal and ovarian cancers [1–4]. It has also been explored in association with surgery for liver metastases from colon cancer [5]. Although this approach may have important advantages in terms of improving resectability and local control, it generally does not improve overall survival when compared to adjuvant chemotherapy [2].

The benefit of neoadjuvant therapy may be more apparent among mucinous appendiceal neoplasms, which are often associated with peritoneal involvement at the time of diagnosis. The optimal treatment for this condition involves cytoreductive surgery and heated intraperitoneal chemotherapy (HIPEC) which results in long-term survival ranging from 30–80% at 20 years [6–8]. The histological characteristics of the peritoneal metastases range from adenomucinosis which has an excellent long-term outcome when treated with cytoreductive surgery and HIPEC to peritoneal mucinous adenocarcinoma (PMCA) which has a less favorable outcome despite this aggressive treatment [9]. Therefore, systemic therapy as an adjunct to cytoreductive surgery and HIPEC for PMCA is often utilized based on the effectiveness of FOLFOX chemotherapy in advanced colon

cancer [10]. Recently, there have been studies indicating reasonable activity of several 5-FU-based regimens in patients with advanced carcinomatosis from appendix cancer [11]. We have previously published our initial experience using FOLFOX chemotherapy as a neoadjuvant treatment prior to cytoreductive surgery and HIPEC in 34 patient with PMCA [12]. This initial manuscript described the clinical and histological parameters of response and showed that the ability of clinical examination and CT imaging to assess response to treatment was limited. However, pathologic examination showed a significant histological response in almost 30% of patients. In this study, we report the impact of neoadjuvant chemotherapy on perioperative outcomes including extent of cytoreductive surgery and morbidity as well as early survival in the original cohort of 34 patients and in a comparison group of 24 patients who were not treated with neoadjuvant chemotherapy.

2. Methods

Patients with histologically confirmed PMCA of appendiceal origin treated with cytoreductive surgery and HIPEC at the Washington Cancer Institute between January 2005 and December 2009 were retrospectively identified from a prospectively-collected database. Permission to collect and analyze this data was obtained from our Institutional Review Board.

From January 2005 until July 2009, patients with PMCA who were thought to be candidates for cytoreductive surgery and HIPEC at the time of their referral were enrolled in a prospective clinical pathway and treated with systemic chemotherapy prior to cytoreductive surgery. All of these patients had the diagnosis confirmed histologically at the time of initial laparotomy or laparoscopy and their slides reviewed to confirm the diagnosis of PMCA. Systemic chemotherapy consisted of a 5-FU- or capecitabine-based regimen with oxaliplatin. The choice of the specific regimen and the use of bevacizumab were at the discretion of the treating medical oncologist. The recommended initial duration of the therapy was 6 cycles followed by imaging and clinical evaluation. Additional 6 cycles of therapy were permitted if there was no evidence of progression at the completion of the first 6 cycles. Following completion of systemic chemotherapy, all patients underwent cytoreductive surgery and HIPEC. During this time period, 22 patients did not have systemic chemotherapy prior to cytoreductive surgery due to their refusal to participate in the prospective clinical pathway or inability to appropriately coordinate treatment with oncologists outside our institution and instead were treated with CRS and HIPEC upfront. Following the completion of our prospective observational study evaluating the use of routine preoperative systemic chemotherapy prior to CRS in July 2009, patients undergoing CRS did not receive routine systemic chemotherapy prior to surgery. Therefore, from July 2009 until December 2009 2 additional patients who did not receive systemic chemotherapy prior to CRS and HIPEC were identified in our database. All of these patients constituted the control group of 24 patients without neoadjuvant systemic chemotherapy in this analysis. Patients who were referred to our center after receiving multiple lines of systemic chemotherapy or who were treated with systemic chemotherapy because they were thought to have unresectable disease on initial evaluation were excluded from this analysis.

Cytoreductive surgery was performed by the senior author in all cases and consisted of peritonectomies and visceral resections performed as needed to achieve complete tumor removal whenever possible as previously described [13]. After all resections were completed, the patients underwent HIPEC for 90 minutes. The HIPEC regimen consisted of mitomycin C and doxorubicin at 15 mg/m^2 administered intraperitoneally at 42°C with simultaneous infusion of 5-FU 400 mg/m^2 and leucovorin 20 mg/m^2 intravenously. Early postoperative intraperitoneal chemotherapy with 5-FU was used selectively in patients who did not have more than 6 cycles of preoperative systemic chemotherapy and/or who had a moderate cytoreduction without multiple or high risk intestinal anastomoses. Perioperative variables including the peritoneal cancer index, completeness of cytoreduction, and a detailed assessment of morbidity by grade and organ system for each patient were prospectively assessed and entered into our database. For patients treated with neoadjuvant chemotherapy, response was assessed histologically by comparing the microscopic characteristics of the tumor resected at the time of cytoreduction to the appearance at the time of the initial diagnosis. A histological near-complete response was defined as the presence of adenomucinosis alone or the presence of extensive fibrosis with only sporadic malignant epithelial cells. A histological complete response was defined as absence of any tumor seen despite extensive sampling at the time of CRS.

3. Results

There were a total of 58 patients with PMCA identified in our HIPEC database during the study period: 34 patients who received systemic chemotherapy prior to CRS and HIPEC and 24 who did not. There were 27 males and 31 females with a mean age of 50.7 years. There were no differences between the 2 groups in terms of gender, age, histology, or lymph node status. The demographic and systemic chemotherapy data on the 34 patients who received and the 24 patients who did not receive systemic chemotherapy prior to cytoreductive surgery is shown in Table 1.

For the 34 patients treated with neoadjuvant systemic chemotherapy, none of the analyzed clinical factors including histological subtype, presence of positive lymph nodes, type of systemic regimen used, duration of preoperative systemic chemotherapy, or use of bevacizumab were predictive of histological complete or near-complete response.

In Table 2, the data gathered perioperatively in the 34 patients treated with neoadjuvant chemotherapy was statistically compared to the 24 patients who did not receive neoadjuvant chemotherapy prior to CRS and HIPEC. Patients receiving preoperative systemic chemotherapy had a lower peritoneal carcinomatosis index (mean 19) compared to patients not receiving neoadjuvant chemotherapy (mean 28, $P = 0.0003$). The mean number of peritonectomies

Table 1: Demographic and treatment data on 34 patients with PMCA from appendix cancer who received neoadjuvant systemic chemotherapy prior to cytoreductive surgery and HIPEC. None of these clinical parameters were predictive of histological response.

	Patients treated with neoadjuvant chemotherapy	Patients not treated with neoadjuvant chemotherapy	*P* value
Age (mean)	47.9	48.8	0.66
Gender		0.53	
Male	17	10	
Female	17	14	
Histological subtype		0.37	
Signet ring	9	4	
PMCA/adenocarcinoid	25	20	
Lymph node status		0.62	
Positive	12	7	
Negative	22	17	
Number of preoperative chemotherapy cycles	N/A		
6 cycles	12		
12 cycles	22		
Chemotherapy regimens	N/A		
FOLFOX	30		
XELOX	4		
Use of bevacizumab	N/A		
Yes	21		
No	13		
Gross assessment of response at cytoreduction	N/A		
Stable or response	16		
Progression	17		
Histological assessment of response			
No response	24		
Complete or near-complete response	10		

Table 2: Comparison of perioperative variables between 34 patients treated with neoadjuvant chemotherapy prior to cytoreductive surgery and HIPEC and 24 patients that did not receive preoperative chemotherapy before cytoreductive surgery and HIPEC.

Clinical characteristic	Patients with PMCA from appendix cancer		
	Neoadjuvant chemotherapy	No neoadjuvant chemotherapy	*P* value
Number of patients	34	24	
Peritoneal cancer index (mean)	19	28	0.0003
Number of peritonectomies	0.0032		
Mean	2.3	3.7	
Range	0–5	1–5	
Number of visceral resections	<0.001		
Mean	2.7	4.4	
Range	1–5	2–7	
Completeness of cytoreduction	0.78		
CCR 0/CCR 1	22	12	
CCR 2	7	5	
CCR 3	5	5	
Complications	0.16		
None or grade1/2	8	10	
Grade 3 or 4	26	14	

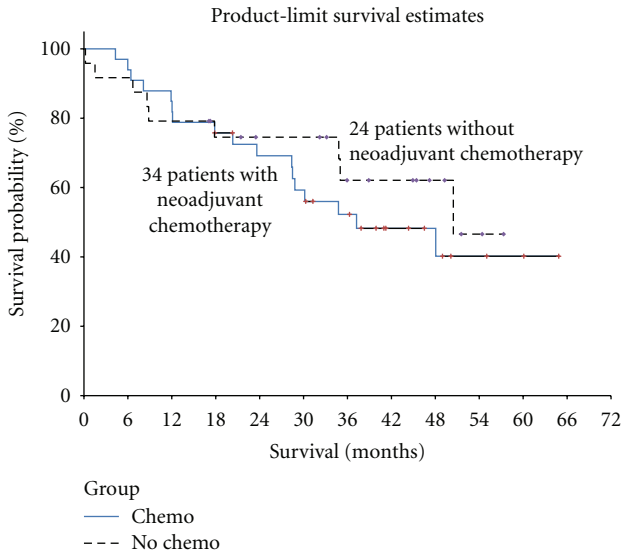

Figure 1: Kaplan-Meier survival analysis of 34 patients with PMCA from appendix cancer treated with neoadjuvant chemotherapy (median survival 37.2 months) compared to 24 patients who did not receive neoadjuvant chemotherapy prior cytoreduction and HIPEC (median survival 50.5 months). The difference in survival is not significant ($P = 0.56$).

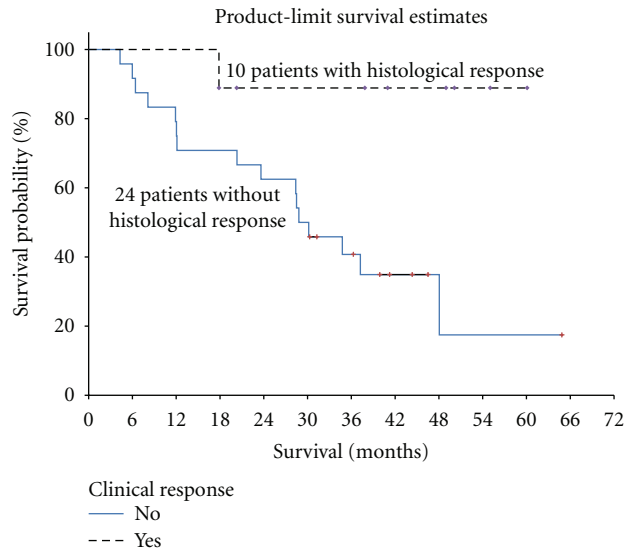

Figure 2: Kaplan-Meier survival analysis of 10 patients with PMCA from appendix cancer treated with neoadjuvant systemic chemotherapy prior to cytoreductive surgery and HIPEC who had a complete or near-complete histological response (median survival not reached) compared to 24 patients who had no significant histological response (median survival 29.5 months). The difference is statistically significant ($P = 0.032$).

(2.3 versus 3.7) and visceral resections (2.7 versus 4.4) was also significantly lower in patients who received preoperative systemic chemotherapy. Twenty-six of the 34 patients treated with neoadjuvant chemotherapy had grade 3 or 4 complications following cytoreductive surgery, similar to patients not treated with preoperative chemotherapy (14 of 24 patients, $P = 0.16$).

Median survival for patients receiving neoadjuvant chemotherapy was 37.2 months compared to 50.5 months for patients who did not receive preoperative chemotherapy ($P = 0.56$, Figure 1). However, among the patients who received neoadjuvant chemotherapy, survival was significantly better for patients who experienced a histological complete or near complete response (median survival not reached compared to patients with no histological response (median survival 29.5 months, $P = 0.033$, Figure 2)).

4. Discussion

We have previously documented that a substantial number of patients in our prospective cohort of PMCA patients treated with neoadjuvant systemic chemotherapy will have a favorable histological response [12]. This may be seen as a transition of PMCA into adenomucinosis, a marked fibrosis with only scattered malignant cells seen or a complete absence of any cancer cells. Having the ability to predict such significant response based on available clinical factors would improve our ability to select the appropriate patients for this treatment and guide certain aspects of the treatment. However, our data showed that none of the analyzed factors could predict response. This is similar to other experiences with preoperative chemotherapy or chemoradiation where clinical factors or imaging studies often fail to accurately predict pathological response [14, 15]. Some studies have used microarray analysis and genomic analysis to improve the ability to predict response to therapy in rectal and breast cancer. Unfortunately, to date, similar studies are not available in patients with appendiceal cancers [16, 17].

Another potential advantage of neoadjuvant chemotherapy is a reduction in tumor volume which can sometime translate into less extensive surgical procedures and allow for improved organ preservation. This is well established in breast cancer where the use of neoadjuvant chemotherapy in patients with locally advanced disease can offer the possibility of breast conservation in a significant number of patients who would otherwise require a mastectomy [18, 19]. Similarly, the use of neoadjuvant chemoradiation in rectal cancer was shown to be associated with an increased number of sphincter preserving procedures in a large prospective study [20]. The assessment of tumor volume and of the impact that a decrease in tumor burden may have on the surgery that is performed is more difficult in patients with peritoneal metastases because both clinical exam and imaging evaluations are inaccurate in assessing the extent of disease. The extent of the peritonectomies and visceral resection required for complete cytoreduction at best can only be estimated based on preoperative imaging. The final decision making is done at the time of the surgical exploration. Therefore, we attempted to evaluate whether neoadjuvant chemotherapy had an impact on the tumor burden and the extent of cytoreductive surgery by comparing 34 patients who received neoadjuvant chemotherapy to a cohort of 24 patients with PMCA who received cytoreductive surgery first. Both groups received the same HIPEC regimen. We found a significantly lower PCI in patients treated

with neoadjuvant chemotherapy suggesting a decrease in tumor burden (downsizing). As could be expected, this translated into a less extensive surgical procedure: the number of peritonectomies and the number of visceral resections were lower in the group of patients treated with neoadjuvant chemotherapy. A similar observation was made when neoadjuvant chemotherapy was studied in patients with advanced ovarian cancer: a significantly larger number of patients who received neoadjuvant chemotherapy was able to undergo complete cytoreduction compared to patients who had primary debulking surgery [21]. These results seem to suggest a significant advantage for the use of neoadjuvant chemotherapy but must be interpreted with some caution considering the nonrandomized nature of our study. Another potential problem in the use of neoadjuvant chemotherapy for peritoneal surface malignancies concerns some difficulties in assessing the gross findings in the operating room. This may lead to incomplete cytoreduction in patients whose frozen section analysis fails to demonstrate residual tumor that is later confirmed on immunohistochemistry or in cases of severe posttreatment fibrosis which makes peritonectomy impossible. However, despite a lower PCI and less extensive cytoreductive surgery, the rate of grade 3 and 4 complications was not significantly different in the two groups.

The impact of neoadjuvant chemotherapy on survival and locoregional control has been studied extensively in breast, rectal, esophageal, and other cancers. Although early reports have sometimes suggested a survival advantage for neoadjuvant therapy, this is usually lost with longer followup. More definitive randomized studies have shown that there is no survival advantage of neoadjuvant compared to adjuvant chemotherapy in breast cancer [2, 18, 19]. In rectal cancer, there is a benefit of preoperative chemoradiation in local control but no survival advantage. The results of a recent randomized study evaluating the role of neoadjuvant chemotherapy in patients with advanced ovarian cancer showed equivalent overall and progression-free survival for patients treated with primary debulking surgery and those treated with neoadjuvant chemotherapy followed by debulking surgery [20–22]. Our study is in agreement with these observations. In this experience, there is no improvement in overall survival in patients treated with neoadjuvant chemotherapy compared to patients without neoadjuvant treatment, but it is important to observe that adjuvant systemic therapy was recommended for these patients. However, considering the high rate of histological complete or near complete response in our cohort of patients, it would be important to know if this subset of patients has an improved survival. Indeed, our early data suggests that the patients who have a histologically significant response have a better short-term survival than those who do not have a significant response. It will be important to follow these patients in the future to determine whether this survival advantage will persist with longer followup. The fact that only patients with histologically significant response seem to have an improvement in survival at least in the short-term further emphasizes the importance of developing clinically useful predictors of response.

In summary, our experience suggests that 6 cycles of systemic chemotherapy prior to cytoreductive surgery for PMCA from appendix cancer may be associated with a reduction in tumor burden which may facilitate a less extensive cytoreductive procedure. We did not observe a significant change in postoperative complications in this group of patients compared to patients who were not treated with preoperative chemotherapy. Although the group as a whole does not seem to have an improved survival compared to patients with PMCA who receive systemic chemotherapy following CRS and HIPEC, the subgroup of patients with complete or near complete histological response appears to have better short-term survival compared to the group of patients without a histological response to preoperative chemotherapy.

Acknowledgments

The authors would like to thank David Chang from Westat for statistical support and Jasna Coralic, MD, for editorial assistance.

References

[1] R. Sauer, H. Becker, W. Hohenberger et al., "Preoperative versus postoperative chemoradiotherapy for rectal cancer," *New England Journal of Medicine*, vol. 351, no. 17, pp. 1731–1810, 2004.

[2] H. D. Bear, S. Anderson, R. E. Smith et al., "Sequential preoperative or postoperative docetaxel added to preoperative doxorubicin plus cyclophosphamide for operable breast cancer: national surgical adjuvant breast and bowel project protocol B-27," *Journal of Clinical Oncology*, vol. 24, no. 13, pp. 2019–2027, 2006.

[3] R. E. Bristow and D. S. Chi, "Platinum-based neoadjuvant chemotherapy and interval surgical cytoreduction for advanced ovarian cancer: a meta-analysis," *Gynecologic Oncology*, vol. 103, no. 3, pp. 1070–1076, 2006.

[4] I. G. Kaklamanos, G. R. Walker, K. Ferry, D. Franceschi, and A. S. Livingstone, "Neoadjuvant treatment for resectable cancer of the esophagus and the gastroesophageal junction: a meta-analysis of randomized clinical trials," *Annals of Surgical Oncology*, vol. 10, no. 7, pp. 754–761, 2003.

[5] L. Capussotti, A. Muratore, M. M. Mulas, P. Massucco, and M. Aglietta, "Neoadjuvant chemotherapy and resection for initially irresectable colorectal liver metastases," *British Journal of Surgery*, vol. 93, no. 8, pp. 1001–1006, 2006.

[6] P. H. Sugarbaker, "Epithelial appendiceal neoplasms," *Cancer Journal*, vol. 15, no. 3, pp. 225–235, 2009.

[7] P. H. Sugarbaker, "New standard of care for appendiceal epithelial neoplasms and pseudomyxoma peritonei syndrome?" *Lancet Oncology*, vol. 7, no. 1, pp. 69–76, 2006.

[8] D. Elias, F. Gilly, F. Quenet et al., "Pseudomyxoma peritonei: a French multicentric study of 301 patients treated with cytoreductive surgery and intraperitoneal chemotherapy," *European Journal of Surgical Oncology*, vol. 36, no. 5, pp. 456–462, 2010.

[9] B. M. Ronnett, C. M. Zahn, R. J. Kurman, M. E. Kass, P. H. Sugarbaker, and B. M. Shmookler, "Disseminated peritoneal adenomucinosis and peritoneal mucinous carcinomatosis: a clinicopathologic analysis of 109 cases with emphasis on

distinguishing pathologic features, site of origin, prognosis and relationship to "pseudomyxoma peritonei"," *American Journal of Surgical Pathology*, vol. 19, no. 12, pp. 1390–1408, 1995.

[10] T. André, C. Boni, L. Mounedji-Boudiaf et al., "Oxaliplatin, fluorouracil, and leucovorin as adjuvant treatment for colon cancer," *New England Journal of Medicine*, vol. 350, no. 23, pp. 2343–2351, 2004.

[11] J. F. Shapiro, J. L. Chase, R. A. Wolff et al., "Modern systemic chemotherapy in surgically unresectable neoplasms of appendiceal origin: a single-institution experience," *Cancer*, vol. 116, no. 2, pp. 316–322, 2010.

[12] P. H. Sugarbaker, L. Bijelic, D. Chang, and D. Yoo, "Neoadjuvant FOLFOX chemotherapy in 34 consecutive patients with mucinous peritoneal carcinomatosis of appendiceal origin," *Journal of Surgical Oncology*, vol. 102, no. 6, pp. 576–581, 2010.

[13] P. H. Sugarbaker, "Peritonectomy procedures," *Surgical Oncology Clinics of North America*, vol. 12, no. 3, pp. 703–727, 2003.

[14] S. P. Hiotis, S. M. Weber, A. M. Cohen et al., "Assessing the predictive value of clinical complete response to neoadjuvant therapy for rectal cancer: an analysis of 488 patients," *Journal of the American College of Surgeons*, vol. 194, no. 2, pp. 131–136, 2002.

[15] O. Zmora, G. M. Dasilva, B. Gurland et al., "Does rectal wall tumor eradication with preoperative chemoradiation permit a change in the operative strategy?" *Diseases of the Colon and Rectum*, vol. 47, no. 10, pp. 1607–1612, 2004.

[16] S. Huerta, J. Hrom, X. Gao et al., "Tissue microarray constructs to predict a response to chemoradiation in rectal cancer," *Digestive and Liver Disease*, vol. 42, no. 10, pp. 679–684, 2010.

[17] C. Hatzis, L. Pusztai, V. Valero et al., "A genomic predictor of response and survival following taxane-anthracycline chemotherapy for invasive breast cancer," *Journal of the American Medical Association*, vol. 305, no. 18, pp. 1873–1881, 2011.

[18] B. Fisher, A. Brown, E. Mamounas et al., "Effect of preoperative chemotherapy on local-regional disease in women with operable breast cancer: findings from national surgical adjuvant breast and bowel project B-18," *Journal of Clinical Oncology*, vol. 15, no. 7, pp. 2483–2493, 1997.

[19] S. V. Liu, L. Melstrom, K. Yao, C. A. Russell, and S. F. Sener, "Neoadjuvant therapy for breast cancer," *Journal of Surgical Oncology*, vol. 101, no. 4, pp. 283–291, 2010.

[20] R. Sauer, H. Becker, W. Hohenberger et al., "Preoperative versus postoperative chemoradiotherapy for rectal cancer," *New England Journal of Medicine*, vol. 351, no. 17, pp. 1731–1810, 2004.

[21] I. Vergote, C. G. Tropé, F. Amant et al., "Neoadjuvant chemotherapy or primary surgery in stage IIIC or IV ovarian cancer," *New England Journal of Medicine*, vol. 363, no. 10, pp. 943–953, 2010.

[22] J. F. Bosset, L. Collette, G. Calais et al., "Chemotherapy with preoperative radiotherapy in rectal cancer," *New England Journal of Medicine*, vol. 355, no. 11, pp. 1114–1123, 2006.

Hindawi Publishing Corporation
Gastroenterology Research and Practice
Volume 2012, Article ID 752643, 5 pages
doi:10.1155/2012/752643

Research Article

Adjuvant Bidirectional Chemotherapy Using an Intraperitoneal Port

Paul H. Sugarbaker and Lana Bijelic

Program in Peritoneal Surface Malignancy, Washington Cancer Institute, Washington, DC 20010, USA

Correspondence should be addressed to Paul H. Sugarbaker, paul.sugarbaker@medstar.net

Received 16 April 2012; Accepted 10 June 2012

Academic Editor: Pompiliu Piso

Cytoreductive surgery (CRS) and hyperthermic intraperitoneal chemotherapy (HIPEC) have been established as treatment options for patients with peritoneal metastases or peritoneal mesothelioma. However, this novel treatment strategy remains associated with a large percentage of local-regional treatment failures. These treatment failures are attributed to the inadequacy of HIPEC to maintain a surgical complete response. Management strategies to supplement CRS and HIPEC are indicated. A simplified approach to the intraoperative placement of an intraperitoneal port for adjuvant bidirectional chemotherapy (ABC) was devised. Four different chemotherapy treatment plans were utilized depending upon the primary site of the malignancy. Thirty-one consecutive patients with an intraoperative placement of the intraperitoneal port were available for study. The incidence of adverse events that caused an early discontinuation of the bidirectional chemotherapy occurred in 75% of the 8 patients who had an incomplete cytoreduction and in 0% of patients who had a complete cytoreduction. All of the patients who had complete cytoreduction completed at least 5 of the scheduled 6 bidirectional chemotherapy treatments. Adjuvant bidirectional chemotherapy is possible following a major cytoreductive surgical procedure using a simplified method of intraoperative intraperitoneal port placement.

1. Introduction

Cancer chemotherapy can be given through a number of different routes of administration. Although intravenous delivery is most common, intraperitoneal, intrapleural, and intrathecal chemotherapy infusions have been utilized with good results. Also, intra-arterial perfusion of chemotherapy has been reported as successful by several groups. The low incidence of complications with simple intravenous drug delivery most likely accounts for its more common utilization. However, in some specific situations, intraperitoneal drug delivery, or intraperitoneal drug delivery combined with intravenous drug delivery have been definitely shown to improve outcome. In patients with ovarian cancer, three prospective and randomized studies with combined intraperitoneal and intravenous chemotherapy compared to only intravenous chemotherapy have consistently shown an improvement in long-term survival with the local-regional approach [1–3]. In patients with ovarian cancer that was resected so that all tumor masses greater than 2 cm were removed, survival was significantly longer in 546 randomized patients in those who received intraperitoneal cisplatin as compared to intravenous cisplatin ($P = 0.02$). Also, moderate to severe nervous system toxicity was reduced with the intraperitoneal cisplatin [1].

Many oncologists acknowledge that disease control may be significantly improved when chemotherapy is administered through the intraperitoneal route [4]. However, they are aware that the complications of intraperitoneal chemotherapy administration are frequent and occasionally life endangering [5]. There are, of course, adverse events with the use of intravenous ports that are used in a large proportion of patients receiving systemic cancer chemotherapy. Nevertheless they are used as standard of care. In contrast, the difficulties that may occur with placement of an intraperitoneal port, the patient discomfort that frequently accompanies chemotherapy administration, and the serious life endangering complications sometimes requiring reoperation discourage its routine use [6].

Successful randomized trials testing combinations of intraperitoneal and intravenous chemotherapy for gastrointestinal peritoneal metastases and for peritoneal mesothelioma have not been performed to date. However, the rationale for such an approach is strong. In this paper, we describe a new and simplified method for placement of an intraperitoneal port following cytoreductive surgery and heated intraoperative intraperitoneal chemotherapy. Our clinical experience with 31 consecutive patients having adjuvant bidirectional chemotherapy for peritoneal mesothelioma or gastrointestinal carcinomatosis from a variety of primary sites is reported.

2. Materials and Methods

All patients in this retrospective paper had peritoneal metastases documented within the abdomen and pelvis. They underwent cytoreductive surgery with an attempt to clear all of the malignancy from the abdomen. Following this, they were treated with a perioperative chemotherapy treatment using heated intraperitoneal or a combination of heated intraperitoneal and intravenous chemotherapy.

2.1. Preparation for Intraperitoneal Port Placement. Following completion of the cytoreductive surgery and hyperthermic intraperitoneal chemotherapy, the abdomen and pelvis were again widely exposed. All intestinal reconstruction was completed. The abdomen was irrigated with 4 liters of a warm saline (37°C) solution. The irrigation solution contained the antibiotics neomycin and polymyxin B (XGen Pharmaceuticals, Big Flats, NY). The abdominal skin was again cleansed with a povidone iodine solution.

2.2. Technique for Intraperitoneal Port Placement. An 8 cm incision was made at the lateral aspect of the left rectus muscle. This transverse incision was in line with the lowest aspect of the ribcage. It was continued through the subcutaneous tissue to the anterior rectus sheath. At the lateral aspect of the rectus muscle, the external oblique aponeurosis was incised.

From this incision, subcutaneous tunnel and pocket for an intraperitoneal port system were constructed (Port-A-Cath, Smiths Medical MD, Inc., St. Paul, MN, USA). The port was located superior to and directly over the superior portion of the left rectus muscle. Care should be taken not to enter the abdominal incision with the tunnel or port pocket (Figure 1).

Through the incision in the external oblique fascia, a tonsil clamp is positioned, moving from the peritoneal cavity to the subcutaneous space with the stab incision. The clamp guides the catheter tip into the midabdomen. The tip is directed toward the jejunal loops of the small bowel. The Dacron cuff is secured with a resorbable purse string suture to the external oblique aponeurosis.

The catheter is cut to an appropriate length and secured to the port. The port is advanced through the tunnel into its pocket. The port is secured manually in its proper position and accessed with a noncoring right angle needle (Port-A-Cath, Gripper Plus, Deltec, Inc., St. Paul, MN, USA). The port and tubing are flushed with saline solution by irrigating the noncoring needle. Following this, the needle is capped off with a male adapter. The plastic base of the right angle noncoring needle is secured at its four corners with a 2–0 nylon suture (Figure 2).

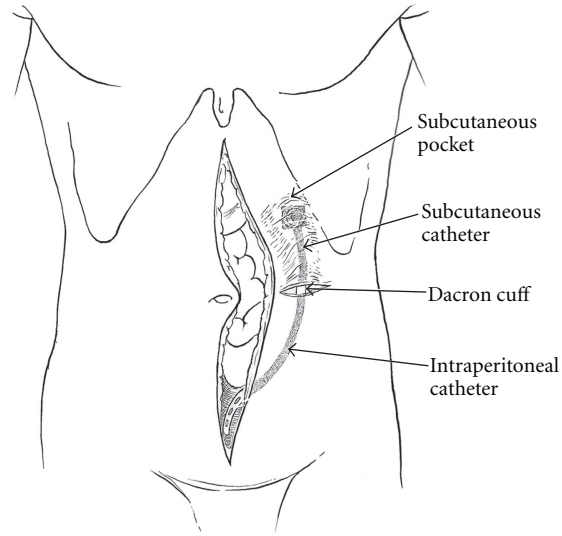

Figure 1: A lateral skin incision allows dissection of the port pocket and access to the abdomen using a stab incision.

The tunnel and incision are copiously irrigated with the antibiotic solution and hemostasis checked. Scarpa's fascia is closed over the Dacron cuff with a resorbable suture and the skin closed with interrupted nonabsorbable sutures. The noncoring needle is covered by an occlusive gauze dressing.

Liberal placement of Seprafilm (Genzyme Biosurgery, Framingham, MA) on abdominal and pelvic surfaces devoid of parietal peritoneum and between the loops of small bowel is recommended.

At this point, the abdominal incision is closed. The port access with the Huber needle is retained for 10 days to ensure proper position of the port for easy access for the adjuvant bidirectional chemotherapy (ABC) treatments.

2.3. Chemotherapy Regimens Utilized. Four different combined intraperitoneal and intravenous chemotherapy regimens were utilized for different diseases treated by the ABC method. For peritoneal mesothelioma, a combination of intraperitoneal pemetrexed with intravenous cisplatin was used. For appendiceal or colorectal malignancy, a combination of intraperitoneal 5-fluorouracil and systemic oxaliplatin was used. For ovarian cancer, a combination of intraperitoneal paclitaxel and systemic cisplatin was used. Finally, for the pancreas cancer patients, intraperitoneal gemcitabine was used. No intravenous chemotherapy was combined with the intraperitoneal gemcitabine (see Table 1).

The selection criteria for intraoperative placement of the intraperitoneal port was variable depending on the patient's diagnosis. All pancreas cancer patients during the study period had an intraperitoneal port placed if the R0 pancreaticoduodenectomy operation could be completed.

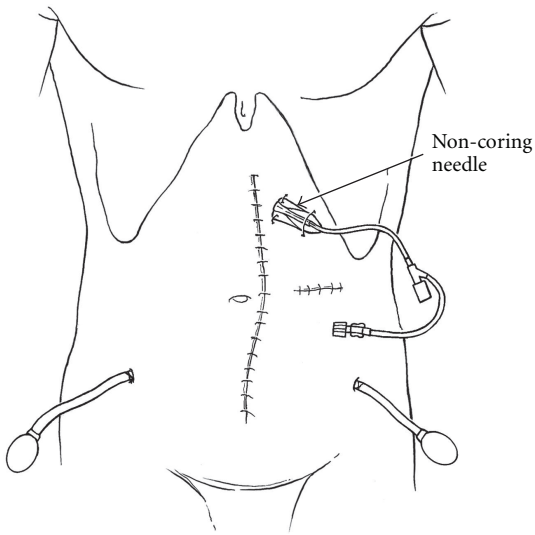

Figure 2: A noncoring needle is used to maintain optimal position of the port for 10 days.

All peritoneal mesothelioma patients had port placement if a complete or near complete cytoreduction was possible. The same was true with the three papillary serous malignancy patients. In patients with appendiceal adenocarcinoma, intraoperative port placement was utilized if systemic treatment options had been exhausted. The same was true with rectal cancer patients.

3. Results

There were 31 patients treated using an intraperitoneal port placed following the completion of cytoreductive surgery and hyperthermic intraperitoneal chemotherapy. Five patients had a diagnosis of appendiceal adenocarcinoma, 19 had peritoneal mesothelioma, 3 had pancreas cancer, 1 had rectal cancer, and 3 had papillary serous cancer. The median age on these patients was 49 with a range from 32 to 74. Twenty-three patients had complete or near complete (adequate) cytoreductive surgery prior to port placement. Eight patients had an incomplete cytoreduction.

Six major events occurred in eight patients (75%) who had incomplete cytoreduction. Four patients had disease progression, 1 patient had bowel perforation, and 1 patient had a port occlusion after 3 cycles which was not remedied and intraperitoneal treatments ceased. In these six patients, the adverse event resulted in a discontinuation of the ABC.

In the 23 patients who had complete or near complete cytoreduction, there were 6 events. One patient had systemic progression at cycle 3 and the combined intraperitoneal and intravenous chemotherapy, was discontinued. One patient developed methicillin-resistant Staphylococcus aureus infection of the port postoperatively. In these two patients (9%) the adverse event resulted in discontinuation of the ABC.

Four patients had events which did not significantly impede or disrupt their chemotherapy treatments, 1 patient had port occlusion after 5 cycles so that the final cycle of ABC was given systemically. One patient had a port occlusion successfully treated by laparoscopic intervention and successfully completed the ABC. One patient had an infected port which was removed; one cycle of pemetrexed and cisplatin chemotherapy was given intravenously and then the port replaced and the bidirectional treatment completed. One patient required hospitalization after ABC treatments on 3 occasions. His final cycle of pemetrexed and cisplatin was then given systemically. One patient had port infection when on second line intraperitoneal chemotherapy and her adverse event (peritonitis) was not included in these statistics.

Table 1: Clinical data on 31 consecutive patients given chemotherapy through a permanent intraperitoneal port placed prior to the closure of the abdomen.

Gender	
Male	16
Female	15
Age	
Median	49
Range	32–74
Diagnosis	
Peritoneal mesothelioma	19
Appendiceal adenocarcinoma	5
Papillary serous cancer	3
Pancreas cancer	3
Rectal cancer	1
Cytoreduction	
Complete or near complete (CC-0/CC-1)	23
Incomplete cytoreduction	8
% of patients completing 5 or more cycles of with adverse events requiring removal of intraperitoneal port	
Complete or near complete cytoreduction	9% (2/23)
Incomplete cytoreduction	75% (6/8)

4. Discussion

4.1. Developmental Plan for Adjuvant Bidirectional Chemotherapy. The ABC regimens used on these patients were designed from pharmacologic data obtained in chemotherapy agents known to show a response in the primary disease to be treated. Also, morbidity and mortality testing showed that the doses and schedules of drugs used were safe [7]. The effectiveness of these combined intraperitoneal and intravenous treatments has not been tested in a randomized study against their intravenous counterparts. This second important step in the development of the ABC approach has yet to be initiated.

4.2. Need for Complete Cytoreduction. By these early data, patient selection for ABC treatment is shown to be necessary. The clinical correlate most impressive was the impact of

completeness of cytoreduction on the likelihood of completing the prescribed chemotherapy. Seventy-five percent of those patients who had gross disease after cytoreduction (CC-3) did not complete their scheduled treatments. The most common reason for this was disease progression. A majority of patients with complete cytoreduction received at least 5 of their 6 treatments using bidirectional administration.

4.3. Advantages of Intraoperative versus Delayed Intraperitoneal Port Placement. There may be advantages of intraoperative placement of the peritoneal port. A major advantage concerns placement of the port directly between jejunal bowel loops. This precise anatomic placement is difficult and usually impossible with a postoperative port placement. Secondly, it is much more acceptable to patients in that it does not require another operative intervention. Also, there may be bowel perforation with a delayed placement of the intraperitoneal port. This serious problem is avoided.

4.4. Precautions to Prevent Infection. A possible disadvantage of intraoperative placement of an intraperitoneal port reported in the literature is a higher infection rate. We have combated this by large volume irrigation of the abdominal space with an antibiotic solution following cytoreductive surgery. Also, not only is the abdomen cleansed with a large volume of irrigation but the skin is reprepared with povidone iodine before the catheter is brought onto the operative field.

4.5. Prolonged Port Stabilization with a Non-Coring Needle after Placement in Its Pocket. Needle access to the port is maintained over ten days in order to allow fixation of the port within its tunnel. No non-absorbable sutures are used at the four corners of the port in order to stabilize it within the pocket. This eliminates the need for an incision close to the port for placement of nonabsorbable sutures at each corner. The port stabilization by a non-coring needle has not caused us any problems with infection. Of course, this also facilitates removal of the port at a later time.

4.6. Position of Port in Left Subcostal Space. Our technique is considerably different in terms of the anatomic placement of the port than other techniques. The port is placed in the subcostal space in the upper left portion of the abdomen. The base of the port is stabilized by the anterior rectus sheath and flexion of the rectus muscle by the patients gives a solid base for access with the non-coring needle. Making a long tunnel up to the ribcage is unnecessary. Also, this long tunnel and port placement on the chest wall is uncomfortable for patients.

4.7. Factors That May Impact on Satisfactory Port Function. In these data, the only clinical feature that had an impact on satisfactory port function was the completeness of cytoreduction. Undoubtedly, there are other factors which, in a larger study, will be shown to influence the long-term function of the port. It is possible that more port or catheter infections will occur in those patients who have had a bowel anastomosis or some other potential contamination of the peritoneal space by enteric organisms. It is possible that the extent of peritonectomy, and therefore the extent of intra-abdominal adhesions, will be important in long-term function. In the patients in this study, all had very extensive cytoreduction and therefore data regarding the extent of cytoreduction was not available. It is possible that the use of adhesion-prevention agents may be important. For example, the liberal use of Seprafilm to cover peritonectomy sites may be advisable. Also, Seprafilm can be used between the loops of small bowel and its mesentery. Alternatively, the use of early postoperative intraperitoneal 5-fluorouracil or paclitaxel may reduce the extent of abdominal and pelvic adhesions and thereby facilitate more adequate long-term port function [8]. Finally, in this study we only gathered data on those patients who had an intraoperative placement of the intraperitoneal port. Whether this placement is best performed in the operating room with the cytoreductive intervention or later on following full recovery from surgery has yet to be determined.

4.8. A Unique Phase II Study. In a survey of the literature regarding the use of an intraperitoneal port, no prior data regarding port placement after CRS and HIPEC was found. This is the first phase II study that attempts to prospectively gather clinical information on port insertion along with the definitive cytoreductive intervention. ABC is feasible using this methodology, and it was thought to be acceptable to patients with a small inconvenience. Trials to test ABC versus traditional systemic chemotherapy may now be appropriate.

4.9. Advantages of Combined Intraperitoneal and Intravenous (Bidirectional) Treatments. Theoretically, it would be possible to administer all of the chemotherapy agents presented in Table 2 by the intraperitoneal route as opposed a bidirectional treatment as proposed in this review. We did not mix drugs for simultaneous two-drug infusions for several reasons. First of all, there are issues with drug incompatibility. For example, 5-fluorouracil cannot be mixed with other drugs because of problems with precipitation. Also, the safety of two drugs simultaneously administered into the peritoneal cavity has not been previously explored. Phase I protocols to test the safety of two drugs administered simultaneously into the peritoneal cavity would be necessary. Perhaps most importantly, pharmacologic data suggests that drugs administered intravenously with an artificial ascites will target the peritoneal surfaces [9]. Van der Speeten and colleagues showed that patients who received intravenous 5-FU along with a volume of intraperitoneal fluid maintained a higher level of 5-FU in the peritoneal space as compared to the intravenous drug levels over a prolonged time period. The area under the curve ratio of peritoneal fluid to plasma was 2.3. These data suggest that intravenous drugs can be targeted to the peritoneal surface if administered simultaneously with a large volume of intraperitoneal chemotherapy solution.

Table 2: Four different combined intraperitoneal and intravenous chemotherapy (bidirectional) treatment options.

Disease	Combined intraperitoneal and intravenous chemotherapy treatment option
Peritoneal mesothelioma	Pemetrexed (500 mg/m^2) in 1000 mL 1.5% dextrose peritoneal dialysis solution as a 60-minute rapid infusion through the intraperitoneal port. Cisplatin (75 mg/m^2) in 250 mg of normal saline is given over 120 minutes immediately following the pemetrexed infusion.
Adenocarcinoma	5-fluorouracil (600 mg/m^2) in 1000 mL 1.5% dextrose peritoneal dialysis solution through the intraperitoneal port with the administration as rapid as possible. After the intraperitoneal chemotherapy infusion is complete, oxaliplatin (130 mg/m^2) in 250 mL of dextrose in water is given as a 2-hour intravenous infusion.
Pancreas cancer	Gemcitabine (1000 mg/m^2) in 1000 mL 1.5% dextrose peritoneal dialysis solution through the intraperitoneal port as rapid as possible is given on days 1, 8, and 15 of a 4-week cycle.
Papillary serous and ovarian cancer	Paclitaxel (20 mg/m^2) in 1000 mL 6% Hetastarch through the intraperitoneal port. Intravenous cisplatin (75 mg/m^2) is given after the paclitaxel infusion is complete over 120 minutes.

References

[1] D. S. Alberts, P. Y. Liu, E. V. Hannigan et al., "Intraperitoneal cisplatin plus intravenous cyclophosphamide versus intravenous cisplatin plus intravenous cyclophosphamide for stage III ovarian cancer," *The New England Journal of Medicine*, vol. 335, no. 26, pp. 1950–1955, 1996.

[2] M. Markman, B. N. Bundy, D. S. Alberts et al., "Phase III trial of standard-dose intravenous cisplatin plus paclitaxel versus moderately high-dose carboplatin followed by intravenous paclitaxel and intraperitoneal cisplatin in small-volume stage III ovarian carcinoma: an intergroup study of the Gynecologic Oncology Group, Southwestern Oncology Group, and Eastern Cooperative Oncology Group," *Journal of Clinical Oncology*, vol. 19, no. 4, pp. 1001–1007, 2001.

[3] D. K. Armstrong, B. Bundy, L. Wenzel et al., "Intraperitoneal cisplatin and paclitaxel in ovarian cancer," *The New England Journal of Medicine*, vol. 354, no. 1, pp. 34–43, 2006.

[4] E. L. Trimble, S. Thompson, M. C. Christian, and L. Minasian, "Intraperitoneal chemotherapy for women with epithelial ovarian cancer," *The Oncologist*, vol. 13, no. 4, pp. 403–409, 2008.

[5] J. L. Walker, D. K. Armstrong, H. Q. Huang et al., "Intraperitoneal catheter outcomes in a phase III trial of intravenous versus intraperitoneal chemotherapy in optimal stage III ovarian and primary peritoneal cancer: a Gynecologic Oncology Group Study," *Gynecologic Oncology*, vol. 100, no. 1, pp. 27–32, 2006.

[6] I. Vergote, F. Amant, K. Leunen et al., "Intraperitoneal chemotherapy in patients with advanced ovarian cancer: the con view," *The Oncologist*, vol. 13, no. 4, pp. 410–414, 2008.

[7] K. Van der Speeten, O. A. Stuart, and P. H. Sugarbaker, "Using pharmacologic data to plan clinical treatments for patients with peritoneal surface malignancy," *Current Drug Discovery Technologies*, vol. 6, no. 1, pp. 72–81, 2009.

[8] P. Jacquet and P. H. Sugarbaker, "Effects of postoperative intraperitoneal chemotherapy on peritoneal wound healing and adhesion formation," in *Peritoneal Carcinomatosis: Principles of Management*, P. H. Sugarbaker, Ed., pp. 327–333, Kluwer Academic, Boston, Mass, USA, 1996.

[9] K. Van der Speeten, O. A. Stuart, H. Mahteme, and P. H. Sugarbaker, "Pharmacology of perioperative 5-fluorouracil," *Journal of Surgical Oncology*, vol. 102, no. 7, pp. 730–735, 2010.

Hindawi Publishing Corporation
Gastroenterology Research and Practice
Volume 2012, Article ID 541842, 12 pages
doi:10.1155/2012/541842

Review Article

Diagnosis and Management of Peritoneal Metastases from Ovarian Cancer

Evgenia Halkia,[1] John Spiliotis,[2] and Paul Sugarbaker[3]

[1] *Department of Gynecology, Metaxa Cancer Memorial Hospital, 18537 Piraeus, Greece*
[2] *1st Department of Surgical Oncology, Metaxa Cancer Memorial Hospital, 18537 Piraeus, Greece*
[3] *Washington Cancer Institute, Program in Peritoneal Surface Malignancy, Washington, DC 20010, USA*

Correspondence should be addressed to Paul Sugarbaker, paul.sugarbaker@medstar.net

Received 29 March 2012; Accepted 12 May 2012

Academic Editor: Yan Li

The management and the outcome of peritoneal metastases or recurrence from epithelial ovarian cancer are presented. The biology and the diagnostic tools of EOC peritoneal metastasis with a comprehensive approach and the most recent literatures data are discussed. The definition and the role of surgery and chemotherapy are presented in order to focuse on the controversial points. Finally, the paper discusses the new data about the introduction of cytoreductive surgery and hyperthermic intraperitoneal chemotherapy (HIPEC) in the treatment of advanced epithelial ovarian cancer.

1. Introduction

Epithelial ovarian cancer (EOC) affects over 210,000 women and causes 128,000 deaths annually worldwide [1]. This cancer remains the leading cause of death from gynecology malignancy in the USA and was responsible for 14,600 deaths in 2009 [2]. The annual incidence and mortality rates have dropped 1.6% and 0.3% per year on average for the years 1997–2006 [3]. Current standard treatment of EOC is cytoreductive surgery (CRS) in order to remove the primary tumor and debulk any metastatic disease in combination with systemic chemotherapy with paclitaxel and platinum-based agents (carboplatin or cisplatin).

Despite this treatment, only 46–49% of women with EOC will survive 5 years [4, 5]. While the incidence is low before the menopause, it rises after that with a median age at the time of diagnosis of 63 years. The lifetime risk of ovarian cancer is 1 in 70, but there are women with much higher risk especially those with germ line mutations of $BRCA_1$ and $BRCA_2$ tumor suppressor genes [6, 7].

If there is a response to systemic chemotherapy, the disease often relapses within 12 to 18 months. The pattern of treatment failure is mostly local-regional, involving only the peritoneum and adjacent intra-abdominal organs. With this natural history, EOC patients may be candidates for local-regional in addition to systemic chemotherapy treatment [8].

2. Biology of Peritoneal Metastasis from Ovarian Cancer

Malignancies that are managed as EOC may have as a primary site the epithelium of the ovary, the peritoneum itself (primary peritoneal adenocarcinoma), or the fallopian tube. They are histologically and clinically similar and are treated in the same fashion [9]. In this paper they are grouped together as EOC.

EOC frequently spreads by direct extension from the primary site tumor to neighboring organs such as bladder and large bowel. Also, exfoliated tumor cells detach from the primary tumor and are transported throughout the peritoneal space by peritoneal fluid and disseminate within the abdominal cavity. Extensive seedy of the peritoneal cavity by tumor cells is often associated with ascites, particularly in advanced high-grade serous carcinomas. Usually patients with EOC have peritoneal deposits in the pelvis with contiguous extension to, or encasement of, the internal genitalia organs (uterus, fallopian tube, ovaries) and the rectosigmoid colon. Unlike other gynecologic cancers, EOC rarely disseminates through the bloodstream. However pelvic and/or para-aortic lymph nodes can be involved [10, 11]. The greater omentum has a large phagocytic capacity for cancer cells so that this organ is almost always infiltrated by the tumor [12].

2.1. Exfoliation of Epithelial Ovarian Cancer Peritoneal Metastases. The biological behavior of the EOC is markedly different from the well-studied pattern of hematogenous metastasis found in most other cancers. The progression of metastases onto peritoneal surfaces appears to be very direct for ovarian cancer [12, 13]. After cancer cells have been detached from the primary cancer as single cells or clusters of cancer cells, they metastasize through a passive mechanism carried by the physiological movement of peritoneal fluid to peritoneal surfaces and omentum.

An important molecule that helps the ovarian cells detach is *E-cadherin*, a membrane glycoprotein located within cell junctions [14]. In EOC peritoneal metastases, the E-cadherin expression of the ovarian cancer cells within peritoneal fluid is lower than in the primary tumor. This observation suggests that cells with low E-cadherin expression are more invasive and the absence of E-cadherin expression in ovarian peritoneal carcinomatosis predicts poor patient survival [15].

2.2. Epithelial Ovarian Cancer in Peritoneal Fluid. After the cancer cells detach, they float in the peritoneal fluid as single cells or as multicellular spheroids. Within the spheroids the cancer cells maintain a epithelial phenotype and express Sip 1, a regulator of E-cadherin and matrix metalloproteinase (MMP-2) [16]. In this phase, integrins (a_5b_1) and its ligands, fibronectin, are present on the surface of the cancer cells and play with other integrins (a_6B_1 and a_2B_1) an important role in spheroid growth and attachment. These molecules modify the microenvironment of ovarian peritoneal metastasis while in ascites fluid. This microenvironment provides the ovarian cells and spheroids the cell surface receptors to adhere to the peritoneal or omentum surfaces [17].

Proteolytic activity is also very important during this journey of ovarian cells. Matrix metalloproteases as MMP-14 or MMP-2 possibly promotes the fast disaggregation of the spheroids to augment adhesion to the peritoneal surface mesothelial cell layer.

2.3. Epithelial Ovarian Cancer Implantation. The organ distribution of ovarian carcinoma metastasis is not random. Initial implantation is on the fallopian tube and the contralateral ovary. Then the most common sites for distant metastasis are the omentum and the peritoneum. The peritoneum beneath the right diaphragm and the small bowel mesentery are preferentially colonized [18].

The mechanisms of cancer cell implantation are not yet well defined. Is it the primary ovarian tumor that prepares the omentum and peritoneum for successful colonization by secretion of factors? Are mobilized bone marrow cells recruited to prepare the metastatic site [12, 13]? Or is an interaction between the cancer cells and the mesothelial cells covering the basement membrane, which stimulates integrins, vascular adhesion molecules and CD44, the principal cell surface receptor for hyaluronic acid? As cancer cells adhere and invade, the mesothelium stimulates MMP2/9 to induce mesothelial cell apoptosis. This is promoted by secretion of Fas-ligand which then binds to a Fas receptor (CD 95) on mesothelial cells [19–21]. This process may be regulated by a protein, transglutaminase2, which is secreted in the ascites [22] and modulates the extracellular matrix of mesothelium.

2.4. Epithelial Ovarian Cancer Implant Progression. Little is known about progression of the ovarian cancer cells after implantation. The study of other cancers suggest that once the metastatic tumor reaches a certain size they require new blood vessels to provide nutrients for the growing tumor. In like manner for ovarian peritoneal metastases, the colony of ovarian cancer cells and spheroids attract new blood vessels to support their growth. A group of vascular endothelial growth factors (VEGFs) stimulate vascular and lymphatic endothelium to form new blood vessels to support their growth. These high levels of VEGFs in serum, ascites, and expression on ovarian carcinoma tissue have been associated with ovarian tumor progression and poor prognosis [23]. Recent studies with microarray demonstrate that the metastatic process in ovarian peritoneal metastasis require genetic changes present in the primary tumor [24].

3. Staging and Symptoms of Ovarian Peritoneal Metastases

3.1. Staging. Disease progression is described for all three types of ovarian cancer by both the TNM and FIGO staging systems [25, 26]. The stages associated with peritoneal metastases are FIGO III, which includes disease that has spread from the ovaries with visible peritoneal implants outside the pelvis (III_b) and retroperitoneal lymph node involvement (III_c). Stages III_b and III_c according to FIGO nomenclature represent 60% of cases of EOC [27]. For a description of the distribution and extent of metastases, one employs the peritoneal cancer Index (PCI) reported by Jacquet and Sugarbaker [28]. This index is a quantitative assessment of both cancer distribution and cancer implants size throughout the abdomen and the pelvis. Two components are involved in its calculation. One component is the distribution of the tumor in the abdominopelvic regions and the other is lesion size score (Figure 1).

4. Symptoms

The symptoms of peritoneal progression from EOC are often nonspecific and frequently caused by advance disease. Symptoms present are pelvic or abdominal pain, bloating, indigestion, abdominal distention, early satiety, and pain with intercourse. There is a symptom index in order to identifying women at risk to peritoneal carcinomatosis [29, 30]. It is not known if ascites is usually present when tumor cells initially metastasize or if ascites is a sign of a more advanced high volume disease. A combination of factors can contribute to ascites formation in ovarian cancer. Cancer cells can obstruct subperitoneal lymphatic channels and prevent the absorption of the physiologically produced peritoneal fluid. In addition, secretion of VEGF by ovarian cancer cells increases the vascular permeability and promotes the ascites formation [31, 32].

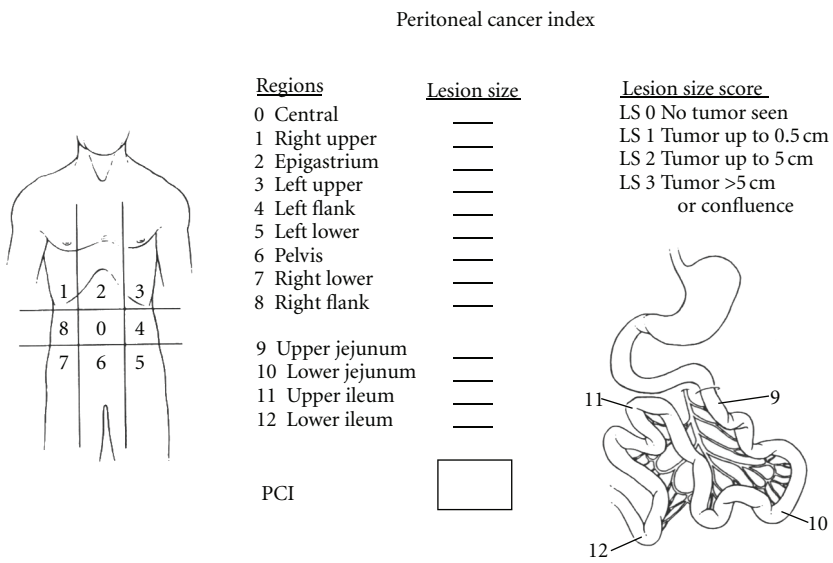

Figure 1: Peritoneal cancer index.

5. Diagnosis of Peritoneal Metastases from Ovarian Cancer

The aim of the preoperative diagnostic assessment in patients with EOC is to estimate as accurately as possible the extent and anatomic location of disease.

5.1. Tumor Markers. While CA-125 (and other markers) are elevated in most patients with advanced disease, it is not specific for peritoneal carcinomatosis from EOC. CA-125 may be elevated in many other conditions. Also in the presence of ovarian cancer, CA-125 does not distinguish between localized or diffuse peritoneal disease [33–35]. Recent studies analyzed the serum cathepsin L (CL), heparane (Hpa) and MMg, and serum survivin for determining the degree of ovarian invasion and peritoneal metastases before surgery. The elevated levels of all of these are correlated with invasion and progression in ovarian cancer [36, 37]. Serial measurements of CA-125 are useful for monitoring for recurrent or metastatic disease provided that it was elevated prior to treatment and normalized during treatment.

5.2. Ultrasound. Ultrasound is a useful tool for the initial diagnosis in ovarian cancer. For determining the extent of peritoneal metastases, it is less accurate. It can detect ascites and splenic and liver metastasis, but it does not image peritoneal nodules accurately enough to evaluate the extent of the disease [35].

5.3. CT Scan. The role of CT in the preoperative evaluation of patients with ovarian cancer is controversial. Also the role of CT imaging in recurrent or peritoneal dissemination from ovarian cancer has received little attention and has not been clarified. The potential role of CT imaging to identify nonresectable disease in primary ovarian cancer has been shown [38]. However, the precise role for cross-sectional imaging has not been identified in the planning, monitoring of treatment response, or in assessment of chemotherapy-refractory or recurrent ovarian cancer. Recent studies attempt to correlate the CT findings with surgical outcome and PCI index to assist in identification of tumor respectability. CT scan seems to be helpful in patients with solitary site as the cause of bowel obstruction. On the other hand, successful treatment or palliation is still feasible in the presence of peritoneal metastases identified on CT scan. This finding alone should not be the reason to avoid surgery in well-selected patients [39]. Recently, the evaluation of multidetector CT (MDCT) in identifying peritoneal deposits preoperatively demonstrates that this procedure is useful in the assessment of the disease at specific locations in the abdomen and pelvis (pouch of Douglas and right subdiaphragmatic area) [40].

5.4. Magnetic Resonance Imaging. Magnetic resonance imaging (MRI) is becoming increasingly important in the diagnostic work up of EOC. MRI has demonstrated value in the evaluation of patients with advance disease. Some studies have shown that higher sensitivity may be achieved with oral contrast agents used for detection of peritoneal or omental dissemination [41]. Efforts in recent years have been focused on the design of systemic MRI contrast agents, which either target biomarkers or take advantage of the different physiology of cancerous cells.

Diffusion-weighted imaging of peritoneal metastases of ovarian cancer is a functional MRI technique that exploits the restricted water mobility within hypercellular tumors to increase the contrast between these lesions and surrounding tissue [42]. Some groups suggest that this technology improves the detection and delineation of peritoneal implants at both initial staging and followup.

5.5. Positron Emission Tomography. Positron Emission Tomography (PET) imaging evaluates the biochemical and physiological characteristics of tumor cells, generating a

Table 1: Indications for surgery in ovarian cancer.

(i) Diagnostic laparotomy or laparoscopy	Exploration performed at any time in the course of ovarian cancer to obtain a histological diagnosis. *A second-look surgery* is performed in patients who are clinically, biochemically, and radiologically free of disease after completion of chemotherapy with the purpose to confirm the response status.
(ii) Staging laparotomy	Surgery performed in patients with clinically early ovarian cancer aiming at the detection of tumor spread.
(iii) Primary cytoreductive surgery	Surgery with the aim of complete resection of all macroscopic tumor in patients with first diagnosis of advanced ovarian cancer before any other treatment (e.g., chemotherapy).
(iv) Secondary surgery/Interval debulking	Surgery performed in patients usually after 3 cycles of chemotherapy, with an attempt to remove any remaining tumor, which has not been eradicated by chemotherapy.
(v) Surgery for progressive ovarian cancer	Surgery with the purpose of removing obviously resistant tumors, which have not responded to chemotherapy and progressed during primary chemotherapy.
(vi) Surgery for recurrent ovarian cancer	Surgery aiming for complete resection for all macroscopic tumor in patients with recurrent ovarian cancer after completion of primary therapy including a subsequent period without any signs of disease.
(vii) Palliative surgery	Surgery performed in patients with symptoms caused by progressive disease or sequelae aiming to relieve symptoms and not towards survival prolongation.

radiographic picture of metabolic activity from the cancer nodule that is not possible with other imaging methods as CT or MRI.

Increased accuracy of PET-CT on peritoneal metastases from ovarian cancer or the recurrence of ovarian cancer is apparent [43]. A recent report from Australia demonstrates that PET-CT scan [44]

(a) alters management in almost 60% of patients with peritoneal carcinomatosis from ovarian cancer,

(b) detects more sites of diseases than abdominal and pelvic CT,

(c) provides superior detection of nodal peritoneal and subcapsular liver disease,

(d) offers the opportunity for technology replacement in this setting.

When one compares contrast-enhanced CT, and PET-CT, there is a similar accuracy in detection of recurrent ovarian cancer [45].

6. Surgical Management of Peritoneal Metastases from Epithelial Ovarian Cancer

Cytoreductive surgery (CRS) may be considered for EOC is at the time of initial treatment (frontline) following neoadjuvant chemotherapy (interval debulking), and with recurrence [46, 47]. It has been established that improved survival following surgery is associated with minimal-volume residual disease. In Table 1, we list the possible indications and time points for surgical intervention in ovarian cancer [48].

In the past, CRS with residual cancerous lesions >1 cm or <2 cm in greatest dimension was considered "optimal." However, the precise definition of optimal or complete cytoreduction has been open to wide differences of opinion and has changed considerably over time. Optimal cytoreduction definitely improves the survival and requires peritonectomy procedures and visceral resections depending on the extent of peritoneal metastases [49–51]. After finishing the CRS, it is important to determine the completeness of cytoreduction score (CCs).

CC-0 indicates no visible residual tumor.

CC-1 indicates residual nodules <2.5 mm.

CC-2 indicates residual nodules >2.5 mm and <2.5 cm.

CC-3 indicates residual nodules >2.5 cm.

This score proposed by Sugarbaker and Chang has been accepted worldwide by the teams of peritoneal surface malignancy treatment groups [52].

6.1. Optimal Debulking. The phrase "optimal debulking" has been introduced for primary CRS. Retrospective studies reported a threshold of ≤1 cm of residual tumor as cut-off for inclusion criteria as complete cytoreduction [53, 54]. Nowadays, the definition of complete CRS has changed to indicate complete resection of all visible tumor, and the Gynecologic Cancer Interstudy Group (GCIG) has changed the official nomenclature to indicate this [55]. However, the concept of "optimal debulking" has not been established in CRS for recurrent disease.

The incidence of patients with complete cytoreduction as defined above (CC score of 0 or 1) varied between 9 and 82% in a systematic review comprising retrospective studies with more than 20 patients [56] and between 9 and 100% in a meta-analysis published in 2009 [57]. Series including >100 patients with cytoreductive surgery for recurrent or peritoneal relapse showed controversial finding concerning the impact of the complete cytoreduction on survival. Some studies [56, 58, 59] reported a significant survival benefit only for patients with complete resection; others indicated a benefit also in patients with residual disease up to 0.5 cm or less than 1 cm [53, 60].

A recent meta-analysis of several studies for surgery in recurrent disease or peritoneal metastases found that obtaining complete cytoreduction in an additional 10% of patients increased median survival by 3.0 months [57]. The first goal of surgery should be optimal CRS. However, if complete resection is not possible, the surgery may be modified in order to minimize surgical morbidity and mortality.

6.2. Predictors for Complete Cytoreduction in Ovarian Peritoneal Metastases. It is difficult to establish selection criteria for surgical intervention in ovarian peritoneal metastases. CA-125 elevation was found to be a predictive factor and the rate of complete resection declines by approximately 3% per week, after first CA-125 elevation was noticed and no surgery was performed [61]. Multivariate analysis of four retrospective studies demonstrated that absence of preoperative salvage chemotherapy, good performance status, and size of recurrent disease less than 10 cm were predictors for complete cytoreduction [58]. Also the number of diseases sites (solitary versus multiple) was an independent factor for complete cytoreduction [62]. Complete cytoreduction is not possible if distant or unresectable metastases are present or if small bowel is extensively seeded [63].

The DESKTOP I trial conducted by the Arbeitsgemeinschaft Gynäkologische Onkologie (AGO) identified a combination of predictive parameters for complete resection: good performance status (ECOG), no residual disease after surgery for primary ovarian tumor or alternatively early initial FIGO stage, and absence of ascites by radiologic studies. Complete resection was achieved in 79% of patients scoring all these factors. If not all factors were positive, a complete resection was achieved in only 43% [64]. The latter group could be further differentiated: complete resection was achieved in 74% of this subgroup, if there were no peritoneal metastases found intraoperatively otherwise only 26% could be completely resected [65].

In the DESKTOP II trial, the "AGO score" was validated in a prospective multicenter study. In 512 patients with primary disease, there were 261 patients (51%) with good performance status, complete resection at primary surgery, and absence of ascites and were defined as a positive "AGO score." From these, 129 (49.4%) had a first relapse and underwent surgery for recurrent disease. These patients with a positive "AGO score" had a complete resection rate of 76% [66]. In conclusion, the "AGO score" may help to identify patients in whom complete resection of relapsed ovarian cancer is most likely.

6.3. Prognostic Factors Associated with Prolonged Survival in Patients Who Received Surgery in Recurrent or Advanced Ovarian Cancer. Many series reported a relationship between survival and surgical outcome. Complete cytoreduction was the strongest predictors for survival in all multivariate analyses performed. All other analyzed factors provided controversial results. Treatment-free interval between initial treatment and cytoreductive surgery showed no significant impact on outcome in univariate analysis in 50% of the series but others reported a significant role [56].

The DESKTOP I trial showed a benefit for treatment-free interval exceeding 6 months but no differences if the interval was longer than 6 months. The same applies to the series of Chi et al., [67]. A similar observation was reported by Zang et al. who saw a benefit for longer progression-free intervals in univariate analysis, which could not be confirmed by multivariate analysis [60].

6.4. Lymph Node Metastases in Patients with Peritoneal Metastases from Ovarian Cancer. The presence of lymph node metastases in patients with advanced ovarian cancer or with peritoneal metastases indicates a poor prognosis. Its role in diagnosis is clear but its therapeutic role remains controversial, and the role for systematic removal of retroperitoneal lymph nodes as part of maximal cytoreduction is still unclear [68].

A recent study from Italy [69] showed that the addition of systematic lymphadenectomy to cytoreductive surgery prolonged progression-free survival, which, in turn, may have an important impact on the quality of life of patients with advance disease. However, systematic lymphadenectomy did not prolong overall survival. The superior assessment of node status in patients undergoing lymphadenectomy could help refine the prognosis of patients with advanced ovarian cancer.

7. Morbidity and Mortality in Cytoreductive Surgery for Peritoneal Metastasis from Ovarian Cancer

Postoperative morbidity and mortality rates are quite variable between institutions. Mean 30-day morbidity varies between 19.2% and 34% [57, 67, 70]. Complications rates in cytoreductive surgery for recurrent ovarian cancer are not significantly higher, compared to primary debulking surgery [71]. Mean 30-day mortality rate ranges between 0.7 and 2.8% for primary debulking surgery, while the mortality rate of surgery in recurrent disease range between 1.2 and 5.5% [57, 59, 66, 72].

7.1. Long-Term Systemic Plus Intraperitoneal Chemotherapy for Treatment of Primary Disease. Intraperitoneal chemotherapy (IP) is designed to improve the pharmacokinetic profile of chemotherapeutic agents and thereby deliver higher doses into the anatomic compartments that are at greatest risk for disease recurrence. The majority of IP chemotherapy solution stays within the peritoneal compartment, with limited deep tissue penetration; therefore, it

is indicated only for patients who have completed cytoreductive surgery in combination with IV chemotherapy as initial treatment with a significant benefit in overall survival 65.5 months in the IV + IP arm versus 49.7 months in the IV only arm [73]. Studies in recurrent ovarian cancer after secondary cytoreductive surgery are needed in order to identify the possible benefit of this strategy for recurrent disease. The German Association of Gynecologic Oncology (AGO) has now initiated a study in advanced ovarian cancer (LION), which compares the value of systematic lymph node dissection with no lymph node resection in patients without any visible tumor residuals (NCT00712218). Until these data are in fact available, patients with advanced ovarian cancer should be informed in detail about the pros and cons of systematic lymph node dissection.

8. Systemic Chemotherapy for Recurrent Disease

While increasing numbers of patients with ovarian cancer are experienced 5-year survival, 90% of suboptimally debulked patients and 70% of optimally debulked patients relapse 18 to 24 months following primary treatment [73, 74]. Traditionally patients with recurrent platinum-sensitive ovarian cancer, defined as a disease-free interval from completion of primary treatment of at least 6 months, have been retreated with platinum-based chemotherapy, often in combination with another cytostatic agent.

In ICON 4 study patients with recurrent disease were randomized to receive a platinum-based regimen with or without a taxane. In the taxane-containing arm, 90% received paclitaxel as a part of a doublet. Results demonstrated that patients in the taxane group experienced higher response rate, longer progression-free survival, and superior overall survival compared to those who received retreatment with single-agent platinum [75]. A major problem in retreatment is the cumulative toxicity from primary therapy.

Another study, AGO OVAR 2.5, compared single-agent carboplatin with the combination regimen of gemcitabine and carboplatin in recurrent disease. The study showed that double drug treatment experienced a higher response rate and a superior progression-free survival but not difference in overall survival and concluded that the doublet of gemcitabine and carboplatin was an acceptable regimen for recurrent disease [76]. Currently, the OCEANS trial is evaluating outcomes of previous doublet drugs in combination with bevacizumab [77].

As an alternative strategy, the CALYPSO trial randomized patients to receive either the doublet of pegylated liposomal doxorubicin (PLD) and carboplatin versus paclitaxel and carboplatin [78]. The study demonstrated an improvement in progression-free survival for the PLD/carboplatin arm (median 11.3 months versus 9.4 months, $P < 0.005$) with less marrow toxicity and carboplatin hypersensitivity reactions.

Whereas combination treatment with platinum doublet is frequently used for recurrent platinum-sensitive patients, single-agent treatment is currently the preferred approach for platinum-resistant patients or for platinum-sensitive patients who have a short time to recurrence, such as a 6- to 12-month disease-free interval [79]. Numerous agents are available that can be used as single-agent therapy—gemcitabine, PLD, topotecan, paclitaxel, docetaxel, oral etoposide, and hormonal agents. Also worthy of consideration is the patients anticipated tolerability and cumulative toxicity from the frontline therapy in making the individual treatment selection for recurrent disease.

9. Target Therapies for Recurrent Disease

Targeted therapeutic agents are currently analyzed in clinical trials to evaluate translational end points in order to select patients and monitoring therapeutic response.

9.1. Antiangiogenic Agents. Numerous protocols evaluating antiangiogenic agents in combination with cytotoxic chemotherapy for recurrent disease are currently open [80]. The use of bevacizumab in recurrent ovarian cancer has been explored with promising results and response rates up to 24% [81].

9.2. mTOR Inhibitors. Many mTOR inhibitors are in clinical trials. GOG 1701, a phase II study for recurrent/persistent ovarian cancers, evaluated the use of temsirolimus in recurrent ovarian cancer and primary peritoneal cancer. Results presented in 2010 suggested modest activity of weekly single-agent temsirolimus in persistent or recurrent disease, with 24.1% progression-free survival ≥6 months [82].

9.3. PARP Inhibitors. Inhibition of polyAdenosine diphosphate-ribose polymerase (PARP), a key enzyme in the repair of DNA, may lead to the accumulation of breaks in double-stranded DNA and cell death. A phase II study with these inhibitors demonstrated a clinical benefit in the 57.6% of patients with platinum-sensitive ovarian cancer as a treatment in recurrent disease [83].

9.4. Histone Deacetylase Inhibitors. A phase II study by the GOG (protocol 0126T) is examining the use of belinostat in combination with carboplatin among patients with recurrent or persistent platinum-resistant disease. Histone hypoacetylation has been associated with malignancy through the transcriptional silencing of tumor suppressor genes [84].

10. Hyperthermic Intraperitoneal Chemotherapy in Peritoneal Metastases from Epithelial Ovarian Cancer

The first report of the use of hyperthermic intraperitoneal chemotherapy (HIPEC) for EOC was in 1994 [85]. Since that time, there has been a large volume of published research evaluating this modality in conjunction with CRS. The published reports are mainly case series and early phase II studies. The patients are in variable stages of their disease with HIPEC used as frontline treatment, interval debulking treatment, or as adjuvant treatment in recurrent disease. Recently Spiliotis et al. [86] in a small phase III prospective

Table 2: Survival rates in HYPERO study. Adapted from [87].

Time-point HIPEC used	n	OS (m)	2 years %	5 years %
Overall	141	30.3	49.1	25.4
Frontline	26	41.7	57.0	33.3
Interval debulking	19	68.6	80.4	50.2
Consolidation	12	53.7	63.6	42.4
Recurrence	83	23.5	40.9	18.0

OS: overall survival.

trial evaluated the role of CRS and HIPEC plus systemic chemotherapy versus CRS plus systemic chemotherapy in women with recurrent EOC after initial debulking surgery and systemic chemotherapy. The median survival rate was 19.5 months versus 11.2 months ($P < 0.05$) and the three-year survival was 50% versus 18% in favor of the HIPEC group [86].

HYPER-O, an internet registry, collected and analyzed data from multiple centers to achieve an understanding of current practice and outcome [87]. In the initial report, 141 women were treated; as frontline ($n = 26$), as interval debulking ($n = 19$), for consolidation ($n = 12$), or for recurrence ($n = 83$). The median duration of HIPEC was 100 min (range 30–120), the average perfusion temperature was 38.5–43.6°C (median 41.9°C). The HIPEC drug was with platinum ($n = 72$), mitomycin ($n = 53$), or a combination ($n = 14$). The median overall survival was 30.3 m.

The results of HYPER-O study are presented in Table 2.

10.1. HIPEC as Frontline Treatment. The evolution of management of advanced EOC in the last decade has been characterized by the validation of intraperitoneal chemotherapy. A Cochrane meta-analysis of all randomized intraperitoneal versus intravenous trials showed a hazard ratio, 0.79 for disease-free survival and 0.79 for overall survival favoring in the intraperitoneal arms [88]. The use of HIPEC as frontline treatment is presented in several studies with small number of patients. The data suggests that with HIPEC 2-year overall survival and progression-free survival were not significantly different with those of cytoreductive surgery and systemic chemotherapy. Rufian et al. reported 19 patients with stage III cancer treated at the time of frontline surgery with paclitaxel for 60 minutes at 41–43°C [89]. The mean overall 3- and 5-year survival was 46 and 37%. In patients with complete cytoreduction, there was a median overall survival of 66 months. Similar results were demonstrated recently by Deraco and coworkers [90]. These results are comparable but do not exceed studies with maximal CRS followed by systemic chemotherapy in frontline treatment of EOC.

10.2. Use of HIPEC during Interval Cytoreduction. A major controversy concerns the optimal time-point in the natural history of EOC for the performance CRS + HIPEC [91]. Data suggests that maximal surgical effort, combined with systemic and intraperitoneal chemotherapy in the primary setting, represents indirect evidence that CRS + HIPEC could be tested as upfront treatment in the context of a phase III trial [92]. The use of CRS following the maximal response from neoadjuvant systemic chemotherapy is theoretically the most optimal time-point for HIPEC [92].

The numbers from different studies and especially from HYPERO are small and the data difficult to interpret. When one compares the survivals between patients when HIPEC used as frontline or used at the time of interval debulking following neo-adjuvant chemotherapy, there was no significant difference [87]. However, a large randomized study showed no difference in overall survival in women with stage IIIc and IV disease randomized to initial CRS then intravenous chemotherapy or neo-adjuvant chemotherapy followed by interval debulking surgery then further systemic chemotherapy [93]. Recently, Spiliotis et al. reported an ongoing trial of laparoscopic-assisted neoadjuvant HIPEC in patients with stage IIIc or IV ovarian cancer, in combination of systemic chemotherapy followed by interval debulking + HIPEC and then further systemic chemotherapy [94].

10.3. HIPEC in Recurrent EOC. Survival for patients with recurrent EOC, treated by chemotherapy alone, tends to be inferior to that reported for secondary CRS. The influence of secondary CRS without HIPEC on survival outcomes has been addressed in a substantial number of studies and has been recently systematically reviewed [95]. However, these were noncontrolled studies not strictly comparable since chemotherapy trials will include patients not suitable for traditional cytoreduction including patients with a high PCI. A consistent survival data comparing secondary CRS with chemotherapy is expected to be provided by the ongoing randomized trial AGO-OVAR OP4 [96].

Results from studies reporting median and mean overall survival and progression-free survival are given in Table 3 [86, 97–103]. These data suggest that HIPEC is an interesting and promising treatment in recurrent EOC when it is combined with complete cytoreduction. The numbers are small but interesting in that the 3-year and 5-year survivals were significantly better in the HIPEC group versus conventional treatment [101–103].

The prognostic factors, which can predict the survival outcome, define also the criteria for "optimal"-HIPEC in recurrent ovarian cancer [86, 104]. These are age, performance status, interval from initial treatment to recurrent, PCI, completeness of cytoreduction, presence of lymph nodes, and initial platinum response (Table 4).

10.4. HIPEC as Consolidation Treatment. Consolidation treatment is defined as additional treatment following a complete response to frontline therapy. Patients with initial stage III EOC were treated with HIPEC at second laparotomy compared with patients who had a complete response but did not receive HIPEC [105]. The 5-year survival rate was 66.1% with HIPEC versus 31.3% in the control group.

In another study of 51 patients with EOC underwent frontline surgery with CRS and systemic chemotherapy and a CC-0/CC-1 cytoreduction. Thirty-two underwent second-look laparotomy with HIPEC and the others 19 who refused second look were used as a control group. The median

Table 3: Cytoreductive surgery and hyperthermic intraperitoneal chemotherapy in recurrent epithelial ovarian cancer.

Author	Year	*N*	OS (months)		PFS (months)	
			Median	Mean	Median	Mean
Deraco et al. [97]	2001	27			21.8	
Zanon et al. [98]	2004	30	28.1			
Raspagliesi et al. [99]	2006	40		41.4		23.9
Helm et al. [100]	2007	18	31		10	
Di Giorgio et al. [101]	2008	25	22.5		15.5	
Fagotti et al. [102]	2009	25			10	
Carrabin et al. [103]	2010	8			10	
Spiliotis et al. [86]	2011	25	19.5		14.5	

OS: overall survival; PFS: progression-free survival.

Table 4: Prognostic-predictive factor for "optimal" HIPEC in recurrent EOC.

(i) Age < 65
(ii) Performance status >80
(iii) Interval from initial diagnosis >12 months
(iv) Peritoneal Cancer Index <20
(v) Completeness of Cytoreduction CC-0 or CC-1
(vi) Absence of retroperitoneal lymph nodes
(vii) Platinum-sensitive

survival was 64.4 months in HIPEC arm versus 46.4 months in control group [106]. A future project is to use HIPEC consolidation treatment in second-look laparoscopy in order to reduce the surgical morbidity.

10.5. Morbidity and Mortality of HIPEC. There is a question that arises when discussing the morbidity and mortality in this treatment. It is unclear whether increased morbidity and mortality is related to CRS or to HIPEC. The estimation of morbidity and mortality related to HIPEC delivery is complicated by the fact that the major surgery with visceral resections and peritonectomy procedures is itself associated with high morbidity. In a recent study by Fagotti et al., in recurrent ovarian cancer with CRS and HIPEC, the morbidity rate was 34.8% with no mortality. Ileus, anastomotic leakage, bleeding, wound infection, fistula formation, pleural effusion, and thrombocytopenia represented the commonest complications [107].

Postoperative bleeding is a serious complication especially if oxaliplatin is used for HIPEC. One study reported premature closure because of a 29% severe morbidity rate [108]. The rate of anastomotic leak in the absence of a diverting stoma remains unknown and range between 1.6% and 3% [109]. Spontaneous bowel perforation may reflect the effect of heated chemotherapy on bowel, which has been traumatized during the enterolysis.

Hematological complications due to HIPEC are common and are a drug-dependent complication. The morbidity and mortality in patients with EOC having CRS and HIPEC remains dependent upon the patient's age and performance status, the number and type of peritonectomy procedures, and the duration of HIPEC.

An important factor to reduce the morbidity and mortality in cytoreductive surgery and HIPEC is the importance of learning curve. The performance of at least 130 procedures is necessary to consider the physician an expert in cytoreduction using the Sugarbaker technique [110].

11. Conclusions

Peritoneal metastases in patients with EOC are a poor prognostic factor for survival. An optimal management strategy includes CC-0/CC-1 CRS, but the role of HIPEC in this disease remains level 4 [111]. Innovative clinical studies with sufficient data need to compare conventional treatment with and without HIPEC [111].

A problem in the evaluation of HIPEC for the treatment of ovarian cancer concerns the adequacy of the HIPEC chemotherapy regimen. In many instances mitomycin C alone has been used. In other HIPEC chemotherapy regimens, it has been moderate dose cisplatin combined with doxorubicin. To this point in time, no large phase II trials using bidirectional chemotherapy at maximum doses has been used. Also, HIPEC has not been combined with EPIC in order to maximize the perioperative use of paclitaxel. Paclitaxel is usually used as EPIC at moderate dose for 5 days postoperatively. Phase II trials with a more modern perioperative chemotherapy regimen that would have a higher response rate need to be performed. The perioperative chemotherapy must be effective enough to maintain the surgical complete response that can be achieved with an optimal cytoreduction using both peritonectomy and visceral resections.

In the future, understanding both genome structure variation and functional deregulation in cancer may predict which patients with EOC are candidates to develop peritoneal metastases and which patients will be benefitted by selected chemotherapy agents [112].

References

[1] American Cancer Society, "Cancer facts and figures," 2010, http://www.cancer.org/acs/.

[2] J. Liu and U. A. Matulonis, "New advances in ovarian cancer," *Oncology*, vol. 24, no. 8, pp. 691–698, 2010.

[3] M. J. Horner, L. A. G. Ries, M. Krapcho et al., *SEER Cancer Statistics Review 1975—2006*, Bethesda, Md, USA, 2010, http://seer.cancer.gov/csr/1975_2006/.

[4] A. P. Heintz, F. Odicino, and P. Maisonneuve, "Carcinoma of the ovary FIGO 6th annual report on the results of treatment in Gynecological cancer," *International Journal of Gynecology & Obstetrics*, supplement I, pp. 161–192, 2006.

[5] A. Jemal, R. Siegel, E. Ward, Y. Hao, J. Xu, and M. J. Thun, "Cancer statistics, 2009," *CA Cancer Journal for Clinicians*, vol. 59, no. 4, pp. 225–249, 2009.

[6] A. Gadducci, F. Landoni, E. Sartori et al., "Analysis of treatment failures and survival of patients with fallopian tube carcinoma: a Cooperation Task Force (CTF) study," *Gynecologic Oncology*, vol. 81, no. 2, pp. 150–159, 2001.

[7] F. A. Tavassoli, "Pathology and Genetics of tumors of the breast and Female genital organs," in *World Health Organization Classification of Tumors*, F. A. Tavassoli and P. Devilee, Eds., France IARC Press, Lyon, France, 2003.

[8] J. D. Spiliotis, "Peritoneal carcinomatosis cytoreductive surgery and HIPEC: a ray of hope for cure," *Hepato-Gastroenterology*, vol. 57, no. 102-103, pp. 1173–1177, 2010.

[9] R. S. Tuma, "Origin of ovarian cancer may have implications for screening," *Journal of the National Cancer Institute*, vol. 102, no. 1, pp. 11–13, 2010.

[10] S. M. Eisenkop and N. M. Spirtos, "The clinical significance of occult macroscopically positive retroperitoneal nodes in patients with epithelial ovarian cancer," *Gynecologic Oncology*, vol. 82, no. 1, pp. 143–149, 2001.

[11] AJCC, "Ovary and primary peritoneal carcinoma," in *AJCC Cancer Staging Handbook*, pp. 501–506, Spinger, 7th edition, 2009.

[12] E. Lengyel, "Ovarian cancer development and metastasis," *The American Journal of Pathology*, vol. 177, no. 3, pp. 1053–1064, 2010.

[13] G. P. Gupta and J. Massagué, "Cancer metastasis: building a framework," *Cell*, vol. 127, no. 4, pp. 679–695, 2006.

[14] M. A. Huber, N. Kraut, and H. Beug, "Molecular requirements for epithelial-mesenchymal transition during tumor progression," *Current Opinion in Cell Biology*, vol. 17, no. 5, pp. 548–558, 2005.

[15] S. Elloul, M. B. Elstrand, J. M. Nesland et al., "Snail, slug, and smad-interacting protein 1 as novel parameters of disease aggressiveness in metastatic ovarian and breast carcinoma," *Cancer*, vol. 103, no. 8, pp. 1631–1643, 2005.

[16] K. M. Burleson, L. K. Hansen, and A. P. N. Skubitz, "Ovarian carcinoma spheroids disaggregate on type I collagen and invade live human mesothelial cell monolayers," *Clinical and Experimental Metastasis*, vol. 21, no. 8, pp. 685–697, 2005.

[17] K. M. Burleson, R. C. Casey, K. M. Skubitz, S. E. Pambuccian, T. R. Oegema, and A. P. N. Skubitz, "Ovarian carcinoma ascites spheroids adhere to extracellular matrix components and mesothelial cell monolayers," *Gynecologic Oncology*, vol. 93, no. 1, pp. 170–181, 2004.

[18] J. Sehouli, F. Senyuva, C. Fotopoulou et al., "Intra-abdominal tumor dissemination pattern and surgical outcome in 214 patients with primary ovarian cancer," *Journal of Surgical Oncology*, vol. 99, no. 7, pp. 424–427, 2009.

[19] H. A. Kenny, S. Kaur, L. M. Coussens, and E. Lengyel, "The initial steps of ovarian cancer cell metastasis are mediated by MMP-2 cleavage of vitronectin and fibronectin," *Journal of Clinical Investigation*, vol. 118, no. 4, pp. 1367–1379, 2008.

[20] S. Kaur, H. A. Kenny, S. Jagadeeswaran et al., "β3-integrin expression on tumor cells inhibits tumor progression, reduces metastasis, and is associated with a favorable prognosis in patients with ovarian cancer," *The American Journal of Pathology*, vol. 175, no. 5, pp. 2184–2196, 2009.

[21] L. Chen, S. M. Park, A. V. Tumanov et al., "CD95 promotes tumour growth," *Nature*, vol. 465, no. 7297, pp. 492–496, 2010.

[22] Y. H. Jee, L. S. Mangala, J. Y. Fok et al., "Clinical and biological significance of tissue transglutaminase in ovarian carcinoma," *Cancer Research*, vol. 68, no. 14, pp. 5849–5858, 2008.

[23] N. Nishida, H. Yano, K. Komai, T. Nishida, T. Kamura, and M. Kojiro, "Vascular endothelial growth factor C and vascular endothelial growth factor receptor 2 are related closely to the prognosis of patients with ovarian carcinoma," *Cancer*, vol. 101, no. 6, pp. 1364–1374, 2004.

[24] L. Khalique, A. Ayhan, J. C. Whittaker et al., "The clonal evolution of metastases from primary serous epithelial ovarian cancers," *International Journal of Cancer*, vol. 124, no. 7, pp. 1579–1586, 2009.

[25] AJCC, "Fallopian tube Carcinoma," in *AJCC Cancer Staging Handbook*, pp. 501–506, Springer, New York, NY, USA, 2009.

[26] FIGO, "Current FIGO staging for cancer of the vagina, fallopian tube, ovary and gestational trophoblastic neoplasia," *International Journal of Gynecology & Obstetrics*, vol. 105, pp. 3–4, 2009.

[27] A. Heintz, F. Odicino, P. Maisonneuve et al., "Carcinoma of the ovary. FIGO 6th annual report of the results of treatment in Gynecological Cancer," *International Journal of Gynecology & Obstetrics*, vol. 95, supplement 1, pp. S161–S192, 2006.

[28] P. Jacquet and P. H. Sugarbaker, "Clinical research methodologies in diagnosis and staging of patients with peritoneal carcinomatosis," *Cancer Treatment and Research*, vol. 82, pp. 359–374, 1996.

[29] B. A. Goff, L. S. Mandel, C. W. Drescher et al., "Development of an ovarian cancer symptom index: possibilities for earlier detection," *Cancer*, vol. 109, no. 2, pp. 221–227, 2007.

[30] M. R. Andersen, B. A. Goff, K. A. Lowe et al., "Use of a Symptom Index, CA125, and HE4 to predict ovarian cancer," *Gynecologic Oncology*, vol. 116, no. 3, pp. 378–383, 2010.

[31] S. A. Cannistra, "Cancer of the ovary," *The New England Journal of Medicine*, vol. 351, no. 24, pp. 2519–2529, 2004.

[32] A. T. Byrne, L. Ross, J. Holash et al., "Vascular endothelial growth factor-trap decreases tumor burden, inhibits ascites, and causes dramatic vascular remodeling in an ovarian cancer model," *Clinical Cancer Research*, vol. 9, no. 15, pp. 5721–5728, 2003.

[33] E. J. Lee, S. H. Kim, Y. H. Kim, and H. J. Lee, "Is CA-125 an additional help to radiologic findings for differentiation borderline ovarian tumor from stage I carcinoma?" *Acta Radiologica*, vol. 52, no. 4, pp. 458–462, 2011.

[34] L. S. Bradford and J. O. Schorge, "CA125 screening after risk-reducing salpingo-oophorectomy: are the titers too high, or is it all just too much?" *Menopause*, vol. 18, no. 2, pp. 123–124, 2011.

[35] N. B. Rettenmaier, C. R. Rettenmaier, T. Wojciechowski et al., "The utility and cost of routine follow-up procedures in the surveillance of ovarian and primary peritoneal carcinoma: a 16-year institutional review," *British Journal of Cancer*, vol. 103, no. 11, pp. 1657–1662, 2010.

[36] W. Zhang, H. C. Yang, Q. Wang et al., "Clinical value of combined detection of serum matrix metalloproteinase-9 heparanose and cethepsin for determining ovarian cancer invasion and metastasis," *Anticancer Research*, vol. 31, no. 10, pp. 3423–3428, 2011.

[37] J. H. No, Y. T. Jeon, Y. B. Kim, and Y. S. Song, "Quantitative detection of serum survivin and its relationship with prognostic factors in ovarian cancer," *Gynecologic and Obstetric Investigation*, vol. 71, no. 2, pp. 136–140, 2011.

[38] S. A. Funt, H. Hricak, N. Abu-Rustum, M. Mazumdar, H. Felderman, and D. S. Chi, "Role of CT in the management of recurrent ovarian cancer," *American Journal of Roentgenology*, vol. 182, no. 2, pp. 393–398, 2004.

[39] J. A. Rauh-Hain, A. B. Olawaiye, E. G. Munro et al., "Role of computed tomography in the surgical management of patients with bowel obstruction secondary to recurrent ovarian carcinoma," *Annals of Surgical Oncology*, vol. 17, no. 3, pp. 853–860, 2010.

[40] S. H. Chandrashekhara, S. Thulkar, D. N. Srivastava et al., "Pre-operative evaluation of peritoneal deposits using multidetector computed tomography in ovarian cancer," *British Journal of Radiology*, vol. 84, no. 997, pp. 38–43, 2011.

[41] J. Klostergaard, K. Parga, and R. G. Raptis, "Current and future applications of magnetic resonance imaging (MRI) to breast and ovarian cancer patient management," *Puerto Rico Health Sciences Journal*, vol. 29, no. 3, pp. 223–231, 2010.

[42] S. Kyriazi, D. J. Collins, V. A. Morgan, S. L. Giles, and N. M. deSouza, "Diffusion-weighted imaging of peritoneal disease for noninvasive staging of advanced ovarian cancer," *Radiographics*, vol. 30, no. 5, pp. 1269–1285, 2010.

[43] F. V. Cookley, "Staging ovarian cancer: role of imaging," *Radiologic Clinics of North America*, vol. 40, no. 3, pp. 609–636, 2002.

[44] M. J. Fulham, J. Carter, A. Baldey, R. J. Hicks, J. E. Ramshaw, and M. Gibson, "The impact of PET-CT in suspected recurrent ovarian cancer: a prospective multi-centre study as part of the Australian PET Data Collection Project," *Gynecologic Oncology*, vol. 112, no. 3, pp. 462–468, 2009.

[45] E. Sala, M. Kataoka, N. Pandit-Taskar et al., "Recurrent ovarian cancer: use of contrast-enhanced CT and PET/CT to accurately localize tumor recurrence and to predict patients' survival," *Radiology*, vol. 257, no. 1, pp. 125–134, 2010.

[46] D. S. Chi, F. Musa, F. Dao et al., "An analysis of patients with bulky advanced stage ovarian, tubal and peritoneal carcinoma treated with primary debulking surgery (PDS) during an identical time period as the randomized EORTC-NCIC trial of PDS vs neo-adjuvant chemotherapy," *Gynecologic Oncology*, vol. 124, pp. 10–14, 2012.

[47] A. du Bois, M. Quinn, T. Thigpen et al., "2004 consensus statements on the management of ovarian cancer," *Annals of Oncology*, vol. 16, no. 8, pp. 7–12, 2005.

[48] P. Harter, F. Hilpert, S. Mahner, S. Kommoss, F. Heitz, and A. Du Bois, "Role of cytoreductive surgery in recurrent ovarian cancer," *Expert Review of Anticancer Therapy*, vol. 9, no. 7, pp. 917–922, 2009.

[49] P. H. Sugarbaker, "Peritonectomy procedures," *Cancer Treatment and Research*, vol. 134, pp. 247–264, 2007.

[50] J. Spiliotis, A. A. K. Tentes, A. Vaxevanidou et al., "Cytoreductive surgery and hyperthermic intraperitoneal chemotherapy in the management of peritoneal carcinomatosis. Preliminary results and cost from two centers in Greece," *Journal of B.U.ON*, vol. 13, no. 2, pp. 205–210, 2008.

[51] J. Spiliotis, A. Vaxevanidou, A. Datsis, A. Rogdakis, and S. Kekelos, "Peritoneal carcinomatosis: intra-operative and post-operative assessment of patients undergoing cytoreduction and HIPEC," *Hepato-Gastroenterology*, vol. 57, no. 102-103, pp. 1052–1059, 2010.

[52] P. H. Sugarbaker and D. Chang, "Results of treatment of 385 patients with peritoneal surface spread of appendiceal malignancy," *Annals of Surgical Oncology*, vol. 6, no. 8, pp. 727–731, 1999.

[53] A. du Bois, J. Herrstedt, A. C. Hardy-Bessard et al., "Phase III trial of carboplatin plus paclitaxel with or without gemcitabine in first-line treatment of epithelial ovarian cancer," *Journal of Clinical Oncology*, vol. 28, no. 27, pp. 4162–4169, 2010.

[54] R. F. Ozols, B. N. Bundy, B. E. Greer et al., "Phase III trial of carboplatin and paclitaxel compared with cisplatin and paclitaxel in patients with optimally resected stage III ovarian cancer: a Gynecologic Oncology Group study," *Journal of Clinical Oncology*, vol. 21, no. 17, pp. 3194–3200, 2003.

[55] A. du Bois, A. Reuss, E. Pujade-Lauraine, P. Harter, I. Ray-Coquard, and J. Pfisterer, "Role of surgical outcome as prognostic factor in advanced epithelial ovarian cancer: a combined exploratory analysis of 3 prospectively randomized phase 3 multicenter trials: by the arbeitsgemeinschaft gynaekologische onkologie studiengruppe ovarialkarzinom (AGO-OVAR) and the groupe d'Investigateurs nationaux pour les etudes des cancers de l'Ovaire (GINECO)," *Cancer*, vol. 115, no. 6, pp. 1234–1244, 2009.

[56] P. Harter and A. du Bois, "The role of surgery in ovarian cancer with special emphasis on cytoreductive surgery for recurrence," *Current Opinion in Oncology*, vol. 17, no. 5, pp. 505–514, 2005.

[57] R. E. Bristow, I. Puri, and D. S. Chi, "Cytoreductive surgery for recurrent ovarian cancer: a meta-analysis," *Gynecologic Oncology*, vol. 112, no. 1, pp. 265–274, 2009.

[58] S. M. Eisenkop, R. L. Friedman, and N. M. Spirtos, "The role of secondary cytoreductive surgery in the treatment of patients with recurrent epithelial ovarian carcinoma," *Cancer*, vol. 88, pp. 144–153, 2000.

[59] J. Sehouli, R. Richter, E. I. Braicu et al., "Role of secondary cytoreductive surgery in ovarian cancer relapse: who will benefit? A systematic analysis of 240 consecutive patients," *Journal of Surgical Oncology*, vol. 102, no. 6, pp. 656–662, 2010.

[60] R. Y. Zang, Z. Y. Zhang, Z. T. Li et al., "Effect of cytoreductive surgery on survival of patients with recurrent epithelial ovarian cancer," *Journal of Surgical Oncology*, vol. 75, pp. 24–30, 2000.

[61] N. D. Fleming, I. Cass, C. S. Walsh, B. Y. Karlan, and A. J. Li, "CA125 surveillance increases optimal resectability at secondary cytoreductive surgery for recurrent epithelial ovarian cancer," *Gynecologic Oncology*, vol. 121, no. 2, pp. 249–252, 2011.

[62] B. Gronlund, L. Lundvall, I. J. Christensen, J. B. Knudsen, and C. Høgdall, "Surgical cytoreduction in recurrent ovarian carcinoma in patients with complete response to paclitaxel-platinum," *European Journal of Surgical Oncology*, vol. 31, no. 1, pp. 67–73, 2005.

[63] A. A. K. Tentes, O. S. Korakianitis, S. Kakolyris et al., "Cytoreductive surgery and perioperative intraperitoneal chemotherapy in recurrent ovarian cancer," *Tumori*, vol. 96, no. 3, pp. 411–416, 2010.

[64] P. Harter, A. du Bois, M. Hahmann et al., "Surgery in recurrent ovarian cancer: the Arbeitsgemeinschaft Gynaekologische Onkologie (AGO) DESKTOP OVAR trial," *Annals of Surgical Oncology*, vol. 13, no. 12, pp. 1702–1710, 2006.

[65] P. Harter, M. Hahmann, H. J. Lueck et al., "Surgery for recurrent ovarian cancer: role of peritoneal carcinomatosis: exploratory analysis of the DESKTOP i trial about risk factors, surgical implications, and prognostic value of peritoneal carcinomatosis," *Annals of Surgical Oncology*, vol. 16, no. 5, pp. 1324–1330, 2009.

[66] P. Harter, J. Sehouli, A. Reuss et al., "Prospective validation study of a predictive score for operability of recurrent ovarian cancer: the multicenter intergroup study DESKTOP II," *International Journal of Gynecological Cancer*, vol. 21, no. 2, pp. 289–295, 2011.

[67] D. S. Chi, O. Zivanovic, K. L. Levinson et al., "The incidence of major complications after the performance of extensive upper abdominal surgical procedures during primary cytoreduction of advanced ovarian, tubal, and peritoneal carcinomas," *Gynecologic Oncology*, vol. 119, no. 1, pp. 38–42, 2010.

[68] C. Scarabelli, A. Gallo, A. Zarrelli, C. Visentin, and E. Campagnutta, "Systematic pelvic and para-aortic lymphadenectomy during cytoreductive surgery in advanced ovarian cancer: potential benefit on survival," *Gynecologic Oncology*, vol. 56, no. 3, pp. 328–337, 1995.

[69] P. B. Panici, A. Maggioni, N. Hacker et al., "Systematic aortic and pelvic lymphadenectomy versus resection of bulky nodes only in optimally debulked advanced ovarian cancer: a randomized clinical trial," *Journal of the National Cancer Institute*, vol. 97, no. 8, pp. 560–566, 2005.

[70] C. G. Gerestein, G. M. Nieuwenhuyzen-de Boer, M. J. Eijkemans, G. S. Kooi, and C. W. Burger, "Prediction of 30-day morbidity after primary cytoreductive surgery for advanced stage ovarian cancer," *European Journal of Cancer*, vol. 46, no. 1, pp. 102–109, 2010.

[71] L. Woelber, S. Jung, C. Eulenburg et al., "Perioperative morbidity and outcome of secondary cytoreduction for recurrent epithelial ovarian cancer," *European Journal of Surgical Oncology*, vol. 36, no. 6, pp. 583–588, 2010.

[72] C. G. Gerestein, R. A. M. Damhuis, C. W. Burger, and G. S. Kooi, "Postoperative mortality after primary cytoreductive surgery for advanced stage epithelial ovarian cancer: a systematic review," *Gynecologic Oncology*, vol. 114, no. 3, pp. 523–552, 2009.

[73] D. K. Armstrong, B. Bundy, L. Wenzel et al., "Intraperitoneal cisplatin and paclitaxel in ovarian cancer," *The New England Journal of Medicine*, vol. 354, no. 1, pp. 34–43, 2006.

[74] D. S. Dizon, M. L. Hensley, E. A. Poynor et al., "Retrospective analysis of carboplatin and paclitaxel as initial second-line therapy for recurrent epithelial ovarian carcinoma: application toward a dynamic disease state model of ovarian cancer," *Journal of Clinical Oncology*, vol. 20, no. 5, pp. 1238–1247, 2002.

[75] M. K. Parmar, J. A. Ledermann, N. Colombo et al., "Paclitaxel plus platinum-based chemotherapy versus conventional platinum-based chemotherapy in women with relapsed ovarian cancer the ICON 4/AGO-OVAR 2.2 trial," *The Lancet*, vol. 361, pp. 2099–2106, 2003.

[76] J. Pfisterer, M. Plante, I. Vergote et al., "Gemcitabine plus carboplatin compared with carboplatin in patients with platinum-sensitive recurrent ovarian cancer: an intergroup trial of the AGO-OVAR, the NCIC CTG, and the EORTC GCG," *Journal of Clinical Oncology*, vol. 24, no. 29, pp. 4699–4707, 2006.

[77] G. P. Sfakianos and L. J. Havrilesky, "A review of cost-effectiveness studies in ovarian cancer," *Cancer Control*, vol. 18, no. 1, pp. 59–64, 2011.

[78] P. Benedetti Panici, A. de Vivo, F. Bellati et al., "Secondary cytoreductive surgery in patients with platinum-sensitive recurrent ovarian cancer," *Annals of Surgical Oncology*, vol. 14, no. 3, pp. 1136–1142, 2007.

[79] G. J. Gardner and E. L. Jewell, "Current and future directions of clinical trials for ovarian Cancer," *Cancer Control*, vol. 18, no. 1, pp. 44–51, 2011.

[80] R. A. Burger, "Role of vascular endothelial growth factor inhibitors in the treatment of gynecologic malignancies," *Journal of Gynecologic Oncology*, vol. 21, no. 1, pp. 3–11, 2010.

[81] A. A. Garcia, H. Hirte, G. Fleming et al., "Phase II clinical trial of bevacizumab and low-dose metronomic oral cyclophosphamide in recurrent ovarian cancer: a trial of the California, Chicago, and Princess Margaret Hospital phase II consortia," *Journal of Clinical Oncology*, vol. 26, no. 1, pp. 76–82, 2008.

[82] K. Behbakht, M. W. Sill, K. M. Darcy et al., "Phase II trial of the mTOR inhibitor, temsirolimus and evaluation of circulating tumor cells and tumor biomarkers in persistent and recurrent epithelial ovarian and primary peritoneal malignancies: a Gynecologic Oncology Group study," *Gynecologic Oncology*, vol. 123, no. 1, pp. 19–26, 2011.

[83] Phase II randomized, double blind, multicentre study to assess the efficacy of AZD, 2281 in the treatment of patients with platinum sensitive ovarian cancer following treatment with two or more platinum regimens. NCT00753545, 2010, http://clinicaltrials.gov/ct2/show/NCT00753545.

[84] A phase II evaluation of belinostat and carboplatin in the treatment of recurrent or persistent platinum—resistant ovarian, fallopian tube, or primary peritoneal cancer. NCT-00993616, 2010, http://clinicaltrials.gov/ct2/show/NCT0099-3616.

[85] B. W. Loggie, J. M. Sterchi, A. T. Rogers et al., "Intraperitoneal hyperthermic chemotherapy for advanced gastrointestinal and ovarian cancers," *Regional Cancer Treatment*, vol. 7, no. 2, pp. 78–81, 1995.

[86] J. Spiliotis, A. Vaxevanidou, F. Sergouniotis, E. Lambropoulou, A. Datsis, and A. Christopoulou, "The role of cytoreductive surgery and hyperthermic intraperitoneal chemotherapy in the management of recurrent advanced ovarian cancer: a prospective study," *Journal of B.U.ON*, vol. 16, no. 1, pp. 74–79, 2011.

[87] C. W. Helm, S. D. Richard, J. Pan et al., "HIPEC in ovarian cancer: first report of HYPER-O registry," *International Journal of Gynecological Cancer*, vol. 20, no. 1, pp. 61–69, 2010.

[88] K. Rowan, "Intraperitoneal therapy for ovarian cancer: why has it not become standard?" *Journal of the National Cancer Institute*, vol. 101, no. 11, pp. 775–777, 2009.

[89] S. Rufian, F. C. Munoz-Casares, J. Briceno et al., "Radical surgery—peritonectomy and intra-operative intraperitoneal chemotherapy for the treatment of peritoneal carcinomatosis in recurrent or primary ovarian cancer," *Journal of Surgical Oncology*, vol. 94, no. 4, pp. 316–324, 2006.

[90] M. Deraco, S. Kusomura, S. Virzi et al., "Cytoreductive surgery and hyperthermic intra-peritoneal chemotherapy as up front therapy for advanced. EOC: multi-institutional phase II study," *Gynecologic Oncology*, vol. 122, no. 2, pp. 215–220, 2011.

[91] M. Deraco, D. Baratti, B. Laterza et al., "Advanced cytoreduction as surgical standard of care and hyperthermic intraperitoneal chemotherapy as promising treatment in epithelial ovarian cancer," *European Journal of Surgical Oncology*, vol. 37, no. 1, pp. 4–9, 2011.

[92] K. Jaaback and N. Johnson, "Intraperitoneal chemotherapy for the initial management of primary epithelial ovarian cancer," *Cochrane Database of Systematic Reviews*, no. 1, Article ID CD005340, 2006.

[93] I. Vergote, C. G. Trope, F. Amant et al., "Neo-adjuvant chemotherapy or primary surgery in stage IIIc or IV ovarian cancer," *The New England Journal of Medicine*, vol. 363, no. 10, pp. 943–953, 2010.

[94] J. Spiliotis, E. Halkia, and E. Efstathiou, "Peritoneal carcinomatosis 2011. Is about time for chemosurgery?" *Journal of B.U.ON*, vol. 16, pp. 400–408, 2011.

[95] K. Galaal, R. Naik, R. E. Bristow, A. Patel, A. Bryant, and H. O. Dickinson, "Cytoreductive surgery plus chemotherapy versus chemotherapy alone for recurrent epithelial ovarian cancer," *Cochrane Database of Systematic Reviews*, vol. 6, Article ID CD007822, 2010.

[96] "Study comparing tumor debulking surgery versus chemotherapy alone in recurrent platinum-sensitive ovarian cancer," AGO—OVAR OP4 DESKTOP III, NCT01166737.

[97] M. Deraco, C. R. Rossi, E. Pennacchioli et al., "Cytoreductive surgery followed by intraperitoneal hyperthermic perfusion in the treatment of recurrent epithelial ovarian cancer: a phase II clinical study," *Tumori*, vol. 87, no. 3, pp. 120–126, 2001.

[98] C. Zanon, R. Clara, I. Chiappino et al., "Cytoreductive surgery and intraperitoneal chemohyperthermia for recurrent peritoneal carcinomatosis from ovarian cancer," *World Journal of Surgery*, vol. 28, no. 10, pp. 1040–1045, 2004.

[99] F. Raspagliesi, S. Kusamura, J. C. Campos Torres et al., "Cytoreduction combined with intraperitoneal hyperthermic perfusion chemotherapy in advanced/recurrent ovarian cancer patients: the experience of National Cancer Institute of Milan," *European Journal of Surgical Oncology*, vol. 32, no. 6, pp. 671–675, 2006.

[100] C. W. Helm, L. Randall-Whitis, R. S. Martin et al., "Hyperthermic intraperitoneal chemotherapy in conjunction with surgery for the treatment of recurrent ovarian carcinoma," *Gynecologic Oncology*, vol. 105, no. 1, pp. 90–96, 2007.

[101] A. Di Giorgio, E. Naticchioni, D. Biacchi et al., "Cytoreductive surgery (peritonectomy procedures) combined with hyperthermic intraperitoneal chemotherapy (HIPEC) in the treatment of diffuse peritoneal carcinomatosis from ovarian cancer," *Cancer*, vol. 113, no. 2, pp. 315–325, 2008.

[102] A. Fagotti, I. Paris, F. Grimolizzi et al., "Secondary cytoreduction plus oxaliplatin-based HIPEC in platinum-sensitive recurrent ovarian cancer patients: a pilot study," *Gynecologic Oncology*, vol. 113, no. 3, pp. 335–340, 2009.

[103] N. Carrabin, F. Mithieux, P. Meeus et al., "Hyperthermic intraperitoneal chemotherapy with oxaliplatin and without adjuvant chemotherapy in stage IIIC ovarian cancer," *Bulletin du Cancer*, vol. 97, no. 4, pp. E23–E32, 2010.

[104] C. W. Helm, "The role of hyperthermic intraperitoneal chemotherapy (HIPEC) in ovarian cancer," *Oncologist*, vol. 14, no. 7, pp. 683–694, 2009.

[105] J. H. Bae, J. M. Lee, K. S. Ryu et al., "Treatment of ovarian cancer with paclitaxel- or carboplatin-based intraperitoneal hyperthermic chemotherapy during secondary surgery," *Gynecologic Oncology*, vol. 106, no. 1, pp. 193–200, 2007.

[106] J. Gori, R. Castaño, M. Toziano et al., "Intraperitoneal hyperthermic chemotherapy in ovarian cancer," *International Journal of Gynecological Cancer*, vol. 15, no. 2, pp. 233–239, 2005.

[107] A. Fagotti, B. Costantini, G. Vizzielli et al., "HIPEC in recurrent ovarian cancer patients: morbidity-related treatment and long-term analysis of clinical outcome," *Gynecologic Oncology*, vol. 122, no. 2, pp. 221–225, 2011.

[108] R. M. Smeenk, V. J. Verwaal, and F. A. N. Zoetmulder, "Learning curve of combined modality treatment in peritoneal surface disease," *British Journal of Surgery*, vol. 94, no. 11, pp. 1408–1414, 2007.

[109] C. Pomel, G. Ferron, G. Lorimier et al., "Hyperthermic intraperitoneal chemotherapy using Oxaliplatin as consolidation therapy for advanced epithelial ovarian carcinoma. Results of a phase II prospective multicentre trial. CHIPOVAC study," *European Journal of Surgical Oncology*, vol. 36, no. 6, pp. 589–593, 2010.

[110] J. D. Spiliotis, A. Rogdakis, A. Vaxevanidou, A. Datsis, G. Zacharis, and A. Christopoulou, "Morbidity and mortality of cytoreductive surgery and hyperthermic intraperitoneal chemotherapy in the management of peritoneal carcinomatosis," *Journal of B.U.ON*, vol. 14, no. 2, pp. 259–264, 2009.

[111] Oxford Center for Evidence Based Medicine, 2010, http://www.cebm.net/index.aspx?o=1025.

[112] J. Spiliotis, E. Halkia, and D. H. Roukos, "Ovarian cancer screening and peritoneal carcinomatosis: standards, "omics" and miRNAs for personalized management," *Expert Review of Molecular Diagnostics*, vol. 11, no. 5, pp. 465–467, 2011.

Hindawi Publishing Corporation
Gastroenterology Research and Practice
Volume 2012, Article ID 309417, 9 pages
doi:10.1155/2012/309417

Research Article

Cytoreductive Surgery Plus Hyperthermic Perioperative Chemotherapy for Selected Patients with Peritoneal Metastases from Colorectal Cancer: A New Standard of Care or an Experimental Approach?

Paul H. Sugarbaker

Washington Cancer Institute, Program in Peritoneal Surface Malignancy, Washington, DC 20010, USA

Correspondence should be addressed to Paul H. Sugarbaker, paul.sugarbaker@medstar.net

Received 5 April 2012; Accepted 16 May 2012

Academic Editor: Pompiliu Piso

Peritoneal metastases (PM) are a common presentation for patients with metastatic colorectal cancer (CRC), and the median survival of patients with PM is approximately one year. In a majority of patients, the disease remains limited to the peritoneal cavity. Therefore, investigators have applied cytoreductive surgery (CRS) and heated perioperative chemotherapy (HIPEC) as a standard approach for selected patients with PM from CRC. These investigators have demonstrated a very promising long-term survival in a subset of patients with a limited amount of isolated peritoneal metastatic disease. This paper presents the data that supports CRS and HIPEC as a treatment option for CRC patients with PM. These results of treatment are compared and contrasted to the results that can be expected with systemic chemotherapy alone.

1. Introduction

As new responsibilities are recognized by the surgeon, he/she must expand the science of surgical technology in order to bring about progress in patient care. In the surgical management of PM the major innovation in the craft of surgery is the peritonectomy procedure. Removal of large areas of peritoneum involved by cancer implants is an important new surgical technology. Also, the use of chemotherapy in the operating room or in the early postoperative period is a surgical innovation specifically used for the management of PM and peritoneal mesothelioma. When used as a combined treatment, CRS (including peritonectomy) and HIPEC have become a treatment option repeatedly reported with favorable results for patients with PM, from colorectal malignancy. As occurs with many other diseases, knowledgeable patient selection is an important aspect of surgical management. This paper will critically evaluate the evidence that supports this treatment strategy for PM and make recommendations to optimize the management of the peritoneal surface component of colorectal cancer dissemination.

2. Cytoreductive Surgery and Hyperthermic Perioperative Chemotherapy as a Treatment Option

The efficacy of CRS and HIPEC as a treatment option for PM from CRC is an established part of the oncologic literature. The survival benefits were well described before the use of modern treatments for metastatic colorectal cancer, using oxaliplatin, irinotecan, and molecular agents. In 1995, three-year survival of 35% in 51 patients with PM from colon cancer treated only with CRS plus intraperitoneal 5-fluorouracil and mitomycin C was shown [1]. In 2003, Verwaal and coworkers in Amsterdam published a three-year projected survival of 38% in 54 patients treated by CRS and hyperthermic intraperitoneal mitomycin C with adjuvant systemic 5-fluorouracil [2]. Shen and coworkers, between 1991 and 2002, treated 77 nonappendiceal CRC patients with CRS and HIPEC. They concluded that one-third of patients with complete resection have long-term survival and that systemic chemotherapy did not contribute to the control of PM in these patients [3]. These studies, performed in

the absence of modern CRC chemotherapy agents, document the efficacy of CRS and perioperative chemotherapy to rescue approximately one-third of these patients.

Some medical oncologists question the benefits of CRS and HIPEC now that oxaliplatin, irinotecan, and molecular agents are available. Are the benefits of systemic chemotherapy alone so great that CRS plus HIPEC are not needed? Or is the best option, at our current state of knowledge, a multidisciplinary approach using the best surgical and best medical oncology treatments available? Franko and colleagues presented data to show that these two strategies were most effective when combined. They showed that the median survival was longer in patients treated by modern systemic chemotherapy when CRS and HIPEC were added to the clinical pathway [4]. Until more data becomes available, patients with PM from CRC have the right to be informed of a possible curative treatment option and it is the oncologists' obligation to provide the relevant information in a timely manner.

2.1. Cytoreductive Surgery and Hyperthermic Perioperative Chemotherapy for Peritoneal Metastases Provides an Individualized Treatment Strategy. Currently, the medical oncologic standard of care for stage IV CRC involves treatments that are nearly identical for all patients. A routine surgery is followed by a routine systemic chemotherapy regimen. A routine followup by physical examination and CT then occurs. If symptoms or radiologic findings suggest metastases, a palliative surgery may be performed, followed by second line chemotherapy. This current standard of care fails to recognize that metastatic disease is a complex process and that the anatomic sites of treatment failure vary greatly between individuals. In those patients who have a high risk for local-regional failure, or are determined to have PM at the time of cancer recurrence, a treatment specifically directed at the abdominal and pelvic surfaces is appropriate.

2.2. A New Strategy for Colorectal Peritoneal Metastases. The new strategy demands a surgical procedure combined with cancer chemotherapy in the operating room. Cytoreductive surgery involves five different peritonectomy procedures that are combined as needed with eight different visceral resections, in order to make patients with PM visibly disease-free [6]. Immediately following the complete cancer resection and prior to intestinal reconstruction, the abdominal and pelvic spaces are flooded by a warm chemotherapy solution with agents augmented by heat. These treatments may be continued with early postoperative intraperitoneal chemotherapy (EPIC), using cell cycle-specific drugs that should contact all visceral and parietal surfaces because their use precedes the development of abdominal adhesions [7].

2.2.1. Quantitative Prognostic Indicators. As with nearly all successful surgical interventions, the proper selection of patients for treatment is an important requirement for long-term benefit. It is well documented that the results of CRS and HIPEC for PM vary greatly with the clinical status of the patient being treated. Quantitative prognostic indicators have been established that allow the cancer surgeon to predict the likelihood of long-term benefit [8]. An important prognostic indicator is the completeness of cytoreduction (CC) score; for CRC, a complete cytoreduction indicates that the surgeon was successful in clearing all visible sites of disease (CC-0), or he left behind only a few minute deposits of cancer that are expected to be eradicated by the HIPEC (CC-1). Complete cytoreduction includes both CC-0 and CC-1 CRS. A necessary requirement for long-term benefit in the management of PM is complete cytoreduction. A French multicentric trial that studied 523 patients compares survival with complete versus incomplete cytoreduction. The data is shown in Figure 1 [5].

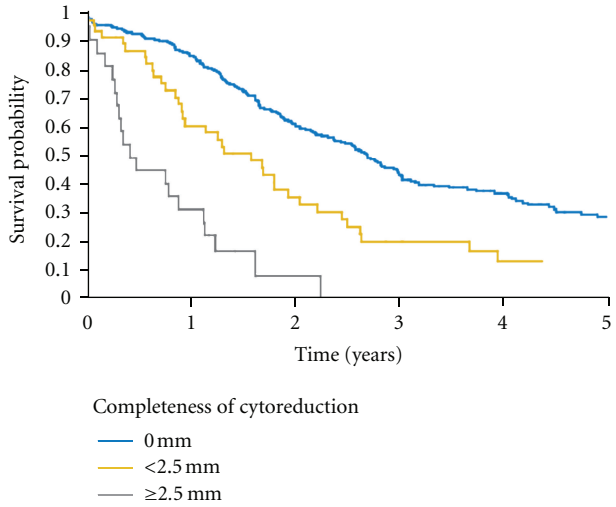

Figure 1: Prognostic impact of the completeness of cytoreductive surgery ($P < 0.001$) on overall survival [5].

A second useful quantitative prognostic indicator is the peritoneal cancer index (PCI). This prognostic indicator scores both the distribution and extent of PM in 13 abdominal and pelvic regions to arrive at a quantitative assessment of the extent of disease [8]. The PCI predicts the likelihood of an incomplete cytoreduction; it also predicts long-term survival even if the cytoreduction is complete [9]. A low PCI indicating a limited extent of carcinomatosis is associated with an improved prognosis. Elias and coworkers in the French collaborative study of 523 patients reported a 50% survival at 5 years with a PCI of 6 or less, 27% 5-year survival with PCI between 7 and 19, and less than 10% with PCI greater than 19 [5]. Elias suggested that the very extensive CRS required in patients who have a PCI of greater than 20 should only occur under special circumstances such as a very young and fit patient. These data showing the impact of PCI on survival are shown in Figure 2.

2.2.2. Extent of Disease as a Major Determinant of Prognosis with Peritoneal Metastases. The concept of increasing benefits of treatment with reduced extent of disease may be a valid concept throughout oncology. It is the basic hypothesis that drives the TNM system. Certainly, it operates in the treatment of CRC liver metastases. The greater the number of

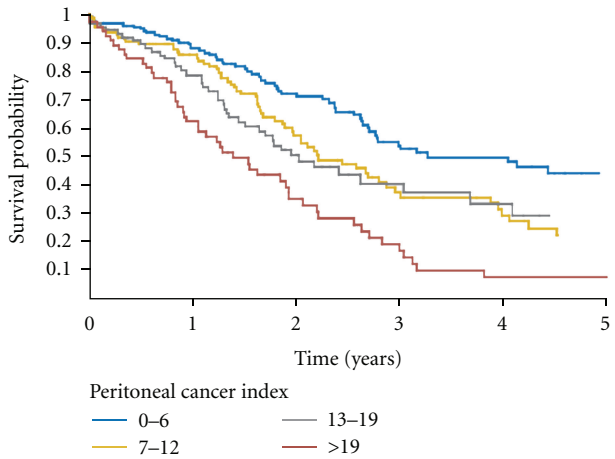

Figure 2: Prognostic impact of the extent of carcinomatosis (i.e., peritoneal cancer index; $P < 0.001$) on overall survival [5].

deposits resected from the liver, the poorer the prognosis; this is true even though an R0 liver resection is achieved. It should not be surprising that this concept of increasing benefits with lesser extent of disease is important for interpreting the results of treatment of CRC PM.

The two prognostic indicators, CC score and PCI, taken together tell us that the extent of PM has a profound effect on treatment outcome when this manifestation of metastatic disease is treated by CRS and HIPEC. A reliable concept worthy of pursuit states that the likelihood of long-term survival will continue to improve as extent of disease at the time of definitive treatment decreases. Clinically, this means that definitive treatment early in the progression of PM can be expected to optimize the survival benefit.

Support for this concept of early intervention with small volume of PM can be found in the recent report by Elias and colleagues [10]. They describe a new plan for early intervention in patients at high risk for local-regional and peritoneal surface progression after primary CRC surgery. These patients had small volume peritoneal seeding, ovarian metastases, or perforation through the primary cancer at the time of colon resection. After treatment with systemic chemotherapy, the patients were taken back to the operating room for a "systematic second-look surgery." Return for reoperation was within one year. At exploration, Elias and colleagues found cancer present in 16 of the 29 patients (55%). All patients in whom progressive disease was found were treated with CRS and HIPEC. At 27 months, median followup for the survival of these patients, was 50%. The high incidence of prolonged survival in this group of patients with PM undergoing early definitive second-look surgery, supports the concept of maximal benefit in patients treated with a minimal burden of disease.

2.2.3. Proactive Intervention in Patients with Colorectal Peritoneal Metastases. An important clinical question concerns the general application of this concept of proactive intervention in the management of CRC PM. Currently, CRS and HIPEC may not be considered a reasonable treatment option by the medical oncologist because the risks of treatment are perceived to exceed its benefit. The perception is that these patients must submit to a high-risk major surgical intervention with an extended hospitalization and long convalescence. Unfortunately, the alternative to comprehensive management, using CRS and HIPEC, is death from disease progression. Within a few months or perhaps a few years, the PM will progress. These patients now with high volume intra-abdominal disease have no treatment options except palliative surgery. This provides a minimum short-term benefit, if any benefit at all. Perhaps valid in the past, this nihilistic attitude toward the management of PM needs to change. Late referral by the medical oncologist after all systemic chemotherapy options have failed and the patients are now symptomatic from the PM should be considered a part of oncologic history. The proactive management of every patient with PM needs to be included in the discussions within the multidisciplinary team.

2.2.4. As Morbidity and Mortality Decreases the Referral for Definitive Treatment Expands. It is no doubt that three decades of clinical and laboratory studies in PM have allowed the surgical team to ascend a learning curve that results in increased benefit and reduced toxicity. This learning curve is a phenomenon repeatedly observed with a complex surgical procedure and it has been reported with CRS and HIPEC [11, 12]. As the adverse events decrease, the reluctance of the medical oncologist to refer a patient for definitive treatment of PM should disappear. In our last 150 cytoreductions at the Washington Cancer Institute, 60% of patients had 3, 4, or 5 peritonectomy procedures. Eighty-five percent had 2 or more visceral resections, and 50% had at least one anastomosis. These patients with colorectal or appendiceal PM had a major surgical intervention with an average time in the operating room of 9.6 hours. Despite this extensive CRS with HIPEC, there was a single postoperative mortality (0.6%) and a serious complication rate of 12% [13]. Numerous publications regarding the current expectation for adverse events associated with CRS and HIPEC have been recently published [14].

2.3. Absence of Evidence-Based Medicine Regarding Management of Peritoneal Metastases from Colorectal Cancer by Systemic Chemotherapy Alone. There is no doubt that modern systemic chemotherapy using oxaliplatin, irinotecan, and maximal doses of fluorouracil have led to a prolongation of life in patients with metastatic CRC. The molecular agents, bevacizumab and cetuximab, has also had a modest effect on survival [15]. However, in the multiple publications regarding the medical oncologic management of metastatic disease, data regarding the objective response rate, progression-free survival, and survival in the subset of patients with PM have not been made available. Data regarding systemic chemotherapy treatment of a general population of patients with CRC metastases is not at all relevant to PM patients. Unfortunately, reliable data from the medical oncologic literature regarding the survival of patients with CRC PM does not exist.

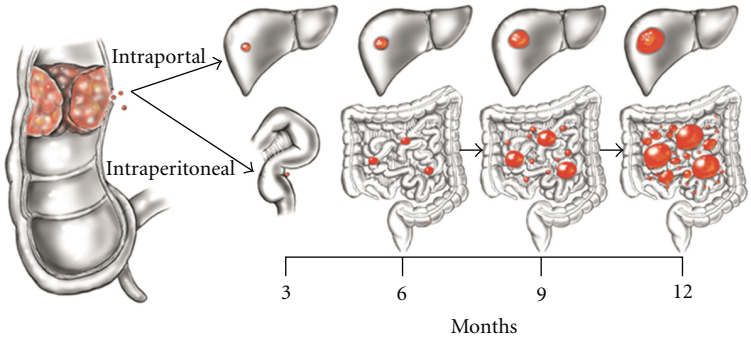

Figure 3: Schematic diagram that presents a theoretical model comparing the progression of one colorectal liver metastasis to one peritoneal metastases over one year. The liver metastasis will expand within the liver parenchyma with a doubling time of approximately three months. The peritoneal metastasis will progress at approximately the same speed but will also exfoliate cancer cells into the free peritoneal space. Many cancer nodules of many different sizes will occur widely distributed throughout the abdomen and pelvis within one year.

2.3.1. Comparatively Poor Survival of Patients with Peritoneal Metastases. Patients with PM should not be assumed to have the same benefits as those patients with liver metastases or lung metastases who have indicator lesions by radiologic tests and, therefore, are included in the data regarding survival with modern chemotherapy regimens. Patients with PM have a more limited survival when compared to patients with liver or other systemic metastases if systemic chemotherapy is the only treatment [16]. Franko and coworkers compared the survival of 364 patients with PM from CRC to 1731 patients who had CRC metastases in the absence of PM. The median overall survival was reduced to 12.7 months in patients with PM as compared to 17.6 months in patients without PM (HR 1.3 (95% CI 1.2–1.5)). The anatomic location of liver metastases, lung metastases, and retroperitoneal lymph node metastases is such that disease progression can occur in many patients without substantial disruption of function. In contrast, PM, even of small size, will soon result in bowel obstruction, fistulization, or bowel perforation. Palliative surgical interventions in this clinical situation are of short-term benefit. The bowel is a delicate organ whose essential nutritional function can be completely disrupted even by a small volume of PM.

2.3.2. Fundamental Differences in the Progression of Metastases to Parenchymal Organs as Compared to Peritoneal Surface Metastases. Not only do PM, because of their intimate relationship with the bowel, rapidly disrupt host function, but also their progression is usually more rapid than with parenchymal metastases. The epithelial cell is programmed to exfoliate from its attachment to the basement membrane as the cancer nodule enlarges. Cancer nodules on peritoneal surfaces may exfoliate cancer cells in great numbers into the free peritoneal space (reviewed in [17]). Growth inhibition of these newly implanted cells does not exist and nodules rapidly progress, and then cause additional peritoneal implants. The exponential progression of disease to multiple sites on the abdominal and pelvic peritoneal surfaces may rapidly cause the death of the patient. Without surgical interventions, PM will progress much more rapidly than metastases at other anatomic sites (Figure 3).

2.3.3. Site-Specific Reporting of Benefit for Treatment of Metastatic Disease Needed. The survival statistics in patients with metastatic disease at isolated anatomic sites should be reported separately. Brain metastases, lung metastases, liver metastases, retroperitoneal nodal metastases, and PM are likely to represent a strong biological variance of the process currently and collectively referred to as disseminated colorectal malignancy. Currently, all anatomic sites of disease are treated in the same manner using systemic chemotherapy. However, their responses will vary greatly with the anatomic location of the malignancy. Unfortunately, data regarding this difference in response and in survival does not exist in the oncologic literature. The clinician knows that the survival following detection of liver metastases, peritoneal, or other sites of metastases varies greatly. For example, brain metastases, of only a few centimeters in diameter, may disrupt function of the host completely within a few weeks of detection. The same size lesion in the liver or lung parenchyma may be totally asymptomatic and remain asymptomatic for years. Also, survival of disease at different anatomic sites will vary greatly because definitive surgical intervention may or may not be possible. Without CRS and HIPEC, PM of small size may have a profound effect on the host by disrupting enteral nutrition because of the intimate anatomic relationship of the cancer with the small bowel.

2.3.4. Absence of Radiologic Monitoring of Peritoneal Metastases. It is not surprising that a firm assessment of the benefits of modern systemic chemotherapy on the survival of patients with PM has not been forthcoming. Large multi-institutional studies require an indicator lesion that can accurately assess changes in disease status over time. In patients with PM the radiologic assessment of disease progression is difficult—in most patients it is impossible. Only patients who have a large burden of PM and, therefore, a very limited survival are candidates for longitudinal radiologic followup. Usually these patients with limited survival expectations are not eligible for clinical trials with systemic chemotherapy.

The best data regarding survival of patients with PM comes from surgical studies of patients with isolated and possibly resectable disease. Elias and coworkers studied

48 patients with PM treated with palliative chemotherapy using modern chemotherapy agents [18]. The patients were not treated with CRS and HIPEC because this treatment modality was not available at their institution. The median survival was 23.9 months. In 48 matched patients, who had CRS and HIPEC, the median survival was 62.7 months with a statistically significant difference in survival ($P < 0.5$). Elias and coworkers concluded that chemotherapy alone using modern agents may achieve a median survival of 24 months and a 13% 5-year survival. However, CRS plus HIPEC resulted in a median survival of 63 months with a 51% 5-year survival. There are possible criticisms of these data presented by Elias and coworkers. The control group was treated by systemic chemotherapy alone, whereas the experimental group had second-look CRS plus HIPEC. It is possible that the control group, given the benefit of CRS, would have an improved survival in the absence of HIPEC.

Franko and colleagues studied 38 patients with PM who were matched to 67 patients who had CRS and HIPEC [4]. The median survival of patients receiving systemic chemotherapy was 16.8 months, whereas the survival of those treated by systemic chemotherapy plus CRS and HIPEC was 34.7 months. These differences were significant with a P-value of less than 0.001. Franko and colleagues concluded that CRS and HIPEC complement systemic chemotherapy for the management of PM; they should not, in a multidisciplinary approach, be considered to be competing therapies.

2.4. Evidence-Based Medicine Regarding Management of Peritoneal Metastases from Colorectal Cancer by Cytoreductive Surgery and Hyperthermic Perioperative Chemotherapy. In sharp contrast to the absence of data with systemic chemotherapy, evidence-based medicine regarding management of PM from CRC using CRS and HIPEC is extensive. Most relevant is the phase III study reported by Verwaal and colleagues in 2003 [2]. This landmark study compared 105 patients who were randomly assigned to receive either standard treatment with systemic 5-fluorouracil-leucovorin as compared to an aggressive CRS and HIPEC with mitomycin C. The patients in the "experimental therapy" also had systemic 5-fluorouracil chemotherapy. After a median followup of 21.6 months, the median survival was 12.6 months with systemic chemotherapy and 22.3 months with CRS and HIPEC ($P = 0.032$). These authors reported that a complete cytoreduction and a limited extent of disease were important determinants of benefit. The durability of the CRS and HIPEC was confirmed in a follow-up manuscript in 2008 [19].

From the perspective of a medical oncologist, a major criticism of the Verwaal phase III trial is the absence of modern systemic chemotherapy in the treatment of the control group. Would FOLFOX chemotherapy improve the survival of the control group to equal that of patients having CRS and HIPEC? Or, as might be expected, would modern systemic chemotherapy improve the survival of both groups of patients in this trial? It may be expected that CRS plus HIPEC plus FOLFOX are the optimal strategy for CRC PM [4].

Another important evidence-based report in support of these combined treatments was the multi-institutional registry of 506 patients reported by Glehen et al. in 2004 [20]. Glehen collected data on 506 patients from 28 institutions who had CRS and HIPEC for CRC PM. The overall median survival was 19.2 months but in patients in whom cytoreduction was complete, the median survival was 32.4 months; the survival was 8.4 months in patients in whom complete cytoreduction was not possible ($P < 0.001$).

Yan and colleagues published a systematic review [21] of 64 publications from single institutions that reported results of this combined treatment modality. The systematic review contained two randomized controlled trials, one nonrandomized comparative study, and 11 observational studies without control groups, including one large multi-institutional study. Yan and colleagues concluded that the current evidence suggests that CRS combined with HIPEC is associated with improved survival as compared to systemic chemotherapy in patients with PM from CRC.

The multi-institutional French study reported on 523 patients from 23 French-speaking centers [5]. The overall median survival was 30.1 months and 5-year overall survival was 27%. In 84% of patients who had a complete cytoreduction, the median survival was 33 months. This group concluded that CRS and HIPEC are now considered the standard of care for selected patients in the French guidelines for management of PM.

Verwaal reported long-term Dutch multicenter data [22]. The survival of 562 patients at 10 years was 37%. From the extensive data of references 2, 4, 5, and 19–22, one must conclude that patients who had a CC-0 or CC-1 CRS had a median survival of 30–60 months and 5-year survival between 20 and 40%.

Manuscripts that show a prolonged median survival and a definite 5-year survival benefit with CRS and HIPEC are being published on a regular basis in the oncology literature. These patients may be selected in that the favorable results only occur in patients who undergo complete macroscopic CRS. It is likely that this results in a selection bias compared to patients that only qualify for palliative systemic chemotherapy. Possible differences between these groups of patients need to be addressed in future studies. Nevertheless, similar reports showing the benefit of systemic chemotherapy for CRC PM are not being published. By default, CRS and HIPEC must be considered as a valid treatment option to be presented to selected patients with PM. Patients deserve to be informed.

2.4.1. Long Followup (5 and 10 Years) Necessary to Evaluate Treatments. It is crucial to note the large difference in long-term survival produced by modern systemic chemotherapy as compared to long-term survival produced by CRS and HIPEC. Yes, both cause a prolongation in the median survival; this is estimated at approximately 20 months for systemic chemotherapy in contrast to 40 months for CRS and HIPEC. However, the great difference is the 30–40% of patients who show 5- and 10-year survival with the combined treatment. Such percentages of 5- and 10-year survival do not exist as part of the medical oncologic

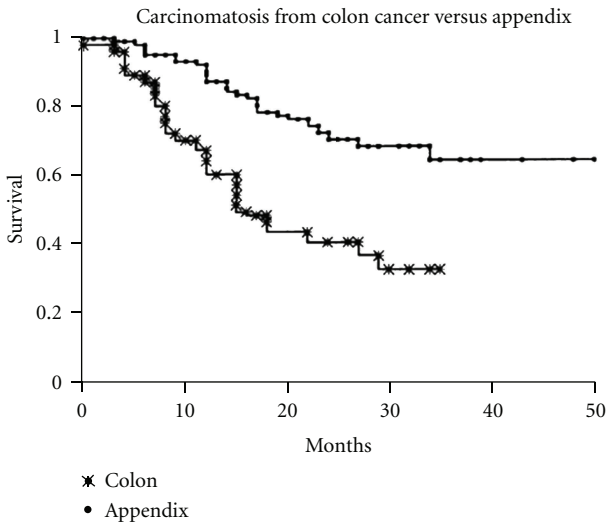

Figure 4: Comparison of survival of colon and appendiceal peritoneal metastases in patients having the same treatments [1].

literature. The percent of long-term survival with CRS and HIPEC will depend on the experience of the institution, the PCI and CC scores of patients treated [5]. The best results will be realized when the multidisciplinary team considers all CRC PM patients for proactive treatment as an initial treatment option.

2.5. Peritoneal Metastases from Colorectal Cancer Compared to Peritoneal Metastases from Other Gastrointestinal Malignancies. CRS and HIPEC are not only of benefit to patients with CRC PM, but also for other gastrointestinal malignancies with peritoneal dissemination. As a general rule, it seems that the lower the biological aggressiveness of the malignancy, the greater the efficacy of CRS and HIPEC. For example, Sugarbaker showed a 65% survival of patients with pseudomyxoma peritonei (peritoneal metastases from appendiceal malignancy) who have a PCI greater than 20 [23]. This survival is present after 20 years of followup. This is in contrast to a 5-year survival of 7% in CRC patients with a PCI of 20 or greater [5].

Data comparing survival of patients with PM from CRC with patients who have appendiceal cancer is shown in Figure 4. There is no debate about the general application of CRS and HIPEC for patients with appendiceal mucinous neoplasms [1, 24].

Although CRS and HIPEC have produced some limited prolongation of survival in patients with gastric cancer, long-term survival in terms of a "cure" is rarely achieved [25, 26]. In gastric cancer, the important role for HIPEC may be in the adjuvant treatment of patients at high risk for local-regional and peritoneal dissemination [27]. It is largely ineffective in the treatment of documented PM, except in patients with a very low PCI.

2.6. Peritoneal Metastases from Colorectal Cancer Compared to Liver Metastases from Colorectal Cancer. Multicenter randomized controlled trials showing the benefit of the surgical removal of colorectal liver metastases as compared to nonoperative management have never been performed [28]. The survival of patients with resected liver metastases has often been compared to the survival of patients who have the combined treatment of PM [29, 30]. These results with peritoneal and liver metastases can also be compared to results of treatment with lung metastases [31]. By historical analogy and many precedents, the management of PM by CRS and HIPEC has been accepted and is being performed at most major institutions in the USA.

2.7. Introducing Perioperative Chemotherapy into the Management of Primary Colorectal Cancer. If a patient with primary CRC and a small volume of PM or a patient with primary CRC at high risk for local-regional recurrence undergoes colon or rectal cancer resection at an institution that delivers perioperative chemotherapy, definitive treatment for peritoneal dissemination should be considered as a part of management of primary CRC. Pestieau and Sugarbaker reported on 5 patients with PM, in which the diagnosis was made at the time of primary CRC resection [32]. These patients had small volume of PM not evident by clinical signs or radiologic studies prior to colon resection. All patients survived at least 5 years. Two of these patients manifested late recurrences and eventually died of systemic disease. When a small volume of PM was definitively treated along with the resection of the primary CRC the outcome was favorable.

2.8. Requirements for Further Investigations

2.8.1. Is HIPEC Essential in All Patients? The combined treatment of CRS and HIPEC has been in use for over three decades for colorectal PM, and has consistently shown benefits in terms of long-term survival in a selected group of patients. Nevertheless, many important questions require an answer to optimize this treatment strategy. A basic question, as yet not clarified, concerns the contribution of the colorectal cancer to the CRS. Can some patients survive PM using complete CRS in the absence of HIPEC? If so, how can these patients be identified? In France, a randomized and controlled multi-institutional study to answer this question is currently accruing patients (Federation Nationale des Centres de Lutte Contre le Cancer: Cytoreductive Surgery with or without HIPEC for Colorectal Carcinomatosis). Thus, an answer to this question utilizing perioperative chemotherapy with 5-fluorouracil, oxaliplatin, and irinotecan should become available within several years.

2.8.2. Perioperative Chemotherapy Capable of Maintaining the Surgical Complete Response. After a surgical complete response has been achieved by CRS, the disease-free status within the abdomen and pelvis needs to be preserved. The most effective choice of combination chemotherapy delivered by both the intravenous and intraperitoneal routes, has not been determined in a clinical trial. Pharmacologic studies have suggested multiagent chemotherapy but further

clinical studies to demonstrate the durability of the surgical complete response by HIPEC are indicated [33].

Another important issue is the optimal balance of chemotherapy effect and adverse events. Increasing the dose intensity and the number of perioperative chemotherapy agents is expected to increase the response; however, it is likely to result in increased toxicity.

2.8.3. Systemic Chemotherapy with Cytoreductive Surgery and Perioperative Chemotherapy. One aspect of treatment of PM that is well supported is the adjuvant use of systemic chemotherapy [4, 5, 20]. What has not yet been determined is the proper sequencing of the standard systemic treatments for metastatic disease with CRS and HIPEC. Some data exists to suggest that full dose neoadjuvant chemotherapy is associated with a reduced survival [20]. It is possible that full dose systemic chemotherapy caused a long delay definitive treatment that allowed for progression of peritoneal metastases in nonresponding patients. Also, full dose neoadjuvant chemotherapy may reduce the effectiveness of perioperative chemotherapy by causing acquired drug resistance. Bone marrow damage caused by a full 6 months of systemic chemotherapy requires a dose reduction of HIPEC and consequently a decreased dose intensity within the peritoneal cavity. This may translate into reduced cancer control within the peritoneal space. At this point in time, it is safe to say that the role of neoadjuvant FOLFOX chemotherapy in the management of PM has not been determined. The favorable results demonstrated in other gastrointestinal cancers need to be investigated for CRC PM.

Finally, the proper role for 5-fluorouracil (5-FU) in HIPEC has not been determined. A majority of successful chemotherapy regimens for gastrointestinal cancer are combinations of drugs added on to 5-FU at approximately 2000 mg/m^2 per treatment cycle. This requirement for 5-FU has not been met in most HIPEC regimens. One possible plan to fulfill the need for 5-FU is to use intravenous 5-FU with HIPEC and then administer an additional 4 doses of EPIC 5-FU on postoperative days 1–4. If each 5-FU dose is 400 mg/m^2, a 2000 mg/m^2 dose has been achieved over 5 perioperative days.

3. Conclusion

Because of a large amount of mature data gathered over 30 years, one can begin to formulate the advantages and disadvantages associated with CRS and HIPEC for CRC PM (Table 1). The most important advantages is the long-term survival of 20–50% of a highly selected group of patients on surgical series. Secondly, the degree of PM as measured by CC and PCI scores allows selection of individuals who are most likely to benefit.

There are disadvantages that remain. The procedure is associated with significant morbidity. Mortality from the operation appears to be less than 5% in centers of excellence and may be less than 1% in some centers. There is lack of uniformity of the patients that are entered into surgical databases, and lack of uniformity in the technical aspects of CRS and HIPEC treatments between the centers that do this procedure.

Table 1: Cytoreductive surgery (CRS) and hyperthermic perioperative chemotherapy (HIPEC) for colorectal peritoneal metastases.

Credits	Debits
(i) Long-term survival in 30% of patients (ii) Patients with minimal carcinomatosis experience best survival	(i) The cytoreductive surgical procedure is complex and requires an extended learning curve
(iii) Morbidity (12%) and mortality (1%) at experienced centers is possible	(ii) Surgical series contain patients who have received many different HIPEC regimens at many different timepoints in their treatment (iii) The relative roles of CRS and HIPEC in the causation of long-term survival have not been determined (iv) Seventy percent of patients in the literature went on to die of peritoneal metastases usually because HIPEC did not sustain the surgical complete response

Search Strategy and Selection Criteria

Data for this paper were identified by searches of databases that were MEDLINE, Current Contents, PubMed, and references from relevant articles using the search terms "Peritoneal carcinomatosis"; "colon cancer"; "rectal cancer"; "colorectal cancer"; "adenocarcinoma of the colon"; "heated intraperitoneal chemotherapy"; "HIPEC"; "cytoreductive surgery"; "intraperitoneal chemotherapy." Only articles published in English between 1990 and 2011 were included.

Conflict of Interests

P. H. Sugarbaker declared no conflict of interests.

References

[1] P. H. Sugarbaker and K. A. Jablonski, "Prognostic features of 51 colorectal and 130 appendiceal cancer patients with peritoneal carcinomatosis treated by cytoreductive surgery and intraperitoneal chemotherapy," *Annals of Surgery*, vol. 221, no. 2, pp. 124–132, 1995.

[2] V. J. Verwaal, S. Van Ruth, E. De Bree et al., "Randomized trial of cytoreduction and hyperthermic intraperitoneal chemotherapy versus systemic chemotherapy and palliative surgery in patients with peritoneal carcinomatosis of colorectal cancer," *Journal of Clinical Oncology*, vol. 21, no. 20, pp. 3737–3743, 2003.

[3] P. Shen, J. Hawksworth, J. Lovato et al., "Cytoreductive surgery and intraperitoneal hyperthermic chemotherapy with mitomycin C for peritoneal carcinomatosis from nonappendiceal colorectal carcinoma," *Annals of Surgical Oncology*, vol. 11, no. 2, pp. 178–186, 2004.

[4] J. Franko, Z. Ibrahim, N. J. Gusani, M. P. Holtzman, D. L. Bartlett, and H. J. Zeh, "Cytoreductive surgery and hyperthermic intraperitoneal chemoperfusion versus systemic chemotherapy alone for colorectal peritoneal carcinomatosis," *Cancer*, vol. 116, no. 16, pp. 3756–3762, 2010.

[5] D. Elias, F. Gilly, F. Boutitie et al., "Peritoneal colorectal carcinomatosis treated with surgery and perioperative intraperitoneal chemotherapy: retrospective analysis of 523 patients from a multicentric french study," *Journal of Clinical Oncology*, vol. 28, no. 1, pp. 63–68, 2010.

[6] P. H. Sugarbaker, "Peritonectomy procedures," *Surgical Oncology Clinics of North America*, vol. 12, no. 3, pp. 703–727, 2003.

[7] P. H. Sugarbaker, T. Graves, E. A. DeBruijn et al., "Early postoperative intraperitoneal chemotherapy as an adjuvant therapy to surgery for peritoneal carcinomatosis from gastrointestinal cancer: pharmacological studies," *Cancer Research*, vol. 50, no. 18, pp. 5790–5794, 1990.

[8] P. Jacquet and P. H. Sugarbaker, "Current methodologies for clinical assessment of patients with peritoneal carcinomatosis," *Journal of Experimental and Clinical Cancer Research*, vol. 15, no. 1, pp. 49–58, 1996.

[9] R. G. da Silva and P. H. Sugarbaker, "Analysis of prognostic factors in seventy patients having a complete cytoreduction plus perioperative intraperitoneal chemotherapy for carcinomatosis from colorectal cancer," *Journal of the American College of Surgeons*, vol. 203, no. 6, pp. 878–886, 2006.

[10] D. Elias, D. Goéré, D. Di Pietrantonio et al., "Results of systematic second-look surgery in patients at high risk of developing colorectal peritoneal carcinomatosis," *Annals of surgery*, vol. 247, no. 3, pp. 445–450, 2008.

[11] F. Mohamed and B. J. Moran, "Morbidity and mortality with cytoreductive surgery and intraperitoneal chemotherapy: the importance of a learning curve," *Cancer Journal*, vol. 15, no. 3, pp. 196–199, 2009.

[12] T. C. Chua, T. D. Yan, A. Saxena, and D. L. Morris, "Should the treatment of peritoneal carcinomatosis by cytoreductive surgery and hyperthermic intraperitoneal chemotherapy still be regarded as a highly morbid procedure?: a systematic review of morbidity and mortality," *Annals of Surgery*, vol. 249, no. 6, pp. 900–907, 2009.

[13] P. H. Sugarbaker, K. van der Speeten, O. A. Stuart, D. Chang, and H. Mahteme, "Patient- and treatment-related variables, adverse events and their statistical relationship for treatment of peritoneal metastases," in *Cytoreductive Surgery and Perioperative Chemotherapy for Peritoneal Surface Malignancy: Textbook and Video Atlas*, P. H. Sugarbaker, Ed., Cine-Med, Woodbury, Conn, USA, 2012.

[14] T. C. Chua, J. Esquivel, J. O. Pelz, and D. L. Morris, "Critical analyses of treatment modality and impact on outcome in peritoneal metastases from colorectal cancer: a systematic review," *Annals of Oncology*. In press.

[15] S. K. Libutti, L. B. Saltz, and G. Willett, "Cancer of the colon," in *Cancer. Principles and Practice of Oncology*, V. T. De Vita, T. S. Lawrence, and S. A. Rosenberg, Eds., pp. 1084–1126, JB Lippincott, Philadelphia, Pa, USA, 9th edition, 2010.

[16] J. Franko, Q. Shi, C. D. Goldman et al., "Treatment of colorectal peritoneal carcinomatosis with systemic chemotherapy: a pooled analysis of North Central Cancer Treatment Group phase III trials N9741 and N9841," *Journal of Clinical Oncology*, vol. 30, no. 3, pp. 263–267, 2012.

[17] C. P. Carmignani, T. A. Sugarbaker, C. M. Bromley, and P. H. Sugarbaker, "Intraperitoneal cancer dissemination: mechanisms of the patterns of spread," *Cancer and Metastasis Reviews*, vol. 22, no. 4, pp. 465–472, 2003.

[18] D. Elias, J. H. Lefevre, J. Chevalier et al., "Complete cytoreductive surgery plus intraperitoneal chemohyperthermia with oxaliplatin for peritoneal carcinomatosis of colorectal origin," *Journal of Clinical Oncology*, vol. 27, no. 5, pp. 681–685, 2009.

[19] V. J. Verwaal, S. Bruin, H. Boot, G. van Slooten, and H. van Tinteren, "8-Year follow-up of randomized trial: cytoreduction and hyperthermic intraperitoneal chemotherapy versus systemic chemotherapy in patients with peritoneal carcinomatosis of colorectal cancer," *Annals of Surgical Oncology*, vol. 15, no. 9, pp. 2426–2432, 2008.

[20] O. Glehen, F. Kwiatkowski, P. H. Sugarbaker et al., "Cytoreductive surgery combined with perioperative intraperitoneal chemotherapy for the management of peritoneal carcinomatosis from colorectal cancer: a Multi-Institutional study," *Journal of Clinical Oncology*, vol. 22, no. 16, pp. 3284–3292, 2004.

[21] T. D. Yan, D. Black, R. Savady, and P. H. Sugarbaker, "Systematic review on the efficacy of cytoreductive surgery combined with perioperative intraperitoneal chemotherapy for peritoneal carcinomatosis from colorectal carcinoma," *Journal of Clinical Oncology*, vol. 24, no. 24, pp. 4011–4019, 2006.

[22] V. J. Verwaal, "Long-term results of cytoreduction and HIPEC followed by systemic chemotherapy," *Cancer Journal*, vol. 15, no. 3, pp. 212–215, 2009.

[23] P. H. Sugarbaker, "Epithelial appendiceal neoplasms," *Cancer Journal*, vol. 15, no. 3, pp. 225–235, 2009.

[24] P. H. Sugarbaker, "New standard of care for appendiceal epithelial neoplasms and pseudomyxoma peritonei syndrome?" *Lancet Oncology*, vol. 7, no. 1, pp. 69–76, 2006.

[25] O. Glehen, F. N. Gilly, C. Arvieux et al., "Peritoneal carcinomatosis from gastric cancer: a multi-institutional study of 159 patients treated by cytoreductive surgery combined with perioperative intraperitoneal chemotherapy," *Annals of Surgical Oncology*, vol. 17, no. 9, pp. 2370–2377, 2010.

[26] X. J. Yang, C. Q. Huang, T. Suo et al., "Cytoreductive surgery and hyperthermic intraperitoneal chemotherapy improves survival of patients with peritoneal carcinomatosis from gastric cancer: final results of a phase III randomized clinical trial," *Annals of Surgical Oncology*, vol. 18, no. 6, pp. 1575–1581, 2011.

[27] T. D. Yan, D. Black, P. H. Sugarbaker et al., "A systematic review and meta-analysis of the randomized controlled trials on adjuvant intraperitoneal chemotherapy for resectable gastric cancer," *Annals of Surgical Oncology*, vol. 14, no. 10, pp. 2702–2713, 2007.

[28] T. Kaido, "Verification of evidence in surgical treatment for colorectal liver metastasis," *Hepato-Gastroenterology*, vol. 55, no. 82-83, pp. 378–380, 2008.

[29] P. Gertsch, "A historical perspective on colorectal liver metastases and peritoneal carcinomatosis: similar results, different treatments," *Surgical Oncology Clinics of North America*, vol. 12, no. 3, pp. 531–541, 2003.

[30] O. Varban, E. A. Levine, J. H. Stewart, T. P. McCoy, and P. Shen, "Outcomes associated with cytoreductive surgery and intraperitoneal hyperthermic chemotherapy in colorectal cancer patients with peritoneal surface disease and hepatic metastases," *Cancer*, vol. 115, no. 15, pp. 3427–3436, 2009.

[31] P. M. McCormack, M. E. Burt, M. S. Bains, N. Martini, V. W. Rusch, and R. J. Ginsberg, "Lung resection for colorectal metastases: 10-Year results," *Archives of Surgery*, vol. 127, no. 12, pp. 1403–1406, 1992.

[32] S. R. Pestieau, P. H. Sugarbaker, and D. M. Ota, "Treatment of primary colon cancer with peritoneal carcinomatosis:

comparison of concomitant versus delayed management," *Diseases of the Colon and Rectum*, vol. 43, no. 10, pp. 1341–1348, 2000.

[33] K. Van Der Speeten, O. A. Stuart, and P. H. Sugarbaker, "Pharmacokinetics and pharmacodynamics of perioperative cancer chemotherapy in peritoneal surface malignancy," *Cancer Journal*, vol. 15, no. 3, pp. 216–224, 2009.

Hindawi Publishing Corporation
Gastroenterology Research and Practice
Volume 2012, Article ID 690256, 6 pages
doi:10.1155/2012/690256

Review Article

Pulmonary Metastasis from Pseudomyxoma Peritonei

Toshiyuki Kitai

Department of Surgery, Kishiwada City Hospital, 1001 Gakuhara-cho, Kishiwada, Osaka 5968501, Japan

Correspondence should be addressed to Toshiyuki Kitai, tmhs8943@kcn.ne.jp

Received 3 March 2012; Accepted 19 April 2012

Academic Editor: Yutaka Yonemura

Pseudomyxoma peritonei (PMP) is a rare clinical condition, where copious mucinous ascites accumulate in the peritoneal cavity due to dissemination of mucin-producing tumor. Because of this disseminating, yet nonmetastasizing, behavior, PMP attracts much interest from surgical oncologists in that aggressive locoregional therapy can give the opportunity of long survival and even cure. Although extra-abdominal metastasis is exceptionally rare, the lung is the most likely site in such a case. In this paper, the clinical findings and treatment of eleven cases with pulmonary metastasis from PMP were reviewed, including ten cases in the literature and one case which we experienced. The clinical features of PMP cases with pulmonary metastasis were similar to cases without pulmonary metastasis. The histological type was low-grade mucinous neoplasm in most cases. Pulmonary lesions were resected in seven cases in which abdominal lesions were controlled by cytoreductive surgery and hyperthermic intraperitoneal chemotherapy or another therapeutic modality. Disease-free state was maintained in five cases at the end of the follow-up period. However, it should be noted that rapid progression after resection was seen in two cases, suggesting that biological features may have changed by surgical intervention.

1. Introduction

Pseudomyxoma peritonei (PMP) is a rare clinical condition, where copious mucinous ascites accumulate in the peritoneal cavity due to dissemination of mucin-producing tumor [1]. It is initiated by perforation of low-grade mucinous appendiceal neoplasm in most cases. Although the condition becomes fatal if untreated, progression is slow, and extra-abdominal metastasis is exceptionally rare. Because of these biological behaviors, PMP attracts much interest from surgical oncologists in that aggressive locoregional therapy can give the opportunity of long survival and even cure [2, 3]. Cytoreductive surgery (CRS) and hyperthermic intraperitoneal chemotherapy (HIPEC), which were initiated by Sugarbaker, have been accepted as an option for the standard treatment for PMP in many specialized centers.

Although extra-abdominal metastasis is very rare, the lung is one of the most probable sites in such a case. Once pulmonary metastasis occurs, it is important to consider that the biological features of PMP with metastasis may be different from those without metastasis. It is not clear whether surgical resection of metastatic lesions improves prognosis. In addition, if the biological features of PMP cases with pulmonary metastasis are more aggressive than those without pulmonary metastasis, CRS and HIPEC may not be indicated for these cases. In this paper, the clinical findings and treatment of eleven cases with pulmonary metastasis from PMP were reviewed, including ten cases reported in the previous literature and one case which we experienced.

2. Case

A 60-year-old female was referred to us for the treatment of PMP. She had undergone palliative resection and HIPEC for PMP one year before. Histological diagnosis was low-grade appendiceal mucinous neoplasm with peritoneal dissemination, classified as disseminated adenomucinosis (DPAM) according to the criteria by Ronnett. At the time of referral, tumor was diffusely spread in the peritoneal cavity and single nodule was observed in the right lower lung (Figure 1). CRS and HIPEC were performed, and complete cytoreduction was achieved. The lung nodule was removed by wedge resection. Histological findings of the lung nodule were similar with those of appendiceal tumor, showing that low-grade mucinous neoplasm invaded pulmonary

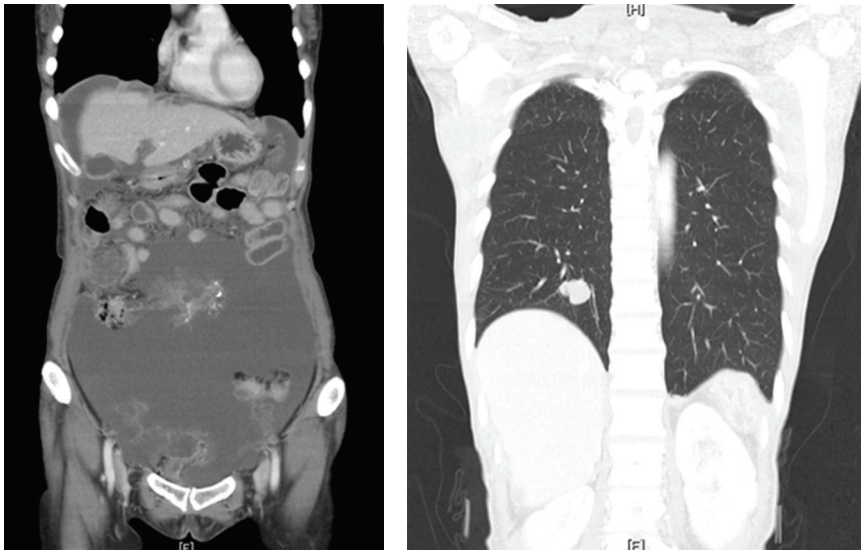

(a) (b)

Figure 1: CT at the time of referral: massive tumor was diffusely spread in the peritoneal cavity. A solitary nodule in the right lower lung was also observed.

parenchyma (Figure 2). CT examination two months after CRS showed multiple lung nodules, and they progressed rapidly (Figure 3). She underwent laparotomy for intestinal obstruction caused by diffuse abdominal recurrence five months later. The histological type of recurrent lesions was the same as that of previously resected specimens. Serum levels of CEA and CA19-9 were 10.6 ng/mL and 62.3 U/mL before CRS, and returned to normal ranges after CRS, respectively. They still remained in the normal range at the time of CT examination, and increased again to 6.8 and 105.5 at the time of laparotomy. She died of the disease one year after CRS.

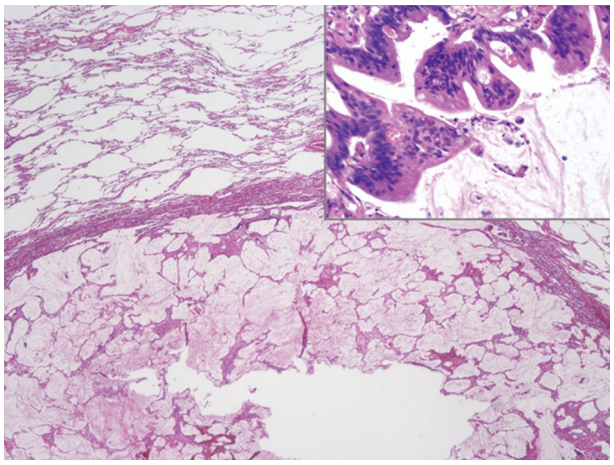

Figure 2: Histological findings of the lung nodule: atypical cells with histological characteristics similar to appendiceal tumor invaded pulmonary parenchyma.

3. Review of the Literature

3.1. Clinical Findings. Eleven cases of pulmonary metastasis from PMP have been reported including the present case [4–10] (Table 1). Patients included seven males and four females, and the mean age was 51.8 years old (range: 39–65 years old). The origin of the disease was low-grade appendiceal neoplasm [11], and the histology of PMP corresponded to disseminated adenomucinosis [12] in most cases, although it is difficult to be sure from the description by some authors exactly how pulmonary metastasis would be classified. Two cases reported by Lee et al. [8] and Kahn et al. [10] were classified as well-differentiated mucinous adenocarcinoma and mucinous cystadenocarcinoma, respectively. However, from their description and published photographs, it would likely be considered as DPAM in both cases. Pulmonary metastasis was multiple in seven cases and bilateral in five cases. All cases were metachronous, and the median interval between the first clinical presentation of PMP and lung metastases was three years (range: 3 months–7 years). Pleural extension coexisted in two cases, but they were separated from pulmonary lesions.

3.2. Treatment. In the three cases which were reported earlier by Berge, Chevillotte et al., and Kreissig et al. [4–6], patients underwent palliative debulking surgery for PMP, and lung metastasis was histologically confirmed by autopsy or lung biopsy. CRS and HIPEC were performed in six out of the eight cases, which were reported more recently [7, 9]. Only CRS was done in one case [8], and appendectomy with radiotherapy was done in another case [10]. Pulmonary lesions were resected in the seven cases in which abdominal lesions were controlled by CRS and HIPEC

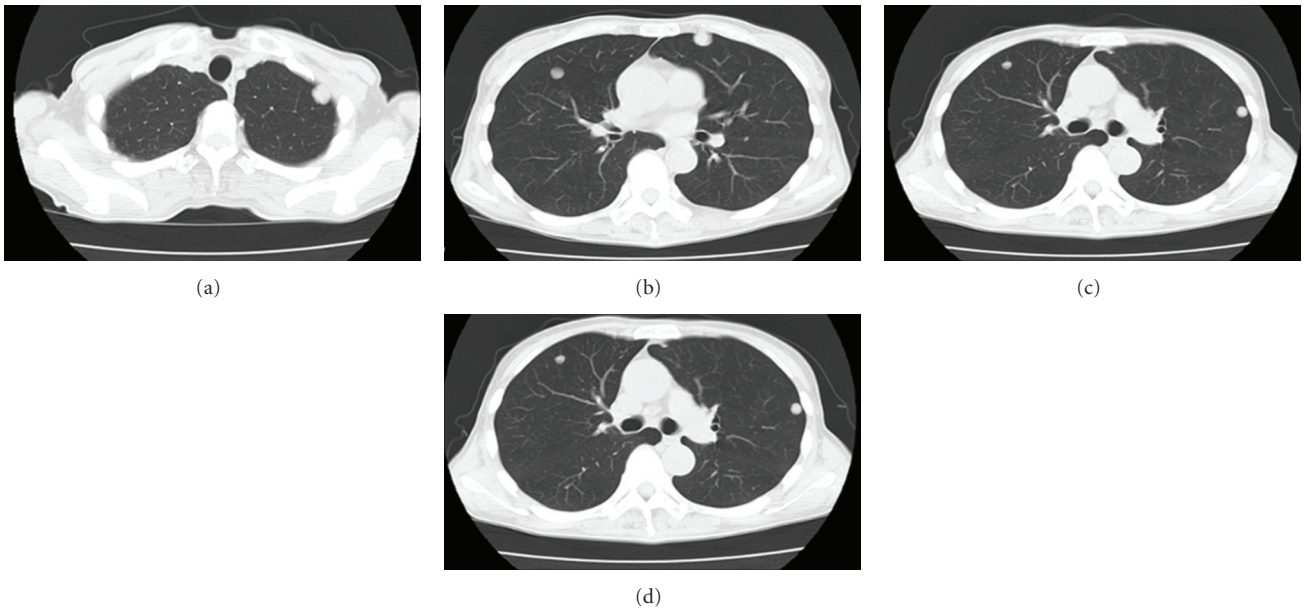

Figure 3: CT examination two months after CRS revealed rapid progression of multiple lung metastases.

or by appendectomy with radiotherapy. Wedge resection was done in four cases, and lobectomy with or without lymph node dissection was done in three cases to achieve disease-free state. Recurrence occurred in four cases, among which recurrent sites were the lung in three cases and the abdomen in one case. The mode of pulmonary resection did not affect the probability of recurrence. Intervals between pulmonary resection and recurrence were 2 months, 1 year, and 13 years in three cases. In one case, multiple pulmonary recurrences occurred shortly after resection, but the interval length was not exactly described. Salvage surgery for recurrent lesions was performed in two cases: one was CRS and HIPEC for abdominal recurrence, and the other was pulmonary wedge resection for pulmonary recurrence. Disease-free state was maintained in five out of the seven cases at the end of the follow-up period ranging from 2 to 14 years. However, two cases showed rapid progression after pulmonary resection and were judged as inoperable. There was no description in any report that systemic chemotherapy was performed for pulmonary metastasis from PMP.

4. Discussion

Extra-abdominal metastasis of PMP is exceptionally rare, but the lung and pleura are the most likely sites in such a case [9]. The majority of pleural metastases were caused by diaphragmatic injury at previous cytoreductive surgery or direct invasion through the diaphragm [13, 14]. Congenital pleuroperitoneal communication was also reported as a rarer cause [15]. They are thought to be extensions of dissemination rather than metastasis. By contrast, pulmonary metastasis is thought to occur through lymphatic fluid or venous blood. Although several cases of splenic metastasis have been reported as hematogenous, most lesions were thought to be an entrapment of mucinous tumor within splenic surface trabeculae, which expand into splenic parenchyma resembling metastatic disease [16]. Two cases showed coexistence of pleural extension in this review, but pulmonary lesions were separated from pleural lesions. A recent biological study reported that the decreased expression of E-cadherin and increased expression of N-cadherin and vimentin in tumor cells of PMP were more significant than in those of adenocarcinoma of the colon. The authors suggested that these specific phenotypes may characterize the disseminating, yet nonmetastatic, behavior of PMP [17]. It was also shown that Ki-67 expression significantly increased in adenocarcinoma but was similar in PMP as compared to that in normal colonic mucosa, suggesting a correlation with the slow growing behavior of PMP. Such specific biological features of PMP may have changed in pulmonary metastasis cases. Although no biological study was done in previous case reports, the histological types of PMP and pulmonary metastasis were classified as DPAM and low-grade mucinous neoplasm in all cases. PMP was well controlled by CRS and HIPEC in most cases. There seems to be no clinical finding suggesting that they had different biological features. However, as to the two cases which showed rapid progression after CRS and pulmonary resection, it was highly suspected that inflammatory reactions caused by surgical stress and other factors may have changed biological features which cannot be determined by the histological type.

Resection of metastatic lesions was indicated, when abdominal lesions were controlled by CRS and HIPEC. Wedge resection would be enough except such occasions where the possibility of primary lung cancer cannot be excluded. Prognosis was fairly good, although the follow-up period was rather short. It is noteworthy that long survival

Table 1

(a)

Case	Reference	Sex	Age	Origin	Histology of origin	Abdominal surgery	Multiple/solitary	Laterality
1	Berge [4]	M	59	Appendix	Low grade	Palliative	Multiple	Bilateral
2	Chevillotte et al. [5]	M	45	Appendix	Low grade	Palliative	Multiple	Bilateral
3	Kreissig et al. [6]	F	39	Appendix	Low grade	Palliative	Multiple	Bilateral
4	Mortman et al. [7]	F	47	Appendix	Low grade	CRS + HIPEC[a]	Multiple	Right
5		M	48	Appendix	Low grade	CRS + HIPEC	Solitary	Left
6		M	41	Appendix	Low grade	CRS + HIPEC	Multiple	Right
7	Lee et al. [8]	M	60	Appendix	Low grade	CRS[b]	Multiple	Bilateral
8	Geisinger et al. [9]	M	61	Appendix	Low grade	CRS + HIPEC	Solitary	Right
9		F	45	Appendix	Low grade	CRS + HIPEC	Solitary	Right
10	Khan et al. [10]	M	65	Appendix	Low grade	Appendectomy + RT	Multiple	Bilateral
11	Present case (2012)	F	60	Appendix	Low grade	CRS + HIPEC	Solitary	Right

(b)

Case	Metachronous/ synchronous	Interval to pulmonary metastasis[c]	Pleural extension	Histology of lung	Pulmonary surgery
1	Metachronous	3 years	ND	Low grade	
2	Metachronous	7 years	(−)	Low grade	
3	Metachronous	5 years	ND	Low grade	
4	Metachronous	3 months	(−)	Low grade	Right lower lobectomy + LND
5	Metachronous	2 years	(−)	Low grade	Left lower lobectomy + LND
6	Metachronous	2 years	(−)	Low grade	Wedge resection
7	Metachronous	5 years	(+)	Low grade[d]	
8	Metachronous	ND	(−)	Low grade	Wedge resection
9	Metachronous	ND	(−)	Low grade	Wedge resection
10	Metachronous	7 years	(−)	Low grade	Right upper lobectomy, left upper lobectomy + wedge resection[e]
11	Metachronous	1 year	(+)	Low grade	Wedge resection

(c)

Case	Recurrence	Interval to recurrence	2nd surgery	Present status	Follow-up period[f]
1				DWD	
2				DWD	
3				ND	
4	(−)			NED	2 years
5	Abdomen	1 year	CRS + HIPEC	NED	3 years
6	(−)			NED	8 years
7				ND	
8	Lung	Shortly	No	ND	
9	(−)			NED	2 years
10	Lung	13 years	Wedge resection	NED	14 years
11	Lung + abdomen	2 months	No	DWD	1 year

CRS: cytoreductive surgery, HIPEC: hyperthermic intraperitoneal chemotherapy, RT: radiation therapy, ND: not described, DWD: died with disease, and NED: no evidence of disease. [a]CRS + HIPEC were performed three times. [b]The diaphragm was injured at CRS. [c]Interval between the first abdominal presentation and the lung metastasis. [d]Histology of the pleural lesion. [e]Two-stage pulmonary resection was performed. [f]Follow-up period from the pulmonary resection.

was achieved in one case in which multistep pulmonary resection was performed for multiple and bilateral lung metastases. However, it should be cautiously noted that rapid progression after pulmonary resection was seen in two cases. It was suspected that inflammatory reaction caused by CRS and abdominal infection may have changed biological features towards rapid deterioration [18, 19].

A more recent retrospective study showed that 42 cases of intrathoracic metastases were found out of 626 cases of appendiceal adenocarcinoma [20], which included 10 cases of pleura, 22 cases of lung, and 10 cases of both. Prognosis depended on histology. The authors concluded that lung metastasis from appendiceal adenocarcinoma may be higher than previously thought. It was not clear how many cases of PMP were included in the group of lung metastasis, but they may not be exceptional since appendiceal adenocarcinoma is frequently found to be ruptured at the time of laparotomy.

Pulmonary resection for pulmonary metastasis of colon cancer is recommended by NCCN guidelines [21], but few surgeons would consider surgical indication in cases with both pulmonary metastasis and peritoneal dissemination. PMP had been regarded as a noncurable disease for a long time, and repeated debulking surgeries were the choice of treatment [22]. Although CRS and HIPEC provided the possibility of cure as well as longer survival than conventional treatments, this aggressive locoregional cancer therapy is only performed at limited specialized centers and is still the subject of controversy at the majority of institutions. In addition, the rare incidence of PMP that was reported as one per million, the complexity of the procedures, and the high morbidity and mortality associated with the treatment are the main causes to prevent it from being accepted in general. The fact that there have been few reports of pulmonary metastasis from PMP may be related with the fact that CRS and HIPEC for curative intent were performed only at limited institutions and that, therefore, no interest was paid to pulmonary metastasis from PMP, which was noncurable by nature. The clinical implication of pulmonary metastasis from PMP would be more important if recognition that PMP can be cured by CRS and HIPEC become more popular in the future.

5. Conclusions

Extra-abdominal metastasis from PMP was exceptionally rare, but the lung was the most likely site in such a case. Clinical findings of PMP cases with pulmonary metastasis were similar to those without pulmonary metastasis. Resection of pulmonary lesions was indicated, and long survival may be expected when abdominal lesions were controlled by CRS and HIPEC. However, it should be cautiously noted that rapid progression after resection was seen in some cases, where biological features may be changed.

Conflict of Interests

The author has no conflict of interests concerning this work.

References

[1] J. Rosai, "Pseudomyxoma peritonei," in *Rosai and Ackerman's Surgical Pathology*, pp. 2386–2387, Mosby, London, UK, 9th edition, 2004.

[2] B. Moran, D. Baratti, T. D. Yan, S. Kusamura, and M. Deraco, "Consensus statement on the loco-regional treatment of appendiceal mucinous neoplasms with peritoneal dissemination (pseudomyxoma peritonei)," *Journal of Surgical Oncology*, vol. 98, no. 4, pp. 277–282, 2008.

[3] T. D. Yan, D. Black, R. Savady, and P. H. Sugarbaker, "A systematic review on the efficacy of cytoreductive surgery and perioperative intraperitoneal chemotherapy for pseudomyxoma peritonei," *Annals of Surgical Oncology*, vol. 14, no. 2, pp. 484–492, 2007.

[4] T. Berge, "Mucocelle appendicis with pseudomyxoma peritonei and pulmonary metastases," *Acta Pathologica et Microbiologica Scandinavica*, vol. 60, pp. 483–486, 1964.

[5] G. Chevillotte, R. Choux, and G. Spik, "Pseudomyxoma peritonei: a case report with multiple metastasis. Ultrastructural study and chemical analysis of mucoid substance," *Gastroenterologie Clinique et Biologique*, vol. 7, no. 5, pp. 445–450, 1983.

[6] P. Kreissig, J. Daucourt, and G. Garnier, "Pseudomyxoma peritonei with pulmonary metastasis," *Presse Medicale*, vol. 20, no. 27, p. 1287, 1991.

[7] K. D. Mortman, P. A. Sugarbaker, B. M. Shmookler, V. C. DeGuzman, and M. S. Soberman, "Pulmonary metastases in pseudomyxoma peritonei syndrome," *Annals of Thoracic Surgery*, vol. 64, no. 5, pp. 1434–1436, 1997.

[8] B. Y. Lee, H. S. Kim, S. H. Lee et al., "Pseudomyxoma peritonei: extraperitoneal spread to the pleural cavity and lung," *Journal of Thoracic Imaging*, vol. 19, no. 2, pp. 123–126, 2004.

[9] K. R. Geisinger, E. A. Levine, P. Shen, and R. F. Bradley, "Pleuropulmonary involvement in pseudomyxoma peritonei: morphologic assessment and literature review," *American Journal of Clinical Pathology*, vol. 127, no. 1, pp. 135–143, 2007.

[10] A. A. Khan, J. Tambiah, P. Cane, and L. Lang-Lazdunski, "Prolonged survival in a patient with recurrent pulmonary metastases secondary to mucinous cystadenocarcinoma of the appendix with pseudomyxomatous peritonei," *Annals of Thoracic Surgery*, vol. 83, no. 5, pp. 1893–1894, 2007.

[11] J. Misdraji, "Appendiceal mucinous neoplasms: controversial issues," *Archives of Pathology and Laboratory Medicine*, vol. 134, no. 6, pp. 864–870, 2010.

[12] B. M. Ronnett, H. Yan, R. J. Kurman, B. M. Shmookler, L. Wu, and P. H. Sugarbaker, "Patients with pseudomyxoma peritonei associated with disseminated peritoneal adenomucinosis have a significantly more favorable prognosis than patients with peritoneal mucinous carcinomatosis," *Cancer*, vol. 92, no. 1, pp. 85–91, 2001.

[13] S. R. Pestieau, J. Esquivel, and P. H. Sugarbaker, "Pleural extension of mucinous tumor in patients with pseudomyxoma peritonei syndrome," *Annals of Surgical Oncology*, vol. 7, no. 3, pp. 199–203, 2000.

[14] T. C. Chua, T. D. Yan, Z. L. Yap, M. D. Horton, G. C. Fermanis, and D. L. Morris, "Thoracic cytoreductive surgery and intraoperative hyperthermic intrathoracic chemotherapy for pseudomyxoma peritonei," *Journal of Surgical Oncology*, vol. 99, no. 5, pp. 292–295, 2009.

[15] S. R. Pestieau, R. Wolk, and P. H. Sugarbaker, "Congenital pleuroperitoneal communication in a patient with pseudomyxoma peritonei," *Journal of Surgical Oncology*, vol. 73, no. 3, pp. 174–178, 2000.

[16] J. Cabanas, R. Gomes Da Silva, L. Zappa et al., "Splenic metastases from mucinous neoplasms of the appendix and colon," *Tumori*, vol. 92, no. 2, pp. 104–112, 2006.

[17] R. Bibi, N. Pranesh, M. P. Saunders et al., "A specific cadherin phenotype may characterise the disseminating yet non-metastatic behaviour of pseudomyxoma peritonei," *British Journal of Cancer*, vol. 95, no. 9, pp. 1258–1264, 2006.

[18] C. Semino-Mora, H. Liu, T. McAvoy et al., "Pseudomyxoma peritonei: is disease progression related to microbial agents? A study of bacteria, MUC2 and MUC5AC expression in disseminated peritoneal adenomucinosis and peritoneal mucinous carcinomatosis," *Annals of Surgical Oncology*, vol. 15, no. 5, pp. 1414–1423, 2008.

[19] G. Lorusso and C. Rüegg, "The tumor microenvironment and its contribution to tumor evolution toward metastasis," *Histochemistry and Cell Biology*, vol. 130, no. 6, pp. 1091–1103, 2008.

[20] J. Hill, S. Rafeeq, D. Rice et al., "Clinicopathological characteristics of patients with appendiceal adenocarcinoma (AA) and intra-thoracic metastasis," in *Proceedings of the 7th International Symposium on Regional Cancer Therapies*, Fla, USA, February 2012.

[21] NCCN guidelines Version 3, "Colon cancer. Principles of surgery, criteria for resectability of metastases and locoregional therapy within surgery, 2012".

[22] T. J. Miner, J. Shia, D. P. Jaques, D. S. Klimstra, M. F. Brennan, and D. G. Coit, "Long-term survival following treatment of pseudomyxoma peritonei: an analysis of surgical therapy," *Annals of Surgery*, vol. 241, no. 2, pp. 300–308, 2005.

Hindawi Publishing Corporation
Gastroenterology Research and Practice
Volume 2012, Article ID 827534, 5 pages
doi:10.1155/2012/827534

Research Article

Hyperthermic Intraperitoneal Chemotherapy with Melphalan: A Summary of Clinical and Pharmacological Data in 34 Patients

Lana Bijelic,[1] Paul H. Sugarbaker,[1] and O. Anthony Stuart[2]

[1] *Washington Cancer Institute, Washington, DC 20010, USA*
[2] *MedStar Health Research Institute, Washington, DC 20010, USA*

Correspondence should be addressed to Paul H. Sugarbaker, paul.sugarbaker@medstar.net

Received 16 April 2012; Accepted 1 May 2012

Academic Editor: Yan Li

Cytoreductive surgery (CRS) with hyperthermic intraperitoneal chemotherapy (HIPEC) is a treatment option for peritoneal metastases. The optimal agents for HIPEC have not been established. Melphalan is a drug with broad activity and a favorable profile for intraperitoneal application. The purpose of this study is to review our experience using melphalan for HIPEC. Pharmacologic data was obtained. Thirty four patients who underwent CRS for peritoneal metastases received melphalan for HIPEC between 2003 and 2011. The first 10 patients received 70 mg/m^2; subsequent 24 received 60 or 70 mg/m^2. The mean PCI was 21 ± 7. Twenty-eight patients (83%) had a CC score of 1 or 2. The mean length of stay was 18 ± 2 days. Nine patients (26%) had a grade 3 and 6 (17%) had grade 4 morbidity. There were no postoperative deaths. The pharmacologic analysis of plasma to peritoneal fluid levels of melphalan showed an AUC ratio of 33 while the tumor nodules to peritoneal ratio was 8. Melphalan is an acceptable agent for use in HIPEC. The morbidity of intraperitoneal melphalan at the dose of 60–70 mg/m^2 appears acceptable. Further studies comparing the effectiveness of melphalan and other HIPEC agents are needed.

1. Introduction

Cytoreductive surgery, combined with heated intraperitoneal chemotherapy (HIPEC), is a treatment modality that can provide long-term survival for selected patients with peritoneal metastases from gastrointestinal cancer and mesothelioma [1–3]. The best outcomes are achieved in patients who have a complete surgical removal of the peritoneal deposits [4, 5]. Unfortunately, recurrence on the peritoneal surface is common even after successful complete cytoreduction [6–8]. Therefore, efforts should be directed to improve the effectiveness of intraperitoneal chemotherapy as a way to maintain the disease control obtained with complete cytoreduction.

While HIPEC is almost universally used as an integral component of the cytoreductive procedure, there is little consensus on the optimal regimen. There is variability in both the chemotherapy agents and doses used among treatment centers due to a lack of studies directly comparing different HIPEC regimens. Treatment centers often base their choice of HIPEC regimen on theoretical principals and pharmacologic data.

Melphalan is an antineoplastic alkylating agent that causes the formation of interstrand DNA crosslinks and shows a marked increase in activity with heat [9, 10]. For this reason, it remains the principal agent used in isolated limb perfusion for the treatment of in-transit metastases of melanoma [11]. We have previously shown in an animal model that the intraperitoneal administration of melphalan combined with heat is effective in delaying tumor growth and that the effect of hyperthermia on the pharmacokinetics and tissue distribution of intraperitoneally administered melphalan indicated increased intraabdominal tissue concentrations [12].

Therefore, we sought to evaluate the feasibility of using melphalan for heated intraperitoneal chemotherapy combined with cytoreductive surgery for the treatment of peritoneal metastases from appendix and colorectal cancer as well as mesothelioma.

2. Methods

All patients, undergoing cytoreductive surgery with HIPEC utilizing melphalan, were identified by searching our

prospectively maintained database. From July 2003 until July 2011, 34 patients received HIPEC with melphalan. The first 10 patients were treated as part of a prospective, single-institution phase I trial approved by the Institutional Review Board.

Cytoreductive surgery was performed by the senior author in all cases and consisted of peritonectomies and visceral resections performed as needed to achieve complete tumor removal whenever possible as previously described [13]. After all resections were completed, the patients underwent HIPEC with melphalan for 60 or 90 minutes. Melphalan was given at a dose of 50–70 mg/m^2 in 1.5 L/m^2 of 1.5% dextrose peritoneal dialysis solution. The dose of melphalan was chosen based on the number of cycles of systemic chemotherapy that the patients received prior to cytoreductive surgery and their performance status. HIPEC was performed using the open coliseum method except in select patients with incomplete cytoreduction in whom the closed method was used to provide increased intraabdominal pressure [14]. One inflow catheter and four outflow catheters were used to circulate the chemotherapy solution in both the open and closed method. The temperature of the chemotherapy solution was maintained at 41-42°C inside the abdomen and continuously monitored with two temperature probes.

Early postoperative intraperitoneal chemotherapy with 5-FU was used in four patients who did not receive any prior systemic or intraperitoneal chemotherapy during the phase I trial. Following completion of the phase I trial, HIPEC with melphalan was used in patients with recurrent disease being treated with repeat cytoreductive surgery and HIPEC. This group of patients did not receive EPIC. Perioperative variables, including the peritoneal cancer index (PCI), extent of cytoreductive surgery, completeness of cytoreduction (CC score) and a detailed assessment of morbidity by grade, and organ system for each patient, were prospectively assessed and entered into a database.

Pharmacological assessments were done on the first 10 patients enrolled in the phase I trial and an additional 10 patients treated afterwards. In patients who underwent pharmacologic analysis, samples of peritoneal fluid, blood, urine, and, where available, tumor nodules were collected immediately prior and every 15 minutes during HIPEC. Melphalan concentration was assessed using high-performance liquid chromatography (HPLC) within 24 hours of collection. Melphalan concentrations were determined using a modification of the HPLC method described by Norda et al. [15] We used a Shimadzu LC7A instrument equipped with a SPD-6AV (UV-VIS) detector set at 270 nm along with a C-R6a Chromatopac data processor. A Dynamax reversed-phase C_{18} column ($150 \times 4.6\,\text{mm}^2$) of Microsorb 100° 5 μm particles was used coupled to a guard column of the same chemical consistency (Varian Associates, Walnut Creek, CA, USA). The mobile phase consisted of an isocratic mixture of 30% acetonitrile in 0.005 M NaH_2PO_4 with the pH adjusted to 3.5 with phosphoric acid. The flow rate was set at 1.2 mL/min and the volume of sample injections was 50 μL. All solvents used were HPLC grade (Fisher Scientific, Norcross, GA, USA).

Table 1: Demographic and perioperative data on 34 patients treated with cytoreductive surgery and heated intraperitoneal chemotherapy with melphalan.

Gender	
Male	14
Female	20
Age (mean)	46.1
Primary diagnosis	
Appendix cancer	23
Mesothelioma	6
Colon cancer	2
Ovarian cancer	2
Urachal cancer	1
Peritoneal cancer index (PCI)	
Mean	21
Range	4–39
Completeness of cytoreduction score	
CC-1	21
CC-2	7
CC-3	6
Dose of melphalan	
50 mg/m^2	5
60 mg/m^2	17
70 mg/m^2	10

3. Results

Thirty-four patients received heated intraoperative intraperitoneal melphalan between July 2003 and July 2011. There were 20 females and 14 males. Twenty-three patients had appendiceal carcinoma, 6 had mesothelioma, 2 colon cancer, 2 ovarian cancer, and 1 had urachal carcinoma. Eleven patients received melphalan at their first cytoreduction with HIPEC while 23 had repeat CRS+HIPEC for recurrent disease.

The mean PCI was 28 for patients who received melphalan at the time of their first cytoreductive procedure and 18 for patients who had repeat cytoreduction.

Twenty-one patients had a CC score of 1, seven had a CC score of 2, and six had a CC score of 3. All the demographic and perioperative data is summarized in Table 1.

The number of peritonectomies performed ranged from 0 to 4 (mean 1.05). The number of visceral resections performed ranged from 0 to 6 (mean 2.26). The mean length of stay was 18 ± 2 days. Nine patients (26%) had a grade 3 complication in the postoperative period. The following grade 3 complications were observed: deep vein thrombosis in 4 instances, urinary tract infection in 3, diarrhea in 2, respiratory distress in 2, neutropenia in 2, and catheter associated bloodstream infection in 1 (Figure 1). Six patients (17%) had grade 4 morbidity: there was 1 fistula and 1 Hartmann's pouch leak, 1 severe pancreatitis, 1 occurrence of postoperative bleeding, 1 case of ARDS, 1 lower extremity compartment syndrome, and 1 grade IV neutropenia (Figure 2). There were no postoperative deaths. On univariate analysis, the dose of melphalan, the number of visceral

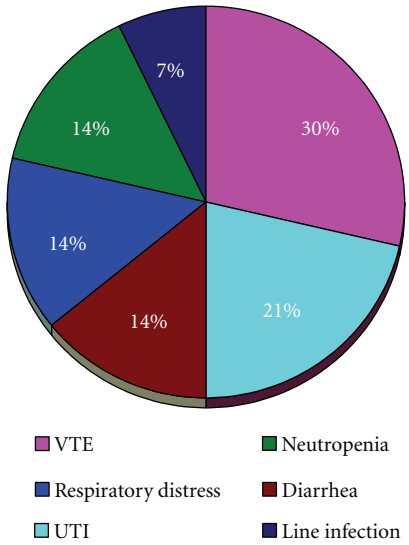

Figure 1: Grade 3 complications observed during the postoperative period in 34 patients treated with cytoreductive surgery and HIPEC with melphalan.

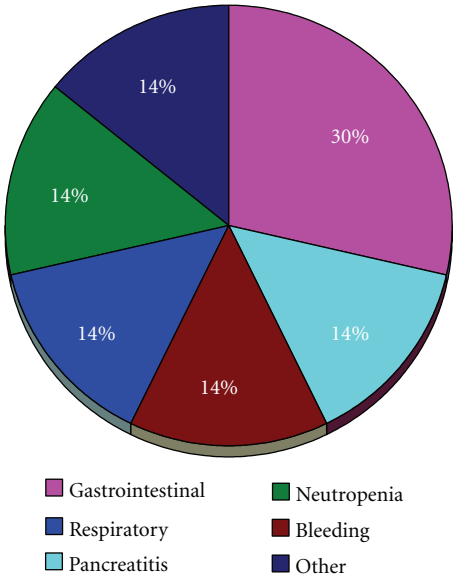

Figure 2: Grade 4 complications observed during the postoperative period in 34 patients treated with cytoreductive surgery and HIPEC with melphalan.

resection, and the number of peritonectomies were associated with an increased incidence of grade 4 complications, while the peritoneal cancer index and the use of EPIC were not (Table 2).

The mean total dose of melphalan received was 116 ± 21 mg. Five patients were treated with 50 mg/m^2, 17 patients received 60 mg/m^2, and 10 received 70 mg/m^2 (the dose/m^2 data was unknown for 2 patients). The pharmacologic analysis was carried out in 20 patients. During 90 minutes of HIPEC, an average of 85.7 ± 5.2% of melphalan was absorbed. The average absorption at 60 minutes of treatment

Table 2: Univariate analysis of clinical factors associated with grade 4 postoperative morbidity in 34 patients treated with cytoreductive surgery and HIPEC with melphalan.

Clinical variable	Grade 4 morbidity		*P* value
	Yes	No	
Dose of melphalan			0.01
50 mg/m^2	0	4	
60 mg/m^2	0	16	
70 mg/m^2	4	6	
Number of peritonectomies			<0.001
≤2	1	24	
>2	5	3	
Number of visceral resections			0.002
≤2	0	20	
>2	6	8	
Peritoneal cancer index			0.38
≤20	1	16	
>20	5	12	
EPIC			0.13
Yes	2	2	
No	26	4	

was 75.2 ± 7.5%. The average peritoneal fluid AUC over 90 minutes of HIPEC was 1541 ± 295 μg/mL while the average plasma AUC was 46 ± 13. The average peritoneal fluid to plasma AUC ratio was 35 ± 13 (Figure 3).

There were three patients who received intraperitoneal melphalan using the closed technique who had a complete pharmacologic evaluation. The pharmacologic data on these patients was compared to 12 patients treated with hyperthermic intraperitoneal melphalan using the open technique. The melphalan levels in these patients are shown in Figure 4. The plasma levels of melphalan were slightly increased in the closed technique as compared to the open; however; these results were not statistically significant.

4. Discussion

The rationale for using local regional chemotherapy following cytoreductive surgery for peritoneal metastases is based on the well-documented pharmacokinetic advantage of intraperitoneal delivery that results in high peritoneal fluid levels and comparatively low systemic levels [16]. From a theoretical standpoint, the choice of agents for use in HIPEC should take maximal advantage of this principle. The pharmacokinetics of intraperitoneal melphalan have been studied by Howell at al. under normothermic conditions showing approximately 90% systemic absorption at 4 hours [17]. However, we have previously shown in an animal model that the addition of hyperthermia increases the rate of systemic absorption [12]. In the current study, we performed melphalan HIPEC for 90 minutes in the first 18 patients. An analysis of the pharmacology shows there was approximately 85% absorption at 90 minutes compared to 75% at 60 minutes. Considering, there is only a 10%

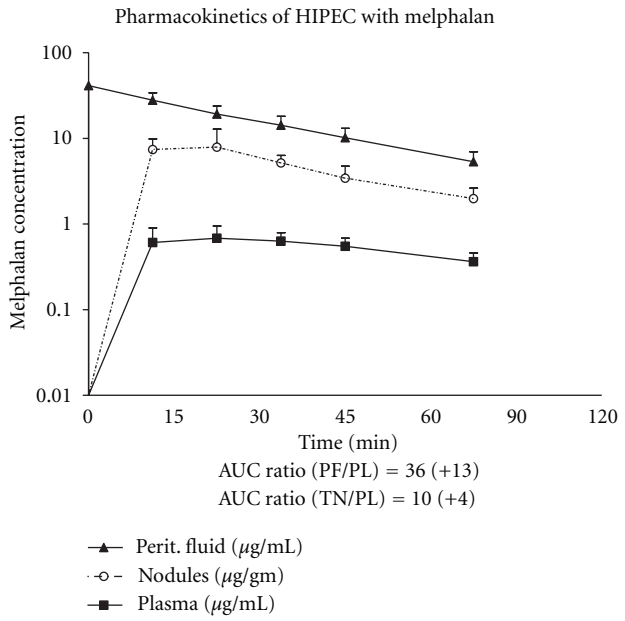

Figure 3: Pharmacologic analysis showing peritoneal fluid, plasma, and tumor nodule levels of melphalan in 20 patients treated with cytoreductive surgery and HIPEC with melphalan.

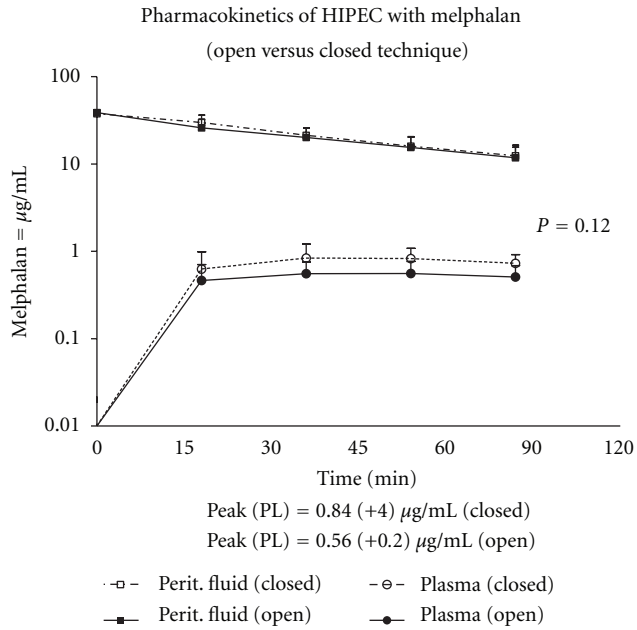

Figure 4: Pharmacokinetics of hyperthermic intraperitoneal melphalan in 3 patients in whom the closed technique was used compared to 12 patients treated with the open technique. The difference in the plasma levels was not statistically significant ($P = 0.12$).

additional systemic exposure in the last 30 minutes of treatment, we have modified the duration of melphalan HIPEC to 60 minutes. Our pharmacologic analysis also confirms a favorable peritoneal fluid to plasma AUC ratio of 36 when melphalan is used for HIPEC. This AUC ratio compares favorably with other chemotherapy agents that are commonly used for HIPEC, such as mitomycin C with a peritoneal fluid to plasma AUC ratio of 24 and cisplatin with an AUC ratio of 8 [18]. Urano and Ling studied the effect of hyperthermia on the cytotoxicity of melphalan showing maximal thermal enhancement of melphalan at 41.5°C [10]. Therefore, we have used a target temperature of 41-42°C for the perfusate in the current study.

Previous studies of normothermic intraperitoneal melphalan by Howell at al. showed the maximal tolerated dose to be approximately 70 mg/m^2 [17]. Our early experience with melphalan HIPEC at a dose of 70 mg/m^2 seemed to suggest an increased incidence of perioperative morbidity. Based on this clinical observation, we empirically decreased the dose to 60 mg/m^2. The current study provides an analysis of all the patients we have treated with heated intraperitoneal melphalan. The univariate analysis of clinical variables associated with grade 4 morbidity confirms our clinical impression and shows a statistically significant increase in grade 4 morbidity for patients treated with 70 mg/m^2 of melphalan. Other factors associated with increased morbidity were the number of peritonectomies and visceral resections. The morbidities observed in this group of patients were very similar to those observed in our recent study of patients undergoing cytoreductive surgery and HIPEC with mitomycin C and doxorubicin [19]. We did not observe morbidities specific to the use of melphalan.

Heated intraperitoneal chemotherapy can be delivered using the open or the closed abdomen technique. There have been no studies showing a clear advantage of one technique over the other. In our practice, we use both techniques depending on the clinical scenario. The closed technique is typically used when no cytoreduction of small bowel surfaces needs to be done or in patients with incomplete cytoreduction in whom the increased intra-abdominal pressure may provide improved tissue penetration of the chemotherapy solution. In this study, we compared the pharmacology of melphalan used with the open versus the closed abdomen technique. One might suspect that the closed technique would demonstrate an increased clearance of chemotherapy from the abdominal/pelvic space into the plasma. There is an increase in the total diffusion surface because the surface of the anterior abdominal wall and the surface of the skin and subcutaneous tissue are exposed to the chemotherapy in the closed method. These surfaces are only intermittently exposed with the open method. Also, there is a slight increase in pressure within the abdomen with the closed technique. However, pharmacologically, these expected differences were not observed and the pharmacology of melphalan is virtually identical regardless of the HIPEC technique used. We have previously shown that more significant changes in the diffusion surface, such as those seen with large visceral resections or in patients with a contracted peritoneal space do have an impact on the clearance of mitomycin C and doxorubicin from the peritoneal cavity [20, 21].

This study was primarily designed to provide information about the safety of hyperthermic intraperitoneal melphalan and to help establish an optimal dose and duration of melphalan HIPEC. It is not possible to make judgments regarding the clinical efficacy of melphalan in terms of its impact on survival from the current series. The patient population, in this study, is heterogeneous in terms of primary diagnosis as well as whether the cancer was primary or recurrent. Therefore, an analysis of survival, following HIPEC with melphalan, would not provide clinically useful insights into its efficacy.

In conclusion, our experience in 34 patients treated with hyperthermic intraperitoneal melphalan suggests that melphalan is a reasonable chemotherapy agent to use for HIPEC with a favorable pharmacologic and safety profile. We suggest a dose of 60 mg/m^2 for 60 minutes. Based on our experience, melphalan should be included in future studies comparing different HIPEC agents, especially for patients with peritoneal recurrence following initial cytoreduction plus HIPEC.

References

[1] P. H. Sugarbaker, "Epithelial appendiceal neoplasms," *Cancer Journal*, vol. 15, no. 3, pp. 225–235, 2009.

[2] L. Maggiori and D. Elias, "Curative treatment of colorectal peritoneal carcinomatosis: current status and future trends," *European Journal of Surgical Oncology*, vol. 36, no. 7, pp. 599–603, 2010.

[3] T. D. Yan, M. Deraco, D. Baratti et al., "Cytoreductive surgery and hyperthermic intraperitoneal chemotherapy for malignant peritoneal mesothelioma: multi-institutional experience," *Journal of Clinical Oncology*, vol. 27, no. 36, pp. 6237–6242, 2009.

[4] T. C. Chua, I. Al-Alem, A. Saxena, W. Liauw, and D. L. Morris, "Surgical cytoreduction and survival in appendiceal cancer peritoneal carcinomatosis: an evaluation of 46 consecutive patients," *Annals of Surgical Oncology*, vol. 18, no. 6, pp. 1540–1546, 2011.

[5] T. D. Yan, E. A. Brun, C. A. Cerruto, N. Haveric, D. Chang, and P. H. Sugarbaker, "Prognostic indicators for patients undergoing cytoreductive surgery and perioperative intraperitoneal chemotherapy for diffuse malignant peritoneal mesothelioma," *Annals of Surgical Oncology*, vol. 14, no. 1, pp. 41–49, 2007.

[6] L. Bijelic, T. D. Yan, and P. H. Sugarbaker, "Failure analysis of recurrent disease following complete cytoreduction and perioperative intraperitoneal chemotherapy in patients with peritoneal carcinomatosis from colorectal cancer," *Annals of Surgical Oncology*, vol. 14, no. 8, pp. 2281–2288, 2007.

[7] T. D. Yan, L. Bijelic, and P. H. Sugarbaker, "Critical analysis of treatment failure after complete cytoreductive surgery and perioperative intraperitoneal chemotherapy for peritoneal dissemination from appendiceal mucinous neoplasms," *Annals of Surgical Oncology*, vol. 14, no. 8, pp. 2289–2299, 2007.

[8] D. Baratti, S. Kusamura, A. D. Cabras, P. Dileo, B. Laterza, and M. Deraco, "Diffuse malignant peritoneal mesothelioma: failure analysis following cytoreduction and hyperthermic intraperitoneal chemotherapy (HIPEC)," *Annals of Surgical Oncology*, vol. 16, no. 2, pp. 463–472, 2009.

[9] G. Sarosy, B. Leyland-Jones, P. Soochan, and B. D. Cheson, "The systemic administration of intravenous melphalan," *Journal of Clinical Oncology*, vol. 6, no. 11, pp. 1768–1782, 1988.

[10] M. Urano and C. C. Ling, "Thermal enhancement of melphalan and oxaliplatin cytotoxicity in vitro," *International Journal of Hyperthermia*, vol. 18, no. 4, pp. 307–315, 2002.

[11] A. Testori, C. Verhoef, H. M. Kroon et al., "Treatment of melanoma metastases in a limb by isolated limb perfusion and isolated limb infusion," *Journal of Surgical Oncology*, vol. 104, no. 4, pp. 397–404, 2011.

[12] O. Glehen, O. A. Stuart, F. Mohamed, and P. H. Sugarbaker, "Hyperthermia modifies pharmacokinetics and tissue distribution of intraperitoneal melphalan in a rat model," *Cancer Chemotherapy and Pharmacology*, vol. 54, no. 1, pp. 79–84, 2004.

[13] P. H. Sugarbaker, "Peritonectomy procedures," *Annals of Surgery*, vol. 221, no. 1, pp. 29–42, 1995.

[14] A. D. Stephens, R. Alderman, D. Chang et al., "Morbidity and mortality analysis of 200 treatments with cytoreductive surgery and hyperthermic intraoperative intraperitoneal chemotherapy using the coliseum technique," *Annals of Surgical Oncology*, vol. 6, no. 8, pp. 790–796, 1999.

[15] A. Norda, U. Loos, M. Sastry, J. Goehl, and W. Hohenberger, "Pharmacokinetics of melphalan in isolated limb perfusion," *Cancer Chemotherapy and Pharmacology*, vol. 43, no. 1, pp. 35–42, 1999.

[16] R. L. Dedrick and M. F. Flessner, "Pharmacokinetic problems in peritoneal drug administration: tissue penetration and surface exposure," *Journal of the National Cancer Institute*, vol. 89, no. 7, pp. 480–487, 1997.

[17] S. B. Howell, C. E. Pfeifle, and R. A. Olshen, "Intraperitoneal chemotherapy with Melphalan," *Annals of Internal Medicine*, vol. 101, no. 1, pp. 14–18, 1984.

[18] P. H. Sugarbaker, J. T. Mora, P. Carmignani, O. A. Stuart, and D. Yoo, "Update on chemotherapeutic agents utilized for perioperative intraperitoneal chemotherapy," *Oncologist*, vol. 10, no. 2, pp. 112–122, 2005.

[19] T. D. Yan, L. Zappa, G. Edwards, R. Alderman, C. E. Marquardt, and P. H. Sugarbaker, "Perioperative outcomes of cytoreductive surgery and perioperative intraperitoneal chemotherapy for non-Appendiceal peritoneal carcinomatosis from a prospective database," *Journal of Surgical Oncology*, vol. 96, no. 2, pp. 102–112, 2007.

[20] K. Van der Speeten, O. A. Stuart, D. Chang, H. Mahteme, and P. H. Sugarbaker, "Changes induced by surgical and clinical factors in the pharmacology of intraperitoneal mitomycin C in 145 patients with peritoneal carcinomatosis," *Cancer Chemotherapy and Pharmacology*, vol. 68, no. 1, pp. 147–156, 2011.

[21] P. H. Sugarbaker, K. Van der Speeten, O. Anthony Stuart, and D. Chang, "Impact of surgical and clinical factors on the pharmacology of intraperitoneal doxorubicin in 145 patients with peritoneal carcinomatosis," *European Journal of Surgical Oncology*, vol. 37, no. 8, pp. 719–726, 2011.

Hindawi Publishing Corporation
Gastroenterology Research and Practice
Volume 2012, Article ID 836425, 5 pages
doi:10.1155/2012/836425

Clinical Study

Morbidity and Mortality Outcomes of Cytoreductive Surgery and Hyperthermic Intraperitoneal Chemotherapy at a Single Institution in Japan

Akiyoshi Mizumoto,[1] Emel Canbay,[2,3] Masamitsu Hirano,[1] Nobuyuki Takao,[1] Takayuki Matsuda,[1] Masumi Ichinose,[1] and Yutaka Yonemura[3]

[1] *Department of Surgery, Kusatsu General Hospital, Yabase Kusatsu 1660, Japan*
[2] *General Surgery Clinic, Kocaeli Derince Education and Research Hospital, Kocaeli, Turkey*
[3] *NPO Organization to Support Peritoneal Dissemination Treatment, Osaka, Japan*

Correspondence should be addressed to Akiyoshi Mizumoto, mizumotoakiyoshi1206@yahoo.co.jp

Received 2 March 2012; Revised 24 April 2012; Accepted 3 May 2012

Academic Editor: Yan Li

Background. Even though cytoreductive surgery (CRS) and hyperthermic intraperitoneal chemotherapy (HIPEC) are associated with a high morbidity and mortality rates, it has been reported that CRS and HIPEC improved survival of selected patients with peritoneal carcinomatosis. We aimed to report morbidity and mortality results of CRS and HIPEC from a single institution in Japan. *Methods and Results*. Total of 284 procedures of CRS were performed on patients with pseudomyxoma peritonei, peritoneal carcinomatosis (PC) from colon cancer and gastric cancer between 2007 and 2011 in our institution. The morbidity rate was 49% of all procedure, and grades I/II and grades III/IV complications were 28% and 17%, respectively. Most frequent complication was surgical site infections including intraabdominal abscess. The mortality rate was 3.5%, and reoperation was needed in 11% of all procedures. Univariate and multivariate analysis showed peritoneal carcinomatosis index (PCI) greater than 20 was the only significant factor for occurrence of postoperative complications ($P < 0.01$). In contrast, HIPEC significantly reduced postoperative complications ($P < 0.05$). *Conclusions*. The morbidity and mortality rates of our institution are comparable with previous reports that are in acceptable rates. Optimal patient selection such as patients with PCI less than 20 seems to be of paramount importance to CRS and HIPEC.

1. Introduction

Peritoneal carcinomatosis (PC) originated from gastrointestinal tract malignancies has been regarded as a lethal condition, and these patients have considered to receive systemic chemotherapy or palliative therapy. However, long-term survival is difficult to obtain by systemic chemotherapy. Sugarbaker [1] developed a novel therapeutic approach in the treatment of peritoneal surface malignancies with combination of peritonectomy and intraperitoneal chemotherapy applications in the mid 1990s. Since then, cytoreductive surgery (CRS) and hyperthermic intraperitoneal chemotherapy (HIPEC) have been recognized as a useful treatment for patients with PC arising from gastrointestinal cancer, gynecological malignancies or primary peritoneal surfaces malignancies as mesothelioma. Although survival benefit of this procedure has been reported in numerous literatures, this treatment is still not widely accepted worldwide because of the necessity of long learning curves for application of these techniques and high postoperative mortality and morbidity rates.

Literatures concerning CRS in Japan are almost limited to the gynecological field. Postoperative complication after CRS and HIPEC for PC originated from gastrointestinal malignancies has not been reported in Japan, except for PC originated from gastric cancer [2]. The purpose of this study is to investigate the morbidity and mortality outcomes of CRS and HIPEC for patients with pseudomyxoma peritonei and PC originated from colon cancer and gastric cancer in the single institution of Japan.

Table 1: Characteristics of the patients with peritoneal carcinomatosis.

Diagnosis	Pseudomyxoma peritonei	Colon cancer	Gastric cancer	All
Number of patients	205	29	16	250
Number of operations	236	32	16	284
Gender (male/female)	61/144	12/17	5/11	78/172
Age	58 ± 13 (28–88)	54 ± 14 (23–78)	48 ± 13 (30–68)	57 ± 13 (23–88)
PCI score	22 ± 12 (0–39)	12 ± 11 (0–39)	10 ± 10 (0–30)	20 ± 13 (0–39)
Operating time (minutes)	292 ± 100 (30–535)	257 ± 71 (95–413)	275 ± 67 (182–384)	288 ± 96 (30–535)
Blood loss (L)	2.6 ± 2.2 (0.5–11)	1.4 ± 1.2 (0.4–6.5)	1.9 ± 1.2 (0.5–4.5)	2.4 ± 2.1 (0.5–11)
CC 0, 1/CC 2, 3	147/89 (62%/38%)	25/7 (78%/22%)	11/5 (69%/31%)	183/101 (64%/36%)
HIPEC (yes/no)	141/95 (60%/40%)	27/5 (84%/16%)	13/3 (81%/19%)	181/103 (64%/36%)
Complications	118 (50%)	12 (38%)	9 (56%)	139 (49%)
None	118 (50%)	20 (68%)	7 (44%)	145 (51%)
Grades I/II	72 (31%)	5 (16%)	3 (19%)	80 (28%)
Grades III/IV	37 (16 %)	6 (19%)	6 (38%)	49 (17%)
Grade V	9 (3.8%)	1 (3%)	0	10 (3.5%)

2. Methods

2.1. Patients. Patients treated at the Kusatsu General Hospital between 2007 and 2011 with a diagnosis of PC were included in this study. Patients with extraperitoneal lesions were excluded from the study by contrast-enhanced computed tomography (CT) scans and/or positron emission tomography (PET). Careful preoperative evaluations including physical examination, hematological laboratory data, and cardiopulmonary function were performed. Patients characteristic are shown in Table 1. Total of 284 procedures of CRS were performed on patients with PC that those of 236 procedures on 205 patients were with pseudomyxoma peritonei, 32 procedures with 29 patients with PC originated from colon cancer, 16 procedures on 16 patients with PC originated from gastric cancer. They were 78 males (31%) and 172 females (69%). The mean ± SD age was 57 ± 13 years (range from 23 to 88 years old). This study was approved by the Local Ethical Committee of Kusatsu General Hospital.

2.2. Cytoreductive Surgery (CRS). All procedures were performed by the same surgical team, led by a single surgeon (Y. Yonemura). A mid-line skin incision from xiphoid process to pubic tubercle was performed. Peritoneal carcinomatosis index (PCI) was evaluated at the time of laparotomy as described before [3]. CRS included several visceral resections such as stomach, colon, ovary, uterus, spleen, gallbladder, and small bowel. Parietal peritonectomy, greater omentectomy, and lesser omentectomy were also included. The residual tumors were classified intraoperatively using the completeness of cytoreduction (CC) score [4]. CC-0 indicates that no macroscopical tumors remained and CC-1 residual tumor nodules less than 2.5 mm. CC-2 and CC-3 indicate residual tumor nodules between 2.5 mm and 2.5 cm and >2.5 cm, respectively.

2.3. Hyperthermic Intraperitoneal Chemotherapy (HIPEC). CRS was followed by HIPEC. Two inflow and one outflow drainage tubes were placed subphrenically and in the pelvic cavity, respectively. Abdominal cavity was lavaged 10 times by 1 L of normal saline before HIPEC. Then, heated normal saline was circulated for 60 minutes by using a roller pump and heat exchanger. 20 mg of mitomycin C and 100 mg of cisplatin were used as chemotherapeutic agents. Intraperitoneal temperature was monitored by placement of a thermometer in the abdominal cavity and maintained at approximately at 41-42°C. After HIPEC, abdominal cavity was lavaged by 10 times of 1 L of normal saline. HIPEC were not performed if a high risk of postoperative complications was concerned. Therefore, patients with poor preoperative performance status, serious laboratory data, intraoperative excessive bleeding, and very aggressive operation procedures did not receive HIPEC.

2.4. Data and Statistical Analysis. Data expressed the mean ± standard deviation, when appropriate. Postoperative complication was assessed based on Common Terminology Criteria for Adverse Events v 4.0. Content of postoperative complications was determined by the first complication observed after surgery or was selected more severe complication when multiple complications occurred almost simultaneously. All analyses were performed using StatMate IV for Windows (Atms, Tokyo, Japan). ANOVA, chi-square test or Fisher exact test was used to compare the number of postoperative complications when appropriate. Multivariate analysis was performed using a logistic regression analysis to detect independent risk factors for postoperative complications. $P < 0.05$ was considered as significant.

3. Results

Details of patients characteristic are shown in Table 1. The mean age of patients with gastric cancer was significantly younger than that of the patients with pseudomyxoma peritonei or colon cancer ($P < 0.01$). The mean PCI ± SD was 20 ± 13 in all patients, and was 22 ± 12 in pseudomyxoma peritonei, was 12 ± 11 in colon cancer, and was 10 ± 10 in

Table 2: Morbidity and mortality after cytoreductive surgery.

	Grades I/II	Grades III/IV	Grade V	All	Reoperation
SSIs; intraabdominal abscess	52	12		64	4
Gastric or intestinal perforation	2	13		15	11
Postoperative ileus	9	5		14	2
Anastomotic leakage	3	6	3	12	4
Urinary disturbance	9	1		10	
Intestinal fistula	5	3	1	9	2
Postoperative bleeding		6	2	8	8
Sepsis			3	3	
DIC		1	1	2	
Respiratory distress		1		1	
Diaphragmatic hernia		1		1	1
Total	80	49	10	139	32

SSIs: surgical site infections.

gastric cancer, respectively. The mean PCI of pseudomyxoma peritonei was significantly higher than that of colon cancer or gastric cancer ($P < 0.01$). The mean operating time was 288 ± 96 minutes, and there were no significant difference among patients groups. The mean intraoperative blood loss was 2.4 ± 2.1 L in all procedures, and that of pseudomyxoma peritonei was significantly higher than that of colon cancer or gastric cancer ($P < 0.01$).

Of the 284 CRS for PC, 64% of all procedures underwent to CC-0 or CC-1 resection, whereas 36% of all procedures resulted in CC-2 or CC-3 resection. There were no significant differences among pseudomyxoma peritonei, colon cancer and gastric cancer group, in terms of completeness of cytoreduction. HIPEC was performed in 64% of all procedures.

3.1. Morbidity and Mortality. The morbidity rate was 49% (139/284) in all procedures (Table 1). According to Common Terminology Criteria for Adverse Events, 80 cases (28%) were associated with grades I/II complications and 49 cases (17%) with grades III/IV complications in all procedures. grades III/IV complications in gastric cancer group (38%) seemed to be higher than that in the other groups, but the difference was not statistically significant.

Most frequent complication was surgical site infections including intraabdominal abscess, which was 46% (64/139) of total number of postoperative complications (Table 2). Gastric or small intestinal perforation, postoperative ileus, anastomotic leakage, urinary disturbance, intestinal fistula and postoperative bleeding were the other main complications after cytoreductive surgery and HIPEC. Gastric or small intestinal perforation, intraabdominal abscess, anastomotic leakage, and postoperative bleeding were the main severe complications as grade III complications.

Postoperative death within 30 days was observed in 10 cases (3.5%). The mortality rate was 3.8% (9/236) in pseudomyxoma peritonei group, 3% (1/32) in colon cancer group, and none in gastric cancer group (Table 1). The causes of death were anastomotic leakage, intestinal fistula, postoperative bleeding, sepsis, and DIC. Sepsis or multiorgan failure was developed due to anastomotic leakage or intestinal fistula. Reoperations were needed in 11% of all procedures (32/284). In particular, all cases of postoperative bleeding, and most cases of gastric or intestinal perforation were required reoperation (Table 2).

3.2. Learning Curve. When divided into two groups; the first 142 procedures and the latter 142 procedures, postoperative complication rate was 49% (69/142) and 47% (67/142), respectively. The occurrence of grades I/II, grades III/IV and grade V complication in the first half were 27% (38/142), 18% (26/142), and 3.5% (5/142), respectively, and those in the latter half were 27% (39/142), 16% (23/142) and 3.5% (5/142), respectively. There was no significant difference between groups ($P > 0.05$).

3.3. Risk Factors Associated with Postoperative Complications. Univariate analysis showed that PCI greater than 20, operation time longer than 5 hours, and blood loss greater than 2.5 L were the significant risk factors for the occurrences of postoperative complications. On the other hand, the complication rate in patients received HIPEC was significantly lower than that in the patients without HIPEC. Gender, age divided into 65 years old, origin of peritoneal carcinomatosis, or completeness of cytoreduction were not related to the occurrence of postoperative complications (Table 3).

Multivariate analysis using a logistic regression model showed that PCI higher than 20 was the only significant factor which increased the occurrence of postoperative complications. PCI greater than 20 was associated with 2.8 times increased the risk of the occurrence of postoperative complications (Table 4). Patients who receive HIPEC showed significant lower mortality and morbidity rate than patients not received HIPEC after multivariate analysis.

4. Discussion

PC of gastrointestinal origin has been regarded as inoperable conditions and treated by systemic chemotherapy or

Table 3: Univariate analysis of variables associated with postoperative complications.

Variables	Complications	No complications	*P*
Gender			0.47
Male	44	42	
Female	92	106	
Age			0.84
<65	98	105	
>65	38	43	
Diagnosis			0.39
Pseudomyxoma peritonei	115	121	
Colon cancer	12	20	
Gastric cancer	9	7	
PCI			<0.001
<20	48	94	
>20	85	51	
Operation time (hr)			<0.05
<5	63	91	
>5	73	57	
Blood loss (L)			<0.001
<2.5	67	113	
>2.5	68	35	
Completeness of cytoreduction			0.13
CC-0/1	81	102	
CC-2/3	55	46	
HIPEC			<0.001
Yes	72	109	
No	64	39	

Table 4: Multivariate analysis of risk factors for postoperative complication.

Variable	Hazard ratio	95% CI	*P* value
PCI	2.83	1.46–5.49	<0.01
Operation time	1.79	0.97–3.29	0.06
Blood loss	1.69	0.94–3.05	0.08
HIPEC	0.34	0.16–0.69	<0.01

palliative therapy. Based on the theory that peritoneal carcinomatosis is a locoregional disease, cytoreductive surgery and perioperative intraperitoneal chemotherapy have been applied in selected patients with peritoneal carcinomatosis. This procedure has achieved a 5-year survival rate of 73% in patients with pseudomyxoma peritonei [3], 45% in patients with PC of colon cancers [5], and 27% in patients with PC of gastric cancer [2]. However, high morbidity and mortality rates remain a serious concern of cytoreductive surgery and HIPEC.

Chua et al. [6] reviewed that a major morbidity rates ranges from 12% to 52% in high-volume centers. In the present study, the morbidity rate of 49% in all procedures and 21% more than grade III complication were observed, which were within the reported ranges. Considering severe situation of patients with PC and aggressive surgical method of cytoreductive surgery, the morbidity rate is thought to be acceptable because of obtained survival benefit from these procedures.

The most frequent complication in our institution was surgical site infections including intra-abdominal abscess, which occupied 46% of all complications. Intra-abdominal abscess was diagnosed by dirty discharge from drainage tube and computed tomography. Surgical site infections including intraabdominal abscess could be treated usually by drainage of infected site (81%, 52/64), by needle puncture to abscess cavity using ultrasound device or computed tomography (13%, 8/64), or by surgical reoperation (6%, 4/64). Surgery-related complications such as gastric or intestinal perforation, anastomotic leakage, intestinal fistula, and postoperative bleeding were other major complications after cytoreductive surgery and HIPEC.

The mortality rate after cytoreductive surgery and HIPEC has been reported to be ranging from 0.9% to 5.8% [6]. A mortality rate in our institution was 3.5% in all procedures. The cause of death included anastomotic leakage, sepsis, postoperative bleeding, intestinal fistula, and DIC. Reoperation was needed in 11% of all procedures. Serious complications required reoperations were gastric or intestinal perforation and postoperative bleeding.

Risk factors associated with postoperative complications from univariate analysis were PCI greater than 20, duration of operation longer than 5 hours and intraoperative bleeding greater than 2.5 L. Multivariate analysis showed that only PCI >20 was the significant risk factor for the occurrence of postoperative complications. Chua et al. [7] showed left upper quadrant peritonectomy and small bowel resection were the factors that predicted for a poor perioperative outcome. Saxena et al. [8] showed that ASA more than 3 and an operation length more than 10 h were the significant risk factors for grades IV/V morbidity in patients with pseudomyxoma peritonei.

It has been demonstrated that HIPEC is not a significant risk factor associated with postoperative complications, although HIPEC may affect bone marrow activity, renal function or operating duration. Unexpectedly, we found that patients received HIPEC were associated with significant lower complication rate by univariate and multivariate analysis. The reason is not known, but the indication of which we usually did not apply HIPEC on patients with CC-2/3, excessive intraoperative bleeding, poor laboratory data or performance status more than 3, might affect the results obtained in this study. Further studies are needed to clarify the role of HIPEC in postoperative complications after CRS.

Elias et al. [3] and Glehen et al. [9] reported that a risk of morbidity and mortality after cytoreductive surgery and HIPEC significantly is related to the institution, where the treatment was performed and concluded that this procedure should be centralized to institutions with expertise in the management of peritoneal carcinomatosis. Moreover, it is demonstrated that learning curve is an important factor to reduce the occurrence of postoperative complications [10, 11]. Approximately, 130–140 cases are reported to be necessary to minimize mortality and morbidity after the procedure [10, 11]. In this study, we did not find any difference between the first 142 and the latter 142 cases in terms of the occurrence of postoperative complications. The significant difference between groups was the ratio of CC-0/1 and CC-2/3 resections. CC-0/1 resection was performed 55% of the procedures (78/141) in the first half and 77% (108/141) in the latter half ($P < 0.05$, data not shown). Regarding the similar complication rates between two groups, we thought that we performed all surgical procedures with one experienced surgeon. Accumulation of experience in this procedure in our experienced surgeon could be the reason similar complication rates in the two groups. Even though, morbidity and mortality rates were not differed between two groups, complete resection rates were increased in latter group still suggesting that there was a learning curve associated with this procedure.

In conclusion, the morbidity and mortality rate after cytoreductive surgery and HIPEC in our institution did not differ from previous reports. The morbidity and mortality rate after the procedure are compatible to those after pancreaticoduodenectomy or esophagotomy, which are widely performed all over the world. Up to now, long-term survival of patients with PC can be obtained only by cytoreductive surgery and HIPEC. This procedure could be, therefore, considered as a standard treatment of PC in selected patients.

References

[1] P. H. Sugarbaker, "Peritonectomy procedures," *Annals of Surgery*, vol. 221, no. 1, pp. 29–42, 1995.

[2] Y. Yonemura, Y. Endou, M. Shinbo et al., "Safety and efficacy of bidirectional chemotherapy for treatment of patients with peritoneal dissemination from gastric cancer: selection for cytoreductive surgery," *Journal of Surgical Oncology*, vol. 100, no. 4, pp. 311–316, 2009.

[3] D. Elias, F. Gilly, F. Quenet et al., "Pseudomyxoma peritonei: a French multicentric study of 301 patients treated with cytoreductive surgery and intraperitoneal chemotherapy," *European Journal of Surgical Oncology*, vol. 36, no. 5, pp. 456–462, 2010.

[4] P. Jacquet and P. H. Sugarbaker, "Clinical research methodologies in diagnosis and staging of patients with peritoneal carcinomatosis," *Cancer Treatment and Research*, vol. 82, pp. 359–374, 1996.

[5] P. H. Sugarbaker, "Peritoneal surface oncology: review of a personal experience with colorectal and appendiceal malignancy," *Techniques in Coloproctology*, vol. 9, no. 2, pp. 95–103, 2005.

[6] T. C. Chua, T. D. Yan, A. Saxena, and D. L. Morris, "Should the treatment of peritoneal carcinomatosis by cytoreductive surgery and hyperthermic intraperitoneal chemotherapy still be regarded as a highly morbid procedure?: a systematic review of morbidity and mortality," *Annals of Surgery*, vol. 249, no. 6, pp. 900–907, 2009.

[7] T. C. Chua, A. Saxena, J. F. Schellekens et al., "Morbidity and mortality outcomes of cytoreductive surgery and perioperative intraperitoneal chemotherapy at a single tertiary institution: towards a new perspective of this treatment," *Annals of Surgery*, vol. 251, no. 1, pp. 101–106, 2010.

[8] A. Saxena, T. D. Yan, T. C. Chua, and D. L. Morris, "Critical assessment of risk factors for complications after cytoreductive surgery and perioperative intraperitoneal chemotherapy for pseudomyxoma peritonei," *Annals of Surgical Oncology*, vol. 17, no. 5, pp. 1291–1301, 2010.

[9] O. Glehen, F. N. Gilly, F. Boutitie et al., "Toward curative treatment of peritoneal carcinomatosis from nonovarian origin by cytoreductive surgery combined with perioperative intraperitoneal chemotherapy: a multi-institutional study of 1290 patients," *Cancer*, vol. 116, no. 24, pp. 5608–5618, 2010.

[10] R. M. Smeenk, V. J. Verwaal, and F. A. Zoetmulder, "Learning curve of combined modality treatment in peritoneal surface disease," *British Journal of Surgery*, vol. 94, no. 11, pp. 1408–1414, 2007.

[11] S. Kusamura, D. Baratti, and M. Deraco, "Multidimensional analysis of the learning curve for cytoreductive surgery and hyperthermic intraperitoneal chemotherapy in peritoneal surface malignancies," *Annals of Surgery*, vol. 255, no. 2, pp. 348–356, 2012.

Hindawi Publishing Corporation
Gastroenterology Research and Practice
Volume 2012, Article ID 378064, 9 pages
doi:10.1155/2012/378064

Review Article

Pharmacokinetics of the Perioperative Use of Cancer Chemotherapy in Peritoneal Surface Malignancy Patients

K. Van der Speeten,[1,2,3] K. Govaerts,[1] O. A. Stuart,[3] and P. H. Sugarbaker[3]

[1] *Department of Surgical Oncology, Oost-Limburg Hospital, Schiepse Bos 6, 3600 Genk, Belgium*
[2] *Department of Biochemistry, Faculty of Medicine, University Hasselt, 3590 Diepenbeek, Belgium*
[3] *Washington Cancer Institute, Washington Hospital Center, Washington, DC 20010, USA*

Correspondence should be addressed to K. Van der Speeten, kurt.vanderspeeten@zol.be

Received 10 March 2012; Accepted 23 April 2012

Academic Editor: Yan Li

Background. The peritoneal surface is an acknowledged locoregional failure site of abdominal malignancies. Previous treatment attempts with medical therapy alone did not result in long-term survival. During the last two decades, new treatment protocols combining cytoreductive surgery with perioperative intraperitoneal and intravenous cancer chemotherapy have demonstrated very encouraging clinical results. This paper aims to clarify the pharmacologic base underlying these treatment regimens. *Materials and Methods*. A review of the current pharmacologic data regarding these perioperative chemotherapy protocols was undertaken. *Conclusions*. There is a clear pharmacokinetic and pharmacodynamic rationale for perioperative intraperitoneal and intravenous cancer chemotherapy in peritoneal surface malignancy patients.

1. Introduction

The peritoneal surface is an established failure site for digestive and gynecological malignancies as well as the primary location for some tumors [1–7]. Historical attempts at cure with medical therapy alone have never resulted in long-term survival. During the last two decades, new treatment modalities combining extensive cytoreductive surgery (CRS) and perioperative intraperitoneal and intravenous cancer chemotherapy have emerged. In several phase II and phase III trials, these new therapeutic approaches for peritoneal surface malignancy have shown very promising clinical results [8–18]. Although further clinical trials are mandatory, another route of exploration is equally important for further improvement of these combined treatment regimens. Pharmacologic studies of perioperative cancer chemotherapy should guide further progress in this field and offer clues for a more standardization. This paper aims to review the current pharmacologic data and point out areas of controversy needing clarification.

2. Dose Intensification

Dose intensification between the peritoneal compartment and the body compartment is the basic underlying pharmacologic rationale for all intraperitoneal therapy as initially stated by Dedrick et al. [19, 20]. The two above-mentioned compartments are separated by a semi permeable membrane the peritoneum. In 1941, Baron reported an elaborated description of the ultrastructure of the peritoneum in man [21]. The peritoneum consists of a monolayer of mesothelial cells supported by a basement membrane and five layers of connective tissue which account for a total thickness of 90 μm. The connective tissue layers include interstitial cells and a matrix of collagen, hyaluronan, and proteoglycans. The cellular component consists of fibroblasts, pericytes, parenchymal cells, and blood capillaries. Contrary to intuitive thinking, it is not the mesothelial lining which is the main transport barrier. Flessner et al. demonstrated in a rodent model that neither removal of the stagnant fluid layer on the mesothelium nor removal of the mesothelial

lining influenced the transport over the barrier [22]. This has been confirmed in human studies in patients undergoing partial or total peritonectomy showing that the clearance of mitomycin C was not significantly changed by the removal of the mesothelium [23, 24]. Basic research suggests that rather the blood capillary wall and the surrounding interstitium are the most important barriers for transport from the peritoneal space to the plasma [25]. Fluid enters the vascular compartment by diffusion from the peritoneal compartment or by absorption through the peritoneal lymphatic stomata which are concentrated on the diaphragmatic surface [26, 27]. Diffusion of fluid through the parietal peritoneum generally results in flow to the plasma compartment. Drainage through the visceral peritoneum covering the surfaces of liver, spleen, stomach, small and large bowel, and mesentery is into the portal venous blood [28].

The two-compartment Dedrick model of intraperitoneal chemotherapy is shown in Figure 1. A simplified mathematical formula describes the transport as follows: rate of mass transfer = PA ($C_P - C_B$), where PA = permeability area (PA = effective contact area x permeability), C_P = concentration in peritoneal cavity, and C_B = concentration in the blood [29]. This formula indicates the importance of the size of the effective contact area of the peritoneal membrane. One should keep in mind that although the equation permits calculation of the pharmacokinetic advantage, the model does not predict the actual penetration of the cancer chemotherapy drug into the tissue or tumor nodule [30]. It neither predicts the value of the effective contact area. It simply describes the transfer between two compartments.

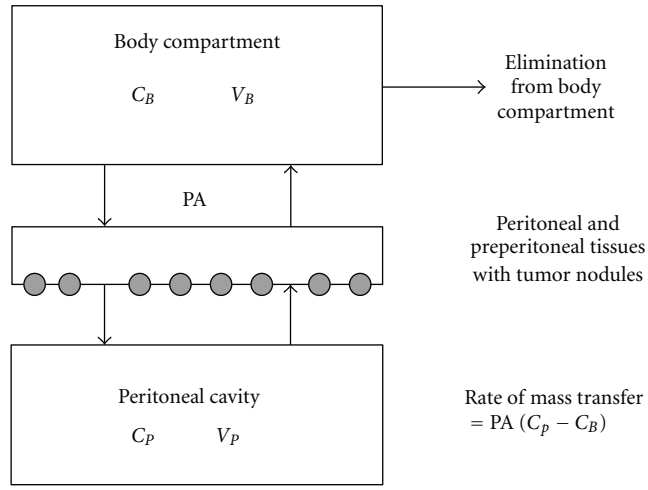

Figure 1: Traditional two-compartment model of peritoneal transport in which transfer of a drug from the peritoneal cavity to the blood occurs across the "peritoneal membrane." The permeability-area product (PA) governs this transfer and can be calculated by measuring the rate of drug disappearance from the cavity and dividing by the overall concentration difference between the peritoneal cavity and the blood (or plasma). C_B: the free drug concentration in the blood (or plasma); V_B: volume of distribution of the drug in the body; C_P: the free drug concentration in the peritoneal fluid; V_P: volume of the peritoneal cavity. Modified from R. L. Dedrick, M. F. Flessner: pharmacokinetic problems in peritoneal drug administration: Tissue penetration and surface exposure [31].

Table 1: Molecular weight and area under the curve ratios of intraperitoneal exposure to systemic exposure of chemotherapeutic agents used to treat peritoneal carcinomatosis.

Drug	Molecular weight (Daltons)	Area under the curve ratio
5-Fluorouracil	130.08	250
Carboplatin	371.25	10
Cisplatin	300.1	7.8
Docetaxel	861.9	552
Doxorubicin	579.99	230
Etoposide	588.58	65
Floxuridine	246.2	75
Gemcitabine	299.5	500
Irinotecan	677.19	N/A
Melphalan	305.2	93
Mitomycin C	334.3	23.5
Mitoxantrone	517.41	115–255
Oxaliplatin	397.3	16
Paclitaxel	853.9	1000
Pemetrexed	597.49	40.8

3. Drugs Used in Perioperative Cancer Chemotherapy Protocols

Table 1 provides an overview of drugs commonly used in perioperative cancer chemotherapy protocols and their main pharmacologic characteristics.

3.1. Mitomycin C. Mitomycin C is an alkylating antibiotic whose most important mechanism of action is through DNA cross-linking. Although mitomycin C is not regarded as a prodrug, it is not active against cancerous tissue as the unchanged molecule. The drug is modified as it enters the cell into an active state [34]. It has been used extensively in intraperitoneal cancer chemotherapy treatment protocols in appendiceal, gastric, and colorectal peritoneal carcinomatosis (PC) patients [8, 24, 35, 36]. Barlogie et al. suggested in vitro thermal enhancement of mitomycin C [37]. Controversies still exist regarding the proper dosimetry of the chemotherapy solution. Some institutions use a single dose of mitomycin C, others a double dose, and still others triple dose the drug over a 90-minute time period [38–40]. A remarkable difference in drug dosimetry between different groups of investigators is reported. Van Ruth and coworkers at the Dutch Cancer Institute reported a dose-finding study [40]. Their data suggest that a dose of 35 mg/m^2 resulted in the highest peritoneal/plasma area under the curve (AUC) ratio with acceptable toxicity. In order to maintain the concentration throughout the 90 minutes perfusion time, the dose was divided into three fractions: 50% at the start, 25% after 30 minutes, and 25% at 60 minutes. The toxicity profile of mitomycin C, including anastomotic dehiscence and impaired wound healing, has been well characterized

[24, 41–43]. Our data suggest large amounts of mitomycin C (62%) remain within the body compartment after the 90-minute hyperthermic intraperitoneal treatment [24].

3.2. Cisplatin. Cisplatin (*cis*-diamminedichloroplatinum-III CDDP) causes apoptotic cell death by formation of DNA adducts [44]. It has been well studied in the setting of adjuvant intraperitoneal chemotherapy of residual small volume ovarian cancer after CRS. Three randomized trials showed a significant survival benefit [45–47]. In the setting of cytoreductive surgery and hyperthermic intraperitoneal peroperative chemotherapy (HIPEC), cisplatin has been used for intracavitary therapy of ovarian cancer, gastric cancer, and peritoneal mesothelioma. Urano and coworkers showed an excellent in vitro and in vivo thermal augmentation of cisplatin [48].

3.3. Oxaliplatin. Oxaliplatin (oxalato-1,2-diaminocyclohexane-platinum(II)) is a third generation platinum complex with a similar cytotoxic mechanism as cisplatinum. In contrast with cisplatin, it has a proven activity in colorectal and appendiceal malignancies [49]. Its clinical use in PC patients as a component of bidirectional intraoperative chemotherapy has been pioneered by Elias and Sideris [50]. In a dose escalation and pharmacokinetic study, they showed that 460 mg/m^2 of oxaliplatin in 2 L/m^2 of chemotherapy solution over 30 minutes was well tolerated [51]. The low AUC ratio is compensated by the rapid absorption of the drug into the tissue. In contrast to cisplatin and mitomycin, oxaliplatin is not stable in chloride-containing solutions and can only be administered in dextrose 5% [52]. This may result in serious electrolyte disturbances and hyperglycemia during the intracavitary therapy [53].

A recent murine pharmacokinetic study with oxaliplatin confirmed its substantial heath augmentation [54].

3.4. Carboplatin. Carboplatin ((1,1-cyclobutanedicarboxylate)platinum(II)) is a higher molecular weight platinum compound than cisplatin which at the present time is mostly used in normothermic intraperitoneal chemotherapy protocols in patients with advanced ovarian cancer. Cjezka et al. in a clinical study with normothermic carboplatin reported a relative bioavailability (calculated as AUC values) which was at least 6-times higher in the intraperitoneal fluid than in the serum for 48 hours [55]. Los and coworkers compared carboplatin and cisplatin after intraperitoneal administration in a rat model of peritoneal carcinomatosis [56]. Their data demonstrate that despite a clear pharmacokinetic advantage of carboplatin over cisplatin, its capacity to penetrate into peritoneal cancer nodules and tumor cells is far lower than that of cisplatin. These data limit its clinical application.

3.5. Doxorubicin. Doxorubicin ($C_{27}H_{29}NO_{11}$) or hydroxyldaunorubicin (adriamycin) is an anthracycline antibiotic. Although being categorized as a DNA-intercalating drug, the actual mechanism of action is a critical interaction of doxorubicin with the cell surface membrane [57, 58]. Because of its wide in vitro and in vivo activity against a broad range of malignancies, its slow clearance from the peritoneal compartment due to the high molecular weight of the hydrochloride salt (579, 99 Dalton), its favorable area under the curve ratio of intraperitoneal to intravenous concentration times of 230, and the absence of risk for dose-limiting cardiotoxicity when used as a single-shot intraperitoneal instillation, doxorubicin was considered a potential beneficial agent for perioperative intraperitoneal delivery. This was supported by both experimental and clinical pharmacokinetic data [59–64].

3.6. Gemcitabine. Gemcitabine (2′,2′-difluorodeoxycitidine) is a pyrimidine analogue with a wide range of in vitro cytotoxic activity, particularly against pancreatic cancer. Pestiau et al. investigated the pharmacokinetics and tissue distribution of intraperitoneal gemcitabine in a rat model [65]. The AUC ratio (intraperitoneal/intravenous) after intraperitoneal administration was 26.8 ± 5.8 and as such favorable for intraperitoneal administration. Several investigators explored the use of normothermic intraperitoneal gemcitabine in advanced cancer outside the setting of cytoreductive surgery [66–68]. Resected advanced pancreatic cancer with high risk of recurrence in the operative field is a potential indication for intraoperative intraperitoneal administration of heated gemcitabine in an adjuvant setting [69].

3.7. Melphalan. Melphalan (L-phenylalanine mustard) is a chemotherapy drug belonging to the class of nitrogen mustard alkylating agents. Alberts et al. were the first to investigate the pharmacokinetics of intraperitoneal melphalan [70]. Melphalan systemic absorption from the peritoneal cavity averaged only 39% of the administered dose. Urano showed a remarkable heat augmentation of melphalan [48]. Glehen and coworkers investigated the effect of hyperthermia on the pharmacokinetics of intraperitoneal melphalan in a rat model [71]. Hyperthermia decreased the AUC of peritoneal fluid without increasing the plasma AUC. Intra-abdominal tissue concentrations were markedly elevated compared to normothermic controls. Sugarbaker et al. in a pharmacokinetic and phase-II study of intraoperative intraperitoneal melphalan showed that 90% of the cancer chemotherapy drug was absorbed during the 90-minute procedure with a 30-times higher exposure at the peritoneal surface than in the blood [72]. Concentrations in tumor nodules were 10-times higher than concentrations in the blood. This favorable pharmacokinetic profile and tissue distributions, combined with cytotoxic activity against a wide range of malignancies, makes melphalan an excellent salvage drug for intraperitoneal treatment protocols.

3.8. Taxanes. Paclitaxel and docetaxel are taxanes considered for i.p. chemotherapy. The taxanes stabilize the microtubule against depolymerization, thereby disrupting normal microtubule dynamics [73]. They exert cytotoxic activity against a broad range of tumors. Due to their high molecular weight these molecules have a remarkable high AUC ratio of 853 and 861 respectively, [74]. This translates itself into a clear pharmacokinetic advantage for intraperitoneal administration [75]. The data regarding possible thermal augmentation of taxanes are conflicting [76–79]. Taxanes

have been used in a neoadjuvant intraperitoneal setting as well as intraoperatively and postoperatively. Postoperative intraperitoneal paclitaxel conferred a survival benefit in this postoperative setting. Their cell-cycle specific mechanism of action makes them a particular good candidate for repetitive application such as in early postoperative intraperitoneal chemotherapy (EPIC) or normothermic adjuvant postoperative intraperitoneal chemotherapy [45, 46, 80–82].

3.9. 5-Fluorouracil. 5-Fluorouracil is an inhibitor of thymidylate synthase. Since thymidine is the only nucleotide precursor specific to DNA, thymidilate synthase is an obvious target for cytotoxic agents. 5-Fluorouracil is intracellularly metabolized in two steps to its active metabolite, 5-fluoro-2′-deoxyuridine monophosphate (FdUMP). This molecule will, in the presence of reduced folate, bind at the same site and with the same affinity as deoxyuridine monophosphate (dUMP) and ultimately impair the enzymatic activity of the thymidilate synthetase [83]. The action of 5-fluorouracil is therefore cell cycle specific. Also 5-FU by its metabolites 5-fluoro-uridine diphosphate and 5-fluoro-uridine triphosphate gets incorporated in RNA, resulting in a second cytotoxic pathway. Minor augmentation of 5-fluorouracil by mild hyperthermia is reported [84, 85]. 5-Fluorouracil is not chemically compatible with other drugs in a mixed solution for infusion or instillation. These characteristics limit the use of 5-fluorouracil perioperatively to either early postoperative intraperitoneal chemotherapy or intraoperative intravenous 5-fluorouracil.

3.10. Pemetrexed. Pemetrexed is a multitargeted antifolate. It is an analogue of folic acid with cytotoxic activity against a variety of malignancies, especially mesothelioma and colon cancer. It belongs to the antimetabolites. It acts mainly as a thymidilate synthase inhibitor but is also unique in terms of cellular transport and lipid solubility [86]. Pestieau et al. reported favorable intraperitoneal pharmacokinetics [87]. It is currently under investigation for the intraperitoneal treatment of peritoneal mesothelioma.

3.11. Ifosfamide. Ifosfamide is a prodrug which needs the cytochrome P 450 system of liver or red blood cells to be activated to its active metabolite 4-hydroxyifosfamide. Consequently, it requires intravenous administration rather than intraperitoneal instillation for its cytotoxic activity. It is one of four drugs that show true heat synergy, with 5- to 10-times the duration of tumor control with 41.5°C heat as compared to normal temperatures [48]. It may be an ideal systemic drug to increase the cytotoxicity of hyperthermic intraperitoneal peroperative chemotherapy. Our pharmacokinetic data show the presence of ifosfamide and its active metabolite in peritoneal tumor nodules after intravenous continuous infusion during bidirectional intraoperative chemotherapy. In these bidirectional treatment protocols, intravenous and intraperitoneal routes of administration are combined after CRS inside the operating room.

Table 2: Pharmacokinetic and pharmacodynamic variables involved in the administration of perioperative cancer chemotherapy in peritoneal surface malignancy patients.

Pharmacokinetic variables	Pharmacodynamic variables
Dose	Temperature
Volume	Nodule size of residual tumor
Duration	Density
Carrier solution	Binding
Pressure	Interstitial fluid pressure
Vasoactive agents	Charge
Macromolecular vehicles	Vascularity

4. Pharmacologic Variables in Perioperative Chemotherapy

Pharmacokinetics describe what the body does to the drug, whereas pharmacodynamics describe what the drug does to the body. Table 2 summarizes the pharmacokinetic and pharmacodynamic variables involved in perioperative intraperitoneal and intravenous chemotherapy. One of the most challenging problems hindering a further wide application of these new treatment modalities is the compelling variety of regimens available worldwide. These protocols are sometimes based on little or no pharmacologic data. Furthermore this variability in dosimetry and technology makes multicenter registry or trials very difficult. The international scientific community must come up with a consensus on standardizing the application. This should be based on a thorough review of the available pharmacologic data and clinical results.

5. Pharmacologic Controversies

5.1. Concentration-Based or Body Surface Area-(BSA-) Based Dosimetry. Most groups use a drug dose based on calculated body surface area (mg/m^2). However, Rubin et al. demonstrate that there is an imperfect correlation between actual peritoneal surface area and calculated body surface area and there may be sex differences in peritoneal surface areas, which in turn affects absorption characteristics [88]. The female has a 10% larger peritoneal surface in proportion to body size than the male. There have been attempts to estimate the functional peritoneal surface area through applying stereological methods to computer tomography (CT) scans by extrapolating data from cadaver measurements [89, 90]. Body surface area is an accurate predictor of drug metabolism and is useful for estimating systemic drug toxicity.

Some groups use a totally different dosimetry regimen based on concentration. The total amount of cancer chemotherapy is mixed in a large volume of carrier solution (usually six liters) that is placed in a reservoir. For example, Deraco and Rossi at the Milan Cancer Institute use doxorubicin 15.25 mg/m^2/L and cisplatin 43 mg/m^2/L with a total volume of 6 liters. Glehen and Gilly from Lyon have used mitomycin C 0.5 mg/kg and cisplatin 0.7 mg/kg in a total volume of 4 to 6 liters [91–94]. In this closed method, the amount of

chemotherapy solution in contact with the peritoneal surface is determined by multiple variables: the amount of distention (between 2 and 6 liters) of the abdominal cavity, which is induced by the chemotherapy solution, the patient's sex, the amount of ascites present preoperatively, and the extent of the visceral resection. The big advantage of a concentration-based system is that the residual tumor nodules after CRS are exposed to a constant diffusional force and thus cytotoxicity. Unfortunately, the prize to be paid for a better prediction of the efficacy of the intraperitoneal chemotherapy is a high unpredictability of the plasmatic cancer chemotherapy levels and thus toxicity. Indeed, according to the above-mentioned Dedrick formula of transport over the peritoneal membrane, an increase in the volume of intraperitoneal chemotherapy solution will cause an increase in both diffusion surface and the amount of drug transferred from peritoneal space to plasma. For example, in 10 patients dialyzed with different volumes ranging from 0.5 up to 3 liters, there is a linear rise in mass transfer [95].

Other factors contribute to the controversy over the proper dosage of chemotherapy solution. Some institutions use a single dose of the intraperitoneal drug; others use a double, or even triple, dose of the same drug over a 90-minute period [96–98].

5.2. Pharmacokinetics versus Pharmacodynamics. Until recently, the pharmacologic efficacy of intraperitoneal cancer chemotherapy protocols was assessed by looking at the pharmacokinetics of the i.p. and i.v. compartments. The efficacy of the IP protocol was then quantified by calculating the area-under-the-curve (AUC) ratio of the IP exposure over the AUC of the IV exposure. This, however, does not take into account any pharmacodynamic variables. Figure 2 demonstrates that the pharmacodynamic event of doxorubicin binding to the tumor nodule results in higher intratumoral concentrations than can be predicted by the simple IP/IV pharmacokinetics [32]. Another example of the equal importance of pharmacodynamics is shown in Figure 3. With identical pharmacokinetics the amount of doxorubicin showing up in the less dense diffuse peritoneal adenomysis (DPAM) subtype of appendiceal malignancy PC is statistically significantly lower than in the more dense peritoneal mucinous carcinomatosis (PMCA) nodules [32]. The identical pharmacokinetic advantage (expressed as AUC IP/IV ratios) resulted in different drug levels according to the density of the tumor nodules; this stressed the importance of pharmacodynamic variables such as tumor nodule density, size, and vascularity. Increased awareness of the pharmacodynamic aspects of these treatment protocols has also been reported by Ceelen et al. [99]. Therefore, it was proposed that the tumor nodule was a more appropriate pharmacological endpoint than AUC ratios.

5.3. Adding Intravenous Intraoperative Chemotherapy to the Equation. By combining intraoperative intravenous and intraoperative intraperitoneal cancer chemotherapy, a bidirectional diffusion gradient is created through the intermediate tissue layer which contains the cancer nodules. This offers opportunities for optimizing cancer chemotherapy delivery to the target peritoneal tumor nodules. In 2002, Elias et al. first reported the clinical use of intraoperative intravenous 5-fluorouracil and leucovorin in conjunction with oxaliplatin-based hyperthermic intraperitoneal perioperative chemotherapy [100]. Figure 4 demonstrates the concentrations of 5-fluorouracil in tumor nodules that were harvested during bidirectional (intraperitoneal doxorubicin and mitomycin C plus rapid infusion intravenous 5-fluorouracil) intraoperative chemotherapy treatment [33]. The rapid distribution of the 5-fluorouracil after IV administration affects all compartments similarly. The metabolism of the 5-fluorouracil on the other hand is mainly restricted

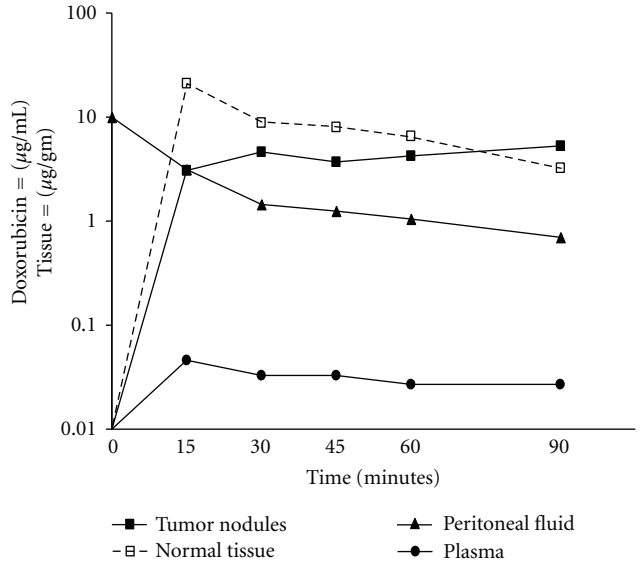

Figure 2: Doxorubicin concentration in plasma, peritoneal fluid, tumor nodules, and normal adjacent tissues [32].

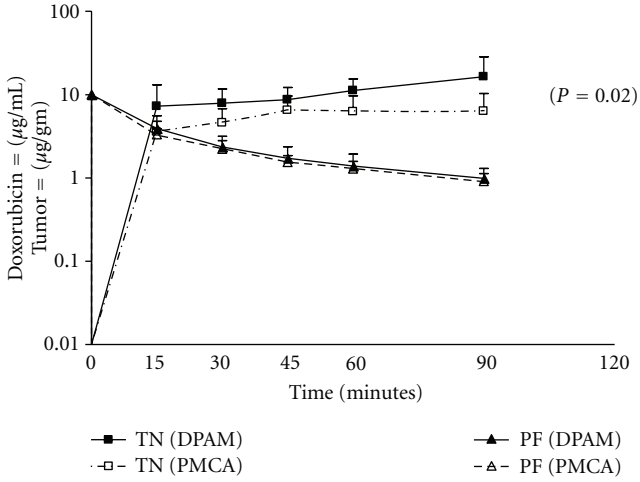

Figure 3: Doxorubicin levels in appendiceal tumor tissue showing diffuse peritoneal adenomucinosis (DPAM) versus peritoneal mucinous carcinomatosis (PMCA). Peritoneal fluid concentrations are also shown. TN: tumor nodule; PF: peritoneal fluid [32].

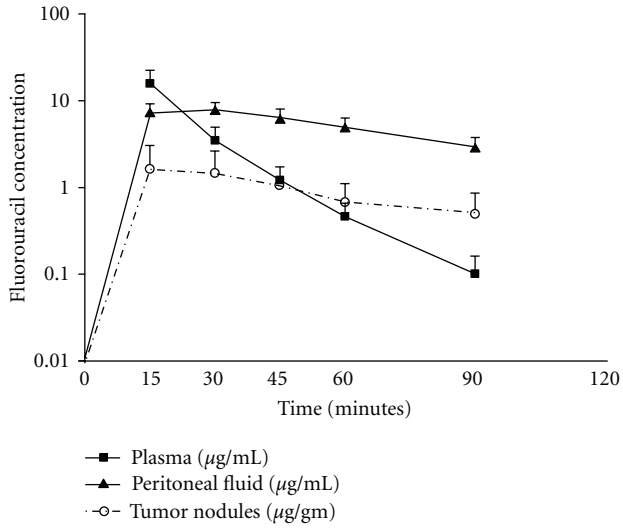

Figure 4: 5-Fluorouracil concentrations in plasma, peritoneal fluid, and tumor nodules after intravenous administration during hyperthermic intraperitoneal chemotherapy procedure [33].

to the plasma compartment by the liver. The high level of 5-fluorouracil persists within the peritoneal fluid because the drug can only leave the peritoneal space by back diffusion through the peritoneal and subperitoneal tissues; the enzyme dihydropyrimidine dehydrogenase is not present in the artificial ascites fluid. These data show clear pharmacokinetic advantage for the intraoperative intravenous administration of 5-fluorouracil. Although 5-fluorouracil is administered as a normothermic intravenous solution, it penetrates into the heated tumor nodules. Normothermic administered 5-fluorouracil becomes subject to augmentation of mild hyperthermia of the subperitoneal compartment. Therefore, heat targeting is achieved by modulating the timing of intravenous chemotherapy.

Recently, we were able to demonstrate a similar pharmacokinetic advantage and heat targeting of intraoperative intravenous ifosfamide (continuous infusion over 90 minutes) [101].

6. Conclusions

The last two decades saw the emergence of perioperative cancer chemotherapy protocols in the treatment of PC patients. This has resulted in remarkable clinical successes in contrast with prior failures. Now that the concept is proven, time has come to further improve the treatment protocols. Building more pharmacologic data on perioperative chemotherapy in PC patients should result in both more standardization and better clinical outcome.

References

[1] D. G. Jayne, S. Fook, C. Loi, and F. Seow-Choen, "Peritoneal carcinomatosis from colorectal cancer," *British Journal of Surgery*, vol. 89, no. 12, pp. 1545–1550, 2002.

[2] J. T. Brodsky and A. M. Cohen, "Peritoneal seeding following potentially curative resection of colonic carcinoma: implications for adjuvant therapy," *Diseases of the Colon and Rectum*, vol. 34, no. 8, pp. 723–727, 1991.

[3] D. Z. J. Chu, N. P. Lang, C. Thompson, P. K. Osteen, and K. C. Westbrook, "Peritoneal carcinomatosis in nongynecologic malignancy. A prospective study of prognostic factors," *Cancer*, vol. 63, no. 2, pp. 364–367, 1989.

[4] B. Sadeghi, C. Arvieux, O. Glehen et al., "Peritoneal carcinomatosis from non-gynecologic malignancies: results of the EVOCAPE 1 multicentric prospective study," *Cancer*, vol. 88, no. 2, pp. 358–363, 2000.

[5] N. A. Shepherd, K. J. Baxter, and S. B. Love, "The prognostic importance of peritoneal involvement in colonic cancer: a prospective evaluation," *Gastroenterology*, vol. 112, no. 4, pp. 1096–1102, 1997.

[6] A. Jemal, T. Murray, E. Ward, and A. Samuels, "Cancer statistics, 2005," *Ca-A Cancer Journal for Clinicians*, vol. 55, pp. 10–30, 2005.

[7] A. Poveda, "Ovarian cancer treatment: what is new," *International Journal of Gynecological Cancer*, vol. 13, no. 2, pp. 241–250, 2003.

[8] V. J. Verwaal, S. Van Ruth, E. De Bree et al., "Randomized trial of cytoreduction and hyperthermic intraperitoneal chemotherapy versus systemic chemotherapy and palliative surgery in patients with peritoneal carcinomatosis of colorectal cancer," *Journal of Clinical Oncology*, vol. 21, no. 20, pp. 3737–3743, 2003.

[9] V. J. Verwaal, S. Bruin, H. Boot, G. van Slooten, and H. van Tinteren, "8-Year follow-up of randomized trial: cytoreduction and hyperthermic intraperitoneal chemotherapy versus systemic chemotherapy in patients with peritoneal carcinomatosis of colorectal cancer," *Annals of Surgical Oncology*, vol. 15, no. 9, pp. 2426–2432, 2008.

[10] D. Elias, J. H. Lefevre, J. Chevalier et al., "Complete cytoreductive surgery plus intraperitoneal chemohyperthermia with oxaliplatin for peritoneal carcinomatosis of colorectal origin," *Journal of Clinical Oncology*, vol. 27, no. 5, pp. 681–685, 2009.

[11] O. Glehen, F. Kwiatkowski, P. H. Sugarbaker et al., "Cytoreductive surgery combined with perioperative intraperitoneal chemotherapy for the management of peritoneal carcinomatosis from colorectal cancer: a multi-institutional study," *Journal of Clinical Oncology*, vol. 22, no. 16, pp. 3284–3292, 2004.

[12] O. Glehen, F. Mithieux, D. Osinsky et al., "Surgery combined with peritonectomy procedures and intraperitoneal chemohyperthermia in abdominal cancers with peritoneal carcinomatosis: a phase II study," *Journal of Clinical Oncology*, vol. 21, no. 5, pp. 799–806, 2003.

[13] T. D. Yan, D. Black, P. H. Sugarbaker et al., "A systematic review and meta-analysis of the randomized controlled trials on adjuvant intraperitoneal chemotherapy for resectable gastric cancer," *Annals of Surgical Oncology*, vol. 14, no. 10, pp. 2702–2713, 2007.

[14] L. Bijelic, A. Jonson, and P. H. Sugarbaker, "Systematic review of cytoreductive surgery and heated intraoperative intraperitoneal chemotherapy for treatment of peritoneal carcinomatosis in primary and recurrent ovarian cancer," *Annals of Oncology*, vol. 18, no. 12, pp. 1943–1950, 2007.

[15] T. D. Yan, L. Welch, D. Black, and P. H. Sugarbaker, "A systematic review on the efficacy of cytoreductive surgery combined with perioperative intraperitoneal chemotherapy

for diffuse malignancy peritoneal mesothelioma," *Annals of Oncology*, vol. 18, no. 5, pp. 827–834, 2007.

[16] T. D. Yan, D. Black, R. Savady, and P. H. Sugarbaker, "A systematic review on the efficacy of cytoreductive surgery and perioperative intraperitoneal chemotherapy for pseudomyxoma peritonei," *Annals of Surgical Oncology*, vol. 14, no. 2, pp. 484–492, 2007.

[17] T. D. Yan, D. Black, R. Savady, and P. H. Sugarbaker, "Systematic review on the efficacy of cytoreductive surgery combined with perioperative intraperitoneal chemotherapy for peritoneal carcinomatosis from colorectal carcinoma," *Journal of Clinical Oncology*, vol. 24, no. 24, pp. 4011–4019, 2006.

[18] D. Elias, O. Glehen, and F. Gilly, "Carcinose péritonéales d'origine digestive et primitive," in *Proceedings of the Rapport du 110 éme Congrès de l'AFC*, Arnette : Wolters Kluwer France, 2008.

[19] R. L. Dedrick, C. E. Myers, P. M. Bungay, and V. T. Devita, "Pharmacokinetic rationale for peritoneal drug administration in the treatment of ovarian cancer," *Cancer Treatment Reports*, vol. 62, no. 1, pp. 1–11, 1978.

[20] R. L. Dedrick, "Theoretical and experimental bases of intraperitoneal chemotherapy," *Seminars in Oncology*, vol. 12, no. 3, supplement 4, pp. 1–6, 1985.

[21] M. A. Baron, "Structure of the intestinal peritoneum in man," *American Journal of Anatomy*, vol. 69, pp. 439–497, 1941.

[22] M. Flessner, J. Henegar, S. Bigler, and L. Genous, "Is the peritoneum a significant transport barrier in peritoneal dialysis?" *Peritoneal Dialysis International*, vol. 23, no. 6, pp. 542–549, 2003.

[23] V. De Lima Vazquez, O. A. Stuart, F. Mohamed, and P. H. Sugarbaker, "Extent of parietal peritonectomy does not change intraperitoneal chemotherapy pharmacokinetics," *Cancer Chemotherapy and Pharmacology*, vol. 52, no. 2, pp. 108–112, 2003.

[24] K. Van der Speeten, O. A. Stuart, D. Chang, H. Mahteme, and P. H. Sugarbaker, "Changes induced by surgical and clinical factors in the pharmacology of intraperitoneal mitomycin C in 145 patients with peritoneal carcinomatosis," *Cancer Chemotherapy and Pharmacology*, vol. 68, no. 1, pp. 147–156, 2011.

[25] G. Stelin and B. Rippe, "A phenomenological interpretation of the variation in dialysate volume with dwell time in CAPD," *Kidney International*, vol. 38, no. 3, pp. 465–472, 1990.

[26] U. Bettendorf, "Lymph flow mechanism of the subperitoneal diaphragmatic lymphatics," *Lymphology*, vol. 11, no. 3, pp. 111–116, 1978.

[27] U. Bettendorf, "Electronmicroscopic studies on the peritoneal resorption of intraperitoneally injected latex particles via the diaphragmatic lymphatics," *Lymphology*, vol. 12, no. 2, pp. 66–70, 1979.

[28] M. H. Katz and R. M. Barone, "The rationale of perioperative intraperitoneal chemotherapy in the treatment of peritoneal surface malignancies," *Surgical Oncology Clinics of North America*, vol. 12, no. 3, pp. 673–688, 2003.

[29] R. L. Dedrick, C. E. Myers, P. M. Bungay, and V. T. Devita, "Pharmacokinetic rationale for peritoneal drug administration in the treatment of ovarian cancer," *Cancer Treatment Reports*, vol. 62, no. 1, pp. 1–11, 1978.

[30] M. F. Flessner, J. D. Fenstermacher, R. L. Dedrick, and R. G. Blasberg, "A distributed model of peritoneal-plasma transport: tissue concentration gradients," *American Journal of Physiology*, vol. 248, no. 3, pp. F425–F435, 1985.

[31] R. L. Dedrick and M. F. Flessner, "Pharmacokinetic problems in peritoneal drug administration: tissue penetration and surface exposure," *Journal of the National Cancer Institute*, vol. 89, no. 7, pp. 480–487, 1997.

[32] K. Van der Speeten, O. A. Stuart, H. Mahteme, and P. H. Sugarbaker, "A pharmacologic analysis of intraoperative intracavitary cancer chemotherapy with doxorubicin," *Cancer Chemotherapy and Pharmacology*, vol. 63, no. 5, pp. 799–805, 2009.

[33] K. Van der Speeten, O. A. Stuart, H. Mahteme, and P. H. Sugarbaker, "Pharmacology of perioperative 5-fluorouracil," *Journal of Surgical Oncology*, vol. 102, no. 7, pp. 730–735, 2010.

[34] N. R. Bachur, S. L. Gordon, M. V. Gee, and H. Kon, "NADPH cytochrome P-450 reductase activation of quinone anticancer agents to free radicals," *Proceedings of the National Academy of Sciences of the United States of America*, vol. 76, no. 2, pp. 954–957, 1979.

[35] D. Elias, P. Dubé, F. Blot et al., "Peritoneal carcinomatosis treatment with curative intent: the Institut Gustave-Roussy experience," *European Journal of Surgical Oncology*, vol. 23, no. 4, pp. 317–321, 1997.

[36] P. H. Sugarbaker and D. Chang, "Results of treatment of 385 patients with peritoneal surface spread of appendiceal malignancy," *Annals of Surgical Oncology*, vol. 6, no. 8, pp. 727–731, 1999.

[37] B. Barlogie, P. M. Corry, and B. Drewinko, "In vitro thermochemotherapy of human colon cancer cells with cis-dichlorodiammineplatinum(II) and mitomycin C," *Cancer Research*, vol. 40, no. 4, pp. 1165–1168, 1980.

[38] P. H. Sugarbaker, "Successful management of microscopic residual disease in large bowel cancer," *Cancer Chemotherapy and Pharmacology, Supplement*, vol. 43, pp. S15–S25, 1999.

[39] J. Esquivel, "Technology of hyperthermic intraperitoneal chemotherapy in the United States, Europe, China, Japan, and Korea," *Cancer Journal*, vol. 15, no. 3, pp. 249–254, 2009.

[40] S. Van Ruth, V. J. Verwaal, and F. A. N. Zoetmulder, "Pharmacokinetics of intraperitoneal mitomycin C," *Surgical Oncology Clinics of North America*, vol. 12, no. 3, pp. 771–780, 2003.

[41] R. M. Smeenk, V. J. Verwaal, and F. A. N. Zoetmulder, "Toxicity and mortality of cytoreduction and intraoperative hyperthermic intraperitoneal chemotherapy in pseudomyxoma peritonei—a report of 103 procedures," *European Journal of Surgical Oncology*, vol. 32, no. 2, pp. 186–190, 2006.

[42] O. Glehen, D. Osinsky, E. Cotte et al., "Intraperitoneal chemohyperthermia using a closed abdominal procedure and cytoreductive surgery for the treatment of peritoneal carcinomatosis: morbidity and mortality analysis of 216 consecutive procedures," *Annals of Surgical Oncology*, vol. 10, no. 8, pp. 863–869, 2003.

[43] P. H. Sugarbaker, R. Alderman, G. Edwards et al., "Prospective morbidity and mortality assessment of cytoreductive surgery plus perioperative intraperitoneal chemotherapy to treat peritoneal dissemination of appendiceal mucinous malignancy," *Annals of Surgical Oncology*, vol. 13, no. 5, pp. 635–644, 2006.

[44] V. Cepeda, M. A. Fuertes, J. Castilla, C. Alonso, C. Quevedo, and J. M. Pérez, "Biochemical mechanisms of cisplatin cytotoxicity," *Anti-Cancer Agents in Medicinal Chemistry*, vol. 7, no. 1, pp. 3–18, 2007.

[45] D. K. Armstrong, B. Bundy, L. Wenzel et al., "Intraperitoneal cisplatin and paclitaxel in ovarian cancer," *New England Journal of Medicine*, vol. 354, no. 1, pp. 34–43, 2006.

[46] M. Markman, B. N. Bundy, D. S. Alberts et al., "Phase III trial of standard-dose intravenous cisplatin plus paclitaxel versus moderately high-dose carboplatin followed by intravenous paclitaxel and intraperitoneal cisplatin in small-volume stage III ovarian carcinoma: an intergroup study of the gynecologic oncology group, Southwestern Oncology Group, and Eastern Cooperative Oncology Group," *Journal of Clinical Oncology*, vol. 19, no. 4, pp. 1001–1007, 2001.

[47] D. S. Alberts, P. Y. Liu, E. V. Hannigan et al., "Intraperitoneal cisplatin plus intravenous cyclophosphamide versus intravenous cisplatin plus intravenous cyclophosphamide for stage III ovarian cancer," *New England Journal of Medicine*, vol. 335, no. 26, pp. 1950–1955, 1996.

[48] M. Urano, M. Kuroda, and Y. Nishimura, "For the clinical application of thermochemotherapy given at mild temperatures," *International Journal of Hyperthermia*, vol. 15, no. 2, pp. 79–107, 1999.

[49] J. H. Stewart IIII, P. Shen, G. Russell et al., "A phase I trial of oxaliplatin for intraperitoneal hyperthermic chemoperfusion for the treatment of peritoneal surface dissemination from colorectal and appendiceal cancers," *Annals of Surgical Oncology*, vol. 15, no. 8, pp. 2137–2145, 2008.

[50] D. M. Elias and L. Sideris, "Pharmacokinetics of heated intraoperative intraperitoneal oxaliplatin after complete resection of peritoneal carcinomatosis," *Surgical Oncology Clinics of North America*, vol. 12, no. 3, pp. 755–769, 2003.

[51] D. Elias, M. Bonnay, J. M. Puizillou et al., "Heated intraoperative intraperitoneal oxaliplatin after complete resection of peritoneal carcinomatosis: pharmacokinetics and tissue distribution," *Annals of Oncology*, vol. 13, no. 2, pp. 267–272, 2002.

[52] E. Jerremalm, M. Hedeland, I. Wallin, U. Bondesson, and H. Ehrsson, "Oxaliplatin degradation in the presence of chloride: identification and cytotoxicity of the monochloro monooxalato complex," *Pharmaceutical Research*, vol. 21, no. 5, pp. 891–894, 2004.

[53] F. de Somer, W. Ceelen, J. Delanghe et al., "Severe hyponatremia, hyperglycemia, and hyperlactatemia are associated with intraoperative hyperthermic intraperitoneal chemoperfusion with oxaliplatin," *Peritoneal Dialysis International*, vol. 28, no. 1, pp. 61–66, 2008.

[54] N. Piché, F. A. Leblond, L. Sidéris et al., "Rationale for heating oxaliplatin for the intraperitoneal treatment of peritoneal carcinomatosis: a study of the effect of heat on intraperitoneal oxaliplatin using a murine model," *Annals of Surgery*, vol. 254, no. 1, pp. 138–144, 2011.

[55] M. Czejka, W. Jäger, J. Schüller et al., "Pharmacokinetics of carboplatin after intraperitoneal administration," *Archiv der Pharmazie*, vol. 324, no. 3, pp. 183–184, 1991.

[56] G. Los, E. M. E. Verdegaal, P. H. A. Mutsaers, and J. G. McVie, "Penetration of carboplatin and cisplatin into rat peritoneal tumor nodules after intraperitoneal chemotherapy," *Cancer Chemotherapy and Pharmacology*, vol. 28, no. 3, pp. 159–165, 1991.

[57] T. R. Tritton, "Cell surface actions of adriamycin," *Pharmacology and Therapeutics*, vol. 49, no. 3, pp. 293–309, 1991.

[58] P. Lane, P. Vichi, D. L. Bain, and T. R. Tritton, "Temperature dependence studies of adriamycin uptake and cytotoxicity," *Cancer Research*, vol. 47, no. 15, pp. 4038–4042, 1987.

[59] P. Jacquet, A. Averbach, O. A. Stuart, D. Chang, and P. H. Sugarbaker, "Hyperthermic intraperitoneal doxorubicin: pharmacokinetics, metabolism, and tissue distribution in a rat model," *Cancer Chemotherapy and Pharmacology*, vol. 41, no. 2, pp. 147–154, 1998.

[60] K. Van der Speeten, O. A. Stuart, H. Mahteme, and P. H. Sugarbaker, "A pharmacologic analysis of intraoperative intracavitary cancer chemotherapy with doxorubicin," *Cancer Chemotherapy and Pharmacology*, vol. 63, no. 5, pp. 799–805, 2009.

[61] P. B. Johansen, "Doxorubicin pharmacokinetics after intravenous and intraperitoneal administration in the nude mouse," *Cancer Chemotherapy and Pharmacology*, vol. 5, no. 4, pp. 267–270, 1981.

[62] R. F. Ozols, K. R. Grotzinger, and R. I. Fisher, "Kinetic characterization and response to chemotherapy in a transplantable murine ovarian cancer," *Cancer Research*, vol. 39, no. 8, pp. 3202–3208, 1979.

[63] R. F. Ozols, G. Y. Locker, and J. H. Doroshow, "Pharmacokinetics of adriamycin and tissue penetration in murine ovarian cancer," *Cancer Research*, vol. 39, no. 8, pp. 3209–3214, 1979.

[64] R. F. Ozols, R. C. Young, and J. L. Speyer, "Phase I and pharmacological studies of adriamycin administered intraperitoneally to patients with ovarian cancer," *Cancer Research*, vol. 42, no. 10, pp. 4265–4269, 1982.

[65] S. R. Pestieau, O. A. Stuart, D. Chang, P. Jacquet, and P. H. Sugarbaker, "Pharmacokinetics of intraperitoneal gemcitabine in a rat model," *Tumori*, vol. 84, no. 6, pp. 706–711, 1998.

[66] P. Sabbatini, C. Aghajanian, M. Leitao et al., "Intraperitoneal cisplatin with intraperitoneal gemcitabine in patients with epithelial ovarian cancer: results of a phase I/II Trial," *Clinical Cancer Research*, vol. 10, no. 9, pp. 2962–2967, 2004.

[67] R. J. Morgan Jr., T. W. Synold, B. Xi et al., "Phase I trial of intraperitoneal gemcitabine in the treatment of advanced malignancies primarily confined to the peritoneal cavity," *Clinical Cancer Research*, vol. 13, no. 4, pp. 1232–1237, 2007.

[68] T. C. Gamblin, M. J. Egorin, E. G. Zuhowski et al., "Intraperitoneal gemcitabine pharmacokinetics: a pilot and pharmacokinetic study in patients with advanced adenocarcinoma of the pancreas," *Cancer Chemotherapy and Pharmacology*, vol. 62, no. 4, pp. 647–653, 2008.

[69] P. H. Sugarbaker, O. A. Stuart, and L. Bijelic, "Intraperitoneal gemcitabine chemotherapy treatment for patients with resected pancreatic cancer: rationale and report of early data," *International Journal of Surgical Oncology*, vol. 2011, Article ID 161862, 7 pages, 2011.

[70] D. S. Alberts, H. S. Chen, S. Y. Chang, and Y. M. Peng, "The disposition of intraperitoneal bleomycin, melphalan, and vinblastine in cancer patients," *Recent Results in Cancer Research*, vol. 74, pp. 293–299, 1980.

[71] O. Glehen, O. A. Stuart, F. Mohamed, and P. H. Sugarbaker, "Hyperthermia modifies pharmacokinetics and tissue distribution of intraperitoneal melphalan in a rat model," *Cancer Chemotherapy and Pharmacology*, vol. 54, no. 1, pp. 79–84, 2004.

[72] P. H. Sugarbaker and O. A. Stuart, "Pharmacokinetic and phase II study of heated intraoperative intraperitoneal melphalan," *Cancer Chemotherapy and Pharmacology*, vol. 59, no. 2, pp. 151–155, 2007.

[73] W. P. Ceelen, L. Påhlman, and H. Mahteme, "Pharmacodynamic aspects of intraperitoneal cytotoxic therapy," *Cancer Treatment and Research*, vol. 134, pp. 195–214, 2007.

[74] P. H. Sugarbaker, J. T. Mora, P. Carmignani, O. A. Stuart, and D. Yoo, "Update on chemotherapeutic agents utilized for perioperative intraperitoneal chemotherapy," *Oncologist*, vol. 10, no. 2, pp. 112–122, 2005.

[75] F. Mohamed and P. H. Sugarbaker, "Intraperitoneal taxanes," *Surgical Oncology Clinics of North America*, vol. 12, no. 3, pp. 825–833, 2003.

[76] R. C. Rietbroek, D. M. Katschinski, M. H. E. Reijers et al., "Lack of thermal enhancement for taxanes in vitro," *International Journal of Hyperthermia*, vol. 13, no. 5, pp. 525–533, 1997.

[77] D. S. Schrump, S. Zhai, D. M. Nguyen et al., "Pharmacokinetics of paclitaxel administered by hyperthermic retrograde isolated lung perfusion techniques," *Journal of Thoracic and Cardiovascular Surgery*, vol. 123, no. 4, pp. 686–694, 2002.

[78] A. Cividalli, G. Cruciani, E. Livdi, P. Pasqualetti, and D. Tirindelli Danesi, "Hyperthermia enhances the response of paclitaxel and radiation in a mouse adenocarcinoma," *International Journal of Radiation Oncology Biology Physics*, vol. 44, no. 2, pp. 407–412, 1999.

[79] F. Mohamed, O. A. Stuart, O. Glehen, M. Urano, and P. H. Sugarbaker, "Docetaxel and hyperthermia: factors that modify thermal enhancement," *Journal of Surgical Oncology*, vol. 88, no. 1, pp. 14–20, 2004.

[80] Y. Yonemura, E. Bandou, T. Sawa et al., "Neoadjuvant treatment of gastric cancer with peritoneal dissemination," *European Journal of Surgical Oncology*, vol. 32, no. 6, pp. 661–665, 2006.

[81] E. De Bree, H. Rosing, J. H. Beijnen et al., "Pharmacokinetic study of docetaxel in intraoperative hyperthermic i.p. chemotherapy for ovarian cancer," *Anti-Cancer Drugs*, vol. 14, no. 2, pp. 103–110, 2003.

[82] E. DeBree, H. Rosing, D. Filis et al., "Cytoreductive surgery and intraoperative hyperthermic intraperitoneal chemotherapy with paclitaxel: a clinical and pharmacokinetic study," *Annals of Surgical Oncology*, vol. 15, no. 4, pp. 1183–1192, 2008.

[83] J. L. Speyer, J. M. Collins, and R. L. Dedrick, "Phase I and pharmacological studies of 5-fluorouracil administered intraperitoneally," *Cancer Research*, vol. 40, no. 3, pp. 567–572, 1980.

[84] P. Jacquet, A. Averbach, A. D. Stephens, O. Anthony Stuart, D. Chang, and P. H. Sugarbaker, "Heated intraoperative intraperitoneal mitomycin C and early postoperative intraperitoneal 5-fluorouracil: pharmacokinetic studies," *Oncology*, vol. 55, no. 2, pp. 130–138, 1998.

[85] R. B. Diasio and Z. Lu, "Dihydropyrimidine dehydrogenase activity and fluorouracil chemotherapy," *Journal of Clinical Oncology*, vol. 12, no. 11, pp. 2239–2242, 1994.

[86] C. H. Takimoto, "Antifolates in clinical development," *Seminars in Oncology*, vol. 24, no. 5, supplement 18, pp. S18–S40, 1997.

[87] S. R. Pestieau, O. A. Stuart, and P. H. Sugarbaker, "Multitargeted antifolate (MTA): pharmacokinetics of intraperitoneal administration in a rat model," *European Journal of Surgical Oncology*, vol. 26, no. 7, pp. 696–700, 2000.

[88] J. Rubin, M. Clawson, A. Planch, and Q. Jones, "Measurements of peritoneal surface area in man and rat," *American Journal of the Medical Sciences*, vol. 295, no. 5, pp. 453–458, 1988.

[89] A. Chagnac, P. Herskovitz, T. Weinstein et al., "The peritoneal membrane in peritoneal dialysis patients: estimation of its functional surface area by applying stereologic methods to computerized tomography scans," *Journal of the American Society of Nephrology*, vol. 10, no. 2, pp. 342–346, 1999.

[90] A. M. Albanese, E. F. Albanese, J. H. Miño et al., "Peritoneal surface area: measurements of 40 structures covered by peritoneum: correlation between total peritoneal surface area and the surface calculated by formulas," *Surgical and Radiologic Anatomy*, vol. 31, no. 5, pp. 369–377, 2009.

[91] C. R. Rossi, M. Deraco, M. De Simone et al., "Hyperthermic intraperitoneal intraoperative chemotherapy after cytoreductive surgery for the treatment of abdominal sarcomatosis: clinical outcome and prognostic factors in 60 consecutive patients," *Cancer*, vol. 100, no. 9, pp. 1943–1950, 2004.

[92] D. Baratti, S. Kusamura, A. Martinetti et al., "Prognostic value of circulating tumor markers in patients with pseudomyxoma peritonei treated with cytoreductive surgery and hyperthermic intraperitoneal chemotherapy," *Annals of Surgical Oncology*, vol. 14, no. 8, pp. 2300–2308, 2007.

[93] O. Glehen, V. Schreiber, E. Cotte et al., "Cytoreductive surgery and intraperitoneal chemohyperthermia for peritoneal carcinomatosis arising from gastric cancer," *Archives of Surgery*, vol. 139, no. 1, pp. 20–26, 2004.

[94] F. N. Gilly, P. Y. Carry, A. C. Sayag et al., "Regional chemotherapy (with mitomycin C) and intra-operative hyperthermia for digestive cancers with peritoneal carcinomatosis," *Hepato-Gastroenterology*, vol. 41, no. 2, pp. 124–129, 1994.

[95] P. Keshaviah, P. F. Emerson, E. F. Vonesh, and J. C. Brandes, "Relationship between body size, fill volume, and mass transfer area coefficient in peritoneal dialysis," *Journal of the American Society of Nephrology*, vol. 4, no. 10, pp. 1820–1826, 1994.

[96] P. H. Sugarbaker, "Successful management of microscopic residual disease in large bowel cancer," *Cancer Chemotherapy and Pharmacology, Supplement*, vol. 43, pp. S15–S25, 1999.

[97] J. Esquivel, "Technology of hyperthermic intraperitoneal chemotherapy in the United States, Europe, China, Japan, and Korea," *Cancer Journal*, vol. 15, no. 3, pp. 249–254, 2009.

[98] S. Van Ruth, V. J. Verwaal, and F. A. N. Zoetmulder, "Pharmacokinetics of intraperitoneal mitomycin C," *Surgical Oncology Clinics of North America*, vol. 12, no. 3, pp. 771–780, 2003.

[99] W. P. Ceelen, L. Påhlman, and H. Mahteme, "Pharmacodynamic aspects of intraperitoneal cytotoxic therapy," *Cancer Treatment and Research*, vol. 134, pp. 195–214, 2007.

[100] D. Elias, M. Bonnay, J. M. Puizillou et al., "Heated intraoperative intraperitoneal oxaliplatin after complete resection of peritoneal carcinomatosis: pharmacokinetics and tissue distribution," *Annals of Oncology*, vol. 13, no. 2, pp. 267–272, 2002.

[101] K. Van der Speeten, O. A. Stuart, H. Mahteme et al., "Pharmacokinetic study of perioperative intravenous ifosfamide," *International Journal of Surgical Oncology*, vol. 2011, Article ID 185092, 9 pages, 2011.

Hindawi Publishing Corporation
Gastroenterology Research and Practice
Volume 2012, Article ID 506571, 5 pages
doi:10.1155/2012/506571

Clinical Study

Preliminary Results of Hyperthermic Intraperitoneal Intraoperative Chemotherapy as an Adjuvant in Resectable Pancreatic Cancer

Antonios-Apostolos K. Tentes,[1] Dimitrios Kyziridis,[1] Stylianos Kakolyris,[2] Nicolaos Pallas,[1] Georgios Zorbas,[1] Odysseas Korakianitis,[3] Christos Mavroudis,[1] Nicolaos Courcoutsakis,[4] and Panos Prasopoulos[4]

[1] *Surgical Department, Didimotichon General Hospital, Didimotichon 68300, Greece*
[2] *Department of Clinical Oncology, Alexandroupolis General Hospital, Democritus University of Thrace, Greece*
[3] *Department of Anesthesiology, Didimotichon General Hospital, Greece*
[4] *Department of Radiology, Alexandroupolis General Hospital, Democritus University of Thrace, Greece*

Correspondence should be addressed to Antonios-Apostolos K. Tentes, atentes@did-hosp.gr

Received 25 February 2012; Accepted 26 March 2012

Academic Editor: Paul H. Sugarbaker

Background and Aims. 5-year survival in patients with pancreatic cancer is poor. Surgical resection is the only potentially curative resection. The results of adjuvant treatment either with chemotherapy or with radiotherapy have been contradictory and the incidence of local-regional recurrence remains high. If local-regional recurrence is controlled survival may be expected to increase. Hyperthermic intraoperative intraperitoneal chemotherapy (HIPEC) may be used in order to control local-regional recurrences. The purpose of the study is to identify the effect of HIPEC in patients with pancreatic cancer undergoing potentially resection. *Patients and Methods*. From 2007–2011, 21 patients, mean age 69.4 ± 9.5 (50–86) years, underwent tumor resection, and HIPEC with gemcitabine. The hospital mortality and morbidity rate was 9.5% and 33.3%, respectively. 5-year and median survival was 23% and 11 months, respectively. The recurrence rate was 50% but no patient developed local-regional recurrence. No patient was recorded with gemcitabine-induced toxicity. *Conclusions*. This clinical study of 21 patients is the first to combine an R_0 pancreas cancer resection with HIPEC. Increased morbidity and mortality from intraoperative gemcitabine was not apparent. Patients with pancreatic cancer undergoing potentially curative resection in combination with HIPEC may be offered a survival benefit. Data suggested that local-regional recurrences may be greatly reduced. Further studies with greater number of patients are required to confirm these findings.

1. Introduction

Pancreatic cancer is one of the most frequent causes of cancer-related deaths in the western world. The overall 5-year survival rate after potentially curative resection does not exceed 15% in most series [1–3], although in high volume centers it may be as high as 20–25% [4, 5]. Surgical resection remains the single potentially curative option but only 10–15% of the diagnosed tumors are eligible for resection [6–9]. Increase of long-term survival may result either if the proportion of patients with locally unresectable tumors decreases or if treatments that may control disease recurrence, and particularly the local-regional ones, are developed.

In 1985 the Gastrointestinal Study Group showed that adjuvant chemoradiation offers significant survival benefit after surgical resection in patients with pancreatic cancer [10] but a decade later this was disputed by the study conducted by EORTC [11]. The ESPAC study showed that chemotherapy only offers a survival benefit [12]. Recent studies have shown that chemoradiation may be a favorable option for patients with resectable tumors [13]. A review

of these manuscripts document that the data concerning adjuvant treatment for resectable pancreatic cancer are contradictory.

The sites of recurrence after curative resection are the liver in 50–60%, the peritoneal surfaces in 40–50%, and the pancreatic bed in 50% of the cases [14]. The pathophysiology of local-regional recurrence after R_0 resection remains an enigma. It may be the result of metastases undetected on imaging or laparotomy. Or tumor dissemination and implantation of cancer emboli at the resection sites may occur with pancreatectomy [15]. If this is true then intraperitoneal chemotherapy may be the treatment that has a beneficial impact on overall survival by reducing the number of local-regional recurrences. Intraperitoneal chemotherapy has the capability to eradicate the microscopic cancer emboli and reduce the incidence of local-regional recurrences. It is obvious that there is an absolute need for adjuvant treatment in addition to surgical resection.

The purpose of the study is to identify the potential benefits of hyperthermic intraperitoneal intraoperative chemotherapy (HIPEC) with gemcitabine in patients that undergo R_0 resection for pancreatic cancer.

2. Patients-Methods

From April 2007 until August 2011, 21 patients with resectable pancreatic cancer, without distant metastatic lesions as assessed by routine preoperative staging (physical examination, CT-scan, MRI, and bone scanning) were enrolled in the study. The study was approved by the Ethical Committee of the hospital and patients signed an informed consent prior to accepting this therapeutic approach.

The diagnosis was possible by physical examination, hematological-biochemical examination, tumor markers (CEA, CA 19-9, CA-125), CT abdominal and thoracic scan or MRI, and bone scanning. No preoperative histological examination was performed.

Patients between 16–90 years of age, with satisfactory cardiopulmonary function, satisfactory renal function (blood urea level <50 mg/dL and creatinine level <1.5 mg/dL), satisfactory liver function (other than hepatobiliary obstruction), with white blood cell count >4000/mL, platelet count >150.000/mL, and acceptable performance status (Karnofsky performance status >50%) were included in the study.

Patients with evidence of distant metastatic disease (liver, osseous, brain and pulmonary), with prior antitumor therapy, with prior malignancy at risk for recurrence (except for basal cell carcinoma or in situ carcinoma of the cervix adequately treated), with poor performance status (Karnofsky performance status <50%), with psychiatric diseases or addictive disorders, and pregnant women were not included in the study.

Patients with periampullary tumors were not included in the study. Patients with resectable pancreatic cancer and limited peritoneal metastases for whom CC-0 or CC-1 cytoreduction could be possible, were included in the study.

2.1. Treatments. Patients with cancer of the head of the pancreas underwent subtotal pancreatoduodenectomy (Kausch-Whipple procedure). Distal pancreatectomy was used for cancer of the body or the tail of the pancreas. After tumor resection and before the reconstruction of the alimentary tract, HIPEC was performed for 60 min at 42–43°C with gemcitabine at a dose of 1000 mg/m^2. HIPEC was administered using the open (Coliseum) technique. A heater circulator with two roller pumps, one heat exchanger, one reservoir, and an extracorporeal system of two inflow and two outflow tubes, and 4 thermal probes was used for HIPEC (Sun Chip, Gamida Tech, France). A prime solution of 2-3 liters of normal saline was instilled prior to administration of the cytostatic drug and as soon as the mean abdominal temperature reached 40°C gemcitabine was instilled in the abdomen.

During perfusion adequate fluids were administered in addition to dopamine at a diuretic dose of 3 μg/K.b.w., in order to maintain diuresis at 500 mL/h. Dopamine was also used after surgery for 24 hours to maintain diuresis at the same levels.

The reconstruction of the alimentary tract was performed after the completion of HIPEC. After subtotal pancreatoduodenectomy the reconstruction was always made with an end-to-side pancreato-jejunal anastomosis, end-to-side choledocho-jejunal anastomosis, followed by a Roux-en-Y gastrointestinal anastomosis with a second jejunal loop.

Cytoreductive surgery with standard peritonectomy procedures was used for the treatment of peritoneal metastases whenever they were found [16]. A CC-0 operation did not leave behind macroscopically visible tumor. A CC-1 operation had residual tumor less than 2.5 mm in its largest diameter [17].

All resected specimens were sent for histopathological examination and complete staging. Stage III patients received additional systemic chemotherapy with gemcitabine and 5-FU.

2.2. Followup. All patients were followed up at 3-month intervals with physical examination, hematological, and biochemical examinations, tumor markers (CEA, CA 19-9, CA-125), and thoracic and abdominal CT. Recurrences and the sites of recurrence were recorded.

2.3. Statistical Analysis. The proportion of patients with a given characteristic was compared by chi-square analysis or by Pearson's test. Differences in the means of continuous measurement were tested by the Student's t-test. The survival curves were obtained with the Kaplan-Meier method. A two-tailed P value of <0.05 was considered statistically significant.

3. Results

The mean age of the patients was 69.4 ± 9.5 (50–86) years. The characteristics of the patients are listed in Table 1. Histopathology revealed that all patients had pancreatic cancer. One patient with cancer of the pancreatic tail and extensive peritoneal carcinomatosis underwent distal

Table 1: Patients' general characteristics.

Male/Female	No. of patients	%
	9/12	42.9/57.1
Tumor anatomic distribution		
Head	17	81
Body	1	4.8
Tail	3	14.3
Performance status		
90–100%	15	71.4
70–80%	5	23.8
50–60%	1	4.8
Tumor infiltration		
T_1	1	4.8
T_2	3	14.3
T_3	17	81
Nodal infiltration		
N_0	9	42.9
N_1	12	57.1
TNM stage		
I	3	14.3
II	6	28.6
III	12	57.1
Degree of differentiation		
G_1	4	19
G_2	9	42.9
G_3	8	38.1
Residual tumor		
R_0	20	95.3
R_1	1	4.7

pancreatectomy and near complete cytoreduction (CC-1) combined with HIPEC. This was defined as R_1 surgery because of possible residual tumor <2.5 mm left on the peritoneal surfaces of the mesentery. All the other patients had resectable tumors and underwent R_0 resection of the tumor combined with HIPEC. Seventeen patients with tumor of the head of the pancreas underwent subtotal pancreatoduodenectomy. The other four patients (three with cancer of the tail and one with cancer of the body) underwent distal pancreatectomy.

The hospital morbidity rate was 33.3% (7 patients). The recorded complications are listed in Table 2. One patient was reoperated because of postoperative bleeding that was successfully controlled. One further patient was reoperated because the choledochojejunal anastomosis failed, but was successfully controlled by T-tube insertion. The other patient with anastomotic leak underwent conservative treatment. The rate of reoperation was 9.5%. Only one patient was recorded with grade II neutropenia that did not require specific treatment. The hospital mortality rate was 9.5% (2 patients). One of them died because of ARDS and the other one of sepsis with an unknown primary site. The mean hospital length of stay was 18 days.

Table 2: Postoperative complications.

	No. of patients	%
Postoperative bleeding	1	4.8
Anastomotic leak	2	9.5
Acute respiratory distress syndrome	2	9.5
Sepsis	1	4.8
Grade II neutropenia	1	4.8

The 5-year survival rate was 23% and the median survival 11 months (Figure 1). Eleven stage III patients received systemic adjuvant chemotherapy with gemcitabine. One of the patients with stage II disease died during the immediate postoperative period. The median disease-free survival time was 5 months. The median follow-up time was 7 months. During followup 9 patients (50%) were recorded with recurrence. Three of them were stage II and 6 were stage III. All these patients had liver metastases and no locoregional recurrence, was recorded.

Currently 8 patients (38.1%) are alive without evidence of disease, 10 patients (47.6%) died because of recurrence, and 3 patients (14.3%) died of other causes unrelated to cancer.

4. Discussion

Although the pathophysiology of local-regional recurrence is unclear it has been assumed that the resection of a tumor located within narrow margins of resection may result in tumor dissemination because of interstitial tissue trauma, or severed lymphatics leaking cancer cells, or from venous blood loss contaminated by cancer cells. The disseminated cancer emboli are trapped in fibrin, stimulated by growth factors, and give rise to local-regional recurrent tumors within months-years after initial surgical manipulations [15]. The eradication of the entrapped microscopic cancer emboli may be possible by using intraperitoneal chemotherapy. Intraperitoneal chemotherapy has been shown to be very effective in carcinomatosis from colorectal cancer either as HIPEC or as early postoperative intraperitoneal chemotherapy (EPIC) under normothermia. The advantage of intraperitoneal chemotherapy is the high drug level that can be achieved by low systemic exposure [18].

Gemcitabine as systemic adjuvant treatment has been proved to be very effective in high risk patients undergoing potentially curative resection [19]. However, systemic chemotherapy has not been confirmed to assist in control of local disease. In contrast, it has been shown both from laboratory and clinical studies that the intraperitoneal use of gemcitabine may effectively target local disease. Laboratory studies have shown that the intraoperative use of gemcitabine may effectively prevent the development of peritoneal metastases. In addition early postoperative intraperitoneal chemotherapy may reduce the extent of peritoneal metastases [20]. Our data shows that the intraperitoneal use of gemcitabine in patients having pancreatectomy is well tolerated and does not produce severe toxicity. After all, only one

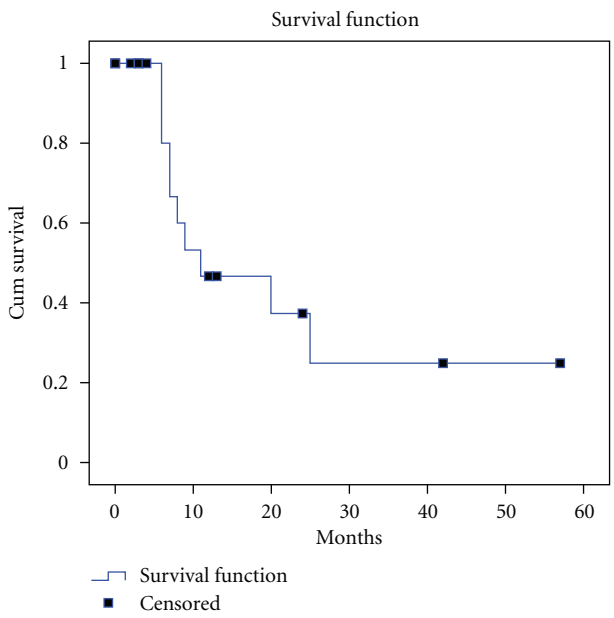

Figure 1: Overall survival of 21 patients with pancreatic cancer treated with complete resection plus hyperthermic intraoperative intraperitoneal chemotherapy.

patient developed grade II neutropenia that did not require any specific treatment. Intraperitoneal gemcitabine may be incriminated for the two anastomotic failures although it has not been proved. The large concentration of gemcitabine sustained in the peritoneal space and the low plasma concentration are findings supporting its intraperitoneal use [21].

The theoretical advantage of intraperitoneal gemcitabine has been confirmed by clinical and laboratory studies. Pharmacokinetic studies of intraperitoneal administration in a rat model have demonstrated that the area under the curve ratio of intraperitoneal to systemic drug exposure is closely related to the intraperitoneal dose and tissue samples showed increased drug concentration when administered with heat [22]. Preliminary pharmacokinetic data in patients with resectable pancreatic cancer that underwent HIPEC with gemcitabine at a dose of 1000 mg/m^2 showed marked local-regional drug exposure [23]. In addition, the intraperitoneal use of gemcitabine in clinical practice has shown equal results to platinum-based regimens in women with ovarian cancer [24]. These data taken together suggest that studies to test gemcitabine in patients with resectable pancreatic cancer are justified. It appears that intraperitoneal chemotherapy may have a favorable effect in eradicating microscopic cancer emboli not only locoregionally but also in the portal venous circulation. It has been found that the measured portal vein concentrations exceeded the measured concentration in other vessels when 5-FU was administered intraperitoneally [25]. Although the number of the included patients is very small and the median follow-up time short, no patient developed local-regional recurrence. This implies that HIPEC is likely to be effective in eradicating residual microscopic cancer emboli at the peritoneal surfaces.

5. Conclusions

Our preliminary results in the resection of pancreatic cancer with HIPEC using gemcitabine have shown that there may be a survival advantage even in patients with nodal involvement.

References

[1] S. R. Bramhall, W. H. Allum, A. G. Jones, A. Allwood, C. Cummins, and J. P. Neoptolemos, "Treatment and survival in 13 560 patients with pancreatic cancer, and incidence of the disease, in the West Midlands: an epidemiological study," *British Journal of Surgery*, vol. 82, no. 1, pp. 111–115, 1995.

[2] A. Jemal, A. Thomas, T. Murray, and M. Thun, "Cancer statistics," *Ca-A Cancer Journal for Clinicians*, vol. 52, no. 3, pp. 23–47, 2002.

[3] H. G. Beger, B. Rau, F. Gansauge, G. Leder, M. Schwarz, and B. Poch, "Pancreatic cancer–low survival rates," *Deutsches Arzteblatt*, vol. 105, no. 14, pp. 255–262, 2008.

[4] J. E. Lim, M. W. Chien, and C. C. Earle, "Prognostic factors following curative resection for pancreatic adenocarcinoma: a population-based, linked database analysis of 396 patients," *Annals of Surgery*, vol. 237, no. 1, pp. 74–85, 2003.

[5] J. L. Cameron, T. S. Riall, J. Coleman, and K. A. Belcher, "One thousand consecutive pancreaticoduodenectomies," *Annals of Surgery*, vol. 244, no. 1, pp. 10–15, 2006.

[6] G. Schneider, J. T. Siveke, F. Eckel, and R. M. Schmid, "Pancreatic cancer: basic and clinical aspects," *Gastroenterology*, vol. 128, no. 6, pp. 1606–1625, 2005.

[7] R. J. Geer, M. F. Brennan, J. Cameron et al., "Prognostic indicators for survival after resection of pancreatic adenocarcinoma," *American Journal of Surgery*, vol. 165, no. 1, pp. 68–73, 1993.

[8] S. S. Nitecki, M. G. Sarr, T. V. Colby, and J. A. van Heerden, "Long-term survival after resection for ductal adenocarcinoma of the pancreas: is it really improving?" *Annals of Surgery*, vol. 221, no. 1, pp. 59–66, 1995.

[9] J. D. Birkmeyer, A. L. Warshaw, S. R. G. Finlayson, M. R. Grove, and A. N. A. Tosteson, "Relationship between hospital volume and late survival after pancreaticoduodenectomy," *Surgery*, vol. 126, no. 2, pp. 178–183, 1999.

[10] M. H. Kalser and S. S. Ellenberg, "Pancreatic cancer. Adjuvant combined radiation and chemotherapy following curative resection," *Archives of Surgery*, vol. 120, no. 8, pp. 899–903, 1985.

[11] J. H. Klinkenbijl, J. Jeekel, T. Sahmoud et al., "Adjuvant radiotherapy and 5-fluorouracil after curative resection of cancer of the pancreas and periampullary region: phase III trial of the EORTC gastrointestinal tract cancer cooperative group," *Annals of Surgery*, vol. 230, no. 6, pp. 776–784, 1999.

[12] J. P. Neoptolemos, D. D. Stocken, H. Friess et al., "A randomized trial of chemoradiotherapy and chemotherapy after resection of pancreatic cancer," *The New England Journal of Medicine*, vol. 350, no. 12, pp. 1200–1210, 2004.

[13] C. C. Hsu, J. M. Herman, M. M. Corsini et al., "Adjuvant chemoradiation for pancreatic adenocarcinoma: the johns hopkins hospital-mayo clinic collaborative study," *Annals of Surgical Oncology*, vol. 17, no. 4, pp. 981–990, 2010.

[14] A. L. Warshaw and C. Fernández-del Castillo, "Pancreatic carcinoma," *The New England Journal of Medicine*, vol. 326, no. 7, pp. 455–465, 1992.

[15] P. Sugarbaker, "Observations concerning cancer spread within the peritoneal cavity and concepts supporting an ordered pathophysiology," in *Peritoneal Carcinomatosis: Principles and Practice of Management*, P. Sugarbaker, Ed., pp. 79–100, Kluwer Academic, Boston, Mass, USA, 1996.

[16] P. H. Sugarbaker, "Peritonectomy procedures," *Annals of Surgery*, vol. 221, no. 1, pp. 29–42, 1995.

[17] P. Jacquet and P. H. Sugarbaker, "Clinical research methodologies in diagnosis and staging of patients with peritoneal carcinomatosis," in *Peritoneal Carcinomatosis: Principles and Practice of Management*, P. Sugarbaker, Ed., pp. 369–374, Kluwer Academic, Boston, Mass, USA, 1996.

[18] R. L. Dedrick, "Theoretical and experimental bases of intraperitoneal chemotherapy," *Seminars in Oncology*, vol. 12, no. 3, supplement 4, pp. 1–6, 1985.

[19] H. Oettle, S. Post, P. Neuhaus et al., "Adjuvant chemotherapy with gemcitabine vs observation in patients undergoing curative-intent resection of pancreatic cancer: a randomized controlled trial," *Journal of the American Medical Association*, vol. 297, no. 3, pp. 267–277, 2007.

[20] K. Ridwelski, F. Meyer, A. Hribaschek, U. Kasper, and H. Lippert, "Intraoperative and early postoperative chemotherapy into the abdominal cavity using gemcitabine may prevent postoperative occurence of peritoneal carcinomatosis," *Journal of Surgical Oncology*, vol. 79, no. 1, pp. 10–16, 2002.

[21] T. C. Gamblin, M. J. Egorin, E. G. Zuhowski et al., "Intraperitoneal gemcitabine pharmacokinetics: a pilot and pharmacokinetic study in patients with advanced adenocarcinoma of the pancreas," *Cancer Chemotherapy and Pharmacology*, vol. 62, no. 4, pp. 647–653, 2008.

[22] S. R. Pestieau, O. A. Stuart, D. Chang, P. Jacquet, and P. H. Sugarbaker, "Pharmacokinetics of intraperitoneal gemcitabine in a rat model," *Tumori*, vol. 84, no. 6, pp. 706–711, 1998.

[23] P. H. Sugarbaker, J. T. Mora, P. Carmignani, O. A. Stuart, and D. Yoo, "Update on chemotherapeutic agents utilized for perioperative intraperitoneal chemotherapy," *Oncologist*, vol. 10, no. 2, pp. 112–122, 2005.

[24] P. Sabbatini, C. Aghajanian, M. Leitao et al., "Intraperitoneal cisplatin with intraperitoneal gemcitabine in patients with epithelial ovarian cancer: results of a phase I/II trial," *Clinical Cancer Research*, vol. 10, no. 9, pp. 2962–2967, 2004.

[25] J. L. Speyer, P. H. Sugarbaker, J. M. Collins, R. L. Dedrick, R. W. Klecker Jr., and C. E. Myers, "Portal levels and hepatic clearance of 5-fluorouracil after intraperitoneal administration in humans," *Cancer Research*, vol. 41, pp. 1916–1922, 1981.

Hindawi Publishing Corporation
Gastroenterology Research and Practice
Volume 2012, Article ID 963403, 9 pages
doi:10.1155/2012/963403

Review Article

Disposition Kinetics of Taxanes in Peritoneal Dissemination

Ken'ichi Miyamoto, Tsutomu Shimada, Kazuki Sawamoto, Yoshimichi Sai, and Yutaka Yonemura

Department of Pharmacy, Kanazawa University Hospital, 13-1 Takara-machi, Kanazawa 920-8641, Japan

Correspondence should be addressed to Ken'ichi Miyamoto, miyaken@staff.kanazawa-u.ac.jp

Received 6 January 2012; Accepted 14 February 2012

Academic Editor: Yan Li

Treatment of cancers in the abdominal cavity, such as peritoneal dissemination, is difficult, but in principle intraperitoneal administration of anticancer drugs is expected to be preferable to systemic administration. Taxane anticancer drugs are used to treat gastric cancer patients with peritoneal dissemination. They are administered as micellar preparations, Taxol and Taxotere, which consist of paclitaxel in Cremophor EL (crEL) and docetaxel in Polysorbate-80 (PS-80), respectively. In this paper we review the disposition kinetics of taxane anticancer drugs after intraperitoneal administration in peritoneal dissemination patients and animal models and also discuss the effect of the surfactant vehicle on the behavior of taxanes.

1. Introduction

Taxane alkaloids, paclitaxel and docetaxel, are widely used in the treatment of various cancers. Their anticancer activity is related to stabilization of microtubule assembly, and they cause mitotic arrest in the G_2M phase of the cell cycle [1]. Paclitaxel and docetaxel have similar chemical and physical characteristics, as shown in Figure 1, and are barely soluble in various solvents. They are therefore used as micellar preparations, Taxol and Taxotere, which consist of paclitaxel in Cremophor EL (crEL) and docetaxel in Polysorbate-80 (PS-80), respectively (Figure 2).

Chemotherapy for patients with peritoneal dissemination has generally been unsatisfactory. Peritoneal cancer occurs in about 10–15% of patients with gastric cancer and in about 50–60% of relapsed cases after gastrectomy. In general, however, treatment of the peritoneal cancer is ineffective, and the 5-year survival rate is extremely low even after multidisciplinary treatment, such as surgical resection, radiotherapy, and chemotherapy. In most cases, anticancer drugs have been given by systemic administration. But, the peritoneal cavity acts as a sanctuary against systemic chemotherapy because of the existence of a blood-peritoneal barrier consisting of stromal tissue between mesothelial cells and submesothelial blood capillaries [2]. Thus, inadequate therapeutic effects might be due at least in part to failure of the drugs to reach abdominal cancerous tissues at sufficient concentration to eradicate the cancer. The intraperitoneal (i.p.) dosage route might be better than systemic administration for treatment of peritoneal dissemination, and it would be expected to produce a higher drug concentration in the abdominal cavity and to exhibit a lower systemic toxicity compared with intravenous (i.v.) administration. Fushida et al. [3, 4] and Yonemura et al. [5] tried the i.p. infusion of taxane anticancer drugs in gastric cancer patients with peritoneal dissemination and reported that the treatment was more effective, with fewer side effects, than systemic i.v. administration. Sugarbaker et al. [6] have reviewed perioperative intraperitoneal chemotherapy; they noted that the ratio of the area under the drug concentration-time curve (AUC) in the peritoneal cavity and AUC in plasma (AUC_a/AUC_p) was much larger for paclitaxel and docetaxel than for other anticancer drugs, suggesting that taxanes may be effective when used in early postoperative intraperitoneal chemotherapy, without severe systemic toxicity. Moreover, i.p. docetaxel appeared to be more effective than paclitaxel on peritoneal dissemination. Here, we review the disposition kinetics of taxanes after i.p. administration of taxane preparations and discuss the relationship between the pharmacokinetic characteristics and anticancer effects of

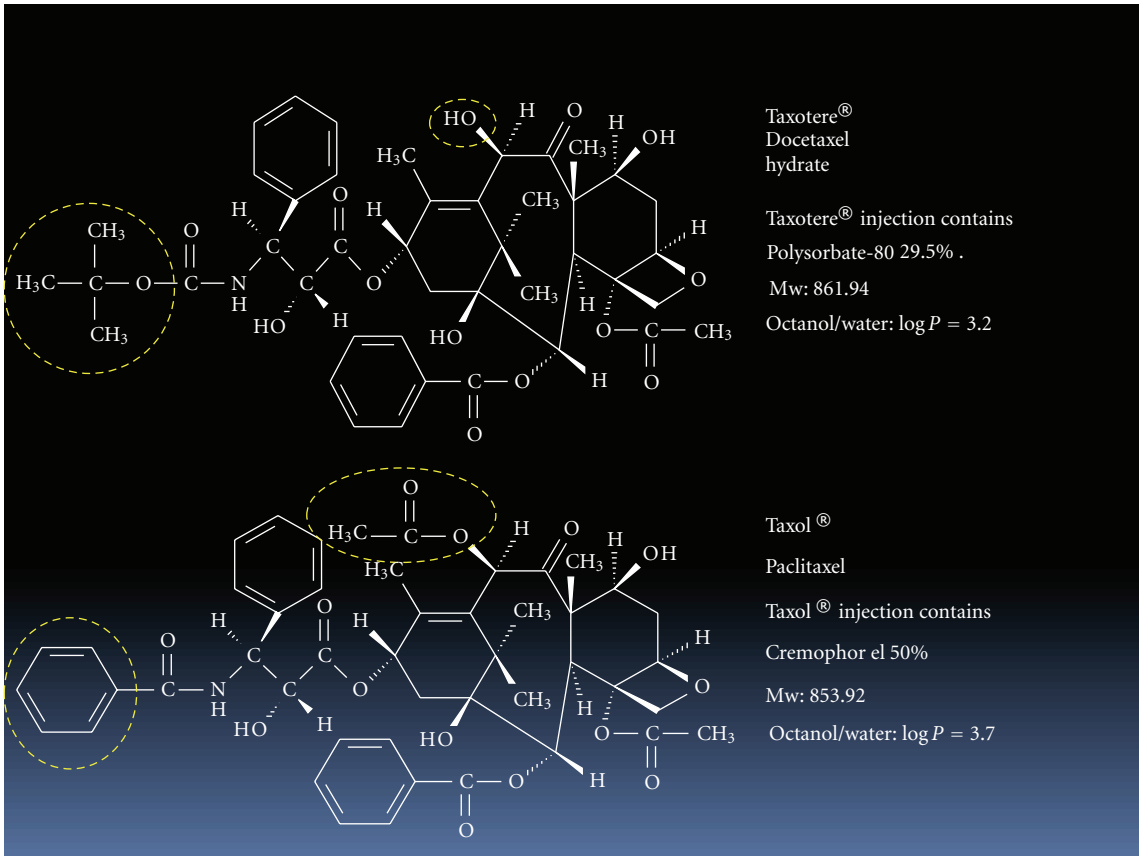

Figure 1: Chemical structures of taxane anticancer drugs. Circles indicate the differences between docetaxel and paclitaxel.

taxanes, as well as the influence of the micellar surfactant vehicles.

2. Disposition Kinetics in Patients with Peritoneal Cancers

We investigated changes of taxane concentration in the abdominal cavity and peripheral blood after i.p. administration in advanced gastric cancer patients with peritoneal dissemination [7]. Taxol (120 mg, 180 mg) or Taxotere (60 mg, 80 mg) was dissolved in 1 L of physiological saline (final concentration of surfactant; crEL: 1.1–1.6% for Taxol, PS-80: 0.15–0.2% for Taxotere). and the preparation was infused into the peritoneal cavity of nine patients for 1 h. Blood and ascites samples were collected at designated time intervals, and the concentrations of paclitaxel and docetaxel were measured using a modification of the high-performance liquid chromatography method of Vergniol et al. [8] and Loos et al. [9].

When Taxol (120 and 180 mg) was intraperitoneally infused at a volume of 1 L for 1 h, the maximum peritoneal concentrations of paclitaxel just after the infusion were about 110 and 190 μg/mL, respectively, and decreased to 16 and 19 μg/mL, respectively, after 24 h. The plasma concentration reached maximum levels of 38 and 54 ng/mL, respectively, within 3 h after the infusion and fell below the detection limit (5 ng/mL) after 24 h. On the other hand, after 1 h infusion of Taxotere (60 and 80 mg/L), the maximum peritoneal concentrations of docetaxel were 29 and 40 μg/mL, respectively. These concentrations were about a half of the calculated initial concentration of docetaxel, suggesting that the drug was distributed to the peritoneal tissues or elsewhere during infusion. The peritoneal concentration was about 1 to 6 μg/mL after 24 h. The plasma concentration reached the maximum levels of about 112 and 144 ng/mL, respectively, within 2 h after the infusion, then decreased to 5 to 10% of the maximum after 24 h.

Calculation of the pharmacokinetic parameters in ascitic fluid indicated that the distribution volume (Vd_a) and the clearance (CL_a) of docetaxel were two to three times than those of paclitaxel. Among the pharmacokinetic parameters in plasma of these drugs, Vd_p, and CL_p of paclitaxel were larger than those of docetaxel, but the AUC_p, 0−25 of docetaxel tended to be larger than that of paclitaxel. The ratio of AUC in ascitic fluid and AUC in plasma (AUC_a/AUC_p) was 500 to 1700 for paclitaxel and 50 to 100 for docetaxel (Table 1). Similarly, it has been reported that the AUC_a/AUC_p of paclitaxel (about 1,000) [10, 11] was larger than that of docetaxel (about 200) [12, 13] after i.p. infusion. These results suggest that after infusion of taxane preparations into the peritoneal cavity, docetaxel is more easily transferred to peripheral blood vessels than paclitaxel. Namely, after i.p. infusion of Taxol the peritoneal concentration of paclitaxel

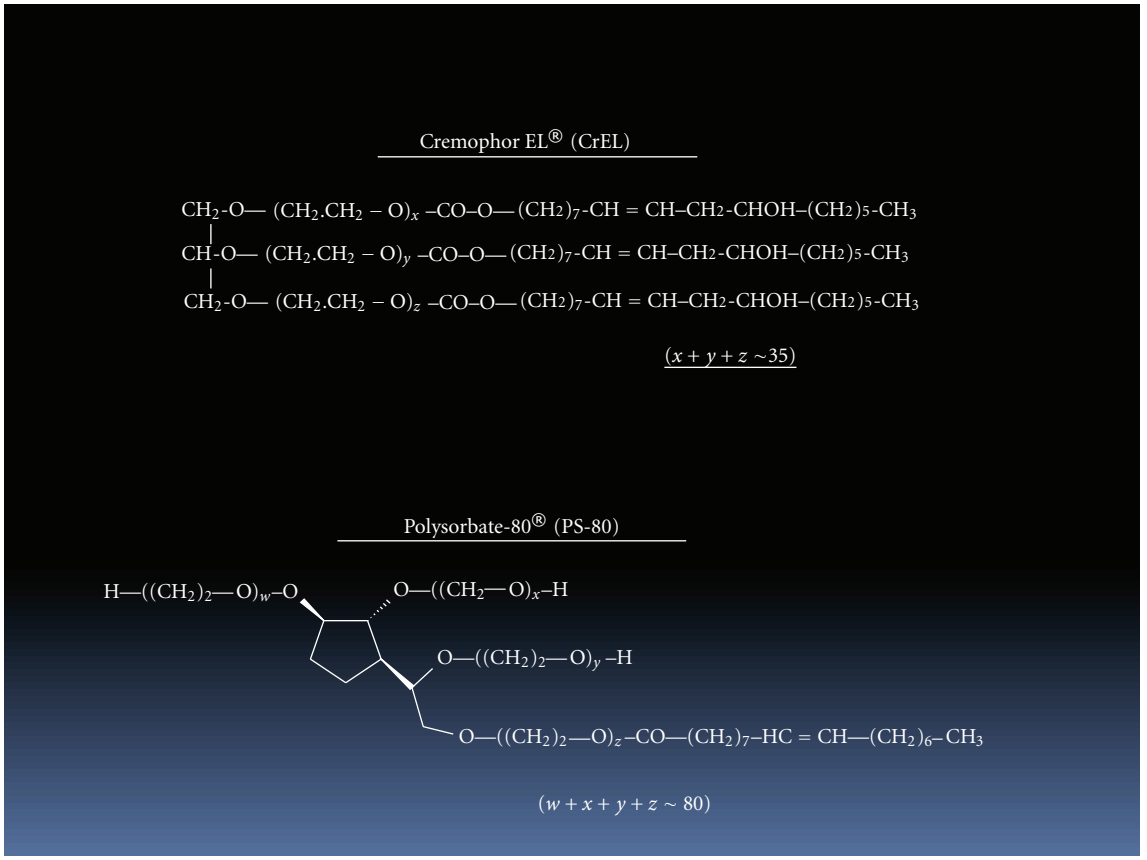

Figure 2: Chemical structures of the major components of Cremophor EL and Polysorbate-80.

Table 1: The values of AUC of paclitaxel and docetaxel in plasma and ascitic fluid after an i.p. infusion of Taxol and Taxotere in patients with peritoneal tumor [7].

		AUC_p (mg∗hr/L)	AUC_a (mg∗hr/L)	Ratio of AUC_a/AUC_p
Paclitaxel	120 mg	2.57 ± 1.43	1,298 ± 238	505
	180 mg	1.30 ± 0.86	2,214 ± 128	1705
Docetaxel	60 mg	6.65 ± 3.75	370 ± 87	56
	80 mg	2.27 ± 0.65	238 ± 24	105

The value of AUC was calculated from 0 to 25 h including the period of the infusion administration.
Each value represents the mean ± SE of three patients.
*Significantly different from Taxotere at $P < 0.01$.

was well maintained for a long time and permeation into the systemic circulation was low, suggesting that paclitaxel should be effective against peritoneal cancers, and side effects, such as bone marrow depression, should be weak. In the case of intraperitoneally administered Taxotere, the concentrations of docetaxel in the peritoneal cavity and peripheral plasma were above the cytotoxic concentration (*in vitro* IC_{50}: 4–35 ng/mL) [14], so this anticancer drug may exhibit anticancer action against peritoneal cancers but may also cause systemic side effects.

3. Disposition Kinetics in Peritoneal Dissemination Tumor Model Animals

The rat ascites hepatoma cell line AH130 was established as transplantable tumor by Yoshida [16]. This cell line is maintained by i.p. passage at weekly intervals in female Donryu rats and is widely used to prepare animal models of peritoneal cancer dissemination. The pharmacokinetic behavior of taxane anticancer drugs and the effects of their micellar formulation vehicles have been studied using

Table 2: The values of AUC of paclitaxel and docetaxel in plasma and ascitic fluid after an i.p. injection of Taxol and Taxotere into AH130 tumor-bearing rats [15].

	ka (hr^{-1})	AUC_p (mg∗hr/L)	AUC_a (mg∗hr/L)	Ratio of AUC_a/AUC_p
Paclitaxel	0.0424 ± 0.0011*	17.6 ± 5.8*	7,480 ± 255*	425
Docetaxel	0.325 ± 0.043	8.50 ± 3.27	1,300 ± 191	153

The value of AUC was calculated from 0 to 24 h after an i.p. administration of 40 mg/kg of each drug.
ka: the apparent first-order absorption rate constant from the peritoneal cavity.
Each value represents the mean ± SD of three rats.
*Significantly different from Taxotere at $P < 0.01$.

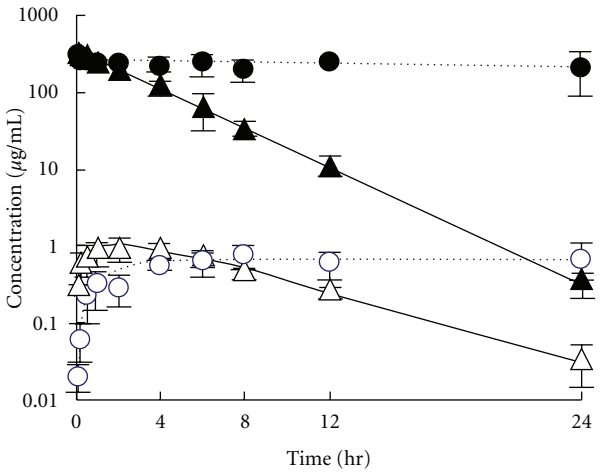

Figure 3: Time courses of paclitaxel (circles) or docetaxel (triangles) concentration in ascitic fluid (closed symbols) and plasma (open symbols) after an i.p. injection of 40 mg/kg of Taxol or Taxotere into AH130 tumor-bearing rats [15]. Each point with bar represents the mean ± SD of three rats.

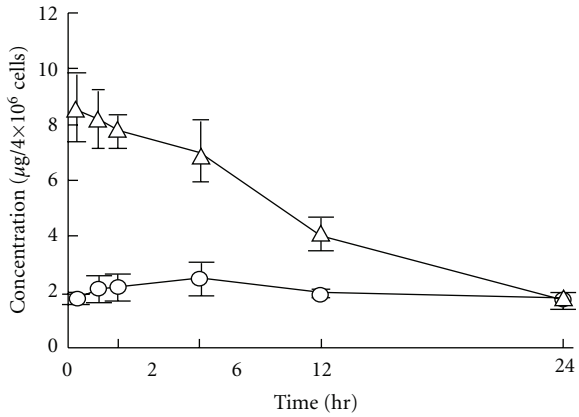

Figure 4: Time courses of paclitaxel (circles) or docetaxel (triangles) concentration in free tumor cells in the peritoneal cavity after an i.p. injection of 40 mg/kg of Taxol or Taxotere into AH130 tumor-bearing rats [15]. Each point with bar represents the mean ± SD of three rats.

this model [15]. Four-week-old female Donryu rats were inoculated with 2×10^6 AH130 cells into the peritoneal cavity and used for experiments after 1 to 2 weeks, following an overnight fast. Taxol or Taxotere was given by i.p. injection at a dose of 40 mg/kg in a 20 mL volume containing 0.2% blue dextran as a volume marker; the resulting peritoneal solutions contained 4.2% crEL for paclitacel and 1.5% PS-80 for docetaxel, which are close to the concentrations used in the case of i.v. injection of taxanes in the clinic. In the case of i.v. injection, 5 mg/kg of each drug in a volume of 200 μL was administered by bolus injection into the tail vein. After i.p. or i.v. administration of taxanes to the AH130-bearing rats, the concentrations of drugs in ascitic fluid, free cancer cells, and plasma obtained from the jugular vein were measured at designated time intervals. Solid cancers in the peritoneal cavity were excised after the rats had been killed by decapitation, and the drugs were extracted and their concentrations were measured.

After i.p. administration of taxanes, the ascitic concentration of paclitaxel decayed very slowly, whereas that of docetaxel decreased rapidly. The plasma concentrations of both drugs were very low, but that of paclitaxel increased until 4 h and then remained at a plateau, while that of docetaxel reached the maximum at 1.5 h and then decreased (Figure 3). The values of AUC_p, 0–24 h, and AUC_a, 0–24 h of paclitaxel were significantly larger, by about 2- and 6-fold, respectively, than those of docetaxel, and the apparent first-order absorption rate constant from the peritoneal cavity (ka) of paclitaxel was extremely small (Table 2). The AUC_a/AUC_p ratio of paclitaxel was much larger than that of docetaxel. These results indicate that paclitaxel was retained at much higher concentration than docetaxel in the peritoneal cavity after i.p. administration of taxane preparations, and the transfer of paclitaxel into the systemic circulation was much lower than that of docetaxel, in agreement with clinical findings [7, 10–13]. Figure 4 shows the changes of taxane concentration in free cancer cells in the peritoneal cavity after i.p. administration of Taxol and Taxotere (each 40 mg/kg). The concentration of paclitaxel was very low after Taxol administration, while that of docetaxel was high just after Taxotere administration and then decreased gradually in parallel with the decay of the peritoneal concentration. On the other hand, at 1 h after i.p. administration, the concentration of paclitaxel in solid cancer tissue growing in the peritoneum (1.3 ± 0.2 μg/g tissue) was lower than that of docetaxel (4.1 ± 2.8 μg/g tissue). Figure 5 shows the apparent concentration ratio in solid cancer tissue versus plasma (Kp, app) 1 h after i.p. or i.v. administration. No marked difference was observed between

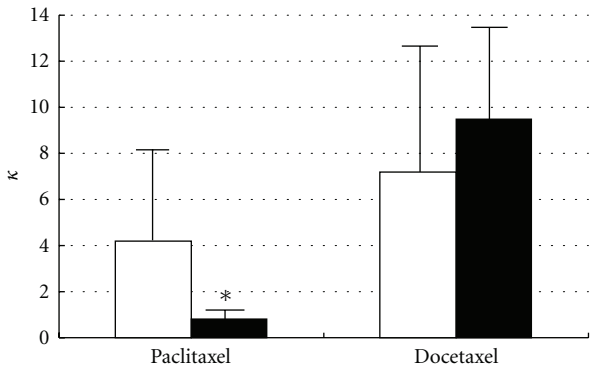

Figure 5: Values of apparent solid tumor to plasma concentration ratio (Kp, app) of paclitaxel and docetaxel 1 h after an i.p. (40 mg/kg, open column) or i.v. (5 mg/kg, closed column) injection of Taxol and Taxotere into AH130 tumor-bearing rats [15]. Each column with bar represents the mean ± SD of three rats. *Significantly different from docetaxel at $P < 0.05$.

the Kp,app values of these drugs after i.p. administration, but after i.v. administration the Kp, app of paclitaxel was significantly smaller than that of docetaxel. These results indicate that after i.p. administration of Taxol, paclitaxel was retained at high concentration in the peritoneal cavity and was not readily transferred into either the systemic circulation or cancer cells and tissues. The distribution of paclitaxel into cancer tissues was also low after i.v. administration. Docetaxel was more extensively distributed into cancer tissues than paclitaxel after administration via both routes.

Moreover, we found that i.p. administration of docetaxel rather than i.v. injection was pharmacokinetically superior in the treatment of peritoneal dissemination of cancer in mice [17, 19]. Docetaxel (8 mg/kg) was intravenously or intraperitoneally injected into athymic nude mice with peritoneal dissemination of MKN-45P human gastric cancer, and we measured the concentration changes in plasma, ascitic fluid, solid cancer tissue, and cancer cells suspended in the peritoneal cavity (Figure 6). The drug concentration in ascitic fluid was about 100-fold higher after i.p. injection than after i.v. injection, while the plasma concentrations were rather similar. In suspended free cancer cells in the peritoneal cavity, the drug concentration was much higher in the i.p. group than in the i.v. group, in parallel with the concentrations in ascites after drug injection via these routes. In the case of i.v. injection, the drug appeared rapidly in solid cancer tissue and then the concentration gradually decreased, following the change in the plasma concentration, but the apparent cancer tissue to plasma concentration ratio (Kp,app) was maintained at about 3 to 8 for 8 h, as observed in the AH130-bearing rat model (Figure 5). Docetaxel concentration in solid cancer was maintained at a higher level from 2 h to 8 h after i.p. injection as compared with that after i.v. injection. On the other hand, the docetaxel concentrations in normal organs rapidly decreased up to 1 h and then gradually decreased in the i.v. group, while in the i.p. group the concentrations increased up to 2 or 4 h after injection and then slowly decreased [17]. Namely, docetaxel injected into the peritoneal cavity was transferred rather slowly to the peripheral blood flow; the ratio of AUC_p/AUC_a after i.p. injection of docetaxel was 0.071, but when i.v. injected, the drug passed comparatively easily into the peritoneal cavity from the blood flow; the ratio of AUC_a/AUC_p after i.v. injection was 0.233 although it has been reported the existence of a blood-peritoneal barrier [2]. These results indicate that the i.p. injection of docetaxel was considered to be advantageous as a treatment method for peritoneal dissemination of cancers, offering higher local drug concentration and low systemic toxicity compared with i.v. injection.

4. Influence of Surfactant Vehicles on the Pharmacokinetic Behavior of Taxanes

Because paclitaxel and docetaxel have physicochemically similar properties, the difference of distribution after administration of these drugs may be attributed largely to the surfactant vehicles used to micellize and dissolve these drugs, but not the properties of the drugs themselves. Taxane anticancer drugs are commercially available as micellar preparations, Taxol and Taxotere, which consist of paclitaxel in crEL and docetaxel in PS-80, respectively. It has been reported that surfactants increase cellular accumulation of anticancer drugs and modulate the drug resistance of cancers expressing P-glycoprotein [20, 21]. On the other hand, crEL has been reported to inhibit the intestinal absorption and tissue permeability of paclitaxel [22–25]. However, P-glycoprotein is an efflux transporter in both multidrug-resistant cells and small intestinal epithelium cells, and therefore if these surfactants only inhibit the function of P-glycoprotein, drug accumulation should increase. This apparent contradiction may be explained as follows. CrEL increased the sensitivity of multidrug-resistant cells to daunorubicin at concentrations over 0.1 μL/mL (0.01%) and completely reversed the resistance at 2.0 μL/mL (0.2%) [26, 27]. PS-80 has also been shown to be a multidrug resistance modulator in vitro at concentrations between 0.2 and 0.3 μL/mL (0.02–0.03%) [21, 28] but was ineffective in vivo, because of its very rapid clearance [27, 29]. Then, we examined the influence of crEL and PS-80 on the in vitro uptake of taxanes into AH130 cells, which do not express P-glycoprotein [30]. The intracellular uptake of docetaxel and paclitaxel decreased with increasing vehicle concentration (Figure 7). When these drugs were dissolved in 0.0125% ethanol (final concentration), the intracellular amounts of these drugs were similar, but in the presence of surfactants (at concentrations above 0.0125%) paclitaxel transport into the cells was less than half that of docetaxel. CrEL and PS-80 at concentrations above 0.5% both inhibited paclitaxel entry into red blood cells, in a concentration-dependent manner and with similar potency [18]. These results indicate that both surfactants inhibit the plasma membrane permeability at concentrations above 0.125%, although they can modulate the P-glycoprotein-dependent drug transport at lower concentrations. It is thought that the cell membrane

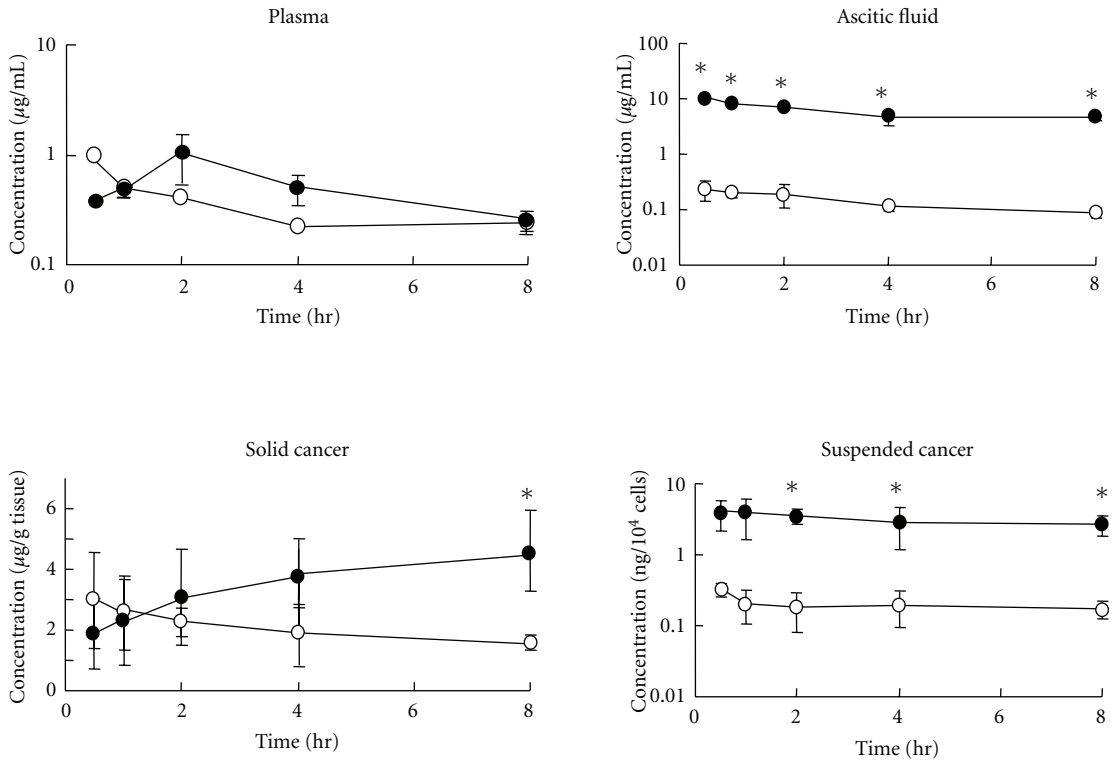

Figure 6: Time courses of docetaxel concentration in plasma, ascetic fluid, solid cancer, and suspended free cancer cells after an i.v. or i.p. injection of Taxotere in MKN-45P gastric cancer-bearing mice [17]. Taxotere (8 mg/kg) was i.v. (open symbols) or i.p. (closed symbols) injected into cancer-bearing mice on day 21 after i.p. inoculation of 10^7 MKN-45P gastric cancer cells. Each point with bar represents the mean ± SD of three mice. *Significantly different from i.v. injection at $P < 0.05$.

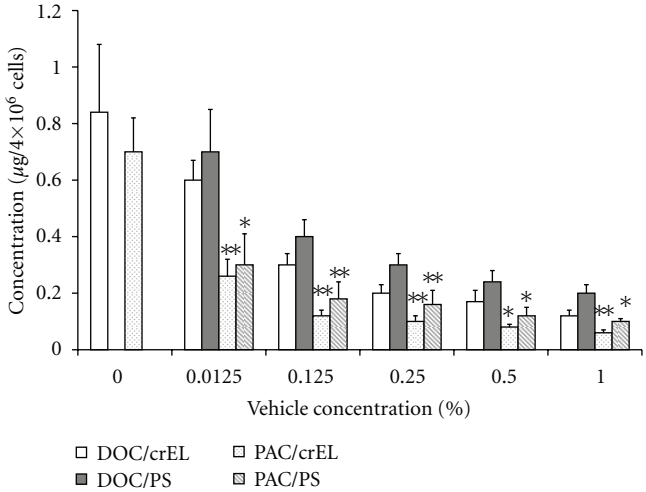

Figure 7: Effects of surfactants on uptake of paclitaxel and docetaxel in AH130 cells. Cells were treated with 3 μg/mL of docetaxel (DOC) or paclitaxel (PAC) dissolved with 0.125% ethanol (0) or the indicated concentrations of crEL or PS-80 (PS) for 30 min. The data at 0.0125% concentration of these surfactants are taken from [15]. Each column with bar represents the mean ± SD of at least three experiments performed in triplicate. *,**Significantly different from docetaxel at $P < 0.05$ and 0.01, respectively.

permeability of taxanes is determined by the degree of affinity for, and the ease of dissociation from, surfactant micelles [31]. Paclitaxel seems to be trapped in the surfactant micelles more easily and binds to them more strongly than docetaxel.

Next, we compared the influence of surfactants on the in vivo pharmacokinetics of taxanes administered intraperitoneally to rats [18]. After injection of paclitaxel in 4.2% crEL into the peritoneal cavity, the permeation of paclitaxel into the systemic circulation was very slow compared with that

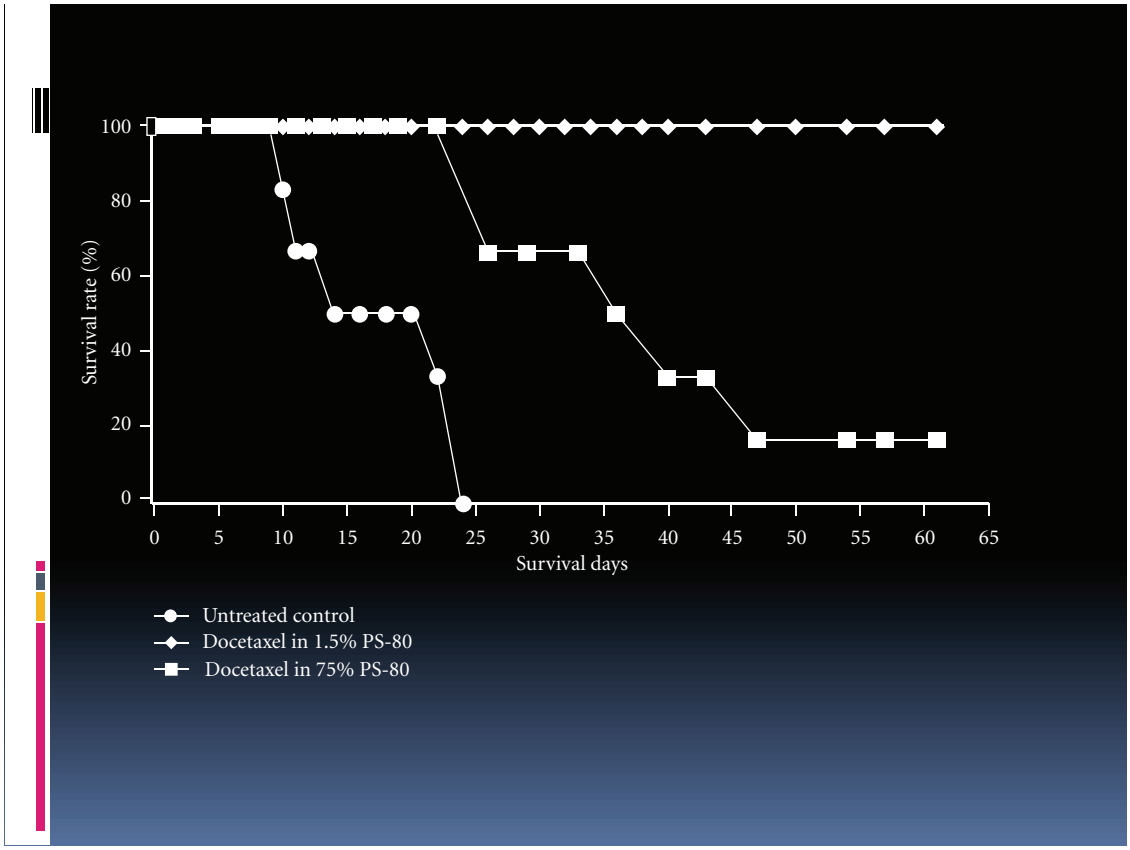

Figure 8: Influence of PS-80 on the anticancer effect of docetaxel (1 mg/kg) in AH130 tumor-bearing rats. AH130 tumor-bearing rats were intraperitoneally administered 1 mg/kg of docetaxel in a volume of 20 mL of 1.5% or 7.5% PS-80 on day 0. $N = 6$.

Table 3: Pharmacokinetic parameters of paclitaxel (PAC) and docetaxel (DOC) in plasma and ascitic fluid after an i.p. administration of drugs in crEL or PS-80 to nontumor rats [18].

	ka (hr^{-1})	AUC_p (mg∗hr/L)	AUC_a (mg∗hr/L)	Ratio of AUC_p/AUC_a
PAC in 4.2% crEL	0.019 ± 0.0018*	18.4 ± 3.3*	8,870 ± 790*	0.00207 ± 0.00029*
DOC in 1.5% PS-80	0.394 ± 0.021	6.93 ± 1.32	1,170 ± 120	0.00592 ± 0.00153
DOC in 4.2% crEL	0.165 ± 0.004	8.59 ± 1.23	3,520 ± 110	0.00244 ± 0.00026
DOC in 7.5% PS-80	0.130 ± 0.005	11.4 ± 1.1	3,130 ± 320	0.00364 ± 0.00026

The value of AUC was calculated from 0 to 24 h after an i.p. administration of 40 mg/kg of each drug.
ka: the apparent first-order absorption rate constant from the peritoneal cavity.
Each value represents the mean ± SD of three rats.
*Significantly different from DOC in 1.5% PS-80 at $P < 0.01$.

of docetaxel in 1.5% PS-80. However, the permeation of docetaxel from the peritoneal cavity to the peripheral blood stream was markedly decreased by changing the surfactant from 1.5% PS-80 to 4.2% crEL though it did not reach the level of paclitaxel in 4.2% crEL. van Tellingen et al. [29] noted that PS-80 does not interfere with the disposition kinetics of docetaxel. However, the peritoneal permeability of docetaxel was lowered by increasing the concentration of PS-80 to 7.5% (Table 3).

Thus, the disposition kinetics of paclitaxel is influenced more strongly than that of docetaxel by micellar surfactants, as the concentration is increased.

5. Influence of Surfactants on the Anticancer Effect of Taxanes

Finally, we examined the influence of surfactants on the anticancer effect of docetaxel after i.p. administration to AH130-bearing rats. The anticancer effect of docetaxel became less potent as the concentration of PS-80 was increased (Figure 8). The surfactant not only decreased the permeation of the taxane into the systemic circulation and maintained a high concentration of the drugs in the peritoneal cavity (Table 2), but also inhibited the drug transport into cancer cells, in a concentration-dependent manner,

thereby reducing the anticancer effect. Similarly, it is thought that the anticancer effect of paclitaxel is strongly influenced by its vehicle, crEL, because the cell permeation of paclitaxel is readily inhibited by surfactants. The antitumor potency of Taxotere is known to be about 3 times that of Taxol. But, this difference in the potency of these antitumor drugs may be due largely to the difference in the kind and concentration of micellar surfactants used. Moreover, it has been reported that PS-80 is readily degraded by serum esterase [27, 29, 31], while crEL is stable in the body [32]. Consequently, because Taxotere readily releases docetaxel in the peritoneal cavity so that it can rapidly permeate into the systemic circulation, not only can docetaxel be directly transported into cancer cells, but also the drug can be distributed to cancer cells from the blood. This has been called the "sandwich effect" of Taxotere or the dual anticancer effect of docetaxel [33]. Taxol, a paclitaxel formulation with crEL, hardly releases the antitumor agent, so the distribution to tumors is small, and the antitumor potency may be less than that of Taxotere.

6. Conclusion and Perspective

Though the chemical and physical properties of taxane anticancer drugs, paclitaxel, and docetaxel are very similar, the disposition kinetics of these drugs are markedly influenced by their micellar surfactant vehicles after administration of commercial preparations. To treat peritoneal dissemination of cancers, i.p. administration seems logically preferable to systemic administration. In fact, after i.p. administration of commercial preparations diluted with physiological solution, paclitaxel showed a much higher i.p. concentration and less penetration into the systemic circulation than docetaxel. Consequently, the anticancer effect of paclitaxel appears to be stronger than that of docetaxel. However, actually the opposite is the case because the cell permeability of paclitaxel is significantly inhibited by surfactants. Taxol is a micellar formulation of paclitaxel in crEL, of which the content is much higher than in other crEL micellar preparations [34]. Taxotere is a preparation of docetaxel micellized with PS-80, which is rapidly degraded in the body and readily releases the anticancer ingredient, as compared with crEL. These characteristics seem to be the reasons why the anticancer effect of Taxotere is more potent than that of Taxol. Moreover, because many drugs are solubilized in a micellar surfactant vehicle, such as crEL, pharmacokinetic and pharmacodynamic drug-drug interactions may occur when hydrophobic drugs are administered in combination with an injection preparation containing a surfactant vehicle [35]. Further, a preparation not containing crEL is desirable to avoid hypersensitivity reaction. Recently, Abraxane has been developed as a novel crEL-free nanoparticle albumin-bound paclitaxel preparation. Data on the disposition kinetics of paclitaxel after i.p. administration of the preparation have not yet been reported and would be of considerable interest. Furthermore, hyperthermic intraperitoneal chemoperfusion (HIPEC) has been developed for treatment for peritoneal cancers with a variety of anticancer agents. It will also be important to study the pharmacokinetics of anticancer drugs in HIPEC to ensure safe and effective treatment.

Conflict of Interests

The authors do not have any conflict of interests with the content of the manuscript.

References

[1] J. F. Diaz and J. M. Andreu, "Assembly of purified GDP-tubulin into microtubules induced by taxol and taxotere: reversibility, ligand stoichiometry, and competition," *Biochemistry*, vol. 32, no. 11, pp. 2747–2755, 1993.

[2] N. Furui, T. Yamazaki, K. Yokogawa, Y. Fushida, K. Miwa, and K. Miyamoto, "Ascites and the plasma cencentration-time courses of the taxanes after an intraperitoneal administration in patients with peritoneal tumors," *Japanese Journal of Pharmaceutical Health Care and Sciences*, vol. 29, no. 3, pp. 263–269, 2003.

[3] S. Fushida, F. Nao, S. Kinami et al., "Pharmacologic study of intraperitoneal docetaxel in gastric cancer patients with peritoneal dissemination," *Japanese Journal of Cancer and Chemotherapy*, vol. 29, no. 10, pp. 1759–1763, 2002.

[4] S. Fushida, N. Furui, S. Kinami et al., "Pharmacologic study of intraperitoneal paclitaxel in gastric cancer patients with peritoneal dissemination," *Japanese Journal of Cancer and Chemotherapy*, vol. 29, no. 12, pp. 2164–2167, 2002.

[5] Y. Yonemura, E. Bandou, K. Kinoshita et al., "Effective therapy for peritoneal dissemination in gastric cancer," *Surgical Oncology Clinics of North America*, vol. 12, no. 3, pp. 635–648, 2003.

[6] P. H. Sugarbaker, J. T. Mora, P. Carmignani, O. A. Stuart, and D. Yoo, "Update on chemotherapeutic agents utilized for perioperative intraperitoneal chemotherapy," *Oncologist*, vol. 10, no. 2, pp. 112–122, 2005.

[7] P. H. Sugarbaker, "Peritoneal-plasma barrier," in *Peritoneal Carcinomatosis: Principles of Management*, P. H. Sugarbaker, Ed., pp. 53–63, Kluwer Academic Publisher, Boston, Mass, USA, 1996.

[8] J. C. Vergniol, R. Bruno, G. Montay, and A. Frydman, "Determination of Taxotere in human plasma by a semi-automated high-performance liquid chromatographic method," *Journal of Chromatography*, vol. 582, no. 1-2, pp. 273–278, 1992.

[9] W. J. Loos, J. Verweij, K. Nooter, G. Stoter, and A. Sparreboom, "Sensitive determination of docetaxel in human plasma by liquid-liquid extraction and reversed-phase high-performance liquid chromatography," *Journal of Chromatography B*, vol. 693, no. 2, pp. 437–441, 1997.

[10] F. Mohamed and P. H. Sugarbaker, "Intraperitoneal taxanes," *Surgical Oncology Clinics of North America*, vol. 12, no. 3, pp. 825–833, 2003.

[11] L. S. Hofstra, A. M. E. Bos, E. G. E. de Vries et al., "Kinetic modeling and efficacy of intraperitoneal paclitaxel combined with intravenous cyclophosphamide and carboplatin as first-line treatment in ovarian cancer," *Gynecologic Oncology*, vol. 85, no. 3, pp. 517–523, 2002.

[12] F. Mohamed, O. A. Stuart, and P. H. Sugarbaker, "Pharmacokinetics and tissue distribution of intraperitoneal docetaxel with different carrier solutions," *Journal of Surgical Research*, vol. 113, no. 1, pp. 114–120, 2003.

[13] R. J. Morgan, J. H. Doroshow, T. Synold et al., "Phase I trial of intraperitoneal docetaxel in the treatment of advanced malignancies primarily confined to the peritoneal cavity

dose-limiting toxicity and pharmacokinetics," *Clinical Cancer Research*, vol. 9, pp. 5896–5901, 2003.

[14] M. C. Bissery, G. Nohynek, G. Sanderink, and F. Lavelle, "Docetaxel (Taxotere): a review of preclinical and clinical experience. part I: preclinical experience," *Anti-Cancer Drugs*, vol. 6, no. 3, pp. 339–368, 1995.

[15] T. Yoshida, "Contributions of the ascites hepatoma to the concept of malignancy of cancer," *Annals of the New York Academy of Sciences*, vol. 63, no. 5, pp. 852–881, 1956.

[16] Y. Kamijo, C. Ito, M. Nomura, Y. Sai, and K. Miyamoto, "Surfactants influence the distribution of taxanes in peritoneal dissemination tumor-bearing rats," *Cancer Letters*, vol. 287, no. 2, pp. 182–186, 2010.

[17] Y. Yonemura, Y. Endou, E. Bando et al., "Effect of intraperitoneal administration of docetaxel on peritoneal dissemination of gastric cancer," *Cancer Letters*, vol. 210, no. 2, pp. 189–196, 2004.

[18] T. Shimada, M. Nomura, K. Yokogawa et al., "Pharmacokinetic advantage of intraperitoneal injection of docetaxel in the treatment for peritoneal dissemination of cancer in mice," *Journal of Pharmacy and Pharmacology*, vol. 57, no. 2, pp. 177–181, 2005.

[19] G. J. Schuurhuis, H. J. Broxterman, H. M. Pinedo et al., "The polyoxyethylene castor oil Cremophor EL modifies multidrug resistance," *British Journal of Cancer*, vol. 62, no. 4, pp. 591–594, 1990.

[20] E. Friche, P. B. Jensen, M. Sehested, E. J. F. Demant, and N. N. Nissen, "The solvents Cremophor EL and Tween 80 modulate daunorubicin resistance in the multidrug resistant Ehrlich ascites tumor," *Cancer Communications*, vol. 2, no. 9, pp. 297–303, 1990.

[21] A. Sparreboom, O. van Teilingen, W. J. Nooijen, and J. H. Beijnen, "Nonlinear pharmacokinetics of paclitaxel in mice results from the pharmaceutical vehicle cremophor EL," *Cancer Research*, vol. 56, no. 9, pp. 2112–2115, 1996.

[22] A. G. Ellis and L. K. Webster, "Inhibition of paclitaxel elimination in the isolated perfused rat liver by Cremophor EL," *Cancer Chemotherapy and Pharmacology*, vol. 43, no. 1, pp. 13–18, 1999.

[23] H. A. Bardelmeijer, M. Ouwehand, M. M. Malingre, J. H. Schellens, J. H. Beijnen, and O. van Tellingen, "Entrapment by Cremophor EL decreases the absorption of paclitaxel from the gut," *Cancer Chemotherapy and Pharmacology*, vol. 49, no. 2, pp. 119–125, 2002.

[24] H. Gelderblom, J. Verweij, D. M. van Zomeren et al., "Influence of Cremophor EL on the bioavailability of intraperitoneal paclitaxel," *Clinical Cancer Research*, vol. 8, no. 4, pp. 1237–1241, 2002.

[25] L. K. Webster, M. E. Linsenmeyer, M. J. Millward, C. Morton, J. F. Bishop, and D. M. Woodcock, "Measurement of cremophor EL following taxol: plasma levels sufficient to reverse drug exclusion mediated by the multidrug-resistant phenotype," *Journal of the National Cancer Institute*, vol. 85, no. 20, pp. 1685–1690, 1993.

[26] L. K. Webster, M. E. Linsenmeyer, D. Rischin, M. E. Urch, D. M. Woodcock, and M. J. Millward, "Plasma concentrations of polysorbate 80 measured in patients following administration of docetaxel or etoposide," *Cancer Chemotherapy and Pharmacology*, vol. 39, no. 6, pp. 557–560, 1997.

[27] D. M. Woodcock, M. E. Linsenmeyer, G. Chojnowski et al., "Reversal of multidrug resistance by surfactants," *British Journal of Cancer*, vol. 66, no. 1, pp. 62–68, 1992.

[28] O. van Tellingen, J. H. Beijnen, J. Verweij, E. J. Scherrenburg, W. J. Nooijen, and A. Sparreboom, "Rapid esterase-sensitive breakdown of polysorbate 80 and its impact on the plasma pharmacokinetics of docetaxel and metabolites in mice," *Clinical Cancer Research*, vol. 5, no. 10, pp. 2918–2924, 1999.

[29] S. Wakusawa, S. Nakamura, and K. Miyamoto, "Establishment by adriamycin exposure of multidrug-resistant rat ascites hepatoma AH130 cells showing low DT-diaphorase activity and high cross resistance to mitomycins," *Japanese Journal of Cancer Research*, vol. 88, no. 1, pp. 88–96, 1997.

[30] K. Yokogawa, M. Jin, N. Furui et al., "Disposition kinetics of taxanes after intraperitoneal administration in rats and influence of surfactant vehicles," *Journal of Pharmacy and Pharmacology*, vol. 56, no. 5, pp. 629–634, 2004.

[31] L. van Zuylen, J. Verweij, and A. Sparreboom, "Role of formulation vehicles in taxane pharmacology," *Investigational New Drugs*, vol. 19, no. 2, pp. 125–141, 2001.

[32] A. Sparreboom, J. Verweij, M. E. L. van de Burg et al., "Disposition of Cremophor EL in humans limits the potential for modulation of the multidrug resistance phenotype in vivo," *Clinical Cancer Research*, vol. 4, no. 8, pp. 1937–1942, 1998.

[33] S. Fushida, J. Kinoshita, Y. Yagi et al., "Dual anti-cancer effects of weekly intraperitoneal docetaxel in treatment of advanced gastric cancer patients with peritoneal carcinomatosis: a feasibility and pharmacokinetic study," *Oncology Reports*, vol. 19, no. 5, pp. 1305–1310, 2008.

[34] R. T. Dorr, "Pharmacology and toxicology of Cremophor EL diluent," *Annals of Pharmacotherapy*, vol. 28, no. 5, pp. S11–S14, 1994.

[35] M. Jin, T. Shimada, K. Yokogawa et al., "Cremophor EL releases cyclosporin A adsorbed on blood cells and blood vessels, and increases apparent plasma concentration of cyclosporin A," *International Journal of Pharmaceutics*, vol. 293, no. 1-2, pp. 137–144, 2005.

Hindawi Publishing Corporation
Gastroenterology Research and Practice
Volume 2012, Article ID 521487, 10 pages
doi:10.1155/2012/521487

Clinical Study

Surgical Results of Patients with Peritoneal Carcinomatosis Treated with Cytoreductive Surgery Using a New Technique Named Aqua Dissection

Y. Yonemura,[1,2,3] A. Elnemr,[1] Y. Endou,[4] H. Ishibashi,[1,3] A. Mizumoto,[2] M. Miura,[5] and Yan Li[6]

[1] *NPO Organization to Support Peritoneal Surface Malignancy Treatment, 1-26, Haruki-Moto-Machi, Kishiwada, Osaka, Japan*
[2] *Department of Surgery, Kusatsu General Hospital, Shiga, Japan*
[3] *Department of Surgery, Peritoneal Surface Malignancy Center, Kishiwada Tokushukai Hospital, Kishiwada, Japan*
[4] *Department of Experimental Therapeutics, Cancer Research Institute, Kanazawa University, Kanazawa, Japan*
[5] *Department of Anatomy, School of Medicine, Oita University, Oita, Japan*
[6] *Department of Oncology, Zhongnam Hospital and Cancer Center, Wuhan University, Wuhan, China*

Correspondence should be addressed to Y. Yonemura, y.yonemura@coda.ocn.ne.jp

Received 14 January 2012; Accepted 11 March 2012

Academic Editor: Pompiliu Piso

During 2004 to 2011, 81, 420, and 166 patients with colorectal cancer (CRC), epithelial appendiceal neoplasm (APN), and gastric cancer (GC) with PC were treated with cytoreductive surgery (CRS) plus perioperative chemotherapy. CRS was performed by peritonectomy techniques using an aqua dissection. *Results*. Complete cytoreduction was done in 62/81 (76.5%), 228/420 (54.3%), and 101/166 (60.8%) of patients with CRC, APN, and GC. The main reasons of incomplete resections were involvement of all peritoneal regions and diffuse involvement of small bowel. The incidence (64%, 302/470) of CC-0 resection after introduction of an aqua dissection was significantly higher than before (42%, 82/197). A total of 41 (6.1%) patients died postoperatively. Major complication (grade 3-4 complications) occurred in 126 patients (18.9%). A reoperation was necessary in 36 patients (5.4%). By the multivariate analysis, PCI scores capable of serving as thresholds for favorable versus poor prognosis in each group and CC scores demonstrated as the independent prognostic factors. *Conclusions*. Peritonectomy using an aqua dissection improves the incidence of complete cytoreduction, and improves the survival of patients with PC. Patients with PCI larger than the threshold values should be treated with chemotherapy to improve the incidences of complete cytoreduction.

1. Introduction

The current state-of-the-art treatment for the peritoneal carcinomatosis (PC) from colorectal, appendiceal, and gastric cancers consists of a comprehensive management strategy using cytoreductive surgery (CRS) and perioperative intraperitoneal chemotherapy (PIC) [1–5]. Patients with a low tumor volume, well/moderately differentiated tumors, and complete cytoreduction may potentially benefit from combined treatment. No survival benefit has been reported by cytoreduction alone [3]. In contrast, CRS plus hyperthermic intraoperative intraperitoneal chemotherapy (HIPEC) confers a prolonged survival period [2, 3]. Among several prognostic factors, complete cytoreduction is the most important prognostic factor for a good outcome [1–3].

However, complete cytoreduction is sometimes difficult in patients with deep invasion into the liver hilum, lesser omentum, pelvic structures, liver parenchyma, or diffuse involvement of the mesentery and serosa of small bowel. Even by the most experienced surgeons in the world, the incidences of complete cytoreduction are reported 77% (617/802) [4]. However, the complete cytoreduction rate depends on the selection criteria for the CRS and the ability and experiences of the surgeons. In the present paper, our

surgical techniques for the complete yet safe cytoreduction and the results after CRS will be reported; 81 (42.9%), 420 (72.7%) and 166 (51.5%).

2. Patients and Methods

2.1. Patients. Between June, 2004, and January, 2011, a total of 667 patients underwent CRS combined with PIC for peritoneal carcinomatosis from colorectal origin (N = 81), epithelial appendiceal neoplasm (N = 420), and gastric cancer (N = 166), led by a single surgeon (Y. Yonemura) at Kishiwada Tokushukai and Kusatsu General Hospital, Japan. The included patients were >19 and, <87 years old, with good performance status (World Health Organization Performance Status ≤2). All patients underwent extensive preoperative investigations, which included physical examination and abdominal, pelvic, and chest computed tomography (CT) scans to assess the extent of the disease involved. CT scans were performed following the administration of oral and intravenous contrast media. Signed informed consent was obtained from all patients.

2.2. Quantitative Evaluation of the Volume of PC and Assessment Completeness of Cytoreduction. Preoperatively, the tumor volume was quantified according to computed tomography (CT) scans using the Peritoneal Cancer Index (PCI, Washington Cancer Institute) [6, 7]. The abdomen and pelvis were divided into nine regions and the small bowel into four: each assigned a lesion size (LS) score of 0–3, representative of the largest implant visualized. LS-0 denotes the absence of implants, LS-1 indicates implants <0.25 cm, LS-2 implants between 0.25 and 5 cm, and LS-3 implants >5 cm or a confluence of disease. These figures amount to a final numerical score of 0–39.

2.3. Selection Criteria for CRS. CRS consists of numerous surgical procedures depending on the extent of peritoneal tumor manifestation. Surgery may include parietal and visceral peritonectomy, greater and lesser omentectomy, splenectomy, cholecystectomy, resection of the liver capsule, small bowel resections, colonic and rectal resections, gastrectomy, pancreatic resection, hysterectomy, ovariectomy, and urine bladder resection [8].

Patients who had the following criteria are excluded as candidates for peritonectomy: (1) evidence of lymph node involvement and distant hematogenous metastasis confirmed by computed tomography (CT), magnetic resonance imaging (MRI), or ^{18}Fluorodeoxyglucose positron emission tomography (PET/CT), (2) progressive disease after preoperative chemotherapy, and (3) severe comorbidities or poor general condition.

2.4. Methods of CRS Using Peritonectomy Techniques

2.4.1. Dissection Techniques of CRS. Under general anesthesia, midline incision was made from the xiphoid to the pubis, and PCI score was calculated in each case [8, 9].

For the tissue dissection, electrosurgical techniques are used. In electrosurgery, a generator delivers high frequency current greater than 200 kHz under high power electricity (100 Watt), and the tissue impedance converts electric current into thermal energy, resulting in the localized tissue heating and coagulation. We use the electrosurgical generator (Valleylab Inc., Boulder, CO, USA), on pure cut and adjusted to the maximum electrical power. The mainly used handpiece is the ball-tipped type. The 2 mm ball-tip electrode is used for dissecting on visceral surfaces, including stomach, small bowel, and colon. When more rapid tumor destruction is required, the 5 mm ball-tip can be used.

Before the tissue dissection with electrosurgery, a 5% dextran solution plus adrenaline (a concentration of 10^{-6}) is injected into the dissection plane to separate the layers properly and to decrease bleeding. The technique is named the *aqua dissection* method and was started in January, 2008. The ball-tipped instrument is placed at the interface of tumor and normal tissues. The focal point for further dissection is placed on strong traction.

2.4.2. Peritonectomy for Parietal Peritoneum. The skin incision deepened through the *linea alba* till reaching the extraperitoneal fat layer without opening the peritoneum. Then, both sides of the parietal peritoneum are peeled off from the posterior rectus sheath by the traction of the skin using stay silk sutures and anchoring the edge of the skin to the ring frame of the Munster retractor. As the plane between the posterior rectus sheath and peritoneum is loose in the area inferior to the arcuate line, the dissection is started in the lower parietal peritoneum. Then, the dissection between the peritoneum and the transversalis fascia is continued to the retroperitoneal space. The dissection continues deeply and in a counterclockwise direction, starting in the right flank till reaching the peritoneum covering the left cupula of the diaphragm. Then, the dissection is completed in the upper right side till reaching the anterior renal fascia, inferior vena cava, and posterior wall of the duodenum.

The peritoneum of the Morrison pouch and paracolic gutters on both sides is completely freed from retroperitoneum and is removed with the anterior parietal peritoneum. The ureters and gonadal vessels are identified and taped. In males, the gonadal vessels should be preserved but are removed with the ovary in females.

The dissected parietal peritoneum is opened in the midline, and extensive wash and aspiration of the peritoneal cavity ten times using one liter of normal saline each time is done. The purpose of the washing is to remove peritoneal free cancer cells and mucinous materials from the peritoneal cavity. During the washing surgeons decide the operation plan.

2.4.3. Peritonectomy of the Undersurface of Diaphragm. If the undersurface of the diaphragm is involved, stripping of peritoneum from the right and left hemidiaphragm is done. The falciform and round ligament are taken down and resected completely. Bleeding from diaphragmatic muscle is stopped by argon beam coagulation (ABC) which has a penetration

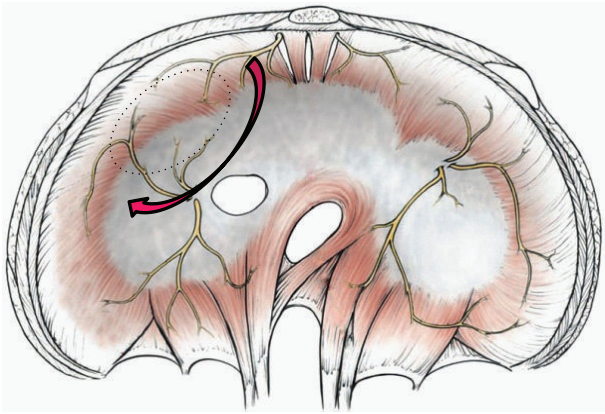

Figure 1: Cancer cells tend to invade the muscle layer of the encircled area of the right hemidiaphragm, where is the boundary of bare area and peritoneal reflection. Bare area below the invaded.

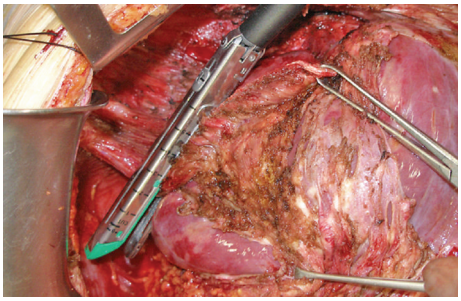

Figure 2: Partial resection of the diaphragm by using a linear stapler.

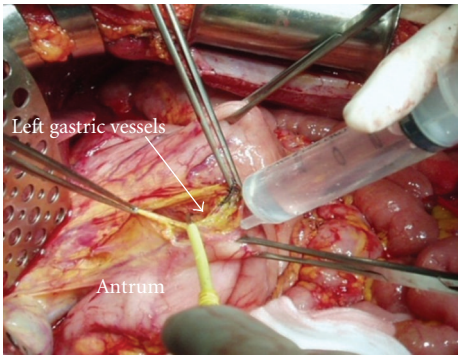

Figure 3: A 5% dextrose solution is injected in the incision site on the lesser curvature, and the left gastric vessels are identified and taped. Aqua dissection technique.

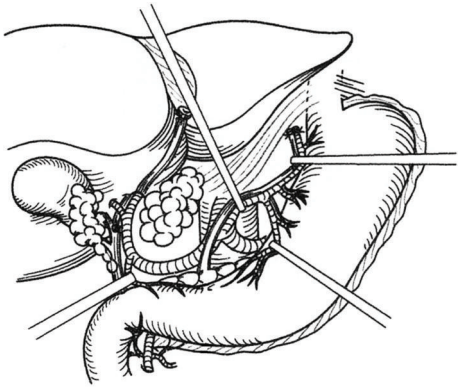

Figure 4: Preservation of the left gastric vessels and whole stomach. Surgical techniques of the removal of lesser omental tumors.

depth of coagulation limited to a few millimeters. Advantages of ABC include the ability to coagulate broad surface areas and larger vessels.

Figure 1 shows the area where cancer cells tend to invade into the muscle layer of the right hemidiaphragm. After the blunt dissection of the posterior space of the invaded diaphragm with finger between diaphragm and the bare area, partial resection of the full thickness of the right diaphragmatic cupula infiltrated by tumor is excised using a linear stapler (Figure 2). The staple line is then reinforced with an absorbable suture material.

2.4.4. Perigastric Peritonectomy. A greater omentectomy is performed with combination of splenectomy and the resection of anterior leaf of mesocolon. If the omentum is free of disease, gastroepiploic arcade is preserved after taping the root of the vessels. Greater omentum is removed with the right gastroepiploic vessels if it is involved with bulky tumor. Splenic artery and vein are identified and ligated at the splenic hilum. If the right gastroepiploic vessels and spleen are removed, left gastric artery and vein should be preserved. After the left lobe of the liver is freed from the left triangular ligament, resection of the lesser omentum along the Arantius duct is started. Next the small incisions are made on the peritoneal attachment to the stomach wall, and the 5% dextran solution is injected through the incision (*aqua dissection* technique), resulting in the separation of lesser omental tumor from the left gastric vessels. In the appendiceal tumor and colorectal cancer, the boundary between tumor and normal tissue is clear, and the omental tumors can be easily removed by the traction of the taped vessels (Figures 3 and 4). The whole stomach is preserved by the preservation of the left gastric vessels without perforation.

Except for gastric cancer, gastrectomy may be sometimes indicated in patients with peritoneal carcinomatosis from PMP, colorectal cancer, ovarian cancer, and mesothelioma [6, 7]. The reason of gastrectomy is the tumor invasion into the gastric wall. The parts of gastric wall liable to involvement by the disease process are (1) the posterior wall of the antrum in the vestibule of the omental bursa, (2) the mid-lesser curvature, which are invaded from the metastasis of lesser omentum, and (3) the upper greater curvature by the invasion from splenic hilar metastasis (Figure 5). In PMP, almost all invasions are limited in the muscle layer of stomach. If the invasion into the stomach wall is less than 5 cm in diameter, a seromuscular resection or a wedge resection of the whole layer of the stomach using stapler techniques is recommended. Surgeons should decide the

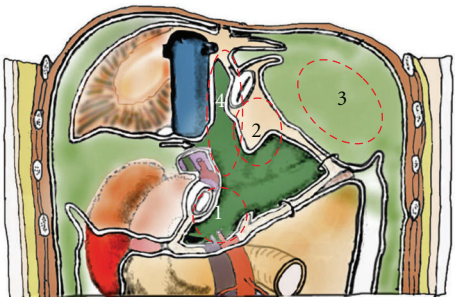

Figure 5: The parts of gastric wall liable to involvement by the disease process (dotted line): (1) the posterior wall of the antrum in the vestibule of the omental bursa, (2) the mid-lesser curvature, which are invaded from the metastasis of lesser omentum, and (3) the upper greater curvature by the invasion from splenic hilar metastasis. Region 4 is named as superior omental recessus, which is frequently involved in pseudomyxoma peritonei.

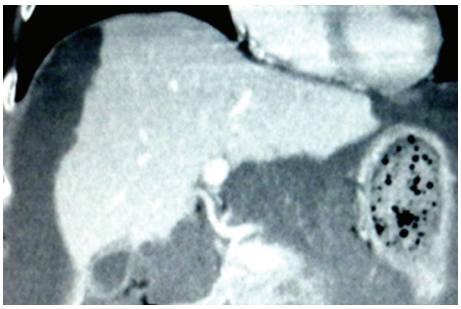

Figure 6: Enhanced CT scan shows tumor located in the hilar, cystic, and umbilical plate, and tumor extended in Glisson's capsule.

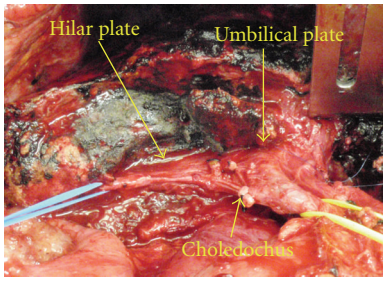

(a)

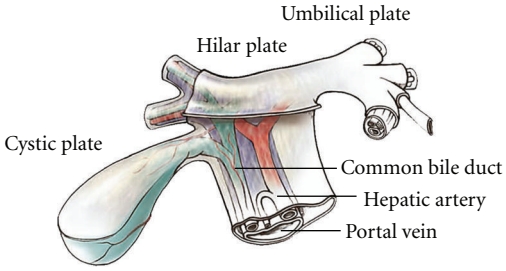

(b)

Figure 7: The view of the hilar plate after complete eradication of the infiltrating tumor. The right portal pedicle is tapped by blue tape. The oozing blood from the liver surface is controlled by ABC. Dissection of mucinous tumor from the hilar plate after taping the right portal pedicle branches. This excision only involves surgical removal of Glisson's capsule bearing tumor and approximately 1-2 cm in depth of hepatic parenchyma.

necessity of the gastrectomy from the arterial supply for the residual stomach, the areas of invasion, and residual part of the stomach. Importantly, the small bowel should be intact for the safe reconstruction either by esophagojejunostomy or gastrojejunostomy.

2.4.5. Perihepatic Peritonectomy. In PC from PMP and mucinous ovarian tumors, hepatoduodenal ligament and liver hilar plate are frequently involved (Figures 6 and 7). The plate system is formed at the level of the liver hilum by coalescence and thickening of Glisson's capsule and vasculobiliary sheaths. This plate system is divided into three parts of connective thickening: the hilar plate that separates the biliary confluence from the inferior part of the quadrate lobe (S4b), the cystic plate that envelops the gallbladder and cystic duct, and the umbilical plate that covers the umbilical portion of the portal vein (Figure 7).

Figure 6 shows the enhanced CT scan showing the tumor located in the hilar, cystic, and umbilical plates and the tumor extended in Glisson's capsule.

The only efficient procedure for hilar metastases is excision, which is followed by complementary treatment. Surgery should start with the dissection of the hepatoduodenal ligament, to identify the limits of the tumor, its mobility, or infiltration of adjacent planes and elements, confirming the existence or absence of infiltration of vascular elements and, in particular, of the portal vein or its branches. Dissection of the hepatic pedicle usually begins with isolation of the artery followed by the biliary tract and portal vein. Aqua dissection enables to identify the second branches of the portal triads (Figure 7). The gall bladder is removed. Lesser omentum is excised routinely. The attachment of the lesser omentum to the caudate lobe and ligamentum venosum is excised and the omental bursa is exposed. The left gastric artery and vein are identified and taped. The lesser omentum is taken all the way from the lesser curvature to the caudate lobe and ligamentum venosum by preserving the left and right gastric vessels.

As shown in Figure 8, axial contrast-enhanced CT scan of the upper abdomen demonstrates multiple low attenuated cystic lesions with rim-like calcifications scalloping the liver margin, infiltrating the spleen, and compressing the bowel, pancreas, and left kidney. To remove such lesions, liver capsule near the lesions is cut with electrocautery, and the space between the capsule of the scalloping lesion and liver parenchyma is dissected with scalpel by making a countertraction of tumors. Figure 9 shows the operative view and resected specimen after enucleating of a large cystic lesion indents the liver deeply.

Peritoneum of the superior omental recess (region 4 in Figure 5), which occupies the caudate lobe, diaphragmatic crus, and anterior wall of vena cava, is removed.

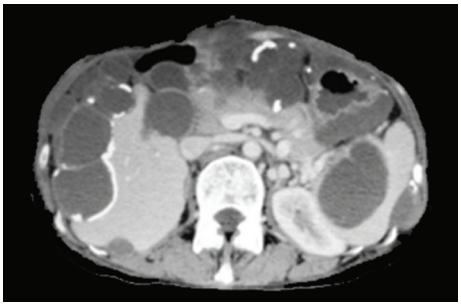

Figure 8: Axial contrast-enhanced CT scan of the upper abdomen demonstrates multiple low attenuated cystic lesions with rim-like calcifications scalloping the liver margin, infiltrating the spleen, and compressing the bowel, pancreas, and left kidney.

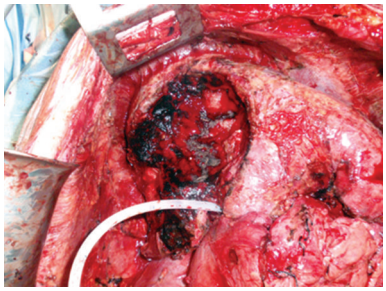

(a)

(b)

Figure 9: The operative view after enucleating of a large cystic lesion indenting the liver deeply. The resected specimen of the lesion described in Figure 8.

Figure 10 shows the tumors in the superior omental recess. By traction of tumors to left side, the capsule of caudate lobe is cut and the tumors with liver capsule and retroperitoneum are peeled off from the caudate lobe, left crural muscle, and vena cava.

Morrison's pouch and the paracolic gutter are the common sites of tumor implantation. The peritoneum covering Morrison's pouch is removed with the peritoneum on the right paracolic gutter, right subdiaphragm, and right abdominal wall (Figures 11 and 12).

Large tumors attach on the ascending colon and hepatic flexure, and tumors on the paracolic gutter and Morrison's pouch are removed in combination with extended right hemicolectomy.

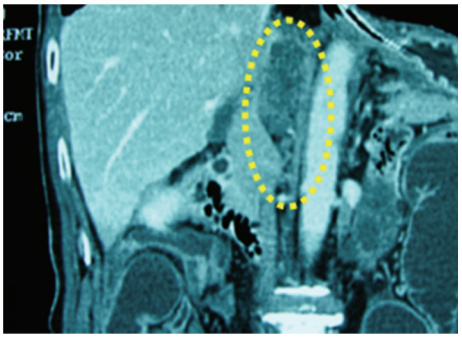

Figure 10: Coronal enhanced CT scan shows tumor located between the inferior vena cava, caudate lobe, and left crus of diaphragm.

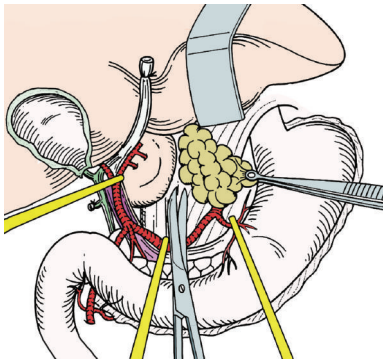

(a)

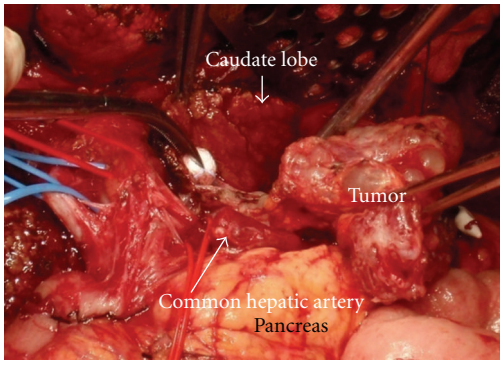

(b)

Figure 11: Dissection of the tumor in the superior omental recessus. By traction of tumors to the left side, the capsule of the caudate lobe is cut and the tumors with liver capsule and retroperitoneum are dissected from the caudate lobe, left crural muscle, and vena cave.

2.4.6. Pelvic Peritonectomy. The entire pelvic peritoneum is dissected from the anterior inferior abdominal wall, urinary bladder, and retroperitoneum. The peritoneum covering the urinary bladder is dissected, and the rectovesical pouch is completely freed from the urinary bladder and rectum. In males, the space between the seminal vesicle and peritoneum of rectovesical pouch is dissected, lifting the vas deferens off. In females, blood vessels around the uterus are dissected and cut with Ligasure (Valleylab Inc., Boulder, CO, USA).

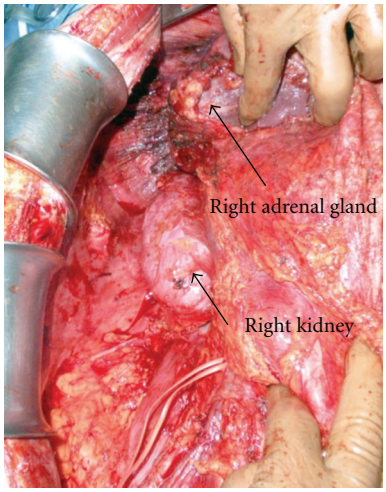

(a)

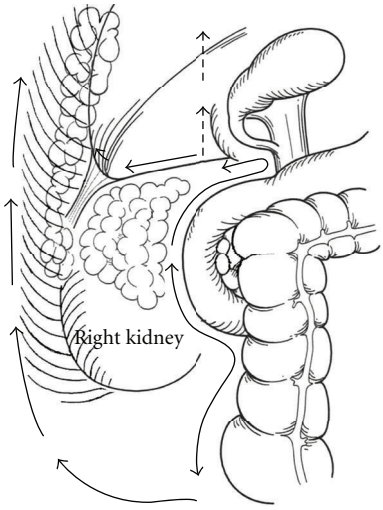

(b)

Figure 12: Dissection line of Morrison's pouch. The peritoneum covering Morrisons's pouch is removed with the peritoneum on the right paracolic gutter, right subdiaphragm, and right abdominal wall.

Amputation of the vagina is done at a plane 1 cm below the peritoneal reflection of the Douglass pouch to ensure removal of all tumors occupying the cul-de-sac.

If the tumor invades the anterior rectal wall, the rectum is cut at 1 cm below the peritoneal reflection. Reasonable length of the rectum should be preserved for the anastomosis with the colon or ileum.

2.4.7. Peritonectomy of Small Bowel. The entire small bowel and its mesentery are traced from the duodenojejunal flexure to the ileocecal junction. There are often tumor nodules at paraduodenal recesses covering the ligament of Treitz, and these are easily dissected by the *aqua dissection* technique and resected as well as any other tumor along the way. Then, both sides of the mesentery are inspected and palpated and the tumor nodules excised with electrosurgery.

Complete cytoreduction is aimed by removing all macroscopic tumors by peritonectomy combined with laser or electric fulguration and HIPEC for microscopic PC.

2.4.8. Assessment of Completeness of Cytoreduction. The aim of CRS was to obtain complete macroscopic cytoreduction as a precondition for the application of HIPEC. The residual disease was classified intraoperatively using the completeness of cytoreduction (CC) score [9]. CC-0 indicates no visible residual tumor, CC-1 indicates residual tumor nodules ≤2.5 mm, CC-2 indicates residual tumor nodules between 2.5 mm and 25 mm, and CC-3 indicates residual tumor nodules >25 mm or a confluence of unresectable tumor nodules at any site within the abdomen and the pelvis. CC-2 and CC-3 cytoreductions are regarded incomplete.

2.5. Statistical Analyses. All patients were followed up and no patients were lost to follow up. Outcome data were obtained from medical records and patients' interviews. All statistical analyses were performed using the SPSS software statistical computer package version 17 (SPSS Inc., Chicago, USA).

3. Results

3.1. Completeness of Cytoreduction. CC-0,-1 resections were done in 62/81 (76.5%), 228/420 (54.3%), and 101/166 (60.8%) of patients with colorectal cancer, appendiceal neoplasm, and gastric cancer (Table 1). CC-0,-1 resections of colorectal and appendiceal neoplasm patients with PCI ≤ 20 were performed in 89.4% (59/66) and 86.2% (168/195), but that in gastric cancer patients was done only in 67.6% (100/148). In contrast, 5.6% of gastric cancer patients with PCI ≥ 20 underwent CC-0,-1 resections (1/18), but CC-0,-1 resections in colorectal and appendiceal neoplasm patients were performed in 20.0% (3/15) and 26.6% (60/165), respectively. One gastric cancer patient underwent CC-0 resection for PCI score of 32 which was mucinous adenocarcinoma.

The reasons of CC-2,-3 resections are listed in Table 2. The most frequent reasons were involvement of all peritoneal regions ($N = 89$) and diffuse involvement of small bowel serosa or mesentery ($N = 113$). In appendiceal neoplasms, massive bleeding more than 5 L was the reason to stop operation ($N = 10$). Old age ($N = 6$) and comorbidities ($N = 4$) are also the reasons of CC-2,-3 resections. In appendiceal neoplasms, 6 patients with massive scalloping to the liver hilum or parenchyma showed the reason of CC-2,-3 resections. In gastric cancers, local invasion to the surrounding organs from the primary tumor, positive surgical margin at the esophageal or duodenal stump, and distant lymph node metastasis were found in 6, 3, and 3 patients.

Regarding the correlation between PCI scores of small bowel (SB-PCI) and CC scores in colorectal cancer patients, CC-0,-1 resection was done in 36 of 38 (95%) patients with SB-PCI ≤ 3, but only in 12 of 24 (50%) patients with SBPCI ≥ 4.

Table 1: Correlation of CC scores and PCI scores.

	PCI ≤ 10	11 ≤ PCI ≤ 20	21 ≤ PCI ≤ 30	PCI ≥ 31	Total
colorectal cancer					
CC-0,-1	43 (95.5%)	16 (76.2%)	3 (30.0%)	0 (0.0%)	62 (76.5%)
CC-2,-3	2	5	7	5	19
Appendiceal neoplasm					
CC-0,-1	111 (97.4%)	57 (0.3%)	39 (36.4%)	21 (17.8%)	228 (54.3%)
CC-2,-3	3	24	68	97	192
Gastric cancer					
CC-0,-1	95 (79.2%)	5 (21.7%)	0 (0.0%)	1 (25.0%)	101 (60.8%)
CC-2,-3	25	23	14	3	66

Table 2: The causes of CC-2,-3 resections.

	Colorectal cancer	Appendiceal neoplasm	Gastric cancer
Involvement of all peritoneal regions	7	71 (22 + old age)	11
Diffuse small bowel involvement	5 (2 + LB[#], 1 + PH[$])	86 (15 + LB, 3 + PH,1 + ST[&])	22 (1 + LG)
Bleeding	0	10	0
Old age	1	5	0
Comorbidity	0	4	0
Positive histologic margin	0	0	6
Local invasion	0	2	3
Lymph node metastasis	0	0	3
Perihepatic involvement	0	6	0
Emergency	1	2	0
others	1	4	1

[#]LB: large bowel involvement, [$]PH: perihepatic involvement, and [&]ST: stomach involvement.

In gastric cancer patients, 65 of 78 (83%) of patients with SB-PCI ≤ 3 and 43/83 (52%) of those with SBPCI ≥ 4 underwent CC-0,-1 resections.

In PMP patients, CC-0,-1 resection rate was significantly higher in patients with SB-PCI ≤ 6 (209/265, 79%) than that in those with SB-PCI ≥ 7 (19/155, 12%).

Before December, 2007 (first 3 years), CC-0,-1 resection was done in 82 (42%) of 197 patients. After January, 2008 (next 3 years), when the aqua dissection method was introduced, it was done in 302 (64.3%) of 470 patients, and there was a significant difference ($P < 0.001$). In the first 3 years, complete cytoreduction was done in 14% (11/67) of patients with PCI ≥ 29, but was done in 23.6% (29/122) in the last 3 years.

3.2. Postoperative Mortality and Morbidity. A total of 41 (6.1%) among 667 patients died postoperatively. Mortality rate (3.6%, 14/391) after CC-0,-1 resections was significantly lower than that (8.7%, 24/276) after CC-1,-2 resections (Table 3). Causes of deaths were septic shock ($N = 14$), fistula and peritonitis ($N = 12$), multiple organ failure ($N = 4$), tumor progression ($N = 4$), lung embolism ($N = 2$), cardiac arrhythmia ($N = 2$), bleeding from duodenal ulcer ($N = 1$), and massive abdominal bleeding ($N = 1$). There was no difference between the complication rates and disease categories.

Major complication (grade 3-4 complications) occurred in 126 patients (18.9%). A reoperation was necessary in 36 patients (5.4%). The experienced complications were abdominal abscess ($N = 45$), bowel fistula ($N = 19$), anastomosis or stump leakage ($N = 18$), ileus ($N = 9$), leakage from urinary bladder ($N = 8$), perforation of stomach ($N = 6$), abdominal bleeding ($N = 5$), bile leak ($N = 3$), perforation of diaphragm ($N = 3$), respiratory failure ($N = 3$), renal failure ($N = 1$), arrhythmia ($N = 1$), bleeding from duodenal ulcer ($N = 1$), and others ($N = 4$).

3.3. Survival after CRS. The overall 1-year, 3-year, and 5-year survival rates and median survivals of the three groups are shown in Table 4. Univariate analysis showed that the lymph node status, tumor differentiation, gender, and performance status did not have prognostic impact on survival. The 5-year survival rates after CC-0,-1 resection for colorectal cancer, appendiceal neoplasm, and gastric cancer patients were 28%, 84%, and 17%, respectively. In contrast, those in CC-2,-3 groups were 0%, 50%, and 2% respectively.

The 5-year survival rate of colorectal cancer patients with PCI score ≤ 10 was significantly better than that with PCI score ≥ 11 ($P < 0.001$). In appendiceal cancer, patients with

Table 3: Postoperative mortality and morbidity after cytoreductive surgery.

	No complication	Grades 1-2	Grade 3	Reoperation	Hospital deaths
Colorectal cancer					
CC-0,-1	35 (56.5%)	19 (30.1%)	3 (4.8%)	3 (4.8%)	2 (3.2%)
CC-2,-3	10 (52.6%)	3 (15.8%)	4 (21.0%)	0	2 (10.6%)
Appendiceal neoplasm					
CC-0,-1	128 (56.1%)	44 (19.3%)	32 (14.0%)	19 (8.3%)	5 (2.2%)
CC-2,-3	98 (51.0%)	26 (13.5%)	38 (19.8%)	10 (5.2%)	20 (10.4%)
Gastric cancer					
CC-0,-1	76 (75.2%)	8 (7.9%)	9 (8.9%)	2 (2.0%)	7 (6.9%)
CC-2,-3	45 (68%)	10 (15.2%)	4 (6.1%)	2 (3.0%)	5 (7.6%)

PCI score ≤ 28 survived significantly better than those with PCI score ≥ 29 ($P < 0.001$). Five-year survival rate of gastric cancer patients with PCI score ≤ 6 was significantly better than that of patients with PCI score ≥ 7 (Table 4).

By the multivariate analysis, PCI scores were capable of serving as thresholds for favorable versus poor prognosis in each group and CC scores demonstrated as the significant independent prognostic factors after CRS. In colorectal cancer patients, CC score (CC-0,1 versus CC-2,-3) and PCI score (PCI ≤ 10 versus PCI ≥ 11) emerged as the independent prognostic factors ($P = 0.031$, $P = 0.0016$). RR of patients with CC-2,3 versus CC-0,-1 was 4.63, and that of patients with PCI ≥ 11 versus those with PCI ≤ 10 was 9.98. In gastric cancer patients, CC score (CC-0,-1 versus CC-2,3) was an only independent prognostic factor ($P < 0.05$, $X2 = 68.47$, RR = 26.5).

4. Discussion

Current surgical management of the PC can be performed with curative intent and potential long-term survival when a strategy of CRS combined with HIPEC is used to select patients.

Adequate patient selection and the improvement of surgical skills of surgeons are crucial to obtain a complete macroscopic cytoreduction, which is a leading predictor of patient outcome. Adequate patient selection is sometimes difficult for surgeons with experience of small number of cases with PC. Many criteria have to be assessed in each patient: performance status, response to chemotherapies, existence of lymph node and/or hematogenous metastasis, histologic grading, PCI, and comorbidities. Patients with poor performance status, severe comorbidities, and PC already spread to the entire peritoneal cavity are not indicated for complete cytoreduction. In gastric cancer, response after neoadjuvant chemotherapy is one of the selection criteria for CRS [5].

In the surgical treatment of patients with PC from colorectal cancer, appendiceal neoplasm, and gastric cancer, complete cytoreduction is believed as an essential factor for a good prognosis. In the present data, CC-0,-1 and the PCI scores of less than the threshold values for each disease clearly were demonstrated as independent prognostic factors after CRS plus perioperative chemotherapy. Peritonectomy techniques improved the incidence of complete cytoreduction, as compared with the ordinary surgical techniques [6, 9–12]. However, patients often with advanced metastases and a limited life span undergo a comprehensive therapy of multivisceral resection with several intestinal anastomosis and HIPEC. Surgeons are required to safely perform complete macroscopic tumor resection extended across several surgical disciplines, including general surgery, hepatobiliary surgery, urology, and gynecology. The incidences of complete cytoreduction for colorectal cancer, appendiceal neoplasm and gastric cancer in the present paper were 76.5%, 54.3% and 60.8%, respectively. The values appeared reasonable as compared with the results of other big centers [1, 4, 11, 13]. The incidences of complete cytoreduction for colorectal cancer, appendiceal neoplasm, and gastric cancer were reported as 49% ~ 54% (50/102, 271/506) [1, 11], 73.6% (577/783) [4], and 53% (85/159) [13], respectively. The incidences of complete cytoreduction are mainly depending on the surgeons' experiences. A learning curve had been already reported by several authors [12, 14, 15]. Moran et al. reported a decreased mortality rate from 18 to 3% [12] and the Netherlands Cancer Center from 8 to 4% [15]. The present results also demonstrated the the importance of the learning curve and the introduction of new technique of aqua dissection method. The deep invasion or scalloping into the liver hilum and superior omental recess and diffuse small bowel involvement are the limiting factors to achieve complete cytoreduction.

We developed an aqua dissection technique to guide surgeons to perform a safe tumor dissection through the correct dissection plane, to avoid injury of the important vessels, and to reduce the blood loss. Using this technique, the dissection around the hepatic hilar plate and lateral dissection of the pelvic spaces can be done in a safer and easier manner.

Diffuse small bowel involvement is the most frequent cause of incomplete cytoreduction. Tumor nodules from colorectal and gastric cancer often invade the mesentery where the blood vessels enter the small bowel and this can be especially problematic to resect the tumor nodules without full-thickness injury to the bowel. Once the small

Table 4: Survival after CRS in terms of CC score and PCI score.

	Median survivals months	1-year survival (%)	3-year survival (%)	5-year survival (%)	Log-rank test (P) $X2$
Colorectal cancer					
CC-0,-1 ($N = 62$)	38.4	93	51	28	$P = 0.003$
CC-2,-3 ($N = 19$)	19.2	33	16	0	$X2 = 8.53$
PCI ≤ 10 ($N = 45$)	NR	95	59	59	$P < 0.001$
PCI ≥ 11($N = 36$)	18.2	83	37	0	$X2 = 12.90$
Appendiceal neoplasm					
CC-0,-1 ($N = 228$)	NR	99	93	84	$P < 0.001$
CC-2,-3 ($N = 192$)	NR	91	69	50	$X2 = 41.48$
PCI ≤ 28 ($N = 257$)	NR	99	89	76	$P < 0.001$
PCI ≥ 29 ($N = 163$)	49.2	87	63	55	$X2 = 38.81$
Gastric cancer					
CC-0,-1 ($N = 101$)	21.5	70	26	17	$P < 0.001$
CC-2,-3 ($N = 65$)	13.6	59	8	2	$X2 = 14.90$
PCI ≤ 6 ($N = 111$)	21.5	76	23	14	$P < 0.001$
PCI ≥ 7 ($N = 55$)	13.6	57	21	3	$X2 = 10.48$

bowel is inspected completely, a decision is made to perform resections while leaving adequate bowel length for normal nutritional function and minimizing the number of anastomoses. In colorectal and gastric cancer, the present data demonstrated that the complete cytoreduction rate in patients with SB-PCI ≤ 3 was significantly higher (85.6%, 15/118) than that in patients with SB-PCI ≤ 4 (32.3%, 20/42). In appendiceal neoplasm patients, CC-0,-1 resection rate was significantly higher in patients with SB-PCI ≤ 6 (209/265, 79%) than that in those with SB-PCI ≥ 7 (19/155, 12%). Accordingly, the SB-PCI thresholds for the complete cytoreduction were ≥ 3 for colorectal and gastric cancer and ≥ 6 for appendiceal neoplasm. Esquivel et al. reported that there is no surgical option to remove all affected sites of small bowel even if there is evidence of intestinal obstruction at more than one site [16]. In colorectal and gastric cancer, an extended removal of the small bowel will cause not only a short bowel syndrome but also a recurrence within short time. Accordingly, the indication for the extensive bowel resection in colorectal and gastric cancer is limited. On the contrary, Bao and Bartlett reported that 200 cm of small bowel should be maintained in appendiceal neoplasm. These results indicate that the extended resection of small bowel is indicated for the PC from the tumors with a less aggressive biological behavior, like appendiceal neoplasms.

PCI score demonstrated its significant influence on survival, and a PCI score capable of serving as a threshold for favorable versus poor prognosis has been reported. In colorectal cancer, the survival results were significantly better when the PCI was lower than 16 [17, 18]. Sugarbaker also reported a 5-year survival rate of 50% when the PCI was less than 10, a rate of 20% for an index of 11–20, and a rate of 0% for an index >20 [6]. In gastric cancer, Glehen et al. reported that no patients were alive even after complete cytoreduction when the PCI was more than 12. Accordingly, PCI of more than 12 should be contraindicated for CRS and HIPEC [13]. The present study demonstrated that the survival of gastric cancer patients with a PCI ≤ 6 was significantly better than those with a PCI ≥ 7. In contrast, in appendiceal neoplasm, patients with PCI score ≤ 28 showed significant better survival than those with PCI score ≥ 29. Sugarbaker reported that the PCI threshold for appendiceal neoplasm was 20 [4]. Gastric cancer and colorectal cancer have a more aggressive biological behavior than appendiceal neoplasm, and patients with PCI larger than the threshold values should be treated with palliative intent of CRS combined with systemic chemotherapy.

Recently, neoadjuvant intraperitoneal/systemic chemotherapy improves survival results in gastric cancer. Patients who progress or develop extra-abdominal metastases during neoadjuvant chemotherapy may be excluded from an aggressive CRS [5]. In addition, intraperitoneal chemotherapy for gastric cancer is effective to eradicate peritoneal-free cancer cells and small PC nodules [5]. After IP chemotherapy, complete disappearance of cancer cells of PC was observed in 50% of 30 patients with gastric cancer, and also stage migration from stage 4 to stage 1, 2, or 3 was experienced in 33% of patients [5]. These results may indicate that the neoadjuvant chemotherapy can increase the incidence of complete cytoreduction by eradicating PC nodules before surgery. In particular, patients with small bowel involvement should be treated with this strategy before CRS and HIPEC.

Conflict of Interests

The authors have no financial interest related to the contents of this paper to disclose.

References

[1] V. J. Verwaal, S. van Ruth, E. de Bree et al., "Randomized trial of cytoreduction and hyperthermic intraperitoneal chemotherapy versus systemic chemotherapy and palliative surgery in patients with peritoneal carcinomatosis of colorectal cancer," *Journal of Clinical Oncology*, vol. 21, no. 20, pp. 3737–3743, 2003.

[2] V. J. Verwaal, S. Bruin, H. Boot, G. van Slooten, and H. van Tinteren, "8-Year follow-up of randomized trial: cytoreduction and hyperthermic intraperitoneal chemotherapy versus systemic chemotherapy in patients with peritoneal carcinomatosis of colorectal cancer," *Annals of Surgical Oncology*, vol. 15, no. 9, pp. 2426–2432, 2008.

[3] T. D. Yan and D. L. Morris, "Cytoreductive surgery and perioperative intraperitoneal chemotherapy for isolated colorectal peritoneal carcinomatosis: experimental therapy or standard of care?" *Annals of Surgery*, vol. 248, no. 5, pp. 829–835, 2008.

[4] P. H. Sugarbaker, "Epithelial appendiceal neoplasms," *Cancer Journal*, vol. 15, no. 3, pp. 225–235, 2009.

[5] Y. Yonemura, Y. Endou, M. Shinbo et al., "Safety and efficacy of bidirectional chemotherapy for treatment of patients with peritoneal dissemination from gastric cancer: selection for cytoreductive surgery," *Journal of Surgical Oncology*, vol. 100, no. 4, pp. 311–316, 2009.

[6] T. A. Sugarbaker, D. Chang, P. Koslowe, and P. H. Sugarbaker, "Patterns of spread of recurrent intraabdominal sarcoma.," *Cancer Treatment and Research*, vol. 82, pp. 65–77, 1996.

[7] P. Piso, P. Slowik, F. Popp, M. H. Dahlke, G. Glockzin, and H. J. Schlitt, "Safety of gastric resections during cytoreductive surgery and hyperthermic intraperitoneal chemotherapy for peritoneal carcinomatosis," *Annals of Surgical Oncology*, vol. 16, no. 8, pp. 2188–2194, 2009.

[8] P. H. Sugarbaker, "Peritonectomy procedures," *Annals of Surgery*, vol. 221, no. 1, pp. 29–42, 1995.

[9] P. Jacquet and P. H. Sugarbaker, "Clinical research methodologies in diagnosis and staging of patients with peritoneal carcinomatosis," *Cancer Treatment and Research*, vol. 82, pp. 359–374, 1996.

[10] P. H. Sugarbaker, "Successful management of microscopic residual disease in large bowel cancer," *Cancer Chemotherapy and Pharmacology*, vol. 43, pp. S15–S25, 1999.

[11] O. Glehen, F. Kwiatkowski, P. H. Sugarbaker et al., "Cytoreductive surgery combined with perioperative intraperitoneal chemotherapy for the management of peritoneal carcinomatosis from colorectal cancer: a multi-institutional study," *Journal of Clinical Oncology*, vol. 22, no. 16, pp. 3284–3292, 2004.

[12] B. J. Moran, "Decision-making and technical factors account for the learning curve in complex surgery," *Journal of Public Health*, vol. 28, no. 4, pp. 375–378, 2006.

[13] O. Glehen, F. N. Gilly, C. Arvieux et al., "Peritoneal carcinomatosis from gastric cancer: a multi-institutional study of 159 patients treated by cytoreductive surgery combined with perioperative intraperitoneal chemotherapy," *Annals of Surgical Oncology*, vol. 17, no. 9, pp. 2370–2377, 2010.

[14] T. D. Yan, M. Links, S. Fransi et al., "Learning curve for cytoreductive surgery and perioperative intraperitoneal chemotherapy for peritoneal surface malignancy—a journey to becoming a Nationally Funded Peritonectomy Center," *Annals of Surgical Oncology*, vol. 14, no. 8, pp. 2270–2280, 2007.

[15] R. M. Smeenk, V. J. Verwaal, and F. A. N. Zoetmulder, "Learning curve of combined modality treatment in peritoneal surface disease," *British Journal of Surgery*, vol. 94, no. 11, pp. 1408–1414, 2007.

[16] J. Esquivel, D. Elias, D. Baratti, S. Kusamura, and M. Deraco, "Consensus statement on the loco regional treatment of colorectal cancer with peritoneal dissemination," *Journal of Surgical Oncology*, vol. 98, no. 4, pp. 263–267, 2008.

[17] D. Elias, F. Blot, O. A. A. El Otmany et al., "Curative treatment of peritoneal carcinomatosis arising from colorectal cancer by complete resection and intraperitoneal chemotherapy," *Cancer*, vol. 92, no. 1, pp. 71–76, 2001.

[18] J. L. Koh, T. D. Yan, D. Glenn, and D. L. Morris, "Evaluation of preoperative computed tomography in estimating peritoneal cancer index in colorectal peritoneal carcinomatosis," *Annals of Surgical Oncology*, vol. 16, no. 2, pp. 327–333, 2009.

Hindawi Publishing Corporation
Gastroenterology Research and Practice
Volume 2012, Article ID 623417, 7 pages
doi:10.1155/2012/623417

Research Article

Hyperthermic Intraoperative Thoracoabdominal Chemotherapy

Paul H. Sugarbaker,[1] David Chang,[2] and O. Anthony Stuart[1]

[1] *Washington Hospital Center, Washington Cancer Institute, 106 Irving Street, NW, Suite 3900, Washington, DC 20010, USA*
[2] *Westat, 1600 Research Boulevard, Rockville, MD 20850-3129, USA*

Correspondence should be addressed to Paul H. Sugarbaker, paul.sugarbaker@medstar.net

Received 6 February 2012; Accepted 1 March 2012

Academic Editor: Pompiliu Piso

Cytoreductive surgery combined with hyperthermic intraperitoneal chemotherapy (HIPEC) is a treatment option for selected patients with pseudomyxoma peritonei (PMP) and diffuse malignant peritoneal mesothelioma (DMPM). Tumor infiltration of the hemidiaphragm requiring partial resection occurs as a result of large volume and/or invasive disease at this anatomic site. Transmission of disease from abdomen to chest is a great danger in this group of patients. From a prospective database, patients who had diaphragm resection and then hyperthermic thoracoabdominal chemotherapy (HITAC) as a component of a cytoreductive surgical procedure were identified. Data from control patients receiving HIPEC or hyperthermic intrathoracic chemotherapy (HITOC) were analyzed for comparison. The morbidity, mortality, survival, and recurrence rate within the thoracic space were presented. Thirty patients had partial resection of a hemidiaphragm as part of a cytoreductive surgical procedure that utilized HITAC. The pharmacologic benefit of intracavitary chemotherapy administration was documented with an area under the curve ratio of intracavitary concentration times time to plasma concentration times time of 27 ± 10 for mitomycin C and 75 ± 26 for doxorubicin. Comparing percent chemotherapy absorbed for a ninety-minute treatment showed the largest for HIPEC, then for HITAC, and lowest for HITOC. The incidence of grade 3 and 4 adverse events was 43%. There was no mortality. Adjustments in the chemotherapy dose are not necessary with HITAC. The morbidity was high, the survival was acceptable, and intrathoracic recurrence was low.

1. Introduction

Increasing interest in the surgical management of peritoneal metastases from gastrointestinal cancer is evident from the many recent publications on this subject [1–5]. Improvements in surgical technology by using cytoreductive surgery with peritonectomy are a necessary part of these new management strategies [6]. Also, perioperative chemotherapy, especially hyperthermic intraperitoneal chemotherapy, has routinely been added to the surgical intervention [7]. Gastrointestinal cancer with peritoneal metastases may accumulate in large volume on the undersurfaces of the hemidiaphragms. Invasion of the hemidiaphragm, especially its tendinous midportion, may be required in order to achieve optimal cytoreduction. The perioperative chemotherapy and clinical management strategy for patients whose cytoreduction required partial excision of a hemidiaphragm are the subject of this paper.

2. Materials and Methods

Permission to accumulate and analyze these data was obtained from the ethics committee of our institution. From a prospective database of patients with appendiceal mucinous neoplasms with peritoneal metastases, colon cancer patients with peritoneal metastases, gastric cancer with peritoneal metastases, and peritoneal mesothelioma patients; we identified those in whom a diaphragm resection was required at the time of cytoreductive surgery. The clinical features of these patients including their diagnosis, age, gender, and diaphragm resected (right versus left versus both right and left) were tabulated.

All of these patients had an attempt at complete removal of their peritoneal surface malignancy prior to the initiation of the hyperthermic intraoperative chemotherapy [8]. In all of these patients disease infiltration of the diaphragm required resection of a portion of the diaphragm in order to

try and achieve the goal of complete cytoreduction. If even a small transection of the hemidiaphragm occurred, the entire central tendinous portion of the diaphragm was resected. The pleural space was visualized as possible through the opening in the hemidiaphragm. If cancer nodules within the thoracic space were visualized, one or several were biopsied. An attempt at pleurectomy was not added to the treatment strategy. This was to allow the free flow of hyperthermic intraoperative chemotherapy into the thoracic cavity from the abdominal cavity. To deliver the chemotherapy there was a single inflow catheter that was periodically moved around the abdominal space. There were three closed suction drains within the abdomen and a thoracostomy tube within the chest. The chest tube was 28 French diameter and many times larger than the intraabdominal drainage tubes thereby favoring heated chemotherapy flow from abdomen, through the diaphragm, and into the thoracic cavity.

During the chemotherapy treatment specimens from blood and the thoracoabdominal fluid were obtained at 15-minute intervals for 60 minutes and then a single sample at 90 minutes. These samples were centrifuged to remove debris or red blood cells. The cell-free solutions were frozen and stored for high-performance liquid chromatography (HPLC) analysis which was performed within 1 week.

The dose of chemotherapy was 15 mg/m^2 for mitomycin C and 15 mg/m^2 for doxorubicin. The volume of chemotherapy solution was always 1.5 liters/m^2 of body surface. This was a volume of chemotherapy solution that would fill the peritoneal space and the thoracic space at the initiation of the combined thoracoabdominal chemotherapy lavage.

Following the hyperthermic thoracoabdominal chemotherapy treatments, all chemotherapy fluid was removed from the abdomen and pelvis. The volume of chemotherapy solution was carefully measured so that the total milligrams of chemotherapy that left the thoracoabdominal space into the body compartment could be calculated.

Following the chemotherapy treatments, the diaphragm was closed in a routine fashion with interrupted and continuous sutures. Thereafter, reconstruction of the gastrointestinal tract and closure of the abdomen occurred.

Pharmacokinetic studies of mitomycin C and doxorubicin were performed on peritoneal fluid and plasma in order to determine the relative exposure (area under the curve ratio) of chemotherapy in the peritoneal and pleural fluid versus chemotherapy in the plasma. The drug concentrations in these fluids were determined by HPLC assay as previously described [9, 10]. Also, 25 patients in whom the regional chemotherapy was confined to the peritoneal cavity (HIPEC) matched for age, diagnosis, and extent of disease (except for diaphragm resection) who had mitomycin C and doxorubicin pharmacokinetics determined were used as a comparison for data from patients who had both thoracic and abdominal chemotherapy lavage (HITAC). In a third group of patients, the hyperthermic chemotherapy treatment was limited to the thoracic cavity after pleurectomy and decortication (HITOC). The percent of the chemotherapy absorbed in these three groups of patients was compared.

Table 1: Clinical and demographic information on patients having hyperthermic intraoperative thoracoabdominal chemotherapy (HITAC), patients having hyperthermic perioperative chemotherapy (HIPEC), and patients having hyperthermic intrathoracic chemotherapy (HITOC).

DEMOGRAPHICS	HITAC	HIPEC	HITOC
Total patients	30	25	5
Male	14	10	1
Female	16	15	4
Diagnosis			
Appendix	16	23	4
Colon	5	2	
Peritoneal mesothelioma	8		1
Gastric	1		
Right	23	Not applicable	3
Left	6	Not applicable	2
Right and left	1	Not applicable	0
Complete cytoreduction			
CC-0/CC-1	18	21	5
Incomplete cytoreduction			
CC-2/CC-3	12	4	0
Median age	50	48	50
Range	33–68	33–67	43–58

2.1. Statistics. A Student's *t*-test (Microsoft Excel 2007) was used to compare the percent of total intracavitary chemotherapy absorbed over 90 minutes from the thoracoabdominal space versus the thoracic space. Survival analyses were prepared using the Kaplan-Meier method.

A postoperative prospective morbidity/mortality database was maintained on these patients. There were 8 categories of events and 47 items scored in the eight categories as previously described [11]. Also, followup on these patients in terms of long-term survival and recurrence of disease within the hemithorax was determined.

3. Results

There were a total of 30 patients with peritoneal metastases between January 2000 and September 2011 whose cytoreductive surgery required a diaphragm excision. Sixteen patients had appendiceal mucinous neoplasm, 5 colon cancer, 8 peritoneal mesothelioma, and 1 gastric cancer. The median age of these patients was 50 with a range of 33 to 68 years. There were 16 female patients and 14 male patients. The right pleural space was entered in 23 patients, the left pleural space was entered in 6 patients, and both right and left hemidiaphragms partially resection in a single patient. At the close of the cytoreductive surgery, a CC-0/CC-1 (complete) cytoreduction was recorded in 18 patients and a CC-2/CC-3 (incomplete) cytoreduction in 12 (Table 1). In 6 patients the cytoreduction was scored as incomplete because of residual disease within the thorax.

In the 25 control patients with hyperthermic chemotherapy limited to the peritoneal space, 23 had a diagnosis of appendiceal mucinous neoplasm, and two a diagnosis of

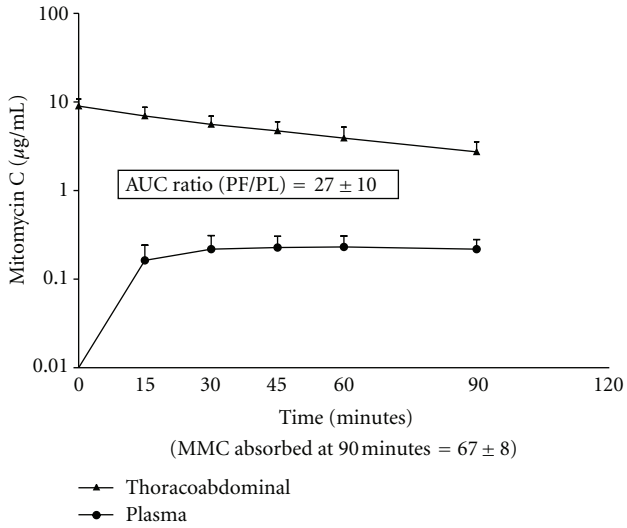

Figure 1: Pharmacokinetics of mitomycin C in 12 patients with simultaneous intraabdominal and intrathoracic chemotherapy used in conjunction with cytoreductive surgery.

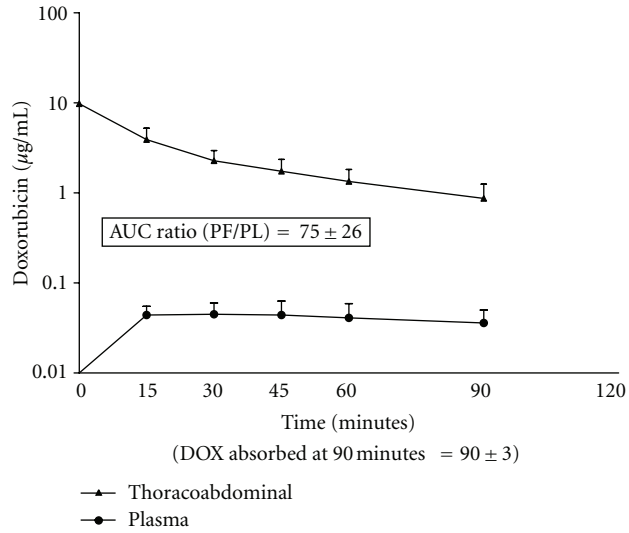

Figure 2: Pharmacokinetics of doxorubicin in 12 patients with simultaneous intraabdominal and intrathoracic chemotherapy administration in conjunction with cytoreductive surgery.

colon cancer. In the three patients who received intrathoracic mitomycin C, all had an appendiceal mucinous neoplasm. In the four patients who received intrathoracic doxorubicin, three had appendiceal mucinous neoplasm and one had peritoneal mesothelioma (Table 1).

3.1. Pharmacokinetics of Hyperthermic Chemotherapy in Thoracic and Abdominal Cavity (HITAC). In 12 patients complete pharmacokinetic data was available so that the mitomycin C concentrations in fluid from the thoracic and abdominal space could be determined along with plasma concentrations of this drug. Figure 1 shows the area under the curve for thoracoabdominal mitomycin C as compared to the area under curve for plasma mitomycin C. The area under the curve ratio was 27 ± 10. Nine of these patients had appendiceal neoplasms, 2 colon cancer, and 1 peritoneal mesothelioma.

Similar data was obtained from the same 12 patients who received intrathoracic and abdominal doxorubicin. The area under the curve for thoracoabdominal fluid as compared to the area under the curve for plasma is shown in Figure 2. The area under the curve ratio was 75 ± 26.

3.2. Comparison of Thoracic and Abdominal Chemotherapy Treatment (HITAC) to a Chemotherapy Lavage Limited to the Abdominal Space (HIPEC) and to a Chemotherapy Lavage Limited to the Thoracic Space (HITOC). In 25 control patients in whom hyperthermic intraoperative chemotherapy treatment was limited to the abdominal and pelvic space (HIPEC), the percent of drug absorbed from the peritoneal cavity over the 90 minutes of treatment was determined. Also in three patients the hyperthermic mitomycin C treatments were limited to the thoracic cavity (HITOC). These results were compared to the percent of chemotherapy absorbed in patients with thoracic and abdominal chemotherapy lavage

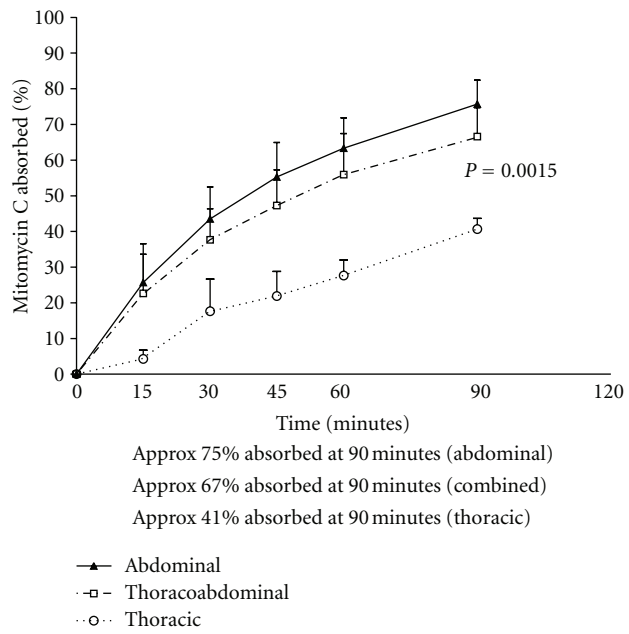

Figure 3: Comparison of percent mitomycin C absorbed after 90 minutes of treatment from the abdominal cavity, combined thoracic and abdominal cavity, and the thoracic cavity alone.

(HITAC). Figure 3 shows the results with mitomycin C. In patients with HIPEC mitomycin C treatment, 75% of the total drug administered at time zero was absorbed at 90 minutes. In patients with HITAC 67% was absorbed. In the patients with HITOC, only 41% was absorbed from this space at 90 minutes. This was highly significant as compared to the HITAC ($P = .0015$). Figure 4 shows similar data for doxorubicin. Very similar percent absorption over 90 minutes occurred in patients receiving HIPEC as compared to HITAC. For HITOC with doxorubicin, 72% was absorbed.

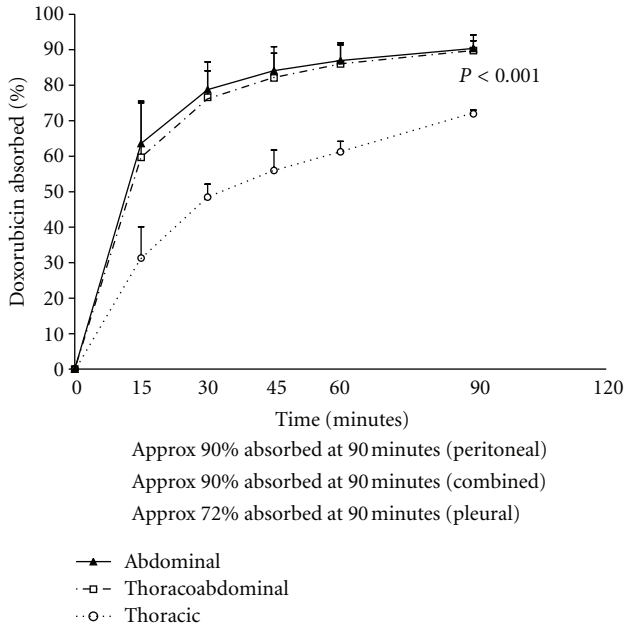

Figure 4: Comparison of percent of doxorubicin absorbed after 90 minutes of treatment from the abdominal cavity, thoracic and abdominal cavity, and the thoracic cavity alone.

This was statistically different when compared to the HITAC ($P < .001$).

3.3. Prospective Morbidity and Mortality Data. The prospective morbidity/mortality database on this group of 30 patients showed that no deaths occurred. In 11 of these 30 patients (37%) at least one grade III adverse event was recorded. Also in 8, at least one grade IV adverse event occurred (27%). The combined incidence of grade III and IV events was 43%. There was a single adverse grade III or IV event in 3 patients. However, most patients who had one adverse event experienced others. Five had two adverse grade III or IV events, one had three adverse events, one had 4 adverse events, and one had 7 adverse events recorded. The 30 adverse events recorded in 13 patients are listed in Table 2.

3.4. Survival Data. The overall survival of these groups of patients is presented in Figure 5. Median survival for appendiceal malignancy patients was 129 months, for peritoneal mesothelioma patients 44.6 months, and for colon cancer patients 13.4 months. In the analysis of the appendiceal mucinous neoplasm patients, adenomucinosis histology (one patient) was combined with those patients with peritoneal mucinous carcinoma (15 patients). The single gastric cancer patient died at 5 months.

3.5. Recurrence. All patients have been followed to determine if cancer progressed within the thoracic cavity after HITAP. A single patient with appendiceal malignancy who had both the right and left thoracic space entered at the time of cytoreduction recurred within the pleural space. Two mesothelioma patients recurred within the pleural space.

4. Discussion

4.1. Pleural Disease Progression in Patients with and without Hyperthermic Intraoperative Thoracoabdominal Chemotherapy (HITAC). In a previous publication looking at patterns of failure in the treatment of patients with pseudomyxoma peritonei, our group reported 6 of 8 patients to develop disease within the ipsilateral thorax if the pleural space was entered as a result of a subdiaphragmatic peritonectomy [12]. In these patients the diaphragm was closed prior to the intraperitoneal chemotherapy treatment. Therefore, little if any direct contact of chemotherapy solution with the pleural space could occur. In these eight patients, 75% had iatrogenic dissemination of disease from abdominal space to thoracic cavity as a result of an interruption of the integrity of the hemidiaphragm. In the 118 patients in Zoetmulder's manuscript, pleural dissemination did not occur unless the pleural space was entered. These patients all received early postoperative intraperitoneal chemotherapy (EPIC). In contrast, we have followed-up all 16 appendiceal malignancy patients treated with HITAC for disease progression within the pleural space. Pleural progression occurred in a single patient. This was the patient who required both right and left diaphragm resection as the time of her primary cytoreduction. These data strongly suggest that HITAC is an essential part of the treatment of peritoneal metastases if diaphragm resection is required.

4.2. Abdominal versus Thoracic and Abdominal versus Thoracic Chemotherapy Lavage. The pharmacokinetic advantage of chemotherapy administration into the peritoneal cavity has been described in many prior publications. Van der Speeten and colleagues presented doxorubicin levels in plasma, peritoneal fluid, and tumor nodules. The ratio of drug concentration within the peritoneal space as compared to that present in the plasma was 73 times greater within the peritoneal fluid. Doxorubicin levels within tumor tissue were 1.8 times higher than in the peritoneal fluid [13]. Likewise, pharmacokinetic data regarding intraperitoneal administration of mitomycin C has been reported in the past. Van der Speeten and colleagues showed that the exposure of peritoneal surfaces to be 26 times higher than exposure within the plasma [9]. Technical difficulties with extracting mitomycin C from body tissues precluded the data regarding tissue levels of mitomycin C [9]. Because of the large increase in total diffusion surface when the pleural space is added to the abdominal space for HITAC, we expected a more rapid clearance of the intracavitary chemotherapy [14].

To our surprise adding the pleural space to the HIPEC procedure did little to change the pharmacokinetics of the chemotherapy. This is important in that the percent of chemotherapy absorbed from the thoracic and abdominal space should predict the likelihood of hematologic toxicity in this group of patients. Apparently, the absorption of chemotherapy from the pleural space through the parietal pleura and visceral pleura is considerably less efficient than from the abdominal and pelvic cavity. Data showed the clearance of mitomycin C over 90 minutes to be approximately 75% from the abdominal space, 67% from

Table 2: Causes of grade III or IV adverse events. There were 30 adverse events in 13 patients (43%).

	III	IV	III + IV (%)
Line sepsis	4	0	4 (13)
Anemia (Hgb < 6.5)	3	0	3 (10)
Pneumonia	0	2	2 (7)
Venous thrombosis	2	0	2 (7)
Anastomotic leak	0	1	1 (3)
Intraabdominal abscess	0	1	1 (3)
Urinary tract infection	3	0	3 (10)
Profound neutropenia (WBC < 1000)	2	1	3 (10)
Hartmann stump leak	0	1	1 (3)
Unscheduled hospital readmission	1	1	2 (7)
Pleural effusion requiring thoracentesis	2	0	2 (7)
Postoperative bleed requiring reoperation	0	3	3 (10)
Renal failure requiring hemodialysis	0	1	1 (3)
Respiratory failure requiring tracheostomy	0	1	1 (3)
Bile leak from liver surface requiring reoperation	0	1	1 (3)
Total	17	13	30 (43)

the thoracoabdominal space, and only 41% when the lavage is limited to the pleural space. Also, for doxorubicin, 90% of the drug was absorbed from the abdominal space, 90% from the thoracoabdominal space, and only 72% absorbed from the pleural space. This lack of permeability of the pleura to cancer chemotherapy accounts for the similarities of drug absorption from abdominal space as compared to thoracoabdominal space despite a large increase in the total diffusion surface.

This observation is important in this group of patients. It indicates to us that the dose of chemotherapy that would be used to treat the abdomen and pelvis can be estimated to be the same dose as that to treat the thorax and abdominal space. No adjustments in the standardized HIPEC chemotherapy orders are necessary in this clinical situation.

4.3. Adverse Events with Diaphragm Resection. In this group of patients the resection of the hemidiaphragm was associated with a 43% incidence of grade III or IV adverse events. There was no mortality. Our most recent morbidity data showed a 0.7% mortality, a grade III incidence of 20% and grade IV of 12% with cytoreductive surgery limited to the abdomen and pelvis [15]. Our data in 30 patients with diaphragm resection, chemotherapy lavage of both thorax and abdomen, and then a suture repair of the diaphragm showed no mortality, a grade III incidence of 37%, and a grade IV of 27%. Apparently, the subdiaphragmatic peritonectomy with partial excision of a hemidiaphragm identifies a group of patients with extensive cytoreduction and a greater likelihood of morbidity. However, we think these data show that cytoreductive surgeons should not hesitate to perform a resection of the tendinous midportion of the hemidiaphragm in order to achieve a CC-0/CC-1 cytoreduction and combine this surgery with HITAP. Benefits are expected in terms of local control using this approach.

4.4. Survival of Patients Having Diaphragm Resection. Figure 5 shows the survival with diaphragm resection as a part of a cytoreductive surgical procedure. The appendiceal malignancy patients showed the longest median survival (129 months). Also, a median survival of 45 months for peritoneal mesothelioma patients is acceptable. One of the five colon cancer patients who required diaphragm resection for a complete cytoreduction was a long-term survivor.

4.5. Current Recommendations for Management of Diaphragm Resection. Our current recommendation for management of diaphragm whose central tendon is infiltrated by tumor is as follows. If during the right or left subdiaphragmatic peritonectomy it becomes clear that partial resection of the diaphragm is necessary, the dissection beneath the diaphragm ceases and the cytoreduction moves to a different part of the abdomen and pelvis. The cytoreduction is completed as thoroughly as possible at all other sites within the abdomen and pelvis with the exclusion of the hemidiaphragm. Then, there is a vigorous six liter irrigation of the entire abdomen and pelvis in order to mechanically clear free cancer cells from the abdomen and pelvis. Alternatively, the cytoreduction may turn out to be incomplete so that diaphragm resection is not required to finish the CC-2/CC-3 cytoreduction.

After this mechanical cleansing of the abdomen and pelvis of cancer cells, the required resection of the hemidiaphragm occurs. The specimen is carefully labeled in terms of its abdominal and thoracic orientation. It is important to determine if the disease has invaded full thickness through the hemidiaphragm. The thoracic cavity is carefully inspected for nodules of mucinous cancer or mesothelioma. Nodules that can be excised without extensive pleurectomy are removed and also submitted for permanent histopathologic study. Abdominal drains and an inflow catheter are placed. A thoracostomy tube is placed within the chest cavity. The three abdominal drains and the thoracostomy tube are

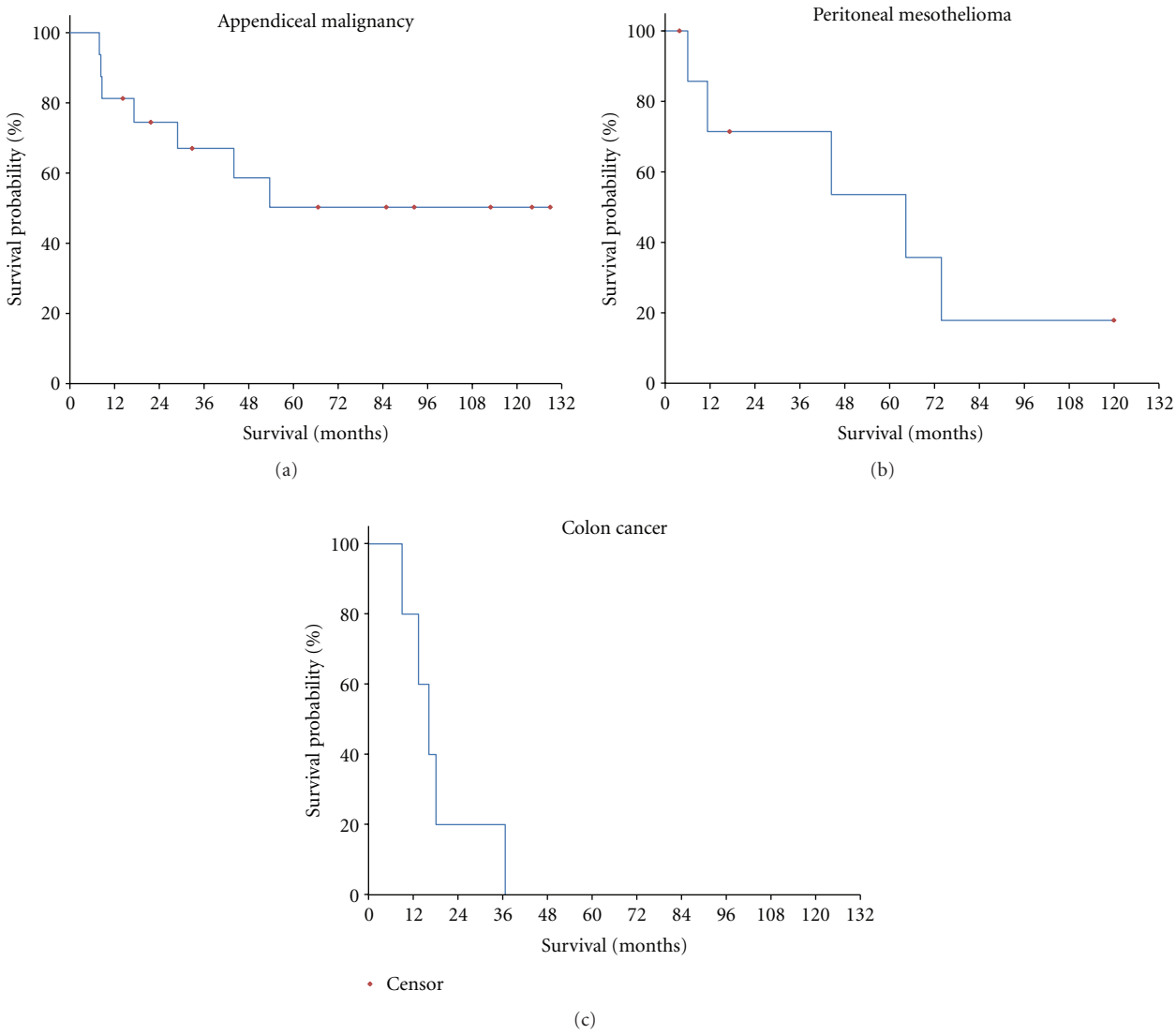

Figure 5: Survival for 29 patients who had a resection of the diaphragm as part of the cytoreductive surgical procedure combined with hyperthermic intraoperative thoracoabdominal chemotherapy (HITAC). (a) appendiceal malignancy ($N = 16$), (b) peritoneal mesothelioma ($N = 8$), and (c) colon cancer ($N = 5$).

simultaneously used for drainage of the chemotherapy. The inflow catheter is sequentially placed in the pelvis, the right paracolic sulcus, the left paracolic sulcus, under the intact hemidiaphragm, and finally through the diaphragm into the chest. After the chemotherapy lavage is complete the fluid is suctioned from the abdomen and pelvis. A count of all laparotomy pads is obtained and then the chest cavity is closed. A series of interrupted and running #1 Vicryl sutures (Ethicon, Cincinnati, OH) are used. The use of a prosthetic diaphragm patch is seldom, if ever, necessary.

4.6. Open versus Closed Hyperthermic Intraperitoneal Chemotherapy. Currently, there remains some controversy regarding the methodology for administration of hyperthermic intraperitoneal chemotherapy. In the closed technique there is less danger, theoretically, for aerosol contamination of the operating theater. With the closed technique, if the diaphragm was opened as a result of cancer infiltration, this opening would be closed prior to the initiation of HIPEC. This is a theoretical disadvantage in that tumor cells can only be mechanically removed from the thoracic cavity rather than treated with the chemotherapy. In the open methodology the combined abdomen and chest cavities are simultaneously lavaged with the chemotherapy solution for the full 90 minutes. Data from this paper suggests that the administration of HITAC does not require dose adjustments of the chemotherapy as compared to HIPEC. Also, these data suggest that local control as a result of HITAC within the thoracic space is excellent. Following the hyperthermic chemotherapy lavage of the contaminated pleural surfaces, the diaphragm would be closed leaving a large bore thoracostomy tube within the thoracic cavity. A separate inflow catheter into the chest was not necessary because of the

large volume of chemotherapy outflow through the open diaphragm and out through the thoracostomy tube. A theoretical and probably actual clinical advantage of the open method over the closed method occurs in patients required to have diaphragm resection.

4.7. Rationale for HITAC in Patients with CC-2/CC-3 Cytoreduction. The data regarding palliative benefit of HIPEC in patients with CC-2/CC-3 cytoreduction has never been rigorously studied. There is no doubt that incomplete cytoreduction is associated with a poor prognosis in appendiceal cancer, colorectal cancer, and peritoneal mesothelioma patients. However, when added to an extensive debulking procedure, the hyperthermic intracavitary chemotherapy may achieve a partial response and prolong the patient's life. This may be most likely if all adhesions on bowel loops are separated so the HIPEC is in contact with all peritoneal surfaces. Also, any patients who have ascites as a component of their peritoneal surface malignancy should receive intracavitary chemotherapy in order to guard against debilitating ascites occurring as the disease progresses. Garofalo and Valle showed that HIPEC is an excellent treatment for the management of cancerous ascites [16].

5. Conclusions

HITAC is a treatment option for cytoreductive surgery in appendiceal and DMPM patients when the diaphragm must be partially resected as part of a cytoreductive surgical procedure. The pharmacokinetic advantage of direct intracavitary administration is preserved when HITAC is utilized. Also, judgments in the chemotherapy dose were not found to be necessary with HITAC as compared to HIPEC. An assessment of adverse events showed a 43% incidence of grade III or grade IV adverse events which is higher than reported for most groups of patients undergoing cytoreductive surgery and HIPEC. However, the survival was acceptable and the incidence of intrathoracic recurrence was low.

References

[1] P. H. Sugarbaker, "Comprehensive management of peritoneal surface malignancy using cytoreductive surgery and perioperative intraperitoneal chemotherapy," *Cancer Research in Cancer*, vol. 3, pp. 179–203, 2009.

[2] O. Glehen, F. N. Gilly, F. Boutitie et al., "Toward curative treatment of peritoneal carcinomatosis from nonovarian origin by cytoreductive surgery combined with perioperative intraperitoneal chemotherapy: a multi-institutional study of 1290 patients," *Cancer*, vol. 116, no. 24, pp. 5608–5618, 2010.

[3] H. Youssef, C. Newman, K. Chandrakumaran, F. Mohamed, T. D. Cecil, and B. J. Moran, "Operative findings, early complications, and long-term survival in 456 patients with pseudomyxoma peritonei syndrome of appendiceal origin," *Diseases of the Colon and Rectum*, vol. 54, no. 3, pp. 293–299, 2011.

[4] D. Elias, J. H. Lefevre, J. Chevalier et al., "Complete cytoreductive surgery plus intraperitoneal chemohyperthermia with oxaliplatin for peritoneal carcinomatosis of colorectal origin," *Journal of Clinical Oncology*, vol. 27, no. 5, pp. 681–685, 2009.

[5] T. D. Yan, D. Black, P. H. Sugarbaker et al., "A systematic review and meta-analysis of the randomized controlled trials on adjuvant intraperitoneal chemotherapy for resectable gastric cancer," *Annals of Surgical Oncology*, vol. 14, no. 10, pp. 2702–2713, 2007.

[6] P. H. Sugarbaker, "Peritonectomy procedures," *Annals of Surgery*, vol. 221, no. 1, pp. 29–42, 1995.

[7] K. Van der Speeten, O. A. Stuart, and P. H. Sugarbaker, "Pharmacokinetics and pharmacodynamics of perioperative cancer chemotherapy in peritoneal surface malignancy," *Cancer Journal*, vol. 15, no. 3, pp. 216–224, 2009.

[8] P. H. Sugarbaker, "Peritonectomy procedures," *Surgical Oncology Clinics of North America*, vol. 12, no. 3, pp. 703–727, 2003.

[9] K. Van der Speeten, O. A. Stuart, D. Chang, H. Mahteme, and P. H. Sugarbaker, "Changes induced by surgical and clinical factors in the pharmacology of intraperitoneal mitomycin C in 145 patients with peritoneal carcinomatosis," *Cancer Chemotherapy and Pharmacology*, vol. 68, no. 1, pp. 147–156, 2011.

[10] P. H. Sugarbaker, K. Van der Speeten, O. Anthony Stuart, and D. Chang, "Impact of surgical and clinical factors on the pharmacology of intraperitoneal doxorubicin in 145 patients with peritoneal carcinomatosis," *European Journal of Surgical Oncology*, vol. 37, no. 8, pp. 719–726, 2011.

[11] P. H. Sugarbaker, R. Alderman, G. Edwards et al., "Prospective morbidity and mortality assessment of cytoreductive surgery plus perioperative intraperitoneal chemotherapy to treat peritoneal dissemination of appendiceal mucinous malignancy," *Annals of Surgical Oncology*, vol. 13, no. 5, pp. 635–644, 2006.

[12] F. A. N. Zoetmulder and P. H. Sugarbaker, "Patterns of failure following treatment of pseudomyxoma peritonei of appendiceal origin," *European Journal of Cancer Part A*, vol. 32, no. 10, pp. 1727–1733, 1996.

[13] K. Van der Speeten, O. A. Stuart, H. Mahteme, and P. H. Sugarbaker, "A pharmacologic analysis of intraoperative intracavitary cancer chemotherapy with doxorubicin," *Cancer Chemotherapy and Pharmacology*, vol. 63, no. 5, pp. 799–805, 2009.

[14] R. L. Dedrick and M. F. Flessner, "Pharmacokinetic problems in peritoneal drug administration: tissue penetration and surface exposure," *Journal of the National Cancer Institute*, vol. 89, no. 7, pp. 480–487, 1997.

[15] P. H. Sugarbaker, K. Van der Speeten, O. A. Stuart, D. Chang, and H. Mahteme, "Patient- and treatment-related variables, adverse events and their statistical relationship for treatment of peritoneal metastases," in *Cytoreductive Surgery and Perioperative Chemotherapy for Peritoneal Surface Malignancy: Textbook and Video Atlas*, P. H. Sugarbaker, Ed.

[16] A. Garofalo and M. Valle, "Laparoscopy in the management of peritoneal carcinomatosis," *Cancer Journal*, vol. 15, no. 3, pp. 190–195, 2009.

Hindawi Publishing Corporation
Gastroenterology Research and Practice
Volume 2012, Article ID 141585, 7 pages
doi:10.1155/2012/141585

Clinical Study

Prevention of Peritoneal Metastases from Colon Cancer in High-Risk Patients: Preliminary Results of Surgery plus Prophylactic HIPEC

Paolo Sammartino,[1] Simone Sibio,[1] Daniele Biacchi,[1] Maurizio Cardi,[1] Fabio Accarpio,[1] Pietro Mingazzini,[2] Maria Sofia Rosati,[2] Tommaso Cornali,[1] and Angelo Di Giorgio[1]

[1] *Dipartimento di Chirurgia Pietro Valdoni, Azienda Policlinico Umberto I, Università degli Studi di Roma "La Sapienza," 00161 Roma, Italy*
[2] *Dipartimento di Medicina Sperimentale, Azienda Policlinico Umberto I, Università degli Studi di Roma "La Sapienza," 00161 Roma, Italy*

Correspondence should be addressed to Paolo Sammartino, paolo.sammartino@uniroma1.it

Received 26 January 2012; Accepted 17 February 2012

Academic Editor: Paul H. Sugarbaker

The study compared the outcome in patients with advanced colonic cancer at high risk of peritoneal metastases (mucinous or signet-ring cell) without peritoneal or systemic spread, treated with standard colectomy or a more aggressive combined surgical approach. The study included patients with colonic cancer with clinical T3/T4, any N, M0, and mucinous or signet ring cell histology. The 25 patients in the experimental group underwent hemicolectomy, omentectomy, bilateral adnexectomy, hepatic round ligament resection, and appendectomy, followed by HIPEC. The control group comprised 50 patients treated with standard surgical resection during the same period in the same hospital by different surgical teams. Outcome data, morbidity, peritoneal recurrence rate, and overall, and disease-free survival, were compared. Peritoneal recurrence developed in 4% of patients in the experimental group and 22% of controls without increasing morbidity ($P < 0.05$). Actuarial overall survival curves disclosed no significant differences, whereas actuarial disease-free survival curves showed a significant difference between groups (36.8 versus 21.9 months, $P < 0.01$). A more aggressive preventive surgical approach combined with HIPEC reduces the incidence of peritoneal recurrence in patients with advanced mucinous colonic cancer and also significantly increases disease-free survival compared with a homogeneous control group treated with a standard surgical approach without increasing morbidity.

1. Introduction

Epidemiological data indicate that peritoneal spread from colorectal cancer is an event that involves 10–15% of patients at the time of primary cancer resection and about 25–50% of patients with recurrent disease, generally leading to death within weeks or months [1–5]. Several features of primary tumors of colorectal origin appear to be related to a later development of peritoneal spread: mucinous colorectal cancers or signet ring cell carcinomas tend preferentially to metastasize to the peritoneum or ovaries [6–10]. Intraperitoneal metastases may spread by full-thickness bowel wall invasion or may arise iatrogenically during surgery when "in transit" tumor cells or emboli escape from dissected lymph vessels within the bowel lumen or reach the peritoneal cavity through blood spill from the surgical field [11].

Since the 1990s, Paul Sugarbaker's studies on cytoreductive surgery plus perioperative intraperitoneal chemotherapy such as hyperthermic intraperitoneal chemotherapy (HIPEC) have prompted a new treatment option for selected pa-tients with peritoneal metastases from colorectal cancer [12–14]. Three studies, one randomized and two nonrandomized, have shown that this combined procedure provides a better outcome than 5-fluorouracil-based chemotherapy or more modern chemotherapy regimens [15–17].

Despite these encouraging results, even if 5-year survival can reach a value close to 45% at the expense of a mortality rate ranging from 3 to 5% and a morbidity rate around 30%

in selected cases [18, 19], outcome depends on many factors. The first is peritoneal involvement as measured by the peritoneal cancer index (PCI), the second the degree of cytoreduction achieved, and finally the surgical team's level of experience [20, 21]. Given that better prognostic results can be expected only in patients with a low PCI, in whom complete cytoreduction is possible, and because current imaging techniques cannot detect peritoneal metastases before they becomes clinically evident and symptomatic [22, 23], in practice these combined approaches apply only to few patients and rarely offer long-term survival.

In the past, in line with what others now propose for ovarian cancer [24], experimental investigations and clinical trials have used normothermic intraperitoneal chemotherapy as adjuvant treatment in colorectal patients at high risk of recurrence, with inconclusive results [25–27]. In recent years, some have suggested early second-look surgery in the absence of clinical signs of recurrence for colorectal patients at high risk of peritoneal relapse to detect and treat those with carcinomatosis at an initial stage [28, 29]. Based on preliminary results, two randomized trials will begin in France and the United States to answer the question whether second-look surgery envisaging cytoreductive surgery with HIPEC or HIPEC alone will prolong overall survival and reduce the risk of relapse compared with standard care (observation) in patients with colorectal cancer at high risk for peritoneal spread [30, 31].

Prompted by the need to seek new ways of managing colorectal cancer in patients at high risk of recurrence but still without evident signs of peritoneal spread, we decided to concentrate our efforts on a timely strategy envisaging a primary operation aimed at preventing peritoneal metastases. Ample evidence shows that the two major elements influencing peritoneal spread in colorectal cancer are the depth of bowel wall invasion (pT3/4) and histological features of the malignancy (mucinous and signet ring cell carcinomas) [5–11]. Both are characteristics that the surgeon can verify during the primary operation and if necessary use the information to change the strategy to a more aggressive approach combining surgical resection and HIPEC.

We designed this single-center case-control study to analyze outcome in two comparable groups of patients with advanced colonic cancer (pT3/4 with mucinous or signet ring cell cancer) without peritoneal or systemic spread treated with standard colectomy, according to the established guidelines [32] (control group), or by a more aggressive combined approach aimed to prevent peritoneal spread. For this purpose, in the experimental group we extended our standard sur-gical resection to the metastatic sanctuaries of peritoneal diffusion (including the omentum, adnexa, and appendix) and combined these surgical procedures with prophylactic HIPEC. As the primary outcome variables we compared morbidity, the incidence of peritoneal recurrence and overall and disease-free survival in the two groups.

2. Materials and Methods

2.1. Experimental Group. The study included patients with colonic cancer or intraperitoneal rectosigmoid cancer (over 15 cm from the anal verge) with clinical T3/T4, any N, and M0 stage treated at the Department of Surgery Pietro Valdoni at Sapienza University of Rome from January 2006 to December 2008. To avoid bias from neoadjuvant therapy we excluded patients with extraperitoneal rectal cancer. Selection criteria were age younger than 70 years, cancer with mucinous or signet ring cell components (>20% according to criteria proposed by Ogino et al. [33], performance status 0–2 (WHO) [34]), and adequate renal, hepatic, and bone marrow function. All patients gave specific informed written consent. Exclusion criteria were metastatic disease, other malignances, multiple colorectal cancer, active infections, or severe associated medical conditions. Patients with perforated cancers were considered eligible regardless of histology. At surgical exploration, patients with unrecognized peritoneal seedings were excluded from the study as well as those with hepatic involvement detected at intraoperative ultrasound. None of the patients underwent peritoneal lavage cytology [35]. At operation, after the standard hemicolectomy done according to the established guidelines, intraoperative pathologic evaluation assessed tumor depth (pT) and the histologic features necessary to include the patient in the study. In the selected cases the surgical resection also included complete omentectomy, bilateral adnexectomy in postmenopausal patients, hepatic round ligament resection and appendectomy if not already done. At the end of surgery, HIPEC was delivered with the closed technique with oxaliplatin 460 mg/m^2 in 2 l/m^2 of dextrose at a temperature of 43°C over 30 minutes at a flow rate of 2 L/min. Before HIPEC began and during surgery patients received intravenous fluorouracil of 400 mg/m^2 and leucovorin of 20 mg/m^2 to potentiate oxaliplatin activity. Systemic adjuvant chemotherapy was reserved after discharge to patients with pT4, node positive, and G3 tumors. The study was approved by the hospital institutional review board.

2.2. Control Group. Control subjects were retrospectively selected from patients with colonic cancer treated with standard surgical resection, during the same period in the same hospital but by different surgical teams. The selection process comprised two steps. During the first step surgeons from another surgical team in our hospital selected from their records all patients with colonic cancer treated from January 2006 to December 2008 and who met the eligibility criteria required in our experimental study and had known follow-up. In particular, we selected patients with T3/T4 mucinous or signet ring cell carcinoma resected for cure (R0) without systemic spread. As in the experimental group, control patients with perforated colon cancer were included regardless of histology. During the second step the principal investigator (P. Sammartino) double-checked the medical records for the potentially eligible patients provided by other surgical teams by recontacting the investigator to ensure that the eligibility criteria had been homogeneously applied. During double-checking the investigator was unaware of the patients' outcome.

2.3. Follow-Up and Statistics. Data for patients in the experimental group were recorded prospectively in a specific

database. Data for patients the control group were recorded retrospectively. Surgical complications and adverse events were monitored in both groups and graded from 0 to V in accordance with the National Cancer Institute Common Toxicity Criteria [36]. Follow-up assessments took place every 3 months with clinical evaluation and tumor marker monitoring. A 64-section multidetector computed tomography (MDCT) and magnetic resonance imaging (MRI) with conventional and diffusion-weighted sequences were obtained alternatively every 6 months in the experimental and control groups, according to a protocol developed in collaboration with a dedicated radiological team [37]. The definition of peritoneal recurrence, included imaging findings of locoregional progression as well as peritoneal metastases distant from the resection site. No patient was excluded from the survival analysis. The chi-square test was used for univariate comparison. Survival curves were calculated with the Kaplan-Meier method and compared with the log-rank test. Survival was measured from the date of surgical treatment until death or the last follow-up. P values < 0.05 were considered to indicate statistical significance.

3. Results

Of the 230 patients with colonic cancer treated in our department between January 2006 and December 2008, 25 fulfilled the inclusion criteria and agreed to take part in this experimental investigation. A total of 75 patients were proposed for matching with those in the experimental study and after double checking for eligible criteria 50 were included in the control group. The clinical characteristics for both groups are shown in Table 1. Surgical procedures performed in both groups are reported in Table 2.

When surgery ended all 25 patients in the experimental group underwent HIPEC. In the study group a mean of 20 lymph nodes per patient were removed (range 15–28) and in the control group a mean of 19 (range 14–31). Locoregional lymph node metastases were found in 34% of patients in the experimental group and in 28% of those in the control group. Anatomopathological studies in the experimental group showed that none of the surgical specimens excised according to the protocol contained malignant disease. All the surgical procedures in both groups were R0. The mean length of surgery, blood loss, and postoperative stay were similar in the two groups. Except for 1 patient in the experimental group who had grade 2 pancreatitis related to HIPEC toxicity (that promptly regressed after medical therapy) morbidity rates were similar in the two groups. One patient in the experimental group underwent emergency laparotomy on postoperative day 2 for bleeding. One patient in the control group had a grade III complication (left ureteral leakage) that required endoscopy to place a stent, and 3 patients underwent a second laparotomy to construct an ileostomy for anastomotic leakage (Table 3). A total of 13 patients in the experimental group (52%) and 23 in the control group (46%) underwent first-line systemic adjuvant chemotherapy with fluorouracil and oxaliplatin. In relapsed patients second-line chemotherapy included irinotecan or molecular target drugs (cetuximab and bevacizumab or both).

Table 1: Clinical characteristics of the 2 groups.

	Patients (25) Mean age 62 (45–70)		Controls (50) Mean age 63 (48–72)	
	N	%	*N*	%
Sex				
Male	16	66	31	62
Female	9	34	19	38
Performance status				
0	21	84	41	82
1	4	16	7	14
2	—	—	2	4
Tumor site				
Right colon	9	36	15	30
Transverse colon	3	12	6	12
Left colon	13	52	29	58
Pt				
pT3	19	76	40	80
pT4a	1	4	1	2
pT4b	5	20	9	18
Nodal status				
N0	16	66	36	72
N1-2	9	34	14	28
Grading				
G2	17	68	37	64
G3	8	32	13	26
Histology				
Mucinous	23	92	45	90
Signet ring cell	1	4	4	8
Adc nos	1*	4	1*	2

* Perforated patients.

3.1. Follow-Up. After a mean 37.8-month follow-up in the experimental group and 35.1 months in the control group, 24% in the experimental group and 32% of the controls had recurrent disease (Table 4).

3.2. Experimental Group. Six patients showed relapse of disease: 5 had hepatic and or pulmonary metastases (mean time of recurrence 13 months) and 1 developed a peritoneal recurrence. This patient underwent a right hemicolectomy with abdominal wall resection for a T4b tumour and experienced a peritoneal recurrence detected at 30 months after operation. Two patients (one with single hepatic metastases and the peritoneal recurrence) underwent a second surgical procedure and are at the moment alive and disease-free at 38 and 39 months. Of the other 4 patients, 1 is currently alive with hepatic and pulmonary metastases and 3 died from progressive disease at a mean of 21 months.

Table 2: Surgical procedures performed in the 2 groups.

	Patients	Controls
Surgical procedures		
Complete omentectomy	25*	—
Hepatic round ligament resection	25*	—
Left hemicolectomy	13	29
Appendectomy	10*	—
Right hemicolectomy	9	15
Bilateral adnexectomy	6*	1°§
Transverse colon resection	3	6
Cholecystectomy	2§	2§
Abdominal wall resection	2°	3°
Small bowel resection	2°	3°
Right adnexectomy	1*	1°
Hysterectomy	1§	1°
Total, mean per patient	99–3.9	61–1.2

* Procedures performed according to the study protocol.
° Procedures performed for the tumor direct invasion.
§ Procedures performed for the coexisting benign disease.

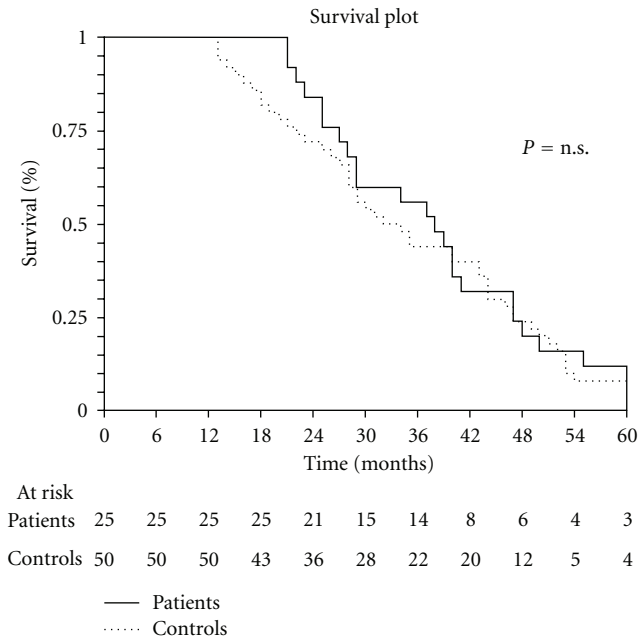

Figure 1: Overall survival.

3.3. Control Group. Sixteen patients showed recurrent disease: a peritoneal recurrence was found in 11 (22%), associated in 4 cases with hepatic and/or pulmonary disease at a mean of 12.7 months after first operation. Initial diagnosis of peritoneal metastases was made after MDCT and MRI findings according to our published protocol [37]. In 9 patients the diagnosis was also confirmed by endoperitoneal ascites cytology or histology during laparoscopy or operation. Five patients showed only a systemic progression of the disease (hepatic in 3, pulmonary in 1, and both in 1). Three patients underwent a second surgical procedure:

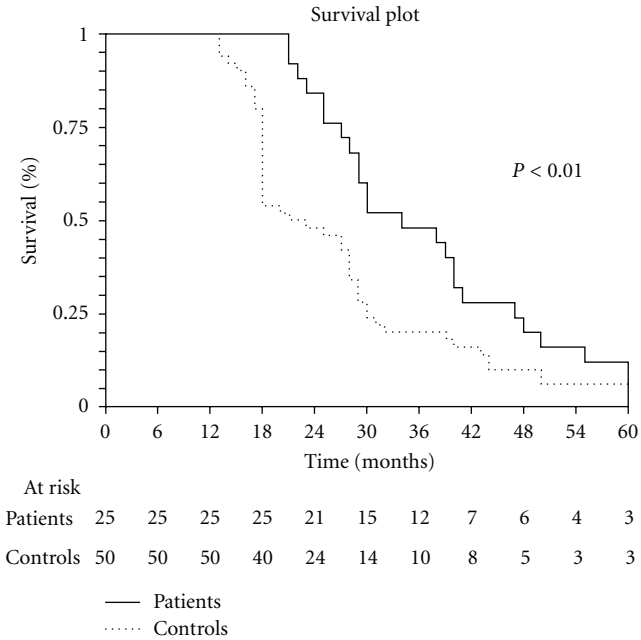

Figure 2: Disease free survival.

1 underwent a wedge resection for a single hepatic metastasis (alive disease-free at 31 months) and 2 cytoreduction and HIPEC for peritoneal metastases (alive with disease at 26 and 24 months). Four patients are currently alive with disease and 9 died from progression at a mean of 15.6 months.

A statistically significant difference in development of peritoneal metastases was observed between the 2 groups ($P < 0.05$, Table 4). The actuarial overall survival curves disclose no significant difference between the two groups (Figure 1) whereas the actuarial disease-free survival curves already show a significant difference ($P < 0.01$) between the two groups (36.8 months in the experimental group versus 21.9 months in the control group, Figure 2).

4. Discussion

Our preliminary results in this single-center case-control study show that our more aggressive preventive surgical approach combined with HIPEC significantly reduces the incidence of peritoneal recurrence in patients with advanced mucinous colonic cancer and also significantly increases disease-free survival compared with a homogeneous control group treated with a standard surgical approach and does so without increasing morbidity. Although our current data for overall survival seem as yet to show no difference between the survival curves for the experimental group and controls, the significant difference in disease-free survival suggests that overall survival will eventually differ as follow-up progresses.

Our preventive surgical strategy could have improved outcome because it is based on current knowledge on peritoneal fluid dynamics showing that exfoliated tumor cells from full-thickness tumors especially those from mucinous histotypes colonize specific sites [38, 39]. According to

Table 3: Surgical outcome in the 2 groups.

Morbidity	Patients		Controls	
	N	%	*N*	%
Grade I/II	3	12	5	10
Grade III	—	—	1	2
Grade IV	1	4	3	6
Hipec tox. grade 2	1*	4	—	—
	Patients		Controls	
Mean operation time (min)	180 (120–210)		155 (90–220)	
Mean blood loss (mL)	210 (180–290)		230 (150–400)	
Postop. stay (days)	11 (8–14)		14 (8–21)	

* Pancreatic.

Table 4: Site of recurrence.

	Patients (25)		Controls (50)		*P*
Metastases	*N*	%	*N*	%	
Distant	5	20	9	18	ns
Peritoneal	1	4	11*	22	<0.05
Total	6	24	16	32	ns

* 4 patients had also distant metastases.

a series of well-documented events, as in ovarian cancer progression, malignant spread in colonic cancer preferentially targets the omentum, pelvis, and ileocecal regions. Removing these target organs at the first surgical intervention regardless of whether they are macroscopically involved and following these surgical procedures with HIPEC, both aimed to eradicate microscopic residual disease, seems a reasonable strategy to reduce peritoneal spread.

We cannot say whether the reduced peritoneal recurrence and significantly improved disease-free survival in the experimental group depend on the associated surgical procedures (omentectomy, adnexectomy, appendectomy, and round ligament resection) or on HIPEC. Although pathological studies of the anatomic structures preventively removed in our patients disclosed no evidence of malignant disease, we can reasonably presume that removing these structures and delivering HIPEC both contributed to preventing microscopic peritoneal diffusion [40, 41].

Our proposal to address the problem from a new angle, namely, preventing colorectal peritoneal spread, seems to offer a promising alternative to those who recommend an early second look in high-risk patients [28, 31]. In our preventive study we defined high-risk patients with advanced colonic cancer as those with pT3/4 mucinous or signet ring cell cancer without peritoneal or systemic spread whereas those proposing second-look surgery enrolled a varied population including patients who at the primary intervention already had limited peritoneal carcinomatosis or ovarian metastases [28, 31]. These nonhomogeneous populations will make it difficult to interpret outcomes in the two ongoing randomized trials investigating second-look surgery [30, 31]. A major concern is whether randomizing patients to second-look surgery or observation is ethically justifiable given that in a preliminary report Elias et al. at second-look found that more than 50% of high-risk patients had peritoneal carcinomatosis that clinical and imaging examination left unrecognized [28]. Lastly, another problem related to second-look surgery is that a whole class of patients (those termed at high risk) must be referred to highly specialized tertiary centers (peritoneal surface malignancy treatment centers) so that peritoneal carcinomatosis if found can be properly treated. As cancer surgeons well know, the medical community still regards integrated treatments for peritoneal carcinomatosis with skepticism. And we all know how difficult it is to persuade patients (and their oncologist) to undergo a second intervention that may be lengthy and not without risks in the absence of specific symptoms and documentable clinical evidence. From the viewpoint of feasibility and costs we therefore consider it more appropriate to concentrate our efforts on and invest our resources in preventing peritoneal carcinomatosis right from the primary operation. If our innovative preventive strategy proves therapeutically worthwhile then it could be done in a larger number of surgical centers, would involve a larger number of patients, and might finally change the therapeutic options available to patients with advanced colorectal cancer at risk for peritoneal carcinomatosis [29].

Some might criticize our preventive proposal stating that in patients with advanced colonic cancer with no documented signs of carcinomatosis our aggressive approach could be considered overtreatment. This criticism notwithstanding, our early aggressive approach receives strong support because without increasing morbidity rates it lowers the incidence of peritoneal carcinomatosis and offers better disease-free survival than in a homogeneous sample of patients who received standard surgical treatment. Our preventive approach also accords with Sugarbaker, who recommended after second-look surgery negative for carcinomatosis a procedure analogous to the one we describe here (omentectomy, adnexectomy, and HIPEC) [29]. Hence, in high-risk patients why not use this approach right from the primary surgical intervention. The true therapeutic value of our preventive surgical approach for patients with advanced mucinous colonic cancer awaits confirmation in future randomized multicenter studies.

Disclosure

The paper was presented at the Sixth International Symposium on Regional Cancer Therapies Incline Village, Nevada on February 19–21, 2011.

References

[1] D. Z. J. Chu, N. P. Lang, C. Thompson, P. K. Osteen, and K. C. Westbrook, "Peritoneal carcinomatosis in nongynecologic malignancy. A prospective study of prognostic factors," *Cancer*, vol. 63, no. 2, pp. 364–367, 1989.

[2] B. Sadeghi, C. Arvieux, O. Glehen et al., "Peritoneal carcinomatosis from non-gynecologic malignancies: results of the EVOCAPE 1 multicentric prospective study," *Cancer*, vol. 88, no. 2, pp. 358–363, 2000.

[3] D. G. Jayne, S. Fook, C. Loi, and F. Seow-Choen, "Peritoneal carcinomatosis from colorectal cancer," *British Journal of Surgery*, vol. 89, no. 12, pp. 1545–1550, 2002.

[4] A. Gómez Portilla, I. Cendoya, I. López De Tejada et al., "Peritoneal carcinomatosis of colorectal origin. Current treatment. Review and update," *Revista Espanola de Enfermedades Digestivas*, vol. 97, no. 10, pp. 716–737, 2005.

[5] V. E. Lemmens, Y. L. Klaver, V. J. Verwaal, H. J. Rutten, J. W.W. Coebergh, and I. H. De Hingh, "Predictors and survival of synchronous peritoneal carcinomatosis of colorectal origin: a population-based study," *International Journal of Cancer*, vol. 128, no. 11, pp. 2717–2725, 2011.

[6] T. Nozoe, H. Anai, S. Nasu et al., "Clinicopathological characteristics of mucinous carcinoma of the colon and rectum," *Journal of Surgical Oncology*, vol. 75, no. 2, pp. 103–107, 2000.

[7] Y. Kanemitsu, T. Kato, T. Hirai et al., "Survival after curative resection for mucinous adenocarcinoma of the colorectum," *Diseases of the Colon and Rectum*, vol. 46, no. 2, pp. 160–167, 2003.

[8] R. Pande, A. Sunga, C. LeVea et al., "Significance of signet-ring cells in patients with colorectal cancer," *Diseases of the Colon and Rectum*, vol. 51, no. 1, pp. 50–55, 2008.

[9] V. Catalano, F. Loupakis, F. Graziano et al., "Mucinous histology predicts for poor response rate and overall survival of patients with colorectal cancer and treated with first-line oxaliplatin- and/or irinotecan-based chemotherapy," *British Journal of Cancer*, vol. 100, no. 6, pp. 881–887, 2009.

[10] W. Song, S. J. Wu, Y. L. He et al., "Clinicopathologic features and survival of patients with colorectal mucinous, signet-ring cell or non-mucinous adenocarcinoma: experience at an institution in southern China," *Chinese Medical Journal*, vol. 122, no. 13, pp. 1486–1491, 2009.

[11] M. J. Koppe, O. C. Boerman, W. J. G. Oyen, and R. P. Bleichrodt, "Peritoneal carcinomatosis of colorectal origin: incidence and current treatment strategies," *Annals of Surgery*, vol. 243, no. 2, pp. 212–222, 2006.

[12] P. H. Sugarbaker, "Peritonectomy procedures," *Annals of Surgery*, vol. 221, no. 1, pp. 29–42, 1995.

[13] P. H. Sugarbaker, *Peritoneal Carcinomatosis: Principles of Management*, Kluwer Academic, Boston, Mass, USA, 1996.

[14] J. Esquivel, R. Sticca, P. Sugarbaker et al., "Cytoreductive surgery and hyperthermic intraperitoneal chemotherapy in the management of peritoneal surface malignancies of colonic origin: a consensus statement," *Annals of Surgical Oncology*, vol. 14, no. 1, pp. 128–133, 2007.

[15] V. J. Verwaal, S. Van Ruth, E. De Bree et al., "Randomized trial of cytoreduction and hyperthermic intraperitoneal chemotherapy versus systemic chemotherapy and palliative surgery in patients with peritoneal carcinomatosis of colorectal cancer," *Journal of Clinical Oncology*, vol. 21, no. 20, pp. 3737–3743, 2003.

[16] D. Elias, J. H. Lefevre, J. Chevalier et al., "Complete cytoreductive surgery plus intraperitoneal chemohyperthermia with oxaliplatin for peritoneal carcinomatosis of colorectal origin," *Journal of Clinical Oncology*, vol. 27, no. 5, pp. 681–685, 2009.

[17] J. Franko, Z. Ibrahim, N. J. Gusani, M. P. Holtzman, D. L. Bartlett, and H. J. Zeh, "Cytoreductive surgery and hyperthermic intraperitoneal chemoperfusion versus systemic chemotherapy alone for colorectal peritoneal carcinomatosis," *Cancer*, vol. 116, no. 16, pp. 3756–3762, 2010.

[18] V. J. Verwaal, S. Van Ruth, A. Witkamp, H. Boot, G. Van Slooten, and F. A. N. Zoetmulder, "Long-term survival of peritoneal carcinomatosis of colorectal origin," *Annals of Surgical Oncology*, vol. 12, no. 1, pp. 65–71, 2005.

[19] D. Elias, B. Raynard, F. Farkhondeh et al., "Peritoneal carcinomatosis of colorectal origin: long-term results of intraperitoneal chemohyperthermia with oxaliplatin following complete cytoreductive surgery," *Gastroenterologie Clinique et Biologique*, vol. 30, no. 10, pp. 1200–1204, 2006.

[20] D. Elias, F. Gilly, F. Boutitie et al., "Peritoneal colorectal carcinomatosis treated with surgery and perioperative intraperitoneal chemotherapy: retrospective analysis of 523 patients from a multicentric french study," *Journal of Clinical Oncology*, vol. 28, no. 1, pp. 63–68, 2010.

[21] C. Cao, T. D. Yan, D. Black, and D. L. Morris, "A systematic review and meta-analysis of cytoreductive surgery with perioperative intraperitoneal chemotherapy for peritoneal carcinomatosis of colorectal origin," *Annals of Surgical Oncology*, vol. 16, no. 8, pp. 2152–2165, 2009.

[22] C. Dromain, S. Leboulleux, A. Auperin et al., "Staging of peritoneal carcinomatosis: enhanced CT vs. PET/CT," *Abdominal Imaging*, vol. 33, no. 1, pp. 87–93, 2008.

[23] J. L. Koh, T. D. Yan, D. Glenn, and D. L. Morris, "Evaluation of preoperative computed tomography in estimating peritoneal cancer index in colorectal peritoneal carcinomatosis," *Annals of Surgical Oncology*, vol. 16, no. 2, pp. 327–333, 2009.

[24] L. Elit, T. K. Oliver, A. Covens et al., "Intraperitoneal chemotherapy in the first-line treatment of women with stage III epithelial ovarian cancer: a systematic review with metaanalyses," *Cancer*, vol. 109, no. 4, pp. 692–702, 2007.

[25] W. Scheithauer, G. V. Kornek, A. Marczell et al., "Combined intravenous and intraperitoneal chemotherapy with fluorouracil + leucovorin vs fluoououracil + levamisole for adjuvant therapy of resected colon carcinoma," *British Journal of Cancer*, vol. 77, no. 8, pp. 1349–1354, 1998.

[26] J. C. Vaillant, B. Nordlinger, S. Deuffic et al., "Adjuvant intraperitoneal 5-fluorouracil in high-risk colon cancer: a multicenter phase III trial," *Annals of Surgery*, vol. 231, no. 4, pp. 449–456, 2000.

[27] B. Nordlinger, P. Rougier, J. P. Arnaud et al., "Adjuvant regional chemotherapy and systemic chemotherapy versus systemic chemotherapy alone in patients with stage II-III colorectal cancer: a multicentre randomised controlled phase III trial," *Lancet Oncology*, vol. 6, no. 7, pp. 459–468, 2005.

[28] D. Elias, D. Goéré, D. Di Pietrantonio et al., "Results of systematic second-look surgery in patients at high risk of developing colorectal peritoneal carcinomatosis," *Annals of Surgery*, vol. 247, no. 3, pp. 445–450, 2008.

[29] P. H. Sugarbaker, "Comprehensive management of disseminated colorectal cancer," *Annals of Surgical Oncology*, vol. 15, no. 12, pp. 3327–3330, 2008.

[30] L. Maggiori and D. Elias, "Curative treatment of colorectal peritoneal carcinomatosis: current status and future trends," *European Journal of Surgical Oncology*, vol. 36, no. 7, pp. 599–603, 2010.

[31] R. T. Ripley, J. L. Davis, C. D. Kemp, S. M. Steinberg, M. A. Toomey, and I. Avital, "Prospective randomized trial evaluating mandatory second look surgery with HIPEC and CRS vs. standard of care in patients at high risk of developing colorectal peritoneal metastases," *Trials*, vol. 11, article no. 62, 2010.

[32] H. Nelson, N. Petrelli, A. Carlin et al., "Guidelines 2000 for colon and rectal cancer surgery," *Journal of the National Cancer Institute*, vol. 93, no. 8, pp. 583–596, 2001.

[33] S. Ogino, M. Brahmandam, M. Cantor et al., "Distinct molecular features of colorectal carcinoma with signet ring cell component and colorectal carcinoma with mucinous component," *Modern Pathology*, vol. 19, no. 1, pp. 59–68, 2006.

[34] World Health Organization, *WHO Handbook for Reporting Results of Cancer Traetment*, WHO, Geneva, Switzerland, 1979.

[35] J. H. Lefevre and D. M. Elias, "Cytoreductive surgery plus intraperitoneal chemohyperthermia in patients with colorectal cancer at high risk for local-regional recurrence," *Cancer Journal*, vol. 15, no. 3, pp. 200–203, 2009.

[36] A. Saxena, T. D. Yan, and D. L. Morris, "A critical evaluation of risk factors for complications after cytoreductive surgery and perioperative intraperitoneal chemotherapy for colorectal peritoneal carcinomatosis," *World Journal of Surgery*, vol. 34, no. 1, pp. 70–78, 2010.

[37] F. Iafrate, M. Ciolina, P. Sammartino et al., "Peritoneal carcinomatosis: imaging with 64-MDCTand 3T MRI with diffusion-weighted imaging," *Abdominal Imaging*. In press.

[38] C. P. Carmignani, T. A. Sugarbaker, C. M. Bromley, and P. H. Sugarbaker, "Intraperitoneal cancer dissemination: mechanisms of the patterns of spread," *Cancer and Metastasis Reviews*, vol. 22, no. 4, pp. 465–472, 2003.

[39] P. H. Sugarbaker, "Mucinous colorectal carcinoma," *Journal of Surgical Oncology*, vol. 77, no. 4, pp. 282–283, 2001.

[40] P. H. Sugarbaker, "It's what the surgeon doesn't see that kills the patient," *Journal of Nippon Medical School*, vol. 67, no. 1, pp. 5–8, 2000.

[41] S. A. Gerber, V. Y. Rybalko, C. E. Bigelow et al., "Preferential attachment of peritoneal tumor metastases to omental immune aggregates and possible role of a unique vascular microenvironment in metastatic survival and growth," *American Journal of Pathology*, vol. 169, no. 5, pp. 1739–1752, 2006.

Hindawi Publishing Corporation
Gastroenterology Research and Practice
Volume 2012, Article ID 981245, 5 pages
doi:10.1155/2012/981245

Clinical Study

Laparoscopic Cytoreductive Surgery and HIPEC in Patients with Limited Pseudomyxoma Peritonei of Appendiceal Origin

Jesus Esquivel and Andrew Averbach

Department of Surgical Oncology, St. Agnes Hospital, Baltimore, MD 21229, USA

Correspondence should be addressed to Jesus Esquivel, jesusesquivel@yahoo.com

Received 12 January 2012; Accepted 16 February 2012

Academic Editor: Pompiliu Piso

Introduction. Increasing numbers of patients with pseudomyxoma peritonei (PMP) of appendiceal origin are being evaluated with a low tumor burden. We explored a minimally invasive approach for this group of patients. *Materials and Methods*. We designed a protocol in which patients with a PMP diagnosis would have a diagnostic laparoscopy. If limited carcinomatosis (PCI ≤ 10) is identified, the procedure will continue laparoscopically. If extensive carcinomatosis (PCI > 10) is found, then the procedure will be converted to an open approach. *Results*. From December 2008 to December 2011, 19 patients had a complete cytoreduction and HIPEC: 18 of them (95%) were done laparoscopically and 1 of them (5%) was converted to an open procedure. Mean PCI was 4.2. Grade 3 morbidity was 0, and one patient (5%) experienced a grade 4 complication, needing a reoperation for an internal hernia. There were no mortalities. Mean length of hospital stay was 5.3 days. At a mean follow-up of 17 months (1–37) all 19 patients are alive and free of disease. *Conclusion*. This study demonstrates that cytoreductive surgery and HIPEC via the laparoscopic route is feasible and safe and should be offered to patients with limited pseudomyxoma peritonei of appendiceal origin.

1. Introduction

Cytoreductive surgery (CRS) and hyperthermic intraperitoneal chemotherapy (HIPEC) have become standard of practice in patients with pseudomyxoma peritonei [1]. The open procedure has been associated with grade III and IV morbidity and prolonged hospitalization. In addition, many patients with PMP are being referred to a peritoneal surface malignancy center as soon as they are diagnosed and not after 3 or 4 abdominal procedures as we used to see in the late 90s. Furthermore, the number of patients that are diagnosed after a laparoscopic appendectomy is on the rise as well. What to do in this particular group of patients is still a matter of debate, with half of the cytoreductive surgeons recommending a watch-and-wait approach and the other half recommending cytoreductive surgery and HIPEC. One of the problems with the watch-and-wait approach is that it generates anxiety in some patients and that the followup requires numerous CT scans. This of course exposes the patient to increasing doses of radiation. MRI is becoming a very useful tool to evaluate the abdomen and pelvis for additional mucinous implants and hopefully will help to reduce the amount of radiation exposure. An obvious disadvantage of treating every patient with PMP with a very large incision in order to rule out the presence of any residual disease is the fact that many of these patients are going to have very limited peritoneal disease. Therefore, this approach represents an opportunity to improve patient care. In this modern era of individualized medicine, reports on laparoscopic surgery for cancer patients have been published in just about every organ in the abdomen [2–4]. Prospective randomized trials have shown that there is no difference in port site and wound recurrence, no difference in distant recurrence, and no difference in survival in patients undergoing laparoscopic surgery for primary colon cancer, in fact, some of these studies show a better outcome in those having laparoscopic surgery [5].

For these reasons, and understanding that laparoscopic surgery is *not* a different surgery but rather just a different approach, our group decided to evaluate the role of laparoscopic cytoreductive surgery and HIPEC in patients with limited peritoneal dissemination. The results with the first 14 patients that included a variety of peritoneal surface

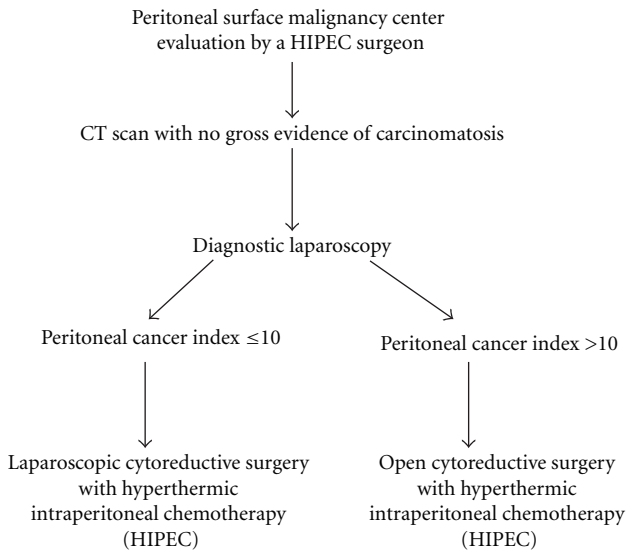

Figure 1: Clinical pathway for the laparoscopic management of peritoneal surface malignancies.

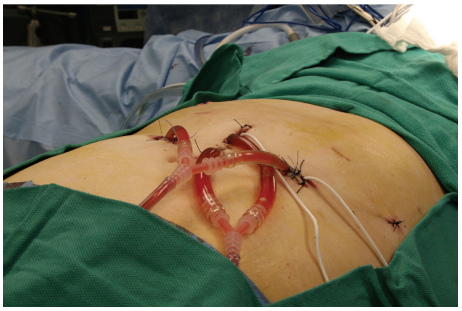

Figure 2: Laparoscopic hyperthermic intraperitoneal chemotherapy (HIPEC).

malignancies look very promising and have been previously published [6]. The purpose of this paper is to report our continued experience from this protocol in patients with pseudomyxoma peritonei of appendiceal origin, also referred to as low-grade mucinous carcinoma peritonei (L-MCP) or disseminated peritoneal adenomucinosis (DPAM).

2. Materials and Methods

Patients with a histological diagnosis of low-grade, mucinous carcinoma peritonei of appendiceal origin and no gross evidence of carcinomatosis on the CT scan were subjected to a diagnostic laparoscopy to determine the peritoneal cancer index. During laparoscopy, if low-volume carcinomatosis is identified, defined as a Peritoneal Cancer Index (PCI) ≤ 10, the oncological procedure will be continued laparoscopically. If at the time of the diagnostic laparoscopy high-volume carcinomatosis is identified, defined as a PCI > 10, the procedure will be converted to the standard open approach. The protocol (RPN 2008-020) was approved by our Institutional Review Board (Figure 1).

The operative team consisted of a very experienced laparoscopic surgeon (A. Averbach) who normally performs more than 150 complex laparoscopic bariatric operations a year and a cytoreductive surgeon (J. Esquivel). The procedures were performed in an integrated minimally invasive operating room with STORZ high-definition laparoscopic equipment. The peritoneal cavity was accessed in the right-upper quadrant with a direct view 12 mm Visiport with a 0 degree laparoscope. Once the pneumoperitoneum was established, two additional 12 mm trocars were placed in the periumbilical and left-upper quadrants under direct visualization. Two 5 mm trocars were placed below the right and left costal margins. Occasionally, a sixth trocar (5 mm) was placed in the midline above the symphysis pubis to facilitate upper abdomen dissections. Lysis of adhesions was performed to free all intra-abdominal structures, and a detailed exploration of both parietal and visceral peritoneum was carried out in order to determine the laparoscopic Peritoneal Cancer Index (PCI). This was facilitated by instrument retraction and positioning the operating room table for gravity-assisted retraction in order to maximize exposure of dependent areas. Once the diagnostic laparoscopy was completed, a decision to continue with the cytoreduction via the laparoscopic route was made based on two factors: the PCI had to be 10 or less and the amount of disease present had to be able to be removed laparoscopically according to the senior surgeon (A. Averbach). We decided on a PCI of 10 or less as this amount of carcinomatosis is what we normally consider as low-volume carcinomatosis in all peritoneal surface malignancies. All patients underwent a greater omentectomy even if there was no evidence of macroscopic disease. The greater omentum was mobilized off the transverse colon, and its hepatic and splenic flexures were taken down for complete excision using the Harmonic scalpel (Ethicon Inc., Guaynabo, PR). The gastrosplenic ligament was severed close to the splenic hilum. Additional visceral resections and peritoneal stripping were performed as needed in order to achieve a complete cytoreduction. Bowel resections were performed with an Endo GIA 3.5/60 mm cartridge (US Surgical, Norwalk, CT) and the staple lines inverted with a running 2.0 Surgidac Endostitch (US Surgical, Norwalk, CT) when needed. The bowel mesentery was transected with the Harmonic scalpel (Ethicon Inc., Guaynabo, PR). Bilateral salpingo-oophorectomies were done with suture ligation of the origins of the Fallopian tubes and subsequent dissection with the Harmonic scalpel (Ethicon Inc., Guaynabo, PR). At the end of the laparoscopic stage of the procedure, a 6 cm periumbilical midline laparotomy was performed and the specimens were extracted. Two inflow and 2 outflow perfusion catheters were placed, and the skin at the laparotomy and port sites was closed with a running nylon stitch to avoid chemotherapy solution leakage and to expose all incisions to its action to reduce the risk of tumor cell implantation. Hyperthermic intraperitoneal chemotherapy with 40 mg of Mitomycin C for 90 minutes at 43 degrees Celsius was administered using either the Belmont (Belmont Instruments, Billerica, MA) or ThermaSolutions (Thermasolutions Inc., Pittsburgh, PA) perfusion systems (Figure 2).

Table 1: Mode of presentation in 18 patients with PMP.

Event	Number	Percentage
Ovarian mass	6	33
Abdominal Pain/CT scan	6	33
Appendicitis	3	16
Other	3	16

At the completion of the heated perfusion, gastrointestinal anastomosis was performed as indicated, the midline laparotomy incision was closed with a running looped 1.0 Maxon stitch (US Surgical, Norwalk, CT), the trocars were reinserted, and the peritoneal cavity was explored to assure lack of visceral injuries and/or bleeding sources. The 12 mm port site incisions were closed with 0 POLYSORB (US Surgical, Norwalk, CT) with a Carter-Thomason suture closing system (Cooper Surgical, Trumbull, CT). In the patient in whom the procedure was converted to an open intervention, the same principles were followed: resections were made, the chemotherapeutic perfusion was carried via the closed abdomen method, and after the perfusion the abdomen was closed with a running looped 1.0 Maxon stitch (US Surgical, Norwalk, CT). Postoperative complications were reported according to the National Cancer Institute Common Toxicity Criteria. Follow-up included a CEA and CA 19-9 every 3 months, a baseline postoperative CT scan at 4 months and then a repeat CT scan or MRI every 6 months.

3. Results

From December 2008 to December 2011, 30 patients with limited peritoneal surface malignancies were taken to the operating room for a laparoscopic cytoreductive surgery and HIPEC. Of these 30 patients, 19 patients had the diagnosis of Pseudomyxoma Peritonei of appendiceal origin and constitute the basis of this study. The most common form of presentation of their appendiceal mucinous neoplasm was an ovarian mass with nearly half of the female patients, 6 out of 14 presenting this way (Table 1). Thirteen patients were enrolled into the protocol with 8 of them previously reported in another manuscript [6]. Once the protocol was completed, we included 6 more patients done off-protocol. There were 15 females and 4 male patients. Mean age was 52 (38–74). All patients had previous surgeries. Sixty-six percent had a previous laparoscopic procedure and 33% a previous open procedure. Median time from initial surgery to cytoreduction and HIPEC was 3 months (1–22). All 19 patients had a complete cytoreduction and HIPEC; 18 (95%) were done laparoscopically and 1 (5%) was converted to an open procedure because the evaluation by the senior surgeon (A. Averbach) indicated that we would not be able to remove the disease that was present in the previous anastomosis via the laparoscopic route. This case, which was the third patient on the study, is the only patient with PMP that was converted to an open procedure, and it happened 33 months ago; since then, the following 16 cases have been completed laparoscopically. The mean PCI was 4.3 (1–10), and mean operative time was 4.2 hours (3.5–6) (Table 2). Forty-four percent of the patients required a limited peritonectomy, and 27% required a bowel resection (Table 3). Mean blood loss was 50 mL, and no patients received a blood transfusion. All patients were extubated at the end of the procedure and transferred to the postanesthesia care unit and then to the regular surgical ward. No nasogastric tubes or intra-abdominal drains were placed. Grade 3 morbidity was zero, and one patient (5%) in the laparoscopy group experienced a grade 4 complication, needing a reoperation for an internal hernia; this reoperation was also completed laparoscopically,

Table 2: Characteristics of patients with limited pseudomyxoma peritonei (L-MCP) treated with cytoreductive surgery and HIPEC.

Variable	Laparoscopic CRS and HIPEC	Laparoscopic to open CRS and HIPEC
Number of patients (n)	18	1
Mean age	50	74
Sex		
Male	4	0
Female	14	1
Previous surgery		
No	0	0
Yes	18	1
Previous chemotherapy		
No	18	1
Mean body mass index	26.2	29.1
Mean peritoneal cancer index	4.2	10
Complete cytoreduction		
Yes	18	1
Bowel resection		
No	13	1
Yes	5	0
Mean estimated blood loss	50 mL	100 mL
Mean blood transfused	0	0
Mean duration of surgery	4.2 hours	5 hours
Grade 3 complications		
No	18	1
Grade 4 complications		
No	17	1
Yes	1	0
Mean length of hospital stay	5.3 days	7 days
Mean follow-up	17 months	33 months

Table 3: Procedures performed in 18 patients undergoing laparoscopic cytoreduction.

Surgical resection	Number	Percentage
Greater omentectomy	17	94
Limited peritonectomy	8	44
Bowel resection	5	27
Salpingo-oophorectomy	2	11

Table 4: Summary of pathological findings.

Event	Number	Percentage
Extracellular mucinous deposits outside of the appendix	18	100
Epithelial cells present outside of the appendix	13	72
Omentum with grossly normal appearance	16	89
Final pathology positive	13	81
Pathology of the omentum showing extracellular mucin	10	62
Pathology of the omentum showing epithelial cells	3	18

and the patient went home 14 days after the first surgery. There were no operative deaths. Mean length of hospital stay was 5.3 days (3–14). A summary of pathological findings is included on Table 4. At a mean followup of 17 months (1–37), all patients are alive and well, with no evidence of disease recurrence.

4. Discussion

The first case report of cytoreductive surgery and HIPEC in a patient with Pseudomyxoma Peritonei (PMP) of appendiceal origin dates back to 1979 [7]. Since then, cytoreductive surgery and HIPEC have become the standard treatment for this group of patients even though there has never been a prospective randomized trial. Analysis of the published data demonstrates that a complete surgical eradication of this low-grade type of tumor is associated with the best outcome, and while the added benefit of the hyperthermic intraperitoneal chemotherapy to a complete cytoreduction continues to be a matter of debate and has never been clearly established, a trial that would compare cytoreductive surgery with or without HIPEC in patients with PMP is just not a feasible trial.

When it comes to the mode of presentation of PMP of appendiceal origin, nothing has changed too much in the last 3 decades. An ovarian mass continues to be a very common presentation in women, as well as being diagnosed after an appendectomy for appendicitis. What has changed is the amount of tumor burden. An increasing abdominal girth used to be a very common presentation [8], and now it is becoming a rather infrequent one. The treatment remains the same: cytoreductive surgery to remove all visible tumor and HIPEC to eradicate microscopic residual disease.

Recommending surgery in patients with Pseudomyxoma peritonei after their initial diagnosis has been established but now having a negative CT scan on follow-up remains a topic of discussion. There appears to be an unwritten agreement on what to do with patients that have no gross evidence of carcinomatosis but that have epithelial cells outside of the appendix. Most cytoreductive surgeons will recommend cytoreductive surgery and HIPEC. In this series, 72% of the patients had epithelial cells outside of the appendix and extracellular mucin was found in 100% of the patients.

We used to recommend a watch-and-wait followup for patients that had a perforated appendix, had a negative CT scan, and only mucin in the periappendiceal tissue. We had believe that most of these patients will not go on to develop pseudomyxoma peritonei syndrome. We were concerned with the amount of radiation exposure as a result of multiple CT scans, and for this reason now we use MRI to follow these patients. However, some of these patients do not feel comfortable with just a watch-and-wait approach, and we do not believe that a patient should have an exploratory laparotomy to document that they do not have any disease. This was the initial rationale for developing a minimally invasive approach. It is interesting that in this study, of the 16 omentums that looked normal even during the laparoscopic examination, 81% had at least mucin found during the pathological examination. Of course we do not know what would be the natural history of that finding, but it is a finding, that raises a valid concern.

Our current approach and recommendations are as follows: if the patient has a ruptured mucinous appendiceal neoplasm, has a CT scan or MRI with no gross evidence of peritoneal dissemination, and has epithelial cells in the periappendiceal tissue, we recommend a laparoscopic cytoreductive surgery that includes a greater omentectomy, a portion of the lesser omentum, a bilateral salpingo-oophorectomy in postmenopausal women or premenopausal women that do not wish to have children, and HIPEC. If the patient has a ruptured mucinous neoplasm with only mucin in the periappendiceal tissue, we recommend a peritoneal metastases protocol MRI and if that does not show any evidence of mucinous deposits, then we recommend follow-up with a routine MRI every 6 months for the first 3 years and then once a year.

It is important to emphasize that this approach needs longer followup, and as any new therapeutic approach, it should be done under the auspices of a clinical research protocol. In order to decrease the learning curve, the surgical team should include not only a cytoreductive surgeon but a surgeon that does minimally invasive surgeries on a routine basis. As mentioned before, our only conversion was 33 months ago this represented our 3rd case, and the patient that needed the reoperation was our second patient. We have learned since then that the minimally invasive nature of early Pseudomyxoma Peritonei is amenable to a minimally invasive management and treatment.

5. Conclusion

This initial investigative stage demonstrates that laparoscopic cytoreductive surgery and HIPEC in patients with limited peritoneal dissemination from Pseudomyxoma Peritonei of appendiceal origin are feasible and safe and therefore should be added to the armamentarium of treatment options for this group of patients.

References

[1] T. C. Chua, T. D. Yan, A. Saxena, and D. L. Morris, "Should the treatment of peritoneal carcinomatosis by cytoreductive

surgery and hyperthermic intraperitoneal chemotherapy still be regarded as a highly morbid procedure?: a systematic review of morbidity and mortality," *Annals of Surgery*, vol. 249, no. 6, pp. 900–907, 2009.

[2] M. L. Kendrick and D. Cusati, "Total laparoscopic pancreaticoduodenectomy feasibility and outcome in an early experience," *Archives of Surgery*, vol. 145, no. 1, pp. 19–23, 2010.

[3] A. M. Kazaryan, I. P. Marangos, A. R. Rosseland et al., "Laparoscopic liver resection for malignant and benign lesions: ten-year Norwegian single-center experience," *Archives of Surgery*, vol. 145, no. 1, pp. 34–40, 2010.

[4] K. Y. Bilimoria, D. J. Bentrem, H. Nelson et al., "Use and outcomes of Laparoscopic-assisted colectomy for cancer in the United States," *Archives of Surgery*, vol. 143, no. 9, pp. 832–840, 2008.

[5] E. Angst, J. R. Hiatt, B. Gloor, H. A. Reber, and O. J. Hines, "Laparoscopic surgery for cancer: a systematic review and a way forward," *Journal of the American College of Surgeons*, vol. 211, no. 3, pp. 412–423, 2010.

[6] J. Esquivel, A. Averbach, and T. C. Chua, "Cytoreductive surgery and hyperthermic intraperitoneal chemotherapy in patients with limited peritoneal surface malignancies: initial feasibility and safety results," *Annals of Surgery*, vol. 253, no. 4, pp. 764–768, 2011.

[7] J. S. Spratt, R. A. Adcock, and M. Muskovin, "Clinical delivery system for intraperitoneal hyperthermic chemotherapy," *Cancer Research*, vol. 40, no. 2, pp. 256–260, 1980.

[8] J. Esquivel and P. H. Sugarbaker, "Clinical Presentation of The Pseudomyxoma Peritonei Syndrome," *British Journal of Surgery*, vol. 87, pp. 1414–1418, 2000.

Hindawi Publishing Corporation
Gastroenterology Research and Practice
Volume 2012, Article ID 471205, 4 pages
doi:10.1155/2012/471205

Research Article

Pharmacokinetics of Hyperthermic Intrathoracic Chemotherapy following Pleurectomy and Decortication

Paul H. Sugarbaker,[1] O. Anthony Stuart,[1] and Christopher Eger[2]

[1] *Washington Cancer Institute, MedStar Washington Hospital Center, Washington, DC 20010, USA*
[2] *Thoracic Oncology Center, MedStar Washington Hospital Center, Washington, DC 20010, USA*

Correspondence should be addressed to Paul H. Sugarbaker, paul.sugarbaker@medstar.net

Received 3 January 2012; Accepted 22 January 2012

Academic Editor: Yutaka Yonemura

In patients with pseudomyxoma peritonei or peritoneal mesothelioma, direct extension of disease through the hemidiaphragm may result in an isolated progression of tumor within the pleural space. We monitored the intrapleural and plasma levels of mitomycin C and doxorubicin by HPLC assay in order to determine the pharmacokinetic behavior of this intracavitary use of chemotherapy. Our results showed a persistent high concentration of intrapleural drug as compared to plasma concentrations. The increased exposure for mitomycin C was 96, and the increased exposure for doxorubicin was 241. When the clearance of chemotherapy from the thoracic cavity was compared to clearance from the abdomen and pelvis, there was a considerably more rapid clearance from the abdomen as compared to the thorax. The pharmacologic study of intrapleural chemotherapy in these patients provides a strong pharmacologic rationale for regional chemotherapy in this group of patients.

1. Introduction

In a majority of patients, the instillation of chemotherapy into the pleural space is a palliative treatment designed to reduce or eliminate debilitating accumulations of peritoneal fluid. In these patients, disease outside of the pleural space precludes any reasonable attempt to definitively resect the cancer within the pleural space. An exception to this is pleural mesothelioma, where the thoracic surgeon performs a pleurectomy and decortication of the lung in an attempt to achieve long-term survival in patients with a limited extent of pleural mesothelioma. Also, some diseases may progress by direct extension through the hemidiaphragm and involve the thoracic cavity. If disease control within the abdomen can be achieved with cytoreductive surgery combined with hyperthermic intraperitoneal chemotherapy (HIPEC), definitive treatment of intrapleural progression may be of long-term benefit to the patient. Diseases where pleural extension of an intraabdominal disease has been reported include pseudomyxoma peritonei [1], peritoneal mesothelioma, and epithelial ovarian cancer. In these clinical situations, a patient must have disease control demonstrated within the abdomen and pelvis. Also, prior to the administration of intrapleural chemotherapy, a thoracic cytoreduction (pleurectomy and decortication) is performed in an attempt to remove all visible evidence of the malignant disease. In this paper, we report on the pharmacology of hyperthermic intrathoracic chemotherapy (HITOC) in patients with pseudomyxoma peritonei or peritoneal mesothelioma that had gained entrance to the chest through the hemidiaphragm. The chemotherapy agents studied are mitomycin C and doxorubicin.

2. Materials and Methods

Permission to accumulate and analyze these data was obtained from the Ethics Committee at our institution. Patients undergoing pleurectomy and decortication followed by intrapleural chemotherapy for thoracic extension of pseudomyxoma peritonei and pleural mesothelioma were studied. These patients were identified through a prospective clinical database. The clinical management of these patients was as follows. Disease control within the abdomen and pelvis was determined over a minimum six-month time interval using abdominal and pelvic CT scans. Disease within

the thoracic space was shown to progress over this time interval. After obtaining consent, the patients were taken to the operating room for a thoracotomy [2]. The extended right or left thoracotomy was accompanied by a resection of the seventh rib. First, a complete parietal peritonectomy was performed. Then, a partial visceral pleurectomy was performed, only removing pleura that was invaded by the malignant process. The visceral pleura within the pulmonary fissures was also carefully cytoreduced. Following completion of the cancer resection, the thoracic cavity was irrigated with copious warm saline solution and meticulous hemostasis obtained. The skin at the anterior and posterior extent of the thoracotomy incision was sutured shut with a running skin suture. The skin edges in the mid-portion of the chest cavity were elevated on a self-retaining retractor (Thompson Surgical Instruments, Traverse City, MI) in order to maintain a reservoir within the thoracic space. For infusion of chemotherapy solution, a Tenckhoff catheter was placed over the edge of the thoracotomy incision and secured by a suture. For drainage, a single 28 French straight thoracostomy tube was inserted through an intercostal space at the level of the hemidiaphragm posteriorly and directed up towards the apex of the chest. The chemotherapy solution was heated and repeatedly circulated by a hyperthermia pump (Belmont Instrument Corporation, Billerica, MA). Temperature of the chemotherapy solution was between 41 and 43°C within the hemithorax. During this dissection, the lung was maintained partially collapsed through the use of a double-lumen tube; the lung was allowed to inflate approximately half of its volume for the duration of the HITOC.

The patients received hyperthermic chemotherapy using mitomycin C at 15 mg/m^2, doxorubicin at 15 mg/m^2, and 5-fluorouracil at 400 mg/m^2 with leucovorin at 20 mg/m^2 given intravenously.

The concentration of mitomycin C and doxorubicin within the pleural fluid and plasma was determined at 15-minute intervals. HPLC assay was used to determine the concentration as described elsewhere [3, 4].

The carrier solution for the chemotherapy was 1.5% dextrose peritoneal dialysis solution. The chemotherapy was diluted in 2 liters of this carrier solution prior to instillation into the thoracic cavity through the Tenckhoff catheter.

All data presented on the graphs are +1 standard deviation. Calculations of area under the curve (AUC) and subsequent AUC ratios were obtained using GraphPad Prism analyses (GraphPad Software, Inc., La Jolla, CA).

For comparison of HITOC pharmacokinetics with hyperthermic intraperitoneal chemotherapy (HIPEC) pharmacokinetics, data from intraperitoneal and plasma drug concentrations in 25 consecutive patients were utilized. These patients were treated during the approximate time period as the patients receiving HITOC.

3. Results

For mitomycin C pharmacokinetics, three patients were available for study. All three patients had pseudomyxoma peritonei in the pleural space, and all three had a complete visible removal of disease at the time of thoracic cytoreduction. Two had a right thoracotomy and one had left-sided disease. Figure 1 shows the area under the curve concentration times, time for the pleural fluid and for the plasma. The area under the curve pleural fluid to plasma ratio was 96 ± 41 over the 90 minutes. During the HITOC, 41 ± 3 percent of the total mitomycin C was absorbed from the thoracic space into the body compartment.

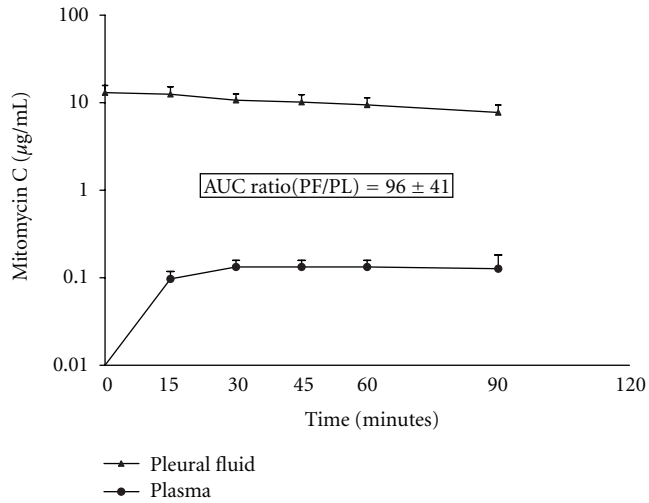

Figure 1: Pharmacokinetic study of mitomycin C instilled into the thoracic space following pleurectomy and decortication for pseudomyxoma peritonei spread by direct extension through the hemidiaphragm. The chemotherapy solution was maintained at 41–43°C by circulating the chemotherapy fluid through a hyperthermia pump.

For comparison of HITOC mitomycin C clearance with HIPEC mitomycin C clearance, we used data from 25 patients whose pseudomyxoma was confined to the abdomen and pelvis. The mitomycin C was used at 15 mg/m^2 and was diluted in 3 liters of 1.5% dextrose peritoneal dialysis solution. Temperature within the peritoneal space was 41 to 43°C. Figure 2 shows the percentage of mitomycin C absorbed from the peritoneal space as compared to the pleural space. Approximately half of the amount of mitomycin C was absorbed from the pleural space as compared to the peritoneal space.

Figure 3 shows the area under the curve for pleural doxorubicin and for plasma doxorubicin in 4 patients treated with HITOC doxorubicin at 15 mg/m^2 in 2 liters of 1.5% dextrose peritoneal dialysis solution. Two patients had pseudomyxoma peritonei and two had peritoneal mesothelioma. All patients had complete visible removal of disease at the time of thoracic cytoreduction. The area under the curve ratio was 241 ± 83.

In Figure 4, the percent of drug absorbed in 4 patients with HITOC with doxorubicin are compared to 25 patients who had HIPEC with doxorubicin. Seventy-two percent of this drug was absorbed at 90 minutes with intrapleural

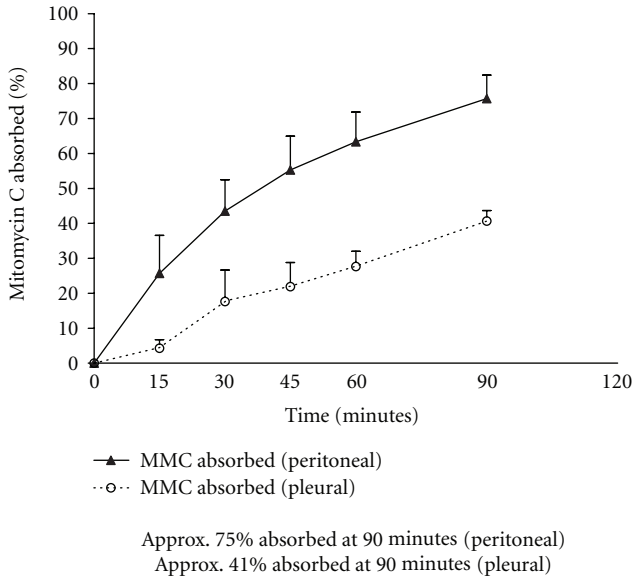

Figure 2: Percent mitomycin C absorbed from the chest cavity as compared to the peritoneal cavity following intrathoracic or intraperitoneal chemotherapy treatment. The chemotherapy solution in both groups of patients was maintained between 41 and 43°C by circulating the chemotherapy solution through a hyperthermia pump.

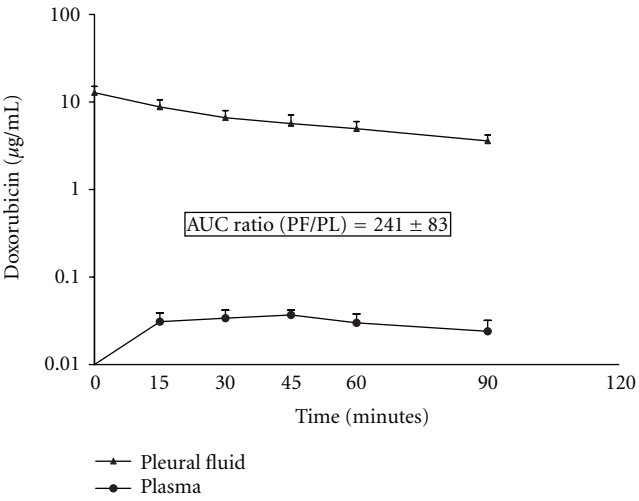

Figure 3: Pharmacokinetic study of doxorubicin in 4 patients who had drug instillation into the thoracic cavity. The chemotherapy solution was maintained between 41 and 43°C by circulation through a hyperthermia pump.

administration, and 90% was absorbed with intraperitoneal administration.

4. Discussion

Intrapleural chemotherapy continues to be well used palliatively in order to control debilitating and unrelenting pleural effusions from cancer. In this current application of intrapleural chemotherapy, the patient population was different

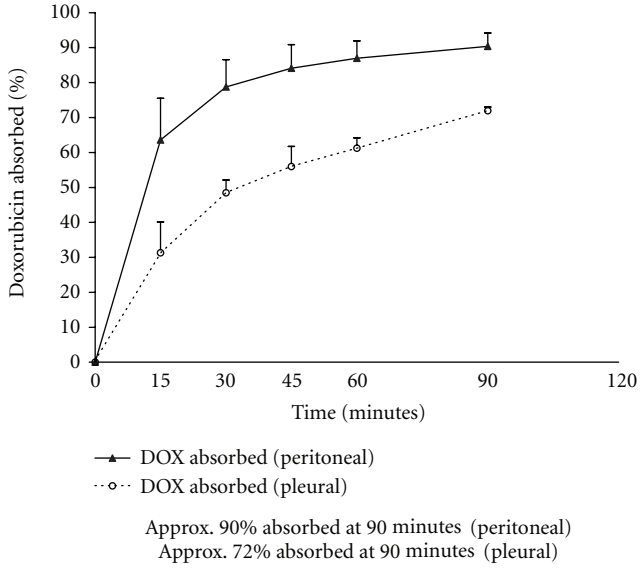

Figure 4: Percent doxorubicin absorbed from the pleural space as compared to the peritoneal cavity following intrathoracic or intraperitoneal chemotherapy treatment. The chemotherapy solution was maintained between 41 and 43°C by circulation through a hyperthermia pump.

in that no other known sites of disease were present in our patients. Therefore, the goal of the HITOC treatment was a curative one. The intrapleural chemotherapy administration was preceded by a thoracic cytoreduction of both parietal and involved visceral pleura. The goal of the cancer pleurectomy and decortication was to remove all visible evidence of disease. The role of the HITOC was to eliminate the microscopic residual disease that cannot be removed by cancer surgery. This strategy has been shown to be effective for peritoneal metastases from appendiceal malignancy, colorectal cancer, and peritoneal mesothelioma [5]. The rationale for this treatment within the chest cavity is the same as that within the peritoneal space.

4.1. Pharmacologic Advantage of Hyperthermic Intrathoracic Chemotherapy. Our data from patients treated with mitomycin C and with doxorubicin clearly show that the pharmacologic advantage of intracavitary chemotherapy exists within the thoracic space. This should result in a marked therapeutic benefit if the residual disease is of minimal extent so that the intrathoracic chemotherapy can penetrate the cancer cells. Entrance into the tissues surrounding the thoracic cavity is by simple diffusion [6]. An area under the curve ratio for mitomycin C of 96 ± 41 over the 90 minutes confirms the pharmacologic advantages of regional chemotherapy administration. Likewise, the area under the curve ratio of 241 for doxorubicin documents the same advantage.

4.2. Reduced Clearance of Intrapleural as Compared to Intraperitoneal Chemotherapy. In Figures 2 and 4, we calculated the percent of the total dose of cancer chemotherapy instilled

at time 0 that was absorbed through the chest wall or through the partially deflated lung into the body compartment. The percent absorbed in 3 patients with HITOC mitomycin C was compared to 25 patients with HIPEC mitomycin C. Approximately half of the total quantity of mitomycin C instilled escaped from the pleural cavity as compared to the peritoneal cavity. Also, there was a reduction in the percent of doxorubicin absorbed from the pleural space as compared to the peritoneal space. Approximately 80% of the amount of drug was absorbed from the pleural space as compared to the peritoneal cavity.

In the two drugs used for HITOC in which we performed HPLC assays of chemotherapy concentration, both showed a high area under the curve ratio of pleural fluid to plasma. This reduced clearance from the pleural space resulted in a higher area under the curve ratio for intrapleural mitomycin C or doxorubicin as compared to intraperitoneal mitomycin C or doxorubicin. Our previous work with mitomycin C showed that the area under the curve ratio for intraabdominal treatment was approximately 27 [3]. It was almost three times as large in this study with intrapleural mitomycin C. The area under the curve ratio for intraperitoneal doxorubicin was approximately 79 [4]. Again, it was more than three times greater with intrapleural doxorubicin administration as compared to intrapleural instillation.

4.3. Speculations Regarding the Cause of Reduced Intrapleural Chemotherapy Clearance. The Dedrick model for predicting the clearance of intracavitary chemotherapy states that the permeability of the surface combined with the total diffusion surface controls the rate at which the concentration of a drug within the body cavity tends to normalize with that in the plasma [6]. A chest wall from which the pleura has been completely removed may be less permeable to mitomycin C and doxorubicin. Also, the partially deflated lung within the chest cavity filled by chemotherapy solution will be poorly perfused. Therefore, it may transmit drug less rapidly away from the lung surface. Most probably, the perfusion of the down lung is much less than the perfusion of the viscera absorbing and transporting drug within the abdomen and pelvis. Also, the pleural space generally has a capacity between 1 and 1.5 liters of chemotherapy solution. The intraabdominal space has a 2-3 liter capacity for intraabdominal chemotherapy. This lesser volume of chemotherapy would result in a lesser total diffusion surface.

4.4. Possible Need for Further Phase I/II Studies. Upon the initiation of our clinical experience with intrapleural chemotherapy, we considered an effort to increase the concentration of the intrapleural chemotherapy above that which has been used for many years within the abdominal space. However, two findings made it, we thought, unnecessary to perform further dose escalations. First of all, the control of pseudomyxoma peritonei and peritoneal mesothelioma in the chest cavity following thoracic cytoreduction and HITOC chemotherapy has approached 100%. Unpublished data shows 30 patients treated to date with no recurrences recorded. Also important regarding dose escalation is the morbidity and mortality seen with these studies. Complications resulting from parenchymal lung disease have been noted in 3 of the 30 patients (10%). Two patients developed pulmonary aspergillosis postoperatively and both of these patients went on to die. Another patient developed interstitial pneumonitis. This did not result in her demise but was a continuing problem in her limited survival. She died as a result of progressive disease within the abdomen. As a result of our clinical experience to date, further escalation of the intrathoracic chemotherapy concentration does not seem necessary. Our early clinical experience with thoracic cytoreduction and intrathoracic chemotherapy has been reported [1].

References

[1] S. R. Pestieau, J. Esquivel, and P. H. Sugarbaker, "Pleural extension of mucinous tumor in patients with pseudomyxoma peritonei syndrome," *Annals of Surgical Oncology*, vol. 7, no. 3, pp. 199–203, 2000.

[2] N. Z. Alam, R. J. Flores, and V. W. Rusch, "Pleurectomy and decortication for malignant pleural diseases," in *Adult Chest Surgery*, D. J. Sugarbaker, R. Bueno, M. J. Krasna, S. J. Mentzer, and L. Zellos, Eds., pp. 860–867, McGraw-Hill, New York, NY, USA, 2009.

[3] K. van der Speeten, O. A. Stuart, D. Chang, H. Mahteme, and P. H. Sugarbaker, "Changes induced by surgical and clinical factors in the pharmacology of intraperitoneal mitomycin C in 145 patients with peritoneal carcinomatosis," *Cancer Chemotherapy and Pharmacology*, vol. 68, no. 1, pp. 147–156, 2011.

[4] P. H. Sugarbaker, K. van der Speeten, O. A. Stuart, and D. Chang, "Impact of surgical and clinical factors on the pharmacology of intraperitoneal doxorubicin in 145 patients with peritoneal carcinomatosis," *European Journal of Surgical Oncology*, vol. 37, no. 8, pp. 719–726, 2011.

[5] F. Roviello, S. Caruso, D. Marrelli et al., "Treatment of peritoneal carcinomatosis with cytoreductive surgery and hyperthermic intraperitoneal chemotherapy: state of the art and future developments," *Surgical Oncology*, vol. 20, no. 1, pp. e38–e54, 2011.

[6] R. L. Dedrick and M. F. Flessner, "Pharmacokinetic problems in peritoneal drug administration: tissue penetration and surface exposure," *Journal of the National Cancer Institute*, vol. 89, no. 7, pp. 480–487, 1997.