


# Coronary Artery Spasm in Patients Referred for Cardiac Catheterization

Lead Guest Editor: Ming-Yow Hung

Guest Editors: Nicholas G. Kounis, Dimitris Tousoulis, and George N. Hahalis





---

## **Coronary Artery Spasm in Patients Referred for Cardiac Catheterization**



**Coronary Artery Spasm in Patients  
Referred for Cardiac Catheterization**

Lead Guest Editor: Ming-Yow Hung

Guest Editors: Nicholas G. Kounis, Dimitris  
Tousoulis, and George N. Hahalis



Copyright © 2020 Hindawi Limited. All rights reserved.

This is a special issue published in “Journal of Interventional Cardiology.” All articles are open access articles distributed under the Creative Commons Attribution License, which permits unrestricted use, distribution, and reproduction in any medium, provided the original work is properly cited.



# Chief Editor

Patrizia Presbitero, Italy


## Academic Editors

Amr E. Abbas, USA  
Antonio Abbate, USA  
Jeremiah Brown , USA  
Fausto Castriota, Italy  
Periklis Davlourous, Greece  
Leonardo De Luca , Italy  
Salvatore De Rosa , Italy  
Seif S. El-Jack, New Zealand  
Anca Daniela Farcas , Romania  
Gopal Chandra Ghosh , India  
Cristina Giannini, Italy  
Akshay Goel , USA  
Runmin Guo, China  
William B. Hillegass , USA  
Yu-Li Huang , China  
David G. Iosseliani , Russia  
Adam Kern , Poland  
Michael C. Kim, USA  
Faisal Latif, USA  
Michael Lichtenauer , Austria  
Yuichiro Maekawa , Japan  
Benedetta Maria Motta , Italy  
Piotr Musiafek, Poland  
Toshiko Nakai , Japan  
Thach N. Nguyen , USA  
Vasileios Panoulas , United Kingdom  
Stefano Rigattieri , Italy  
Kintur Sanghvi, USA  
Celestino Sardu , Italy  
Alessandro Sciahbasi, Italy  
Fernando Scudiero , Italy  
Magnus Settergren, Sweden  
Martin J. Swaans , The Netherlands  
Jan-Peter Van Kuijk, The Netherlands  
Luigi Vignali, Italy  
Ming-Ming Wu , China  
Zhen Yang , China  
Shenghua Zhou , China

## Contents

---

### **Coronary Artery Spasm: New Insights**

Anthony Matta, Frederic Bouisset, Thibault Lhermusier, Fran Campelo-Parada, Meyer Elbaz, Didier Carrié, and Jerome Roncalli 

Review Article (10 pages), Article ID 5894586, Volume 2020 (2020)



## Review Article

# Coronary Artery Spasm: New Insights

**Anthony Matta,<sup>1,2</sup> Frederic Bouisset,<sup>1</sup> Thibault Lhermusier,<sup>1</sup> Fran Campelo-Parada,<sup>1</sup> Meyer Elbaz,<sup>1</sup> Didier Carrié,<sup>1</sup> and Jerome Roncalli<sup>1</sup>**

<sup>1</sup>Department of Cardiology, Institute CARDIOMET, CHU-Toulouse, Toulouse, France

<sup>2</sup>Faculty of Medicine, Holy Spirit University of Kaslik, Kaslik, Lebanon

Correspondence should be addressed to Jerome Roncalli; [roncalli.j@chu-toulouse.fr](mailto:roncalli.j@chu-toulouse.fr)

Received 22 November 2019; Revised 27 March 2020; Accepted 18 April 2020; Published 15 May 2020

Academic Editor: Shenghua Zhou

Copyright © 2020 Anthony Matta et al. This is an open access article distributed under the Creative Commons Attribution License, which permits unrestricted use, distribution, and reproduction in any medium, provided the original work is properly cited.

Coronary artery spasm (CAS) defined by a severe reversible diffuse or focal vasoconstriction is the most common diagnosis among INOCA (ischemia with no obstructive coronary artery disease) patients irrespective to racial, genetic, and geographic variations. However, the prevalence of CAS tends to decrease in correlation with the increasing use of medicines such as calcium channel blockers, angiotensin converting enzyme inhibitor, and statins, the controlling management of atherosclerotic risk factors, and the decreased habitude to perform a functional reactivity test in highly active cardiac catheterization centers. A wide spectrum of clinical manifestations from silent disease to sudden cardiac death was attributed to this complex entity with unclear pathophysiology. Multiple mechanisms such as the autonomic nervous system, endothelial dysfunction, chronic inflammation, oxidative stress, and smooth muscle hypercontractility are involved. Regardless of the limited benefits proffered by the newly emerged cardiac imaging modalities, the provocative test remains the cornerstone diagnostic tool for CAS. It allows to reproduce CAS and to evaluate reactivity to nitrates. Different invasive and noninvasive therapeutic approaches are approved for the management of CAS. Long-acting nondihydropyridine calcium channel blockers are recommended for first line therapy. Invasive strategies such as PCI (percutaneous coronary intervention) and CABG (coronary artery bypass graft) have shown benefits in CAS with significant atherosclerotic lesions. Combination therapies are proposed for refractory cases.

## 1. Introduction

Coronary artery spasm (CAS), which is a reversible vasoconstriction driven by a spontaneous vascular smooth muscle hypercontractility and vascular wall hypertonicity narrowing the lumen of normal or atherosclerotic coronary arteries compromising the myocardial blood flow, is recognized recently under the chapter of myocardial infarction with nonobstructive coronary arteries (MINOCA) [1, 2]. Several features were attributed to this complex ischemic entity over time passing by “A variant form of angina pectoris or variant angina” [3], “variant of the variant” [4], “coronary vasospastic angina” [5], “a false-positive STEMI” [1], and “forgotten coronary disorder” [6].

The concept of CAS was first postulated by Prinzmetal et al. by describing a nonexertional angina occurring at rest or during regular daily activities [3], which could not be

explained by an increase in myocardial oxygen demand unlike the classical angina of Heberden induced by an emotional or physical stress and relieved by exercise cessation or nitrates [7, 8]. Thus, they proposed an underlying culprit vasospasm reducing blood supply to a localized myocardial area [3] that explains the remarkable accompanied electrical changes such as transient ST segment elevation or depression in the corresponding leads [9, 10].

Recently, the coronary artery spasm hypothesis was confirmed and demonstrated in several experimental studies, especially after the introduction of either the provocative test that induces vasospasm [6, 11] or coronary angiography that illustrates spasm on the epicardial coronary artery in patients with vasospastic angina [4, 12, 13]. As a result, CAS acquired an essential contributing role in ischemic heart disease pathophysiology. This article is an update review of CAS, highlighting the unfamiliar

subclinical entity known as “Kounis syndrome” and the latest development in the diagnostic modalities such as CMRI, IVUS, and OCT.

## 2. Epidemiology

CAS prevalence varies widely among races and between countries, but it remains the main cause of ischemic heart disease with nonobstructive coronary lesions [14]. It was estimated at 50% in patients presenting with angina and 57% in whom presenting with ACS [15–17]. In fact, CAS is more common in males than females [5, 18], individuals aged between 40 and 70 years [5, 18], and more in Japanese (24.3%) followed by Taiwanese (19.3%) and Caucasian (7.5%) populations [19]. The widespread use of calcium channel blockers, statins, angiotensin II receptor blockers, and converting enzyme inhibitors, smoking awareness campaigns, and declining tendency of physicians to carry out coronary vasoreactivity tests contribute to a reduction in CAS prevalence, particularly in Japan [20, 21].

## 3. Clinical Features

**3.1. Symptoms and EKG.** The length of the CAS episode is important in terms of the large variance of clinical manifestations from the asymptomatic event to the different aspects of ACS (unstable angina, NSTEMI, and STEMI) and sudden cardiac death [22–25]. Nonetheless, silent ischemia often found with a short episode of CAS is twice as prevalent as angina pectoris and chest pain, which is considered to be the most common feature related to CAS [20]. Therefore, a prolonged CAS accelerates the progression of atherosclerosis and triggers thrombus formation by platelets activation [14, 26]. Unlike vasovagal symptoms such as nausea, vomiting, and cold sweat, the circadian variability characteristic for CAS occurs regularly at rest and early in the morning between midnight and 5 a.m. and especially while performing light exercises [27, 28]. This is thought to be the result of the autonomous nervous system involvement in the pathophysiology of CAS [21, 29]. Furthermore, transient elevation of the ST segment occurs less often than the depression of the ST segment usually accompanying a spasm of a small coronary artery, a nondiffuse or nonsevere spasm of major coronary artery, and a spasm of major occluded coronary artery supplied by collaterals, which resume the main electrocardiographic modifications revealing CAS [9, 10, 30]. Also, various types of ventricular and supra-ventricular arrhythmias could be observed [20].

**3.2. Kounis Syndrome.** Kounis syndrome is an unfamiliar form of CAS appearing in a specific situation characterized by the simultaneous occurrence of ACS and hypersensitivity reaction. It is known as “allergic angina” or “allergic myocardial infarction” [31]. CAS constitutes the core component of the physiopathology of different forms of Kounis syndrome, particularly type 1 and 2, which are differentiated according to coronary angiography. Type 1 is a pure spasm involving a normal coronary artery, while type 2 is a spasm occurring on an atherosclerotic coronary artery

causing plaque rupture. Variant inflammatory mediators such as histamines and leukotrienes massively secreted in the peripheral circulation during hypersensitivity reaction trigger CAS via their effects on the smooth muscle of coronary vessels [32]. Since Kounis syndrome is little known among physicians, we draw attention to this clinical form of CAS through this review knowing that an early appropriate approach is ultimately needed to avoid progression to a critical clinical situation [33].

## 4. Risk Factors and Precipitating Factors

**4.1. Risk Factors.** The main risk factors for CAS are age, smoking, hypertension, LDL-cholesterol, diabetes mellitus, and Hs-CRP [34–36]. Moreover, smoking has a great impact on CAS in male gender [18, 35], younger subjects [37], and Japanese population [38] as opposed to female gender, older individuals, and Caucasian population. The coexistence of several risk factors strengthens their effects to induce CAS, which may on itself sustain CAS leading to a vicious circle [23, 28]. However, diabetes mellitus is more potent in triggering CAS for women with lower Hs-CRP compared to those with higher levels of Hs-CRP [35, 39–41].

**4.2. Precipitating Factors.** A long-term mental stress [42], a light exercise especially in the early morning [28], cold exposure [43], hyperventilation [44, 45], magnesium deficiency [46], valsalva maneuver [44, 45], alcohol consumption [47], cocaine use [48], pharmacological sympathomimetic or parasympathomimetic or beta blocking or anticholinesterase agents [28], phentermine consumption [6], and platelets activation via vasoconstriction agents (thromboxane and serotonin) [49, 50] can precipitate CAS. As well, an alcohol ingestion following a stressful event can induce CAS within several hours [51, 52].

## 5. Pathophysiology

The exact pathophysiology of CAS is not clearly understood. However, CAS phenomenon is multifactorial implicating the autonomic nervous system, endothelial dysfunction, inflammation, oxidative stress, smooth muscle hyperreactivity, atherosclerosis, thrombosis, and genetic predisposition (Table 1).

**5.1. Autonomic Nervous System.** The complex relation between CAS and the autonomic nervous system is illustrated via the contribution of its two components: the sympathetic and the parasympathetic nervous system [19]. The role of the parasympathetic nervous system is supported by the frequent occurrence of CAS at midnight or at rest correlating with the highest vagal activity [53, 54] and by the ability of acetylcholine to induce CAS [55]. As such, the increased levels of catecholamines following an ischemic episode of CAS [56] and the occurrence of CAS at night during the rapid eye movement phase of sleep are marked by a reduction of vagal tone and increased adrenergic activity, enhancing the contribution of the sympathetic nervous



TABLE 1: Pathophysiologic mechanisms.

Main pathophysiologic mechanisms in CAS
Autonomic nervous system
Endothelial dysfunction
Chronic inflammation
Oxidative stress
Smooth muscle hypercontractility
Atherosclerosis and thrombosis
Genetics

CAS: coronary artery spasm.

system [57]. In fact, alpha blockers are not effective in controlling CAS symptoms [58]. On the other hand, non-selective beta-1 adrenoreceptor blockers such as propranolol promote CAS as opposed to selective blockers such as atenolol [59, 60].

**5.2. Endothelial Dysfunction.** The nitric oxide (NO) produced by a normal functional endothelium enhances vasodilatation via suppressing the release of vasoconstrictors agents such as angiotensin II and endothelin I [61, 62]. Therefore, the deficiency in NO due to dysfunctional endothelial nitric oxide synthase explains the fact that different endothelium-dependent vasodilators such as ergonovine, histamine, acetylcholine, and serotonin, which are supposed to induce coronary vasodilatation, provoke vasoconstriction in patients with CAS [63, 64]. Also, it explains the high sensitivity of vasospastic angina to nitrate, an independent-endothelium vasodilator [65]. Meanwhile, endothelial dysfunction that may predispose to CAS is not present in all cases.

**5.3. Chronic Inflammation.** The relationship between inflammation and CAS was first described by Lewis et al. in a case report of variant angina and pericarditis [66]. An increased level of Hs-CRP, monocyte and WBC counts, interleukin-6, and adhesion proteins found in CAS patients are the culprits contributing the inflammatory mechanism [39, 67]. This correlation was observed; for example, the administration of interleukin-B triggers CAS [68]. In addition, chronic smoking is associated with chronic inflammation, which is the main risk factor for CAS [69]. Recently published studies suggest the inflammatory enrollment of the coronary vascular adventitia and adipose tissue [70].

**5.4. Oxidative Stress.** Oxygen free radicals stimulate vasoconstriction and endothelial damage via degrading nitric oxide released by endothelial cells [71]. The increased level of thioredoxin, a marker for oxygen reactive agents [72], in combination with reduced level of antioxidants such as vitamins C and E [73] support the role played by oxidative stress in CAS addressing the direct contribution of endothelial dysfunction in coronary spastic angina [74].

**5.5. Smooth Muscle Hypercontractility.** Phosphorylation and dephosphorylation of the myosin light chain (MLC) regulate

coronary smooth muscle reactivity [75, 76]. In CAS, the increased activity of Rho-kinase sensitizes vascular smooth cells to  $\text{Ca}^{2+}$  enhancing MLC phosphorylation, which promote vasoconstriction [75]. Similarly, multiple pathways are involved in coronary smooth muscle cell hypercontractility such as nitric oxide [77], phospholipase C [78], and  $\text{K}_{\text{ATP}}$  channels [79, 80].

**5.6. Atherosclerosis and Thrombosis.** CAS and atherosclerosis are two distinct clinical entities that share common risk factors such as male gender, smoking, elevated Hs-CRP, dyslipidemia, and diabetes mellitus [34, 81]. Both entities may coexist, and the progression of either one influences the evolution of the other [23, 28]. In recent studies, it is shown that stent angioplasty for coronary lesions does not affect the recurrence of CAS that may happen in the distal parts of lesions [82–84]. In comparison with atherosclerosis, the prevalence of CAS tends to decrease with age. [20]. It is also well known that a prolonged CAS triggers thrombus formation through platelet activation [85] and mediator secretions such as fibrinopeptide A, which increases following a CAS event [86, 87].

**5.7. Genetics.** Genetic polymorphisms or mutations coding for angiotensin converting enzyme [88], paraoxonase I [89], adrenergic receptors [90], inflammatory mediators [78, 91], endothelial nitric oxide synthase [92, 93], and serotonergic receptors [94] play a role in the pathogenesis of CAS. Studies identified some susceptible genes such as those coding for NADH/NADPH oxidase in male gender [95], interleukin-6 and stromelysin-1 in female gender [95], e-NOS in Caucasian and mostly in Asian populations [92], and ALDH (aldehyde dehydrogenase) activity [96]. ALDH2 deficiency, most common in the East Asian population, is strongly associated with CAS [97], with an increased effect due to the coexistence of smoking and/or alcohol [98, 99]. Furthermore, a strong association between ischemic heart disease and ALDH2 was found to be a powerful indicator of myocardial ischemic attacks [100, 101] and as a predictor for lower sensitivity to nitrate administration [102]. Eventually, in gene polymorphisms or mutations, we consider an environmental impact while no role has been identified for a family history.

**5.8. Microvascular Dysfunction.** The contributing role of microvascular dysfunction in the pathophysiology of INOCA is a current trend in cardiology. Female gender, low BMI (body mass index), decreased adenosine triphosphate-induced coronary flow reserve (ATP-CFR), borderline diastolic to systolic velocity ratio (DSVR), and minor ischemic ECG findings at rest are the identified predictors for microvascular CAS [103]. Microvascular dysfunction is characterized by a reduction in microvascular wall response to vasodilators in conjunction with hyperreactivity to vasoconstrictors. Furthermore, a significant coexistence of endothelial dysfunction in the systemic peripheral arterioles

and in the coronary microcirculation was demonstrated in vasospastic angina [2].

## 6. Diagnosis

The most reliable method for diagnosing CAS is the provocation test adjunctive to coronary angiography [104] with several vascular lumen reduction thresholds set at more than 50% [104], 70% [105], 75% [106], and 90% [5] or any luminal reduction associated to angina and/or ischemic electrocardiographic modifications [28]. Functional tests including intracoronary injection of ergonovine or acetylcholine are most commonly used [104] while intravenous administration was abandoned due to serious side effects [107–109]. Figure 1 shows a positive and reversible provocative test with subocclusion of the LAD. Intracoronary provocative testing can also lead to complications, especially when performed in multiple vessels, including angina, dyspnea, vomiting, and arrhythmias [28, 110]. It should not be performed in pregnant women and in patients with severe hypertension, significant left main stenosis, advanced heart failure, and severe aortic stenosis [104]. A false negative result is possible in case of low disease activity [111]. In addition, the vascular reactivity to nitroglycerin administration is tested by spasm provocation testing. Ohba et al. diagnosed microvascular CAS through detecting an increase in lactate production level in coronary circulation and a simultaneous decrease in coronary blood flow [103]. These measures were conducted on patients presenting for angina with no obstructive coronary artery disease in whom the intracoronary acetylcholine provocative test failed to show angiographic epicardial coronary spasm.

Current modalities of coronary imaging detect CAS-specific findings. For example, intravascular ultrasound study (IVUS) provides clues to differentiate vasospastic angina from nonvasospastic angina. It identifies a small lesion site plaque volume and burden and a diffuse coronary intimal thickening reflecting intimal hyperplasia in vasospastic angina [112] as well as different plaque components appearing as a hypoechoic, less-calcified, and fibrous-dominant plaque [113–115]. Therefore, IVUS studies contribute to understand the pathophysiology of CAS. IVUS detects the presence of occult atherosclerotic lesions at the site of focal coronary artery spasm even in the lack of angiographic disease [113–115]. This finding confirms the hypothesis that CAS is caused by local hypercontractility to vasoconstrictor stimulus on minimal atherosclerotic disease. Nevertheless, optical coherence tomography (OCT) delineates structural changes of coronary arteries in patients with CAS. In spastic coronaries, we find a reduced medial thickness reactivity and an increased medial area and thickness in comparison with normal coronaries [116]. Also, some relevant findings are revealed by OCT such as the presence of erosion at the coronary spasm site in one-third of cases and the presence of luminal irregularities in two-thirds of cases, suggesting the role of antiplatelet therapy in vasospastic angina [117].

Currently, cardiac magnetic resonance imaging (CMRI) is the gold standard, as it is safe and noninvasive for

assessing MINOCA patients [118], but its role remains controversial in vasospastic angina [119]. Recent studies suggest, however, that a reduced myocardial blood flow or asynchronism in myocardial perfusion outlined by CMRI indicates CAS. The advantage of performing CMRI in MINOCA patients is eliminating other potential differential diagnoses such as takotsubo and myocarditis and then favoring a CAS attack [120, 121].

## 7. Treatment

Sublingual nitrate remains the main treatment to relieve acute attacks of CAS [122]. Smoking cessation, controlling risk factors, and avoiding precipitating factors are recommended to prevent CAS recurrences, especially in atherosclerotic cases [36]. The first therapeutic approach is based on long-acting calcium channel blockers (CCBs) preferably taken at night due to circadian variability of CAS [123, 124]. Benidipine had shown a better prognostic profile compared with other CCBs [125]. However, a near-complete reduction in CAS recurrence is observed with nondihydropyridine CCBs (e.g., diltiazem and verapamil) rather than dihydropyridine CCB [125]. Blocking calcium flow into the coronary artery smooth muscle and stimulating nitrate production to NO result in vascular vasodilation. No significant difference is demonstrated between the usage of CCBs or nitrate on reducing CAS recurrence [126]. The combination of dihydropyridine and nondihydropyridine CCBs may be used for severe symptoms [19]. Besides, CCBs act on potential CAS complications such as atrioventricular block representing an independent survival predictor [127]. Unless it is effective, regular use of nitrates is not recommended due to drug-related issues [128, 129]. Nicorandil, a potassium and nitrate channel activator, is recommended in CAS refractory to CCBs and nitrate [130]. It is worth mentioning that beta-blockers exacerbate CAS by enhancing a vasoconstrictive response [59] except for nebivolol which differs from other beta-blockers by its high beta-1 selectivity and its ability to produce NO promoting vasodilation [125]. Overall, studies have documented a positive role of statins in suppressing the CAS episode and decreasing the risk of recurrence via improving endothelial function [131, 132]. Also, the administration of magnesium and antioxidants such as vitamins C and E is helpful in the management of CAS [133, 134]. Aspirin has a controversial role: small doses result in vasodilation via inhibiting thromboxane A2, while large doses result in vasoconstriction via blocking prostacyclin production [135].

Several invasive approaches to drug refractory CAS were proposed. The feasibility and success rates of the coronary artery bypass graft are considered according to the underlying characteristics of CAS, as a focal, nondiffused atherosclerotic site of CAS is an essential determinant [136]. On the other hand, stent angioplasty is only recommended in patients with CAS and significant stenosis because the efficacy of coronary stenting to prevent vasospastic angina remains unclear in patients with nonobstructive lesions acknowledging that the recurrence of CAS to the stenting site was observed distally after intervention [137–140].

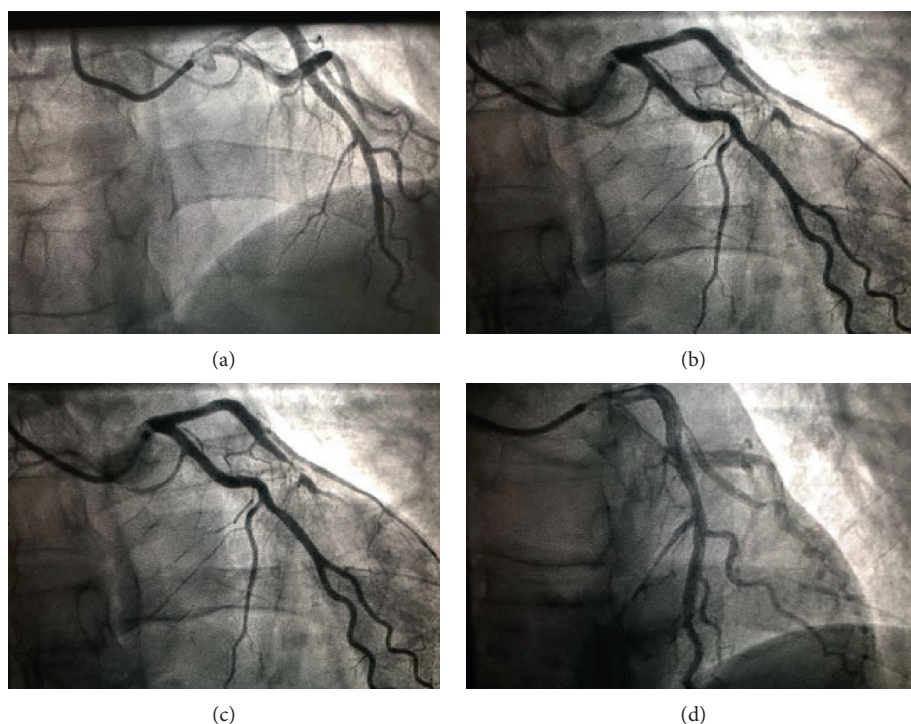


FIGURE 1: (a) Fluoroscopy showing a nonsignificant atheromatous lesion in the middle part of LAD in a 42-year-old patient with a familial history of sudden cardiac death. (b) Left coronary angiogram showing a subocclusive focal LAD coronary spasm after the methergin test. (c) Fluoroscopy showing an improved coronary blood flow after intracoronary nitrate injection. (d) Left coronary angiogram showing LAD returned to the basal blood flow. LAD : left anterior descending coronary artery.

Finally, the indication for sympathectomy or implantable cardiac defibrillator was limited to life-threatening situations defined by cardiac arrest survivors and episodes of ventricular arrhythmia [141–143]. Despite that CAS can lead to lethal arrhythmias, ICD indication remains unclear and is based on each case situation on top of physician experience. To date, there are no recommendations for ICD implantation in primary prevention for CAS patients. In secondary prevention, current evidence shows a beneficial role of ICD in aborted sudden cardiac death CAS patients regardless of the optimal medical therapy [125]. Some report an appropriate ICD shock recorded in one-fourth of patients with failed sudden death, suggesting to use the result of the provocative pharmacological test performed under optimal medical therapy in resuscitated CAS patients as a determinant parameter for secondary ICD implantation [126]. Sympathetic denervation remains a promising therapeutic approach for severe refractory CAS. Only few cases with dramatic good outcome are reported in literature [144, 145].

## 8. Prognosis

The first 3 months following the CAS attack is the critical period with highest risk for cardiovascular events [146]. Smoking cessation and CCB therapy are the most determinant prognostic factors [147]. There is no clear evidence defining the appropriate duration to continue CCBs. Cardiac death occurs between 0 and 10% among patient with CAS [148, 149], and recurrent vasospastic angina was observed in

3.9 up to 18.6% [150, 151]. CAS in Japanese population is associated with better outcome than western population [151]. Advanced age, elevated Hs-CRP, multivessel spasm, significant atheromatous lesion, and reduced ejection fraction are poor prognostic predictors [151]. An increased rate of lethal arrhythmia and sudden cardiac death is detected [152]. Risk and prognostic stratification scores are elaborated by the Japanese Coronary Spasm Association in order to assess CAS patients [152].

## 9. Conclusion

CAS is a complex multifactorial disease that can lead to serious complications. A wide clinical spectrum is attributed, and sudden cardiac death may well be the uncovering event. As a result, an early recognition and appropriate medical approach is primordial. The prevalence of CAS tends to decrease with wide spread use of ACE inhibitors and statins and diminished performance of spasm provocation tests which are considered time consuming in highly active cardiac centers.

Although CMRI plays a key role in the differential diagnosis of MINOCA, further studies are needed to emphasize CMRI's utility in CAS diagnosis.

## Conflicts of Interest

The authors declare that they have no conflicts of interest.



## References

- [1] S. Pasupathy, R. Tavella, and J. F. Beltrame, "Myocardial infarction with nonobstructive coronary arteries (MINOCA)," *Circulation*, vol. 135, no. 16, pp. 1490–1493, 2017.
- [2] T. J. Ford, P. Rocchiccioli, R. Good et al., "Systemic microvascular dysfunction in microvascular and vasospastic angina," *European Heart Journal*, vol. 39, no. 46, pp. 4086–4097, 2018.
- [3] M. Kennamer, R. Merliss, R. Wada, T. Bor, and N. au, "Angina pectoris I. A variant form of angina pectoris," *The American Journal of Medicine*, vol. 27, no. 3, pp. 375–388, 1959.
- [4] T. O. Cheng, T. Bashour, G. A. Kelser Jr., L. Weiss, and J. Bacos, "Variant angina of Prinzmetal with normal coronary arteriograms," *Circulation*, vol. 47, no. 3, pp. 476–485, 1973.
- [5] JCS Joint Working Group, "Japanese Circulation Society of guidelines for diagnosis and treatment of patients with vasospastic angina (coronary spastic angina) (JCS 2008): digest version," *Circulation Journal*, vol. 74, pp. 1745–1762, 2010.
- [6] K. B. Franke and P. J. Psaltis, "Coronary vasospasm induced by phentermine," *Mayo Clinic Proceedings*, vol. 94, no. 7, pp. 1138–1140, 2019.
- [7] W. Heberden, "Some account of a disorder of the breast," *Medical Transactions*, vol. 2, pp. 59–67, 1772.
- [8] R. N. Macalpin, A. A. Kattus, and A. B. Alvaro, "Angina pectoris at rest with preservation of exercise capacity," *Circulation*, vol. 47, no. 5, pp. 946–958, 1973.
- [9] H. Nakagawa, Y. Morikawa, Y. Mizuno et al., "Coronary spasm preferentially occurs at branch points," *Circulation: Cardiovascular Interventions*, vol. 2, no. 2, pp. 97–104, 2009.
- [10] C.-W. Cheng, N.-I. Yang, W.-J. Cherng, M.-J. Hung, and K.-J. Lin, "Role of coronary spasm for a positive noninvasive stress test result in angina pectoris patients without hemodynamically significant coronary artery disease," *The American Journal of the Medical Sciences*, vol. 335, no. 5, pp. 354–362, 2008.
- [11] M. Endo, K. Hirokawa, N. Kaneko, Y. Hase, Y. Konno, and S. au, "Prinzmetal's variant angina," *New England Journal of Medicine*, vol. 294, no. 5, pp. 252–255, 1976.
- [12] H. Yasue, M. Touyama, H. Kato, S. Tanaka, and F. Akiyama, "Prinzmetal's variant form of angina as a manifestation of alpha-adrenergic receptor-mediated coronary artery spasm: documentation by coronary arteriography," *American Heart Journal*, vol. 91, no. 2, pp. 148–155, 1976.
- [13] P. B. Oliva, D. E. Potts, and R. G. Pluss, "Coronary arterial spasm in Prinzmetal angina," *New England Journal of Medicine*, vol. 288, no. 15, pp. 745–751, 1973.
- [14] V. Ioannis, K. Konstantinos, S. Antonios, and B. Ioannis, "Acute coronary syndrome with normal coronary arteries: a case of spontaneous spasm lysis," *Medical Archives*, vol. 72, no. 2, pp. 154–156, 2018.
- [15] M.-J. Hung, W.-J. Cherng, C.-W. Cheng, and L.-F. Li, "Comparison of serum levels of inflammatory markers in patients with coronary vasospasm without significant fixed coronary artery disease versus patients with stable angina pectoris and acute coronary syndromes with significant fixed coronary artery disease," *The American Journal of Cardiology*, vol. 97, no. 10, pp. 1429–1434, 2006.
- [16] M.-J. Hung, C.-W. Cheng, N.-I. Yang, M.-Y. Hung, and W.-J. Cherng, "Coronary vasospasm-induced acute coronary syndrome complicated by life-threatening cardiac arrhythmias in patients without hemodynamically significant coronary artery disease," *International Journal of Cardiology*, vol. 117, no. 1, pp. 37–44, 2007.
- [17] P. Ong, A. Athanasiadis, S. Hill, H. Vogelsberg, M. Voehringer, and U. Sechtem, "Coronary artery spasm as a frequent cause of acute coronary syndrome," *Journal of the American College of Cardiology*, vol. 52, no. 7, pp. 523–527, 2008.
- [18] M.-Y. Hung, K.-H. Hsu, M.-J. Hung, C.-W. Cheng, and W.-J. Cherng, "Interactions among gender, age, hypertension and C-reactive protein in coronary vasospasm," *European Journal of Clinical Investigation*, vol. 40, no. 12, pp. 1094–1103, 2010.
- [19] M.-J. Hung, P. Hu, and M.-Y. Hung, "Coronary artery spasm: review and update," *International Journal of Medical Sciences*, vol. 11, no. 11, pp. 1161–1171, 2014.
- [20] H. Yasue, Y. Mizuno, and E. Harada, "Coronary artery spasm clinical features, pathogenesis and treatment," *Proceedings of the Japan Academy, Series B*, vol. 95, no. 2, pp. 53–66, 2019.
- [21] O. M. Demir, J. Hudson, and W. Wallis, "Current concepts in coronary artery spasm," *European Medical Journal Cardiology*, vol. 4, no. 1, pp. 96–102, 2006.
- [22] A. Maesri, A. L'Abbate, G. Baroldi et al., "Coronary vasospasm as a possible cause of myocardial infarction. A conclusion derived from the study of 'preinfarction' angina," *New England Journal of Medicine*, vol. 299, pp. 1271–1277, 1978.
- [23] H. Yasue and K. Kugiyama, "Coronary spasm: clinical features and pathogenesis," *Internal Medicine*, vol. 36, no. 11, pp. 760–765, 1997.
- [24] M. Nakamura, A. Takeshita, and Y. Nose, "Clinical characteristics associated with myocardial infarction, arrhythmias, and sudden death in patients with vasospastic angina," *Circulation*, vol. 75, no. 6, pp. 1110–1116, 1987.
- [25] A. Maseri, S. Severi, M. d. Nes et al., "'Variant' angina: one aspect of a continuous spectrum of vasospastic myocardial ischemia," *The American Journal of Cardiology*, vol. 42, no. 6, pp. 1019–1035, 1978.
- [26] B. Ibáñez, S. James, S. Agewall et al., "2017 ESC Guidelines for the management of acute myocardial infarction in patients presenting with ST-segment elevation," *Revista Española de Cardiología (English Edition)*, vol. 70, no. 12, pp. 1082–1095, 2017.
- [27] Y. Kusama, E. Kodani, A. Nakagomi et al., "Variant angina and coronary artery spasm: the clinical spectrum, pathophysiology, and management," *Journal of Nippon Medical School*, vol. 78, no. 1, pp. 4–12, 2011.
- [28] H. Yasue, H. Nakagawa, T. Itoh, E. Harada, and Y. Mizuno, "Coronary artery spasm—Clinical features, diagnosis, pathogenesis, and treatment," *Journal of Cardiology*, vol. 51, no. 1, pp. 2–17, 2008.
- [29] M. Jougasaki, H. Yasue, and K. Takahashi, "Perivascular nerve lesion of the coronary artery involved in spasm in a patient with variant angina," *Pathology*, vol. 21, no. 4, pp. 304–307, 1989.
- [30] H. Yasue, S. Omote, A. Takizawa et al., "Comparison of coronary arteriographic findings during angina pectoris associated with S-T elevation or depression," *The American Journal of Cardiology*, vol. 47, no. 3, pp. 539–546, 1981.
- [31] N. G. Kounis and G. M. Zavras, "Histamine-induced coronary artery spasm: the concept of allergic angina," *The British Journal of Clinical Practice*, vol. 45, no. 45, pp. 121–128, 1991.

- [32] C. Cevika, K. Nugenta, G. P. Shomea, and N. G. Kounis, "Review treatment of kounis syndrom," *International Journal of Cardiology*, vol. 143, pp. 233–236, 2010.
- [33] N. G. Kounis, "Kounis syndrome (allergic angina and allergic myocardial infarction): a natural paradigm?" *International Journal of Cardiology*, vol. 110, no. 1, pp. 7–14, 2006.
- [34] P. Libby, K. E. Bornfeldt, and A. R. Tall, "Atherosclerosis," *Circulation Research*, vol. 118, no. 4, pp. 531–534, 2016.
- [35] M. J. Hung, K. H. Hsu, W. S. Hu, N. C. Chang, and M. Y. Hung, "C-reactive protein for predicting prognosis and its gender-specific associations with diabetes mellitus and hypertension in the development of coronary artery spasm," *Plos One*, vol. 8, Article ID e77655, 2013.
- [36] K. Takaoka, M. Yoshimura, H. Ogawa et al., "Comparison of the risk factors for coronary artery spasm with those for organic stenosis in a Japanese population: role of cigarette smoking," *International Journal of Cardiology*, vol. 72, no. 2, pp. 121–126, 2000.
- [37] M.-Y. Hung, M.-J. Hung, K.-H. Hsu, C.-W. Cheng, L.-T. Kuo, and W.-J. Cherng, "Interaction between cigarette smoking and high-sensitivity C-reactive protein in the development of coronary vasospasm in patients without hemodynamically significant coronary artery disease," *The American Journal of the Medical Sciences*, vol. 338, no. 6, pp. 440–446, 2009.
- [38] C. Pristipino, J. F. Beltrame, M. L. Finocchiaro et al., "Major racial differences in coronary constrictor response between Japanese and Caucasians with recent myocardial infarction," *Circulation*, vol. 101, no. 10, pp. 1102–1108, 2000.
- [39] T. Itoh, Y. Mizuno, E. Harada, M. Yoshimura, H. Ogawa, and H. Yasue, "Coronary spasm is associated with chronic low-grade inflammation," *Circulation Journal*, vol. 71, no. 7, pp. 1074–1078, 2007.
- [40] J. Roeters van Lennep, H. T. Westerveld, D. W. Erkelens, and E. E. Van der wall, "Risk factors for coronary heart disease: implications of gender," *Cardiovascular Research*, vol. 53, no. 3, pp. 538–549, 2002.
- [41] S. Yusuf, S. Hawken, S. Ôunpuu et al., "Effect of potentially modifiable risk factors associated with myocardial infarction in 52 countries (the INTERHEART study): case-control study," *The Lancet*, vol. 364, no. 9438, pp. 937–952, 2004.
- [42] A. C. Yeung, V. I. Vekshtein, D. S. Krantz et al., "The effect of atherosclerosis on the vasomotor response of coronary arteries to mental stress," *New England Journal of Medicine*, vol. 325, no. 22, pp. 1551–1556, 1991.
- [43] A. E. Raizner, R. A. Chahine, T. Ishimori et al., "Provocation of coronary artery spasm by the cold pressor test. Hemodynamic, arteriographic and quantitative angiographic observations," *Circulation*, vol. 62, no. 5, pp. 925–932, 1980.
- [44] K. Nakao, M. Ohgushi, M. Yoshimura et al., "Hyperventilation as a specific test for diagnosis of coronary artery spasm," *The American Journal of Cardiology*, vol. 80, no. 5, pp. 545–549, 1997.
- [45] H. Miyagi, H. Yasue, K. Okumura, H. Ogawa, K. Goto, and S. Oshima, "Effect of magnesium on anginal attack induced by hyperventilation in patients with variant angina," *Circulation*, vol. 79, no. 3, pp. 597–602, 1989.
- [46] K. Goto, H. Yasue, K. Okumura et al., "Magnesium deficiency detected by intravenous loading test in variant angina pectoris," *The American Journal of Cardiology*, vol. 65, no. 11, pp. 709–712, 1990.
- [47] D. Fernandez, J. E. Rosenthal, L. S. Cohen, G. Hammond, and S. Wolfson, "Alcohol-induced Prinzmetal variant angina," *The American Journal of Cardiology*, vol. 32, no. 2, pp. 238–239, 1973.
- [48] W. R. Pitts, R. A. Lange, J. E. Cigarroa, and L. David Hillis, "Cocaine-induced myocardial ischemia and infarction: pathophysiology, recognition, and management," *Progress in Cardiovascular Diseases*, vol. 40, no. 1, pp. 65–76, 1997.
- [49] F. A. Heupler Jr., W. L. Proudfit, M. Razavi, E. K. Shirey, R. Greenstreet, and W. C. Sheldon, "Ergonovine maleate provocative test for coronary arterial spasm," *The American Journal of Cardiology*, vol. 41, no. 4, pp. 631–640, 1978.
- [50] M. Tada, T. Kuzuya, M. Inoue et al., "Elevation of thromboxane B2 levels in patients with classic and variant angina Pectoris," *Circulation*, vol. 64, no. 6, pp. 1107–1115, 1981.
- [51] A. Takizawa, H. Yasue, S. Omote et al., "Variant angina induced by alcohol ingestion," *American Heart Journal*, vol. 107, no. 1, pp. 25–27, 1984.
- [52] K. Miwa, A. Igawa, Y. Miyagi, and M. Fujita, "Importance of magnesium deficiency in alcohol-induced variant angina," *The American Journal of Cardiology*, vol. 73, no. 11, pp. 813–816, 1994.
- [53] H. Yasue, Y. Horio, N. Nakamura et al., "Induction of coronary artery spasm by acetylcholine in patients with variant angina: possible role of the parasympathetic nervous system in the pathogenesis of coronary artery spasm," *Circulation*, vol. 74, no. 5, pp. 955–963, 1986.
- [54] D. D. Waters, D. D. Miller, A. Bouchard, X. Bosch, and P. Theroux, "Circadian variation in variant angina," *The American Journal of Cardiology*, vol. 54, no. 1, pp. 61–64, 1984.
- [55] J. C. Kaski, A. Maseri, M. Vejar, F. Crea, D. Hackett, and P. Halson, "Spontaneous coronary artery spasm in variant angina is caused by a local hyperreactivity to a generalized constrictor stimulus," *Journal of the American College of Cardiology*, vol. 14, no. 6, pp. 1456–1463, 1989.
- [56] R. M. Robertson, Y. Bernard, and D. Robertson, "Arterial and coronary sinus catecholamines in the course of spontaneous coronary artery spasm," *American Heart Journal*, vol. 105, no. 6, pp. 901–906, 1983.
- [57] M. J. King, L. M. Zir, A. J. Kaltman, and A. C. Fox, "Variant angina associated with angiographically demonstrated coronary artery spasm and REM sleep," *The American Journal of the Medical Sciences*, vol. 265, no. 5, pp. 419–422, 1973.
- [58] M. Shirokuni, R. Yokota, I. Kouchi et al., "Influence of atenolol on coronary artery spasm after acute myocardial infarction in a Japanese population," *International Journal of Cardiology*, vol. 139, no. 2, pp. 181–186, 2010.
- [59] T. L. Svendsen, "Central hemodynamics of beta-adrenoreceptor blocking drugs: beta 1 selectivity versus intrinsic sympathomimetic activity," *Journal of Cardiovascular Pharmacology*, vol. 5, pp. 21–25, 1983.
- [60] P. Y. Tilmant, J. M. Lablanche, F. A. Thieuleux, B. A. Dupuis, and M. E. Bertrand, "Detrimental effect of propranolol in patients with coronary arterial spasm countered by combination with diltiazem," *The American Journal of Cardiology*, vol. 52, no. 3, pp. 230–233, 1983.
- [61] C. Boulanger and T. F. Luscher, "Release of endothelin from the porcine aorta. Inhibition by endothelium-derived nitric oxide," *Journal of Clinical Investigation*, vol. 85, no. 587, p. 590, 1990.
- [62] M. Takemoto, K. Egashira, M. Usui et al., "Important role of tissue angiotensin-converting enzyme activity in the pathogenesis of coronary vascular and myocardial structural changes induced by long-term blockade of nitric oxide



- synthesis in rats," *Journal of Clinical Investigation*, vol. 99, no. 2, pp. 278–287, 1997.
- [63] K. Kugiyama, H. Yasue, K. Okumura et al., "Nitric oxide activity is deficient in spasm arteries of patients with coronary spastic angina," *Circulation*, vol. 94, no. 3, pp. 266–272, 1996.
- [64] M. Nakayama, H. Yasue, M. Yoshimura et al., "T → 786 → C mutation in the 5'-flanking region of the endothelial nitric oxide synthase gene is associated with coronary spasm," *Circulation*, vol. 99, no. 22, pp. 2864–2870, 1999.
- [65] K. Kugiyama, M. Ohgushi, S. Sugiyama et al., "Supersensitive dilator response to nitroglycerin but not to atrial natriuretic peptide in spastic coronary arteries in coronary spastic angina," *The American Journal of Cardiology*, vol. 79, no. 5, pp. 606–610, 1997.
- [66] J. R. Lewis, R. Kisilevsky, and P. W. Armstrong, "Prinzmetal's angina, normal coronary arteries and pericarditis," *Canadian Medical Association Journal*, vol. 119, no. 119, pp. 36–39, 1978.
- [67] M.-J. Hung, W.-J. Cherng, M.-Y. Hung et al., "Increased leukocyte Rho-associated coiled-coil containing protein kinase activity predicts the presence and severity of coronary vasospastic angina," *Atherosclerosis*, vol. 221, no. 2, pp. 521–526, 2012.
- [68] H. Shimokawa, "Cellular and molecular mechanisms of coronary artery spasm," *Japanese Circulation Journal*, vol. 64, no. 1, pp. 1–12, 2000.
- [69] H. Yasue, N. Hirai, Y. Mizuno et al., "Low-Grade inflammation, thrombogenicity, and atherogenic lipid profile in cigarette smokers," *Circulation Journal*, vol. 70, no. 1, pp. 8–13, 2006.
- [70] K. Ohyama, Y. Matsumoto, K. Takanami et al., "Coronary adventitial and perivascular adipose tissue inflammation in patients with vasospastic angina," *Journal of the American College of Cardiology*, vol. 71, no. 4, pp. 414–425, 2018.
- [71] S. Moncada, R. M. Palmer, and E. A. Higgs, "Nitric oxide: physiology, pathophysiology, and pharmacology," *Pharmacological Reviews*, vol. 43, no. 43, pp. 109–142, 1991.
- [72] S. Miyamoto, H. Kawano, T. Sakamoto et al., "Increased plasma levels of thioredoxin in patients with coronary spastic angina," *Antioxidants & Redox Signaling*, vol. 6, no. 1, pp. 75–80, 2004.
- [73] K. Miwa, Y. Miyagi, A. Igawa, K. Nakagawa, and H. Inoue, "Vitamin E deficiency in variant angina," *Circulation*, vol. 94, no. 1, pp. 14–18, 1996.
- [74] K. Egashira, Y. Katsuda, M. Mohri et al., "Basal release of endothelium-derived nitric oxide at site of spasm in patients with variant angina," *Journal of the American College of Cardiology*, vol. 27, no. 6, pp. 1444–1449, 1996.
- [75] T. Kandabashi, H. Shimokawa, K. Miyata et al., "Inhibition of myosin phosphatase by upregulated rho-kinase plays a key role for coronary artery spasm in a porcine model with interleukin-1 $\beta$ ," *Circulation*, vol. 101, no. 11, pp. 1319–1323, 2000.
- [76] A. P. Somlyo and A. V. Somlyo, "Ca<sub>2+</sub> sensitivity of smooth muscle and nonmuscle myosin II: modulated by G proteins, kinases, and Myosin phosphatase," *Physiological Reviews*, vol. 83, no. 4, pp. 1325–1358, 2003.
- [77] E. Bussemaker, F. Pistrosch, S. Forster et al., "Rho kinase contributes to basal vascular tone in humans: role of endothelium-derived nitric oxide," *American Journal of Physiology-Heart and Circulatory Physiology*, vol. 293, pp. 541–547, 2007.
- [78] T. Nakano, T. Osanai, H. Tomita, M. Sekimata, Y. Homma, and K. Okumura, "Enhanced activity of variant phospholipase C- $\delta$ 1 protein (R257H) detected in patients with coronary artery spasm," *Circulation*, vol. 105, no. 17, pp. 2024–2029, 2002.
- [79] W. A. Chutkow, J. Pu, M. T. Wheeler et al., "Episodic coronary artery vasospasm and hypertension develop in the absence of Sur2 KATP channels," *Journal of Clinical Investigation*, vol. 110, no. 2, pp. 203–208, 2002.
- [80] R. Kakkar, B. Ye, D. A. Stoller et al., "Spontaneous coronary vasospasm in K ATP mutant mice arises from a smooth muscle-extrinsic process," *Circulation Research*, vol. 98, no. 5, pp. 682–689, 2006.
- [81] S. Morita, Y. Mizuno, E. Harada et al., "Differences and interactions between risk factors for coronary spasm and atherosclerosis - smoking, aging, inflammation, and blood pressure," *Internal Medicine*, vol. 53, no. 23, pp. 2663–2670, 2014.
- [82] D. Katoh, Y. Mizuno, E. Harada et al., "High incidence of provoked coronary spasm in the presence of a stent after myocardial infarction," *Coronary Artery Disease*, vol. 23, no. 3, pp. 141–145, 2012.
- [83] S. Hokimoto, Y. Mizuno, D. Sueta et al., "High incidence of coronary spasm after percutaneous coronary interventions," *International Journal of Cardiology*, vol. 182, pp. 171–173, 2015.
- [84] R. Hata, N. Oka, S. Kubo et al., "Impact of stent type and presence of vasospastic angina on long-term prognosis," *Circulation Journal*, vol. 82, no. 2, pp. 469–476, 2018.
- [85] S. Miyamoto, H. Ogawa, H. Soejima et al., "Formation of platelet aggregates after attacks of coronary spastic angina pectoris," *The American Journal of Cardiology*, vol. 85, no. 4, pp. 494–497, 2000.
- [86] S. Oshima, H. Yasue, H. Ogawa, K. Okumura, and K. Matsuyama, "Fibrinopeptide A is released into the coronary circulation after coronary spasm," *Circulation*, vol. 82, no. 6, pp. 2222–2225, 1990.
- [87] H. Ogawa, H. Yasue, S. Oshima, K. Okumura, K. Matsuyama, and K. Obata, "Circadian variation of plasma fibrinopeptide A level in patients with variant angina," *Circulation*, vol. 80, no. 6, pp. 1617–1626, 1989.
- [88] Y. Oike, A. Hata, Y. Ogata, Y. Numata, K. Shido, and K. Kondo, "Angiotensin converting enzyme as a genetic risk factor for coronary artery spasm. Implication in the pathogenesis of myocardial infarction," *Journal of Clinical Investigation*, vol. 96, no. 6, pp. 2975–2979, 1995.
- [89] T. Ito, H. Yasue, M. Yoshimura et al., "Paraoxonase gene Gln192Arg (Q192R) polymorphism is associated with coronary artery spasm," *Human Genetics*, vol. 110, no. 1, pp. 89–94, 2002.
- [90] J. S. Park, S. Y. Zhang, S. H. Jo et al., "Common adrenergic receptor polymorphisms as novel risk factors for vasospastic angina," *American Heart Journal*, vol. 111, pp. 674–706, 2006.
- [91] N. Inoue, S. Kawashima, K. Kanazawa, S. Yamada, H. Akita, and M. Yokoyama, "Polymorphism of the NADH/NADPH oxidase p22 phox gene in patients with coronary artery disease," *Circulation*, vol. 97, no. 2, pp. 135–137, 1998.
- [92] M. Yoshimura, H. Yasue, M. Nakayama et al., "A missense Glu298Asp variant in the endothelial nitric oxide synthase gene is associated with coronary spasm in the Japanese," *Human Genetics*, vol. 103, no. 1, pp. 65–69, 1998.
- [93] H. Kaneda, J. Taguchi, Y. Kuwada et al., "Coronary artery spasm and the polymorphisms of the endothelial nitric oxide

- synthase gene," *Circulation Journal*, vol. 70, no. 4, pp. 409–413, 2006.
- [94] A. Kaumann and F. Levy, "5-hydroxytryptamine receptors in the human cardiovascular system," *Pharmacology & Therapeutics*, vol. 111, no. 3, pp. 674–706, 2006.
- [95] Y. Murase, Y. Yamada, A. Hirashiki et al., "Genetic risk and gene-environment interaction in coronary artery spasm in Japanese men and women," *European Heart Journal*, vol. 25, no. 11, pp. 970–977, 2004.
- [96] Y. Mizuno, E. Harada, S. Morita et al., "East Asian variant of aldehyde dehydrogenase 2 is associated with coronary spastic angina," *Circulation*, vol. 131, no. 19, pp. 1665–1673, 2015.
- [97] C.-H. Chen, J. C. B. Ferreira, E. R. Gross, and D. Mochlyrosen, "Targeting aldehyde dehydrogenase 2: new therapeutic opportunities," *Physiological Reviews*, vol. 94, no. 1, pp. 1–34, 2014.
- [98] Y. Mizuno, S. Hokimoto, E. Harada, K. Kinoshita, M. Yoshimura, and H. Yasue, "Variant aldehyde dehydrogenase2 (ALDH2\*2) in east asians interactively exacerbates tobacco smoking risk for coronary spasm-Possible role of reactive aldehydes," *Circulation Journal*, vol. 81, pp. 96–102, 2016.
- [99] Y. Mizuno, S. Hokimoto, E. Harada et al., "Variant aldehyde dehydrogenase 2 (ALDH2 \* 2) is a risk factor for coronary spasm and ST-segment elevation myocardial infarction," *Journal of the American Heart Association*, vol. 5, Article ID e003247, 2016.
- [100] F. Takeuchi, M. Yokota, K. Yamamoto et al., "Genome-wide association study of coronary artery disease in the Japanese," *European Journal of Human Genetics*, vol. 20, no. 3, pp. 333–340, 2012.
- [101] J.-Y. Gu and L.-W. Li, "ALDH2 Glu504Lys polymorphism and susceptibility to coronary artery disease and myocardial infarction in East Asians: a meta-analysis," *Archives of Medical Research*, vol. 45, no. 1, pp. 76–83, 2014.
- [102] A. Daiber, M. Oelze, P. Wenzel et al., "Nitrate tolerance as a model of vascular dysfunction: roles for mitochondrial aldehyde dehydrogenase and mitochondrial oxidative stress," *Pharmacological Reports*, vol. 61, no. 1, pp. 33–48, 2009.
- [103] K. Ohba, S. Sugiyama, H. Sumida et al., "Microvascular coronary artery spasm presents distinctive clinical features with endothelial dysfunction as nonobstructive coronary artery disease," *Journal of the American Heart Association*, vol. 1, Article ID e002485, 2012.
- [104] P. J. Scanlon, D. P. Faxon, A.-M. Audet et al., "ACC/AHA guidelines for coronary angiography," *Journal of the American College of Cardiology*, vol. 33, no. 6, pp. 1756–1824, 1999.
- [105] D. S. Baim, "Coronary angiography," in *Grossman's Cardiac Catheterization, Angiography, and Intervention*, D. S. Baim, Ed., Lippincott Williams & Wilkins, Philadelphia, PA, USA, 7th edition, 2006.
- [106] M. E. Bertrand, J. M. Lablanche, P. Y. Tilmant, F. A. Thieuleux, M. G. Delforge, and R. A. Chahine, "The provocation of coronary arterial spasm in patients with recent transmural myocardial infarction," *European Heart Journal*, vol. 4, no. 8, pp. 532–535, 1983.
- [107] K. K. Hamilton and C. J. Pepine, "A renaissance of provocative testing for coronary spasm?" *Journal of the American College of Cardiology*, vol. 35, no. 7, pp. 1857–1859, 2000.
- [108] A. Buxton, S. Goldberg, J. W. Hirshfeld et al., "Refractory ergonovine-induced coronary vasospasm: importance of intracoronary nitroglycerin," *The American Journal of Cardiology*, vol. 46, no. 2, pp. 329–334, 1980.
- [109] M. B. Harding, M. E. Leithe, D. B. Mark et al., "Ergonovine maleate testing during cardiac catheterization: a 10-year perspective in 3,447 patients without significant coronary artery disease or Prinzmetal's variant angina," *Journal of the American College of Cardiology*, vol. 20, no. 1, pp. 107–111, 1992.
- [110] E. Eshaghpour, L. Mattioli, M. L. Williams, and A. N. Moghadam, "Acetylcholine in the treatment of idiopathic respiratory distress syndrome," *The Journal of Pediatrics*, vol. 71, no. 2, pp. 243–246, 1967.
- [111] M. Zaya, P. K. Mehta, and C. N. Bairey Merz, "Provocative testing for coronary reactivity and spasm," *Journal of the American College of Cardiology*, vol. 63, no. 2, pp. 103–109, 2014.
- [112] Y. Miyao, K. Kugiyama, H. Kawano et al., "Diffuse intimal thickening of coronary arteries in patients with coronary spastic angina," *Journal of the American College of Cardiology*, vol. 36, no. 2, pp. 432–437, 2000.
- [113] K. Tsujita, K. Sakamoto, S. Kojima et al., "Coronary plaque component in patients with vasospastic angina: a virtual histology intravascular ultrasound study," *International Journal of Cardiology*, vol. 168, no. 3, pp. 2411–2415, 2013.
- [114] S. Saito, M. Yamagishi, T. Takayama et al., "Plaque morphology at coronary sites with focal spasm in variant angina," *Circulation Journal*, vol. 67, no. 12, pp. 1041–1045, 2003.
- [115] Y. J. Hong, M. H. Jeong, Y. H. Choi et al., "Plaque components at coronary sites with focal spasm in patients with variant angina: virtual histology-intravascular ultrasound analysis," *International Journal of Cardiology*, vol. 144, no. 144, pp. 367–372, 2010.
- [116] A. Tanaka, K. Shimada, G. J. Tearney et al., "Conformational change in coronary artery structure assessed by optical coherence tomography in patients with vasospastic angina," *Journal of the American College of Cardiology*, vol. 58, no. 15, pp. 1608–1613, 2011.
- [117] E.-S. Shin, S. H. Ann, G. B. Singh et al., "OCT-defined morphological characteristics of coronary artery spasm sites in vasospastic angina," *JACC: Cardiovascular Imaging*, vol. 8, no. 9, pp. 1059–1067, 2015.
- [118] S. Agewall, J. F. Beltrame, H. R. Reynolds et al., "ESC working group position paper on myocardial infarction with non obstructive coronary arteries," *European Heart Journal*, vol. 38, Article ID ehv149, 2017.
- [119] T. J. Ford, D. Corcoran, and C. Berry, "Stable coronary syndromes: pathophysiology, diagnostic advances and therapeutic need," *Heart (British Cardiac Society)*, vol. 104, no. 104, pp. 284–292, 2018.
- [120] D. Cocoran, T. J. Ford, L. Y. Hsu et al., "Rationale and design of the coronary microvascular angina cardiac magnetic resonance imaging (CorCMR) diagnostic study: the CorMicA CMR sub-study," *Open Heart*, vol. 5, no. 2, Article ID e000924, 2018.
- [121] H. Bettina, R. Gianni, B. Nora et al., "Systematic use of cardiac magnetic resonance imaging in MINOCA led to a five-fold increase in the detection rate of myocarditis: a retrospective study," *Swiss Medical Weekly*, vol. 149, 2019.
- [122] JCS Joint Working Group, "Guidelines for diagnosis and treatment of patients with vasospastic angina (Coronary Spastic Angina) (JCS 2013)," *Circulation Journal*, vol. 78, no. 11, pp. 2779–2801, 2014.
- [123] R. A. Chahine, R. L. Feldman, T. D. Giles et al., "Randomized placebo-controlled trial of amlodipine in vasospastic angina," *Journal of the American College of Cardiology*, vol. 21, no. 6, pp. 1365–1370, 1993.

- [124] J. A. De lemons and R. A. O'Rourke, "Unstable angina and non-ST-segment elevation myocardial infarction," in *Hurst's the Heart*, V. Fuster, Ed., pp. 1371-1372, Mc Graw, New York, NY, USA, 12th edition, 2008.
- [125] M. Rodríguez-Mañero, T. Oloriz, J.-B. Le polain de Waroux et al., "Long-term prognosis of patients with life-threatening ventricular arrhythmias induced by coronary artery spasm," *EP Europace*, vol. 20, no. 5, pp. 851-858, 2018.
- [126] S. Sueda and H. Kohno, "Optimal medications and appropriate implantable cardioverter-defibrillator shocks in aborted sudden cardiac death due to coronary spasm," *Internal Medicine*, vol. 57, no. 10, pp. 1361-1369, 2018.
- [127] B. Gao, Z. Zhang, J. Qian et al., "The use of calcium channel blockers in the treatment of coronary spasm and atrioventricular block," *Cell Biochemistry and Biophysics*, vol. 72, no. 2, pp. 527-531, 2015.
- [128] A. Daiher and T. Munzel, "Organic nitrate therapy, nitrate tolerance, and nitrate-induced endothelial dysfunction: emphasis on redox biology and oxidative stress," *Antioxidants & Redox Signaling*, vol. 23, pp. 899-942, 2015.
- [129] J. Takahashi, T. Nihei, Y. Takagi et al., "Prognostic impact of chronic nitrate therapy in patients with vasospastic angina: multicentre registry study of the Japanese coronary spasm association," *European Heart Journal*, vol. 36, no. 4, pp. 228-237, 2015.
- [130] J. C. Kaski, "Management of vasospastic angina? Role of nicorandil," *Cardiovascular Drugs and Therapy*, vol. 9, no. S2, pp. 221-227, 1995.
- [131] Z. H. Piao, M. H. Jeong, Y. Li et al., "Benefit of statin therapy in patients with coronary spasm-induced acute myocardial infarction," *Journal of Cardiology*, vol. 68, no. 1, pp. 7-12, 2016.
- [132] M. Ishii, K. Kaikita, K. Sato et al., "Impact of statin therapy on clinical outcome in patients with coronary spasm," *Journal of the American Heart Association*, vol. 5, p. e003426, 2016.
- [133] K. Kugiyama, T. Motoyama, O. Hirashima et al., "Vitamin C attenuates abnormal vasomotor reactivity in spasm coronary arteries in patients with coronary spastic angina," *Journal of the American College of Cardiology*, vol. 32, no. 1, pp. 103-109, 1998.
- [134] T. Motoyama, H. Kawano, K. Kugiyama et al., "Vitamin E administration improves impairment of endothelium-dependent vasodilation in patients with coronary spastic angina," *Journal of the American College of Cardiology*, vol. 32, no. 6, pp. 1672-1679, 1998.
- [135] M. Slavich and R. S. Patel, "Coronary artery spasm: current knowledge and residual uncertainties," *IJC Heart & Vascular*, vol. 10, pp. 47-53, 2016.
- [136] R. C. Pasternak, A. M. Hutter, R. W. DeSanctis, M. F. JaRo, and M. J. Buckley, "Variant angina," *The Journal of Thoracic and Cardiovascular Surgery*, vol. 78, no. 4, pp. 614-622, 1979.
- [137] A. Gaspardone, F. Tomai, F. Versaci et al., "Coronary artery stent placement in patients with variant angina refractory to medical treatment," *The American Journal of Cardiology*, vol. 84, no. 1, pp. 96-98, 1999.
- [138] H. H. Chou, K. E. Lim, and Y. L. Ko, "Treatment of spontaneous left main coronary artery spasm with a drug-eluting stent," *Acta Cardiologica Sinica*, vol. 25, pp. 43-46, 2009.
- [139] M. T. Chou and T. Y. Huang, "Coronary stenting for coronary vasospasm complicated with refractory ventricular tachycardia and fibrillation," *Acta Cardiologica Sinica*, vol. 28, pp. 145-147, 2012.
- [140] T. Nakamura, K. Furukawa, H. Uchiyama, Y. Seo, S. Okuda, and T. Ebizawa, "Stent placement for recurrent vasospastic angina resistant to medical treatment," *Catheterization and Cardiovascular Diagnosis*, vol. 42, no. 4, pp. 440-443, 1997.
- [141] R. Cardona-Guarache, J. Pozen, A. Jahangiri et al., "Thoracic sympathectomy for severe refractory multivessel coronary artery spasm," *The American Journal of Cardiology*, vol. 117, no. 1, pp. 159-161, 2016.
- [142] P. Chevalier, A. Dacosta, P. Defaye et al., "Arrhythmic cardiac arrest due to isolated coronary artery spasm: long-term outcome of seven resuscitated patients," *Journal of the American College of Cardiology*, vol. 31, no. 1, pp. 57-61, 1998.
- [143] S. R. Meisel, A. Mazur, I. Chetboun et al., "Usefulness of implantable cardioverter-defibrillators in refractory variant angina pectoris complicated by ventricular fibrillation in patients with angiographically normal coronary arteries," *The American Journal of Cardiology*, vol. 89, no. 9, pp. 1114-1116, 2002.
- [144] K. Yoshida, T. Inoue, N. Hirakawa, and K. Node, "Endoscopic thoracic sympathectomy as a novel strategy for vasospastic angina refractory to medical treatments," *Journal of Cardiology*, vol. 52, no. 1, pp. 49-52, 2008.
- [145] L. Yaowang, L. Huadong, Y. Danqing et al., "Sympathectomy versus conventional treatment for refractory coronary artery spasm," *Coronary Artery Disease*, vol. 30, no. 6, pp. 418-424, 2019.
- [146] Beltrame et al., "The who, what, why, when, how and where of vasospastic angina," *Circulation Journal*, vol. 80, no. 2, pp. 288-311, 2016.
- [147] H. Yasue, A. Takizawa, M. Nagao et al., "Long-term prognosis for patients with variant angina and influential factors," *Circulation*, vol. 78, no. 1, pp. 1-9, 1988.
- [148] M. Bory, F. Pierron, D. Panagides, J. L. Bonnet, S. Yvorra, and L. Desfossez, "Coronary artery spasm in patients with normal or near normal coronary arteries: long-term follow-up of 277 patients," *European Heart Journal*, vol. 17, no. 7, pp. 1015-1021, 1996.
- [149] S. B. Freedman, D. R. Richmond, M. Alwyn, and D. T. Kelly, "Late follow-up (41 to 102 months) of medically treated patients with coronary artery spasm and minor atherosclerotic coronary obstructions," *The American Journal of Cardiology*, vol. 57, no. 15, pp. 1261-1263, 1986.
- [150] P. Ong, A. Athanasiadis, G. Borgulya, M. Voehringer, and U. Sechtem, "3-year follow-up of patients with coronary artery spasm as cause of acute coronary syndrome," *Journal of the American College of Cardiology*, vol. 57, no. 2, pp. 147-152, 2011.
- [151] J.-M. Ahn, K. H. Lee, S.-Y. Yoo et al., "Prognosis of variant angina manifesting as aborted sudden cardiac death," *Journal of the American College of Cardiology*, vol. 68, no. 2, pp. 137-145, 2016.
- [152] Y. Takagi, J. Takahashi, S. Yasuda et al., "Prognostic stratification of patients with vasospastic angina," *Journal of the American College of Cardiology*, vol. 62, no. 13, pp. 1144-1153, 2013.