Pathology Update for Urologists

Guest Editors: Kenneth A. Iczkowski, Rodolfo Montironi, Dengfeng Cao, Cristina Magi-Galluzzi, and M. Scott Lucia

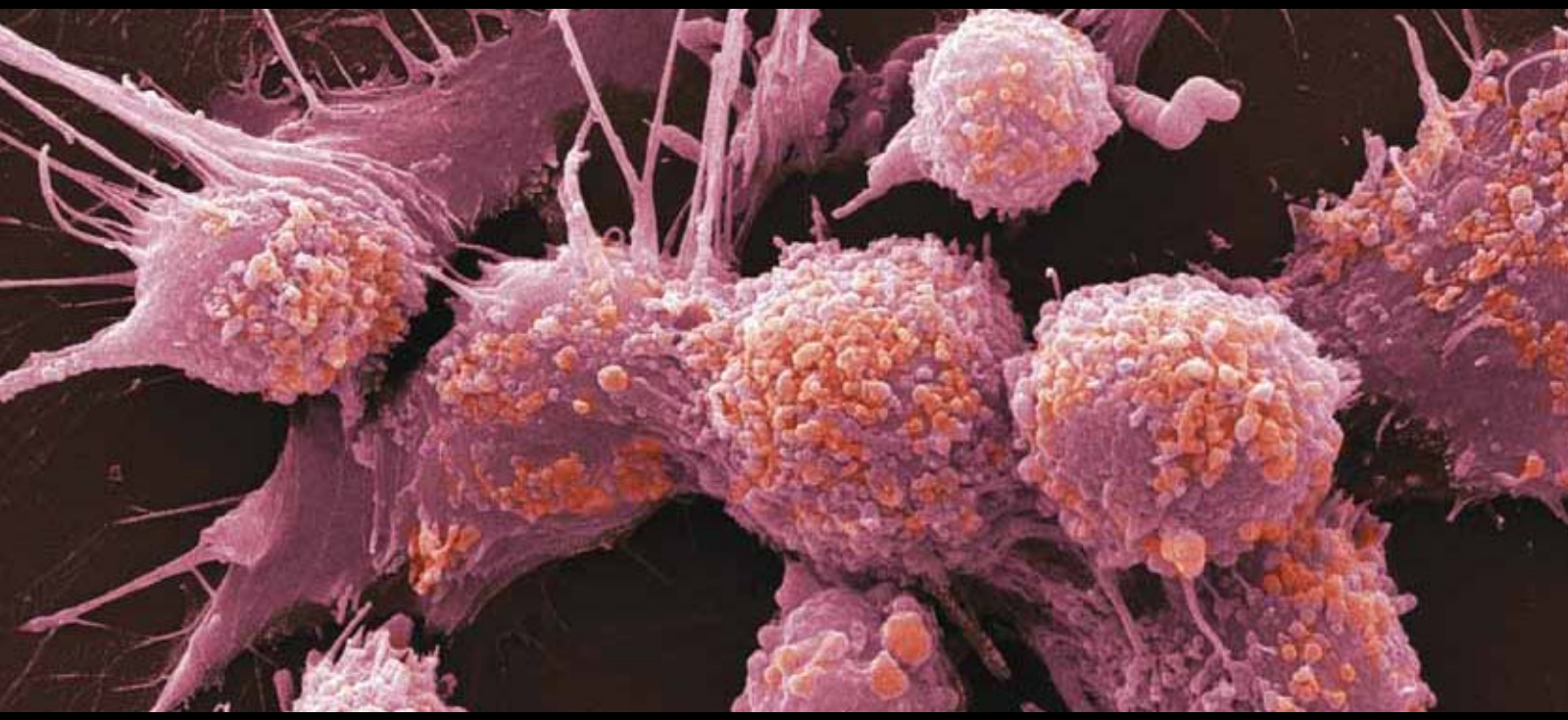

Pathology Update for Urologists

Prostate Cancer

Pathology Update for Urologists

Guest Editors: Kenneth A. Iczkowski, Rodolfo Montironi, Dengfeng Cao, Cristina Magi-Galluzzi, and M. Scott Lucia

Copyright © 2011 Hindawi Publishing Corporation. All rights reserved.

This is a special issue published in volume 2011 of "Prostate Cancer." All articles are open access articles distributed under the Creative Commons Attribution License, which permits unrestricted use, distribution, and reproduction in any medium, provided the original work is properly cited.

Editorial Board

Jens E. Altwein, Germany
Mitchell Benson, USA
R. Daniel Bonfil, USA
Michael Borre, Denmark
James D. Brooks, USA
E. David Crawford, USA
William L. Dahut, USA
Rosalind Eeles, UK
Scott E. Eggener, USA
Mark Emberton, UK
Michael Froehner, Germany
Robert Gardiner, Australia
James L. Gulley, USA
Cristina Magi-Galluzzi, USA
Michael McClelland, USA
J. W. Moul, USA
David Nanus, USA
Carl A. Olsson, USA
David K. Ornstein, USA
Daniel P. Petrylak, USA
Douglas K. Price, USA
Craig Robson, UK
Gunnar Ronquist, Sweden
Fazlul H. Sarkar, USA
Jack Schalken, The Netherlands
Johanna Schleutker, Finland
Katsuto Shinohara, USA
Shiv K. Srivastava, USA
Arnulf Stenzl, Germany
George Thalmann, Switzerland
John Trachtenberg, Canada
Bruce J. Trock, USA
Ulka Vaishampayan, USA
Hein Van Poppel, Belgium
Hessel Wijkstra, The Netherlands
Simon A. Williams, USA
Manfred P. Wirth, Germany
Michael Zelefsky, USA
Alexandre R. Zlotta, Canada

Contents

Pathology Update for Urologists, Kenneth A. Iczkowski, Rodolfo Montironi, Dengfeng Cao, Cristina Magi-Galluzzi, and M. Scott Lucia
Volume 2011, Article ID 183761, 2 pages

Systematic Analysis of Transrectal Prostate Biopsies Using an Ink Method and Specific Histopathologic Protocol: A Prospective Study, David Parada, Nahum Calvo, Karla Peña, Vanesa Morente, Rosana Queralt, Pilar Hernandez, and Francesc Riu
Volume 2011, Article ID 380249, 3 pages

Specimen Orientation by Marking the Peripheral End: (Potential) Clinical Advantages in Prostate Biopsy, Andrea Benedetto Galosi, Giovanni Muzzonigro, Vito Lacetera, and Roberta Mazzucchelli
Volume 2011, Article ID 270403, 7 pages

Pseudolumen Size and Perimeter in Prostate Cancer: Correlation with Patient Outcome, Kenneth A. Iczkowski, Kathleen C. Torkko, Gregory R. Kotnis, R. Storey Wilson, Wei Huang, Thomas M. Wheeler, Andrea M. Abeyta, and M. Scott Lucia
Volume 2011, Article ID 693853, 6 pages

Metastasis Update: Human Prostate Carcinoma Invasion via Tubulogenesis, Raymond B. Nagle and Anne E. Cress
Volume 2011, Article ID 249290, 10 pages

Prognostic Factors for the Development of Biochemical Recurrence after Radical Prostatectomy, Ahmed F. Kotb and Ahmed A. Elabbady
Volume 2011, Article ID 485189, 6 pages

Frequency of Positive Surgical Margin at Prostatectomy and Its Effect on Patient Outcome, Kenneth A. Iczkowski and M. Scott Lucia
Volume 2011, Article ID 673021, 12 pages

Review of Small Cell Carcinomas of the Prostate, P. Furtado, M. V. A. Lima, C. Nogueira, M. Franco, and F. Tavora
Volume 2011, Article ID 543272, 5 pages

Proliferative Tumor Doubling Times of Prostatic Carcinoma, Priya N. Werahera, L. Michael Glode, Francisco G. La Rosa, M. Scott Lucia, E. David Crawford, Kenneth Easterday, Holly T. Sullivan, Rameshwar S. Sidhu, Elizabeth Genova, and Tammy Hedlund
Volume 2011, Article ID 301850, 7 pages

Hindawi Publishing Corporation
Prostate Cancer
Volume 2011, Article ID 183761, 2 pages
doi:10.1155/2011/183761

Editorial

Pathology Update for Urologists

Kenneth A. Iczkowski,[1] Rodolfo Montironi,[2,3] Dengfeng Cao,[4] Cristina Magi-Galluzzi,[5] and M. Scott Lucia[6]

[1] *Urology Specialists of America, 2100 Marble Cliff Office Park, Suite A, Columbus, OH 43215-1056, USA*
[2] *Institute of Pathological Anatomy and Histopathology, School of Medicine, Polytechnic University of the Marche Region (Ancona), United Hospitals, Via Conca, 71, Ancona, 60126 Torrette, Italy*
[3] *Arizona Cancer Center, College of Medicine, The University of Arizona, 1515 North Campbell Avenue, Tucson, AZ 85724-5024, USA*
[4] *Department of Pathology and Immunology, Washington University School of Medicine, 660 S Euclid Avenue, Campus Box 8118, Saint Louis, MO 63110, USA*
[5] *Department of Anatomic Pathology and Glickman Urological and Kidney Institute, Cleveland Clinic, Lerner College of Medicine, 9500 Euclid Avenue, OH 44195, USA*
[6] *Department of Pathology, University of Colorado Health Science Center, Aurora, CO 80045, USA*

Correspondence should be addressed to Kenneth A. Iczkowski, iczkoka@usauro.com

Received 12 July 2011; Accepted 12 July 2011

Copyright © 2011 Kenneth A. Iczkowski et al. This is an open access article distributed under the Creative Commons Attribution License, which permits unrestricted use, distribution, and reproduction in any medium, provided the original work is properly cited.

This special issue of *Prostate Cancer* was designed to be read by both urologists and pathologists. It comprises eight papers, of which 3 are original studies and 5 are review papers, largely devoted to promoting urologists' understanding of the histologic findings provided by pathologists in both biopsy and radical prostatectomy specimens.

Many of the papers are closely related and fall into 4 general subheadings: (1) technical implications of biopsy sampling and submission; (2) correlation of histoarchitectural findings with tumor development and outcome; (3) prognostic factors; (4) tumor biology.

Biopsy sampling and submission technique is addressed in one original article and one review article. D. Parada et al. emphasize the cost savings attainable by inking needle cores from various sites submitted in the same block. Galosi et al. review their work and that of others on the benefits of inking the peripheral end of each core for orientation and stage prediction.

Correlation of histoarchitectural findings with tumor development is explored in an original study and a review. K. A. Iczkowski et al. based their study on the observation that not all prostate cancers graded as Gleason 4 look alike. Thus, a quantitative analysis of the density of cancer epithelial cells compared with stroma and the loss of ability to form a lumen (spaces in cancer are termed pseudolumens) may give us additional, cost-effective information to stratify outcomes more finely. The review by R. Nagle and B. Cress ties in with the Iczkowski study, by postulating that loss of polarity and the ability to form lumens are key measures of tumor aggressiveness. They review the literature and postulate that tubule formation, rather than epithelial-mesenchymal transition (EMT) is the main driver of invasion and metastasis.

Prognostic factors are covered in three review articles. Kotb et al. provide an overview of prognostic factors with respect to recurrence. Iczkowski and Lucia review prostatectomy margin status, a key predictor of outcome whose implications may not be well understood by urologists. The location, extent, and grade of margin positivity, it turns out, can modify its importance. P. Furtado et al. review the outcome of a particularly aggressive variant of prostate cancer called small cell carcinoma. This constitutes fewer than 1% of prostate cancers and, importantly, tends not to elevate serum PSA.

Finally, the *tumor biology* of prostate cancer is studied by P. N. Werahera et al. using molecular techniques to estimate

tumor doubling time. They postulate a role for apoptosis in determining tumor aggressiveness.

We are pleased to present this compendium of papers containing the most contemporary thought regarding the submission of specimens, new insights on histologic morphology, prognostic implications of findings, and tumor biology. We hope we have stimulated urologists to understand and take interest in these up-to-the-minute developments in pathology that affect their practice.

Kenneth A. Iczkowski
R. Montironi
Dengfeng Cao
Cristina Magi-Galluzzi
M. Scott Lucia

Hindawi Publishing Corporation
Prostate Cancer
Volume 2011, Article ID 380249, 3 pages
doi:10.1155/2011/380249

Research Article

Systematic Analysis of Transrectal Prostate Biopsies Using an Ink Method and Specific Histopathologic Protocol: A Prospective Study

David Parada,[1,2] Nahum Calvo,[3,4] Karla Peña,[1,2] Vanesa Morente,[1,2] Rosana Queralt,[1,2] Pilar Hernandez,[5] and Francesc Riu[1,2]

[1] *Servei de Patologia i, Hospital Universitari Sant Joan de Reus, Tarragona 43206, Reus, Spain*
[2] *Institut d'Investigació Sanitària Pere Virgili (IISPV), Universitat Rovira i Virgili, Tarragona, Reus, Spain*
[3] *CRC Corporación Sanitària, Tarragona, Reus, Spain*
[4] *Servei de Radiologia i, Hospital Universitari Sant Joan de Reus, Tarragona, 43206 Reus, Spain*
[5] *Epidemiología, Estadística y Bioinformática, Institut d'Investigació Sanitària Pere Virgili (IISPV), Tarragona, Reus, Spain*

Correspondence should be addressed to David Parada, dparada@grupsagessa.com

Received 14 February 2011; Accepted 11 April 2011

Academic Editor: Kenneth A. Iczkowski

Copyright © 2011 David Parada et al. This is an open access article distributed under the Creative Commons Attribution License, which permits unrestricted use, distribution, and reproduction in any medium, provided the original work is properly cited.

Background. Transrectal prostate biopsy is the standard protocol for the screening for prostate cancer. It helps to locate prostatic adenocarcinoma and plan treatment. However, the increasing number of prostate biopsies leads to considerably greater costs for the pathology laboratories. In this study, we compare the traditional method with an ink method in combination with a systematic histopathologic protocol. *Methods*. Two hundred consecutive transrectal prostate biopsy specimens were received from the radiology department. They were separated into two groups: one hundred were processed as six different specimens in the usual manner. The other one hundred were submitted in six containers, the apex, base, and middle section of which were stained different colours. The samples subject to the ink method were embedded in paraffin and placed in two cassettes which were sectioned using a specific protocol. *Results*. The comparative study of the nonink and ink methods for histopathologic diagnosis showed no statistical differences as far as diagnostic categories were concerned (P value $< .005$). The number of PIN diagnoses increased when the ink method was used, but no statistical differences were found. The ink method led to a cost reduction of 48.86%. *Conclusions*. Our ink method combined with a specific histopathologic protocol provided the same diagnostic quality, tumor location information as the traditional method, and lower pathology expenses.

1. Introduction

Biopsy specimens need to be appropriately histologically sampled if diagnoses are to be correct and complete. Inadequate sampling results in less informative diagnoses and misdiagnoses, while oversampling leads to wasted time and expenses. These issues are especially relevant to prostate needle biopsies because they comprise a significant portion of anatomic pathology practice and contain clinically relevant features that are often microscopically focal.

Systematic parasagittal sextant biopsy has been the standard protocol for many years in screening for prostate cancer [1–3], but this "standard method" has been modified to increase the probability of diagnosing prostatic adenocarcinoma and to allow for variation in the sampling and submission of prostate biopsies [4]. To improve the cancer detection rate, many prostate biopsy schemes have been extended to ten, twelve, or more cores per patient [5]. The increase in the number of prostate biopsies creates considerable extra expense for the pathology laboratory: consumables and work for technicians and pathologists' time. In this study, we analyzed the effectiveness of using an ink method for transrectal prostate biopsy combined with a histopathologic protocol that was similar to the routine histopathological method.

2. Materials and Methods

2.1. Tissue Processing. For this study, radiologists submitted two hundred consecutive transrectal prostate biopsy specimens, from September 2009 to January 2010. Specimens were separated into two groups of one hundred samples each: the nonink group and the ink group. The nonink specimens were processed as six different specimens with one or two tissue cores. The apex and base were green and blue, respectively, while the middle section was not inked. The first one hundred were each embedded in paraffin blocks and sectioned until full-face tissue was observed, as usual. Three sections were obtained for histological examination. One slide of nonink material was given to the pathologist's staff. If they considered it to be necessary, they were free to obtain additional H-E (levels or a new H-E) and immunohistochemical studies.

The paraffin-embedded samples from the ink method were placed in two casettes (right and left) with at least six cylinders of material. The two blocks were sectioned using the following protocol. Level 1: 1 H-E + 3 unstained intervening slides for immunohistochemistry study +15 microns sections. Level 2: 1 H-E + 3 unstained intervening slides for immunohistochemistry study +15 microns sections. Level 3: 1 H-E + 3 unstained intervening slides for immunohistochemistry. Unstained sections were subject to immunohistochemical when it was required. The nonused unstained slides were discarded once a diagnosis had been made.

2.2. Histopathologic Review. The study focused on a series of specimens from 200 consecutive 18 gauge transrectal prostate biopsies that were performed at the Sant Joan University Hospital between 1 September, 2009 and 1 January, 2010. The diagnostic categories were, (1) benign prostate tissue, (2) prostatic intraepithelial neoplasia (high-grade PIN), (3) atypical glands suspicious for adenocarcinoma, and (4) prostatic adenocarcinoma. In each category, we evaluated the number of paraffin blocks, number of levels, and number of immunohistochemical studies.

2.3. Statistical Analysis. EPIDAT software was used to analyze the differences between the two protocols. A P value less than .05 was considered significant.

3. Results

3.1. Nonink Method. The histopathologic diagnoses in 100 consecutive cases of transrectal prostate biopsies were the following: benign prostatic tissue 56%, PIN 4%, atypical glands 3%, and adenocarcinoma 37%. A total of 600 initial histological examinations were carried out in each case, and 563 additional levels were required before a diagnosis could be made. Additionally, 66 immunohistochemical studies were performed to confirm the final diagnosis. The total number of H-E, level, and immunohistochemical studies was 1229. The total number of paraffin blocks was 600. The approximate cost of labor/reagents per block/slide/immunohistochemical studies was $22,734.76.

Table 1: Diagnostic proportion differences between nonink and ing groups.

	% nonink	% ink	Difference % P value
Adenocarcinoma	37.0	34.0	.77
PIN	4.0	8.0	.37
Atypical glands	3.0	4.0	1.00
Benign	56.0	54.0	.89

P value < .005 for differences among all categories.

Table 2: Comparative use of resources between nonink and ink groups.

	Number	% nonink	% ink	Difference % P value
H-E levels	863	65.2	34.8	.0001
Immunohistochemistry	120	55.0	45.0	.16
Block	800	75.0	25.0	.0001
Levels + immunohist.	983	64.0	36.0	.0001

P value < .005 for difference among all categories.

Table 3: Relation of the use of resources for each method and sample (mean values).

	Nonink	Ink	Ratio nonink/ink	Ratio ink/nonink
H-E levels	5.63	3.00	1.88	0.53
Immunohistochemistry	0.66	0.54	1.22	0.82
Block	6.00	2.00	3.00	0.33
Levels + immunohist.	6.29	3.54	1.78	0.56

3.2. Ink Method. The histopathologic diagnoses in 100 consecutive cases of transrectal prostate biopsies were the following: benign prostate tissue 54%, PIN 8%, atypical glands 4%, and adenocarcinoma 34%. A total of 600 initial histological examinations were carried out, and no additional levels were required to make a diagnosis. Additionally, 54 immunohistochemical studies were performed to confirm the final diagnosis. The total number of H-E and immunohistochemical studies was 654. The total number of paraffin blocks was 200. The approximate cost of labor/reagents per block/slide/immunohistochemical study was $11,109.43.

3.3. Correlation between Methods. A comparative study between the nonink and ink method for histopathologic diagnosis showed no statistical differences in the diagnostic categories (P value < .005) (Table 1). One interesting result was that the ink method resulted in twice as many diagnoses of PIN than the noninked method, but no statistical differences were found. Table 2 shows the comparative use of resource, and Table 3 shows that, for each test and case studied by the nonink method, we required 0.53 levels,

0.82 immunohistochemical studies, and 0.33 paraffin blocks using the ink method. The cost reduction was 48.86%.

4. Discussion

Although systematic parasagittal sextant biopsy has been the standard protocol for many years, studies that use extended protocols have shown that it misses 10–30% of cancers [3, 6]. The ideal biopsy protocol still has to be determined [7, 8]. There are not any established guidelines for processing prostate biopsy specimens, and practices vary considerably. Our study aims to determine which histological procedure can be used with confidence in the general pathology laboratory. We have chosen to address this question using two different methods: the first is a traditional procedure used in routine pathology laboratories, while the second—the ink method—consists of cylinders stained with colored ink depending on prostate location and a specific histopathologic protocol. Our results showed that the ink method had the same diagnostic quality and gave the same information about prostatic adenocarcinoma.

Using our protocol, the biopsies from the right and left side of the prostate are placed in two paraffin blocks and three HE staining sections of each block are obtained for diagnosis. In this way, pathology expenses are cut by more than half and the information provided about location is the same. The protocol also permits three immunohistochemical markers when necessary, which presents no problems of the loss of paraffin-embedded material.

Previous research has been carried out on the use of the ink method for prostate biopsy [9, 10], and results show that costs can be reduced with the same information about tumor location provided. However, this research focused only on the specific location of the prostate specimen. In our study, we used a specific histopathologic protocol coupled with the ink method, and, in terms of diagnostic category, the results were not different from those of the traditional method. The detection of prostatic intraepithelial neoplasia increased, probably because none of the material studied for diagnosis was lost. On the other hand, when multiple prostate biopsy cores are embedded in a single block, probably less tissue is evaluated because it is difficult to embed all cores in a single plane for optimal tissue presentation [11]. However, with proper handling, multiple cores per cassette seems to be reasonable. Finally, by reducing the number of blocks/slides from six to two, the potential savings could be in hundreds of million per year. Saving has also been shown when the containers are reduced from 12 to 6 [12].

In conclusion, the application of tissue-marking ink in prostate biopsies can prevent valuable information about tumor location from being lost. The combination of the ink method and specific histopathologic information reduces the time and cost of processing biopsies and can still guarantee reliable results.

References

[1] J. I. Epstein, K. Lecksell, and H. B. Carter, "Prostate cancer sampled on sextant needle biopsy: significance of cancer on multiple cores from different areas of the prostate," *Urology*, vol. 54, no. 2, pp. 291–294, 1999.

[2] S. S. Taneja, D. F. Penson, A. Epelbaum, T. Handler, and H. Lepor, "Does site specific labeling of sextant biopsy cores predict the site of extracapsular extension in radical prostatectomy surgical specimen?" *Journal of Urology*, vol. 162, no. 4, pp. 1352–1357, 1999.

[3] K. Eichler, S. Hempel, J. Wilby, L. Myers, L. M. Bachmann, and J. Kleijnen, "Diagnostic value of systematic biopsy methods in the investigation of prostate cancer: a systematic review," *Journal of Urology*, vol. 175, no. 5, pp. 1605–1612, 2006.

[4] K. A. Iczkowski and D. G. Bostwick, "Sampling, submission, and report format for multiple prostate biopsies: a 1999 survey," *Urology*, vol. 55, no. 4, pp. 568–571, 2000.

[5] A. El-Hakim and S. Sabri Moussa, "CUA guidelines on prostate biopsy methodology," *Journal of the Canadian Urological Association*, vol. 4, no. 2, pp. 89–94, 2010.

[6] B. Djavan and M. Margreiter, "Biopsy standards for detection of prostate cancer," *World Journal of Urology*, vol. 25, no. 1, pp. 11–17, 2007.

[7] J. C. Presti Jr., J. J. Chang, V. Bhargava, and K. Shinohara, "The optimal systematic prostate biopsy scheme should include 8 rather than 6 biopsies: results of a prospective clinical trial," *Journal of Urology*, vol. 163, no. 1, pp. 163–167, 2000.

[8] J. Philip, V. Hanchanale, C. S. Foster, and P. Javlé, "Importance of peripheral biopsies in maximising the detection of early prostate cancer in repeat 12-core biopsy protocols," *British Journal of Urology International*, vol. 98, no. 3, pp. 559–562, 2006.

[9] M. K. Terris, "Extended field prostate biopsies: too much of a good thing?" *Urology*, vol. 55, no. 4, pp. 457–460, 2000.

[10] M. K. Terris and J. E. McNeal, "Application of tissue-marking ink to prostate biopsy specimens," *Prostate*, vol. 50, no. 4, pp. 247–251, 2002.

[11] J. Kao, M. Upton, P. Zhang, and S. Rosen, "Individual prostate biopsy core embedding facilitates maximal tissue representation," *Journal of Urology*, vol. 168, no. 2, pp. 496–499, 2002.

[12] F. Firoozi, T. Nazeer, H. A. G. Fisher, R. P. Kaufman Jr., M. D. White, and B. M. Mian, "Tissue-marking scheme for a cost-effective extended prostate biopsy protocol," *Urologic Oncology*, vol. 27, no. 1, pp. 21–25, 2009.

Hindawi Publishing Corporation
Prostate Cancer
Volume 2011, Article ID 270403, 7 pages
doi:10.1155/2011/270403

Review Article

Specimen Orientation by Marking the Peripheral End: (Potential) Clinical Advantages in Prostate Biopsy

Andrea Benedetto Galosi,[1] Giovanni Muzzonigro,[1] Vito Lacetera,[1] and Roberta Mazzucchelli[2]

[1] *Institute of Urology, Azienda Ospedaliero Universitaria, United Hospitals, Torrette, 60126 Ancona, Italy*
[2] *Section of Pathological Anatomy, School of Medicine, Marche Polytechnic University and Azienda Ospedaliero Universitaria, United Hospitals, 60126 Ancona, Italy*

Correspondence should be addressed to Andrea Benedetto Galosi, galosiab@yahoo.it

Received 19 May 2011; Accepted 25 May 2011

Academic Editor: R. Montironi

Copyright © 2011 Andrea Benedetto Galosi et al. This is an open access article distributed under the Creative Commons Attribution License, which permits unrestricted use, distribution, and reproduction in any medium, provided the original work is properly cited.

The aim of this paper is to identify advantages that could be obtained by orientation of the biopsy specimen using the marking technique. We reviewed our experience (4,500 cases) and the published literature. The peripheral (proximal) end of the fresh specimen is marked with ink soon after needle delivering in a few minutes. It is performed easily in association with pre-embedding method. Five potential clinical advantages were identified: (1) tumor localization, (2) atypical lesions localization and planning rebiopsy strategy, (3) planning surgical strategy, (4) selection criteria for focal therapy and active surveillance, and (5) cost reduction. Peripheral end marking is low cost, easy and reproducible. It drives several potential advantages in cancer diagnosis or isolated atypical lesions, in particular, spatial localization within the biopsy (transition versus peripheral zone, anterior versus posterior, subcapsular versus intraparenchima, and extraprostatic extension) should be easy and reliable. We can add a new pathological parameter: pathological orientation or biopsy polarity.

1. Introduction

PSA-driven diagnosis of Pca leads to overdiagnosis and overtreatment in part of the patient population [1]. With the advancement of active surveillance and image-guided focal therapies (brachytherapy, cryotherapy, and high-intensity focused ultrasound) as well as nerve-sparing radical surgery, the anatomical location of cancer at biopsy has become important and assumes a prominent role in treatment planning [2].

Several attempts [3, 4] have been made to improve the preoperative topographic distribution of prostate cancer in terms of number of positive cores, laterality, area of sampling (apex, mid, base), or anterior versus posterior gland. Even 3-dimensional prostate mapping based on transperineal saturation biopsy has been proposed to guide (focal or total) treatment strategy [5, 6].

Specimen orientation by marking the peripheral (proximal) end of the biopsy specimen may have several clinical advantages in order to improve the anatomical location of the cancer. Since transrectal ultrasound biopsy is the worldwide used technique for Pca diagnosis, marking the peripheral end of the core biopsy could easily identify the subcapsular tissue of the peripheral zone just close to the ultrasound probe. Only very few published papers describe the pros and cons of the marking technique [7–10].

Hypothetically, one could have four clinical scenarios if the marking of the peripheral (proximal) end of the biopsy is performed and reported by pathologist: (1) Pca reach the marked end, meaning that subcapsular peripheral zone is involved if transrectal biopsy has been used; (2) Pca is not in contact with the marked end, thus normal tissue is present in the subcapsular area, and the distance could be measured in each specimen; (3) both ends of the specimen are free of cancer, which could be interpreted as intragland cancer or tangential sampling of larger cancer located laterally to biopsy track; (4) Pca lies in the noninked end of the specimen (distal or anterior), which can be interpreted as anterior cancer.



Figure 1: Fresh specimens of PB pre-embedded in tissue cassettes. The peripheral end of each biopsy was marked using black ink.

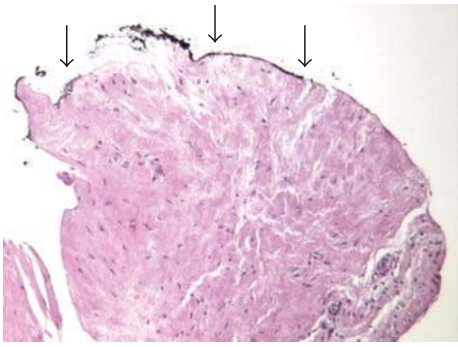

Figure 2: The inked end was always recognized at pathological analysis using microscope.

This hypothetical information could also be applied to isolated atypical lesions (or atipical small acinar proliferation, ASAP) detected on initial biopsy. Using marking techniques, we add more details on the anatomical location of ASAP that could be useful in the sampling strategy in case of repeat biopsy.

The aim of this study is to identify all advantages that could be obtained by orientation of the biopsy specimen using the marking technique. We reviewed our experience and the published literature.

2. Methods

A MEDLINE search using keywords and MeSH term ("Prostatic Neoplasms/pathology" (Mesh) AND "Biopsy" (Mesh) AND "Staining and Labeling" (Mesh) OR "quality" OR "marking" OR "inking" (all fields)) was performed for entries between 01-01-1966 to 03-03-2011. 93 articles were retrieved from the search. In order to evaluate all papers dedicated to tissue marking techniques on prostate biopsy (PB) specimens, we selected the 35 most relevant articles based on title and abstract. Furthermore we reviewed our prostate biopsy database composed by 4,500 cases, most of them using the pre-embedding technique plus inking the peripheral end of PB. We described our technique in previous reports [11, 12]. Therefore, results are based on literature search and our experience.

2.1. Technique of Marking Biopsy Specimen. The marking technique can be applied to pre-embedded specimens by urologists, radiologists, or nurses in few minutes just before formalin fixation (Figure 1). The marking technique cannot be applied to free-floating specimens in formalin vials [13].

The proximal end of the fresh biopsy specimen is marked with ink (usually black ink) on the bench soon after needle delivering. Then the specimen is placed on nylon mesh (or sponges) and then covered with another nylon mesh according to the pre-embedding methods of prostate needle biopsy specimens described by Rogatsch et al. [13]. The specimen is closed and stretched between 2 nylon meshes and placed in a tissue-labelled cassette. One or two biopsy specimens are collected in the same cassette identified by site and prostate lobe. Afterwards the tissue cassettes were submitted in containers filled with 10% buffered formalin to obtain complete specimen fixation and dehydration. After fixation, all tissue cores were embedded in paraffin blocks and then sectioned. The inked end was always easily recognized at the pathological analysis, also in our experience (Figure 2). We called the original pre-embedding technique "sandwich technique" with the addition of few modifications [11, 12].

(1) Nylon meshes (sponges) must be squeezed in saline solution to have fully soaked sponges (without air bubbles). This is very important preliminary step to biopsy specimen release, since it allows subsequent formalin diffusion and specimen fixation. If air bubbles were within the mesh, they could prevent formalin diffusion. Therefore only soaked sponge with saline solution allows complete specimen fixation and dehydration, without loss of ink. Furthermore, any potential dangerous exposure (patient or nurses) with formalin solution (contact or exhalation) is avoided using saline solution.

(2) Biopsy specimens are delivered from the needle directly on nylon mesh, in order to avoid any manipulation, or changes in orientation, or loss of fragmented cores.

(3) The procedure is sterile because meshes and cassettes can be treated in sterilization centre or prepacked.

Other authors [14] described that cassettes were soaked in a glass full of Bouin solution for 1 second before formalin to allow an ink fixation on the tissue. Our experience revealed that this technique was not needed and more time consuming.

Many leading genitourinary pathologists and guidelines [15, 16] recommend the pre-embedding technique, which is considered the best one for processing and submission of PB specimens. The multipack container kits [17] are technically more complex and costly [18]; however, in 2 clinical randomized studies [19, 20] and one experimental study [21], a decreased rate of equivocal diagnosis (atypical glands and ASAP).

3. Results

Marking technique is performed easily on the fresh specimen in association with pre-embedding method of prostate biopsy. The inked PB end was always recognized at pathological analysis by pathologists using microscope. Five potential clinical advantages were identified using prostate biopsy specimen orientation by marking the peripheral end. We review and discuss each advantage separately.

3.1. Tumor Localization. Prognostic information based on biopsy other than diagnosis and grading are to quantify tumor amount within the biopsy and to identify the location of "index lesion" [22].

Given that Pca involves the gland in 3 distinctive ways, with different clinical implications. Specifically, (1) Pca can involve the PZ through multiple or single Pca foci originating in different prostate zones; (2) Pca can involve the TZ only through multiple or single Pca foci; (3) through peripheral zone Pca, which extends into the TZ.

Specimen orientation by marking the peripheral (proximal) end could help in distinguishing these subgroups respectively (Figure 3): in the first subgroup, Pca harbours in the marked proximal end, therefore Pca involves the posterior subcapsular peripheral zone; in the second subgroup, Pca lies only in the noninked end of one or more specimens (distal), that could be interpreted as anterior zone or TZ cancer; finally the third subgroup, Pca lies in the whole specimen or both the ends of one or more specimens, that could be interpreted as PZ Pca, which extends into the TZ.

Using the marking technique, we can add a new pathological parameter: the cancer location within the biopsy specimen.

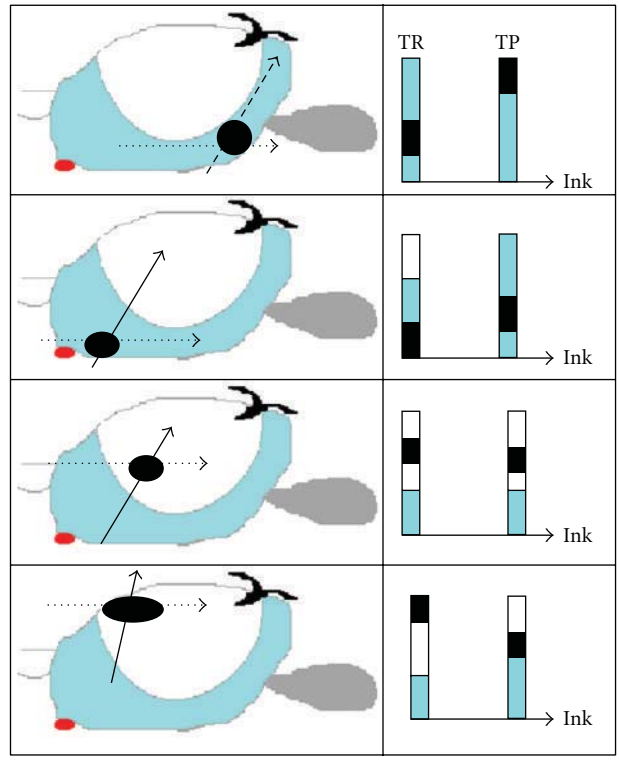

Figure 3: Simulation of biopsy histology corresponding to 4 different cancer foci (black circle) and normal tissue (light blue = PZ, white = TZ) in the prostate gland (longitudinal view) using 2 needle biopsy tracks: transrectal (TR; arrows) and transperineal (TP; dotted arrows). Ink = inked peripheral core end.

3.1.1. Anterior (TZ) versus Posterior (PZ) Cancer. Based on biopsy pathologist's report, the distinction between transition or peripheral cancer is not easy, unless the whole specimen is involved by cancer or the only positive biopsy is the TZ while all negative cores were taken from the PZ.

Inking the peripheral end of biopsy, the posterior or anterior cancer location should be easy and reliable. In particular when Pca touches the noninked end (distal), that could be interpreted as anterior cancer located in the subcapsular area (Figure 4) [23]. This pathological feature could have potential clinical advantage in the surgical management. Ponholzer et al. showed that men, with at least one core with cancer at the inked peripheral margin, had a 3.1-fold (95% CI: 1.1–9.9) increased risk for locally advanced tumour stage in the final surgical specimen [7].

Peripheral cancer has a poor prognostic outcome compared with transizion zone cancer [24], as Erbersdobler et al. [25] showed in cases matched for cancer volume. Although the distinction between subcapsular or anterior gland lesions on surgical whole specimen has been showen to have prognostic relevance, it remains unreliable on the biopsy specimen due to lacking of the specimen orientation. Therefore marking technique improves distinction between anterior and posterior Pca.

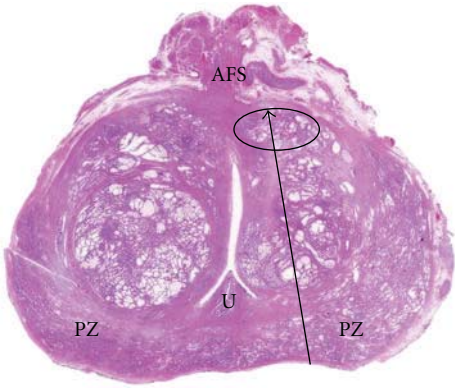

Figure 4: Transverse section of the whole prostate on histology after nerve-sparing surgery. The black circle shows the anterior cancer location. Anterior fibromuscular stroma (AFS), urethra (U). Biopsy track (arrow) in the anterior zone.

3.1.2. Subcapsular versus Non-Subcapsular Cancer. The pathology report may describe the distance or contact with the inked margins in cases of intraprostatic cancer (Figure 5). Pca is not in contact with the marked end, which means normal tissue is present in the subcapsular area, and the distance could be measured in each specimen.

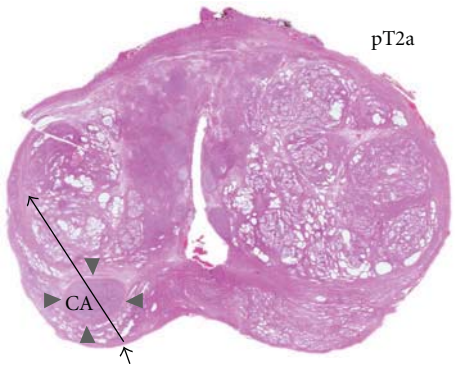

Figure 5: Transverse section of the whole prostate on histology showing peripheral cancer (black circle) and biopsy track (arrow). The cancer (CA) does not reach the capsule or the inked peripheral end (arrowhead) of biopsy specimen.

The mean core biopsy length is 14.5 mm measured on histology slide using a needle sample notch of 18 mm (MaxiCore Bard) in our experience [11, 12] and 14.1 mm in transperineal approach using standard Tru-Cut needle [26]. The distance from cancer to the inked peripheral end (pericapsular tissue) can be measured on slides. The distance depends on the degrees of the of incidence angle of the needle on the prostate. This angle is composed by the needle penetration axis and posterior capsule axis, which ranges 15°–89° (mean 30°) adopting transrectal approach.

3.1.3. Extraprostatic Cancer. Initially, the positive predictive value of an individual positive core for the location of extracapsular extension was considered not sufficient to guide the surgical decision to spare or excise a neurovascular bundle [27]. Therefore, the clinical information provided by individually labelled (cancer site itself) was previously stated not useful and not convenient to justify the increased associated costs [18]. Surprisingly, when Ponholzer et al. [7] considered the cancer location within the core (cancer located at the peripheral end of the specimen), they showed a significant correlation to pT3/pT4 stage ($P = 0.04$) in multivariate analyses of 100 cases.

The marking technique could be useful to biopsy orientation distinguishing which end of the PB contains nonprostate tissue: nerve fibres, seminal vesicle, striated muscle or adipose tissue, Cowper gland, and fibrous capsule. All these tissue may be involved by Pca. Intraprostatic nerves (large or small fibres) are located in all subcapsular areas, therefore orientation by marking one biopsy end helps in distinction from anterior versus posterior perineural invasion. Soft tissues are rarely sampled by biopsy; however, if the tumor invasion of soft tissue has been described in the pathology report, this defines extraprostatic invasion (T3). The posterior or anterior location of extraprostatic extension based on clinical parameters and specimen marking should be easy and reliable.

The distinction of posterior or anterior invasion has importance also for radiation therapist in order to improve local cancer control, given that imaging techniques are sometimes unreliable to detect early T3.

3.1.4. Application to Transperineal Biopsy. Using the transperineal approach, the needle biopsy track follows a longitudinal axis. The marking technique helps to distinguish proximal/apical (outer or perineal location) from distal/base (inner or cranial location). The advantages that we report for transrectal approach can be considered the same for transperineal.

3.2. Atypical Lesions (or ASAP) Localization, Planning Rebiopsy Strategy, and PIN. Hypothetically, one could have four clinical scenarios if marking the peripheral end of the biopsy has been reported after ASAP diagnosis.

(1) ASAP touches the marked proximal end. Therefore atypic glands are located in the subcapsular peripheral zone, thus missed cancer could be located more proximally to the point at which the biopsy needle was fired. Clinical implication in repeated biopsy is that the needle should be activated just before insertion into the prostate capsule in order to sample all of the subcapsular area.

(2) ASAP is not in contact with the marked proximal end or the distal end. That could be interpreted as tangential sampling of underlying cancer located laterally to the initial biopsy track: in particular when 2 ASAP foci are observed in the same specimen, the tangential sampling of lateral cancer should be suspected. Since ASAP has been interpreted [28–30] as tangential sampling of the underling cancer, additional biopsy should be taken also laterally to original ASAP track. Additional biopsy should be taken at the margins of the ASAP location according the transverse axis, far lateral and medial to former biopsy track, and according the longitudinal axis, proximal or distal to former biopsy track.

(3) ASAP lies in the noninked end of the specimen (distal), which could be interpreted as failed sampling of anterior cancer. Therefore atypic glands are located in the far anterior zone, thus missed cancer could be located more anteriorly to the point at which the biopsy needle is sampled. Clinical implication in repeated biopsy is that the needle should be inserted 1-2 cm deeper in order to sample all the anterior area including the subcapsular area according to gland anatomy.

These advantages must be considered as potential, since no case series have never tested the usefulness of the marking technique. Cancer detection rates on repeat biopsy for ASAP using an extended core biopsy scheme, the cancer detection rate remained as high as 36% to 59.1% [28] on first repeat biopsy and 16% on second repeat biopsy [29]. Because most cancers were found in the same region as the ASAP on repeat biopsy, and because 20% to 45% of cancers can be found outside the area of ASAP, a systematic Rebiopsy of the prostate is recommended by Canadian guidelines with additional targeted cores [30, 31].

Different PB techniques were used to minimize false-negative biopsies in repeat biopsy populations, in our experience and daily practice we use this information in addition to other clinical and pathologic features. Saturation biopsy may be considered in high-risk cases (e.g., rising PSA, abnormal DRE, persistent ASAP) with at least 2 previous negative extended biopsies [15]. The incidence of prostate cancer at the second and third biopsy using saturation biopsy scheme versus 18-core set was 22.6% versus 10.9% ($P = 0.02$) and 6.2% versus 0% ($P = 0.01$), respectively [32, 33].

As we described above for Pca and ASAP, we may detect high-grade PIN location, transition, or peripheral zone PIN based on marking technique. Clinical relevance of this information remains to be addressed by research studies.

3.3. Planning Surgical Strategy. In the era of extended biopsy schemes (10–18 cores), which are now the standard of care for detection of prostate cancer, the location of extracapsular extension on prostatectomy specimen correlated well with a positive biopsy site in 70% patients [10]. Preoperative reliable cancer map based on extended biopsy could be useful to reduce positive surgical margins. In fact, aims of surgery are improving control and reduce postoperative erectile dysfunction using intrafascial (pericapsular) gland dissection leaving of few mm of extraprostatic tissue or any tissue on the surgical specimen.

Previously, Rogatsch et al. [34] evaluated the rectal margin (inked) of each core biopsy and the distance from cancer to the inked rectal end, in a selected screening population using 10-core biopsy. They showed that the predictive value of an individual positive apical biopsy was only 28.8% for predicting surgical margin positivity. They concluded that the value of preoperative individually labeled cores and rectal end inking were limited. Results were incomplete because they did not analyse individually all labeled specimens. In fact, PB of the mid, anterior, and base of the prostate were placed together in a tissue cassette whereas specimens from the apex and transition zone were placed in separate cassettes.

Initially, Walsh [35] noted that surgical positive margin at the apex occurs during release of the dorsal vein complex and striated sphincter and not during nerve-sparing procedure. Recently, Nielsen et al. [36] modified initial poit of view introducing a link between apical dissection and nerve-sparing. In fact the high anterior release of the levator fascia in open radical retropubic prostatectomy provided excellent oncological results (1.3% positive margin) and was associated with improved postoperative sexual function (93% versus 77%). The proper selection criteria was based on Tsutzuki nomogram and cancer extent on apical biopsies [37]. The probability of side-specific extraprostatic extension was based on prostate needle biopsy pathology. They were able to predict with 90% accuracy which men would be ideal candidates for nerve-sparing surgery.

We suggest that the multiple measures of carcinoma extent (volume) in the biopsy, tumor grade associated with individually labeled biopsy, as well as cancer at the inked peripheral end (or distance) may be the best means of predicting the risk of extracapsular disease and/or a positive surgical margin.

Furthermore, tumor spread in prostate needle biopsy has become critical in the subsequent management of salvage treatment (surgery or cryoablation) for recurrent prostate carcinoma after radiotherapy. Mapping distribution of cancer based on biopsy is important to assess tumor spread, and it is essential for planning the salvage cryosurgery. The marking technique has a value to determine the level of depth of tumour (peripheral or periurethral, posterior or anterior) and planning of salvage cryoablation [38].

3.4. Selection Criteria for Focal Therapy (FT) and Active Surveillance (AS). The anatomical cancer localization has gained more clinical and prognostic relevance in focal treatment planning. Identification of index lesion: grade, anatomical extension (size, shape, side, and zone) has gained importance in focal treatment strategy. We believe that Pca orientation within each biopsy specimen could add useful information in this clinical setting.

In the selection of patients for FT, the transperineal saturation biopsy using the brachitherapy grid has been considered the best method to have three-dimension pathological mapping and to select patient to focal therapy [39]. Despite the requirement for general anaesthesia and a potential increased urinary retention rate, novel transperineal mapping schemes, when employing a brachytherapy grid template, allow for more accurate sampling of the entire gland. The remit of prostate biopsy now lies beyond pure diagnostics and has become an essential tool for determining the optimal therapeutic approach [39, 40]. The biopsy orientation and exact location of cancer within the specimen could be useful to depict anatomical location of Pca foci and to guide FT.

In the selection of patient for AS, the cancer location within the biopsy has not yet been considered a selection criterion. However, a different cancer location within the gland could not have the same natural history or the same success rate of therapeutic options: an example is given by subcapsular cancer or located at the edge of the gland: (1) early extraprostatic invasion has been observed in small volume Pca arising in the subcapsular tissue [41], (2) positive surgical margins have been reported in 1.5–38% Pca located at the edge of the apical/anterior even if intraprostatic (pT2). Therefore AS in small cancer located at the edge of the gland could have a negative impact on radical treatment.

4. Cost Reduction

The cost of histopathologic evaluation is based on number of individually labeled specimen containers. Submitting biopsy cores individually raises the cost of pathologic evaluation significantly while important prognostic information is lost when the samples are bundled into fewer containers. Marking technique is an easy method to reduce cut costs and specimen identifications. By reducing the number of specimen containers from 12 to 6, including 2 cores in each cassette, the potential savings may be in hundreds of million per year.

Firoozi et al. showed for the first time that marking tissue-labeling is a cost-effective manner in 452 cases, while maintaining ability to glean important prognostic information from each core [10].

This tissue-labeling technique was successfully applied by Scattoni et al. in 617 patients [14]. The 24 cores were put on sponge tissue in 7 different sandwich cassettes and individually inked (Figure 1) with different colors to mark the site from which they were collected. Each single core was individually marked (black, blue, green, and orange ink). They were able recognized to each specimen separately according to anatomical sampling (lateral, subcapsular, sextant, and transition zone cores) besides 3 or 4 biopsy specimens were collected in the same cassette.

Tissue-labeling protocol did not increase the procedure time or introduce any tissue artifacts.

5. Discussion

Our review supports marking the distal end of PB, since it allows spatial specimen orientation. Specimen orientation by ink marking is simple, reproducible, and does not require sophisticated technical aids. It takes approximately 2 min for the nurse to ink the cores at the peripheral end. It takes only few minutes for the incorporation into the final pathology report. It can be obtained without any patient discomfort or risk. Any tissue artefact was observed.

Furthermore the technique allows single specimen identification even if 2 or more cores are embedded in the same cassettes using different colours. Thus marking technique reduces costs while maintaining ability to glean important prognostic information from each core.

We showed the clinical implications in repeated strategy biopsy based on relationship between inked end and atypical lesion: site, depth of needle sampling, and lateral sampling adjusted in each case according tangential sampling of main cancer foci.

We reviewed that marking technique has several potential advantages for urologist and pathologist, but the scientific evidence in favour has been supported by expert opinion and small number of clinical studies derived from published literature. The pathological and anatomical correlation between biopsy and surgical specimen could be considered as good evidence to support this ancillary procedure. However, we defined clinical advantages as "potential" because further studies are needed to confirm all those advantages. These substantial benefits outweigh the additional effort by the pathologist.

6. Conclusions

Using the marking technique, we can add a new pathological parameter: pathological orientation or biopsy polarity. Cancer or atypical lesions can be accurately located within the biopsy specimen and integrated to biopsy approach. It drives several potential advantages in cancer diagnosis or isolated atypical lesions, in particular spatial localization within the biopsy (transition versus peripheral zone, anterior versus posterior, and subcapsular versus intraparenchima) should be easy and reliable.

Peripheral end marking is low cost, easy, and reproducible. It may also reduce costs allowing each specimen identification and analysis.

Abbreviations and Acronyms

AS: Active surveillance
ASAP: Atypical small acinar proliferation
FT: Focal therapy
PB: Prostate biopsy
Pca: Prostate cancer
PIN: Prostatic intraepithelial neoplasia
PZ: Peripheral zone
TRUS: Transrectal ultrasound
TZ: Transizion zone.

References

[1] P. C. Walsh, T. L. DeWeese, and M. A. Eisenberger, "Localized prostate cancer," *New England Journal of Medicine*, vol. 357, no. 26, pp. 2696–2705, 2007.

[2] L. Mearini and M. Porena, "Pros and cons of focal therapy for localised prostate cancer," *Prostate Cancer*, vol. 2011, Article ID 584784, 8 pages, 2011.

[3] R. Montironi, R. Vela-Navarrete, A. Lopez-Beltran, R. Mazzucchelli, and A. Bono, "2005 Update on pathology of prostate biopsies with cancer," *European Urology*, vol. 49, no. 3, pp. 441–447, 2006.

[4] B. Tombal, N. Tajeddine, J. P. Cosyns et al., "Does site-specific labelling and individual processing of sextant biopsies improve the accuracy of prostate biopsy in predicting pathological stage in patients with T1c prostate cancer?" *British Journal Urology International*, vol. 89, no. 6, pp. 543–548, 2002.

[5] S. Natarajan, L. S. Marks, J. Huang et al., "Clinical application of a 3D ultrasound-guided prostate biopsy system," *Urologic Oncology*, vol. 29, no. 3, pp. 334–342, 2011.

[6] G. Onik and W. Barzell, "Transperineal 3D mapping biopsy of the prostate: an essential tool in selecting patients for focal prostate cancer therapy," *Urologic Oncology*, vol. 26, no. 5, pp. 506–510, 2008.

[7] A. Ponholzer, M. Rauchenwald, A. Rainer-Concin et al., "Prostate cancer at the peripheral end of a prostate biopsy specimen as assessed by a novel marking technique may indicate increased risk of locally advanced disease," *Prostate Cancer and Prostatic Diseases*, vol. 14, pp. 69–73, 2010.

[8] A. B. Galosi and G. Muzzonigro, "Methods to obtain more clinical and pathologic information from needle core biopsy of the prostate gland," *Annals of the New York Academy of Sciences*, vol. 963, pp. 218–220, 2002.

[9] M. K. Terris and J. E. McNeal, "Application of tissue-marking ink to prostate biopsy specimens," *Prostate*, vol. 50, no. 4, pp. 247–251, 2002.

[10] F. Firoozi, T. Nazeer, H. A. G. Fisher, R. P. Kaufman Jr., M. D. White, and B. M. Mian, "Tissue-marking scheme for a cost-effective extended prostate biopsy protocol," *Urologic Oncology*, vol. 27, no. 1, pp. 21–25, 2009.

[11] A. B. Galosi, M. Dellabella, M. Polito Jr. et al., "A new method to embedd fragments of prostate biopsy: the "Sandwich" technique, preliminary experience," *Urologia*, vol. 68, no. 2, pp. 170–174, 2001.

[12] D. Minardi, A. B. Galosi, L. Dell'Atti, R. Montironi, and G. Muzzonigro, "Method to improve histopathological analysis of prostate biopsies: the "Sandwich" technique," *European Urology*, vol. 1, no. s1, p. 118, 2002.

[13] H. Rogatsch, P. Moser, H. Volgger et al., "Diagnostic effect of an improved preembedding method of prostate needle biopsy specimens," *Human Pathology*, vol. 31, no. 9, pp. 1102–1107, 2000.

[14] V. Scattoni, M. Raber, F. Abdollah et al., "Biopsy schemes with the fewest cores for detecting 95% of the prostate cancers detected by a 24-Core biopsy," *European Urology*, vol. 57, no. 1, pp. 1–8, 2010.

[15] A. El-Hakim and S. Moussa, "CUA guidelines on prostate biopsy methodology," *Journal of the Canadian Urological Association*, vol. 4, no. 2, pp. 89–94, 2010.

[16] A. Bertaccini, A. Fandella, T. Prayer-Galetti et al., "Systematic development of clinical practice guidelines for prostate biopsies: a 3-year Italian project," *Anticancer Research*, vol. 27, no. 1B, pp. 659–666, 2007.

[17] M. K. Terris, "Ultrasonography and biopsy of the prostate," in *Campbell's Urology*, P. C. Walsh, A. B. Retik, E. D. Vaughan et al., Eds., p. 3054, WB Saunders, Philadelphia, Pa, USA, 2002.

[18] S. S. Taneja, D. F. Penson, A. Epelbaum, T. Handler, and H. Lepor, "Does site specific labeling of sextant biopsy cores predict the site of extracapsular extension in radical prostatectomy surgical specimen?" *Journal of Urology*, vol. 162, no. 4, pp. 1352–1358, 1999.

[19] C. Gupta, J. Z. Ren, and K. J. Wojno, "Individual submission and embedding of prostate biopsies decreases rates of equivocal pathology reports," *Urology*, vol. 63, no. 1, pp. 83–86, 2004.

[20] H. Rogatsh, P. Moser, H. Volgger et al., "Cancer detection rate increased by optimised pre embedding procedures for prostate needle biopsies," *European Urology*, vol. 37, no. S2, p. 73, 2000.

[21] J. Kao, M. Upton, P. Zhang, and S. Rosen, "Individual prostate biopsy core embedding facilitates maximal tissue representation," *Journal of Urology*, vol. 168, no. 2, pp. 496–499, 2002.

[22] R. Montironi, R. Mazzucchelli, M. Scarpelli et al., "Prostate carcinoma II: prognostic factors in prostate needle biopsies," *British Journal Urology International*, vol. 97, no. 3, pp. 492–497, 2006.

[23] A. B. Galosi, M. Tiroli, D. Cantoro, A. Conti, and G. Muzzonigro, "Biopsy of the anterior prostate gland: technique with end-fire transrectal ultrasound," *Archivio Italiano di Urologia e Andrologia*, vol. 82, no. 4, pp. 248–252, 2010.

[24] M. Noguchi, T. A. Stamey, J. E. McNeal, and C. E. M. Yemoto, "An analysis of 148 consecutive transition zone cancers: clinical and histological characteristics," *Journal of Urology*, vol. 163, no. 6, pp. 1751–1755, 2000.

[25] A. Erbersdobler, H. Augustin, T. Schlomm, and R. P. Henke, "Prostate cancers in the transition zone: part 1: pathological aspects," *British Journal Urology International*, vol. 94, no. 9, pp. 1221–1225, 2004.

[26] V. Ficarra, G. Martignoni, G. Novella et al., "Needle core length is a quality indicator of systematic transperineal prostate biopsy," *European Urology*, vol. 50, no. 2, pp. 266–271, 2006.

[27] S. S. Taneja, D. F. Penson, A. Epelbaum, T. Handler, and H. Lepor, "Does site specific labeling of sextant biopsy cores predict the site of extracapsular extension in radical prostatectomy surgical specimen?" *Journal of Urology*, vol. 162, no. 4, pp. 1352–1358, 1999.

[28] M. Amin, S. Jeyaganth et al., "Subsequent prostate cancer detection in patients with prostatic intraepithelial noeplasia or atypical small acinar proliferation," *Canadian Urological Association Journal*, vol. 1, pp. 245–249, 2007.

[29] C. K. Moore, S. Karikehalli, T. Nazeer, H. A. G. Fisher, R. P. Kaufman, and B. M. Mian, "Prognostic significance of high grade prostatic intraepithelial neoplasia and atypical small acinar proliferation in the contemporary era," *Journal of Urology*, vol. 173, no. 1, pp. 70–72, 2005.

[30] K. A. Iczkowski, G. T. MacLennan, and D. G. Bostwick, "Atypical small acinar proliferation suspicious for malignancy in prostate needle biopsies: clinical significance in 33 cases," *American Journal of Surgical Pathology*, vol. 21, no. 12, pp. 1489–1495, 1997.

[31] S. Park, K. Shinohara, G. D. Grossfeld, and P. R. Carroll, "Prostate cancer detection in men with prior high grade prostatic intraepithelial neoplasia or atypical prostate biopsy," *Journal of Urology*, vol. 165, no. 5I, pp. 1409–1414, 2001.

[32] P. Pepe and F. Aragona, "Saturation prostate needle biopsy and prostate cancer detection at initial and repeat evaluation," *Urology*, vol. 70, no. 6, pp. 1131–1135, 2007.

[33] P. G. Borboroglu, S. W. Comer, R. H. Riffenburgh, and C. L. Amling, "Extensive repeat transrectal ultrasound guided prostate biopsy in patients with previous benign sextant biopsies," *Journal of Urology*, vol. 163, no. 1, pp. 158–162, 2000.

[34] H. Rogatsch, W. Horninger, H. Volgger, G. Bartsch, G. Mikuz, and T. Mairinger, "Radical prostatectomy: the value of preoperative, individually labeled apical biopsies," *Journal of Urology*, vol. 164, no. 3, pp. 754–758, 2000.

[35] P. C. Walsh, "Re: radical prostatectomy: the value of preoperative, individually labeled apical biopsies," *Journal of Urology*, vol. 165, no. 3, pp. 915–916, 2001.

[36] M. E. Nielsen, E. M. Schaeffer, P. Marschke, and P. C. Walsh, "High anterior release of the levator fascia improves sexual function following open radical retropubic prostatectomy," *Journal of Urology*, vol. 180, no. 6, pp. 2557–2564, 2008.

[37] T. Tsuzuki, D. J. Hernandez, H. Aydin, B. Trock, P. C. Walsh, and J. I. Epstein, "Prediction of extraprostatic extension in the neurovascular bundle based on prostate needle biopsy pathology, serum prostate specific antigen and digital rectal examination," *Journal of Urology*, vol. 173, no. 2, pp. 450–453, 2005.

[38] A. B. Galosi, F. Lugnani, and G. Muzzonigro, "Salvage cryosurgery for recurrent prostate carcinoma after radiotherapy," *Journal of Endourology*, vol. 21, no. 1, pp. 1–7, 2007.

[39] J. De La Rosette, H. Ahmed, J. Barentsz et al., "Focal therapy in prostate cancer-report from a consensus panel," *Journal of Endourology*, vol. 24, no. 5, pp. 775–780, 2010.

[40] J. L. Dominguez-Escrig, S. R. C. McCracken, and D. Greene, "Beyond diagnosis: evolving prostate biopsy in the era of focal therapy," *Prostate Cancer*, vol. 2011, Article ID 386207, 11 pages, 2011.

[41] A. B. Galosi, V. Lacetera, D. Cantoro et al., "Small volume ($<0.5\,cc$) prostate cancer: characteristics and clinical implications," *Urologia*, vol. 76, no. 4, pp. 236–241, 2009.

Hindawi Publishing Corporation
Prostate Cancer
Volume 2011, Article ID 693853, 5 pages
doi:10.1155/2011/693853

Research Article

Pseudolumen Size and Perimeter in Prostate Cancer: Correlation with Patient Outcome

Kenneth A. Iczkowski,[1,2] Kathleen C. Torkko,[1] Gregory R. Kotnis,[1] R. Storey Wilson,[1] Wei Huang,[3] Thomas M. Wheeler,[4] Andrea M. Abeyta,[1] and M. Scott Lucia[1]

[1] *Department of Pathology, University of Colorado Denver School of Medicine, Aurora, CO 80045, USA*
[2] *2100 Marble Cliff Office Park, Suite A, Columbus, OH 43215, USA*
[3] *Department of Pathology and Laboratory Medicine, University of Wisconsin, Madison, WI 53792, USA*
[4] *Department of Pathology and Immunology, Baylor College of Medicine, Houston, TX 77030, USA*

Correspondence should be addressed to Kenneth A. Iczkowski, iczkoka@usauro.com

Received 7 May 2011; Accepted 9 May 2011

Academic Editor: R. Montironi

Copyright © 2011 Kenneth A. Iczkowski et al. This is an open access article distributed under the Creative Commons Attribution License, which permits unrestricted use, distribution, and reproduction in any medium, provided the original work is properly cited.

We demonstrated in 2011 that 61% of men with postoperative PSA failure had some cribriform pattern of prostate cancer, versus 16% of nonfailures (OR = 5.89, $P < .0001$). That study used digitized radical prostatectomy slides from 153 men, 76 failures (≥0.2 ng/mL) matched to 77 nonfailures. The current study's hypothesis: pseudolumen size and shape variability could stratify outcome within histologic patterns (single separate acini, separate acini with undulating lumens, fused small acini, papillary, cribriform). Pseudolumens were filled digitally on image captures from previously annotated specimens. Among all 5 patterns, pseudolumen spaces averaged smaller in failures than nonfailures. After multivariate analysis controlling for stage, age, margin, cancer amount, prostate volume, and presence of individual cells (grade 5), this retained significance only for the undulating-lumens and papillary patterns. In undulating-lumens pattern, PSA failures had smaller mean pseudolumen space sizes ($P = .03$) but larger perimeters ($P = .04$), implying more pseudolumen irregularity. In papillary pattern, the number of pseudolumen spaces was higher in failures ($P = .015$), space size was smaller ($P = .11$), perimeters were smaller ($P = .04$), and perimeter/size ratio was higher ($P = .02$). In conclusion, digitally measured pseudolumen size and shape may associate with outcome.

1. Introduction

In 1966, a 5-tier prostate cancer grading system that relies entirely on architectural features was devised by Donald Gleason, who correlated patient outcome with the histologic patterns in 270 Veterans Administration patients [1]. The Gleason system is now recognized to predict pathologic stage and guides treatment choice. A few refinements have been introduced to the grading system, some by Gleason himself [2, 3]. Grades of 1 and 2, the lowest grades, have fallen into clinical irrelevance [4, 5], and grade 5 is fairly rare, and thus most cancers are grade 3, grade 4, or a combination of the two, creating three usual diagnostic bins. Gleason later designated a large acinar, undulating pattern of separate acini as pattern 3A and cribriform/papillary carcinoma as pattern 3C [3]. Cribriform cancer in 2000 was still deemed grade 3 [6], but the grading of cribriform cancer later became controversial [3, 7–10].

Within any pattern of cancer, there is a continuum of size, shape, and spacing of pseudolumens. The current work aims to discover whether these relative differences in pseudolumen morphology for any histologic pattern can substratify its association with outcome. We addressed this question by capturing images within a set of 153 previously scanned and annotated specimens [11], then annotating and analyzing the number, size, and shape of pseudolumens. Moreover, in our recent study, within the continuum of histologic patterns considered grade 4, the cribriform pattern was associated with a distinctly adverse outcome [11]. In the prostate cancer population that was studied, the frequency of any cribriform cancer was 38% of specimens: a higher frequency than the frequency of 23% for individual cells, the prototypical

Gleason grade 5. Yet, PSA failure was even more strongly associated with presence of cribriform pattern than with presence of individual cell pattern; thus, the current study paid special attention to cribriform pattern.

2. Materials and Methods

The study used the set of slides from 153 cases of prostate cancer that we published previously [11]. Men chosen for the study came from 3 medical centers: the University of Colorado Denver Hospital ($n = 44$), University of Wisconsin Health System ($n = 60$), and Methodist Hospital, Houston ($n = 49$). Exclusion criteria were a history of receiving cryotherapy, radiotherapy, or androgen deprivation before failure. All men had postoperative drops in PSA to undetectable. Most had Gleason score 7 cancer (95% in the 6–8 range). Biochemical failure was considered as a rise to ≥0.2 ng/mL, without evidence of later, lower measurements that would invalidate the 0.2. All but 2 nonfailures had at least 2 years' followup; 2 had between 1 and 2 years' followup. At all contributing sites, prostates were completely sampled at 4–6 mm intervals.

2.1. Histologic Pattern and Pseudolumen Annotation. Patients' entire prostatectomy slide sets had been re-reviewed. Those slides containing cancer (average per case, 8.0 ± 4.3) were digitally scanned as virtual slides using an Aperio ScanScope XT at a resolution of 0.50 um/pixel (Aperio Technologies, Vista, Calif) [11]. Using Image Scope software, all foci of 6 histologic patterns were previously manually annotated in a nonoverlapping manner, using a different color for each pattern, denoted as follow: (1) S: single, separate small acini like 3B pattern [3]; (2) U: undulated, stellate, or branching medium acini, like 3A pattern [3]; (3) F: fused, ragged small acini including those with mucin; (4) P: (micro)papillary consisting of medium to large spaces with either stromal cores or strands of cells with one or more cell layers bridging across the acinus, with intervening slit-like spaces; (5) C: cribriform, with medium to large acinar spaces having punched-out lumens (inclusive of the glomeruloid pattern [12]); (6) I: individual infiltrating or sheet-like cells lacking lumen formation. For each specimen, a representative 1500 × 1000 pixel section was captured from each annotated pattern (excluding I pattern, since it lacks lumens). All pseudolumen spaces in each image were further annotated using Photoshop. Annotated pseudolumen spaces were then analyzed for several different morphometric criteria using a custom written ImageJ plugin. Measurements for pseudolumen object frequency, area, circularity, perimeter, and maximum and minimum feret diameter were recorded and formatted for subsequent analysis.

Subsequent analysis was focused on the 48 specimens with cribriform pattern, of which 37 had PSA failure, compared to 9 without failure. For each, a second 1500 × 1000 pixel ImageScope snapshot was taken from cribriform areas, using cribriform foci from different slides than previous or different foci from the same slide, wherever possible ($n = 43$). In 5 cases the small size of the cribriform area precluded capturing two snapshots without overlap, so analysis was based on one snapshot. Pseudolumen space annotation and analysis were carried out as above.

2.2. Statistical Analysis. For each patient, biochemical failure status was recorded. To determine whether failure was related to any measurement for the patterns or to preoperative serum PSA, pathologic stage, grade, and margin status (but not Gleason score, owing to collinearity with the measured data), univariate and multivariate analyses were used. Only multivariate analysis results are displayed.

Depending on the distribution of the underlying data, either parametric or nonparametric tests were used to determine the associations of biochemical failure with clinical and pathologic parameters. Logistic regression analysis was used to test associations with failure while adjusting for potential confounding variables. All tests were two-sided, and significance level was set at $P < .05$. All analyses used SAS version 9.2 (SAS Institute, Cary, NC).

3. Results

The cases and controls were matched on length of followup, age at surgery, stage, and grade. Clinicopathologic data on their specimens, from which 1,100 slides were digitized and annotated, proved that a successful match was made on age and length of followup [11]. With our limited number of possible controls, however, stage and grade were not completely matched. To account for any mismatching, we adjusted our multivariate models for these potential confounders. Because we did match, or attempted to match on age, stage, grade, and length of followup, the independent relationship of these variables to PSA failure could not be assessed, as the distribution of these variables in controls did not represent a random sample.

By our definition of PSA failure, the 153 total patients comprised 76 (49.7%) with PSA failure and 77 (50.3%) without failure. Five had known metastases, and 6 had prostatic fossa recurrence. There were 5 deaths from prostate cancer (3.3%) and 2 from other causes in the study. As expected, patient age, follow-up days, and prostate volume were similar with respect to PSA failure status. 105 (68.6%) specimens were Gleason ≥7, 67 (43.8%) were stage T3, and 51 (33.3%) specimens had positive margins. Table 1 demonstrates that there were significant differences between the failures and nonfailures for many measurements for single separate acini, separate acini with undulating lumens, fused small acini, and papillary acini. As a general trend across all patterns, the mean pseudolumen space size was smaller in failures than in nonfailures. These differences were adjusted by multivariate analysis for preoperative serum PSA, pathologic stage, grade, and margin status, and the presence of the individual cell pattern (I) which by definition had to be a categorical variable due to having no annotatable lumens. Significance for odds ratios of failure persisted for the undulating-lumens and papillary patterns. In the undulating-lumens pattern (Figure 1), PSA failures had smaller mean pseudolumen space sizes ($P = .03$) but larger pseudolumen perimeters ($P = .04$), implying

Table 1: Pseudolumen measurements according to pattern, other than cribriform.

Histologic pattern	Nonfailures	Failures	Median for nonfailure	Median for failure	P value, Wilcoxon Rank Sum	Odds ratio, adjusted*	P value for odds ratio
Single separate acini	$n = 80$	$n = 68$					
No. of pseudolumen spaces			39.5	42.9	.49	0.997	.79
Size of spaces based on mean, μm^2			160	130	.03	0.998	.16
Perimeter of spaces, μm			233	204	.004	0.996	.09
Perimeter/size ratio			1.49	1.58	.17	1.29	.49
Undulating-lumen separate acini	$n = 61$	$n = 50$					
No. of pseudolumen spaces			34.0	30.5	.23	0.971	.06
Size of spaces based on mean, μm^2			342.9	314.5	.77	1.001	**.03**
Perimeter of spaces, μm			363	416	.69	1.002	**.04**
Perimeter/size ratio			1.19	1.21	.89	0.576	.39
Fused small acini:	$n = 62$	$n = 62$					
No. of pseudolumen spaces			47.5	46.5	.75	0.975	.98
Size of spaces based on mean, μm^2			66.5	49.1	.002	0.066	.07
Perimeter of spaces, μm			147	117	.002	0.153	.15
Perimeter/size ratio			2.21	2.46	.003	0.059	.06
True papillary acini	$n = 31$	$n = 43$					
No. of pseudolumen spaces			28.0	43.0	.008	1.05	**.015**
Size of spaces based on mean, μm^2			355.7	190.8	.025	0.99	.11
Perimeter of spaces, μm			382	262	.023	0.997	**.04**
Perimeter/size ratio			1.16	1.46	.061	4.77	**.02**

* By multivariate analysis adjusting for preoperative serum PSA, pathologic stage, grade, margin status, and the presence of the individual cell pattern.

Table 2: Pseudolumen measurements for the cribriform pattern.

Cribriform acini	Median for nonfailure, $n = 9$	Median for failure, $n = 39$	P value, Wilcoxon Rank Sum	Odds ratio, adjusted*	P value for odds ratio
No. of pseudolumen spaces	37	48	.552	1.022	.394
Size of spaces based on mean, μm^2	133.5	96.0	.125	0.987	**.048**
Perimeter of spaces, μm	206.2	167.5	.125	0.987	.070
Perimeter/size ratio	1.41	1.75	.178	7.076	.074

* By multivariate analysis adjusting for preoperative serum PSA, pathologic stage, grade, margin status, and the presence of the individual cell pattern.

more irregularity of the spaces. In the true papillary pattern (Figure 2), the number of pseudolumen spaces was higher in failures ($P = .015$), the size of spaces was smaller ($P = .11$), the perimeter of spaces was smaller ($P = .04$), and the perimeter/size ratio was higher ($P = .02$). The latter result again implies more irregularity of the spaces. These both stand in contrast to benign acini, which have large, open lumens (Figure 3).

For the cribriform pattern, some correlations based on one image capture per specimen were significant, and since our prior work had shown that the cribriform pattern carries the most adverse prognosis of all patterns examined [11], we chose to expand the data by capturing a second set of nonoverlapping cribriform cancer images from a different slide where possible. Notably, no specimen had any necrosis within the cribriform component and none of the cribriform areas fit the criteria for ductal carcinoma morphology [13–15]. In Table 2, the median of pseudolumen space size was smaller (133.5) in the failures compared to the failures (96.1) ($P = .048$). The median perimeter of pseudolumens was 167.5 in the failures versus 206.2 in nonfailures ($P = .070$). However, the perimeter/size ratio, describing the degree of lumen contour irregularity, was 1.75 in the failures, higher than the 1.41 in nonfailures ($P = .074$).

The individual cell (I)/Gleason 5 pattern was seen in 35 patients (23%) and in 13 (27%) of 48 specimens with cribriform pattern, all but one of which belonged to a man with PSA failure. A previous study had shown that C pattern frequently coexisted with I pattern, and these were multiplicative with regard to odds ratio for failure and probably minimized the independent associative value for the fairly rare I pattern [11]. Multivariate analysis, as above, considered the presence of I pattern. Size of pseudolumens retained significance ($P = .040$), and perimeter had borderline significance ($P = .058$). An increased perimeter/size ratio gave a high OR for failure, but this missed significance.

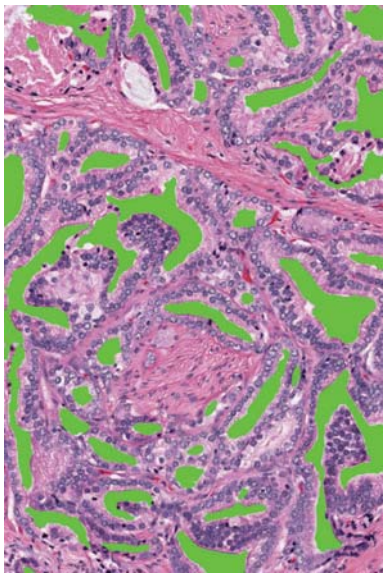

Figure 1: Image capture of undulating lumens grade 3 pattern, 1500 × 1000 pixels, after pseudolumen annotation. Lumens are very irregular; there is perineural invasion. Patient had PSA failure (100x).

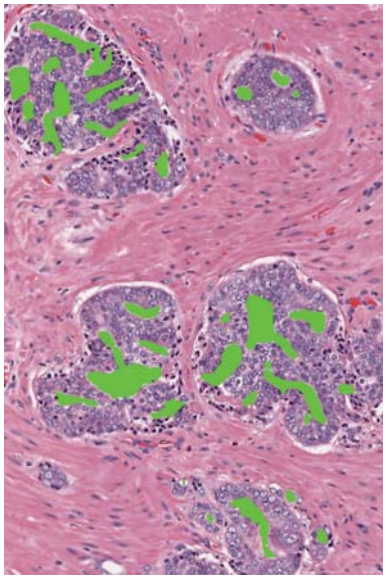

Figure 2: Image capture of true papillary grade 4 pattern, 1500 × 1000 pixels, after pseudolumen annotation. Note bridging across gland space. Patient had PSA failure (100x).

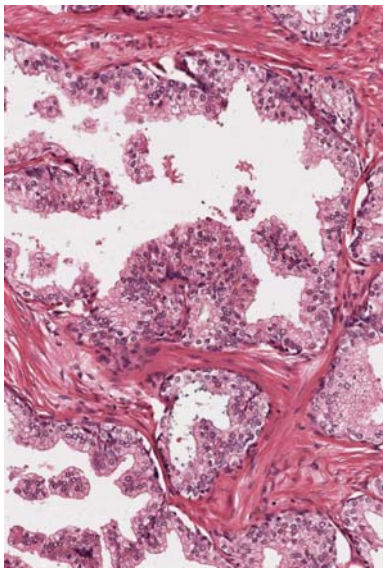

Figure 3: Benign prostatic acini can have undulating, or papillary lumens have lumens that are large and open, usually without bridging across the gland space except in the central zone. Pseudolumen spaces in cancer show various degrees of deviation from normal (100x).

4. Discussion

Large acinar (LA) prostate cancer, comprising the cribriform (C) and papillary (P) patterns, is associated with higher PSA failure odds ratios than other high-grade patterns [11]. Here we have shown, firstly, that there was a trend toward smaller lumen sizes in all 5 patterns. After adjusting for other clinicopathologic findings by multivariate analysis, this held significance for separate, medium-sized glands with undulating lumens and for the P pattern. For the undulating-lumens pattern, larger perimeter of the gland spaces was noted in men with PSA failure, suggesting that a greater complexity of infoldings in this Gleason grade 3 pattern correlates with advanced tumor development. Moreover, within the grade 4, P pattern, there were significant trends for increased number, smaller size, and greater irregularity (perimeter/size ratio) of pseudolumen spaces to be associated with PSA failure. This suggests that, as its epithelium assumes a more complex, nearly solid pattern, there is more advanced tumor development. Finally, the number of men with C pattern was too small of a sample set, with only 9 of 48 men without failure, precluding much statistical significance for its pseudolumen findings, but further study is warranted.

Cribriform and papillary (LA) cancers, as recently as 2000, were placed under grade 3 by a consensus statement of the College of American Pathologists [6]. Subsequent evidence for an elevated biologic potential of cribriform cancer came from Kronz et al., who, in their biopsy study of "atypical cribriform lesions," found that 55% of patients had cancer on repeat biopsy. Also, of 10 patients with subsequent carcinoma, 6 had a component of Gleason pattern 4 [9]. The International Society of Urological Pathology (ISUP) grading consensus conference of 2005 judged that most cribriform structures were grade 4, but those that were rounded and of comparable size to benign acini could be graded as grade 3 [7]. Cribriform pattern (small or large) was present in 60.5% of men with PSA failure but only 15.6% of matched men without failure, resulting in an odds ratio (OR) for PSA failure of 5.89, higher than for any other pattern. The adverse implications of cribriform pattern presence did not depend on whether the cribriform area was large and sprawling, or small, round, and circumscribed. Papillary (P) pattern, the other LA pattern, had a somewhat lower but significant

2.155 odds ratio for PSA failure [11]. Strikingly, among 17 cases with a preponderance of LA (cribriform and papillary) patterns amounting to 1/3 of cancer area, the odds ratio for failure reached 10.80. The ability of pseudolumen measurements to further stratify outcome within LA cancer warrants further investigation.

The only other digital analysis of the correlation of morphometric imaging features with clinical failure was that of Donovan et al. from Aureon Laboratories [16]. That study used a model that incorporated the spacing between epithelial tumor cells and the ratio of epithelial tumor cell area to total tumor area, in grade 3 cancer in prostatic needle biopsies. Combined with these morphologic data were quantitative multiplex immunofluorescence results and three clinicopathologic features. The current study, in contrast, assessed five pseudolumen-forming patterns identifiable in grades 3 and 4 cancer and indirectly approximated the percent of epithelium present by measuring the proportion of pseudolumen area in standard size images, as well as the shapes of those spaces. An asset of this approach is cost-effective outcome prediction without the need for immunofluorescence. A limitation was the inability to mark epithelium differently from stroma (which might be done in future studies using a reticulum stain, a technique that may have sharpened the discrimination of the observed associations).

Because of several other limitations of the current study, validation studies using unselected cases will be needed before results are applied to the population of prostate cancer patients diagnosed on biopsy. The first limitation was that PSA failures were enriched. Since failure is a rarer outcome than nonfailure, it was necessary to overrepresent failures in the matching process to try for statistical significance. Matching the nonfailures for stage, grade, and margins also skewed the nonfailure population to those with more adverse features. Second, the use of prostatectomy specimens was selected for those men who chose surgery and who probably had more aggressive cancer than average. This too was necessary, in order to quantify the entire cancer in the gland without the sampling error inherent in biopsies. A prospective study on biopsy material would be needed to represent the entire spectrum of men with cancer, some of whom elect watchful waiting, hormone ablation, radiation, or cryotherapy. Hence, this study's findings apply best to men who are surgical candidates. Finally, using PSA failure is a valid endpoint, but less definite than death from cancer; however, the study would have had to include many more men to amass a sufficient number of deaths.

5. Conclusion

Morphometry of the pseudolumens of certain acinar patterns—separate acini with undulating lumens, papillary, and cribriform—may correlate with biochemical failure in prostate cancer. Some limitations of this study render these results preliminary, but future studies should use an unselected population to examine the relationship of lumen size, shape, and spacing within annotated patterns to outcome.

References

[1] D. F. Gleason, "Classification of prostatic carcinomas," *Cancer Chemotherapy Reports. Part 1*, vol. 50, no. 3, pp. 125–128, 1966.

[2] D. F. Gleason, G. T. Mellinger, L. J. Ardving et al., "Prediction of prognosis for prostatic adenocarcinoma by combined histological grading and clinical staging," *Journal of Urology*, vol. 111, no. 1, pp. 58–64, 1974.

[3] D. F. Gleason, "Histologic grading of prostate cancer: a perspective," *Human Pathology*, vol. 23, no. 3, pp. 273–279, 1992.

[4] D. M. Berney, "Low Gleason score prostatic adenocarcinomas are no longer viable entities," *Histopathology*, vol. 50, no. 6, pp. 683–690, 2007.

[5] J. I. Epstein, "Gleason score 2-4 adenocarcinoma of the prostate on needle biopsy: a diagnosis that should not be made," *American Journal of Surgical Pathology*, vol. 24, no. 4, pp. 477–478, 2000.

[6] J. R. Srigley, M. B. Amin, D. G. Bostwick, D. J. Grignon, M. E. H. Hammond, and J. Schramm, "Updated protocol for the examination of specimens from patients with carcinomas of the prostate gland: a basis for checklists," *Archives of Pathology and Laboratory Medicine*, vol. 124, no. 7, pp. 1034–1039, 2000.

[7] J. I. Epstein, W. C. Allsbrook Jr., M. B. Amin et al., "The 2005 International Society of Urological Pathology (ISUP) consensus conference on Gleason grading of prostatic carcinoma," *American Journal of Surgical Pathology*, vol. 29, no. 9, pp. 1228–1242, 2005.

[8] L. Egevad, W. C. Allsbrook, and J. I. Epstein, "Current practice of Gleason grading among genitourinary pathologists," *Human Pathology*, vol. 36, no. 1, pp. 5–9, 2005.

[9] J. D. Kronz, A. A. Shaikh, and J. I. Epstein, "Atypical cribriform lesions on prostate biopsy," *American Journal of Surgical Pathology*, vol. 25, no. 2, pp. 147–155, 2001.

[10] M. Latour, M. B. Amin, A. Billis et al., "Grading of invasive cribriform carcinoma on prostate needle biopsy: an interobserver study among experts in genitourinary pathology," *American Journal of Surgical Pathology*, vol. 32, no. 10, pp. 1532–1539, 2008.

[11] K. A. Iczkowski, K. C. Torkko, G. R. Kotnis et al., "Digital quantification of five high-grade prostate cancer patterns, including the cribriform pattern, and their association with adverse outcome," *American Journal of Clinical Pathology*, vol. 136, no. 1, pp. 98–107, 2011.

[12] A. Pacelli, A. Lopez-Beltran, A. J. M. Egan, and D. G. Bostwick, "Prostatic adenocarcinoma with glomeruloid features," *Human Pathology*, vol. 29, no. 5, pp. 543–546, 1998.

[13] D. J. Grignon, "Unusual subtypes of prostate cancer," *Modern Pathology*, vol. 17, no. 3, pp. 316–327, 2004.

[14] D. A. Brinker, S. R. Potter, and J. I. Epstein, "Ductal adenocarcinoma of the prostate diagnosed on needle biopsy: correlation with clinical and radical prostatectomy findings and progression," *American Journal of Surgical Pathology*, vol. 23, no. 12, pp. 1471–1479, 1999.

[15] F. Tavora and J. I. Epstein, "High-grade prostatic intraepithelial neoplasialike ductal adenocarcinoma of the prostate: a clinicopathologic study of 28 cases," *American Journal of Surgical Pathology*, vol. 32, no. 7, pp. 1060–1067, 2008.

[16] M. J. Donovan, F. M. Khan, G. Fernandez et al., "Personalized prediction of tumor response and cancer progression on prostate needle biopsy," *Journal of Urology*, vol. 182, no. 1, pp. 125–132, 2009.

Hindawi Publishing Corporation
Prostate Cancer
Volume 2011, Article ID 249290, 10 pages
doi:10.1155/2011/249290

Review Article

Metastasis Update: Human Prostate Carcinoma Invasion via Tubulogenesis

Raymond B. Nagle[1] and Anne E. Cress[2]

[1] *Department of Pathology, The Arizona Cancer Center, The University of Arizona, Tucson, AZ 85724, USA*
[2] *Department of Cellular and Molecular Medicine, The University of Arizona, Tucson, AZ 85724, USA*

Correspondence should be addressed to Raymond B. Nagle, rnagle@email.arizona.edu

Received 1 March 2011; Accepted 25 April 2011

Academic Editor: Cristina Magi-Galluzzi

Copyright © 2011 R. B. Nagle and A. E. Cress. This is an open access article distributed under the Creative Commons Attribution License, which permits unrestricted use, distribution, and reproduction in any medium, provided the original work is properly cited.

This paper proposes that human prostate carcinoma primarily invades as a cohesive cell collective through a mechanism similar to embryonic tubulogenesis, instead of the popular epithelial-mesenchymal transformation (EMT) model. Evidence supporting a tubulogenesis model is presented, along with suggestions for additional research. Additionally, observations documenting cell adhesion molecule changes in tissue and stromal components are reviewed, allowing for comparisons between the current branching morphogenesis models and the tubulogenesis model. Finally, the implications of this model on prevailing views of therapeutic and diagnostic strategies for aggressive prostatic disease are considered.

1. Introduction

Most pathologists recognize prostate cancer as a series of polarized glandular structures lacking basal cells and varying in differentiation from lumen forming tubules to solid cords. These morphological observations are consistent with an invasion model in which cohesive groups of cells bud off from an in situ precursor lesion such as high-grade prostate intraepithelial neoplasia (HGPIN). Recent molecular marker expression studies are also consistent with this view. However, a prevalent view of prostate cancer invasion depicts single tumor cells invading the surrounding stroma, preceding vascular intravasation and dissemination. This widely held view of metastasis of epithelial cancers involves an epithelial-mesenchymal transformation (EMT) [1]. EMT of the malignant cells at the primary tumor allows for a motile invasive single-cell phenotype [1–4].

EMT is associated with the loss of epithelial-specific E-cadherin from the adheren junctions and a switch from the expression of keratins as the major intermediate filament to the mesenchymal intermediate filament, vimentin [5]. While this concept may be formally possible in epithelial cancers, it is rarely observed in prostate cancers except in the relatively rare Gleason Grade 5 tumors. In fact, others have noted that EMT in cancer invasion is not universally observed [6–8]. Additionally, some models state that, in the absence of EMT inducing signals, tumor cells may also reverse the process and undergo a mesenchymal to epithelial transition (MET) [9, 10]. This transient nature is proposed to explain why metastatic cells morphologically resemble primary tumor cells. An alternative possibility is that the cancer phenotype does not change and, therefore, requires no companion MET process. We propose that human prostate cancer invasion is an EMT-independent event. The invasive collective of tumor cells remain epithelial in nature—and, therefore, do not require a shift back to the epithelial phenotype. This review will challenge the applicability of the EMT concept for prostate cancer and offer an alternative idea: primary prostate cancers invade by a process similar to embryonic tubulogenesis.

2. Prostate Cancer Morphology

A modified grading system based upon Gleason scoring is used to describe prostate cancer morphology [11]. The majority of low Gleason Grade lesions and even Gleason

Grade 4 lesions arise from high-grade prostatic intraepithelial neoplasia (PIN) lesions and appear as invasive tubular structures (Figure 1).

Invasive tubular structures persist in lymph node metastatic lesions, as judged by prominent E-cadherin expression [12, 13], suggesting that prostate carcinoma invades by collective cell migration (see Friedl and Gilmour [14]), a process analogous to normal tubulogenesis. In embryologic tubulogenesis, coherent cells influenced by stromal factors initially migrate into the surrounding stroma as solid cords of cells. Later, lumina are formed and the cells develop polarity with their luminal surfaces facing a lumen and with their basal surfaces resting on a basal lamina [15]. In simple Grade 3 lesions, the polarity is complete. In cribiform Grade 3 and 4 lesions, the polarity is deranged with multiple lumina. In Grade 4, there is solid cord-like lesions form that lacks any lumina. The normal morphological alterations and modifications of the prostate gland yield important clues to the molecular events involved in the deregulation of the gland during cancer progression. In particular, prostate cancer tubulogenesis occurs in areas where the basal cells are lost and the basal lamina lacks laminin 332 (Figure 1).

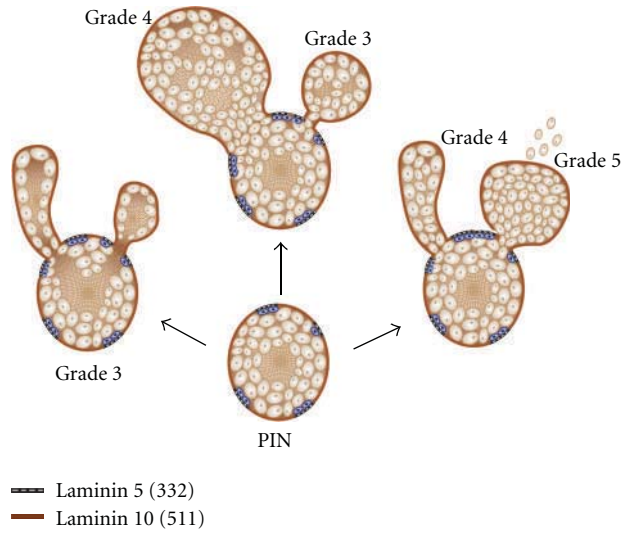

Figure 1: Tubulogenesis model of prostate cancer invasion. High-grade prostatic intraepithelial neoplasia (PIN) gives rise to various degrees of polarity and differentiation of cellular buds. PIN lesions are glandular-type structures characterized by gaps of laminin 10 (brown bar, laminin 10 (511)) and sporadic retention of basal cells (blue) attached to a laminin 5 matrix (laminin 5, 332). Three different patterns of spread (arrows) arise from PIN lesions. Note complete polarity and lumen formation (grade 3), partial lumen formation in cribiform lesion (grades 3-4 depending on size) and lack of lumen formation (grade 5). Importantly, budding occurs in areas where basal cells are lost, and the basal lamina lacks laminin 5 (332); the invasive budding clusters of cells are exposed to laminin 10 (511).

2.1. The Relationship of Prostate Glands to the Surrounding Stroma. The prostate gland, under the influence of androgen, develops from the endoderm-derived urogenital sinus to form branched tubuloalveolar glands [16]. These normal prostate glands are composed of two cell types, the basal cell and the secretory luminal cells [16]. The normal glands are surrounded by a delicate basal lamina containing laminins 111/121, 211, 332, and 511/521, as well as collagen IV and collagen VII [17]. The basal cells attach to this substratum through a number of integrins: $\alpha 2$, $\alpha 3$, $\alpha 4$, $\alpha 5$, $\alpha 6$, coupled with $\beta 1$ and $\alpha v\beta 3$ [18]. A dominant attachment occurs through hemidesmosomes via the $\alpha 6\beta 4$ integrin, an essential gene product, interacting at the c-terminal ends with anchoring filaments (laminin 332) that, in turn, interact with anchoring fibers (Collagen VII) [19]. Loss of the $\alpha 6\beta 4$ integrin function in normal epithelial tissues results in blistering diseases, indicating its essential role [20]. The architecture and assembly of ECM molecules in embryonic spaces provides a morphogenetic language or code that can promote or restrict cell movements and determine cell fate [21, 22]. In human prostate cancer, loss of $\alpha 6\beta 4$ integrin and type VII collagen is a universal feature [13, 18, 19, 23, 24]. In preclinical models, normal prostate cells have a robust DNA damage response dependent upon laminin [25]; early loss of the laminin receptor, $\alpha 6\beta 4$ expression, promotes tumor progression [26]. In the model proposed here, the documented loss of a dominant adhesion structure is permissive for the cohesive budding of cell clusters into the stroma.

The luminal cells are thought to arise from stem-type cells within the basal cell population [27]. The luminal cells are primarily secretory, express androgen receptors, and produce the proteins of the seminal fluid, including prostate specific androgen (PSA). Mitotic errors during intermediate stages of luminal cell development have been postulated as a possible origin for human prostate cancer [28]. In addition, recent work has indicated that luminal cells as compared to basal cells appear defective in their ability to invoke a DNA damage response [29].

Taken together, these observations suggest that loss of a dominant adhesion structure permits budding of cell clusters that are more susceptible to fixed DNA damage. In this context, we note that an accumulation of fixed DNA damage has been previously reported in human prostate cancer tissue [30]. Further, the loss of the normal glandular structure and the loss of fundamental positional cues would provide extracellular signals for invasive budding within a new environment, rich in laminin 511, an essential molecule in development that determines cell fate.

2.2. Changes during Prostate Cancer Progression. In PIN (prostatic intraepithelial neoplasia) lesions, cells with enlarged nuclei and often prominent nucleoli proliferate within the lumen, enlarging the glands and eventually causing the basal cell layer to become attenuated, resulting in continuity gaps. Interestingly, where the basal cells persist, the integrin expression and the hemidesmosomes also persist, including the underlying basal lamina that expresses laminin 332 [31]. In the gaps where the basal cells are lost, laminin 332 and the protein elements of the hemidesmosome are missing [18, 19, 23, 24]. The cells in these gap areas are attached in

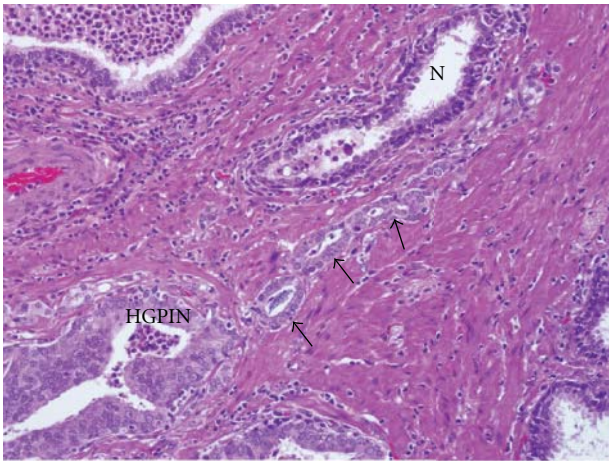

Figure 2: High grade PIN lesion showing budding invasive structure. PIN lesion (HGPIN) progressively changes into proximal lumen formation (arrows) and a distal solid cord of tumor cells. Normal prostate gland (N) is shown for comparison. H&E X400.

the gland via integrins $\alpha 6\beta 1$ and $\alpha 3\beta 1$ [32] and are reactive with an underlying basal lamina expressing laminin 511, a laminin important for epithelial tubulogenesis [33, 34] but not laminin 332. The cells making up the PIN lesions express a mixture of basal cell and luminal cell proteins, further suggesting origination in faulty mitosis [28] or defective DNA damage repair [29]. Analysis of a variety of morphologic nuclear features showed that these cells are very similar to invasive carcinoma cells and are already showing signs of genetic instability with a rate of aneuploidy similar to invasive carcinoma [35, 36].

Recent studies have shown that approximately 16% of PIN lesions show the rearrangement of the ETS-related gene (ERG) [37, 38]. TMPRSS-ERG (transmembrane serine protease) gene fusions are associated with the loss of $\alpha 6\beta 4$ integrin expression, the known regulator of hemidesmosome assembly. Numerous studies have associated early invasive carcinoma with these PIN lesions [27, 39–42]. Others have shown a discrepancy between the occurrence of high-grade PIN (HGPIN) and carcinoma, suggesting that HGPIN is not a precursor to invasive carcinoma [43, 44]. However, serial sectioning of HGPIN reveals invasive tubular structures arising from the PIN lesions (Figure 2, arrows).

The invasive cell clusters arise from gap regions that lack basal cells. The early detection of an invasive cell cluster is observed as a budding of atypical cells into the stroma (Figure 3). Of particular note is the lack of basal cells within the lesion (Figure 3, arrows) which corresponds to the known loss of dominant adhesion structures. As stated earlier, the invasive cells have lost hemidesmosomes and have a restricted $\alpha 6\beta 1$, $\alpha 3\beta 1$ integrin expression [19].

The lack of basal cells in the budding cancer clusters is confirmed by a loss of cytokeratin 5 and 14 expression (basal cell markers) and the corresponding loss laminin 332 (laminin 5) expression in the basal lamina, as observed in serial sections shown in Figure 4. Of particular interest is that while laminin 332 expression is lost in the budding lesion, another form of laminin, laminin 511 (laminin10), is abundant in the microenvironment, surrounding the glands vessels and prominently expressed in the stroma (Figure 4). Laminin 511 (LAM 10) is a potent morphogen essential for embryonic development and governs cell fate [34]. As stated earlier, invasive cancers express $\alpha 6\beta 1$ and $\alpha 3\beta 1$, laminin 511 binding integrins.

Further studies utilizing in situ hybridization techniques have shown that all three of the mRNAs encoding the three laminin 332 chains are present and have normal sequences, a finding that suggests the loss of protein expression is controlled at the translational level [24, 45]. These cells are polarized and have intact tight junctions as well as intact zonula adherens [46, 47]. In less differentiated grades, they may form cribiform glandular structures or solid trabecular structures lacking lumens.

2.3. Relationship of Prostate Cancer Invasion to Tubulogenesis. These early invasive events in which proliferating groups of cells maintain cellular adhesion and reestablish tubular structures closely resemble embryologic tubulogenesis. Knowledge of collective cellular migration (reviewed in Friedl and Gilmour [14]) is derived from several areas of embryology including the study of border cell migration in Drosophila oogenesis [48], tracheal branching morphogenesis in insects [49, 50], mammary gland development [51, 52], and lateral line organogenesis in zebra fish [53]. From studies in these and other systems, a concept of tubulogenesis has arisen in which a placode of cells in an originating epithelium gives rise locally to cells that migrate as a cohesive mass in response to promigratory and polarity-preserving signals produced by neighboring stromal cells. In order for these events to occur, there must be cell-cell cohesion, maintenance of polarity, cytoskeleton reorganization and force generation, extracellular matrix (ECM) remodeling, and stromal signal generation.

Although these processes are not as clearly understood in cancer as they are in normal embryogenesis, there is accumulating evidence that the process in cancer progression is similar. It is clear from immunohistochemical studies that low-grade prostate carcinomas maintain cell cohesion through components of the tight junction including Z01, claudins and occludin (see Martin and Jiang [47]), zonula adherens (E-cadherin, B-catenin, desmosomes) [46], as well as gap junction proteins and apical adhesion molecules such as CEACAM1 (carcinoembryonic antigen-related cell adhesion molecule 1) [54].

The maintenance of cell polarity is variable, with well-differentiated tumors forming basal-luminal polarity in the absence of basal cells. For example, E-cadherin and B-catenin are expressed in low-grade prostate adenocarcinoma (Figure 5). E-cadherin expression results in survival advantage for tumor cells [55, 56]. Specifically, E-cadherin dampens cellular motility behavior by biasing the direction of cell migration without affecting the migration rate. The results also demonstrated that there is cross-talk between E-cadherin and integrin-based adhesion complexes [57]. Integrin alpha 6 expression in human prostate carcinoma is

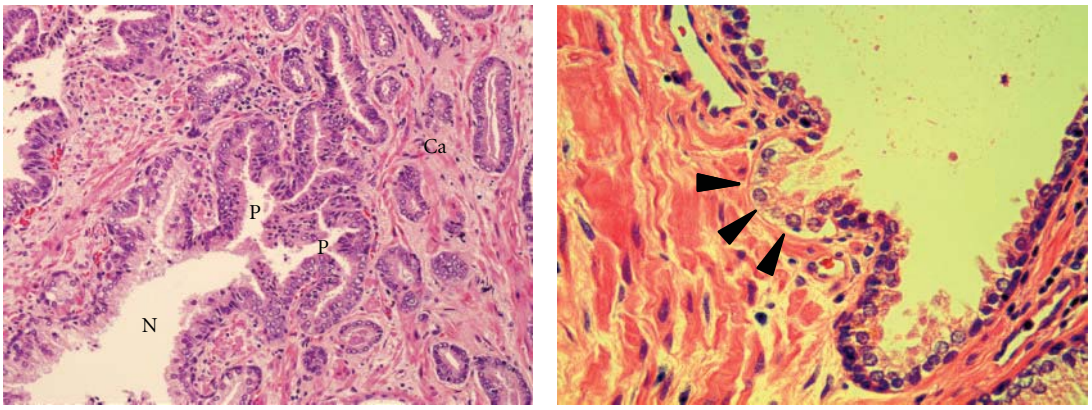

(a) (b)

Figure 3: Progressive morphological features of tubulogenesis in human prostate cancer. (a) is a tissue section stained with H&E X 200 and shows the transition of a normal prostate gland (N) to high-grade PIN (P) which has budded into invasive low-grade carcinoma (Ca). (b) is a tissue section stained with H&E X 400 demonstrating a prostate gland showing an early bud (arrows) of atypical cells. Note the absence of basal cells in the budding lesion.

associated with a migratory and invasive phenotype both in vitro and in vivo [58]. Taken together, these results would indicate that the preservation of E-cadherin and laminin-binding integrin expression in prostate cancer tubulogenesis could aid in the formation and direction of tubular growth.

Several reports have shown reduced expression of E-cadherin and B-catenin with increasing Gleason grade [59–61]. Murant et al. [59] made the interesting observation that there was a reciprocal increase of B1 integrin as E-cadherin decreased. Busch et al. [54] demonstrated that occludin, a component of the tight junctions, was expressed in low-grade prostate tumor but, with polarity loss, was downregulated in Gleason Grade 4 tumors and completely lost in Grade 5 tumors.

Tubulogenesis results in prostate cancer cells becoming attached to a newly synthesized basal lamina. In less differentiated tumors, complex cribiform structures are formed with multiple intraglandular lumina. The invasion process in human prostate carcinogenesis is slow, and little information is available regarding changes in cytoskeleton proteins at the leading edge of the invading tubular structure, although these contractile proteins are known to be important in normal tubulogenesis [15].

It is also clear that there must be initial ECM degradation and regeneration of new basal lamina to support the tubular structures. Studies of invading cells in liquid culture or 3D gels demonstrate two surface metalloproteinase molecules, MTIMMP and MMP2, which degrade the ECM along the leading cells [61, 62]. Our own studies of invasion utilizing an xenograft model of DU145 human prostate cells seeded onto the murine diaphragm revealed tumor colonization of the surface. Collective cell invasion was induced when the tumor cells were permanently transfected to express the metalloproteinase MMP7 [63]. The murine diaphragm surface mimics the stroma of the prostate and contains a vascular supply, sensory and motor nerve endings, stromal fibroblasts, and muscle cells, making it a useful model environment [64]. All of these cell types are potential sources of stimulatory factors.

Invasion of oral squamous cell carcinoma in vitro reportedly has been stimulated by paracrine SDF1 and hepatocyte growth factor produced by stromal fibroblasts driven by tumor cell-derived cytokines [65]. There is an extensive literature describing the role of hepatocyte growth factor (HGF) and its receptor c-Met in prostate cancer progression (see Hurle et al. [66]). Interaction of HGF with its receptor has been demonstrated to modulate cell proliferation, tumor cell interaction, cell migration, cell-matrix adhesion, cell invasion, and angiogenesis in prostate cancer cells (Figure 6). Other factors such as FGF and TGF-b have been also implicated in the stimulation of tumor cell invasion [3, 67].

Another signaling factor known to be important in normal embryonic epithelial modeling is the Wnt pathway, which is involved in cell fate specification, proliferation, polarity, and migration [68]. Both the classic pathways—involving a variety of Wnt ligands binding to the Frizzle receptor and resulting in β-catenin transcription—and the non-Canonical pathway [68] demonstrate activity in prostate cancer (see Yardy and Brewster [69]). Studies have shown that β-catenin interacts with the androgen receptor, perhaps further indicating its relevance to prostate cancer progression [70].

Cells that eventually intravasate into vessels, it seems, leave the active tips of the tubular invasive structures. Single-cell migration into vessels would represent a form of EMT, a possible late event in tubulogenesis, but this needs more detailed documentation and validation. Moreover, there is some evidence that even these intravascular cells retain cohesive properties and actually travel as small groups of attached cells [14]. A careful analysis of changes occurring at the tips of these tubular structures is likely to produce important information that may become the cornerstone of new diagnostic and therapeutic treatments aimed at preventing prostate carcinoma metastasis.

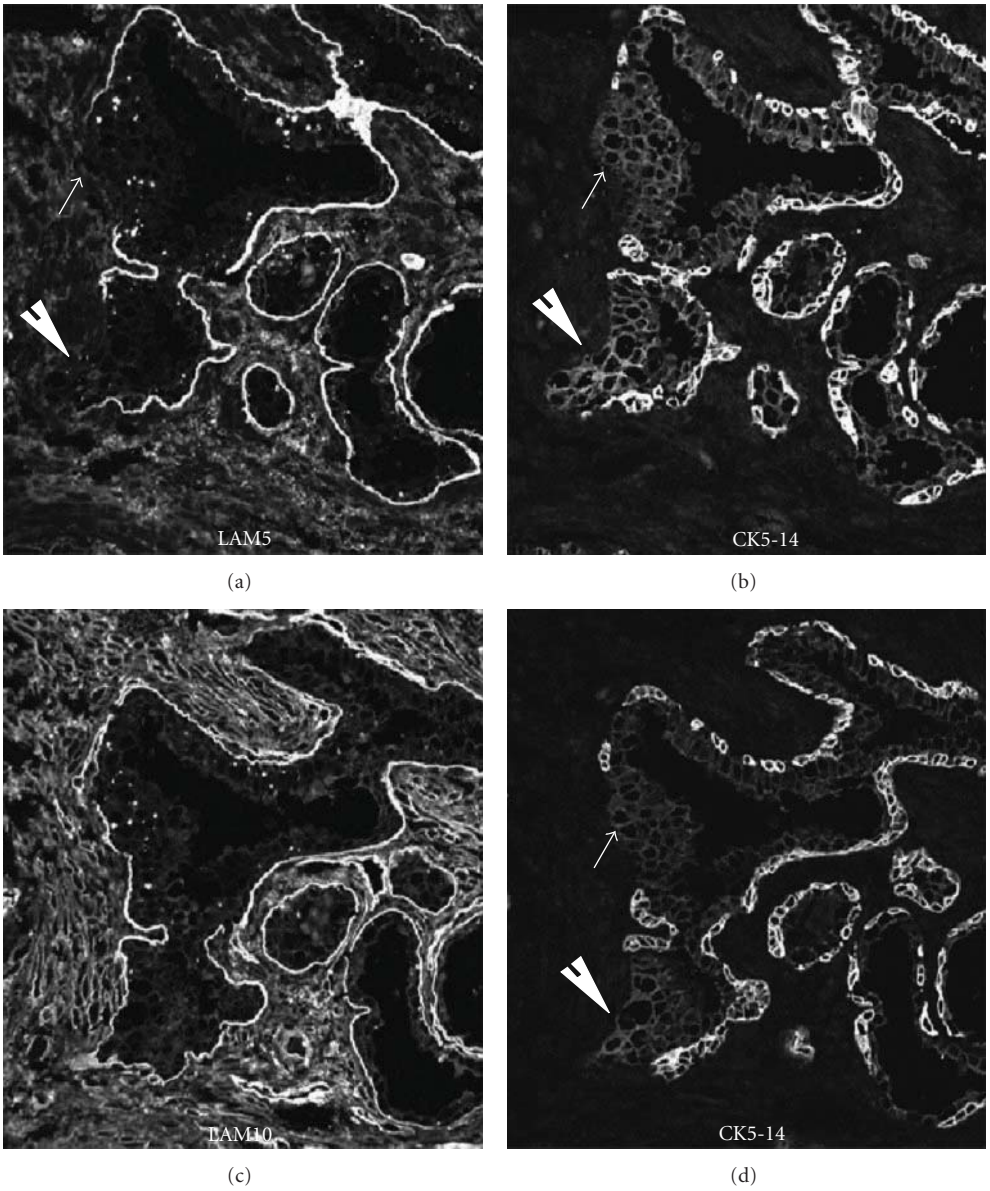

Figure 4: Budding lesions are devoid of basal cells and lack laminin 5 deposition and become exposed to laminin 10. Serial sections containing cell clusters (white arrows) were stained either for laminin 332 (LAM5) or laminin 511 (LAM10) and the basal cell-specific marker, cytokeratin 5 and 14 (CK5-14).

There is considerable evidence that nerves within the peripheral zone in proximity to prostate cancer facilitate tumor penetration of the capsule [67, 71]. Perineural prostate carcinoma growth is routinely observed in areas of extra prostatic extension, where these carcinomas can maintain polarity (Figure 7) and have been observed lining up along the basement membrane.

Invasive cancer invading stroma and then traveling along neural structures has been observed in pancreatic cancer, using serial sectioning methods to reveal tumors growing in a continuous fashion [72]. While similar studies have not been published describing this event in prostate cancer, we infer that tubular structures of invading prostate carcinoma would encounter nerve structures and then travel along these conduits finally reaching the para-prostatic connective tissue [73]. It is not clear at what juncture these cells would intravasate into vascular structures, but it is clear that perineural prostate cells are not within vessel lumens, despite growing in close proximity to lymphatic vessels.

2.4. Implications of the Tubulogenesis Model of Prostate Cancer Progression. There is a pressing need for biomarkers that distinguish indolent from aggressive prostate cancer. It is estimated that 30 to 50% of men diagnosed with prostate cancer could avoid surgery or radiation (and instead be followed by active surveillance) because they have "good prognosis" tumors that are unlikely to progress [74]. Further,

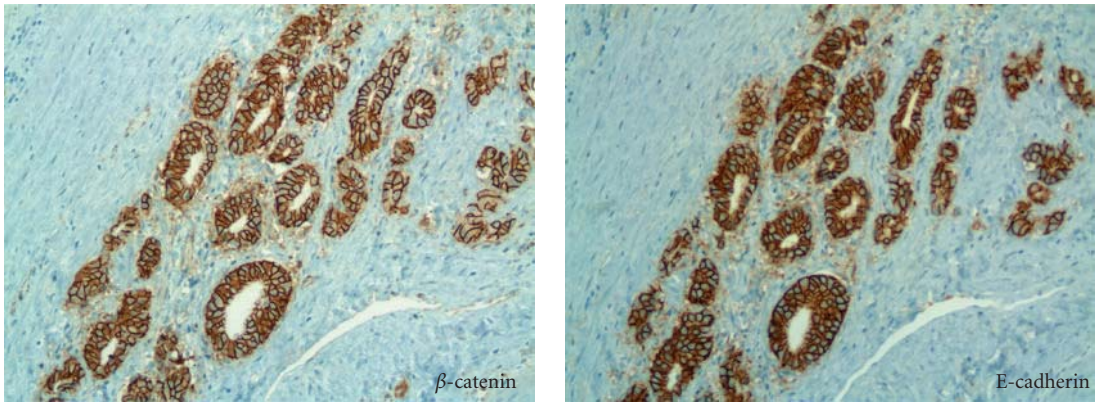

(a) (b)

Figure 5: Preservation of epithelial marker expression in invasive prostate carcinoma. Serial sections of Gleason Grade 3 prostate carcinoma reacted in (a) with anti-B-catenin and (b) reacted with anti-E-cadherin. Note maintenance of intracellular adhesion and polarity in invasive carcinoma. X 200.

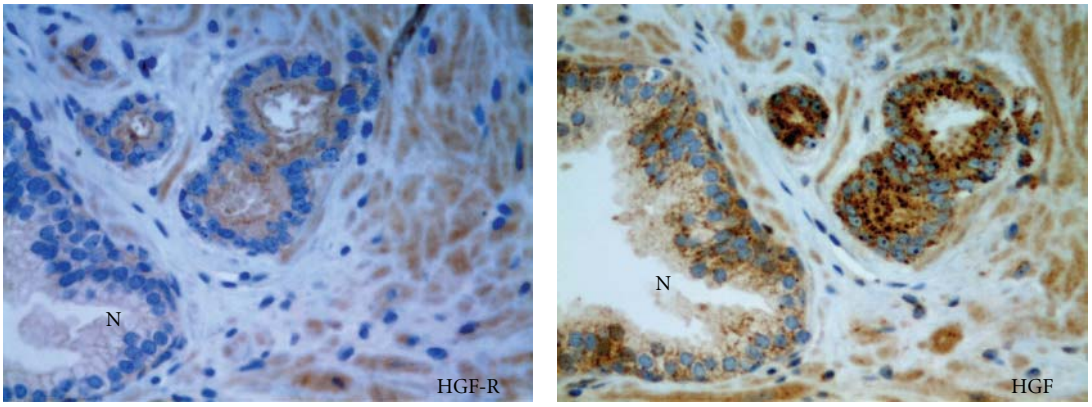

(a) (b)

Figure 6: Increased expression of a morphogenic growth factor and receptor in invasive budding cancer. Serial sections of Gleason Grade 3 prostatic carcinoma and normal gland (N) reacted in (a) with anti-c-Met (aka Hepatocyte Growth Factor (HGF) receptor) and (b) reacted with anti-HGF. X 400.

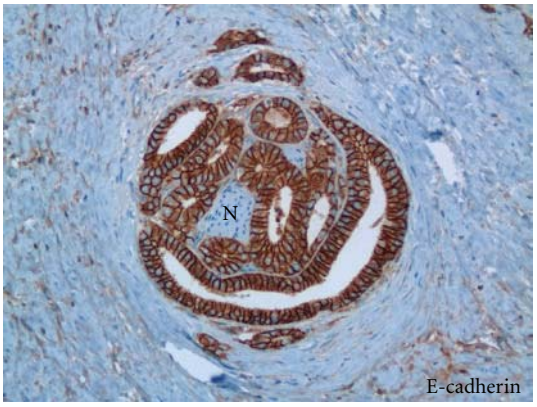

Figure 7: Invasive perineural prostate cancer maintains cell polarity and intracellular adherence. Tissue section of prostate carcinoma reacted with anti E-Cadherin antibody and surrounding a nerve (N). X 400.

recent reports indicate that approximately 50% of patients that are classified as high risk do not develop metastases and 10% of patients classified as low risk develop secondary disease [75]. The critical need for biomarkers has led to integrative genomic profiling of human prostate cancer to annotate alterations corresponding to clusters of low- and high-risk disease beyond that achieved by the Gleason Score [76].

Taylor et al. [76], in a hallmark study, combined methods of pathologist-guided dissection with comprehensive genomic analysis and clinical outcome data. Transcriptomes were defined and copy number alterations documented in 218 prostate tumors (181 primaries and 37 metastases). Several known cancer pathways were observed in human prostate cancer, and the study revealed that nearly all metastases contained changes in P13K, RAS/RAF, and androgen receptor pathways. Independent work examining tumor cells within bone marrow revealed a loss of cell adhesion

components in disseminated tumor cells as a potential harbinger of aggressive disease [75].

Extending the primary tumor analysis approach to understanding the signatures of invasive budding tumors, rather than analysis of the entire cancer specimen, would likely reveal aggressive subsets of tumors. Prostate cancer is multifocal, and intratumor genomic heterogeneity is a well-known phenomenon [77]. Restricting analysis to the invasive tips of the tumor may clarify the relevance of the molecular signatures for identifying aggressive disease. The inherent difficulty in distinguishing the budding cancer from the tumor epicenter will require developing improved strategies of tissue analysis. Recent studies have used a strategy of multiplexed quantum dot mapping to begin providing correlated molecular and morphological information [78]. In other studies, terminal end buds (TEB) during mammary branching morphogenesis have been microdissected, and the transcriptomes identified; specific gene signatures are associated with TEB [79]. A similar strategy could be utilized to define budding prostate cancer from the bulk of the tumor.

In a similar fashion, the responsiveness of the tumor to therapeutic approaches, such as radiation therapy, may be dictated by the degree to which tubulogenesis has been activated. It is well known that the bulk of prostate cancer is relatively radiation resistant as compared to other tumor types. As a slow growing tumor, it is generally considered a tumor type that can be successfully treated using hypofractionation at fractional doses up to 2.8 Gy, since tumor repopulation is not a factor [80]. Other groups are testing whether hypofractionated stereotactic body radiation therapy (19.5 Gy in 3 fractions) followed by intensity-modulated radiation therapy (IMRT) (dose of 50.4 Gy in 28 fractions) offers radiobiological benefits of a large fraction boost for dose escalation. The goal is to achieve a well-tolerated treatment option for men with intermediate- to high-risk prostate cancer [81]. Understanding the biological responsiveness of invasive budding tumor cells and the extent of their activation as compared to the bulk of the tumor are likely to increase the biological effectiveness of the therapy and limit normal tissue damage.

Preclinical xenograft and tissue culture studies revealed the phenomenon of cell adhesion-mediated radiation resistance (CAM-RR) [82–90]. CAM-RR can be overcome by the loss of tumor cell adhesion to the extracellular matrix [25, 86, 90, 91]. Since the tubulogenesis model of invasive cancers involves the loss of cell adhesion, one would predict that an increased efficacy of radiation therapy to block invasive tubulogenesis may be possible using lower doses and lower fractions of radiation therapy than is currently prescribed. As stated above, such an approach may prove more effective and potentially reduce damage to surrounding tissue.

3. Summary

The tubulogenesis model proposes that primary carcinomas of the prostate invade by a budding process similar to embryonic tubulogenesis. The majority of tumors arise from HGPIN lesions with the invasion occurring in portions of the gland where basal cells are lost, and the basal lamina is altered. If the tubulogenesis is complete, well-polarized tubules are formed which are recognized as low Gleason grade carcinoma; partial failure of polarity and lumen formation results in cribiform lesions; complete failure leads to the solid trabecular formations of Gleason grade 4 lesions.

EMT is not observed in prostate carcinoma specimens either by direct morphological assessment or by immunohistochemical analysis of tissue using specific markers of EMT. If the EMT process does occur in the disease, it may occur as a late phenomenon most likely at the growing tips of the tubular structures. Lastly, a careful molecular analysis of the changes occurring at the tips of these tubular studies is likely to produce important information. Understanding molecular networks at the invasive tips may become the cornerstone of new diagnostic biomarkers to distinguish aggressive from indolent disease and to customize therapeutic treatments for preventing prostate carcinoma spread.

Acknowledgments

The authors thank the staff at the tissue acquisition and molecular analysis core service (TACMASS) at the Arizona Cancer Center for tissue section staining and Biomedical Communications (Arizona Health Sciences Center) for graphic art support. Editorial assistance by William L. Harryman is appreciated. This work was supported by National Institutes of Health Grants CA-56666 (to RBN and AEC) and CA23074.

References

[1] J. J. Christiansen and A. K. Rajasekaran, "Reassessing epithelial to mesenchymal transition as a prerequisite for carcinoma invasion and metastasis," *Cancer Research*, vol. 66, no. 17, pp. 8319–8326, 2006.

[2] E. D. Hay, "The mesenchymal cell, its role in the embryo, and the remarkable signaling mechanisms that create it," *Developmental Dynamics*, vol. 233, no. 3, pp. 706–720, 2005.

[3] J. M. Lee, S. Dedhar, R. Kalluri, and E. W. Thompson, "The epithelial-mesenchymal transition: new insights in signaling, development, and disease," *Journal of Cell Biology*, vol. 172, no. 7, pp. 973–981, 2006.

[4] S. Grünert, M. Jechlinger, and H. Beug, "Diverse cellular and molecular mechanisms contribute to epithelial plasticity and metastasis," *Nature Reviews Molecular Cell Biology*, vol. 4, no. 8, pp. 657–665, 2003.

[5] D. R. Hurst and D. R. Welch, "Metastasis suppressor genes at the interface between the environment and tumor cell growth," *International Review of Cell and Molecular Biology*, vol. 286, pp. 107–180, 2011.

[6] R. D. Cardiff, "Epithelial to mesenchymal transition tumors: fallacious or snail's pace?" *Clinical Cancer Research*, vol. 11, no. 24, pp. 8534–8537, 2005.

[7] R. D. Cardiff, "The pathology of EMT in mouse mammary tumorigenesis," *Journal of Mammary Gland Biology and Neoplasia*, vol. 15, pp. 225–233, 2010.

[8] D. Tarin, E. W. Thompson, and D. F. Newgreen, "The fallacy of epithelial mesenchymal transition in neoplasia," *Cancer Research*, vol. 65, pp. 5996–6000, 2005.

[9] H. Hugo, M. L. Ackland, T. Blick et al., "Epithelial—Mesenchymal and mesenchymal—epithelial transitions in carcinoma progression," *Journal of Cellular Physiology*, vol. 213, no. 2, pp. 374–383, 2007.

[10] C. L. Chaffer, J. P. Brennan, J. L. Slavin, T. Blick, E. W. Thompson, and E. D. Williams, "Mesenchymal-to-epithelial transition facilitates bladder cancer metastasis: role of fibroblast growth factor receptor-2," *Cancer Research*, vol. 66, no. 23, pp. 11271–11278, 2006.

[11] J. I. Epstein, W. C. Allsbrook, M. B. Amin et al., "The 2005 International Society of Urological Pathology (ISUP) consensus conference on Gleason grading of prostatic carcinoma," *American Journal of Surgical Pathology*, vol. 29, no. 9, pp. 1228–1242, 2005.

[12] A. M. De Marzo, B. Knudsen, K. Chan-Tack, and J. I. Epstein, "E-cadherin expression as a marker of tumor aggressiveness in routinely processed radical prostatectomy specimens," *Urology*, vol. 53, no. 4, pp. 707–713, 1999.

[13] J. Pontes-Junior, S. T. Reis, M. Dall'Oglio, L. C. Neves de Oliveira, and J. Cury, "Evaluation of the expression of integrins and cell adhesion molecules through tissue microarray in lymph node metastases of prostate cancer," *Journal of Carcinogenesis*, vol. 8, p. 3, 2009.

[14] P. Friedl and D. Gilmour, "Collective cell migration in morphogenesis, regeneration and cancer," *Nature Reviews Molecular Cell Biology*, vol. 10, no. 7, pp. 445–457, 2009.

[15] B. L. Hogan and P. A. Kolodziej, "Organogenesis: molecular mechanisms of tubulogenesis," *Nature Reviews Genetics*, vol. 3, no. 7, pp. 513–523, 2002.

[16] A. A. Thomson and P. C. Marker, "Branching morphogenesis in the prostate gland and seminal vesicles," *Differentiation*, vol. 74, no. 7, pp. 382–392, 2006.

[17] J. D. Knox, A. E. Cress, V. Clark et al., "Differential expression of extracellular matrix molecules and the α 6-integrins in the normal and neoplastic prostate," *American Journal of Pathology*, vol. 145, no. 1, pp. 167–174, 1994.

[18] A. E. Cress, I. Rabinovitz, W. Zhu, and R. B. Nagle, "The α 6 β 1 and α 6 β 4 integrins in human prostate cancer progression," *Cancer and Metastasis Reviews*, vol. 14, no. 3, pp. 219–228, 1995.

[19] T. L. Davis, A. E. Cress, B. L. Dalkin, and R. B. Nagle, "Unique expression pattern of the $\alpha 6\beta 4$ integrin and laminin-5 in human prostate carcinoma," *Prostate*, vol. 46, no. 3, pp. 240–248, 2001.

[20] L. Pulkkinen and J. Uitto, "Hemidesmosomal variants of epidermolysis bullosa: Mutations in the $\alpha\beta$ integrin and the 180-kD bullous pemphigoid antigen/type XVII collagen genes," *Experimental Dermatology*, vol. 7, no. 2-3, pp. 46–64, 1998.

[21] T. Rozario and D. W. DeSimone, "The extracellular matrix in development and morphogenesis: a dynamic view," *Developmental Biology*, vol. 341, no. 1, pp. 126–140, 2010.

[22] C. H. Streuli, "Integrins and cell-fate determination," *Journal of Cell Science*, vol. 122, no. 2, pp. 171–177, 2009.

[23] R. B. Nagle, J. Hao, J. D. Knox, B. L. Dalkin, V. Clark, and A. E. Cress, "Expression of hemidesmosomal and extracellular matrix proteins by normal and malignant human prostate tissue," *American Journal of Pathology*, vol. 146, no. 6, pp. 1498–1507, 1995.

[24] J. Hao, Y. Yang, K. M. McDaniel, B. L. Dalkin, A. E. Cress, and R. B. Nagle, "Differential expression of laminin 5 (α 3 β 3 γ 2) by human malignant and normal prostate," *American Journal of Pathology*, vol. 149, no. 4, pp. 1341–1349, 1996.

[25] C. L. Kremer, M. Schmelz, and A. E. Cress, "Integrin-dependent amplification of the G2 arrest induced by ionizing radiation," *Prostate*, vol. 66, no. 1, pp. 88–96, 2006.

[26] K. Raymond, M. Kreft, J. Y. Song, H. Janssen, and A. Sonnenberg, "Dual role of $\alpha 6\beta 4$ integrin in epidermal tumor growth: tumor-suppressive versus tumor-promoting function," *Molecular Biology of the Cell*, vol. 18, no. 11, pp. 4210–4221, 2007.

[27] H. Bonkhoff and K. Remberger, "Differentiation pathways and histogenetic aspects of normal and abnormal prostatic growth: a stem cell model," *Prostate*, vol. 28, no. 2, pp. 98–106, 1996.

[28] D. L. Hudson, "Epithelial stem cells in human prostate growth and disease," *Prostate Cancer and Prostatic Diseases*, vol. 7, no. 3, pp. 188–194, 2004.

[29] S. Jaamaa, T. M. Af Hallstrom, A. Sankila, V. Rantanen, and H. Koistinen, "DNA damage recognition via activated ATM and p53 pathway in nonproliferating human prostate tissue," *Cancer Research*, vol. 70, pp. 8630—8641, 2010.

[30] D. C. Malins, P. M. Johnson, E. A. Barker, N. L. Polissar, T. M. Wheeler, and K. M. Anderson, "Cancer-related changes in prostate DNA as men age and early identification of metastasis in primary prostate tumors," *Proceedings of the National Academy of Sciences of the United States of America*, vol. 100, no. 9, pp. 5401–5406, 2003.

[31] R. B. Nagle, J. D. Knox, C. Wolf, G. T. Bowden, and A. E. Cress, "Adhesion molecules, extracellular matrix, and proteases in prostate carcinoma," *Journal of Cellular Biochemistry*, vol. 56, no. 19, pp. 232–237, 1994.

[32] M. Schmelz, A. E. Cress, K. M. Scott, F. Burger, and H. Cui, "Different phenotypes in human prostate cancer: alpha6 or alpha3 integrin in cell-extracellular adhesion sites," *Neoplasia*, vol. 4, pp. 243–254, 2002.

[33] P. Ekblom, P. Lonai, and J. F. Talts, "Expression and biological role of laminin-1," *Matrix Biology*, vol. 22, no. 1, pp. 35–47, 2003.

[34] S. Schéele, A. Nyström, M. Durbeej, J. F. Talts, M. Ekblom, and P. Ekblom, "Laminin isoforms in development and disease," *Journal of Molecular Medicine*, vol. 85, no. 8, pp. 825–836, 2007.

[35] M. Petein, P. Michel, R. Van Velthoven et al., "Morphonuclear relationship between prostatic intraepithelial neoplasia and cancers as assessed by digital cell image analysis," *American Journal of Clinical Pathology*, vol. 96, no. 5, pp. 628–634, 1991.

[36] R. B. Nagle, M. Petein, M. Brawer, G. T. Bowden, and A. E. Cress, "New relationships between prostatic intraepithelial neoplasia and prostatic carcinoma," *Journal of Cellular Biochemistry*, pp. 26–29, 1992.

[37] J. M. Mosquera, R. Mehra, M. M. Regan et al., "Prevalence of TMPRSS2-ERG fusion prostate cancer among men undergoing prostate biopsy in the United States," *Clinical Cancer Research*, vol. 15, no. 14, pp. 4706–4711, 2009.

[38] J. M. Mosquera, S. Perner, E. M. Genega et al., "Characterization of TMPRSS2-ERG fusion high-grade prostatic intraepithelial neoplasia and potential clinical implications," *Clinical Cancer Research*, vol. 14, no. 11, pp. 3380–3385, 2008.

[39] D. G. Bostwick, "Prospective origins of prostate carcinoma: prostatic intraepithelial neoplasia and atypical adenomatous hyperplasia," *Cancer*, vol. 78, no. 2, pp. 330–336, 1996.

[40] M. J. Häggman, J. A. Macoska, K. J. Wojno, and J. E. Oesterling, "The relationship between prostatic intraepithelial neoplasia and prostate cancer: critical issues," *Journal of Urology*, vol. 158, no. 1, pp. 12–22, 1997.

[41] Y. G. Man, "A seemingly most effective target for early detection and intervention of prostate tumor invasion," *Journal of Cancer*, vol. 1, pp. 63–69, 2010.

[42] Y. G. Man, "Tumor cell budding from focally disrupted tumor capsules: a common pathway for all breast cancer subtype derived invasion?" *Journal of Cancer*, vol. 1, pp. 32–37, 2010.

[43] W. A. Sakr, D. J. Grignon, J. D. Crissman et al., "High grade prostatic intraepithelial neoplasia (HGPIN) and prostatic adenocarcinoma between the ages of 20–69: an autopsy study of 249 cases," *In Vivo*, vol. 8, no. 3, pp. 439–444, 1994.

[44] W. A. Sakr, G. P. Haas, B. F. Cassin, J. E. Pontes, and J. D. Crissman, "The frequency of carcinoma and intraepithelial neoplasia of the prostate in young male patients," *Journal of Urology*, vol. 150, no. 2, pp. 379–385, 1993.

[45] J. Hao, K. McDaniel, C. Weyer, J. Barrera, and R. B. Nagle, "Cell line-specific translation of two laminin 5 $\beta 3$ chain isoforms," *Gene*, vol. 283, no. 1-2, pp. 237–244, 2002.

[46] S. Breuninger, S. Reidenbach, C. G. Sauer et al., "Desmosomal plakophilins in the prostate and prostatic adenocarcinomas: implications for diagnosis and tumor progression," *American Journal of Pathology*, vol. 176, no. 5, pp. 2509–2519, 2010.

[47] T. A. Martin and W. G. Jiang, "Loss of tight junction barrier function and its role in cancer metastasis," *Biochimica et Biophysica Acta*, vol. 1788, no. 4, pp. 872–891, 2009.

[48] D. J. Montell, "Morphogenetic cell movements: diversity from modular mechanical properties," *Science*, vol. 322, no. 5907, pp. 1502–1505, 2008.

[49] M. Affolter and E. Caussinus, "Tracheal branching morphogenesis in Drosophila: new insights into cell behaviour and organ architecture," *Development*, vol. 135, no. 12, pp. 2055–2064, 2008.

[50] B. E. Kerman, A. M. Cheshire, and D. J. Andrew, "From fate to function: the Drosophila trachea and salivary gland as models for tubulogenesis," *Differentiation*, vol. 74, no. 7, pp. 326–348, 2006.

[51] P. Lu, M. D. Sternlicht, and Z. Werb, "Comparative mechanisms of branching morphogenesis in diverse systems," *Journal of Mammary Gland Biology and Neoplasia*, vol. 11, no. 3-4, pp. 213–228, 2006.

[52] M. D. Sternlicht, H. Kouros-Mehr, P. Lu, and Z. Werb, "Hormonal and local control of mammary branching morphogenesis," *Differentiation*, vol. 74, no. 7, pp. 365–381, 2006.

[53] A. Ghysen and C. Dambly-Chaudière, "The lateral line microcosmos," *Genes and Development*, vol. 21, no. 17, pp. 2118–2130, 2007.

[54] C. Busch, T. A. Hanssen, C. Wagener, and B. OBrink, "Down-regulation of CEACAM1 in human prostate cancer: correlation with loss of cell polarity, increased proliferation rate, and Gleason grade 3 to 4 transition," *Human Pathology*, vol. 33, no. 3, pp. 290–298, 2002.

[55] L. E. Lamb, B. S. Knudsen, and C. K. Miranti, "E-cadherin-mediated survival of androgen-receptor-expressing secretory prostate epithelial cells derived from a stratified in vitro differentiation model," *Journal of Cell Science*, vol. 123, no. 2, pp. 266–276, 2010.

[56] B. S. Knudsen and C. K. Miranti, "The impact of cell adhesion changes on proliferation and survival during prostate cancer development and progression," *Journal of Cellular Biochemistry*, vol. 99, no. 2, pp. 345–361, 2006.

[57] N. Borghi, M. Lowndes, V. Maruthamuthu, M. L. Gardel, and W. J. Nelson, "Regulation of cell motile behavior by crosstalk between cadherin- and integrin-mediated adhesions," *Proceedings of the National Academy of Sciences*, vol. 107, pp. 13324–13329, 2010.

[58] I. Rabinovitz, R. B. Nagle, and A. E. Cress, "Integrin α 6 expression in human prostate carcinoma cells is associated with a migratory and invasive phenotype in vitro and in vivo," *Clinical and Experimental Metastasis*, vol. 13, no. 6, pp. 481–491, 1995.

[59] S. J. Murant, J. Handley, M. Stower, N. Reid, O. Cussenot, and N. J. Maitland, "Co-ordinated changes in expression of cell adhesion molecules in prostate cancer," *European Journal of Cancer Part A*, vol. 33, no. 2, pp. 263–271, 1997.

[60] R. Umbas, W. B. Isaacs, P. P. Bringuier et al., "Decreased E-cadherin expression is associated with poor prognosis in patients with prostate cancer," *Cancer Research*, vol. 54, no. 14, pp. 3929–3933, 1994.

[61] K. Wolf, Y. I. Wu, Y. Liu et al., "Multi-step pericellular proteolysis controls the transition from individual to collective cancer cell invasion," *Nature Cell Biology*, vol. 9, no. 8, pp. 893–904, 2007.

[62] K. Nabeshima, T. Inoue, Y. Shimao et al., "Front-cell-specific expression of membrane-type 1 matrix metalloproteinase and gelatinase A during cohort migration of colon carcinoma cells induced by hepatocyte growth factor/scatter factor," *Cancer Research*, vol. 60, no. 13, pp. 3364–3369, 2000.

[63] W. C. Powell, J. D. Knox, M. Navre et al., "Expression of the metalloproteinase matrilysin in DU-145 cells increases their invasive potential in severe combined immunodeficient mice," *Cancer Research*, vol. 53, no. 2, pp. 417–422, 1993.

[64] J. R. Mccandless, A. E. Cress, I. Rabinovitz et al., "A human xenograft model for testing early events of epithelial neoplastic invasion," *International Journal of Oncology*, vol. 10, no. 2, pp. 279–285, 1997.

[65] A. J. Daly, L. McIlreavey, and C. R. Irwin, "Regulation of HGF and SDF-1 expression by oral fibroblasts—implications for invasion of oral cancer," *Oral Oncology*, vol. 44, no. 7, pp. 646–651, 2008.

[66] R. A. Hurle, G. Davies, C. Parr et al., "Hepatocyte growth factor/scatter factor and prostate cancer: a review," *Histology and Histopathology*, vol. 20, no. 4, pp. 1339–1349, 2005.

[67] F. Marchesi, L. Piemonti, A. Mantovani, and P. Allavena, "Molecular mechanisms of perineural invasion, a forgotten pathway of dissemination and metastasis," *Cytokine and Growth Factor Reviews*, vol. 21, no. 1, pp. 77–82, 2010.

[68] R. K. Miller and P. D. McCrea, "Wnt to build a tube: contributions of Wnt signaling to epithelial tubulogenesis," *Developmental Dynamics*, vol. 239, no. 1, pp. 77–93, 2010.

[69] G. W. Yardy and S. F. Brewster, "Wnt signalling and prostate cancer," *Prostate Cancer and Prostatic Diseases*, vol. 8, no. 2, pp. 119–126, 2005.

[70] C. I. Truica, S. Byers, and E. P. Gelmann, "β-catenin affects androgen receptor transcriptional activity and ligand specificity," *Cancer Research*, vol. 60, no. 17, pp. 4709–4713, 2000.

[71] C. Liebig, G. Ayala, J. A. Wilks, D. H. Berger, and D. Albo, "Perineural invasion in cancer: a review of the literature," *Cancer*, vol. 115, no. 15, pp. 3379–3391, 2009.

[72] M. Kayahara, H. Nakagawara, H. Kitagawa, and T. Ohta, "The nature of neural invasion by pancreatic cancer," *Pancreas*, vol. 35, no. 3, pp. 218–223, 2007.

[73] I. C. Sroka, T. A. Anderson, K. M. McDaniel, R. B. Nagle, M. B. Gretzer, and A. E. Cress, "The laminin binding integrin alpha6beta1 in prostate cancer perineural invasion," *Journal of Cellular Physiology*, vol. 224, no. 2, pp. 283–288, 2010.

[74] M. R. Cooperberg, J. W. Moul, and P. R. Carroll, "The changing face of prostate cancer," *Journal of Clinical Oncology*, vol. 23, no. 32, pp. 8146–8151, 2005.

[75] I. N. Holcomb, D. I. Grove, M. Kinnunen et al., "Genomic alterations indicate tumor origin and varied metastatic potential of disseminated cells from prostate cancer patients," *Cancer Research*, vol. 68, no. 14, pp. 5599–5608, 2008.

[76] B. S. Taylor, N. Schultz, H. Hieronymus et al., "Integrative genomic profiling of human prostate cancer," *Cancer Cell*, vol. 18, no. 1, pp. 11–22, 2010.

[77] B. Beheshti, B. Vukovic, P. Marrano, J. A. Squire, and P. C. Park, "Resolution of genotypic heterogeneity in prostate tumors using polymerase chain reaction and comparative genomic hybridization on microdissected carcinoma and prostatic intraepithelial neoplasia foci," *Cancer Genetics and Cytogenetics*, vol. 137, no. 1, pp. 15–22, 2002.

[78] J. Liu, S. K. Lau, V. A. Varma et al., "Molecular mapping of tumor heterogeneity on clinical tissue specimens with multiplexed quantum dots," *ACS Nano*, vol. 4, no. 5, pp. 2755–2765, 2010.

[79] H. Kouros-Mehr and Z. Werb, "Candidate regulators of mammary branching morphogenesis identified by genome-wide transcript analysis," *Developmental Dynamics*, vol. 235, no. 12, pp. 3404–3412, 2006.

[80] C. Proust-Lima, J. M. Taylor, S. Secher, H. Sandler, and L. Kestin, "Confirmation of a low alpha/beta ratio for prostate cancer treated by external beam radiation therapy alone using a post-treatment repeated-measures model for PSA dynamics," *International Journal of Radiation Oncology Biology Physics*, vol. 79, pp. 195–201, 2011.

[81] E. K. Oermann, R. S. Slack, H. N. Hanscom, S. Lei, and S. Suy, "A pilot study of intensity modulated radiation therapy with hypofractionated stereotactic body radiation therapy (SBRT) boost in the treatment of intermediate- to high-risk prostate cancer," *Technology in Cancer Research and Treatment*, vol. 9, pp. 453–462, 2010.

[82] M. H. Barcellos-Hoff, C. Park, and E. G. Wright, "Radiation and the microenvironment—tumorigenesis and therapy," *Nature Reviews Cancer*, vol. 5, no. 11, pp. 867–875, 2005.

[83] N. Cordes, "Integrin-mediated cell-matrix interactions for prosurvivaland antiapoptotic signaling after genotoxic injury," *Cancer Letters*, vol. 242, no. 1, pp. 11–19, 2006.

[84] N. Cordes, M. A. Blaese, L. Plasswilm, H. P. Rodemann, and D. Van Beuningen, "Fibronectin and laminin increase resistance to ionizing radiation and the cytotoxic drug Ukrain in human tumour and normal cells in vitro," *International Journal of Radiation Biology*, vol. 79, no. 9, pp. 709–720, 2003.

[85] N. Cordes and V. Meineke, "Integrin signalling and the cellular response to ionizing radiation," *Journal of Molecular Histology*, vol. 35, no. 3, pp. 327–337, 2004.

[86] N. Cordes and V. Meineke, "Modification of the cellular radiation survival and proliferation response by cell-matrix interactions: implications for integrin targeting in therapeutic approaches for radiation accident patients," *The British Journal of Radiology*, 27, pp. 152–156, 2005.

[87] N. Cordes, J. Seidler, R. Durzok, H. Geinitz, and C. Brakebusch, "β 1 -integrin-mediated signaling essentially contributes to cell survival after radiation-induced genotoxic injury," *Oncogene*, vol. 25, no. 9, pp. 1378–1390, 2006.

[88] N. Cordes and D. Van Beuningen, "Cell adhesion to the extracellular matrix protein fibronectin modulates radiation-dependent G2 phase arrest involving integrin-linked kinase (ILK) and glycogen synthase kinase-3β (GSK-3β) in vitro," *British Journal of Cancer*, vol. 88, no. 9, pp. 1470–1479, 2003.

[89] T. Cordes, D. Diesing, S. Becker, K. Diedrich, J. Reichrath, and M. Friedrich, "Modulation of MAPK ERK1 and ERK2 in VDR-positive and -negative breast cancer cell lines," *Anticancer Research*, vol. 26, no. 4 A, pp. 2749–2753, 2006.

[90] C. C. Park, H. J. Zhang, E. S. Yao, C. J. Park, and M. J. Bissell, "β 1 integrin inhibition dramatically enhances radiotherapy efficacy in human breast cancer xenografts," *Cancer Research*, vol. 68, no. 11, pp. 4398–4405, 2008.

[91] S. C. Pawar, S. Dougherty, M. E. Pennington et al., "α6 integrin cleavage: sensitizing human prostate cancer to ionizing radiation," *International Journal of Radiation Biology*, vol. 83, no. 11-12, pp. 761–767, 2007.

Hindawi Publishing Corporation
Prostate Cancer
Volume 2011, Article ID 485189, 6 pages
doi:10.1155/2011/485189

Review Article

Prognostic Factors for the Development of Biochemical Recurrence after Radical Prostatectomy

Ahmed F. Kotb and Ahmed A. Elabbady

Urology Department, Faculty of Medicine, Alexandria University, Alexandria, Egypt

Correspondence should be addressed to Ahmed A. Elabbady, a_elabbady@hotmail.com

Received 28 February 2011; Revised 8 April 2011; Accepted 19 April 2011

Academic Editor: Kenneth A. Iczkowski

Copyright © 2011 A. F. Kotb and A. A. Elabbady. This is an open access article distributed under the Creative Commons Attribution License, which permits unrestricted use, distribution, and reproduction in any medium, provided the original work is properly cited.

Prostate cancer is one of the most common cancers in Western countries and is associated with a considerable risk of mortality. Biochemical recurrence following radical prostatectomy is a relatively common finding, affecting approximately 25% of cases. The aim of our paper was to identify factors that can predict the occurrence of biochemical recurrence, so the patient can be properly counselled pre- and postoperatively. Medline review of the literatures was done followed by a group discussion on the chosen publications and their valuable influence. Preoperative serum total PSA and clinical stage, together with prostatectomy Gleason grade, tumour volume, and perineural and vascular invasions, were the most important variables found to influence outcome.

1. Introduction

In Canada, it is estimated that 1 in 7 men will develop prostate cancer (Pca) during their lifetime, and 1 of 27 will die of it (a ratio of 1 death per 4 diagnosed cases) [1]. In 2009, approximately 192.000 men from the USA were diagnosed with prostate cancer, with an estimate of 27.000 of those men dying from it [2].

The Food and Drug Administration (FDA) approved PSA testing in 1986 to monitor men with prostate cancer. Since then, PSA was widely used both to screen prostate cancer and to monitor treatment response and recurrence. This resulted in early diagnosis of cases with organ localized disease amenable to definitive treatment and in early diagnosis of disease recurrence following surgery with early treatment before widespread dissemination.

The ideal therapy for clinically localized prostate cancer is still controversial. Although radical prostatectomy (RP) is a valid option, the rate of biochemical recurrence following open or laparoscopic prostatectomy is estimated to be 15–40% [3, 4].

As PSA may require up to 8 weeks to be cleared from the circulation [5], biochemical recurrence cannot be diagnosed before that time frame, following radical prostatectomy. The American Urological Association and EAU defined biochemical recurrence (BCR) following RP as an initial serum PSA of greater than or equal to 0.2 ng/mL, with a second confirmatory level of PSA greater than 0.2 ng/mL [6, 7]. Freedland et al. attempted to define the lowest PSA cut point associated with PSA progression within 1 year, along with 100% 3-year risk of progression [8]. They concluded that a 0.2 ng/mL represented the most conservative cut point to define BCR, after RP. Stephenson et al. subsequently examined the correlation between 10 definitions of biochemical recurrence with metastatic progression in a clinical cohort [9]. They proposed that biochemical recurrence should be defined as a PSA >0.4 ng/mL with a confirmatory rise. Hattab et al. defined biochemical recurrence as two consecutive serum PSA measurements >0.1 ng/mL [10]. Regardless of which definition may be better in defining BCR, the aim is to identify the perioperative factors associated with a high risk of BCR, so that patients proved to be at a higher risk of BCR can be followed more closely postoperatively and may be advised for early adjuvant treatment, after RP. Cronin et al. studied 5473 patients, who underwent RP from 1985 to 2007 [11]. An analysis of perioperative clinical and pathological parameters was done with 12 definitions of BCR. They observed that the relative risks and hazard ratios were fairly consistent between the 12 definitions examined, and the statistical inference on established prognostic factors was not

impacted by the definition of BCR. So research groups using different definitions for BCR seem to reach similar conclusions regarding prognostic factors.

We discuss some factors we believe to be of important influence on the progression of prostate cancer, following its definitive management.

2. Preoperative Factors

2.1. Clinical Stage. The 2002 American Joint Committee on cancer TNM clinical staging system for prostate cancer substratified localized disease as T1 and T2. According to this committee, T1 represents disease with no abnormality on DRE and T2 represents a DRE palpable disease which is further subclassified into T2a, b, and c according to the extent of prostatic lobes affected [12]. D'Amico et al. developed a risk stratification system to predict BCR, after RP [13]. Both T1c and T2a were considered low-risk groups, whereas T2b and T2c were classified as intermediate- and high-risk groups, respectively. More recently, Billis et al. described different clinicopathological characteristics between patients with clinical stage T1c versus stages T2a and T2b [14]. Freedland et al. also showed no difference in BCR rate between patients with clinical stage T2a and T2b, with excellent 10-year progression-free survival in both groups [15].

Cooperberg et al. reported the San Francisco experience in prostate cancer risk assessment [16]. They demonstrated that clinical stage was not a predictive factor for biochemical recurrence in their model. Armatys et al. confirmed that cases with cT2 had worse pathological outcomes than cT1c [17]. However, no statistical difference between both groups could be found regarding BCR rate. Reese et al. reported that clinical stage in 4899 men who underwent RP for localized Pca was predictive for BCR on univariate, rather than multivariate, studies [18].

Stephenson et al. included clinical stage in their nomogram to predict BCR following RP [19]. Hashimoto et al. showed that clinical stage ≥T2a is highly significant in predicting positive surgical margin (SM) following RP [20]. In their cohort, positive SM was significantly predicting a higher rate of BCR, although they did not directly examine the association between the clinical stage and the BCR. In a study on Japanese populations, Egawa et al. found that clinical stage contributed significantly in the prediction of biochemical recurrence, in their cohort of patients [21].

We confirm DRE to be an integral part in the routine urological examination, for men above 55 years of age. Suspicious findings on DRE can predict worse outcomes following definitive management, compared to cases where diagnosis was based on high serum PSA with normal DRE findings.

2.2. Preoperative Serum PSA and PSA Density (PSAd). PSA and PSAd are factors predicting BCR in most of the available nomograms and studies [16, 18, 22, 23]. Radwan et al. reported that PSAd, whether measured using U/S or the true prostate weight, was highly predicting for BCR, more than PSA [23]. Freedland et al. [24] initially reported that PSAd was a strong predictor for pathological adverse effects and BCR following RP and should be integrated in the risk stratification for Pca. In a more recent study on a larger cohort of patients, Freedland et al. found that preoperative PSAd relative to PSA provides little improvement for predicting BCR following RP [25]. Brassell et al. correlated PSA and PSAd measured using both ultrasound and the true prostate volume [26]. They reported that PSA was significantly better than PSAd in predicting BCR.

From our experience, we believe that PSAd has no added role over PSA alone as a prognostic factor for disease progression in intermediate- and high-risk groups (PSA >10 ng/mL). On the other hand, in low-risk groups, with serum PSA <10 ng/mL, PSAd is pivotal in predicting patient outcome.

3. Pathological Factors

3.1. Gleason Grade. Gleason grade is the most widely accepted grading system for prostatic adenocarcinoma. Given the inherent sampling error of diagnostic needle biopsy and the multifocal nature of this tumor, discrepancy between Gleason score (GS) of needle biopsy and RP specimen was a common finding in the literature. King summarized 11 published series that covered over 2600 patients, in which an accurate match of grading was seen in an average of only 42% of the cases [27]. We thus believe that Gleason grade obtained from needle biopsy has a limited role in the decision making for patient management, compared to the RP Gleason grading.

Gleason score 7 should not be considered in our opinion as a single disease entity, and whenever the urologist is encountered with GS 7, decision on patient management should be done based on its primary Gleason pattern. Lau et al. studied 263 men with grade 7 RP specimens [28]. They noted that patients with primary Gleason grade 4 had a significantly higher rate of progression than patients with primary Gleason grade 3 (46% versus 33%). Sakr et al. performed the same study on 534 men, followed for a mean of 34.6 months [29]. They showed that primary grade 4 was associated with a higher rate of BCR, more than primary grade 3 (23% versus 11%, at 2-year followup).

Some studies considered the percentage of high Gleason pattern as a factor predicting a higher rate of BCR [30, 31]. On the other hand, Chan et al. reported that high Gleason pattern is not likely to be reproducible [32]. It was often difficult and time consuming and results in a prognostic effect only at its extremes (greater than 70% or less than 20% with pattern 4/5).

In our institution, we do not consider the percentage of high Gleason pattern. Nevertheless, we follow the current principals of considering cases with GS ≤6 as low risk, compared to cases with GS >6 as high risk.

3.2. Tumour Volume (TV). Data about the effect of tumour volume on BCR are contradictory in the literature. Some studies could not find a correlation between tumor volume

(TV) and BCR [33, 34], whereas others considered tumour volume a high predictor factor for cancer progression [35–39].

Fukuhara et al. used the maximum tumour diameter (MTD) as an estimate for tumour volume, to correlate with BCR [40]. They noted that, although both PSA and MTD significantly correlated with BCR on univariate analysis, only MTD independently predicted BCR on multivariate analysis. These findings were in agreement with those of Chung et al. [41].

In our institution, we prefer measuring the maximal tumour diameter rather than the tumour volume. No data is currently available for us to judge its direct effect on the rate of BCR. We believe it to be an important variable to be included in our further studies.

3.3. Surgical Margin. Blute et al. reported a positive margin rate of 39% in more than 2500 patients from the Mayo series, and the BFS at 5 years was 67% and 84% in patients with positive and negative SM, respectively [42]. Similarly, Hashimoto et al. reported 5-year BFS rate of 62.6% and 81.7% for patients with positive and negative SM, respectively [43].

Sæther et al. failed to show SM positivity to be an independent risk factor for BCR although they could show that it had a strong trend to do so ($P = .06$) [44].

Lake et al. studied the disease-free survival of patients with negative surgical margin versus those with either focal (FPM) or extensive positive surgical margin (EPM) [45]. In their study, the 10-year DFS was 90%, 76%, and 53% for those with negative SM, FPM, and EPM, respectively, and that achieved statistical significance. Ochiai et al. could also show that patients with positive SM longer than 3 mm had much lower outcomes than those with shorter positive SM [46].

In our experience, a positive surgical margin is not a factor toward a significantly higher rate of BCR, although we consider it an indication for adjuvant radiotherapy.

3.4. Perineural Invasion (PNI). A recent study from Italy reported that 65.7% of their prostatectomy specimens that were associated with higher Gleason grades had PNI, but not BCR [47]. Merrilees et al. detected PNI in 90% of their 105 prostatectomy specimens [48]. They also concluded that PNI was not a significant predictor for the occurrence of BCR. Miyake et al. found PNI to be of significance to predict BCR on univariate analysis but not multivariate analysis [49]. Endrizzi and Seay found PNI in their 131 patients to be a significant factor predicting BCR, with a sensitivity of 82% and a specificity of 57% [50].

Beard et al. studied the association of PNI and the relapse rate following external beam radiation [51]. They reported a significant association of PNI with higher Gleason score and a higher rate of BCR on univariate analysis. On multivariate analysis, PNI was not an independent factor predicting BCR. O'Malley et al. studied 78 patients with PNI detected by prostatic biopsy with other 78 patients with absent PNI [52]. They reported no significant effect of PNI on the rate of BCR following RP, when adjusted to GS, PSA, and pathological stage.

3.5. Vascular Invasion (VI). Van den Ouden et al. reported vascular invasion (VI) in 12% of their patients who underwent prostatectomy [53]. VI was a significant factor in predicting BCR on univariate and multivariate analysis. De la Taille et al. found VI in 12.4% of their cases and confirmed VI to be an independent significant factor predicting BCR [54]. Ferrari et al. detected VI in 18% of their patients and confirmed that VI was associated with worst pathological outcomes and was an independent factor predicting BCR on long-term followup [55]. The College of American Pathologists recommended VI to be assessed routinely in radical prostatectomy specimens [56].

3.6. Neuroendocrinal Differentiation. Quek et al. studied the correlation between neuroendocrinal (NE) expression, using CgA, in malignant and benign acini and recurrences [57]. They detected statistically significant association of the number of NE cells in only malignant acini and clinical recurrence. Weinstein et al. also showed that the number of malignant NE cells is of prognostic significance for patients undergoing radical prostatectomy [58]. In a multivariate analysis, May et al. [59] detected neuroendocrinal differentiation to be the second most significant predictor for biochemical progression. On the other hand, other authors did not find a significant association between NE differentiation and disease progression or biochemical failure [60, 61].

Although there are no solid data on the influence of neuroendocrinal differentiation on BCR and although it is currently not performed as a routine staining in our institution, we recommend staining for NE cells within the prostate as this may serve to predict biochemical recurrence as proposed by some. It may also point toward considering early chemotherapy in relapsing cases with higher degree of NE differentiation.

4. Conclusion

There is wide consensus that biochemical recurrence occurs in a large percentage of patients following successful radical prostatectomy. No single factor can be considered toward the prediction of recurrence. Preoperative PSA, clinical stage, prostatectomy Gleason grade, tumour volume, perineural invasion, and vascular invasion are the most important clinical and pathological parameters for assessing after radical prostatectomy. Neuroendocrinal differentiation may be an important pathological criterion to look for in a prostatectomy specimen.

References

[1] Y. Fradet, L. Klotz, J. Trachtenberg, and A. Zlotta, "The burden of prostate cancer in Canada," *Journal of the Canadian Urological Association*, vol. 3, no. 3, supplement 2, pp. S102–S108, 2009.

[2] A. Jemal, R. Siegel, E. Ward, Y. Hao, J. Xu, and M. J. Thun, "Cancer statistics, 2009," *CA: Cancer Journal for Clinicians*, vol. 59, no. 4, pp. 225–249, 2009.

[3] P. C. Walsh, A. W. Partin, and J. I. Epstein, "Cancer control and quality of life following anatomical radical retropubic prostatectomy: results at 10 years," *Journal of Urology*, vol. 152, no. 5, pp. 1831–1836, 1994.

[4] H. A. Frazier, J. E. Robertson, P. A. Humphrey, and D. F. Paulson, "Is prostate specific antigen of clinical importance in evaluating outcome after radical prostatectomy," *Journal of Urology*, vol. 149, no. 3, pp. 516–518, 1993.

[5] J. E. Oesterling, "Prostate specific antigen: a critical assessment of the most useful tumor marker for adenocarcinoma of the prostate," *Journal of Urology*, vol. 145, no. 5, pp. 907–923, 1991.

[6] M. S. Cookson, G. Aus, A. L. Burnett et al., "Variation in the definition of biochemical recurrence in patients treated for localized prostate cancer: the American Urological Association Prostate Guidelines for Localized Prostate Cancer Update Panel report and recommendations for a standard in the reporting of surgical outcomes," *Journal of Urology*, vol. 177, no. 2, pp. 540–545, 2007.

[7] G. Aus, C. C. Abbou, M. Bolla et al., "EAU guidelines on prostate cancer," *European Urology*, vol. 48, no. 4, pp. 546–551, 2005.

[8] S. J. Freedland, M. E. Sutter, F. Dorey, and W. J. Aronson, "Defining the ideal cutpoint for determining PSA recurrence after radical prostatectomy," *Urology*, vol. 61, no. 2, pp. 365–369, 2003.

[9] A. J. Stephenson, M. W. Kattan, J. A. Eastham et al., "Defining biochemical recurrence of prostate cancer after radical prostatectomy: a proposal for a standardized definition," *Journal of Clinical Oncology*, vol. 24, no. 24, pp. 3973–3978, 2006.

[10] E. M. Hattab, M. O. Koch, J. N. Eble, H. Lin, and L. Cheng, "Tertiary Gleason pattern 5 is a powerful predictor of biochemical relapse in patients with Gleason scores 7 prostatic adenocarcinoma," *Journal of Urology*, vol. 175, no. 5, pp. 1695–1699, 2006.

[11] A. M. Cronin, G. Godoy, and A. J. Vickers, "Definition of biochemical recurrence after radical prostatectomy does not substantially impact prognostic factor estimates," *Journal of Urology*, vol. 183, no. 3, pp. 984–989, 2010.

[12] F. L. Greene, *AJCC Cancer Staging Manual*, Springer, New York, NY, USA, 6th edition, 2002.

[13] A. V. D'Amico, R. Whittington, S. Bruce Malkowicz et al., "Biochemical outcome after radical prostatectomy, external beam radiation therapy, or interstitial radiation therapy for clinically localized prostate cancer," *Journal of the American Medical Association*, vol. 280, no. 11, pp. 969–974, 1998.

[14] A. Billis, L. A. Magna, I. C. Watanabe, M. V. Costa, G. H. Telles, and U. Ferreira, "Are prostate carcinoma clinical stages T1c and T2 similar?" *International Brazilian Journal of Urology*, vol. 32, no. 2, pp. 165–171, 2006.

[15] S. J. Freedland, A. W. Partin, J. I. Epstein, and P. C. Walsh, "Biochemical failure after radical prostatectomy in men with pathologic organ-confined disease: pT2a versus pT2b," *Cancer*, vol. 100, no. 8, pp. 1646–1649, 2004.

[16] M. R. Cooperberg, D. J. Pasta, E. P. Elkin et al., "The University of California, San Francisco Cancer of the Prostate Risk Assessment score: a straightforward and reliable preoperative predictor of disease recurrence after radical prostatectomy," *Journal of Urology*, vol. 173, no. 6, pp. 1938–1942, 2005.

[17] S. A. Armatys, M. O. Koch, R. Bihrle, T. A. Gardner, and L. Cheng, "Is it necessary to separate clinical stage T1c from T2 prostate adenocarcinoma?" *BJU International*, vol. 96, no. 6, pp. 777–780, 2005.

[18] A. C. Reese, M. R. Cooperberg, and P. R. Carroll, "Minimal impact of clinical stage on prostate cancer prognosis among contemporary patients with clinically localized disease," *Journal of Urology*, vol. 184, no. 1, pp. 114–119, 2010.

[19] A. J. Stephenson, P. T. Scardino, J. A. Eastham et al., "Preoperative nomogram predicting the 10-year probability of prostate cancer recurrence after radical prostatectomy," *Journal of the National Cancer Institute*, vol. 98, no. 10, pp. 715–717, 2006.

[20] K. Hashimoto, N. Masumori, F. Takei et al., "Prognostic value of surgical margin status for biochemical recurrence following radical prostatectomy," *Japanese Journal of Clinical Oncology*, vol. 38, no. 1, pp. 31–35, 2008.

[21] S. Egawa, K. Suyama, Y. Arai et al., "A study of pretreatment nomograms to predict pathological stage and biochemical recurrence after radical prostatectomy for clinically resectable prostate cancer in Japanese Men," *Japanese Journal of Clinical Oncology*, vol. 31, no. 2, pp. 74–81, 2001.

[22] H. Isbarn, M. Wanner, G. Salomon et al., "Long-term data on the survival of patients with prostate cancer treated with radical prostatectomy in the prostate-specific antigen era," *BJU International*, vol. 106, no. 1, pp. 37–43, 2010.

[23] M. H. Radwan, Y. Yan, J. R. Luly et al., "Prostate-specific antigen density predicts adverse pathology and increased risk of biochemical failure," *Urology*, vol. 69, no. 6, pp. 1121–1127, 2007.

[24] S. J. Freedland, J. A. Wieder, G. S. Jack, F. Dorey, J. B. Dekernion, and W. J. Aronson, "Improved risk stratification for biochemical recurrence after radical prostatectomy using a novel risk group system based on prostate specific antigen density and biopsy Gleason score," *Journal of Urology*, vol. 168, no. 1, pp. 110–115, 2002.

[25] S. J. Freedland, C. J. Kane, J. C. Presti et al., "Comparison of preoperative prostate specific antigen density and prostate specific antigen for predicting recurrence after radical prostatectomy: results from the search data base," *Journal of Urology*, vol. 169, no. 3, pp. 969–973, 2003.

[26] S. A. Brassell, T. C. Kao, L. Sun, and J. W. Moul, "Prostate-specific antigen versus prostate-specific antigen density as predictor of tumor volume, margin status, pathologic stage, and biochemical recurrence of prostate cancer," *Urology*, vol. 66, no. 6, pp. 1229–1233, 2005.

[27] C. R. King, "Patterns of prostate cancer biopsy grading: trends and clinical implications," *International Journal of Cancer*, vol. 90, no. 6, pp. 305–311, 2000.

[28] W. K. Lau, M. L. Blute, D. G. Bostwick, A. L. Weaver, T. J. Sebo, and H. Zincke, "Prognostic factors for survival of patients with pathological gleason score 7 prostate cancer: differences in outcome between primary gleason grades 3 and 4," *Journal of Urology*, vol. 166, no. 5, pp. 1692–1697, 2001.

[29] W. A. Sakr, M. V. Tefilli, D. J. Grignon et al., "Gleason score 7 prostate cancer: a heterogeneous entity? Correlation with pathologic parameters and disease-free survival," *Urology*, vol. 56, no. 5, pp. 730–734, 2000.

[30] M. Noguchi, T. A. Stamey, J. E. McNeal, and C. M. Yemoto, "Preoperative serum prostate specific antigen does not reflect biochemical failure rates after radical prostatectomy in men with large volume cancers," *Journal of Urology*, vol. 164, no. 5, pp. 1596–1600, 2000.

[31] L. Cheng, M. O. Koch, B. E. Juliar et al., "The combined percentage of gleason patterns 4 and 5 is the best predictor

of cancer progression after radical prostatectomy," *Journal of Clinical Oncology*, vol. 23, no. 13, pp. 2911–2917, 2005.

[32] T. Y. Chan, A. W. Partin, P. C. Walsh, and J. I. Epstein, "Prognostic significance of Gleason score 3+4 versus Gleason score 4+3 tumor at radical prostatectomy," *Urology*, vol. 56, no. 5, pp. 823–827, 2000.

[33] B. A. O'Brien, R. J. Cohen, T. M. Wheeler, and R. E. Moorin, "A post-radical-prostatectomy nomogram incorporating new pathological variables and interaction terms for improved prognosis," *BJU International*, vol. 107, no. 3, pp. 389–395, 2011.

[34] E. Kikuchi, P. T. Scardino, T. M. Wheeler et al., "Is tumor volume an independent prognostic factor in clinically localized prostate cancer?" *Journal of Urology*, vol. 173, no. 4, p. 1433, 2005.

[35] M. Ohori, T. M. Wheeler, M. W. Kattan, Y. Goto, and P. T. Scardino, "Prognostic significance of positive surgical margins in radical prostatectomy specimens," *Journal of Urology*, vol. 154, no. 5, pp. 1818–1824, 1995.

[36] R. B. Watson, F. Civantos, and M. S. Soloway, "Positive surgical margins with radical prostatectomy: detailed pathological analysis and prognosis," *Urology*, vol. 48, no. 1, pp. 80–90, 1996.

[37] M. Ates, D. Teber, A. S. Gözen et al., "Do tumor volume, tumor volume ratio, type of nerve sparing and surgical experience affect prostate specific antigen recurrence after laparoscopic radical prostatectomy? A matched pair analysis," *Journal of Urology*, vol. 177, no. 5, pp. 1771–1776, 2007.

[38] T. A. Stamey, J. E. McNeal, C. M. Yemoto, B. M. Sigal, and I. M. Johnstone, "Biological determinants of cancer progression in men with prostate cancer," *Journal of the American Medical Association*, vol. 281, no. 15, pp. 1395–1400, 1999.

[39] B. A. Nelson, S. B. Shappell, S. S. Chang et al., "Tumour volume is an independent predictor of prostate-specific antigen recurrence in patients undergoing radical prostatectomy for clinically localized prostate cancer," *BJU International*, vol. 97, no. 6, pp. 1169–1172, 2006.

[40] H. Fukuhara, H. Kume, M. Suzuki et al., "Maximum tumor diameter: a simple independent predictor for biochemical recurrence after radical prostatectomy," *Prostate Cancer and Prostatic Diseases*, vol. 13, no. 3, pp. 244–247, 2010.

[41] B. I. Chung, T. V. Tarin, M. Ferrari, and J. D. Brooks, "Comparison of prostate cancer tumor volume and percent cancer in prediction of biochemical recurrence and cancer specific survival," *Urologic Oncology: Seminars and Original Investigations*. In press.

[42] M. L. Blute, E. J. Bergstralh, A. Iocca, B. Scherer, and H. Zincke, "Use of Gleason score, prostate specific antigen, seminal vesicle and margin status to predict biochemical failure after radical prostatectomy," *Journal of Urology*, vol. 165, no. 1, pp. 119–125, 2001.

[43] K. Hashimoto, N. Masumori, F. Takei et al., "Prognostic value of surgical margin status for biochemical recurrence following radical prostatectomy," *Japanese Journal of Clinical Oncology*, vol. 38, no. 1, pp. 31–35, 2008.

[44] T. Sæther, L. T. Sørlien, T. Viset, S. Lydersen, and A. Angelsen, "Are positive surgical margins in radical prostatectomy specimens an independent prognostic marker?" *Scandinavian Journal of Urology and Nephrology*, vol. 42, no. 6, pp. 514–521, 2008.

[45] A. M. Lake, C. He, and D. P. Wood Jr., "Focal positive surgical margins decrease disease-free survival after radical prostatectomy even in organ-confined disease," *Urology*, vol. 76, no. 5, pp. 1212–1216, 2010.

[46] A. Ochiai, T. Sotelo, P. Troncoso, V. Bhadkamkar, and R. J. Babaian, "Natural history of biochemical progression after radical prostatectomy based on length of a positive surgical margin," *Urology*, vol. 71, no. 2, pp. 308–312, 2008.

[47] L. Masieri, M. Lanciotti, G. Nesi et al., "Prognostic role of perineural invasion in 239 consecutive patients with pathologically organ-confined prostate cancer," *Urologia Internationalis*. In press.

[48] A. D. Merrilees, P. B. Bethwaite, G. L. Russell, R. G. Robinson, and B. Delahunt, "Parameters of perineural invasion in radical prostatectomy specimens lack prognostic significance," *Modern Pathology*, vol. 21, no. 9, pp. 1095–1100, 2008.

[49] H. Miyake, I. Sakai, K. I. Harada, H. Eto, and I. Hara, "Limited value of perineural invasion in radical prostatectomy specimens as a predictor of biochemical recurrence in Japanese men with clinically localized prostate cancer," *Acta Urologica Japonica*, vol. 51, no. 4, pp. 241–246, 2005.

[50] J. Endrizzi and T. Seay, "The relationship between early biochemical failure and perineural invasion in pathological T2 prostate cancer," *BJU International*, vol. 85, no. 6, pp. 696–698, 2000.

[51] C. J. Beard, M. H. Chen, K. Cote et al., "Perineural invasion is associated with increased relapse after external beam radiotherapy for men with low-risk prostate cancer and may be a marker for occult, high-grade cancer," *International Journal of Radiation Oncology Biology Physics*, vol. 58, no. 1, pp. 19–24, 2004.

[52] K. J. O'Malley, C. R. Pound, P. C. Walsh, J. I. Epstein, and A. W. Partin, "Influence of biopsy perineural invasion on long-term biochemical disease-free survival after radical prostatectomy," *Urology*, vol. 59, no. 1, pp. 85–90, 2002.

[53] D. Van den Ouden, R. Kranse, W. C. J. Hop, T. H. Van der Kwast, and F. H. Schröder, "Microvascular invasion in prostate cancer: prognostic significance in patients treated by radical prostatectomy for clinically localized carcinoma," *Urologia Internationalis*, vol. 60, no. 1, pp. 17–24, 1998.

[54] A. De La Taille, M. A. Rubin, R. Buttyan et al., "Is microvascular invasion on radical prostatectomy specimens a useful predictor of PSA recurrence for prostate cancer patients?" *European Urology*, vol. 38, no. 1, pp. 79–84, 2000.

[55] M. K. Ferrari, J. E. McNeal, S. M. Malhotra, and J. D. Brooks, "Vascular invasion predicts recurrence after radical prostatectomy: stratification of risk based on pathologic variables," *Urology*, vol. 64, no. 4, pp. 749–753, 2004.

[56] D. E. Henson, R. V.P. Hutter, and G. Farrow, "Practice protocol for the examination of specimens removed from patients with carcinoma of the prostate gland: a publication of the cancer committee, College of American Pathologists," *Archives of Pathology and Laboratory Medicine*, vol. 118, no. 8, pp. 779–783, 1994.

[57] M. L. Quek, S. Daneshmand, S. Rodrigo et al., "Prognostic significance of neuroendocrine expression in lymph node-positive prostate cancer," *Urology*, vol. 67, no. 6, pp. 1247–1252, 2006.

[58] M. H. Weinstein, A. W. Partin, R. W. Veltri, and J. I. Epstein, "Neuroendocrine differentiation in prostate cancer: enhanced prediction of progression after radical prostatectomy," *Human Pathology*, vol. 27, no. 7, pp. 683–687, 1996.

[59] M. May, M. Siegsmund, F. Hammermann, V. Loy, and S. Gunia, "Prognostic significance of proliferation activity and neuroendocrine differentiation to predict treatment failure

after radical prostatectomy," *Scandinavian Journal of Urology and Nephrology*, vol. 41, no. 5, pp. 375–381, 2007.

[60] G. Ahlegren, K. Pedersen, S. Lundberg, G. Aus, J. Hugosson, and P. A. Abrahamsson, "Neuroendocrine differentiation is not prognostic of failure after radical prostatectomy but correlates with tumor volume," *Urology*, vol. 56, no. 6, pp. 1011–1015, 2000.

[61] K. Revelos, C. Petraki, A. Scorilas et al., "Correlation of androgen receptor status, neuroendocrine differentiation and angiogenesis with time-to-biochemical failure after radical prostatectomy in clinically localized prostate cancer," *Anticancer Research*, vol. 27, no. 5B, pp. 3651–3660, 2007.

Hindawi Publishing Corporation
Prostate Cancer
Volume 2011, Article ID 673021, 12 pages
doi:10.1155/2011/673021

Review Article

Frequency of Positive Surgical Margin at Prostatectomy and Its Effect on Patient Outcome

Kenneth A. Iczkowski and M. Scott Lucia

Department of Pathology, School of Medicine, University of Colorado Denver, Aurora, CO 80045, USA

Correspondence should be addressed to Kenneth A. Iczkowski, kenneth.iczkowski@ucdenver.edu and M. Scott Lucia, scott.lucia@ucdenver.edu

Received 9 March 2011; Accepted 27 March 2011

Academic Editor: R. Montironi

Copyright © 2011 K. A. Iczkowski and M. S. Lucia. This is an open access article distributed under the Creative Commons Attribution License, which permits unrestricted use, distribution, and reproduction in any medium, provided the original work is properly cited.

A positive surgical margin at prostatectomy is defined as tumor cells touching the inked edge of the specimen. This finding is reported in 8.8% to 42% of cases (median about 20%) in various studies. It is one of the main determinants of eventual biochemical (PSA) failure, generally associated with a doubled or tripled risk of failure. The effect of a positive margin on outcome can be modified by stage or grade and the length, number and location of positive margins, as well as by technical operative approach and duration of operator experience. This paper tabulates data from the past decade of studies on margin status.

1. Introduction

1.1. Definition of a Positive Surgical Margin (PSM) in Radical Prostatectomy Specimens. As with all surgical specimens resected for cancer, the margins of a prostatectomy specimen are inked, usually using one color dye for the right side and one for the left. It is the pathologist's task to assess the microscopic slides and determine the proximity of tumor glands or cells to the ink to decide whether there is a definite positive surgical margin (PSM) (Figure 1).

A fundamental question is whether a tumor focus that is close to, but not touching, the resection margin (Figure 2) holds the same implications as a PSM. This question was first answered by Epstein and Sauvageot in 1997, in a study of 101 cases [1]. They found that patients with biochemical progression were no more likely to have tumor close to the margin than those without progression. Emerson et al., confining their study to just 278 margin-negative whole-mount prostate cases, validated that the closest distance between tumor and resection margin was not a significant predictor of PSA recurrence by univariate or multivariate analysis [2]. Thus, it was the consensus of the International Society of Urological Pathology in 2009 not to mention in written reports if tumor merely approaches but does not touch the margin [3]. This contrasts with the practice in other types of specimens such as breast lumpectomy specimens, in which the distance of tumor close to the margin is reported and does matter for outcome.

A PSM is a strong determinant of the probability of biochemical failure and is at least as important as grade, stage, and preoperative serum prostate-specific antigen (PSA). In unselected contemporary studies the PSM rate ranges from 8.8% [4] to 37% [5]. The interobserver reproducibility of designation of a PSM by urologic pathologists, using the definition of tumor on ink, has been shown to be good to excellent. The kappa value is 0.73 for definitive surgical margin status [6]. This supports the validity of many studies in concluding that, compared to negative surgical margin (NSM) status, a PSM correlates with a significant rise in biochemical failure rate. The purpose of this paper is to provide a compendium for urologists and their patients of all that is known about prostate margin status as an outcome predictor.

2. Methods

A review of papers pertaining to prostate margin status and its effect on outcome was undertaken using PubMed searches from 1997 to the present.

Table 1: Comparison of PSM rates by technical approach.

First author, yr	No. of pts	Cohort years	Median f/u, yr	Open		Laparoscopic		Robotic		Failure rate if PSM
				PSM rate	*P* value	PSM rate	HR, *P* val.	PSM rate	HR, *P* val.	
Williams 2010 [7]	4240	2004–2006		20.1%		17.4%		17.4%		
Coelho 2010 [8]	≥250††	1994–2009		24.0%		21.3%		13.6%		
Sciarra 2010 [9]	200	2003–2007		18% anterograde, 14% retrograde	$P = .03$	—		—		—
Williams 2010 [10]	950	2005–2008		7.6%		13.5%,	HR 1.9*, $P = .007$	—		—
Coelho 2010 [11]	876	2008-2009		—		—		pT2, 6.8%, pT3, 34.0%	$P < .0001$	—
Guru 2009 [12]	480	2005–2008		—		—		5% apical, 2% versus 8%**		—
Bong 2009 [13]	301	1994–2006	2.0	24.7% at 1 institution but 4.2% at another	$P < .01$***	—		—		25.6% at 1 institution but 100% at other
Hakimi 2009 [14]	150	2001–2008				13.7%		12%		6.7% versus 5.3% $P = .37$
Laurila 2009 [15]	192	2006		14%		—		13%	$P = .5$, no diff in apical margin	—
Terakawa 2008 [16]	137	2000–2007		PSM	Not signif.	—		More multiple PSM, get #		—
Smith 2007 [17]	400	2002–2006		35%†		—		15%	$P < .001$	—
Silva 2007 [18]	179	1999–2003		41.6%		—		24.44%	$P = .023$	—
Touijer 2007 [19]	1177	2003–2005		11.0%; pT2 5.3%, pT3 22.0%		11.3%; pT2 8.2%; pT3 17.2%	HR 1.2, $P = .5$	—		—

*OR falls to 1.6 if nerve-sparing is eliminated as a variable ($P = .05$).
**Lower rate achieved by cold incision of the dorsal venous complex before suture ligation.
***For the same surgeon; but higher average pathologic stage at the first institution.
†But open method was used for more high-risk cases and also cases with a higher preoperative PSA, $P = .002$.
††Review of several papers.

3. Results

3.1. Can Prostate Biopsy Results Predict Margin Status? We undertook a study a few years ago to determine the extent to which prostate biopsy results could predict cancer at prostatectomy that is unifocal, unilateral, margin-negative, and of small volume [20]. These four factors are the main criteria for choosing minimally invasive therapies such as targeted focal ablation of the prostate, as alternatives to radical prostatectomy. Unilateral cancer at prostatectomy was predicted by unilateral cancer in the biopsy (OR, 4.30) and unifocal cancer in the biopsy (OR, 2.63). In that study, negative surgical margins were predicted by unilateral cancer in the biopsy (OR 2.53, positive predictive value 82%). Therefore, biopsy findings can strongly predict prostatectomy margin status and other findings.

3.2. Comparison of PSM Rates by Technical Approach (Table 1). In the past decade, nonrobotic or robotic laparoscopic techniques have been increasingly used in place of conventional open radical prostatectomy. The laparoscopic approaches are often considered superior for continence and potency [8, 11, 12, 14, 16]. Most studies involving prostate

Table 2: Comparison of PSM rates by duration of surgical experience.

First author, yr	Number of cases	Cohort years	PSM rate		
			Open	Laparoscopic	Robotic
Rodriguez 2010 [21]	400, by intervals of 100	2004–2006	—	For pT2: 28.4%–31.9% to 11.6%–11.5%*	—
Yee 2009 [22]	50, then 250	2005–2008	—	—	Cases 1–50: 36%, 51–250: 17.6%, 251–450: 7.5%
Liss 2008 [23]	216	2003–2007	—	—	14.8%, decr. over time $P = .03$, nerve-sparing increased risk $P = .03$
Eastham 2007 [24]	2442	1983–1990 and 1991–2004	18% versus 10%, $P = .001$	—	—
Touijer 2007 [19]	1177	2003–2005	No decrease over time	Decreased over time, $P = .0002$	—

* First 200 cases versus last 200 cases.

Table 3: The effect of margin status on PSA failure rate at 10 years.

First author, yr	n	Cohort years	PSA fail criterion, ng/mL	% PSM, overall	% biochemical failure rate		
					PSM	NSM	P value, HR
Williams 2011 [25]	158††	2005–2009	—	13	No f/u		
Ahyai 2010 [26]	932	1992–2004	≥0.1	12.9	21.7	6.9	$P = .001$
Tsao 2009 [27]	100*	2004–2007	≥0.2	23	—		
Sæther 2008 [28]	219	1996–2004	≥0.2	32.4	40	18	$P = .017$
Pfitzenmaier 2008 [29]	406	1990–2006	≥0.2	17.2	64.3	20.5	$P < .001$, HR 3.21
Swanson 2007 [30]	719	1985–1995	≥0.3	15.3	63	27	$P < .0001$
Ahyai 2010 [26]	936	1992–2003	≥0.4	37	19	7	$P < .01$
Kausik 2002 [31]	1202†	1987–1995	>0.2	42	35	24	$P = .0001$
Menon 2010 [32]	1384	2001–2005*	≥0.2	25.1	—	—	$P < .0001$, HR 2.43 (1.72–3.42)

* Robotic only.
† pT3 cases only.
†† pT2 cases only.

pathology after laparoscopic approaches have found a PSM rate comparable with that of an open approach [7, 8, 14, 15, 19]. PSM rates were as follow: open, 7.6% [10] to 41.6% [18]; laparoscopic without robot, 11.3% [19] to 21.3% [8]; robotic, 13% [15] to 24.44% [18].

PSM rate for robotic approaches was found to be significantly worse than that for open ones ($P = .007$) in one study [10]; however, two other studies found open approaches superior to the robotic ones [17, 18]. In the study that found the open approach better, the result was confounded by nerve sparing, so robotic prostatectomies showed a nonsignificant trend toward lower PSM for a non-nerve-sparing approach ($P = .09$) [10]. When the anterograde open approach was compared with the retrograde approach, significantly fewer PSMs were found by retrograde approach ($P = .03$) [9].

In a comparison of robotic versus nonrobotic laparoscopic approaches, one study found the robotic method superior [8]. Another found that the outcome was highly stage dependent, with 7% of pT2 patients with biochemical failure as opposed to 34% of pT3 patients [11]. Failure could also depend on number of positive margins [16]. In a study evaluating the robotic approach, a lower PSM rate was achieved by cold incision of the dorsal venous complex before suture ligation [12].

3.3. Comparison of PSM Rates by Duration of Surgical Experience (Table 2). In the above comparison of surgical approaches, it must be noted that the new laparoscopic approaches have a demonstrable learning curve. That is, in three studies conducted in the middle of the 2000–2010 decade, the PSM rate improved after a few years of practice [21–23]. While a significant decrease in PSM rate occurred over time with a laparoscopic approach, PSM held steady for open procedures during the same time period [19]. Even

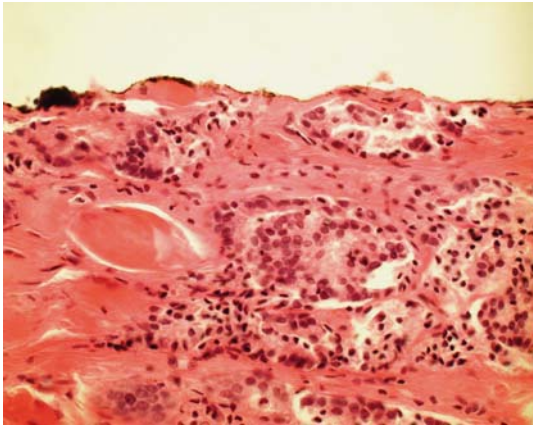

Figure 1: Prostatectomy specimen with a definite positive surgical margin (PSM). The inked resection margin transects tumor (400x).

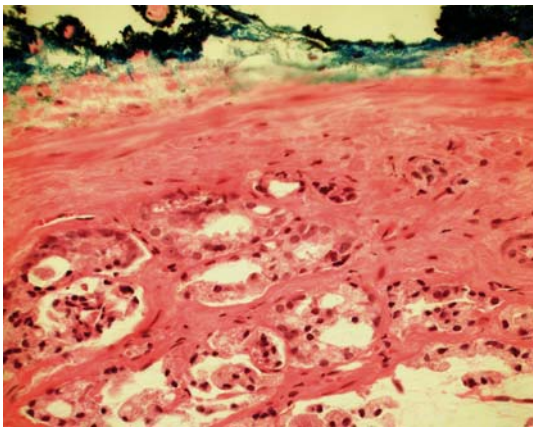

Figure 2: Prostatectomy specimen with negative surgical margin. Tumor approaches within less than 1 millimeter of the inked margin (400x).

with the open approach, during the 1990s and early 2000s, one study had noted that there was also a learning curve with respect to the PSM rate [24].

It is a bit disconcerting but it also must be admitted that individual surgeons may vary in their frequency of PSMs. In a study of 4,629 men operated on by open prostatectomy by one of 44 surgeons, for the 26 surgeons who each treated >10 patients, the rate of PSM ranged from 10% to 48% [33]. A 6-fold difference was even reported for the same surgeon at different institutions [13].

3.4. Margin Status Effect on PSA Failure Rate at 10 Years (Table 3). PSM rates in studies not comparing approaches ranged from 13% [25] to 42% [31] with a median 23% [27]. In the presence of a PSM, the failure rate was either double [28, 30, 32, 34, 40, 42, 43], triple [5, 26, 29, 38] or showed an increase of greater magnitude [4, 39] compared to NSM. Two studies did not specify this [5, 30]. In studies reporting a Hazard Ratio (HR) comparing a PSM to NSM, the HR ranged from 1.3 [46] up to 3.66 [42].

3.5. Tumor Stage (Table 4) or Grade (Table 5) Can Modify the Effect of PSM on PSA Failure Rates, at 10 Years. Nine studies compared PSA failure rates as a function of pathologic stage pT3a and pT3b versus pT2 or of pT3 versus pT2. (The apparent stage sometimes cannot be assessed because of capsular incision [58].) Failure rates with a PSM in stage pT2 ranged from 10.6% [38] to 63% [42], with an HR of 1.7 [4] to 3.81 [34] compared to having an NSM. For stage pT3a, failure rates were 38% [35] to 58% [36], with HR ranging from 1.4 [46] to 3.6 [4] compared to NSM. For stage pT3b, one study reports 71% failure, with HR of 1.4 compared to NSM [35]. Some studies chose to combine both pT3 substages and disclosed failure rates from 57% [37] to 75% [43] and HR of 4.1 [37] to 11.85 [38]. Thus, PSM exerts an effect that is synergistic with increasing stage, although the HR compared to NSM seems fairly constant across stages pT2, pT3a, and pT3b, at about 3 to 4. A study examining the phenomenon of capsular incision, sometimes denoted pT2+, found a 29.3% failure rate versus 7.3% for no incision ($P < .0001$) [46].

The HR for failure with a PSM seems to increase with increasing Gleason score [4, 35, 42, 44]. In one study [34], however, after controlling for Gleason score, a PSM versus NSM with Gleason ≤ 7 was significantly predictive of failure, while PSM versus NSM with Gleason ≥ 8 was not ($P = .115$). Finally, Cao et al. noted that the Gleason score at the positive margin was predictive of biochemical recurrence [59]. Also, as the Gleason score of the main tumor rose, the concordance with the grade at the margin diminished: 99% for score 6 but 38% for score 9. By multivariate analysis, Gleason score at the margin predicted biochemical failure ($P < .05$) [59].

3.6. The Effect of PSM on Mortality Rate at 10 Years Is Also Modified by Stage and Grade (Table 6). Three studies addressed the prostate cancer-specific death rate in the presence of a PSM. Two studies, one based on the SEER cancer data registry [45], found a significantly higher death rate at 10 years in the presence of a PSM [34, 45], namely, 0.86% versus 0.33% ($P < .001$) and 2.6% versus 0.6% which was significant ($P = .006$). In another study, from the Mayo Clinic registry, a PSM was not a significant predictor of death among 11,729 cases ($P = .15$), but did predict death in the subset that was stage pT3 [34].

3.7. PSA Failure Rates after a PSM Are Influenced by Length and Number of PSM (Table 7) and by Location of PSM (Table 8). Many pathologists report the length of a PSM. Using categorical PSM length cut-offs between 3 mm and 10 mm, length significantly affected outcome in many [36, 41, 47–49, 58] but not all [50–52] studies. Emerson et al. [53] found a PSM length >3 mm to be a significant outcome predictor by univariate analysis but it fell short of significance by multivariate analysis ($P = .076$) [53]. Moreover, the length of PSM by frozen section predicted residual tumor in additionally resected neurovascular bundles by multivariate analysis ($P < .001$) [55].

The number of PSMs probably lacks predictive value. In most studies, number of PSM was not significant for

Table 4: Modification of PSA failure rates according to stage, at 10 years (unless specified).

First author, yr	n	Cohort Years	PSA fail criterion ng/mL	% PSM, overall	% biochemical failure rate			% biochemical failure rate with PSM by stage					
					PSM	NSM	P value HR	pT2	P value, HR	pT3a	P value, HR	Stage pT3b	P value, HR
Williams 2010 [7]	4240	2004–2006	—	19.4	No f/u			14.9		42		—	
Ploussard 2010 [34]	1943	2000–2008	>0.2	25.6	54.2	29.9	$P < .001$, HR 2.6		$P < .001$, HR 3.81		$P = .001$, HR 2.09		$P = .1$, HR 1.46
Budäus 2010 [35]	4490	1992–2008	≥0.1	18.9	—			17 versus 5	HR 2.9	38 versus 26	HR 1.9	71 versus 53,	HR 1.4
Brimo 2010 [36]	108†	1995–2008	≥0.2	Inclusion criterion†	—				—	58		—	
Hsu 2010 [37]	164	1977–2004	≥0.2	48.2 (all cT3)	—				—		57%, HR 4.1, $P = .03$		
Ficarra 2009 [38]	322*	2005–2008	≥0.2	29.5	6.2	1.8	$P < .001$ (at 12 mo.)	10.6		57.5	$P < .001$, HR = 11.8	72.2	
Kwak 2010 [39]	266	1995–2007	≥0.2	18.5	52.6	8	$P < .0001$	29.3 versus 7.3$	$P < .0001$	51 versus 10.5	$P = .04$ HR 1.4,	—	
Hashimoto 2008 [40]	238**	1985–2005	≥0.2	34.4	38.4	19.3	$P < .001$		HR = 1		$P = .033$ HR 3.36,		$P = .002$, HR 7.13,
Chuang 2007 [41]	135**	1993–2004	≥0.2	—	—			28.7 versus 3.3	$P < .0001$	Focal EPE 21.4% versus 10.3%, $P = .02$, Ext EPE 41.5% versus 26%, $P < .0001$			
Orvieto 2006 [4]	996	1994–2004	≥0.1	8.8 (all); pT2 1.7, pT3a 24.9, pT3b 27.1	35	7.8	$P < .001$, HR 3.27		$P < .001$, HR = 1.7		$P = .011$, HR 3.6		$P = .19$, HR 6.5
Karakiewicz 2005 [42]	5831	1983–2000	≥0.1–≥0.4	26.7	63.9	29.9	$P = .001$, HR 3.66	63 versus 30	$P < .001$	—		—	
Swindle 2005 [43]	1369	1983–2000	≥0.4	12.9 (all); pT2 6.8, pT3 23	42	19	$P = .002$, HR 1.52	38.6 versus 19.6	$P < .001$	74.9% versus 53.8%, $P < .001$			

*Robotic only.
**Study used 5-year biochemical recurrence.
†Restricted to GS = 7, stage pT3a, and PSM.
$If there is capsular incision, versus no capsular incision.

Table 5: Modification of PSA failure rates according to grade, at 10 years (unless specified).

First author, yr	n	Cohort years	PSA Fail criterion, ng/mL	% PSM, overall	% biochemical failure rate			Gleason score effect on failure if PSM	
					PSM	NSM	P value, HR	Comparisons	P value, HR
Ploussard 2010 [34]	1943	2000–2008	>0.2	25.6	54.2	29.9	$P < .001$ HR 2.6	≤7 versus ≥8	$P < .001$ $P = .115$
Budäus 2010 [35]	4490	1992–2008	≥0.1	18.9	—	—		compared to GS = 6: for 3 + 4, for 4 + 3, for ≥8,	HR 2.81 HR 6.57 HR 9.86, all $P < .001$
Brimo 2010 [36]	108†	1995–2008	≥0.2	Inclusion criterion†	—	—		Score at margin	$P = .007$
Alkhateeb 2010 [44]	11,729‡	1992–2008	≥0.4	31.1	56	77	$P < .0001$ HR 1.63	Low risk 5.1% versus 0.4%; med. risk 17% versus 65%; hi. risk 43.9% versus 21.5%	—
Orvieto 2006 [4]	996	1994–2004	≥0.1	All 8.8; pT2 1.7, pT3a 24.9, pT3b 27.1	35	7.8	$P < .001$ HR 3.27	7 versus ≥8,	$P < .001$, HR 7.2 $P < .001$, HR 21
Karakiewicz 2005 [42]	5831	1983–2000	≥0.1 to ≥0.4	26.7	63.9	29.9	$P = .001$ HR 3.66	≥7	$P \leq .008$, HR 2.81

† Restricted to GS = 7, stage pT3a, and PSM.
‡ Risk groups based on Gleason score and preoperative PSA: low = PSA < 10, Gleason ≤ 6; medium = PSA 10–20 or Gleason 7; high = PSA > 20 or Gleason ≥ 8.

Table 6: Modification of prostate cancer mortality rates according to stage or grade, at 10 years.

First author, yr	n	PSA Fail criterion, ng/mL	PSM, %	Median f/u, yr	PCa death rate if			PSM rate or HR by stage		PSM rate by grade	
					PSM, %	NSM, %	P value, HR	pT2	pT3 a-b	Gleason ≥ 7	P value
Wright 2010 [45]	65,633	—	21.2	7	0.86	0.33	$P < .001$	17.7%	43.8%, $P < .001$	27.5% versus 18.3%	$P < .001$
Boorjian 2010 [34]	11,729	≥0.4	31.1	8.2	4	1	$P = .15$	HR 1.0	HR 2.1, $P < .0001$	—	—
Ploussard 2010 [34]	1943	>0.2	25.6	6.7	2.6	0.6	$P = .006$, 3.7 (1.5–9.5)	16.0	33.6–40.2	—	—

outcome [29, 31, 47, 49]. In two studies, multiple PSMs as opposed to a single PSM predicted failure (HR 1.4, $P = .002$ by multivariate analysis or HR = 2.19) [54, 58]. In another study, number of PSMs carried only borderline significance when ≥3 foci were positive compared to one ($P = .06$) and not significant for 2 foci compared to one [50]. Emerson et al. found that PSM number predicted failure by univariate analysis ($P = .037$) but lost most of its predictive value when adjusted for Gleason score ($P = .076$) [53].

The most common location of a PSM was in the posterior or posterolateral prostate [41, 47, 49], although one study found PSM equally common at the apex [24]. A positive apical soft tissue margin appears more consequential than a prostatic tissue margin [56]. Eastham et al. noted that the elevated risk of a posterior PSM means that "efforts to maintain adequate tissue covering including the routine excision of Denonvilliers' fascia and a component of the fat of the anterior rectal wall should be made in all patients…" [24]. Broken down by various sites, a posterolateral PSM predicted failure in most studies [24, 48] but not all [49].

Comparing various sites of PSM, the effect of an apical PSM was not significantly different from PSM at posterolateral or other sites [29, 52, 58], and another study concluded that the PSM location seemed not to predict failure [53]. However, in two studies, a positive posterolateral margin predicted failure while the apical margin did not [24, 57]. Possibly, residual apical tumor is less viable than residual tumor in the posterolateral region.

4. Conclusion

Prostate margin status is an important determinant of patient outcome after radical prostatectomy. In a 2010 College of American Pathologists survey, this feature was missing from 1% of pathology reports [60], thus the inclusion of this and other essential features is a quality assurance concern

Table 7: Modification of PSA failure rates according to PSM length or number of PSM, at 10 years (unless specified).

First author, yr	n	Cohort years	PSA fail criterion ng/mL	Median f/u, yr	PSM, overall	%Biochemical failure rate			According to length at margin		According to number of PSM	
						PSM	NSM	P value, HR	Fail rate with PSM	HR and P value	Fail rate with PSM	HR and P value
Brimo 2010 [36]	108†	1995–2008	≥0.2	3.0	Inclusion criterion	—	—		>3 mm: as continuous variable	$P = .004$ $P = .015$	—	—
van Oort 2010 [47]	174*	1995–2005	≥0.1	3.0	Inclusion criterion	29	—		>10 mm, 39% versus 21%	HR 2.3, $P = .022$	>1 versus 1	HR 1.46 $P = .24$
Lake 2010 [48]	1997	1996–2008	>0.2	4.1	18, 6.7 for T2	ext. 62, focal 36	16%	$P < .0001$	extensive 62%, focal 36% negative 16%	$P < .0001$	—	—
Stephenson 2009 [46]	7160	1995–2006	≥0.2	3.2	21	40		$P < .001$, HR = 2.3	extensive 66%, focal 34%	HR 1.3, $P = .004$†	multiple 83%, one 17%	HR 1.4, MVA †$P = .002$
Shikanov 2009 [49]	1398	2003–2008	≥0.1	1.0	17**	—		$P < .0001$, HR 4.4	<1 mm 1–3 mm >3 mm	HR 0.26 HR 9.6, $P = .03$ HR 14.8, $P = .01$	?	$P = .3$ for fail
Goetzl 2009 [50]	103	1998–2008	≥0.2	—	23.3	—	—		≥6 mm	HR 1.7, $P = .10$	≥3 PSM versus 1 versus 2 PSM	HR 1.3, $P = .06$ Not sig.
Pfitzenmaier 2008 [29]	406	1990–2006	≥0.2	5.2	17.2	64.3	20.5	$P < .001$, HR 3.21	—	—	≥3 versus 1	$P = .46$
Marks 2007 [51]	158	1990–1998	≥0.1	4	—	55	—		≥5 mm	HR 1.00, $P = .26$	—	—
Vis 2006 [52]	281	1994–1999	≥0.1	6.75	23.5	33.3	7.9	$P < .005$	Focal versus extensive	$P = .49$	—	—
Emerson 2005 [53]	369	1999–2003	≥0.1	1.0	23	25.6	—		Median 3 mm	$P = .031$ univariate but .076 multivar.††	Mean 2.45 versus 1.80	$P = .037$ by univar. analysis
Sofer 2002 [54]	498		≥0.2	4 yr 5 mo	19.7			HR 2.8, $P < .05$			≥2, versus 1	P = NS
Kausik 2002 [31]	1202†††	1987–1995	>0.2	4.9	42	35	24	$P = .0001$	—		≥2, 62% versus 1, 65%	P = NS
Fromont 2004 [55]	734	1992–1999	≥0.2		25	—			—		>2 versus 1	HR 2.19, P not done

*Study used 5-year biochemical recurrence.
**Robotic only.
†But a predictive model nomogram does not improve accuracy of predicting failure after prostatectomy.
††Linear extent of positivity was associated with other pathologic variables such as preoperative PSA and tumor volume and not independently predictive when adjusted for Gleason score.
†††pT3 cases only.

Table 8: Location of PSM and their modification of PSA failure rates, at 10 years (unless specified).

First author, yr	*n*	Cohort years	PSA fail criterion, ng/mL	Median f/u, yr	%PSM, overall	%Biochemical failure rate			Failure according to PSM location		Most common location
						PSM	NSM	*P* value, HR	% fail:	HR and *P* value	
van Oort 2010 [47]	174***	1995–2005	≥0.1	3.0	Inclusion criterion	29			—		Post 43%, ant 35%, apex 33%
Lake 2010 [48]	1997	1996–2008	>0.2	4.1	18, 6.7 for T2	Ext. 62 focal 36	16	$P < .0001$	Apex Ant Posterolat	HR 2.24, $P = .03$, HR 3.7, $P < .0001$ HR 2.5, $P = .002$	—
Godoy 2009 [56]	246**,***	2000–2006	>0.15	2.8	Apical surgical, 3.2, apical soft tissue, 6.6; total 9.8	—			Apical surgical 48.6%, apical soft tissue, 4.7%***		
Stephenson 2009 [46]	7160	1995–2006	≥0.2	3.2	21	40	HR = 2.3	$P < .001$	Apex versus other	HR 1.1, $P = .3$	—
Shikanov 2009 [49]	1398	2003–2008	≥0.1	1.0	17**	—	—	$P < .0001$ HR 4.4	Posterolateral	$P = .7$ for fail	Posterolat 45%; apex 29%; base 6%
Pfitzenmaier 2008 [29]	406	1990–2006	≥0.2	5.2	17.2	64.3	20.5	$P < .001$ HR 3.21	Apex versus nonapex	$P = .21$	
Eastham 2007 [24]	2442	1983–2004	≥0.2	2.9	11.2, pT2 7, pT3 22	25	10	$P = .0005$ HR 1.39	Posterolat. Posterior	HR 2.80 HR 1.96 versus neg, $P < .0005$	Apex 37%, posterolat 35%
Chuang 2007 [41]	135†***	1993–2004	≥0.2	—	—	28.7***	3.3	$P < .0001$			posterolat 61.5% post 19% ant 9%
Vis 2006 [52]	281	1994–1999	≥0.1	6.75	23.5	33.3	7.9	$P < .005$	Apex versus other	$P = .65$	—

Table 8: Continued.

First author, yr	*n*	Cohort years	PSA fail criterion, ng/mL	Median f/u, yr	%PSM, overall	%Biochemical failure rate			Failure according to PSM location		Most common location
						PSM	NSM	*P* value, HR	% fail:	HR and *P* value	
Emerson 2005 [53]	369	1999–2003	≥0.1	1.0	23	25.6	—		Location, gen'l:Ass'n for # of lateral sites:	$P = .437$ $P = .06$	
Pettus 2004 [57]	498		≥0.2	4.4	19.7			HR 2.9, $P < .05$, See breakdown	apex 21% nonapex 26%	$P = .25$, HR 2.25, $P < .05$, HR 2.96	apex 5.6, nonapex 11.4
Kausik 2002 [31]	1202[††]	1987–1995	>0.2	4.9	42	35	24	$P = .0001$	—		apex 46% post. 64%
Sofer 2002 [54]	734	1992–1999	≥0.2		25	—	—	—	—		apex 45%; post. 32%

[**] Robotic only.
[***] Study used 5-year biochemical recurrence.
[†] pT2 cases only.
[††] pT3 cases only.

for pathologists. Most urologic pathologists endorse the reporting of the extensiveness of positive margins, expressed as length, number, or radial extent positive for tumor cells; all these measurements have some relevance toward outcome. The presence of a positive margin confers a 2-3-fold increased hazard ratio for biochemical recurrence—modified by stage and tumor grade—and necessitates close clinical followup.

References

[1] J. I. Epstein and J. Sauvageot, "Do close but negative margins in radical prostatectomy specimens increase the risk of postoperative progression?" *Journal of Urology*, vol. 157, no. 1, pp. 241–243, 1997.

[2] R. E. Emerson, M. O. Koch, J. K. Daggy, and L. Cheng, "Closest distance between tumor and resection margin in radical prostatectomy specimens: lack of prognostic significance," *American Journal of Surgical Pathology*, vol. 29, no. 2, pp. 225–229, 2005.

[3] P. H. Tan, L. Cheng, J. R. Srigley et al., "International society of urological pathology (ISUP) consensus conference on handling and staging of radical prostatectomy specimens. Working group 5: surgical margins," *Modern Pathology*, vol. 24, no. 1, pp. 48–57, 2011.

[4] M. A. Orvieto, N. F. Alsikafi, A. L. Shalhav et al., "Impact of surgical margin status on long-term cancer control after radical prostatectomy," *BJU International*, vol. 98, no. 6, pp. 1199–1203, 2006.

[5] M. A. Simon, S. Kim, and M. S. Soloway, "Prostate specific antigen recurrence rates are low after radical retropubic prostatectomy and positive margins," *Journal of Urology*, vol. 175, no. 1, pp. 140–144, 2006.

[6] A. J. Evans, P. C. Henry, T. H. Van Der Kwast et al., "Interobserver variability between expert urologic pathologists for extraprostatic extension and surgical margin status in radical prostatectomy specimens," *American Journal of Surgical Pathology*, vol. 32, no. 10, pp. 1503–1512, 2008.

[7] S. B. Williams, A. V. D'Amico, A. C. Weinberg, X. Gu, S. R. Lipsitz, and J. C. Hu, "Population-based determinants of radical prostatectomy surgical margin positivity," *BJU International*, vol. 107, pp. 1734–1740, 2011.

[8] R. F. Coelho, B. Rocco, M. B. Patel et al., "Retropubic, laparoscopic, and robot-assisted radical prostatectomy: a critical review of outcomes reported by high-volume centers," *Journal of Endourology*, vol. 24, no. 12, pp. 2003–2015, 2010.

[9] A. Sciarra, C. Cristini, M. von Heland, S. Salciccia, and V. Gentile, "Randomized trial comparing an anterograde versus a retrograde approach to open radical prostatectomy: results in terms of positive margin rate," *Journal of the Canadian Urological Association*, vol. 4, no. 3, pp. 192–198, 2010.

[10] S. B. Williams, M. H. Chen, A. V. D'Amico et al., "Radical retropubic prostatectomy and robotic-assisted laparoscopic prostatectomy: likelihood of positive surgical margin(s)," *Urology*, vol. 76, pp. 1097–1101, 2010.

[11] R. F. Coelho, S. Chauhan, M. A. Orvieto, K. J. Palmer, B. Rocco, and V. R. Patel, "Predictive factors for positive surgical margins and their locations after robot-assisted laparoscopic radical prostatectomy," *European Urology*, vol. 57, no. 6, pp. 1022–1029, 2010.

[12] K. A. Guru, A. E. Perlmutter, M. J. Sheldon et al., "Apical margins after robot-assisted radical prostatectomy: does technique matter?" *Journal of Endourology*, vol. 23, no. 1, pp. 123–127, 2009.

[13] G. W. Bong, C. W. M. Ritenour, A. O. Osunkoya, M. T. Smith, and T. E. Keane, "Evaluation of modern pathological criteria for positive margins in radical prostatectomy specimens and their use for predicting biochemical recurrence," *BJU International*, vol. 103, no. 3, pp. 327–331, 2009.

[14] A. A. Hakimi, J. Blitstein, M. Feder, E. Shapiro, and R. Ghavamian, "Direct comparison of surgical and functional outcomes of robotic-assisted versus pure laparoscopic radical prostatectomy: single-surgeon experience," *Urology*, vol. 73, no. 1, pp. 119–123, 2009.

[15] T. A. J. Laurila, W. Huang, and D. F. Jarrard, "Robotic-assisted laparoscopic and radical retropubic prostatectomy generate similar positive margin rates in low and intermediate risk patients," *Urologic Oncology*, vol. 27, no. 5, pp. 529–533, 2009.

[16] T. Terakawa, H. Miyake, K. Tanaka, A. Takenaka, T. A. Inoue, and M. Fujisawa, "Surgical margin status of open versus laparoscopic radical prostatectomy specimens," *International Journal of Urology*, vol. 15, no. 8, pp. 704–708, 2008.

[17] J. A. Smith Jr., R. C. Chan, S. S. Chang et al., "A comparison of the incidence and location of positive surgical margins in robotic assisted laparoscopic radical prostatectomy and open retropubic radical prostatectomy," *Journal of Urology*, vol. 178, no. 6, pp. 2385–2390, 2007.

[18] E. Silva, U. Ferreira, G. D. Silva et al., "Surgical margins in radical prostatectomy: a comparison between retropubic and laparoscopic surgery," *International Urology and Nephrology*, vol. 39, no. 3, pp. 865–869, 2007.

[19] K. Touijer, K. Kuroiwa, J. A. Eastham et al., "Risk-adjusted analysis of positive surgical margins following laparoscopic and retropubic radical prostatectomy," *European Urology*, vol. 52, no. 4, pp. 1090–1096, 2007.

[20] K. A. Iczkowski, D. Hossain, K. C. Torkko et al., "Preoperative prediction of unifocal, unilateral, margin-negative, and small volume prostate cancer," *Urology*, vol. 71, no. 6, pp. 1166–1171, 2008.

[21] A. R. Rodriguez, K. Rachna, and J. M. Pow-Sang, "Laparoscopic extraperitoneal radical prostatectomy: impact of the learning curve on perioperative outcomes and margin status," *Journal of the Society of Laparoendoscopic Surgeons*, vol. 14, no. 1, pp. 6–13, 2010.

[22] D. S. Yee, N. Narula, M. B. Amin, D. W. Skarecky, and T. E. Ahlering, "Robot-assisted radical prostatectomy: current evaluation of surgical margins in clinically low-, intermediate-, and high-risk prostate cancer," *Journal of Endourology*, vol. 23, no. 9, pp. 1461–1465, 2009.

[23] M. Liss, K. Osann, and D. Ornstein, "Positive surgical margins during robotic radical prostatectomy: a contemporary analysis of risk factors," *BJU International*, vol. 102, no. 5, pp. 603–607, 2008.

[24] J. A. Eastham, K. Kuroiwa, M. Ohori et al., "Prognostic significance of location of positive margins in radical prostatectomy specimens," *Urology*, vol. 70, no. 5, pp. 965–969, 2007.

[25] AK Williams, V Chalasani, CH Martínez et al., "Cumulative summation graphs are a useful tool for monitoring positive surgical margin rates in robot-assisted radical prostatectomy," *BJU International*, vol. 107, no. 10, pp. 1648–1652, 2011.

[26] S. A. Ahyai, M. Zacharias, H. Isbarn et al., "Prognostic significance of a positive surgical margin in pathologically

organ-confined prostate cancer," *BJU International*, vol. 106, no. 4, pp. 478–483, 2010.

[27] A. K. Tsao, M. D. Smaldone, T. D. Averch, and S. V. Jackman, "Robot-assisted laparoscopic prostatectomy: the first 100 patients-improving patient safety and outcomes," *Journal of Endourology*, vol. 23, no. 3, pp. 481–484, 2009.

[28] T. Sæther, L. T. Sørlien, T. Viset, S. Lydersen, and A. Angelsen, "Are positive surgical margins in radical prostatectomy specimens an independent prognostic marker?" *Scandinavian Journal of Urology and Nephrology*, vol. 42, no. 6, pp. 514–521, 2008.

[29] J. Pfitzenmaier, S. Pahernik, T. Tremmel, A. Haferkamp, S. Buse, and M. Hohenfellner, "Positive surgical margins after radical prostatectomy: do they have an impact on biochemical or clinical progression?" *BJU International*, vol. 102, no. 10, pp. 1413–1418, 2008.

[30] G. P. Swanson, M. Riggs, and M. Hermans, "Pathologic findings at radical prostatectomy: risk factors for failure and death," *Urologic Oncology*, vol. 25, no. 2, pp. 110–114, 2007.

[31] S. J. Kausik, M. L. Blute, T. J. Sebo et al., "Prognostic significance of positive surgical margins in patients with extraprostatic carcinoma after radical prostatectomy," *Cancer*, vol. 95, no. 6, pp. 1215–1219, 2002.

[32] M. Menon, M. Bhandari, N. Gupta et al., "Biochemical recurrence following robot-assisted radical prostatectomy: analysis of 1384 patients with a median 5-year follow-up," *European Urology*, vol. 58, no. 6, pp. 838–846, 2010.

[33] J. A. Eastham, M. W. Kattan, E. Riedel et al., "Variations among individual surgeons in the rate of positive surgical margins in radical prostatectomy specimens," *Journal of Urology*, vol. 170, no. 6, pp. 2292–2295, 2003.

[34] G. Ploussard, M. A. Agamy, and O. Alenda, "Impact of positive surgical margins on prostate-specific antigen failure after radical prostatectomy in adjuvant treatment-naïve patients," *BJU International*, vol. 107, pp. 1748–1754, 2011.

[35] L. Budäus, H. Isbarn, C. Eichelberg et al., "Biochemical recurrence after radical prostatectomy: multiplicative interaction between surgical margin status and pathological stage," *Journal of Urology*, vol. 184, no. 4, pp. 1341–1346, 2010.

[36] F. Brimo, A. W. Partin, and J. I. Epstein, "Tumor grade at margins of resection in radical prostatectomy specimens is an independent predictor of prognosis," *Urology*, vol. 76, no. 5, pp. 1206–1209, 2010.

[37] C. Y. Hsu, M. F. Wildhagen, H. Van Poppel, and C. H. Bangma, "Prognostic factors for and outcome of locally advanced prostate cancer after radical prostatectomy," *BJU International*, vol. 105, no. 11, pp. 1536–1540, 2010.

[38] V. Ficarra, G. Novara, S. Secco et al., "Predictors of positive surgical margins after laparoscopic robot assisted radical prostatectomy," *Journal of Urology*, vol. 182, no. 6, pp. 2682–2688, 2009.

[39] K. W. Kwak, H. M. Lee, and H. Y. Choi, "Impact of capsular incision on biochemical recurrence after radical perineal prostatectomy," *Prostate Cancer and Prostatic Diseases*, vol. 13, no. 1, pp. 28–33, 2010.

[40] K. Hashimoto, N. Masumori, F. Takei et al., "Prognostic value of surgical margin status for biochemical recurrence following radical prostatectomy," *Japanese Journal of Clinical Oncology*, vol. 38, no. 1, pp. 31–35, 2008.

[41] A. Y. Chuang, M. E. Nielsen, D. J. Hernandez, P. C. Walsh, and J. I. Epstein, "The significance of positive surgical margin in areas of capsular incision in otherwise organ confined disease at radical prostatectomy," *Journal of Urology*, vol. 178, no. 4, pp. 1306–1310, 2007.

[42] P. I. Karakiewicz, J. A. Eastham, M. Graefen et al., "Prognostic impact of positive surgical margins in surgically treated prostate cancer: multi-institutional assessment of 5831 patients," *Urology*, vol. 66, no. 6, pp. 1245–1250, 2005.

[43] P. Swindle, J. A. Eastham, M. Ohori et al., "Do margins matter? The prognostic significance of positive surgical margins in radical prostatectomy specimens," *Journal of Urology*, vol. 174, no. 3, pp. 903–907, 2005.

[44] S. Alkhateeb, S. Alibhai, N. Fleshner et al., "Impact of positive surgical margins after radical prostatectomy differs by disease risk group," *Journal of Urology*, vol. 183, no. 1, pp. 145–150, 2010.

[45] J. L. Wright, B. L. Dalkin, L. D. True et al., "Positive surgical margins at radical prostatectomy predict prostate cancer specific mortality," *Journal of Urology*, vol. 183, no. 6, pp. 2213–2218, 2010.

[46] A. J. Stephenson, D. P. Wood, M. W. Kattan et al., "Location, extent and number of positive surgical margins do not improve accuracy of predicting prostate cancer recurrence after radical prostatectomy," *Journal of Urology*, vol. 182, no. 4, pp. 1357–1363, 2009.

[47] I. M. Van Oort, H. M. Bruins, L. A. L. M. Kiemeney, B. C. Knipscheer, J. A. Witjes, and C. A. Hulsbergen-Van De Kaa, "The length of positive surgical margins correlates with biochemical recurrence after radical prostatectomy," *Histopathology*, vol. 56, no. 4, pp. 464–471, 2010.

[48] A. M. Lake, C. He, and D. P. Wood Jr., "Focal positive surgical margins decrease disease-free survival after radical prostatectomy even in organ-confined disease," *Urology*, vol. 76, pp. 1212–1216, 2010.

[49] S. Shikanov, J. Song, C. Royce et al., "Length of positive surgical margin after radical prostatectomy as a predictor of biochemical recurrence," *Journal of Urology*, vol. 182, no. 1, pp. 139–144, 2009.

[50] M. A. Goetzl, R. Krebill, T. L. Griebling, and J. B. Thrasher, "Predictors of positive surgical margins after radical perineal prostatectomy," *The Canadian Journal of Urology*, vol. 16, no. 2, pp. 4553–4557, 2009.

[51] R. A. Marks, M. O. Koch, A. Lopez-Beltran, R. Montironi, B. E. Juliar, and L. Cheng, "The relationship between the extent of surgical margin positivity and prostate specific antigen recurrence in radical prostatectomy specimens," *Human Pathology*, vol. 38, no. 8, pp. 1207–1211, 2007.

[52] A. N. Vis, F. H. Schröder, and T. H. van der Kwast, "The actual value of the surgical margin status as a predictor of disease progression in men with early prostate cancer," *European Urology*, vol. 50, no. 2, pp. 258–265, 2006.

[53] R. E. Emerson, M. O. Koch, T. D. Jones, J. K. Daggy, B. E. Juliar, and L. Cheng, "The influence of extent of surgical margin positivity on prostate specific antigen recurrence," *Journal of Clinical Pathology*, vol. 58, no. 10, pp. 1028–1032, 2005.

[54] M. Sofer, K. L. Hamilton-Nelson, F. Civantos, and M. S. Soloway, "Positive surgical margins after radical retropubic prostatectomy: the influence of site and number on progression," *Journal of Urology*, vol. 167, no. 6, pp. 2453–2456, 2002.

[55] G. Fromont, X. Cathelineau, F. Rozet, D. Prapotnich, P. Validire, and G. Vallancien, "Impact of margin size on the incidence of local residual tumor after laparoscopic radical

prostatectomy," *Journal of Urology*, vol. 172, no. 5, pp. 1845–1847, 2004.

[56] G. Godoy, B. U. Tareen, and H. Lepor, "Is the apical soft tissue margin a better predictor of biochemical recurrence than the surgical specimen?" *Urologic Oncology*. In press.

[57] J. A. Pettus, C. J. Weight, C. J. Thompson, R. G. Middleton, and R. A. Stephenson, "Biochemical failure in men following radical retropubic prostatectomy: impact of surgical margin status and location," *Journal of Urology*, vol. 172, no. 1, pp. 129–132, 2004.

[58] A. Y. Chuang and J. I. Epstein, "Positive surgical margins in areas of capsular incision in otherwise organ-confined disease at radical prostatectomy: histologic features and pitfalls," *American Journal of Surgical Pathology*, vol. 32, no. 8, pp. 1201–1206, 2008.

[59] D. Cao, A. S. Kibel, F. Gao, Y. Tao, and P. A. Humphrey, "The gleason score of tumor at the margin in radical prostatectomy is predictive of biochemical recurrence," *American Journal of Surgical Pathology*, vol. 34, no. 7, pp. 994–1001, 2010.

[60] M. O. Idowu, L. G. Bekeris, S. Raab, S. G. Ruby, and R. E. Nakhleh, "Adequacy of surgical pathology reporting of cancer: a college of American pathologists q-probes study of 86 institutions," *Archives of Pathology and Laboratory Medicine*, vol. 134, no. 7, pp. 969–974, 2010.

Hindawi Publishing Corporation
Prostate Cancer
Volume 2011, Article ID 543272, 5 pages
doi:10.1155/2011/543272

Review Article

Review of Small Cell Carcinomas of the Prostate

P. Furtado,[1,2] M. V. A. Lima,[3] C. Nogueira,[3] M. Franco,[1] and F. Tavora[1,3]

[1] *Department of Pathology, Escola Paulista de Medicina Universidade Federal de São Paulo (UNIFESP), Rua Botucatu 740, São Paulo, SP, Brazil*
[2] *Presidente Dutra University Hospital, Federal University of Maranhao, São Luis, MA, Brazil*
[3] *Departments of Pathology and Urology, Cancer Institute of Ceara, CE, Brazil*

Correspondence should be addressed to F. Tavora, ftavora@gmail.com

Received 1 March 2011; Revised 16 May 2011; Accepted 30 May 2011

Academic Editor: Dengfeng Cao

Copyright © 2011 P. Furtado et al. This is an open access article distributed under the Creative Commons Attribution License, which permits unrestricted use, distribution, and reproduction in any medium, provided the original work is properly cited.

Small cell carcinoma of the prostate is a rare neoplasm, with only a few series hitherto reported. A little less than half of the cases are associated with conventional acinar adenocarcinoma, which are usually high grade. Although consensus has not been reached, the majority of patients with small cell neuroendocrine carcinoma of the prostate have advanced disease at diagnosis and disproportionally low PSA levels compared to patients with conventional acinar adenocarcinoma. Treatment consists mainly of chemotherapy associated with surgery. Radiation therapy is reserved for selected cases. This study reviews the most up-to-date information on small cell carcinomas of the prostate.

1. Introduction

Small cell neuroendocrine carcinoma of the prostate is a very uncommon type of prostate cancer, which was first described by Wenk et al. [1]. Lacking a specific classification, neuroendocrine tumors of the prostate are usually reported as carcinoid tumors, which are low-grade neuroendocrine carcinomas, and high-grade neuroendocrine carcinoma, which encompasses large neuroendocrine, small cell neuroendocrine carcinoma, and combined tumors, based on their histological and immunophenotypical profile [2–7].

Barely more than half of small cell carcinomas arising in the prostate are pure without an associated nonsmall cell component. A large number of cases are detected after androgen ablation therapy for conventional adenocarcinoma. In these situations, conventional acinar adenocarcinoma cells may differentiate along neuroendocrine lines [8].

The importance in recognizing small cell neuroendocrine carcinoma resides in its histological overlap with primary high Gleason-grade tumors of the prostate and its biological behavior, which implies in a different clinical presentation and treatment approach [9, 10].

Herein, we review the most up-to-date information on small cell neuroendocrine carcinoma of the prostate, focusing on its histological, immunophenotypical profile as well the most important differential diagnosis. Brief considerations on molecular pathology advances as well as treatment options are also stated.

2. Methods

A literature search for small cell neuroendocrine carcinoma of the prostate was performed. Referred articles were selected and reviewed, and data concerning clinical data of cancer occurrence, histological settings, immunohistochemical and molecular profiles, and treatment options are here discussed.

3. Discussion

Small cell neuroendocrine carcinoma is rare outside the lung. Approximately 10% cases occur in the prostate, making it one of the most common extrapulmonary sites [3, 6, 8, 9, 11–17]. PSA serum levels can vary from undetectable, especially in cases of conventional acinar tumors with prior hormone treatment, to high levels, with a mean level of 4.0 ng/dL(range 0–1896) in one large series [2, 6, 18, 19]. In this series, the interval between the diagnosis of small cell carcinoma subsequent to one of conventional tumors had a mean of 25 months [6]. Interestingly, in another series

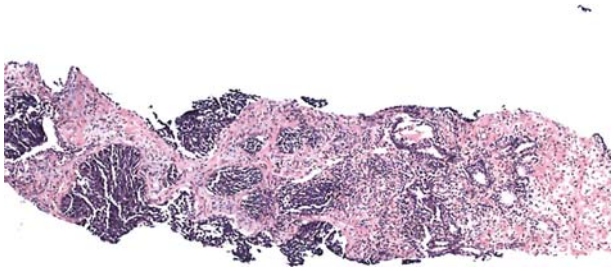

Figure 1: Low power of small cell carcinoma (left) associated with Gleason 7 acinar adenocarcinoma (right).

focusing on large cell neuroendocrine carcinoma (LCNEC), the interval between initial diagnosis of conventional tumor was higher, with a mean of 4.7 years [2]. Stage at presentation seems also to be higher in cases of tumors with neuroendocrine differentiation that were not subject to hormonal treatment [20].

In clinical studies where serum levels of PSA and chromogranin are followed, patients with increasing levels of those markers are diagnosed in an interval of 10 to 30 months, although it is still controversial if serum chromogranin levels independently correlate with prognosis and/or the presence of neuroendocrine differentiation in a given tumor [21–24].

Histological findings are identical to those tumors arising in extraprostatic sites: in small cell carcinoma, neoplastic cells are arranged mostly in a monomorphic pattern of small round or fusiform cells containing oval or convoluted hyperchromatic nuclei with a salt-and-pepper pattern chromatin, rarely with one or more discernible small nucleoli (Figure 1). Two types of tumor cells can be seen, the classic "oat cell" morphology and also an intermediate cell-type variant which have been described previously in other sites of the body [6]. The classic morphology is characterized by cells only slightly larger than lymphocytes with open chromatin and inconspicuous nucleoli, wherein the intermediate cell type, the tumor cells have more abundant cytoplasm, larger nuclei, and occasional visible nucleoli [6].

Pure small cell neuroendocrine carcinomas of the prostate are slightly more common than mixed small cell-adenocarcinomas. The latter occur usually with a high-grade component (Gleason ≥ 8) (Figures 2 and 3) [2, 6, 25, 26]. Cytoplasm is scant. Mitoses are readily discernible and can be numerous. Necrosis is another common histological finding but is usually not extensive. Perineural invasion is also common (Figure 4). Larger atypical cells, formation of true rosettes or pseudorosettes, and a large clear and vacuolated cytoplasm are also described. Another spectrum of neuroendocrine differentiation encompasses Paneth cell-like change. This phenomenon was reported by Weaver et al. and is characterized by the presence of small eosinophilic cytoplasmatic granules resembling intestinal Paneth cells in prostate cancer. Its true neuroendocrine origin is confirmed by immunohistochemical and electron microscopy studies [27].

For the surgical pathologist, the most critical and common issue concerning the diagnosis of a small cell neuroendocrine carcinoma is its confusion with a poorly differentiated acinar adenocarcinoma (Gleason 5), notably those with a solid pattern without gland formation and central necrosis in a small focus on needle biopsies. Indeed, misdiagnosing small cell carcinomas as high-grade acinar adenocarcinoma seems to occur commonly. Studies reveal a 0.5–2% incidence of small cell carcinoma in patients diagnosed in biopsies as opposed to a 10%–20% figure in autopsies cases [28, 29].

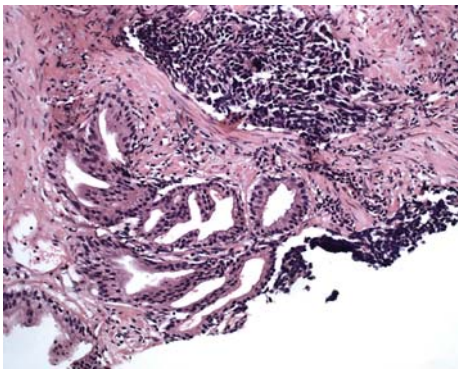

Figure 2: Combined acinar adenocarcinoma and small cell carcinoma diagnosed in a needle biopsy.

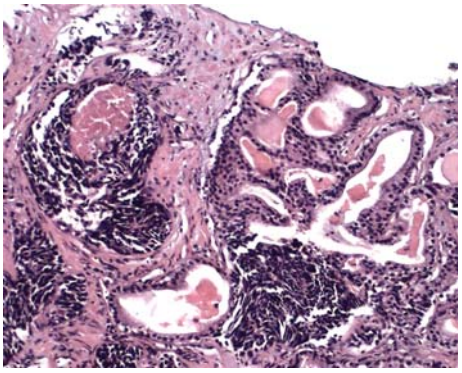

Figure 3: The same case as in Figure 2. Note gradual merging of small cell carcinoma with glands of acinar adenocarcinoma.

Although not required for the diagnosis of small cell carcinoma, immunohistochemical studies may be helpful (Table 1). A comprehensive immunohistochemical panel to differentiate small cell carcinoma from poorly differentiated adenocarcinoma includes PSA, PSAP, P501s, and neuroendocrine markers, CD 56 being the most sensitive for small cell carcinoma (Figures 5 and 6). TTF-1 can be positive in up to half of small cell carcinomas and is not found in the poorly differentiated adenocarcinomas [6, 17]. Most small cell carcinomas are negative for the aforementioned prostate markers (PSA, PSAP, and P501S), with some rare cases showing focal positivity, while poorly differentiated adenocarcinomas are usually diffusely positive for the same antibodies. Expression of neuroendocrine markers can be seen in conventional acinar adenocarcinomas, and the diagnosis of neuroendocrine carcinomas should rely in both immunohistochemical profile and light microscopic morphology.

Pulmonary small cell carcinomas are aggressive neoplasms commonly in advanced stages at diagnosis. PSA

Table 1: Immunohistochemical findings of small cell carcinoma of the prostate compared with conventional high-grade adenocarcinomas [6, 8, 10, 17, 20, 30–35].

Antibody	Small cell carcinoma (approximate percentage of positivity)	Poorly differentiated adenocarcinoma (approximate percentage of positivity)
Cytokeratin	(94%)	+ (70%)
Cytokeratin high molecular weight	(35%) −/+	− (0-33%)
CAM 5.2	(72%)	+ (90%)
CK 7	(39%) −/+	−/+ (30%)
CK 20	(11%) −/+	−/+ (10%)
PSA	(24%) −/+	++ (85%)
PSMA	(20%) −/+	++ (90%)
PSAP	(22%) −/+	++ (95%)
P501s	(25%) −/+	++ (90%)
p63	(40%) −/+	−/+ (15%)
TTF1	(83%) +/−	− (10%)
CD 56	(92%) +	− (10%)
Chromogranin	(80%) +	− (10%)
Synaptophysin	(85%) +	−/+ (13%)
CD44	(60-96%) ++	− (5%)

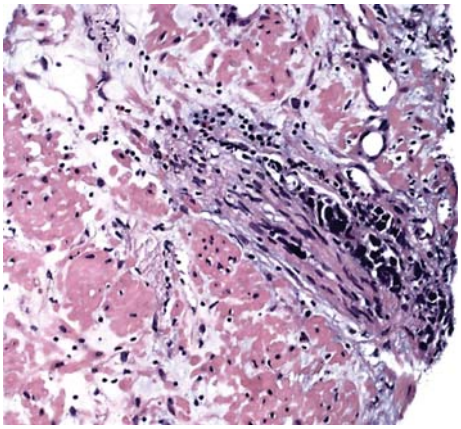

Figure 4: Perineural invasion by the small cell carcinoma component, diagnosed in a needle biopsy.

serum levels are not commonly elevated in primary small cell carcinomas of the prostate, and its levels are not helpful in separate metastatic lung disease from prostate small cell carcinoma. Immunohistochemistry can be helpful in distinguishing them, as small cell carcinomas can be positive (even focally) for at least one prostatic marker (PSA, PSMA, PSAP, or P501s) which are not expressed in lung tumors [36]. CD44, a cell-surface molecule proposed to identify cancer stem/progenitor cells in prostate cancer, has been demonstrated to be highly specific of small cell carcinoma of the prostate, when compared to conventional acinar adenocarcinoma or small cell carcinomas of other sites [10, 30].

The recent discoveries of the TMPRSS2-*ERG* rearrangement in subset of prostate cancer, with prevalence between

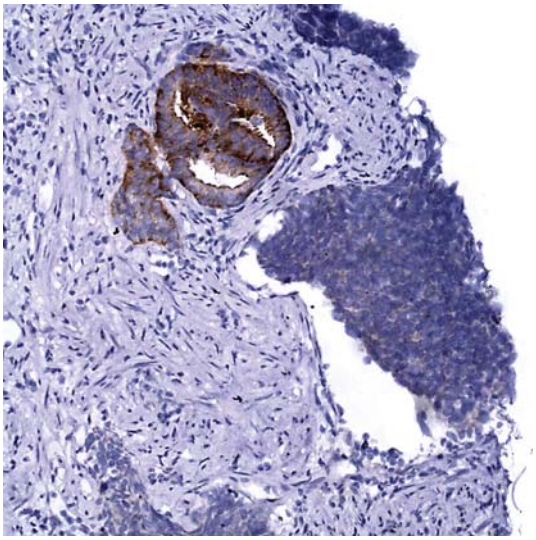

Figure 5: PSA immunostain showing strong positivity in benign prostate glands, whereas the neuroendocrine tumor is faint to absent.

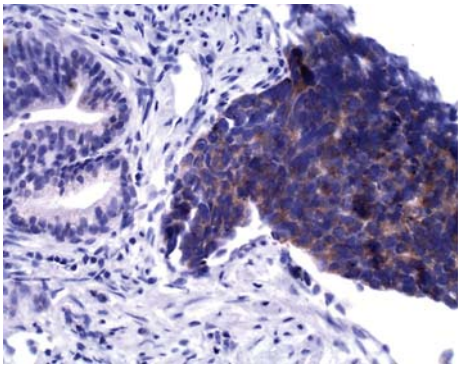

Figure 6: Small cell carcinoma with strong positivity for chromogranin immunostain.

40–70% of all tumors, raised the question of the presence of this genetic aberration in more aggressive forms of prostate tumors. Two recent papers have addressed the issue of the translocation in small cell carcinomas of the prostate. Guo et al. [37] evaluated the TMPRSS2-*ERG* gene fusion in 12 small cell carcinomas of the prostate with small cell carcinomas of the bladder and lung as control, by fluorescent in situ hybridization (FISH), and found the aberration in about 67% of the cases and in none of the controls. In a similar study, Lotan et al. [38] also found the *ERG* translocations in more than 45% of small cell carcinoma of the prostate, and in cases where the acinar component was also available for analysis, there was concordance for the presence/absence of *ERG* gene rearrangement between the different subtypes. These findings strongly suggest a common pathway of genesis of conventional acinar and also small cell carcinoma of the prostate.

More recent data on molecular characterization of small cell carcinoma of the prostate reported by Tai et al. [39] have shown specific association of those cases with PC3, one cell

line related to prostatic carcinoma. Indeed, those cells are immunohistochemically characterized by the expression of CD44, a stem cell marker commonly reported and believed to be more specific for small cell carcinoma of the prostate. On the contrary, conventional adenocarcinoma do not show CD44 positivity and have expression of PSA and androgen receptors like LNCaP, another known cell line associated with prostatic carcinoma [39].

The treatment of small cell carcinoma of the prostate includes a multimodality approach with chemotherapy as the mainstay of treatment, and radiation as supplemental for local control or for palliation. However, no uniform treatment being clearly established. Regimens that include gemcitabine, docetaxel and carboplatin, or cisplatin have been attempted with variable success [40–42]. Radiotherapy is also used, since patients with a small carcinoma diagnosis are not common candidates for surgical treatment [10, 14, 43, 44]. However, primary surgery was the most important prognostic factor for prolonged survival in one study [45]. Neuroendocrine differentiation may play an important role in the development of androgen resistance [14, 41], and advanced prostatic carcinomas with pure or partial neuroendocrine differentiation have a median survival of only 10 months. However, a case of mixed conventional acinar adenocarcinoma and small cell neuroendocrine carcinoma recently reported by Brammer et al. treated with concomitant hormonal and chemotherapy showed complete remission of disease 36 months after the initial diagnosis [46].

Another potential target for the treatment of small cell neuroendocrine carcinoma is the relaxin receptor RXFP1. Relaxin is a small peptide hormone expressed in several cancers such as those of endocrine origin. Its receptor, RXFP1 (a G-protein-coupled receptor), is expressed in androgen receptors' positive and negative cancers, as well as in prostate germ cells. In PC3 prostate cancer cell lines, which include small cell neuroendocrine carcinoma, treatment of RXFP1 showed significant reduction of tumor size, decrease in cell proliferation and metastatic disease, and increased apoptosis [47].

References

[1] R. E. Wenk, B. S. Bhagavan, and R. Levy, "Ectopic ACTH, prostatic oat cell carcinoma, and marked hypernatremia," *Cancer*, vol. 40, no. 2, pp. 773–778, 1977.

[2] A. J. Evans, P. A. Humphrey, J. Belani, T. H. van der Kwast, and J. R. Srigley, "Large cell neuroendocrine carcinoma of prostate: a clinicopathologic summary of 7 cases of a rare manifestation of advanced prostate cancer," *American Journal of Surgical Pathology*, vol. 30, no. 6, pp. 684–693, 2006.

[3] S. Giordano, T. Tolonen, S. Hirsimäki, and V. Kataja, "A pure primary low-grade neuroendocrine carcinoma (carcinoid tumor) of the prostate," *International Urology and Nephrology*, vol. 42, no. 3, pp. 683–687, 2009.

[4] K. H. Lim, M. J. Huang, S. Yang, R. K. Hsieh, and J. Lin, "Primary carcinoid tumor of prostate presenting with bone marrow metastases," *Urology*, vol. 65, no. 1, p. 174, 2005.

[5] A. Reyes and C. A. Moran, "Low-grade neuroendocrine carcinoma (carcinoid tumor) of the prostate," *Archives of Pathology & Laboratory Medicine*, vol. 128, no. 12, pp. e166–168, 2004.

[6] W. Wang and J. I. Epstein, "Small cell carcinoma of the prostate: a morphologic and immunohistochemical study of 95 cases," *American Journal of Surgical Pathology*, vol. 32, no. 1, pp. 65–71, 2008.

[7] A. Zarkovic, J. Masters, and L. Carpenter, "Primary carcinoid tumour of the prostate," *Pathology*, vol. 37, no. 2, pp. 184–186, 2005.

[8] N. Rekhtman, "Neuroendocrine tumors of the lung," *Archives of Pathology and Laboratory Medicine*, vol. 134, no. 11, pp. 1628–1638, 2010.

[9] F. Abbas, F. Civantos, P. Benedetto, and M. S. Soloway, "Small cell carcinoma of the bladder and prostate," *Urology*, vol. 46, no. 5, pp. 617–630, 1995.

[10] C. Alberti, "Neuroendocrine differentiation in prostate carcinoma: focusing on its pathophysiologic mechanisms and pathological features," *Giornale di Chirurgia*, vol. 31, no. 11-12, pp. 568–574, 2010.

[11] J. H. Yoo, J. H. Lee, E. K. Kim, Y. K. Hong, Y. Lee, and H. C. Jeong, "Prostatic metastasis of large cell neuroendocrine carcinoma of the lung," *Respirology*, vol. 14, no. 5, pp. 772–775, 2009.

[12] R. Mazzucchelli, D. Morichetti, A. Lopez-Beltran et al., "Neuroendocrine tumours of the urinary system and male genital organs: clinical significance," *BJU International*, vol. 103, no. 11, pp. 1464–1470, 2009.

[13] K. Brownback, J. Renzulli, R. DeLellis, and J. Myers, "Small-cell prostate carcinoma: a retrospective analysis of five newly reported cases," *Indian Journal of Urology*, vol. 25, no. 2, pp. 259–263, 2009.

[14] M. E. Stein, Z. Bernstein, U. Abacioglu et al., "Small cell (neuroendocrine) carcinoma of the prostate: etiology, diagnosis, prognosis, and therapeutic implications—A retrospective study of 30 patients from the rare cancer network," *American Journal of the Medical Sciences*, vol. 336, no. 6, pp. 478–488, 2008.

[15] A. Abrahamsson, "Neuroendocrine differentiation in prostatic carcinoma," *Prostate*, vol. 39, no. 2, pp. 135–148, 1999.

[16] P. A. Di Sant'Agnese and A. T. K. Cockett, "Neuroendocrine differentiation in prostatic malignancy," *Cancer*, vol. 78, no. 2, pp. 357–361, 1996.

[17] J. L. Yao, R. Madeb, P. Bourne et al., "Small cell carcinoma of the prostate: an immunohistochemical study," *American Journal of Surgical Pathology*, vol. 30, no. 6, pp. 705–712, 2006.

[18] N. Segawa, T. Inamoto, N. Ibuki et al., "Neuroendocrine differentiation in adenocarcinoma of the prostate during hormonal treatment: a case report," *Acta Urologica Japonica*, vol. 56, no. 1, pp. 49–54, 2010.

[19] A. Sella, M. Konichezky, D. Flex, A. Sulkes, and J. Baniel, "Low PSA metastatic androgen-independent prostate cancer," *European Urology*, vol. 38, no. 3, pp. 250–254, 2000.

[20] J. E. Oesterling, C. G. Hauzeur, and G. M. Farrow, "Small cell anaplastic carcinoma of the prostate: a clinical, pathological and immunohistological study of 27 patients," *Journal of Urology*, vol. 147, no. 3, part 2, pp. 804–807, 1992.

[21] L. O. Reis, L. F. Vieira, E. L. Zani, F. Denardi, L. C. De Oliveira, and U. Ferreira, "Assessment of serum chromogranin—A as prognostic factor in high-risk prostate cancer," *Journal of Investigative Medicine*, vol. 58, no. 8, pp. 957–960, 2010.

[22] A. Sciarra, F. Di Silverio, A. M. Autran et al., "Distribution of high chromogranin a serum levels in patients with non-metastatic and metastatic prostate adenocarcinoma," *Urologia Internationalis*, vol. 82, no. 2, pp. 147–151, 2009.

[23] S. Alessandro, G. Vincenzo, A. G. Maria et al., "Chromogranin A and biochemical progression-free survival in prostate adenocarcinomas submitted to radical prostatectomy," *Endocrine-Related Cancer*, vol. 14, no. 3, pp. 625–632, 2007.

[24] S. Isshiki, K. Akakura, A. Komiya, H. Suzuki, N. Kamiya, and H. Ito, "Chromogranin a concentration as a serum marker to predict prognosis after endocrine therapy for prostate cancer," *Journal of Urology*, vol. 167, no. 2, part 1, pp. 512–515, 2002.

[25] D. P. Sarma and T. G. Weilbaecher, "Small-cell carcinoma of prostate," *Urology*, vol. 33, no. 4, pp. 332–335, 1989.

[26] E. A. Turbat-Herrera, G. A. Herrera, I. Gore, R. L. Lott, W. E. Grizzle, and J. M. Bonnin, "Neuroendocrine differentiation in prostatic carcinomas. A retrospective autospy study," *Archives of Pathology and Laboratory Medicine*, vol. 112, no. 11, pp. 1100–1105, 1988.

[27] M. G. Weaver, F. W. Abdul-Karim, and J. R. Srigley, "Paneth cell-like change and small cell carcinoma of the prostate: two divergent forms of prostatic neuroendocrine differentiation," *American Journal of Surgical Pathology*, vol. 16, no. 10, pp. 1013–1016, 1992.

[28] Y. Miyoshi, H. Uemura, K. Kitami, Y. Satomi, Y. Kubota, and M. Hosaka, "Neuroendocrine differentiated small cell carcinoma presenting as recurrent prostate cancer after androgen deprivation therapy," *BJU International*, vol. 88, no. 9, pp. 982–983, 2001.

[29] M. Tanaka, Y. Suzuki, K. Takaoka et al., "Progression of prostate cancer to neuroendocrine cell tumor," *International Journal of Urology*, vol. 8, no. 8, pp. 431–436, 2001.

[30] R. A. Simon, P. A. di Sant'Agnese, L. S. Huang et al., "CD44 expression is a feature of prostatic small cell Carcinoma and Distinguishes it from its Mimickers," *Human Pathology*, vol. 40, no. 2, pp. 252–258, 2009.

[31] C. L. Owens, J. I. Epstein, and G. J. Netto, "Distinguishing prostatic from colorectal adenocarcinoma on biopsy samples: the role of morphology and immunohistochemistry," *Archives of Pathology and Laboratory Medicine*, vol. 131, no. 4, pp. 599–603, 2007.

[32] A. Y. Chuang, A. M. DeMarzo, R. W. Veltri, R. B. Sharma, C. J. Bieberich, and J. I. Epstein, "Immunohistochemical differentiation of high-grade prostate carcinoma from urothelial carcinoma," *American Journal of Surgical Pathology*, vol. 31, no. 8, pp. 1246–1255, 2007.

[33] M. Varma and B. Jasani, "Diagnostic utility of immunohistochemistry in morphologically difficult prostate cancer: review of current literature," *Histopathology*, vol. 47, no. 1, pp. 1–16, 2005.

[34] O. Hameed and P. A. Humphrey, "Immunohistochemistry in diagnostic surgical pathology of the prostate," *Seminars in Diagnostic Pathology*, vol. 22, no. 1, pp. 88–104, 2005.

[35] A. van der Gaast, J. Verweij, A. S. Planting, G. Stoter, and S. C. Henzen-Logmans, "The value of immunohistochemistry in patients with poorly differentiated adenocarcinomas and undifferentiated carcinomas of unknown primary," *Journal of Cancer Research and Clinical Oncology*, vol. 122, no. 3, pp. 181–185, 1996.

[36] D. E. Hansel, M. Nakayama, J. Luo et al., "Shared TP53 gene mutation in morphologically and phenotypically distinct concurrent primary small cell neuroendocrine carcinoma and adenocarcinoma of the prostate," *Prostate*, vol. 69, no. 6, pp. 603–609, 2009.

[37] C. C. Guo, J. Y. Dancer, Y. Wang et al., "TMPRSS2-ERG gene fusion in small cell carcinoma of the prostate," *Human Pathology*, vol. 42, no. 1, pp. 11–17, 2011.

[38] T. L. Lotan, N. S. Gupta, W. Wang et al., "ERG gene rearrangements are common in prostatic small cell carcinomas," *Modern Pathology*, vol. 24, no. 6, pp. 820–828, 2011.

[39] S. Tai, Y. Sun, J. M. Squires et al., "PC3 is a cell line characteristic of prostatic small cell carcinoma," *Prostate*. In press.

[40] H. Aoki, S. Ishidoya, A. Ito, M. Endoh, T. Shimazui, and Y. Arai, "Experience of the treatment with gemcitabine, docetaxel, and carboplatin (GDC) chemotherapy for patients with small-cell carcinoma of the prostate," *International Journal of Urology*, vol. 13, no. 9, pp. 1254–1258, 2006.

[41] J. Köllermann and B. Helpap, "Neuroendocrine differentiation and short-term neoadjuvant hormonal treatment of prostatic carcinoma with special regard to tumor regression," *European Urology*, vol. 40, no. 3, pp. 313–317, 2001.

[42] C. N. Papandreou, D. D. Daliani, P. F. Thall et al., "Results of a phase II study with doxorubicin, etoposide, and cisplatin in patients with fully characterized small-cell carcinoma of the prostate," *Journal of Clinical Oncology*, vol. 20, no. 14, pp. 3072–3080, 2002.

[43] D. Leibovici, P. E. Spiess, P. K. Agarwal et al., "Prostate cancer progression in the presence of undetectable or low serum prostate-specific antigen level," *Cancer*, vol. 109, no. 2, pp. 198–204, 2007.

[44] M. E. Spieth, Y. G. Lin, and T. T. Nguyen, "Diagnosing and treating small-cell carcinomas of prostatic origin," *Clinical Nuclear Medicine*, vol. 27, no. 1, pp. 11–17, 2002.

[45] J. R. Mackey, H. J. Au, J. Hugh, and P. Venner, "Genitourinary small cell carcinoma: determination of clinical and therapeutic factors associated with survival," *Journal of Urology*, vol. 159, no. 5, pp. 1624–1629, 1998.

[46] J. E. Brammer, P. Lulla, and G. R. Lynch, "Complete remission in a patient with metastatic mixed adenocarcinoma/extrapulmonary small cell carcinoma of the prostate," *International Journal of Clinical Oncology*. In press.

[47] S. Feng, I. U. Agoulnik, A. Truong et al., "Suppression of relaxin receptor RXFP1 decreases prostate cancer growth and metastasis," *Endocrine-Related Cancer*, vol. 17, no. 4, pp. 1021–1033, 2010.

Hindawi Publishing Corporation
Prostate Cancer
Volume 2011, Article ID 301850, 7 pages
doi:10.1155/2011/301850

Research Article

Proliferative Tumor Doubling Times of Prostatic Carcinoma

Priya N. Werahera,[1] L. Michael Glode,[2] Francisco G. La Rosa,[1] M. Scott Lucia,[1] E. David Crawford,[3] Kenneth Easterday,[4] Holly T. Sullivan,[1] Rameshwar S. Sidhu,[1] Elizabeth Genova,[1] and Tammy Hedlund[1]

[1] *Department of Pathology, University of Colorado Anschutz Medical Campus, P.O. Box 6511, Aurora, CO 80045, USA*
[2] *Medical Oncology, University of Colorado Anschutz Medical Campus, CO 80045, USA*
[3] *Radiation Oncology, University of Colorado Anschutz Medical Campus, CO 80045, USA*
[4] *Pharmacy Department, University of Colorado Anschutz Medical Campus, CO 80045, USA*

Correspondence should be addressed to Priya N. Werahera, priya.werahera@ucdenver.edu

Received 1 April 2011; Accepted 4 July 2011

Academic Editor: Kenneth A. Iczkowski

Copyright © 2011 Priya N. Werahera et al. This is an open access article distributed under the Creative Commons Attribution License, which permits unrestricted use, distribution, and reproduction in any medium, provided the original work is properly cited.

Prostate cancer (PCa) has a variable biology ranging from latent cancer to extremely aggressive tumors. Proliferative activities of cancers may indicate their biological potential. A flow cytometric assay to calculate maximum proliferative doubling times (T_{max}) of PCa in radical prostatectomy specimens after preoperative *in vivo* bromodeoxyuridine (BrdU) infusion is presented. Only 4/17 specimens had tumors large enough for flow cytometric analysis. The T_{max} of tumors was similar and ranged from 0.6 to 3.6 months. Tumors had calculated doubling times 2- to 25-fold faster than their matched normal tissue. Variations in labeling index and T_{max} were observed within a tumor as well as between different Gleason grades. The observed PSA doubling times (PSA-DT) ranged from 18.4 to 32.0 months, considerably slower than the corresponding T_{max} of tumors involved. While lack of data for apoptotic rates is a limitation, apparent biological differences between latent versus aggressive PCa may be attributable to variations in apoptotic rates of these tumors rather than their cell proliferative rates.

1. Introduction

In the year 2010, an estimated 217,000 men were expected to be diagnosed with prostate cancer and 32,000 men to die from this disease in the United States alone [1]. Prostatic carcinoma (PCa) is a multifocal disease characterized by marked heterogeneity of morphology as well as clinical behavior. Nearly two-thirds of prostates contain multiple cancer foci and the index or the largest tumor may not necessarily determine the clinical outcome [2]. Autopsy studies show that >50% of men age 50 and older have histologic evidence of PCa [3]. These latent tumors are histologically identical to aggressive PCa, but have not progressed or became clinically evident in spite of their histological similarities. Aggressive PCa may be differentiated from latent carcinoma based on volume, histologic grade, and tumor doubling times [4, 5].

Histologic architectural grading is considered the main prognostic tool for PCa [6]. However, the rate of proliferation and tumor doubling time are also expected to have prognostic relevance, and is key to understanding the biological behavior of the tumor [5, 7, 8]. Research in this direction has been limited due to difficulties of obtaining accurate cell kinetic data in clinical settings. Accurate prediction of tumor progression and patient survival is a challenging problem in the clinical management of prostate cancer.

Knowledge of the biological behavior of latent and aggressive tumors will assist clinicians in customizing the treatment modalities. The current concept is that two major categories of prostatic carcinomas exist: (1) those that are latent and will not become clinically significant in a patient's lifetime, and (2) clinically significant tumors that invade and have the potential to metastasize to distant sites

causing death. Prostate tumors of widely varying volumes (range 0.001–35 cc) can be found in a single prostatectomy specimen [2]. It is often assumed that the "small" volume tumors represent the slow growing latent ones while the "large" volume tumors represent the fast growing clinically significant ones. There is no absolute volume that defines "small" from "large" tumors. In addition, (a) small volume tumors can be of high grade and (b) even low-grade, low-volume carcinomas can be locally invasive [2]. While these categories imply that such tumors would have remarkably different doubling times, no data exist that directly measure this variable in appropriate tumors.

The method commonly used to measure proliferative activity is evaluation of the S-phase fraction of the tumor [9]. This is carried out with autoradiography, which has certain limitations. Several investigators have used bromodeoxyuridine (BrdU) incorporation in ethanol fixed prostate biopsy tissue for the study of S-phase fraction or potential doubling times of PCa [10, 11]. Potential doubling times of 23–61 days were observed, but low labeling indices of PCa were a confounding problem [11]. The present study was undertaken to establish a technique to isolate nuclei from formalin-fixed paraffin-embedded radical retropubic prostatectomy (RRP) specimens from patients who were infused with BrdU prior to surgery. These specimens were used to calculate maximum proliferative doubling times ($T_{\max}$) of PCa by flow cytometric analysis.

2. Materials and Methods

This study was approved by the Colorado Multiple Institutional Review Board at the University of Colorado, Denver. Between August 1999 and April 2002, written informed consent was obtained from 17 RRP patients. The BrdU solution of 25 mg/mL was diluted into 250 mL of normal saline. The dose strength was 200 mg per m^2 of body surface area. Between 20 and 48 hours prior to surgery, patients received BrdU by IV administration over a 30 min period. The starting and ending times of infusion were recorded, as well as the time of surgical removal of the prostate. Excised prostates were fixed in formalin, serially sectioned into 4 mm thick blocks, and paraffin-embedded for whole-mount section preparation [12]. From the proximal surface of each paraffin block, two 5-micron sections were cut. One set of 5-micron sections from each block was stained with hematoxylin and eosin (H&E) for routine histologic examination by a pathologist. The remaining set of 5-micron sections was used for immunohistochemical staining of BrdU to confirm nuclear incorporation. The boundary of the Gleason grade of each tumor focus was outlined in ink on H&E slides and transferred to acetate maps to generate 3D computer models of prostates as previously described [13, 14]. Biomorphometric data including multifocality, tumor volume, Gleason composition, capsule perforation were extracted from the 3D computer models of each RRP specimen [14]. Next, 3 sets of alternating 50-micron and 5-micron sections were cut from the proximal surface of each paraffin block containing the tumors of interest for doubling time analyses. Each 5-micron section was again H&E stained and mapped as described above. This was necessary to confirm the presence of tumors as they progressed through the blocks, and to track shifting positions of these tumors. Each 50-micron section was laid on top of the H&E slides containing the outlined tumors. After tracing the edges of the tumors onto the thick sections, tumors were excised using a razor blade. The Gleason score of all tumors were noted. Areas of relatively pure smooth muscle were also marked and excised for use as normal diploid, slow-growing controls for each patient's prostate. We define proliferative tumor doubling time $T_{\max}$ as the theoretical maximum doubling time assuming no cell death. The excised tissues were processed as follows.

2.1. Deparaffinization and Rehydration. Tissue samples were placed in Eppendorf centrifuge tubes and paraffin was removed by incubating for 3 min with Americlear (Richard-Allan Scientific, Kalamazoo, MI). Samples were centrifuged for 2 min at 389 ×g to gently pellet the tissue, and Americlear was removed. The washes with Americlear were repeated twice more. Residual Americlear was removed from the tissue with 2 changes of 100% ethanol, vortexing gently, and incubating 3 min each prior to centrifugation. Tissue was resuspended in fresh 100% ethanol (0.5 mL), and distilled water was added dropwise, tapping the tube between drops, to slowly rehydrate to a final volume of 1 mL (note: if tissue contains residual Americlear, the supernatant becomes cloudy upon the addition of water, and requires additional ethanol washes before attempting rehydration). After centrifugation, tissue was washed once in distilled water, centrifuged again, and supernatant removed.

2.2. Pepsin Digestion. Samples were resuspended in 1 mL 0.5% pepsin in 0.9% NaCl (pH 1.5), and incubated for 30 min at 37°C, vortexing after 15 min. After centrifugation to pellet cells, the supernatant was removed and fresh pepsin added. The suspension was pipetted to break up clumps of cells, and then incubated for 30 min at 37°C. After vortexing, the samples were allowed to continue to digest overnight at 4°C. Cells were then centrifuged and washed once with phosphate buffered saline (PBS) with pH 7.4 and once with distilled water, leaving approximately 150 μL of supernatant on each pellet prior to tapping to resuspend.

2.3. Acid Denaturation of DNA. While slowly vortexing each sample, 1 mL of 2 M HCl with 0.5% triton X-100 was added dropwise. If added too quickly, nuclei may lyse. Samples were then incubated at room temperature for 30 min, centrifuged at 389 ×g for 5 min, and neutralized with 1 mL 0.1 M sodium borate, pH 8.5. PBS (1 mL) was added to each tube, and the suspension was run through 35 μM cell strainers to remove undigested debris. Cells were then centrifuged and washed once in PBS with 0.1% bovine serum albumin and 0.5% Tween-20 (PBS-AT).

2.4. Antibody Staining. After removing most of the supernatant from each sample, the volume in each tube was adjusted to exactly 182.5 μL with PBS-AT, and 87.5 μL of each were transferred to new tubes for paired nonspecific controls. For BrdU detection, 5 μL mouse monoclonal anti-BrdU antibody (clone PrB1, FITC-labeled, Phoenix Flow Systems Inc., San Diego, CA) was added to one set of tubes, yielding a final antibody concentration of 12.5 μg/mL in 100 μL. To measure nonspecific antibody staining, the remaining tubes received 12.5 μL FITC-labeled mouse IgG1 (clone Dak-G01, Dako Corp., Carpenteria, CA) to yield 12.5 μg/mL in 100 μL. After mixing gently, tubes were incubated for either 40 min at room temperature in the dark (mixing after 20 min), or overnight at 4°C in the dark (mixing after 1 hour). Samples were washed 3 times in PBS-AT, incubating for 20–30 min at room temperature each time before centrifuging. These incubations are critical to allow diffusion of unbound antibody from the denatured DNA. The final cell pellet was resuspended in 0.4 mL PBS with 10 μg/mL propidium iodide and 0.05 mg/mL DNase-free RNase A. Samples were then incubated for 1–3 hours at 4°C (protected from light) to allow intercalation of propidium iodide and degradation of any remaining RNA.

2.5. Flow Cytometric Analyses. Samples were analyzed for red and green fluorescence as first reported by Begg et al. [9] on a Coulter XL flow cytometer (Coulter-Beckman, Fullerton, CA). Listmode data were obtained using 50,000 cells for most samples, and at least 10,000 cells for small tumor specimens. All initial listmode files were more carefully analyzed subsequently using Cytomation Summit software (Cytomation Inc., Fort Collins, CO) to fine-tune all gates and statistical regions. Three independent analyses of the same listmode data were done for each sample, to account for differences in how gates and statistical regions were drawn. The following values were collected from the flow cytometric histograms.

Histogram 1 (Figure 1(a)). Doublet discrimination was attempted by gating tightly on the G0/G1, S-phase, and G2/M populations. This was likely to exclude hypertetraploid cells if they existed, as well as doublets.

Histogram 2 (Figure 1(b)). Four different measurements were obtained from this histogram: FG1, FG2/M, FL, and LI. FG1 estimates the degree of red fluorescence (measured by mode rather than mean) of the BrdU-negative G0/G1 population. BrdU-positive cells are excluded from this measurement. FG2/M measures the red fluorescence (mode) of the BrdU-negative G2/M population. FL measures the mean red fluorescence of the BrdU-positive cells in S-phase and G2/M (exclude G0/G1). LI is the labeling index, measuring the percentage of all BrdU-positive cells.

The potential doubling times for each sample were then calculated using Begg's et al. original formulas [9], the flow cytometric values, and the length of time between the BrdU infusion and the surgical removal of the prostate (T_c);

Relative movement:

$$\mathrm{RM} = \frac{[\mathrm{FL} - \mathrm{FG1}]}{[\mathrm{FG2/M} - \mathrm{FG1}]},$$

Length of S-phase:

$$T_s = \frac{[0.5(T_c)]}{[\mathrm{RM} - 0.5]}, \tag{1}$$

Maximum proliferative doubling time:

$$T_{\max} = \frac{\lambda(T_s)}{\mathrm{LI}} \quad \text{where } \lambda \approx 1.$$

2.6. Immunohistochemical Staining of BrdU and Ki-67. Two sets of consecutive 5-micron sections from paraffin-embedded blocks of RRP specimens were used in immunohistochemical (IHC) staining for BrdU and Ki-67 [15]. First set of 5-micron sections was baked in a 60°C oven for 1 hour. Rats infused with BrdU were sacrificed and the intestine harvested to serve as the tissue controls. After deparaffinization, antigen retrieval was performed in BORG solution, pH 9.5 (Biocare Medical, Concord, CA) for 5 min in the Decloaking chamber pressure cooker (Biocare). Slides were left on the countertop for 5–10 min to cool down at room temperature. Endogenous peroxidase was blocked with aqueous 3% hydrogen peroxide for 10 min. Slides were rinsed in APK wash (1X solution, Ventana Medical Systems, Tucson, AZ). All reactions were performed at room temperature. Test slides and positive control were incubated in anti-BrdU, 1 : 10, (*in-situ* kit, BD Biosciences, San Diego, CA) for 1 hour in a humidified chamber. A negative control was incubated with mouse ascites, 1 : 500, (Sigma Aldrich, St. Louis, MO). Slides were rinsed 3 times in APK for 5 min each time, and then further incubated in Streptavidin-HRP supplied from the *in-situ* kit for 30 min in a humidified chamber. A mixture of 1 mL DAB (diaminobenzidine) buffer and 1 drop DAB chromogen was incubated on the slides for 5 min. Afterwards, DAB buffer was rinsed off with deionized water. Slides were equilibrated in aqueous 1% acetic acid, stained in 0.02% light green SF yellowish for 5 dips, and returned to the acetic acid bath to set the color. Finally, slides were dehydrated in graded alcohols, cleared with xylene, and mounted with synthetic resin.

IHC staining for Ki-67 was performed on the second set of 5-micron sections. A mouse antihuman antibody against Ki-67 (DAKO, Carpinteria, CA M7240; 1 : 300) was used to measure proliferation in the tissue sections. Antigen retrieval in BORG solution, pH 9.5 (Biocare Medical, Concord, CA, BDS1000G1) was performed for 5 minutes in the Decloaker pressure cooker (Biocare) at 125°C (22 psi). All incubations were accomplished by the Ventana NexES (Ventana Medical Systems, Tucson, AZ) immunostainer at 37°C. A Ventana I-VIEW DAB detection kit was used to detect the antigens through universal secondary antibodies, streptavidin-horseradish peroxidase enzyme, and DAB visualization.

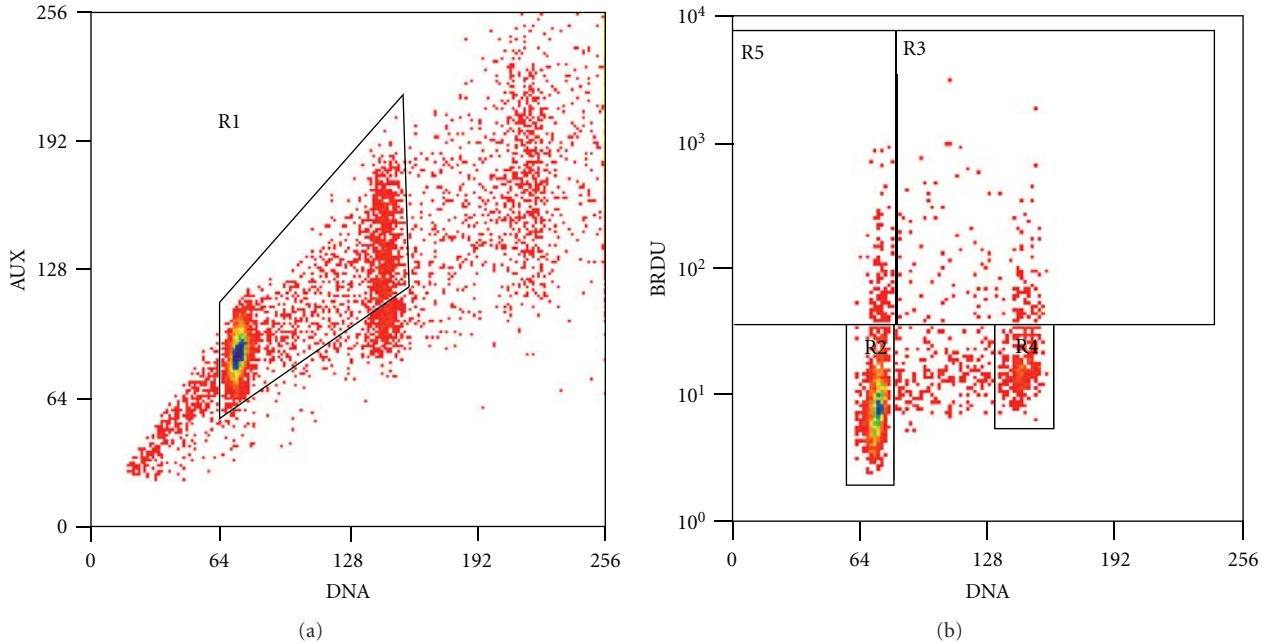

Figure 1: (a) Histogram 1: auxiliary peak red fluorescence versus red fluorescence, and (b) histogram 2: BrdU-FITC green fluorescence versus propidium iodide red fluorescence.

The sections were removed from the immunostainer and counterstained in light green sf yellowish (Sigma-Aldrich, St. Louis, MO, L1886-25G; 0.04% w/v) for 10 seconds, quickly dehydrated in graded alcohols, cleared in xylene, and mounted with synthetic resin. BrdU and Ki-67 LI using IHC staining were determined by counting number of positively stained cells per 1000 cells.

3. Results

The mean age of 17 patients was 57.6 ± 5.17 years (range 44–66 years) and the median age was 58 years. The mean prostate gland volume was 34.39 ± 10.45 cc (range 17.17–54.34 cc), the mean tumor volume was 1.62 ± 3.34 cc (range 0.001–8.663 cc), and the mean number of separate tumors was 2.6 (range 1–8). Only 4/17 prostates had tumors large enough for flow cytometric analysis. Tumor biomorphometry data of four prostates used in flow cytometric analyses are summarized in Table 1. The LI for BrdU and Ki-67 by IHC staining are given in Table 2. The mean LI for BrdU and Ki-67 was 2.14 ± 1.94% and 6.18 ± 4.27, respectively. There was no significant correlation between BrdU and Ki-67 LI (Pearson correlation coefficient $R = 0.41$, $P = 0.16$). Figure 2 illustrates a photomicrograph of Gleason pattern 3 PCa where BrdU has been incorporated into the DNA of 5–7% of dividing S-phase cancer cells. A typical distribution of BrdU-incorporated cell nuclei within Gleason pattern 4 glands is illustrated in Figure 3. Table 3 summarizes flow cytometry data for LI and $T_{\max}$ of prostate tumors from four prostates. The mean LI and T_s of prostate tumors and matched smooth muscle controls (in parenthesis) were 5.3 ± 3.1% (2.5 ± 0.28%) and 58 ± 27 hrs (224 ± 318 hrs), respectively. $T_{\max}$ of smooth muscle in different patients varied from 99 to 636 days. $T_{\max}$ for all tumors ranged from 19 to 108 days (0.6 to 3.6 months) and they doubled between 2-fold and 25-fold faster than their matched smooth muscle controls.

The large tumor PBr4-T1 doubled approximately 2-3-times faster than the small tumor PBr4-T2 depending on the block from which the large tumor samples were excised. For example, T1 doubled approximately twice as fast as T2 when sampled from Block H but it doubled 3-times faster when sampled from Block F. Similar variations in the doubling rates were observed in the large tumor PBr18-T2. In this case, Gleason patterns 3 and 4 portions of T2 in Blocks B and D doubled twice as fast as the Gleason pattern 4 portion of the same tumor in Block D. However, the small tumor PBr18-T1 in Block B doubled 1.5–3-times faster than large tumor T2 in Blocks B and D. In the remaining two specimens (PBr6, PBr16), only the $T_{\max}$ of one large tumor each was reported since we did not have sufficient cell count to run flow cytometric analysis of corresponding small tumors. Also in PBr16-T1, analysis was limited to tumors excised from only two blocks (E and G). LI for smooth muscle in different specimens remained relatively constant but it varied among different tumors as well as within tumors. PSA Doubling times (PSA-DT) of these patients were also calculated [16] and are presented in Table 4 with corresponding average $T_{\max}$ for each tumor. Even in this small sample of tumors analyzed, $T_{\max}$ values of tumors involved were considerably faster than corresponding PSA-DT observed for each patient.

4. Discussion

We have developed an assay to use *in vivo* BrdU infused, formalin-fixed, paraffin-embedded RRP specimens for $T_{\max}$

Table 1: Tumor biomorphometric data.

Specimen	Number of tumors	Gleason score	Tumor volume, cc	Volume of Gleason 3, cc	Volume of Gleason 4, cc
PBr4	1	3 + 3	2.823	2.823	
	2	3 + 3	0.121	0.121	
	3	3 + 3	0.022	0.022	
	4	3 + 3	0.006	0.006	
	5	3 + 3	0.015	0.015	
	6	3 + 3	0.001	0.001	
PBr6	1	3 + 3	0.656	0.656	
	2	3 + 3	0.009	0.009	
	3	3 + 4	0.037	0.025	0.012
	4	3 + 3	0.028	0.028	
PBr18	1	3 + 3	0.015	0.015	
	2	3 + 4	0.842	0.736	0.098
	3	3 + 3	0.755	0.755	
	4	3 + 4	0.023	0.009	0.014
	5	3 + 3	0.021	0.021	
PBr16	1	3 + 4	7.642	7.511	0.131
	2	3 + 3	0.022	0.022	

Table 2: BrdU and Ki-67 LI by IHC staining of consecutive 5-micron sections.

Specimen and block with tumor	*BrdU* LI % by IHC	*Ki67* LI % by IHC
PBr1-E	3.3	4.6
PBr2-C	0.4	7.5
PBr3-D	1.2	0.9
PBr6-E	1.1	2.8
PBr7-E	3.5	8.9
PBr8-C	1.3	3.1
PBr9-G	0.1	9.5
PBr10-C	2.2	5.0
PBr12-E	5.0	7.9
PBr14-D	0.4	2.1
PBr15-C	0.7	1.9
PBr16-D	6.5	10.6
PBr19-C	2.1	15.6

Figure 2: Gleason pattern 3 carcinoma with BrdU incorporated into the DNA of dividing cells (magnification 40X).

evaluation by flow cytometric analysis. This is the first report to establish an *in vivo* BrdU incorporation technique in formalin-fixed prostate tumors and the calculation of $T_{\max}$ in patients with prostate cancer. This protocol appears to accurately estimate doubling times of tissues with rat intestine controls being the fastest (24–48 hr) and human prostate smooth muscle being the slowest. Our data demonstrate that it is possible to study proliferative activity of prostate tumors by direct measurement of $T_{\max}$. Our data also suggest there are variations in $T_{\max}$ calculations within a tumor depending on where the tumor was sampled. Similar variations in $T_{\max}$ were observed within a specific Gleason grade as well as among different Gleason grades. This variability observed in the proliferative activity of prostate tumors in regard to size and Gleason pattern may be due to (a) block-to-block variations in fixation, and (b) the heterogeneous nature of cancer cells and the multifocality of this particular disease. Since we used the average value of $T_{\max}$ calculated from three consecutive samples for each tumor section, contributions due to variability of the methodology should be small compared to other factors. Immunohistochemical staining confirmed that BrdU had been incorporated into the DNA of dividing PCa cells. Each tumor had 2% or more labeled cells, sufficient for flow cytometric analysis and $T_{\max}$ calculations.

Out of 17 patients, we were able to analyze tumors of only four patients. The majority of the tumors were small (<0.1 cc) and hence we were unable to cut a sufficient number of 50-micron thick tissue sections for flow cytometric analysis. Several large tumors were used to develop and refine the flow cytometric protocol. This small sample size is one limitation of our study.

Nemoto et al. studied the S-phase fraction of biopsies collected from patients with *in vivo* BrdU incorporation [10]. The biopsies were fixed with ethanol, embedded in paraffin, sectioned, and stained by an indirect immunoperoxidase

Table 3: Proliferative tumor doubling times of prostatic carcinoma.

Specimen	Tumor	Tumor volume, cc	Block with tumor	Gleason pattern*	*BrdU* LI % by flow cytometry	T_{max}, days	Growth rate**
PBr4	T1	2.823	T1-F	3	9.1 ± 0.9	25.7 ± 4.0	25X
			T1-G	3	4.2 ± 0.5	41.5 ± 3.9	15X
			T1-H	3	3.7 ± 0.3	48.0 ± 4.0	13X
	T2	0.121	T2-C	3	3.4 ± 0.3	97.9 ± 7.8	7X
	Muscle	—	—	—	2.6 ± 0.0	636.2 ± 135.1	—
PBr6	T1	0.656	T1-B	3	3.2 ± 0.3	50.7 ± 1.5	2X
			T1-C	3	3.1 ± 0.3	51.1 ± 5.7	2X
	Muscle	—	—	—	2.3 ± 0.4	98.6 ± 12.7	—
PBr18	T1	0.015	T1-B	3	5.7 ± 2.2	36.6 ± 7.3	6X
	T2	0.842	T2-B	3 & 4	5.2 ± 1.1	52.2 ± 7.0	4X
			T2-D	4	3.8 ± 0.9	108.1 ± 14.8	2X
			T2-D	3 & 4	3.7 ± 0.7	57.4 ± 8.9	4X
	T3	0.755	T3-D	3	13.6 ± 1.7	17.3 ± 2.6	13X
			T3-E	3	4.9 ± 0.7	73.5 ± 9.1	3X
	Muscle	—	—	—	2.7 ± 0.1	221.7 ± 41.8	—
PBr16	T1	7.642	T1-E	3	2.0 ± 0.1	60.0 ± 4.8	2X
			T1-G	4	7.8 ± 0.2	19.0 ± 1.7	7X
	Muscle	—	—	—	1.4 ± 0.2	137.0 ± 33.0	—

*Gleason pattern: Gleason pattern of the excised tumor section for a given block.
**Growth rate: T_{max} of matched muscle/T_{max} of tumor.

Table 4: Proliferative tumor doubling time versus PSA doubling time.

Specimen and Tumor number		Tumor volume (cc)	Average T_{max}* (months)	PSA doubling Time (months)
PBr4	T1	2.823	1.28	18.4
	T2	0.121	3.26	
PBr6	T1	0.656	1.70	22.8
PBr18	T1	0.015	1.22	27.8
	T2	0.842	2.42	
	T3	0.755	1.51	
PBr16	T1	7.642	1.32	32.0

*is the average of T_{max} calculated when tumor is found in more than one paraffin block.

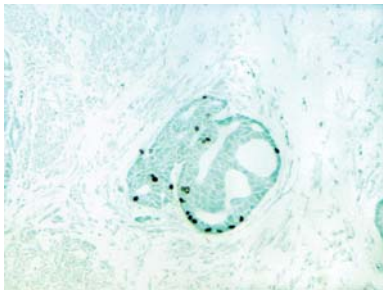

Figure 3: Distribution of BrdU incorporated cell nuclei within Gleason pattern 4 glands (magnification 100X).

method using anti-BrdU monoclonal antibody. LI was determined by counting the number of labeled cells. They demonstrated an average LI of Gleason grade 3, 2, and 1 PCa to be 4.37 ± 0.48%, 2.41 ± 0.49%, and 1.36 ± 0.39%, respectively. Haustermans et al. also used ethanol fixed biopsy tissue from patients with *in vivo* incorporation and reported potential doubling times from 23 to 61 days in prostate tumors among five patients [11].

In our study, the mean BrdU LI by IHC staining was 2.14 ± 1.94% and by flow cytometry 5.3 ± 3.1%. Ki-67 LI also measures cell proliferation. Nagao et al. found that prostate cancer patients with PSA > 4 had a mean Ki-67 LI of 10.5 ± 2.2% [15]. The mean Ki-67 LI in our study was 6.18 ± 4.27%. However, we did not find any significant correlation between BrdU and Ki-67 LI. Since T_{max} depends on both T_s and LI (given by the formula $T_{max} = \lambda(T_s)/\text{LI}$), it is not possible to establish a direct correlation between T_{max} and LI alone. Consequently, LI of BrdU either by IHC or by flow cytometry alone are not accurate predictors of T_{max} and hence the biological potential of tumors. Our results suggest that the measurement of BrdU LI and T_{max} calculations by flow cytometry using formalin-fixed paraffin-embedded prostates may prove to be a quantitative assay of the biological potential of individual tumors.

Schmid et al. found that PSA-DT were faster in patients with higher stages and grades [17, 18]. They found 20/28 clinically organ-confined cancers doubled at rates exceeding 4 years and concluded that prostate tumors have a constant (log-linear) growth rate that is very slow. It should be noted that in men with PSA levels between 4 and 10 with relatively small volume clinically localized tumors, the PSA levels do not correlate well with the tumor volume which potentially indicates that PSA levels in these patients may

not be driven by the cancer cells themselves, but rather by other benign processes in the prostate such as inflammation and/or BPH [19]. In our study, total tumor volume of each prostate selected for flow cytometry was relatively large and hence PSA levels do correlate with tumor volume. PSA-DT for our patients were 18.4–32 months (552–960 days) [16]. This "apparent" slow growth rate of PCa tumors indirectly evaluated from PSA doublings may be attributed to concomitant cell death (apoptosis). Therefore, apoptosis is an important determinant of PSA-DT. Even though PCa cells are dividing at a faster rate, a relatively high apoptotic rate may result in a much slower net growth rate. However, there are no direct methods available to measure *in vivo* apoptotic rates of PCa as cells that undergo apoptosis are removed from the gland. Nevertheless, apparent biological differences between latent versus aggressive PCa may be attributable to variations in cell death rates of these tumors more than to their cell proliferative rates.

5. Conclusion

A flow cytometric assay using *in vivo* BrdU-infused, formalin-fixed paraffin-embedded RRP specimens was developed to determine $T_{\max}$ of prostate tumors. $T_{\max}$ of 4 PCa tended to be similar regardless of tumor volume or histologic grade. However, $T_{\max}$ of tumors were faster than observed PSA-DT of corresponding patients. While lack of data for apoptotic rates is a limitation of this study, relative variations in apoptotic rates may make the difference between latent and aggressive PCa, rather than $T_{\max}$. Future studies need to focus on tumor proliferative doubling times as well as apoptotic rates to better understand biological differences of latent versus aggressive prostate cancer.

Acknowledgment

The authors would like to respectfully acknowledge scientific insight and contributions to this paper by the late Dr. Gary J. Miller who passed away in 2001. Supported by United States Public Health Service Grant CA66161. Presented in abstract format at the *15th International Prostate Cancer Update*, The Vail Cascade, Colorado, February, 2005 and at the *AUA Annual Meeting*, San Antonio, Texas, May 2005.

References

[1] A. Jemal, R. Siegel, J. Xu, and E. Ward, "Cancer statistics, 2010," *CA Cancer Journal for Clinicians*, vol. 60, no. 5, pp. 277–300, 2010.

[2] G. J. Miller and J. M. Cygan, "Morphology of prostate cancer: the effects of multifocality on histological grade, tumor volume and capsule penetration," *Journal of Urology*, vol. 152, no. 5, pp. 1709–1713, 1994.

[3] W. A. Sakr, D. J. Grignon, J. D. Crissman et al., "High grade prostatic intraepithelial neoplasia (HGPIN) and prostatic adenocarcinoma between the ages of 20–69: an autopsy study of 249 cases," *In Vivo*, vol. 8, no. 3, pp. 439–443, 1994.

[4] E. D. Crawford, D. Hirano, P. N. Werahera et al., "Computer modeling of prostate biopsy: tumor size and location—not clinical significance—determine cancer detection," *Journal of Urology*, vol. 159, no. 4, pp. 1260–1264, 1998.

[5] D. Hirano, P. N. Werahera, E. D. Crawford, M. S. Lucia, E. P. DeAntoni, and G. J. Miller, "Morphological analysis and classification of latent prostate cancer using a 3-dimensional computer algorithm: Analysis of tumor volume, grade, tumor doubling time and life expectancy," *Journal of Urology*, vol. 159, no. 4, pp. 1265–1269, 1998.

[6] D. F. Gleason, G. T. Mellinger, and L. J. Ardving, "Prediction of prognosis for prostatic adenocarcinoma by combined histological grading and clinical staging," *Journal of Urology*, vol. 111, no. 1, pp. 58–64, 1974.

[7] D. S. Coffey and J. T. Isaacs, "Prostate tumor biology and cell kinetics—theory," *Urology*, vol. 17, no. 3, pp. 40–53, 1981.

[8] D. M. Berney, "Biomarkers for prostate cancer detection and progression: beyond prostate-specific antigen," *Drug News and Perspectives*, vol. 23, no. 3, pp. 185–194, 2010.

[9] A. C. Begg, N. J. McNally, D. C. Shrieve, and H. Karcher, "A method to measure the duration of DNA synthesis and the potential doubling time from a single sample," *Cytometry*, vol. 6, no. 6, pp. 620–626, 1985.

[10] R. Nemoto, K. Uchida, T. Shimazui, K. Hattori, K. Koiso, and M. Harada, "Immunocytochemical demonstration of S phase cells by anti-bromodeoxyuridine monoclonal antibody in human prostate adenocarcinoma," *Journal of Urology*, vol. 141, no. 2, pp. 337–340, 1989.

[11] K. M. G. Haustermans, I. Hofland, P. H. Van Poppel et al., "Cell kinetic measurements in prostate cancer," *International Journal of Radiation Oncology Biology Physics*, vol. 37, no. 5, pp. 1067–1070, 1997.

[12] G. J. Miller and J. M. Cygan, "Diagnostic correlations with whole mounts of radical prostatectomy specimens," *Monographs in Pathology*, no. 34, pp. 183–197, 1992.

[13] D. F. Gleason, "Histologic grading and clinical staging of prostatic carcinoma," in *Urologic Pathology: The Prostate*, M. D. Tannenbaum, Ed., pp. 171–198, Lea & Febiger, Philadelphia, Pa, USA, 1977.

[14] P. N. Werahera, G. J. Miller, K. Torkko et al., "Biomorphometric analysis of human prostatic carcinoma by using three-dimensional computer models," *Human Pathology*, vol. 35, no. 7, pp. 798–807, 2004.

[15] K. Nagao, Y. Yamamoto, T Hara et al., "Ki67 and BUBR1 may discriminate clinically insignificant prostate cancer in the PSA range <4 ng/ml," *Japanese Journal of Clinical Oncology*, vol. 41, pp. 555–564, 2011.

[16] R. S. Svatek, M. Shulman, P. K. Choudhary, and E. Benaim, "Critical analysis of prostate-specific antigen doubling time calculation methodology," *Cancer*, vol. 106, no. 5, pp. 1047–1053, 2006.

[17] H. P. Schmid, J. E. McNeal, and T. A. Stamey, "Clinical observations on the doubling time of prostate cancer," *European Urology*, vol. 23, no. 2, pp. 60–63, 1993.

[18] H. P. Schmid, J. E. McNeal, and T. A. Stamey, "Observations on the doubling time of prostate cancer: the use of serial prostate-specific antigen in patients with untreated disease as a measure of increasing cancer volume," *Cancer*, vol. 71, no. 6, pp. 2031–2040, 1993.

[19] M. S. Lucia, A. K. Darke, P. J. Goodman et al., "Pathologic characteristics of cancers detected in the prostate cancer prevention trial: implications for prostate cancer detection and chemoprevention," *Cancer Prevention Research*, vol. 1, no. 3, pp. 167–173, 2008.