Journal of Ophthalmology

Innovations in Glaucoma Surgery: Improving the Results

Guest Editors: Michele Figus, Shlomo Melamed, Antonio Ferreras, Giorgio Marchini, and Vital P. Costa

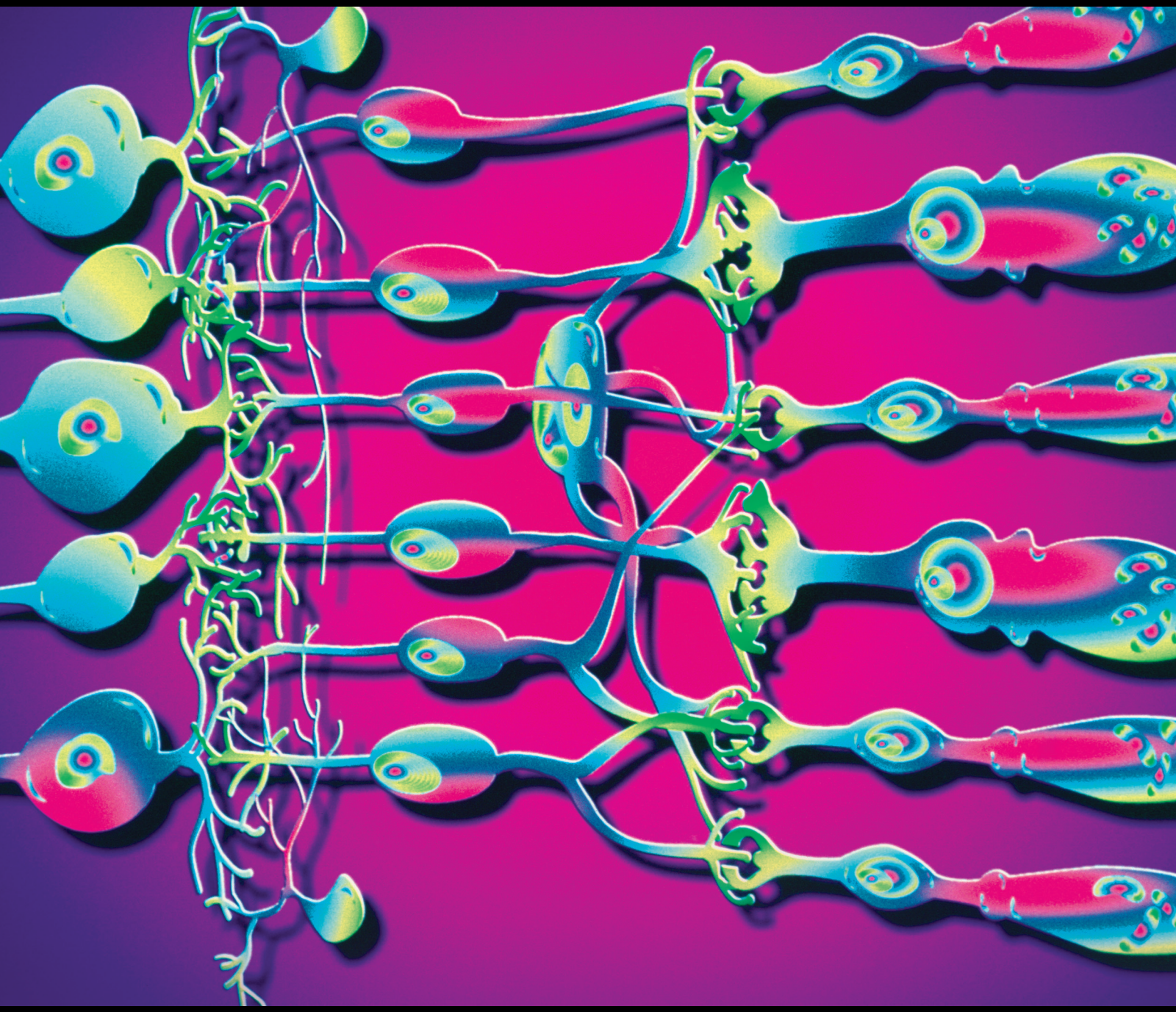

Innovations in Glaucoma Surgery: Improving the Results

Journal of Ophthalmology

Innovations in Glaucoma Surgery: Improving the Results

Guest Editors: Michele Figus, Shlomo Melamed, Antonio Ferreras, Giorgio Marchini, and Vital P. Costa

Editorial Board

Contents

Innovations in Glaucoma Surgery: Improving the Results
Michele Figus, Shlomo Melamed, Antonio Ferreras, Giorgio Marchini, and Vital P. Costa
Volume 2016, Article ID 5856075, 2 pages

iStent® Trabecular Microbypass Stent: An Update
Arthur Fernandes Resende, Neal Sanjay Patel, Michael Waisbourd, and L. Jay Katz
Volume 2016, Article ID 2731856, 9 pages

Canaloplasty: Current Value in the Management of Glaucoma
Carlo Cagini, Claudia Peruzzi, Tito Fiore, Leopoldo Spadea, Myrta Lippera, and Stefano Lippera
Volume 2016, Article ID 7080475, 6 pages

Stab Incision Glaucoma Surgery: A Modified Guarded Filtration Procedure for Primary Open Angle Glaucoma
Soosan Jacob, Michele Figus, Dhivya Ashok Kumar, Ashvin Agarwal, Amar Agarwal, and Saijimol Areeckal Incy
Volume 2016, Article ID 2837562, 7 pages

Comparison of Subconjunctival Mitomycin C and 5-Fluorouracil Injection for Needle Revision of Early Failed Trabeculectomy Blebs
Wei Liu, Jianrong Wang, Miaomiao Zhang, Yuan Tao, and Yan Sun
Volume 2016, Article ID 3762674, 6 pages

Comparison of Surgical Outcomes between Canaloplasty and Schlemm's Canal Scaffold at 24 Months' Follow-Up
Stefano A. Gandolfi, Nicola Ungaro, Stella Ghirardini, Maria Grazia Tardini, and Paolo Mora
Volume 2016, Article ID 3410469, 5 pages

Influence of Endothelin-1 in Aqueous Humor on Intermediate-Term Trabeculectomy Outcomes
Lars Choritz, Benjamin Mahmoodi, and Hagen Thieme
Volume 2016, Article ID 2401976, 8 pages

Outcomes of 23-Gauge Vitrectomy Combined with Phacoemulsification, Panretinal Photocoagulation, and Trabeculectomy without Use of Anti-VEGF Agents for Neovascular Glaucoma with Vitreous Hemorrhage
Hua Yan
Volume 2016, Article ID 3097379, 7 pages

Biodegradable PTLGA Terpolymers versus Collagen Implants Used as an Adjuvant in Trabeculectomy in Rabbit Eye
Weiran Niu, Guanglin Shen, Yuanzhi Yuan, Xiaoping Ma, Suming Li, Jingzhao Wang, Zhongyong Fan, and Lan Liao
Volume 2015, Article ID 737198, 9 pages

Hindawi Publishing Corporation
Journal of Ophthalmology
Volume 2016, Article ID 5856075, 2 pages
http://dx.doi.org/10.1155/2016/5856075

Editorial

Innovations in Glaucoma Surgery: Improving the Results

Michele Figus,[1] Shlomo Melamed,[2] Antonio Ferreras,[3] Giorgio Marchini,[4] and Vital P. Costa[5]

[1] *University of Pisa, 56126 Pisa, Italy*
[2] *University of Tel Aviv, 6997801 Tel Aviv, Israel*
[3] *Miguel Servet University of Zaragoza, 50009 Zaragoza, Spain*
[4] *University of Verona, 37129 Verona, Italy*
[5] *University of Campinas, 13083-970 Campinas, SP, Brazil*

Correspondence should be addressed to Michele Figus; figus@ocupisa.it

Received 9 June 2016; Accepted 12 June 2016

Glaucoma still represents the most frequent cause of irreversible blindness worldwide. The technological advances lead to innovative surgeries, which are rapidly introduced in clinical practice. New devices to lower intraocular pressure without opening the eye wall, bypassing the trabecular meshwork, or shunting the aqueous humor to the suprachoroidal space have been approved undergoing clinical assessment within clinical trials. Currently, other devices under evaluation are showing promising results. Although these methods will increase the options available for glaucoma surgeons, it is unclear if they could replace the present standard surgeries, such as trabeculectomy, deep sclerectomy, and glaucoma drainage devices. Moreover, the standard procedures are continuously modified in different ways to become safer and more effective.

In this issue L. Choritz et al. investigate whether increased concentrations of endothelin-1 in the aqueous humor samples of glaucoma patients influenced wound healing and bleb fibrosis after standard trabeculectomy with mitomycin C. Endothelin-1 is a potent vasoconstrictor produced in the eye by the ciliary epithelium and to be released into the aqueous humor. It has been implicated in the pathophysiology of glaucoma. Endothelin-1 is believed to be involved in the regulation of intraocular pressure (IOP) via effects on the contractility of ciliary muscle and trabecular meshwork.

W. Niu et al. evaluated the efficacy and safety of three different biodegradable terpolymers after trabeculectomy in rabbit eyes compared with Ologen™. The use of these implants aims to reduce the use of mitomycin C as an anti-scarring agent. The first implant used was a porous collagen-glycosaminoglycan matrix, which prevents the adhesion of the conjunctiva and sclera and the collapse of the subconjunctival space after trabeculectomy, leading to collagen deposition and microcyst formation after penetrating antiglaucomatous surgery.

Despite the increasing use of antifibrotic agents to modulate the wound healing response, bleb failure remains a common complication of glaucoma filtration surgery. In the paper by W. Liu et al. the needle revision and subconjunctival mitomycin C injection were compared with needling and subconjunctival 5-Fluorouracil injection for early dysfunctional filtration blebs after trabeculectomies.

Neovascular glaucoma is one of the most recalcitrant glaucoma types to treatment and has one of the worst outcomes compared to other types of glaucoma. Neovascular glaucoma often needs surgical treatment because medical treatment fails to adequately control intraocular pressure. In a retrospective study, H. Yan investigated the long term surgical outcomes, treating neovascular glaucoma complicated by vitreous haemorrhage with 23-gauge vitrectomy combined with phacoemulsification, panretinal laser photocoagulation, and trabeculectomy without using anti-VEGF agents.

C. Cagini et al. explored the role of canaloplasty in the surgical management of glaucoma with an extensive review. Canaloplasty is a nonpenetrating blebless surgical technique for open-angle glaucoma, similar to viscocanalostomy, in

which a flexible microcatheter is inserted within Schlemm's canal for the entire 360 degrees. The results of this ab externo technique are really encouraging. S. A. Gandolfi et al. compared canaloplasty with an ab interno minimally invasive glaucoma surgery, the Hydrus™ implant. Both techniques are innovative and aim to restore the natural pathway, dilating a large size of Schlemm's canal. The results of this retrospective, comparative case series were collected after 2-year follow-up.

A. F. Resende et al. presented a review on the iStent. This trabecular bypass stent is another minimally invasive glaucoma surgery device that has quickly gained popularity in the last years. Randomized controlled trials are still needed to assess the role of these devices in glaucoma surgery.

Finally, S. Jacob et al. presented a new surgical technique, the stab incision glaucoma surgery. Even though it looks similar to standard trabeculectomy the main advantages are the sliding of the superior conjunctiva without dissecting, the creation of a superficial corneoscleral tunnel in a single step, the punch of the internal lip of the tunnel, and finally the suture of the conjunctival incision alone.

In summary, this issue includes different approaches presented by diverse authors covering several topics related to improving of standard filtering surgery and wound healing and to new surgical techniques. This publication will provide valuable information that should be helpful in clinical practice for the whole ophthalmology community, mainly for glaucoma surgeons.

Michele Figus
Shlomo Melamed
Antonio Ferreras
Giorgio Marchini
Vital P. Costa

Hindawi Publishing Corporation
Journal of Ophthalmology
Volume 2016, Article ID 2731856, 9 pages
http://dx.doi.org/10.1155/2016/2731856

Review Article

iStent® Trabecular Microbypass Stent: An Update

Arthur Fernandes Resende, Neal Sanjay Patel, Michael Waisbourd, and L. Jay Katz

Glaucoma Research Center, Wills Eye Hospital, Philadelphia, PA 19107, USA

Correspondence should be addressed to Michael Waisbourd; mwaisbourd@willseye.org

Received 12 October 2015; Accepted 15 May 2016

Academic Editor: Michele Figus

Due to the high rates of complications and failure experienced with current glaucoma procedures, there is a continuous search for a safer and more effective glaucoma surgery. A new class of procedures termed minimally invasive glaucoma surgeries (MIGS) aim to fill this void by offering an alternative method of IOP reduction associated with markedly reduced complication rates and shorter recovery times. The iStent, a trabecular microbypass stent, is a MIGS device that has quickly gained popularity. The device allows aqueous humor to directly drain from the anterior chamber into Schlemm's canal by bypassing an obstructed trabecular meshwork. This review examines publications about the iStent, focusing on the device's efficacy, safety, and cost when a single iStent or multiple iStents are implanted in combination with cataract surgery or as a solo procedure. Current data suggest that the iStent is a safe and effective tool in the management of mild-to-moderate glaucoma, notable for its limited complications and absence of serious adverse events following implantation. As valuable experience is gained performing *ab interno* MIGS, increasing familiarity with angle anatomy and iStent placement, and as newer stent designs are developed, there is promise of continual improvement in the surgical management of glaucoma.

1. Introduction

Glaucoma is the leading cause of irreversible blindness worldwide, affecting over 65 million people [1]. The primary goal in the treatment of glaucoma is the management of intraocular pressure (IOP), which is traditionally first attempted through use of topical medications or laser therapy [2]. However, when these methods fail, surgery is often required to prevent vision loss. Due to the high rates of complications and failure experienced with current glaucoma procedures (e.g., trabeculectomy and tube shunt implantation) [3], there is a continuous search for a safer and more effective glaucoma surgery. Through the use of novel nonpenetrating and bleb-independent approaches, a new class of procedures termed minimally invasive glaucoma surgeries (MIGS) aim to fill this void by offering an alternative method of IOP reduction associated with markedly reduced complication rates and shorter recovery times compared with traditional glaucoma surgery [4–6].

The iStent (Glaukos, Laguna Hills, CA), a trabecular microbypass stent, is a MIGS device that has quickly gained popularity since first being published by Spiegel et al. in 2007 [7]. Being the smallest US Food and Drug Administration approved device ever implanted in the human body, the iStent is a 1 mm heparin-coated, nonferromagnetic, surgical grade titanium stent with a ridged, snorkel design pictured in Figure 1(a). The device allows aqueous humor to directly drain from the anterior chamber into Schlemm's canal by bypassing an obstructed trabecular meshwork. Requiring only a short surgical procedure for implantation, the iStent benefits from a relatively fast learning curve; it is inserted *ab interno* through a clear corneal incision guided by direct gonioscopy (Figure 1(b)). Additionally, the iStent has the potential to be a fiscally favorable alternative to traditional treatments by reducing medication burden in the long term [8]. Herein, we review the literature on the iStent trabecular microbypass stent published between January 2007 and April 2016 in order to better understand its efficacy, safety, cost considerations, and future directions. A PubMed search for "iStent" revealed 44 articles. Each of these full-text articles was reviewed. Secondary searches for "trabecular bypass" and minimally invasive glaucoma surgery or "MIGS" identified

additional relevant articles. Randomized controlled trials (RCT) and relevant case series were included in this review and are listed in Tables 1 and 2. Review articles and cost studies were cited in this paper as well.

2. Outcomes of iStent Implantation with Cataract Surgery

Although cataract surgery is known to reduce IOP by itself (by approximately 2 mmHg) [9], combining this procedure with the implantation of an iStent through the same surgical incision can have a greater impact on reducing IOP and medication burden [10–12]. As such, the most popular and well-researched use of the iStent is when its implantation is performed simultaneously with cataract surgery. One of the earliest reports of this combined surgery in 2008 [13] demonstrated that 70% of subjects ($n = 33/47$) were able to discontinue all previous IOP lowering medications, with a mean IOP reduction of 5.7 ± 3.8 mmHg at 6 months (25.4% reduction, $P < 0.001$), a reduction greater than what has been evidenced in previous studies with cataract surgery as a solo procedure [10, 12–15].

A 2013 prospective, uncontrolled, interventional case series by Patel et al. [14, 16] examined the efficacy and outcomes of the combined iStent implantation and cataract surgery in 40 eyes with open-angle glaucoma (OAG). The study concluded that the procedure resulted in a significant reduction in IOP at 6 months postoperatively, with a mean reduction of 4.4 mmHg from a mean baseline IOP of 21.1 mmHg (20.9% reduction, $P < 0.0001$). Dependence on topical IOP lowering medication was also reduced significantly, with a mean number of medications reduced from 2.3 to 0.6 ($P < 0.01$). By a 6-month follow-up, 66% percent of patients were medication-free, with further 20% only requiring 1 ocular hypotensive medication; additionally all patients on oral acetazolamide prior to surgery ($n = 6$) were able to discontinue its use.

An identical case series conducted by Arriola-Villalobos et al. [16] in 2012 examined a smaller population ($n = 19$) but offered the longest follow-up for this combined procedure currently published in literature. At a mean follow-up of 53 months, a significant reduction in mean IOP of 3.16 mmHg was still demonstrated from a baseline of 19.4 mmHg (16.3% reduction, $P = 0.002$). While all subjects were using at least 1 IOP lowering medication at baseline, by the end of follow-up 8 subjects (42.1%) still did not require any hypotensive medication. Although limited by being an uncontrolled study with a small sample size, these results suggest that the efficacy of iStent implantation may persist in the long term.

The most recent published data on the long-term efficacy of combined cataract and iStent implantation demonstrated outcomes very similar to previous studies. In one study with a 3-year follow-up, iStent placement achieved an IOP reduction from 24.1±6.9 mmHg at the baseline to 14.9±2.3 mmHg, with use of glaucoma medications eliminated in 74% of patients [17]. Fea et al. also published long-term results, including a comparison between cataract extraction as a solo procedure and cataract extraction combined with implantation of one stent. Although not statistically significant, the microbypass stent combined with phacoemulsification group demonstrated a consistently reduced IOP throughout the entire study period, starting from 17.8 ± 2.7 mmHg at baseline to 16.1 ± 2.0 mmHg at 12 months and finally to 15.9 ± 2.3 mmHg at 48 months. At long-term follow-up after washout, IOP in the group receiving phacoemulsification alone was significantly greater than that at baseline (20.4 ± 3.2 versus 16.7 ± 3.0 mmHg, $P = 0.002$) and a 14.2% difference in IOP compared to the combined group was reported, which was statistically significant (17.5 ± 2.3 mmHg in the combined group versus 20.4 ± 3.2 mmHg in the control group, $P = 0.02$) [18].

The largest prospective, randomized, controlled trial to be performed on this topic as of yet is a multicenter study conducted by the US iStent Study Group [15]. The study enrolled a total of 240 eyes with cataract and OAG which were randomized into 2 groups to receive either phacoemulsification alone ($n = 123$) or phacoemulsification combined with a single iStent ($n = 117$). In 2011 Samuelson et al. [15] published results from a 12-month follow-up, with the primary efficacy measure defined as an unmedicated IOP ≤21. The iStent group performed significantly better than the group receiving phacoemulsification alone, with 72% reaching the desired outcome of an IOP of <22 mmHg without glaucoma medications in the iStent group compared to 50% in the control group ($P < 0.001$). A secondary efficacy measure specified as an IOP reduction ≥20% without medication resulted in a similarly significant outcome, demonstrating 18% treatment difference between subjects receiving an iStent group and those receiving phacoemulsification alone (66% versus 48%, $P = 0.003$). While the mean reduction in IOP was similar in both groups at 12 months (as expected due to the study protocol calling for active management of IOP with medication), the iStent group subjects were able to achieve their IOP reduction with significantly fewer medications. The time to first medication was significantly longer in the iStent group, with control subjects taking more ocular hypotensive medications at 1 week compared to iStent group subjects at 1 year. At 12 months the mean decrease in medications from baseline was larger in the iStent group (1.4 versus 1.0, $P = 0.005$) and fewer subjects in the iStent group required IOP lowering medication compared to those in the control group (15% versus 35%, $P = 0.001$). In 2012, Craven et al. [19] reported the data from a 24-month follow-up in the same study subjects. Although a difference in IOP lowering medication use between the 2 groups was no longer statistically significant (the study protocol was not sufficiently powered for a 2-year efficacy evaluation), a difference favoring the iStent group was still observed when considering the same primary efficacy outcome of an unmedicated IOP ≤21 ($P = 0.036$).

A meta-analysis comparing iStent implantation with phacoemulsification versus phacoemulsification alone has been recently published by Malvankar-Mehta et al. [11] in 2015. This meta-analysis reported that while both strategies caused reduction of IOP and the number of medications used in the long term, the combined iStent implantation had significantly better results. Phacoemulsification alone

Table 1: Summary of iStent randomized controlled trials.

Authors (year)	TG (n)	CG (n)	Device	Procedure	TG mean IOP reduction (%)	CG mean IOP reduction (%)	TG med. reduction (%)*	CG med. reduction (%)*	Follow-up (months)
Samuelson et al. [15] (2011)	117	123	iStent	Phaco. versus Phaco. + 1 iStent	8.2	5.4	86.7	73.3	12
Craven et al. [19] (2012)	117	123	iStent	Phaco. versus Phaco. + 1 iStent	8.1	4.3	80.0	66.7	24
Fernández-Barrientos et al. [26] (2010)	17	16	iStent	Phaco. versus Phaco. + 2 iStents	27.3	16.5	100	41.7	12
Fea [10] (2010)	12	24	iStent	Phaco. versus Phaco. + 1 iStent	17.3	9.2	80.0	31.6	15
Fea et al. [27] (2014)	94	98	iStent inject	2 iStents versus med.	38.4	36.2	N/A	N/A	12

CG, control group; IOP, intraocular pressure; med, medication; Phaco., phacoemulsification; TG, treatment group.
*The numerical value listed under "med. reduction" represents the decrease in mean number of IOP lowering medications used postoperatively.

Table 2: Summary of iStent case series.

Authors (year)	*n*	Procedure	Device	Mean IOP reduction (%)	Medication reduction (%)*	Follow-up (months)
Spiegel et al. [7][1] (2007)	6	1 iStent	iStent	23.9	18.5	12
Buchacra et al. [20][1] (2011)	10	1 iStent	iStent	27.3	62.0	12
Ahmed et al. [21][1] (2014)	39	2 iStents + travoprost	iStent	46.9	50	18
Voskanyan et al. [31][1] (2014)	99	2 iStents	iStent inject	39.7	N/A	12
Arriola-Villalobos et al. [30][1] (2013)	20	Phaco. + 1 iStent or 2 iStents	iStent inject	35.7	76.9	12
Spiegel et al. [13][1] (2008)	47	Phaco. + 1 iStent	iStent	25.4	66.7	6
Spiegel et al. [12][1] (2009)	47	Phaco. + 1 iStent	iStent	21.4	75.0	12
Arriola-Villalobos et al. [16][1] (2012)	19	Phaco. + 1 iStent	iStent	16.3	63.6	60
Patel et al. [14][1] (2013)	44	Phaco. + 1 iStent	iStent	20.9	74.3	6
Belovay et al. [22][1] (2012)	53	Phaco. + iStents (2 or 3)	iStent	20.2–20.4	64.3–84.6	12
Klamann et al. [32][2] (2015)	35	1 iStent in phakic OAG	iStent inject	33–35	N/A[3]	6
El Wardani et al. [34][2] (2015)	131	Phaco. alone and 1 iStent or 2 iStents	iStent	N/A[4]	27[5]	6

IOP, intraocular pressure; *n*, number of eyes enrolled; Phaco., phacoemulsification; OAG, open-angle glaucoma.
*The numerical value listed under "medication reduction" represents the decrease in mean number of IOP lowering medications used postoperatively.
[1]Prospective studies.
[2]Retrospective studies.
[3]No statically significant difference was found at the end of follow-up.
[4]Percentage of reduction was not available in abstract (epub ahead of printing).
[5]Number of medications was reduced by 8% in the phacoemulsification alone group, 27% when using one iStent, and 45% when using 2 iStents.

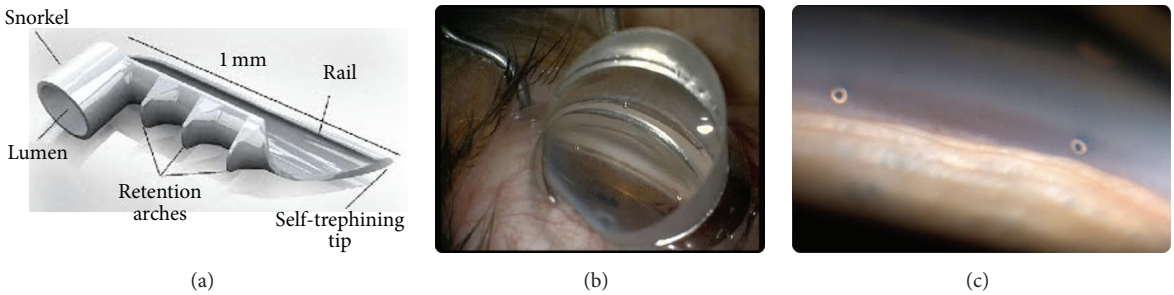

Figure 1: Illustration of the iStent with dimensions and technical specifications (a); intrasurgical view of the trabecular meshwork with a direct gonioscopy lens (b); flipped view of 2 inserted iStents under gonioscopy (c). ((a) and (b), courtesy of Glaukos Corporation; (c), courtesy of Matt Poe, http://www.ophthalmicphotography.info/).

resulted in a 4% mean decrease in IOP from baseline; however, addition of an iStent increased this to a 9% reduction; concurrent implantation of 2 iStents additionally improved this to a 27% reduction in IOP. Moreover, combination surgery resulted in a weighted mean reduction in the number of glaucoma medications by 1.33 per patient, compared to 1.01 with phacoemulsification alone. Success of the combined surgery continued into the long term, with the meta-analysis finding a significant reduction of glaucoma medications by 12 months postoperatively, which remained significant until 4 years of follow-up. Despite significant heterogeneity between studies examined in the meta-analysis, the results concluded that the combined iStent with phacoemulsification surgery significantly outperforms phacoemulsification alone in terms of both IOP reduction and medication burden.

3. iStent as a Solo Procedure

While currently not performed commonly, the implantation of an iStent as a solo procedure has been advocated for by some authors. The earliest studies on this topic were prospective, interventional case series on patients with OAG published by Spiegel et al. in 2007 [7]. The study demonstrated a mean IOP reduction of 23.9% among the 6 patients examined in the study, from a baseline of 20.2 ± 6.3 mmHg to 15.3 ± 3.7 mmHg. Buchacra et al. [20] published results from a similar case series in 2011 which examined 10 patients with secondary OAG (including traumatic, steroid induced, pseudoexfoliative, and pigmentary glaucoma) who underwent single iStent implantation without cataract surgery. Of the 10 patients enrolled in this study, 7 had phakic lenses. The surgery was found to be effective, with 8 patients averaging a 27.3% reduction in IOP after 12 months. Additionally, the solo procedure proved to be very safe, with no complications reported among phakic eyes.

A prospective, nonrandomized study conducted by Ahmed et al. [21] examined the efficacy of 2 iStents implanted simultaneously in a solo procedure (Figure 1(c)). The study enrolled 39 phakic subjects with OAG which were on 2 IOP lowering medications preoperatively. Following a washout of all medications, subjects received iStent implantation surgery and were concurrently started on travoprost topical medication. From a mean baseline prewashout IOP of 22.2 ± 2.0 mmHg, IOP was reduced to 14.0 ± 2.2 mmHg by 1 month and 13.0 ± 2.4 by 12 months, with reduction of 1 medication. At the 12-month follow-up, all 39 subjects had achieved an IOP ≤18 mmHg and a reduction ≥20% from baseline solely on travoprost. Moreover, 29 patients (74.4%) achieved an IOP reduction ≥40% from baseline. Following a washout leading up to a 13-month follow-up, it was observed that the mean unmedicated IOP decreased from 25.3 ± 1.8 mmHg preoperatively to 17.1 ± 2.2 mmHg, with an IOP reduction of 8.2 mmHg or 32.4%. The results suggest that iStent implantation could serve as a substitute for patients using multiple ocular hypotensive medications. Results from a 5-year follow-up on the same subjects are pending and may help elucidate long-term effects of solo iStent implantation.

One control trial has been conducted examining the potential for increased efficacy with the addition of a third iStent in a solo procedure. Conducted by Belovay et al. in 2012 [22], the study compared the use of 1, 2, or 3 iStents, with 30 patients enrolled in each of the 3 groups. It showed that the group that simultaneously received 3 iStents presented with a mean IOP of 12.9 ± 1.6 mmHg at 6 months postoperatively, compared to a baseline of 24.3 ± 3.7 mmHg, with a reduction of 41%. While this outperformed the single iStent group, which experienced a mean IOP reduction of 31%, it performed similarly to the 2 iStents group which had an identical IOP reduction of 41%.

A prospective pilot study evaluated the solo implantation of 2 iStents in 39 patients using one topical IOP lowering medication prior to washout. The primary end point was IOP reduction ≥20% without medication compared to baseline unmedicated IOP at 12-month follow-up and a secondary end point of IOP ≤18 mmHg without medication at 12-month follow-up. The primary and secondary efficacy end points were each achieved by 92.3% of subjects ($n = 36$; 95% CI: 79.1%, 98.4%). Additionally, mean reduction in IOP from baseline was 44%. Most subjects maintained these target IOP thresholds through month 36, with an IOP reduction ≥20% achieved by 86.2% ($n = 25$; 95% CI: 68.3%, 96.1%) and IOP ≤18 mmHg achieved by 89.7% of patients ($n = 26$; 95% CI: 72.6%, 97.8%) [23].

Katz et al. also evaluated the efficacy and safety of the implantation of 1 or multiple iStents as a solo procedure. Subjects were submitted to washout and divided into groups

to receive either 1 (n = 38), 2 (n = 41), or 3 (n = 40) stents. The same primary efficacy end point of an IOP reduction ≥20% without medication at 12 months compared to baseline unmedicated IOP and secondary end point of IOP ≤18 mmHg without medication at 12 months were used in this study. Additional measures included a proportional analysis of subjects with IOP ≤15 mmHg at 12 months. For all analyses of efficacy, patients could not be using topical ocular medication at 12 months and must not have undergone any additional surgical procedures for glaucoma by month 12.

Both the primary and secondary efficacy end points were achieved by 89.2% of one-stent, 90.2% of two-stent, and 92.1% of three-stent subjects. At 12-month follow-up, an IOP ≤15 mmHg without medication was achieved by 64.9% (n = 24, 95% CI: 47.5%–79.8%) of one-stent subjects, 85.4% (n = 35, 95% CI: 70.8%–94.4%) of two-stent subjects, and 92.1% (n = 35, 95% CI: 78.6%–98.3%) of three-stent subjects. Following a 1-month medication washout period at month 12 for eyes on medication, mean unmedicated IOP at months 12–13 were 14.9 ± 1.9 mmHg, 13.6 ± 2.1 mmHg, and 12.7 ± 2.1 mmHg in the three respective groups. IOP reduction was sustained in each of the groups throughout the 18-month postoperative period, with a greater reduction observed in the multiple-stent groups versus the one-stent group. At 18 months, mean IOP was 15.6 ± 1.5 mmHg in the one-stent group, 13.8 ± 1.3 mmHg in the two-stent group, and 12.1 ± 1.2 mmHg in the three-stent group [24].

A recent 2015 meta-analysis assessing solo iStent implantation, conducted by Malvankar-Mehta et al. [25], examined 5 studies with a total of 248 subjects for quantitative synthesis. Despite significant heterogeneity between studies, the meta-analysis concluded that a 22% weighted mean IOP reduction from baseline was observed at 18 months after 1 iStent was implanted, 30% weighted mean IOP reduction from baseline was observed at 6 months after 2 iStents were implanted, and 41% weighted mean IOP reduction from baseline was observed at 6 months after 3 iStents were implanted, with a statistically significant reduction found in all 3 groups. Additionally, a significant reduction in ocular hypotensive medication use was seen after implantation in all 3 groups, with a mean reduction of 1.2 bottles per patient at 18 months after 1 iStent was implanted, 1.45 bottles per patient at 6 months after 2 iStents were implanted, and 1 bottle per patient at 6 months after 3 iStents were implanted. Although data was limited by the fact that only a single study had examined the impact of 3 iStents, results suggested that the IOP decrease correlates positively with the number of iStents injected. Overall, the meta-analysis concluded that iStent implantation as a solo procedure is effective in lowering IOP and reducing dependency on topical glaucoma medications.

4. Complications of iStents

A key aspect of the iStent, as a MIGS device, is its favorable safety profile. Clinical trials and case series have consistently reported few to no adverse events following its implantation [10, 15, 19, 26]. Moreover, when complications occur they are often due to issues with the simultaneously performed cataract surgery rather than the result of issues with the iStent itself.

The randomized control trial for the iStent Study Group, reported on by Samuelson et al. [15] and Craven et al. [19], found that, among the 240 eyes enrolled, implantation of the iStent along with cataract surgery did not result in substantial additional risk or adverse events. The increased efficacy demonstrated in the iStent group during the 24-month study was achieved with no compromise in visual outcomes and with a safety profile comparable to cataract surgery alone. The most common early postoperative complications found in the iStent group were related to iStent malpositioning and obstruction (by iris, blood, etc.). Incidence of these events in the iStent Study Group was 3% and 4%, respectively. A variety of options for managing these complications have proven to be safe and clinically viable, ranging from observation while waiting for spontaneous resolution to more aggressive options such as laser therapy, stent repositioning, or stent replacement. In the iStent Study Group, 5 subjects who received an iStent (4.5%) required secondary surgery to fix iStent related complications (3 stent repositionings, 1 stent replacement, and 1 laser iridoplasty). Importantly, there was no evidence of any severe adverse events following iStent implantation.

While reports of most complications are consistent across all studies, other studies have found a wide range in frequency of complications related to iStent malpositioning. Compared to the iStent Study Group results of a 3% incidence among subjects, a 2010 study by Fernández-Barrientos et al. [26] found that 6 of 34 (17.6%) iStents were malpositioned upon follow-up, and results from Fea in 2010 [10] showed that 2 of 12 (16.7%) were malpositioned. It is notable, however, that none of these cases led to any significant adverse events, nor did any require resurgery. It is likely that this variation among reported results is largely due to a lack of specific standardized criteria defining malpositioning, along with the absence of a universal protocol for determining if surgical intervention is necessary. Among studies examined in this review, surgical intervention (e.g., iStent repositioning or removal) or laser procedures were necessitated in 4.5% to 11.3% of study subjects that experienced complication related to iStent malpositioning and obstruction.

Hyphema is another complication seen in the early postoperative stage and is usually a consequence of blood reflux from the iStent. It is in fact a sign that indicates patency of the iStent and typically resolves spontaneously within 1 week postoperatively. Studies where hyphema was reported largely did not specify if it was a notable complication or normal reflux as a result of the procedure. Given this, the reported frequency of this complication varies greatly among studies from 2.3% to 70% [14, 20].

One rare complication occurs when an ophthalmologist cannot locate an implanted iStent under gonioscopy post-operatively, with one such example of this seen in a study by Fea et al. [27] published in 2014. Ichhpujani et al. [28] conducted a laboratory study in 2010 testing the efficacy of 3 different imaging technologies in their ability to locate a deliberately misplaced iStent. The results demonstrated that ultrasound biomicroscopy was able to locate the "missing"

(a) (b) (c)

Figure 2: Illustration of the second-generation iStent *inject* (a); size comparison of the iStent *inject* (b); schematic illustration of iStent *inject* placement in trabecular meshwork (c). ((a)–(c), courtesy of Glaukos Corporation).

iStents with the best reliability, compared to optical coherence tomography and B-scan ultrasonography.

5. iStent *inject*

The newer, second generation of the iStent is a smaller version of the original model (Figures 2(a) and 2(b)), called the GTS-400 iStent *inject* (Glaukos, Laguna Hills, CA). Developed to reduce IOP in the same safe and effective way, the iStent *inject* is proposed to have an easier learning curve largely due to the device's completely different structure compared to the first generation, notably evidenced by the absence of the snorkel (Figures 2(a) and 2(c)). The new device also includes a modified injector that can be simultaneously loaded with 2 stents, an important improvement that allows surgeons to place both stents with a single entry into the eye. Bahler et al. [29] conducted a laboratory study with the new device utilizing human donor eyes, with a method similar to what has already been performed with first-generation iStent. The results demonstrated that addition of a second iStent significantly increased the outflow.

One of the first reports on the iStent inject was published in 2013 by Arriola-Villalobos et al. [30], in which 20 patients underwent combined phacoemulsification and implantation of 2 iStent *inject* stents as part of a prospective, uncontrolled, interventional case series study. At a 12-month follow-up, the mean washout baseline IOP of 26 ± 3.1 mmHg was decreased by 35.7% to 16.7 ± 2.2 mmHg (9.4 ± 3 mmHg reduction, $P < 0.001$). Mean number of glaucoma medications also fell from 1.3 ± 0.6 to 0.3 ± 0.5 ($P < 0.001$), with 75% patients still completely off medication at 1 year. The study observed no adverse events and concluded that combined cataract surgery with implantation of 2 iStent *inject* stents seems to be a safe and effective procedure.

In 2014, Voskanyan et al. [31] presented results from a prospective, multicenter, open-label study on the implantation of 2 iStent *inject* stents as a solo procedure in 99 phakic and pseudophakic subjects with OAG. At a 12-month follow-up, mean baseline washout IOP values decreased by 10.2 mmHg (39.7% reduction) from 26.3 ± 3.5 to 15.7 ± 3.7 mmHg. Additionally, 66% of subjects had an IOP ≤18 mmHg without medication, and 81% achieved an IOP ≤18 mmHg with either 1 or no medications. Medication burden also improved in 86.9% of subjects, with 15.2% experiencing a reduction of 1 medication and 71.7% discontinuing use of 2 or more medications postoperatively.

Fea et al. [27] conducted a prospective, multicenter, randomized clinical trial in 6 countries, enrolling OAG patients with uncontrolled IOP on 1 medication who either underwent implantation of 2 iStent *inject* stents or received medical therapy consisting of a fixed combination. Ninety-four patients were enrolled in this study for the iStent group, the majority of whom were phakic (98%) and Caucasian (100%). After 12 months of follow up, 94.7% of the eyes in the iStent group reported an IOP reduction ≥20% without use of any medications. The mean baseline IOP after washout was 25.2 ± 1.4 mmHg, and after 12 months the mean IOP decreased to 13.0 ± 2.3 mmHg. A favorable safety profile was achieved in the iStent group as measured by a stable best corrected visual acuity and cup-to-disk ratio among subjects throughout the study, as well as few adverse events.

Complication rates with the iStent *inject* have been found to be comparable to those from the previous model. It is notable that Klamann et al. [32] showed that blood reflux occurred in 91% of the surgeries involving the iStent *inject*; however, there was no incidence of complicated hemorrhage.

6. Cost Considerations

There is a lack of studies considering the cost effectiveness of the iStent; there exists only 1 published study to date on this topic [8]. The study, based in Canada, demonstrated that implantation of 2 iStents could possibly reduce the costs of the glaucoma treatment in comparison to the use of topical medications. Over a 6-year period, potential savings were estimated to be CA$1272 when comparing the iStent to a drug regimen using 2 medications and CA$2124 when compared to 3 medications. The study was limited by solely considering the placement of 2 simultaneous iStents, a relatively uncommon practice that is not approved in some countries (e.g., United States). Further limitations arose from difficulty predicting the effective duration at which iStents can continue to control IOP due to the lack of randomized controlled trials with long-term follow-up times. It is also important to be aware of variation in cost of medications, surgery fees, and many other variables like the cost of the device itself. The financial viability of the iStent device will play a crucial role for patients and doctors when deciding to implement this technology, making it critical for more studies to be conducted on this topic.

7. Conclusion

The considerable focus and interest of the medical community with MIGS in the last decade demonstrates that ophthalmologists are anxious for advancements in the surgical treatment of glaucoma. It is clear that single trabecular microbypass stents do not have an IOP reducing power comparable to more invasive surgeries such as trabeculectomy or tube shunt surgery. However, it is important to understand that the iStent is not intended to totally replace these procedures. MIGS, such as the iStent, instead have the potential to be a valuable option for glaucoma surgeons due to their precise indications, consistent efficacy, and ability to increase patient prognosis and quality of life. Additional high quality randomized controlled trials are still needed to confirm the advantages of MIGS over cataract surgery alone [33].

The favorable safety profile consistently demonstrated across studies is one of the key features of the iStent, as the potential for serious adverse events can be a significant deterrent for patients and physicians when considering surgical interventions during the initial and moderate stages of glaucoma. New devices are continually being developed and improved, and current MIGS devices are likely only the beginning of a new era in glaucoma management. As valuable experience is gained performing ab interno MIGS, increasing familiarity with angle anatomy and iStent placement, and as newer stent designs are developed, there is promise of continual improvement in the surgical management of glaucoma.

Competing Interests

Dr. L. Jay Katz receives research support from Allergan, Aerie Pharm, Bausch & Lomb, Mati Therapeutics, Innfocus Inc., and Diopsys Inc. Dr. Katz is a consultant and/or on the advisory board of Allergan, Alcon, Glaukos, Aerie Pharm, Bausch & Lomb, Sucampo, Inotek, Sensimed AG, Alimera Sciences, ForSight Vision, Mati Therapeutics, and Ocular Therapeutix. Dr. Katz is also speaker for Allergan, Alcon, Merck, and Lumenis. Dr. Katz is a stock shareholder for Glaukos, Mati Therapeutics, and Aerie Pharm and is a medical monitor for Glaukos. All others coauthors have no commercial relationship to declare.

Acknowledgments

This study was funded by the Glaucoma Service Foundation to Prevent Blindness, Philadelphia, PA.

References

[1] Y.-C. Tham, X. Li, T. Y. Wong, H. A. Quigley, T. Aung, and C.-Y. Cheng, "Global prevalence of glaucoma and projections of glaucoma burden through 2040: a systematic review and meta-analysis," *Ophthalmology*, vol. 121, no. 11, pp. 2081–2090, 2014.

[2] D. C. Musch, B. W. Gillespie, L. M. Niziol, L. F. Cashwell, and P. R. Lichter, "Collaborative Initial Glaucoma Treatment Study G. Factors associated with intraocular pressure before and during 9 years of treatment in the Collaborative Initial Glaucoma Treatment Study," *Ophthalmology*, vol. 115, no. 6, pp. 927–933, 2008.

[3] S. J. Gedde, L. W. Herndon, J. D. Brandt, D. L. Budenz, W. J. Feuer, and J. C. Schiffman, "Surgical complications in the Tube Versus Trabeculectomy study during the first year of follow-up," *American Journal of Ophthalmology*, vol. 143, no. 1, pp. 23–31.e2, 2007.

[4] H. Saheb and I. I. K. Ahmed, "Micro-invasive glaucoma surgery: current perspectives and future directions," *Current Opinion in Ophthalmology*, vol. 23, no. 2, pp. 96–104, 2012.

[5] L. M. Brandão and M. C. Grieshaber, "Update on minimally invasive glaucoma surgery (MIGS) and new implants," *Journal of Ophthalmology*, vol. 2013, Article ID 705915, 12 pages, 2013.

[6] G. M. Richter and A. L. Coleman, "Minimally invasive glaucoma surgery: current status and future prospects," *Journal of Clinical Ophthalmology*, vol. 10, pp. 189–206, 2016.

[7] D. Spiegel, W. Wetzel, D. S. Haffner, and R. A. Hill, "Initial clinical experience with the trabecular micro-bypass stent in patients with glaucoma," *Advances in Therapy*, vol. 24, no. 1, pp. 161–170, 2007.

[8] Y. Iordanous, J. S. Kent, C. M. L. Hutnik, and M. S. Malvankar-Mehta, "Projected cost comparison of trabectome, istent, and endoscopic cyclophotocoagulation versus glaucoma medication in the ontario health insurance plan," *Journal of Glaucoma*, vol. 23, no. 2, pp. e112–e118, 2014.

[9] S. L. Mansberger, M. O. Gordon, H. Jampel et al., "Reduction in intraocular pressure after cataract extraction: the ocular hypertension treatment study," *Ophthalmology*, vol. 119, no. 9, pp. 1826–1831, 2012.

[10] A. M. Fea, "Phacoemulsification versus phacoemulsification with micro-bypass stent implantation in primary open-angle glaucoma: randomized double-masked clinical trial," *Journal of Cataract and Refractive Surgery*, vol. 36, no. 3, pp. 407–412, 2010.

[11] M. S. Malvankar-Mehta, Y. Iordanous, Y. N. Chen et al., "iStent with phacoemulsification versus phacoemulsification alone for patients with glaucoma and cataract: a meta-analysis," *PLoS ONE*, vol. 10, no. 7, Article ID e0131770, 2015.

[12] D. Spiegel, W. Wetzel, T. Neuhann et al., "Coexistent primary open-angle glaucoma and cataract: interim analysis of a trabecular micro-bypass stent and concurrent cataract surgery," *European Journal of Ophthalmology*, vol. 19, no. 3, pp. 393–399, 2009.

[13] D. Spiegel, J. García-Feijoó, J. García-Sánchez, and H. Lamielle, "Coexistent primary open-angle glaucoma and cataract: preliminary analysis of treatment by cataract surgery and the iStent trabecular micro-bypass stent," *Advances in Therapy*, vol. 25, no. 5, pp. 453–464, 2008.

[14] I. Patel, T. A. de Klerk, and L. Au, "Manchester iStent study: early results from a prospective UK case series," *Clinical and Experimental Ophthalmology*, vol. 41, no. 7, pp. 648–652, 2013.

[15] T. W. Samuelson, L. J. Katz, J. M. Wells, Y.-J. Duh, and J. E. Giamporcaro, "Randomized evaluation of the trabecular micro-bypass stent with phacoemulsification in patients with glaucoma and cataract," *Ophthalmology*, vol. 118, no. 3, pp. 459–467, 2011.

[16] P. Arriola-Villalobos, J. M. Martínez-de-la-Casa, D. Díaz-Valle, C. Fernández-Pérez, J. García-Sánchez, and J. García-Feijoó, "Combined iStent trabecular micro-bypass stent implantation and phacoemulsification for coexistent open-angle glaucoma and cataract: a long-term study," *British Journal of Ophthalmology*, vol. 96, no. 5, pp. 645–649, 2012.

[17] T. H. Neuhann, "Trabecular micro-bypass stent implantation during small-incision cataract surgery for open-angle glaucoma or ocular hypertension: long-term results," *Journal of Cataract & Refractive Surgery*, vol. 41, no. 12, pp. 2664–2671, 2015.

[18] A. M. Fea, G. Consolandi, M. Zola et al., "Micro-bypass implantation for primary open-angle glaucoma combined with phacoemulsification: 4-year follow-up," *Journal of Ophthalmology*, vol. 2015, Article ID 795357, 4 pages, 2015.

[19] E. R. Craven, L. J. Katz, J. M. Wells, and J. E. Giamporcaro, "Cataract surgery with trabecular micro-bypass stent implantation in patients with mild-to-moderate open-angle glaucoma and cataract: two-year follow-up," *Journal of Cataract and Refractive Surgery*, vol. 38, no. 8, pp. 1339–1345, 2012.

[20] O. Buchacra, S. Duch, E. Milla, and O. Stirbu, "One-year analysis of the istent trabecular microbypass in secondary glaucoma," *Clinical Ophthalmology*, vol. 5, no. 1, pp. 321–326, 2011.

[21] I. I. K. Ahmed, L. J. Katz, D. F. Chang et al., "Prospective evaluation of microinvasive glaucoma surgery with trabecular microbypass stents and prostaglandin in open-angle glaucoma," *Journal of Cataract and Refractive Surgery*, vol. 40, no. 8, pp. 1295–1300, 2014.

[22] G. W. Belovay, A. Naqi, B. J. Chan, M. Rateb, and I. I. K. Ahmed, "Using multiple trabecular micro-bypass stents in cataract patients to treat open-angle glaucoma," *Journal of Cataract and Refractive Surgery*, vol. 38, no. 11, pp. 1911–1917, 2012.

[23] E. D. Donnenfeld, K. D. Solomon, L. Voskanyan et al., "A prospective 3-year follow-up trial of implantation of two trabecular microbypass stents in open-angle glaucoma," *Clinical Ophthalmology*, vol. 9, pp. 2057–2065, 2015.

[24] L. J. Katz, C. Erb, G. A. Carceller et al., "Prospective, randomized study of one, two, or three trabecular bypass stents in open-angle glaucoma subjects on topical hypotensive medication," *Clinical Ophthalmology*, vol. 9, pp. 2313–2320, 2015.

[25] M. S. Malvankar-Mehta, Y. N. Chen, Y. Iordanous, W. W. Wang, J. Costella, and C. M. Hutnik, "iStent as a solo procedure for glaucoma patients: a systematic review and meta-analysis," *PLoS ONE*, vol. 10, no. 5, Article ID e0128146, 2015.

[26] Y. Fernández-Barrientos, J. García-Feijoo, J. M. Martínez-de-la-Casa, L. E. Pablo, C. Fernandez-Perez, and J. G. Sanchez, "Fluorophotometric study of the effect of the glaukos trabecular microbypass stent on aqueous humor dynamics," *Investigative Ophthalmology and Visual Science*, vol. 51, no. 7, pp. 3327–3332, 2010.

[27] A. M. Fea, J. I. Belda, M. Rekas et al., "Prospective unmasked randomized evaluation of the iStent inject® versus two ocular hypotensive agents in patients with primary open-angle glaucoma," *Clinical Ophthalmology*, vol. 8, pp. 875–882, 2014.

[28] P. Ichhpujani, L. J. Katz, R. Gille, and E. Affel, "Imaging modalities for localization of an iStent®," *Ophthalmic Surgery Lasers and Imaging*, vol. 41, no. 6, pp. 660–663, 2010.

[29] C. K. Bahler, C. R. Hann, T. Fjield, D. Haffner, H. Heitzmann, and M. P. Fautsch, "Second-generation trabecular meshwork bypass stent (iStent inject) increases outflow facility in cultured human anterior segments," *American Journal of Ophthalmology*, vol. 153, no. 6, pp. 1206–1213, 2012.

[30] P. Arriola-Villalobos, J. M. Martínez-de-la-Casa, D. Díaz-Valle et al., "Mid-term evaluation of the new Glaukos iStent with phacoemulsification in coexistent open-angle glaucoma or ocular hypertension and cataract," *British Journal of Ophthalmology*, vol. 97, no. 10, pp. 1250–1255, 2013.

[31] L. Voskanyan, J. García-Feijoó, J. I. Belda, A. Fea, A. Jünemann, and C. Baudouin, "Prospective, unmasked evaluation of the iStent® Inject system for open-angle glaucoma: synergy trial," *Advances in Therapy*, vol. 31, no. 2, pp. 189–201, 2014.

[32] M. K. J. Klamann, J. Gonnermann, M. Pahlitzsch et al., "iStent inject in phakic open angle glaucoma," *Graefe's Archive for Clinical and Experimental Ophthalmology*, vol. 253, no. 6, pp. 941–947, 2015.

[33] M. L. Zhang, P. Hirunyachote, and H. Jampel, "Combined surgery versus cataract surgery alone for eyes with cataract and glaucoma," *The Cochrane Database of Systematic Reviews*, vol. 7, Article ID CD008671, 2015.

[34] M. El Wardani, C. Bergin, F. Achache, and E. Sharkawi, "Evaluating the trabecular micro-bypass stent combined with phacoemulsification compared to phacoemulsification alone," *Klinische Monatsblätter für Augenheilkunde*, vol. 232, no. 4, pp. 442–445, 2015.

Hindawi Publishing Corporation
Journal of Ophthalmology
Volume 2016, Article ID 7080475, 6 pages
http://dx.doi.org/10.1155/2016/7080475

Review Article

Canaloplasty: Current Value in the Management of Glaucoma

Carlo Cagini,[1] Claudia Peruzzi,[1] Tito Fiore,[1] Leopoldo Spadea,[2] Myrta Lippera,[3] and Stefano Lippera[3]

[1] *Department of Surgery and Biomedical Science, University of Perugia, Ospedale S. Maria della Misericordia, 06156 Perugia, Italy*
[2] *Department of Biotechnology and Medical-Surgical Sciences, "Sapienza" University of Rome, 04100 Latina, Italy*
[3] *Area Vasta 2 Marche, Ospedale di Fabriano, 60044 Fabriano, Italy*

Correspondence should be addressed to Carlo Cagini; carlo.cagini@unipg.it

Received 25 December 2015; Accepted 17 April 2016

Academic Editor: Vital P. Costa

Canaloplasty is a nonpenetrating blebless surgical technique for open-angle glaucoma, in which a flexible microcatheter is inserted within Schlemm's canal for the entire 360 degrees. When the microcatheter exits the opposite end, a 10-0 prolene suture is tied and it is then withdrawn, by pulling microcatheter back through the canal in the opposite direction. Ligation of prolene suture provides tension on the canal and facilitates aqueous outflow. The main advantage of canaloplasty is that this technique avoids the major complications of fistulating surgery related to blebs and hypotony. Currently, canaloplasty is performed in glaucoma patients with early to moderate disease and combination with cataract surgery is a suitable option in patients with clinically significant lens opacities.

1. Introduction

Glaucoma is linked to substantial social and economic costs due to its prevalence and deleterious impact on quality of life. Although more than 66 million people worldwide are estimated to be affected, up to 50% of glaucoma cases are undiagnosed [1]. Several studies demonstrated that, lowering intraocular pressure (IOP), the principal risk factor for glaucoma progression reduced the progression rate and efficiently preserved sight [2–4]. Standard glaucoma treatment is drug therapy followed by surgery when optimal disease control is not obtained. Trabeculectomy, the gold standard in glaucoma surgery, drains the aqueous humor from the anterior chamber to the subconjunctival space but is associated with a high rate of complications, that is, hypotony, hyphema, choroidal detachment, suprachoroidal hemorrhage, blebitis, and bleb-associated endophthalmitis [5, 6]. Consequently, innovative surgical techniques, such as viscocanalostomy and canaloplasty, were proposed to control IOP. Canaloplasty may be considered the evolution of viscocanalostomy which was described by Stegmann in 1985 [7]. As a nonperforating, blebless surgical technique, canaloplasty was first performed by Lewis et al. in 2007 [8]. It aims at restoring natural aqueous outflow by means of Schlemm's canal dilation which is achieved by tensioning with a 10.0 polypropylene suture. Canaloplasty has aroused substantial interest among surgeons over the last few years.

2. Patient Selection

Correct patient selection is the key to canaloplasty success. Canaloplasty is indicated for patients with mild-to-moderate primary open-angle glaucoma and a low-to-mid-IOP target [9]. Best indications are primary open-angle glaucoma, pseudoexfoliation glaucoma, and pigmentary glaucoma. Canaloplasty is also indicated for patients with advanced glaucoma who are not candidates for trabeculectomy. It may be recommended for patients with thin conjunctiva who could be at risk of bleb leaks and for individuals who cannot comply with the posttrabeculectomy care schedule [10]. After failed trabeculectomy, canaloplasty may be successful in patients with an undamaged Schlemm's canal. Counterindications to canaloplasty are conditions with a trabecular meshwork obstruction that prevents adequate cannulation of Schlemm's canal. These include chronic angle closure, narrow angles,

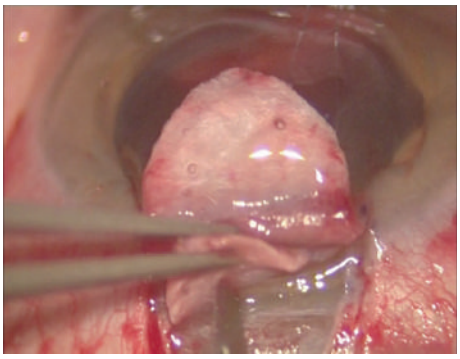

Figure 1

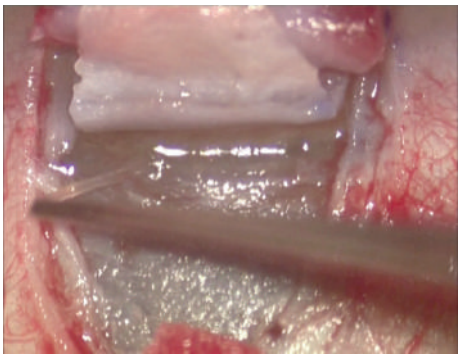

Figure 2

angle recession, neovascular glaucoma, ocular hypertension due to increased episcleral venous pressure and previous surgery that precludes Schlemm's canal cannulation such as trabeculectomy, trabeculotomy, goniotomy, and argon laser trabeculoplasty [11].

3. Surgical Procedure

Canaloplasty is an ab externo procedure. A 10-0 polypropylene suture is positioned within Schlemm's canal for 360° and then tensioned to dilate the canal and restore natural aqueous outflow. Canaloplasty is usually performed in the upper quadrants, with access through the upper-temporal or upper-nasal quadrants. Some surgeons do, however, perform surgery in the lower quadrant. Although a retrobulbar block is commonly used, subconjunctival and topical anaesthesia is sometimes preferred. The eye is infero-ducted by placing a clear corneal traction suture near the limbus, and surgery starts by dissecting the fornix-based conjunctival flap. Careful conjunctiva and Tenon's capsule dissection should be followed by wet-field cautery. Antimetabolites are not used. Then, a nonpenetrating double-flap dissection of the sclera exposes Schlemm's canal. First, a square-shaped, triangular, or parabolic superficial scleral flap is created. Approximately one-third to half-scleral thickness, it is 5 mm wide and 5 mm long. This flap must be dissected up to the clear cornea about 1.5/2.0 mm over the limbus. Second, a deep scleral flap is dissected. A little smaller than superficial flap (one-half to one millimeter), its dissection plane should be immediately superficial to choroid. The deep scleral flap is dissected until ciliary body/choroid becomes visible (Figure 1) and Schlemm's canal is opened and deroofed by removing its inner wall (Figure 2). A paracentesis is then performed to lower IOP and reduce the risk of perforating the trabecular-Descemet membrane. The deep scleral flap is removed. Schlemm's canal openings are carefully dissected. One opening is cannulated using a flexible microcatheter (iTrack, iScience Interventional, Menlo Park, CA, USA) (Figure 3) which is pushed forward through the entire circumference of Schlemm's canal until it exits the other end. The microcatheter is 200 microns in diameter and its tip is illuminated by a laser-diode microillumination system (iLumin by iScience Interventional, Menlo Park, CA, USA) which easily identifies the distal tip through the sclera as

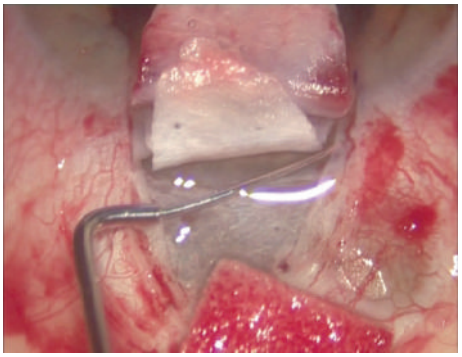

Figure 3

it advances in the canal. When the microcatheter exits the opposite end, it is tied to a 10-0 polypropylene suture and is then withdrawn, by pulling it back through the canal in the opposite direction (Figure 4). During withdrawal, a dedicated injector inserts a small amount of viscoelastic material into Schlemm's canal every two hours. When the microcatheter encounters a stop the surgeon should not force the viscoelastic material any further because Schlemm's canal rupture could cause collector channel blood to pool in the Descemet detachment, increasing the risk of intracorneal hematoma formation.

When the suture arrives at the original end, it is cut from the microcatheter and the two ends are carefully tightened to pull the trabecular meshwork inwards. Achieving correct suture tension is crucial for success. Adequate contraction is needed for homogeneous stretching of the entire circumference but excessive contraction could break the inner wall (Figure 5). Correct suture positioning and canal tension are checked intraoperatively by means of a high-resolution ultrasound system (iUltrasound, iScience Interventional, Menlo Park, CA, USA). After deep scleral flap excision, the superficial scleral flap is closed tightly with 10-0 vicryl (or nylon) sutures. Watertight closure is essential to prevent bleb formation. The conjunctival flap is then sutured with 10-0 vicryl sutures [9, 12].

One of the major difficulties in canaloplasty is the tension suture placement and tightening. A flexible stent, the Stageman Canal Expander (SCE) (Ophthalmos GmbH, Schaffhausen, Switzerland) was developed to overcome this

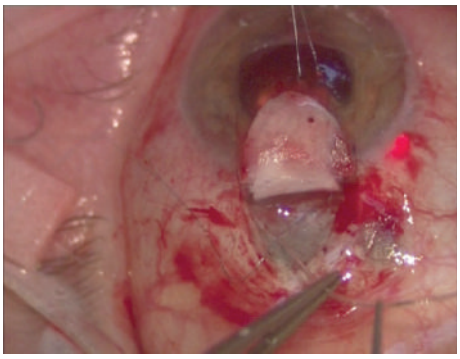

Figure 4

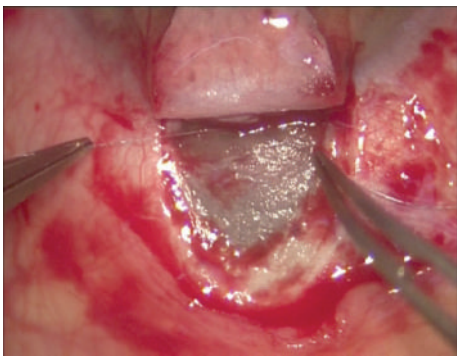

Figure 5

problem and to make canaloplasty easier. This 9.0 mm flexible stent is made of polyamide and is designed to fill a quarter of Schlemm's canal circumference, thus maintaining dilation and allowing the aqueous humor to access collector channels through its fenestrations. Using a 6/0 carrier, stents are placed in Schlemm's canal after microcatheter dilatation. When the microcatheter is withdrawn, stents are placed inside both ends. Stents overcome the obstacle of angles over Schlemm's canal that the polypropylene prolene tip finds difficult to pass over [12, 13].

4. Postoperative Treatment

Postoperatively, patients usually are treated with third or fourth generation fluoroquinolone drops 4 times daily for 1 week and with steroid drops 4 times daily for 1-2 weeks. Steroid therapy is generally tapered in the following 15–30 days. Some authors also administer nonsteroid anti-inflammatory drops in the first month of therapy [9].

5. Mechanism of Action

How canaloplasty lowers IOP is not fully understood but enlargement of Schlemm's canal and collector channels probably plays a role. In fact, canaloplasty is less likely to be successful in eyes with a nonreversible collapse of collector channels or other outflow pathways that cannot be mechanically enlarged. Since the effect of canaloplasty on IOP appears to be correlated, at least in part, to suture tension, some authors tried to measure the suture stent distension of Schlemm's canal inner wall. In a multicenter study using high-resolution anterior segment ultrasound biomicroscopy (UBM), Lewis et al. assessed the relationship between IOP reduction and the degree of canal distension. A grading system of suture tension on Schlemm's canal was created and eyes with a discernable postoperative distension were identified (first group) and compared to eyes without (second group). After two years, IOP was reduced by 31% in the first group and by 20% in the second [14]. Using UBM and anterior segment optical coherence tomography, Brandao et al. [15] quantified Schlemm's canal distension preoperatively and at 12 and 36 months after surgery. Both methods were equally efficient in identifying the suture/stent generated inner wall which did not change significantly over time. Moreover, when pre- and postoperative IOP differences were large, there was a tendency towards a greater Schlemm's canal distension, suggesting the tensioning suture contributed to IOP reduction. An adjunctive mechanism for IOP decrease could be enhanced aqueous humor filtration across the sclera and conjunctiva. Indeed, after successful canaloplasty, confocal laser-scanning microscopy demonstrated an increase in conjunctival microcysts, which are a sign of enhanced aqueous humor filtration across the sclera and conjunctiva [16].

6. Results

Reports concurred that canaloplasty effectively achieved good short- and long- term IOP reductions.

In 2007, Lewis et al. [8] published the results of a 1-year international multicenter prospective study, showing that canaloplasty reduced IOP by 36%. In 2009, the same authors [14] presented a 2-year follow-up of patients after canaloplasty, finding a 30% decrease in IOP (from 23.2 ± 4.0 to 16.3 ± 3.7 mm Hg). Need for medications also dropped from 2.0 ± 0.8 to 0.6 ± 0.8. Grieshaber et al. [17] published results of canaloplasty in 32 Caucasian subjects, observing that, without medications, mean IOP fell from 27 ± 5.6 to 12.8 ± 1.5 mm Hg 12 months after surgery. Complete success (IOP < 21 mm Hg without medications) was achieved in 93.8% of patients, IOP < 18 mm Hg in 84.4% of cases, and IOP < 16 mm Hg in 74.9%.

Grieshaber et al. [18] performed a long-term analysis in 2010 of canaloplasty outcomes in 60 black Africans with a mean preoperative IOP of 45 ± 12.1 mm Hg. At 3 years, with a mean follow-up of 30.6 ± 8.4 months, the mean IOP without medications was 13.3 ± 1.7 mm Hg. Complete success (IOP < 21 mm Hg without medications) was reached in 77.5% of patients and partial success (IOP < 21 mm Hg with or without medications) in 81.6%. In 2011, Lewis et al. [19] reported the results of a 3-year international multicenter prospective study on canaloplasty, as performed on 157 eyes with open-angle glaucoma. Preoperatively, mean IOP was 23.8 ± 5 mm Hg and number of medications was 1.8 ± 0.9. After three years, IOP decreased to 15.2±3.5 mm Hg and the number of medications fell to 0.8 ± 0.9, with 36.1% IOP reduction from baseline. Complete success (IOP < 18 mm Hg without medications)

was achieved in 36% of patients and partial success (IOP < 18 mm Hg with or without medications) in 77.5% [19].

In 2011, Bull et al. [20] analyzed the efficacy of canaloplasty in European patients with open-angle glaucoma, reporting 3-year outcomes in a series of 93 eyes. Mean IOP dropped from 23.0 ± 4.3 to 15.1 ± 3.1 mm Hg and the number of medications fell from 1.9 ± 0.7 to 0.9 ± 0.9. In 2014, Borisuth et al. [10] reported 3-year canaloplasty results in 214 eyes with open-angle glaucoma in patients who were under maximum medical therapy before surgery. The mean preoperative IOP of 29.4 ± 7.9 mm Hg decreased to 17.0 ± 4.2 mm Hg (42.2% mean IOP reduction). Complete success (defined as a postoperative IOP ≤ 21 mm Hg, ≤18 mm Hg and ≤16 mm Hg without any medical treatment) was achieved in 44.8%, 31.0%, and 24.1% of patients, respectively, while partial success (defined as a postoperative IOP ≤ 21 mm Hg, ≤18 mm Hg, and ≤16 mm Hg with or without medical treatment) was achieved in 86.2%, 58.6%, and 37.9% of patients, respectively.

In 2015, Voykov et al. [21] reported a 5-year follow-up on canaloplasty, observing the IOP reduction rate was similar to the 3-year rate. At 1, 3, and 5 years, complete success rates for IOP < 21 mm Hg were, respectively, 37%, 28%, and 10%, which are lower than the reported 40%–45% after three years. The low 5-year complete success rate could be a sign of canaloplasty losing efficacy over time. In this series, 65% of eyes required further surgery for IOP control.

Comparative studies showed canaloplasty was more efficacious in reducing IOP than viscocanalostomy [22] but less so than trabeculectomy with mitomycin C [23–25]. In a 1-year follow-up study, Ayyala et al. reported the mean IOP reduction was 32% after canaloplasty and 43% after trabeculectomy with mitomycin C; furthermore, postoperative need for medical therapy was 36% in the canaloplasty group and 20% in the trabeculectomy group [23].

Brüggemann et al. performed another comparative study on 30 eyes in 15 patients. They had trabeculectomy with mitomycin C in one eye (group 1) and canaloplasty in the other (group 2). After 1 year, mean IOP decreased from 26.3 ± 10.9 to 11.6 ± 5.2 mm Hg in group 1 and from 26.8 ± 6.4 to 13.2 ± 2.8 mm Hg in group 2. The number of glaucoma medications fell from 2.7 to 0.4 ± 0.7 in group 1 and from 2.5 to no medication in group 2. Moreover, the trabeculectomy group required a longer postoperative hospital stay (10.4 ± 2.8 versus 5.4 ± 1.0 days) as well as more postoperative check-ups (8.5 ± 3.6 versus 3.9 ± 0.8) and interventions [24].

In 2014, in a retrospective study, Thederan et al. [26] compared outcomes in 22 eyes after trabeculectomy and in 22 eyes after canaloplasty. Mean IOP in the trabeculectomy and canaloplasty groups decreased from 23.9 ± 10.7 to 10.8 ± 3.7 mm Hg and from 23.7 ± 7.6 to 14.5 ± 3.8 mm Hg, respectively. Complete success (defined as IOP < 21 mm Hg and 20% IOP reduction from baseline without medication), was achieved in 18 eyes (81.8%) after trabeculectomy and in 11 eyes (50.0%) after canaloplasty [26]. In a prospective, 2-year follow-up randomized clinical trial, Matlach et al. compared outcomes of canaloplasty and trabeculectomy in open-angle glaucoma. They observed that both approaches significantly reduced IOP. The mean absolute IOP reduction was 10.8 ± 6.9 mm Hg after trabeculectomy and 9.3 ± 5.7 mm Hg after canaloplasty while the mean IOP was 11.5 ± 3.4 mm Hg after trabeculectomy and 14.4 ± 4.2 mm Hg after canaloplasty. Complete success (IOP ≤ 18 mm Hg without medication) was achieved in, respectively, 74.2% and 39.1%, while partial success (IOP ≤ 18 mm Hg with or without medication) was achieved in 67.7% after trabeculectomy and in 39.1% after canaloplasty. Following trabeculectomy, complications were more frequent and included hypotony (37.5%), choroidal detachment (12.5%) and elevated IOP (25.0%) [25].

In 2014, Klink and coworkers [27] assessed quality of life and patient satisfaction after canaloplasty and trabeculectomy. Patients reported a better quality of life after canaloplasty, particularly with regard to positive postoperative mood, satisfaction with outcome, and lower rates of visual and nonvisual symptoms. In the trabeculectomy group, the authors registered higher stress rates due to surgery, postsurgical treatments, and check-ups and a lower satisfaction rate. They reported that 41% of patients were highly satisfied after trabeculectomy and 57% after canaloplasty. No intergroup differences emerged in restriction from social contacts and loss of independence.

7. Combined Surgery

Combining canaloplasty and phacoemulsification surgery is a suitable option in patients with clinically significant cataract. Cataract surgery alone is known to reduce IOP but the effect is generally small, probably because the wider angle and trabecular meshwork tensioning increased aqueous humor outflow [28]. The combined approach provided a greater hypotensive effect than canaloplasty alone [19, 29]. Angle architecture modification probably resulted in a more open configuration and in trabecular meshwork tensioning which increased aqueous humor outflow [28, 29].

In 2009, Lewis et al. [14] presented a 2-year follow-up of patients after phacocanaloplasty, finding a 42% decrease in IOP. IOP dropped from 23.1 ± 5.5 to 13.4 ± 4.0 mm Hg and the number of medications fell from 1.7 ± 1.0 to 0.2 ± 0.4. In a 3-year study after phacocanaloplasty, Lewis et al. found a 42.1% reduction in IOP from baseline. The mean IOP decreased from 23.5 ± 5.2 mm Hg with 1.5 ± 1.0 medications to 13.6 ± 3.6 mm Hg with 0.3 ± 0.5 medications. Use of hypotensive medications was reduced in 80% of patients [19]. In 2011, Bull et al. analyzed the efficacy of phacocanaloplasty in 16 eyes. The mean preoperative IOP fell from 24.3 ± 6.0 mm Hg with 1.5 ± 1.2 medications to 13.8 ± 3.2 mm Hg with 0.5 ± 0.7 medications after 3 years [20].

Similar results were found by Matlach et al. [30] 12 months after surgery. Phacotrabeculectomy lowered IOP more than phacocanaloplasty, but the difference was not significant. Moreover, the phacotrabeculectomy group needed fewer glaucoma medications (0.2 ± 0.4) than the phacocanaloplasty group (1.0 ± 1.5). In 2015, Schoenberg et al. [31] observed that phacocanaloplasty and phacotrabeculectomy resulted in comparable mean IOP at 12 months and they reported significant reduction in IOP and improvement in visual acuity with comparable success rates.

In 2015, in a comparative, prospective, randomized study, Rękas et al. [32] reported 1-year outcomes after phacocanaloplasty and phaco-nonpenetrating deep sclerectomy. Both techniques effectively reduced IOP with similar efficacy and safety profiles. Patients who underwent phaco-nonpenetrating deep sclerectomy required additional procedures like 5-FU injections, suture lysis, or needling, while phacocanaloplasty patients required no additional procedures.

8. Adverse Events

Although the rate of complications, particularly severe complications, is lower after canaloplasty than trabeculectomy [23], surgeons need to be aware of potential pitfalls that can occur during and after canaloplasty. Inability to cannulate Schlemm's canal is a major intraoperative complication as cannulation is successful in only 74–89.9% of cases [9, 19, 20, 29]. Failures may be due to anatomical anomalies of Schlemm's canal, to trabecular meshwork scars due to previous argon laser trabeculoplasty, or to surgical inexperience [19, 29]. When cannulation fails, the operation can be converted to deep sclerectomy or to viscocanalostomy [9].

Microcatheter escape from Schlemm's canal into surrounding structures is a rare complication. Grieshaber et al. reported catheter penetration of the anterior chamber in one case and of the suprachoroidal space in another [18]. These two cases accounted for 3.3% of all complications in the Grieshaber study.

Descemet's membrane detachment in 1.6–9.1% of cases is another rare intraoperative complication [9, 17, 19, 20, 29]. It may occur if, upon encountering a difficulty in cannulation, attempts to force injection of viscoelastic material lead to channel rupture [9]. Descemet's membrane detachments are usually limited in size (1-2 mm) and resolve spontaneously, but sometime they may reach the visual axis and require surgery [33].

Postoperative complications are divided into early (1–10 days after surgery) and late (2–5 weeks after surgery). The most common early postoperative complication, which is observed in 6.1% to 85.2% of cases, is bleeding from Schlemm's canal into the anterior chamber on the first day after surgery [9, 19, 20, 34]. Blood reaching the anterior chamber from the collector channels is considered a positive prognostic factor because it may indicate the outflow pathways are open and functioning [34]. Hyphema is usually transient, resolving spontaneously and without consequences in up to one month [17, 19, 20].

A transient increase in IOP that can reach 30 mm Hg or more is another early postoperative complication that was reported in 1.6–18.2% of eyes. It is probably due to residual viscoelastic material in Schlemm's canal that prevents aqueous humor from passing into the collector channels. IOP usually stabilizes after 24–48 hours when all residual viscoelastic is reabsorbed [9] and the increase rarely persists for 3-4 weeks. Should it do so, laser goniopuncture might be efficient.

Hypotony, a rare, transient complication (0.6%–9.8%) [9, 19, 20], is due to superficial flap sutures not being watertight.

Late complications of canaloplasty include cataract formation in 12.7% to 19.1% of patients according to diverse studies [19, 20] and long-term failure which may be treated with laser goniopuncture to reduce IOP and, if that fails, trabeculectomy.

Bleb formation is rare (2.5%) especially after phacocanaloplasty [19, 35].

9. Conclusions

Canaloplasty appears to be a valid alternative to conventional glaucoma surgery because of its efficacy and safety profile in selected patients with open-angle glaucoma. Its advantages over trabeculectomy include absence of subconjunctival bleb, no need for mitomycin C, faster visual rehabilitation, easier follow-up, and fewer postoperative complications. On the other hand, disadvantages are the long learning curve, need for specifically designed instruments, impossibility to perform the surgery properly in some cases, and a lower IOP reduction compared with trabeculectomy.

Competing Interests

The authors declare no conflict of interests and no financial support was required.

References

[1] H. A. Quigley, "Number of people with glaucoma worldwide," *British Journal of Ophthalmology*, vol. 80, no. 5, pp. 389–393, 1996.

[2] A. Heijl, M. C. Leske, B. Bengtsson, L. Hyman, B. Bengtsson, and M. Hussein, "Reduction of intraocular pressure and glaucoma progression: results from the Early Manifest Glaucoma Trial," *Archives of Ophthalmology*, vol. 120, no. 10, pp. 1268–1279, 2002.

[3] M. A. Kass, D. K. Heuer, E. J. Higginbotham et al., "The Ocular Hypertension Treatment study: a randomized trial determines that topical ocular hypotensive medication delays or prevents the onset of primary open-angle glaucoma," *Archives of Ophthalmology*, vol. 120, no. 6, pp. 701–713, 2002.

[4] P. R. Lichter, D. C. Musch, B. W. Gillespie et al., "Interim clinical outcomes in the Collaborative Initial Glaucoma Treatment Study comparing initial treatment randomized to medications or surgery," *Ophthalmology*, vol. 108, no. 11, pp. 1943–1953, 2001.

[5] N. Prasad and M. A. Latina, "Blebitis and endophthalmitis after glaucoma filtering surgery," *International Ophthalmology Clinics*, vol. 47, no. 2, pp. 85–97, 2007.

[6] S. Zahid, D. C. Musch, L. M. Niziol, and P. R. Lichter, "Risk of endophthalmitis and other long-term complications of trabeculectomy in the collaborative initial glaucoma treatment study (CIGTS)," *American Journal of Ophthalmology*, vol. 155, no. 4, pp. 674–e1, 2013.

[7] R. C. Stegmann, "Visco-canalostomy: a new surgical technique for open angle glaucoma," *Annals de Istituto Barraquer*, vol. 25, pp. 229–232, 1995.

[8] R. A. Lewis, K. von Wolff, M. Tetz et al., "Canaloplasty: circumferential viscodilation and tensioning of Schlemm's canal using a flexible microcatheter for the treatment of open-angle glaucoma in adults: interim clinical study analysis," *Journal of*

Cataract and Refractive Surgery, vol. 33, no. 7, pp. 1217–1226, 2007.

[9] P. Brusini, "Canaloplasty in open-angle glaucoma surgery: a four-year follow-up," *The Scientific World Journal*, vol. 2014, Article ID 469609, 7 pages, 2014.

[10] N. S. C. Borisuth, B. Phillips, and T. Krupin, "The risk profile of glaucoma filtration surgery," *Current Opinion in Ophthalmology*, vol. 10, no. 2, pp. 112–116, 1999.

[11] D. G. Godfrey, R. L. Fellman, and A. Neelakantan, "Canal surgery in adult glaucomas," *Current Opinion in Ophthalmology*, vol. 20, no. 2, pp. 116–121, 2009.

[12] K. Mansouri and T. Shaarawy, "Update on Schlemm's canal based procedures," *Middle East African Journal of Ophthalmology*, vol. 22, no. 1, pp. 38–44, 2015.

[13] M. C. Grieshaber, G. Sunaric-Mégevand, M. Ronzani, P. Maurer, and M. Fehlker, "Usability testing of the canal expander—a new implant for canaloplasty," *Klinische Monatsblätter für Augenheilkunde*, vol. 232, no. 4, pp. 432–437, 2015.

[14] R. A. Lewis, K. von Wolff, M. Tetz et al., "Canaloplasty: circumferential viscodilation and tensioning of Schlemm canal using a flexible microcatheter for the treatment of open-angle glaucoma in adults: two-year interim clinical study results," *Journal of Cataract and Refractive Surgery*, vol. 35, no. 5, pp. 814–824, 2009.

[15] L. M. Brandao, A. Schötzau, and M. C. Grieshaber, "Suture distension of Schlemm's canal in canaloplasty: an anterior segment imaging study," *Journal of Ophthalmology*, vol. 2015, Article ID 457605, 7 pages, 2015.

[16] L. Mastropasqua, L. Agnifili, M. L. Salvetat et al., "In vivo analysis of conjunctiva in canaloplasty for glaucoma," *British Journal of Ophthalmology*, vol. 96, no. 5, pp. 634–639, 2012.

[17] M. C. Grieshaber, S. Fraenkl, A. Schoetzau, J. Flammer, and S. Orgül, "Circumferential viscocanalostomy and suture canal distension (canaloplasty) for whites with open-angle glaucoma," *Journal of Glaucoma*, vol. 20, no. 5, pp. 298–302, 2011.

[18] M. C. Grieshaber, A. Pienaar, J. Olivier, and R. Stegmann, "Canaloplasty for primary open-angle glaucoma: long-term outcome," *British Journal of Ophthalmology*, vol. 94, no. 11, pp. 1478–1482, 2010.

[19] R. A. Lewis, K. von Wolff, M. Tetz et al., "Canaloplasty: three-year results of circumferential viscodilation and tensioning of Schlemm canal using a microcatheter to treat open-angle glaucoma," *Journal of Cataract and Refractive Surgery*, vol. 37, no. 4, pp. 682–690, 2011.

[20] H. Bull, K. Von Wolff, N. Körber, and M. Tetz, "Three-year canaloplasty outcomes for the treatment of open-angle glaucoma: European study results," *Graefe's Archive for Clinical and Experimental Ophthalmology*, vol. 249, no. 10, pp. 1537–1545, 2011.

[21] B. Voykov, G. Blumenstock, M. A. Leitritz, S. Dimopoulos, and O. Alnahrawy, "Treatment efficacy and safety of canaloplasty for open-angle glaucoma after 5 years," *Clinical & Experimental Ophthalmology*, vol. 43, no. 8, pp. 768–771, 2015.

[22] N. J. Koerber, "Canaloplasty in one eye compared with viscocanalostomy in the controlateral eye in patients with bilateral open-angle glaucoma," *Journal of Glaucoma*, vol. 21, no. 2, pp. 129–134, 2012.

[23] R. S. Ayyala, A. L. Chaudhry, C. B. Okogbaa, and D. Zurakowski, "Comparison of surgical outcomes between canaloplasty and trabeculectomy at 12 months follow-up," *Ophthalmology*, vol. 118, no. 12, pp. 2427–2433, 2011.

[24] A. Brüggemann, J. T. Despouy, A. Wegent, and M. Müller, "Intraindividual comparison of canaloplasty versus trabeculectomy with mitomycin C in a single-surgeon series," *Journal of Glaucoma*, vol. 22, no. 7, pp. 577–583, 2013.

[25] J. Matlach, C. Dhillon, J. Hain, G. Schlunck, F. Grehn, and T. Klink, "Trabeculectomy versus canaloplasty (TVC study) in the treatment of patients with open angle glaucoma: a prospective randomized clinical trial," *Acta Ophthalmologica*, vol. 93, no. 8, pp. 753–761, 2015.

[26] L. Thederan, F. Grehn, and T. Klink, "Comparison of canaloplasty with trabeculectomy," *Klinische Monatsblatter fur Augenheilkunde*, vol. 231, no. 3, pp. 256–261, 2014.

[27] T. Klink, J. Sauer, N. J. Körber et al., "Quality of life following glaucoma surgery: canaloplasty versus trabeculectomy," *Clinical Ophthalmology*, vol. 9, pp. 7–16, 2014.

[28] B. J. Shingleton, J. J. Pasternack, J. W. Hung, and M. W. O'Donoghue, "Three and five year changes in intraocular pressures after clear corneal phacoemulsification in open angle glaucoma patients, glaucoma suspects, and normal patients," *Journal of Glaucoma*, vol. 15, no. 6, pp. 494–498, 2006.

[29] B. Shingleton, M. Tetz, and N. Korber, "Circumferential viscodilation and tensioning of Schlemm canal (canaloplasty) with temporal clear corneal phacoemulsification cataract surgery for open-angle glaucoma and visually significant cataract. One-year results," *Journal of Cataract and Refractive Surgery*, vol. 34, no. 3, pp. 433–440, 2008.

[30] J. Matlach, F. J. Freiberg, S. Leippi, F. Grehn, and T. Klink, "Comparison of phacotrabeculectomy versus phacocanaloplasty in the treatment of patients with concomitant cataract and glaucoma," *BMC Ophthalmology*, vol. 13, article 1, 2013.

[31] E. D. Schoenberg, A. L. Chaudhry, R. Chod, D. Zurakowski, and R. S. Ayyala, "Comparison of surgical outcomes between phacocanaloplasty and phacotrabeculectomy at 12 months' follow-up: a longitudinal cohort study," *Journal of Glaucoma*, vol. 24, no. 7, pp. 543–549, 2015.

[32] M. Rękas, A. Byszewska, K. Petz, J. Wierzbowska, and A. Jünemann, "Canaloplasty versus non-penetrating deep sclerectomy—a prospective, randomised study of the safety and efficacy of combined cataract and glaucoma surgery; 12-month follow-up," *Graefe's Archive for Clinical and Experimental Ophthalmology*, vol. 253, no. 4, pp. 591–599, 2015.

[33] M. Gismondi and P. Brusini, "Intracorneal hematoma after canaloplasty in glaucoma," *Cornea*, vol. 30, no. 6, pp. 718–719, 2011.

[34] J. M. Koch, A. Heiligenhaus, and C. Heinz, "Canaloplasty and transient anterior chamber haemorrhage: a prognostic factor?" *Klinische Monatsblätter für Augenheilkunde*, vol. 228, no. 5, pp. 465–467, 2011.

[35] M. Tetz, N. Koerber, B. J. Shingleton et al., "Phacoemulsification and intraocular lens implantation before, during, or after canaloplasty in eyes with open-angle glaucoma: 3-year results," *Journal of Glaucoma*, vol. 24, no. 3, pp. 187–194, 2015.

Hindawi Publishing Corporation
Journal of Ophthalmology
Volume 2016, Article ID 2837562, 7 pages
http://dx.doi.org/10.1155/2016/2837562

Clinical Study

Stab Incision Glaucoma Surgery: A Modified Guarded Filtration Procedure for Primary Open Angle Glaucoma

Soosan Jacob,[1] Michele Figus,[2] Dhivya Ashok Kumar,[1] Ashvin Agarwal,[1] Amar Agarwal,[1] and Saijimol Areeckal Incy[1]

[1] *Dr. Agarwal's Eye Hospital and Eye Research Centre, 19 Cathedral Road, Chennai 600 086, India*
[2] *University of Pisa, 56126 Pisa, Italy*

Correspondence should be addressed to Amar Agarwal; dragarwal@vsnl.com

Received 18 December 2015; Revised 14 March 2016; Accepted 20 March 2016

Academic Editor: Ozlem G. Koz

Purpose. To describe a modified guarded filtration surgery, stab incision glaucoma surgery (SIGS), for primary open angle glaucoma (POAG). *Methods*. This prospective, interventional case series included patients with POAG (IOP ≥21 mmHg with glaucomatous visual field defects). After sliding superior conjunctiva down over limbus, 2.8 mm bevel-up keratome was used to create conjunctival entry and superficial corneoscleral tunnel in a single step starting 1.5 mm behind limbus. Lamellar corneoscleral tunnel was carefully dissected 0.5–1 mm into cornea and anterior chamber (AC) was entered. Kelly Descemet's punch (1 mm) was slid along the tunnel into AC to punch internal lip of the tunnel, thereby compromising it. Patency of ostium was assessed by injecting fluid in AC and visualizing leakage from tunnel. Conjunctival incision alone was sutured. *Results*. Mean preoperative IOP was 27.41 ± 5.54 mmHg and mean postoperative IOP was 16.47 ± 4.81 mmHg ($n = 17$). Mean reduction in IOP was 38.81 ± 16.55%. There was significant reduction of IOP ($p < 0.000$). 64.7% had IOP at final follow-up of <18 mmHg without medication and 82.35% had IOP <18 mmHg with ≤2 medications. No sight threatening complications were encountered. *Conclusion*. Satisfactory IOP control was noted after SIGS in interim follow-up (14.18 ± 1.88 months).

1. Introduction

Conjunctival dissection is an important step in glaucoma filtering surgery [1, 2]. Decreasing the intraoperative conjunctival manipulation may be expected to lead to less subconjunctival fibrosis and better aqueous drainage in the long term [3–5]. An accepted method of maintaining aqueous drainage has been conventional trabeculectomy where, after raising a conjunctival flap, an artificial channel is made between the anterior chamber and the subconjunctival space by means of a scleral flap [1]. Reduction of intraocular pressure (IOP) has been known to be sustained by this channel over a period [6–9]. In this paper, we have presented a modified technique of trabeculectomy for primary open angle glaucoma (POAG) where a scleral tunnel has been used with decreased conjunctival dissection. This technique was described by one of us (SJ).

2. Materials and Methods

This prospective interventional case series was carried out at Dr. Agarwal's Eye Hospital and Eye Research Centre, Chennai, India. Institutional review board (IRB) approval was obtained and the procedure conformed to declaration of Helsinki. Informed consent was obtained from all patients. Preoperative visual acuity was measured with Snellen acuity charts, IOP by Goldmann applanation tonometer, and anterior chamber depth by optical coherence tomography. Patients with primary open angle glaucoma of age 40 to 70 years, IOP more than 21 mmHg, and visual field defects on automated perimetry and who were willing for follow-up were included after informed consent. Patients with previous uveitis, conjunctival scarring, angle closure glaucoma, previous trabeculectomy, and poor visual acuity in fellow eye and one eyed patients were excluded. The follow-up visits were on day 1, day 7, 1 month, 3 months, 6 months, and so on.

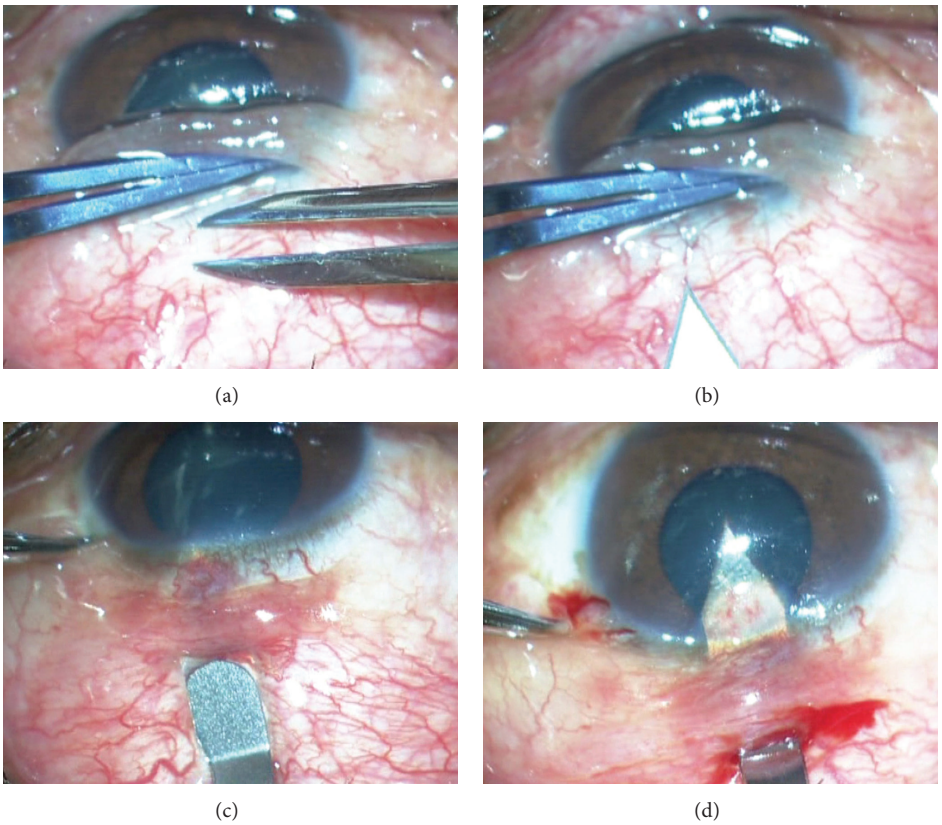

Figure 1: Stab incision glaucoma surgery (SIGS). (a), (b) Superior conjunctiva is slid downwards over the cornea and a 2.8 mm bevel-up metal keratome is introduced 1.5 mm behind the limbus. (c) Keratome is passed through the conjunctiva and into lamellar sclera and a superficial lamellar scleral tunnel is then dissected. (d) Keratome is introduced about 0.5–1 mm into the clear cornea and the anterior chamber (AC) is then entered.

A complete success was defined as an intraocular pressure of <18 mmHg without medications and qualified success was defined as reduction in IOP to <18 mmHg with two or less medications. Failure was defined as need for more than 2 medicines postoperatively for IOP control. Intraoperative or postsurgical event which required conversion to conventional trabeculectomy or resurgery to decrease IOP was also considered as failure. Any ocular adverse effect which required surgical or medical intervention for management apart from regular postoperative regimen was considered as complication of the surgery.

Preoperatively, 0.2 mL of 0.01% mitomycin C (MMC) was injected subconjunctivally in the area of intended bleb creation. Peribulbar anesthesia was given and the eye was prepared and draped. The speculum was loosened slightly to allow more mobile conjunctiva and to prevent it from being pulled into the fornices. Superior conjunctiva was slid downwards over the cornea and a 2.8 mm bevel-up metal keratome was introduced 1.5 mm behind the limbus (Figures 1(a) and 1(b)). The tip of the keratome was passed through the conjunctiva into superficial lamellar sclera (Figure 1(c)). A superficial lamellar scleral tunnel was then dissected with side to side movements of the keratome till the limbus, keeping the depth of dissection such that the blade could be visualized through the overlying sclera and conjunctiva. At the limbus, the blade was angulated more superficially to correspond to the steeper corneal curvature and depth was confirmed by a dimpling of the cornea. The blade was then introduced 0.5 to 1 mm into clear cornea before entering the anterior chamber (AC) in a horizontal plane (Figure 1(d)). Downwards pressure on the keratome was avoided while entering the AC. The blade was then withdrawn and viscoelastic instilled into the AC through either a paracentesis or the stab incision glaucoma surgery (SIGS) tunnel entry (Figure 2(a)). The 1 mm Kelly Descemet's punch (Appasamy Associates, India) was then slid along the tunnel into the AC and with the punch facing downwards, the internal lip of the corneal section was punched (Figures 2(b) and 2(c)). After pushing the iris away with viscoelastic, the ostium thus initiated was extended posteriorly till the limbus with additional punches under visualization through the overlying clear cornea (Figure 2(d)). A peripheral iridectomy (PI) was done with curved Vannas scissors by retracting basal iris through the tunnel with nontoothed forceps while the assistant retracted the conjunctiva for visualization (Figure 3(a)). The iris was gently pushed back into the AC and a simcoe cannula inserted through the tunnel was used to wash out viscoelastic (Figure 3(b)). Balanced salt solution (BSS) was irrigated through the side port and leakage from the SIGS tunnel was assessed. End point looked for was a free flow

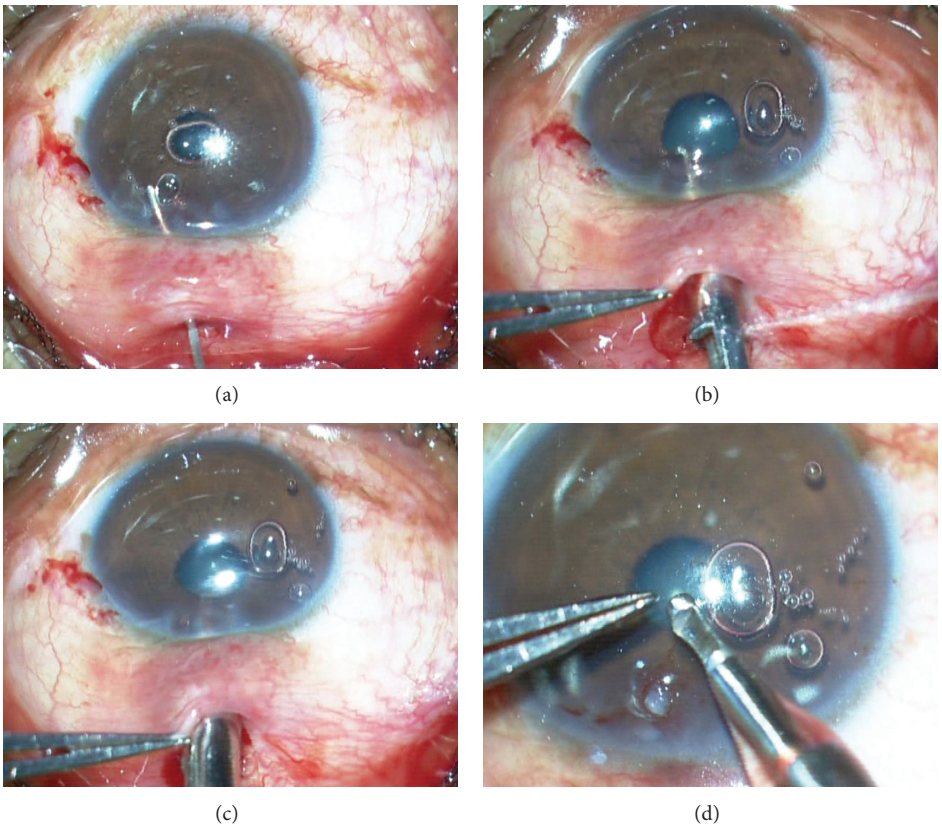

Figure 2: (a) Viscoelastic is injected into the AC. (b), (c) Kelly Descemet's punch used to punch the internal lip of the cornea. (d) The punched tissue from the posterior lip of cornea is seen.

of fluid on irrigation. Additional punches were taken in case of inadequate leak. The 2.8 mm conjunctival cut was sutured with a running 10-0 nylon suture (Figure 3(c)). BSS was injected through the side port to balloon the bleb (Figure 3(d)). Subconjunctival garamycin 0.5 mL and dexamethasone 0.5 mL were given in the inferior forniceal conjunctiva (Video file, at Supplementary Material available online at http://dx.doi.org/10.1155/2016/2837562).

2.1. Statistical Analysis. Data was entered in a Microsoft Excel Sheet (Microsoft Corp., Redmond, Washington, USA) and was analyzed using SPSS version 16.1 (SPSS Inc., Chicago, Illinois, USA). Continuous variables were expressed as means (±standard deviations) and categorical variables were expressed as individual counts. After testing for normality distribution of data, the statistical tests were allotted. Non-parametric tests were used for comparison. Differences were considered statistically significant when the p value was less than 0.05.

3. Results and Discussion

3.1. Results. Seventeen eyes of 17 patients (7 males, 10 females) underwent SIGS with preoperative subconjunctival MMC. The mean age was 57 ± 11.9 years. The mean follow-up was 14.18 ± 1.88 months. The mean preoperative IOP was 27.41 ± 5.54 mmHg (range 21–39 mm Hg) and the mean postoperative IOP was 16.47 ± 4.81 mmHg (range 9–28 mmHg). There was significant reduction in IOP from preoperative values (Wilcoxon signed rank test, $p < 0.000$). The mean reduction in IOP was 38.81 ± 16.55%. Preoperatively 7 out of 17 (41.1%) had advanced glaucomatous field loss and 10 out of 17 (58.8%) had moderate glaucomatous field loss. There was no significant change in pattern standard deviation (PSD) in visual field test ($p = 0.068$) from preoperative to postoperative period. The mean preoperative and postoperative PSD were 6.9 ± 2.7 Decibels and 6.97 ± 2.7 Decibels. The number of topical medications was reduced from a mean of 1.35 preoperatively to 0.59 postoperatively. There was significant reduction in number of medications used from pre- to postoperative period ($p = 0.025$, Wilcoxon signed rank test). A complete success defined as an intraocular pressure of <18 mmHg without medications was seen in 64.70% and 82.35% of patients maintaining an IOP of <18 mmHg with ≤2 medications. Preoperative corrected distance visual acuity (CDVA) measured by Snellen's distant visual acuity charts was 0.80 ± 0.28 and postoperative CDVA was 0.76 ± 0.25 (Wilcoxon signed rank test, $p = 0.230$). Intraoperative complications encountered were premature entry ($n = 1$; small basal punch taken), trapdoor hinging of internal corneal lip ($n = 1$; hinged lip excised), conjunctival buttonhole ($n = 1$; small, no intervention), Descemet's detachment ($n = 1$; small,

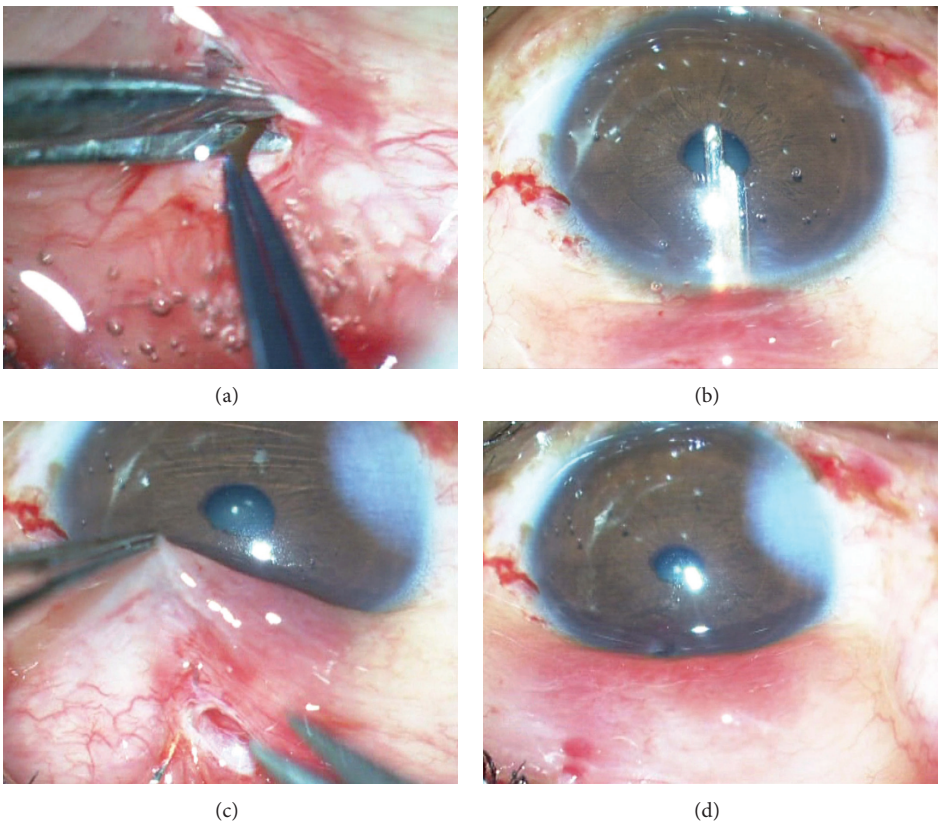

Figure 3: (a) A peripheral iridectomy (PI) is done with curved Vannas scissors by retracting basal iris through the tunnel with nontoothed forceps while the assistant retracts the conjunctiva for visualization. (b) Viscoelastic is washed out. (c) Patency of the tunnel is checked by irrigating the anterior chamber with balanced salt solution and looking for bleb formation. The conjunctival incision is then sutured with a running 10-0 nylon suture. (d) The bleb is seen lifted after side port irrigation.

managed with air bubble), and nonbasal PI ($n = 1$; no intervention). Postoperative complications encountered were microhyphema ($n = 2$; medical management), more than grade 2 AC reaction ($n = 1$; medical management), hypotony ($n = 1$, managed successfully with transconjunctival tunnel compression suture), and uncontrolled IOP ($n = 6$; 3 were managed medically and 3 underwent repeat surgery). There were no sight threatening complications such as bleb inflammation/infection or cystoid macular edema seen in any of the eyes.

3.2. Discussion. Traditional trabeculectomy has been a widely adopted procedure of choice [1, 2]. However, a common cause of glaucoma surgery failure is subconjunctival fibrosis of the bleb. Wound-healing response after filtering surgery can present in one of two ways, either as subconjunctival fibrosis or as sub-Tenon's encapsulation leading to lack of filtration and subsequent increase in IOP. In an attempt to reduce failure due to fibrosis, antimetabolites have been used; however, fibrosis and bleb failure are still reported [10]. Reducing excessive intraoperative manipulation of conjunctiva and Tenon's capsule has been shown to prevent fibrosis [7–13]. Nontraumatic subconjunctival dissection has also been tried to prevent inadvertent conjunctival handling [11–13].

Increased conjunctival manipulation can increase chances of buttonhole, tear, and subsequent fibrosis. A reduction in manipulation would help in reducing the same. Theoretically, positioning the conjunctival incision and scleral entry apart from each other (about 4 mm) may help in preventing direct conduit for microbes. Though there is no exact data on how much the incisions should be spaced for a significant protective effect, there was no inflammation or infection seen in our cases. However, similar to trabeculectomy, in the presence of a leak or wound dehiscence, this potential advantage may be lost and such situations should be avoided. Sliding the conjunctiva towards the limbus to avoid the conjunctival and scleral wounds from overlapping also decreases the risk of fibrosis between overlapping incisions. Mechanical pressure exerted by the conjunctival sutures is transmitted away from the scleral wound and there is therefore less contact zone between the 2 incisions.

SIGS reduces conjunctival dissection as the keratome produces a smooth linear entry. Subconjunctival drainage channels are therefore preserved intact to a larger extent as compared to trabeculectomy, thus potentially inducing less subconjunctival fibrosis and allowing better subconjunctival drainage. Bleb elevation is by hydrostatic expansion of largely intact subconjunctival tissue. In our experience, the creation of the tunnel was easy and one step and thereby surgery

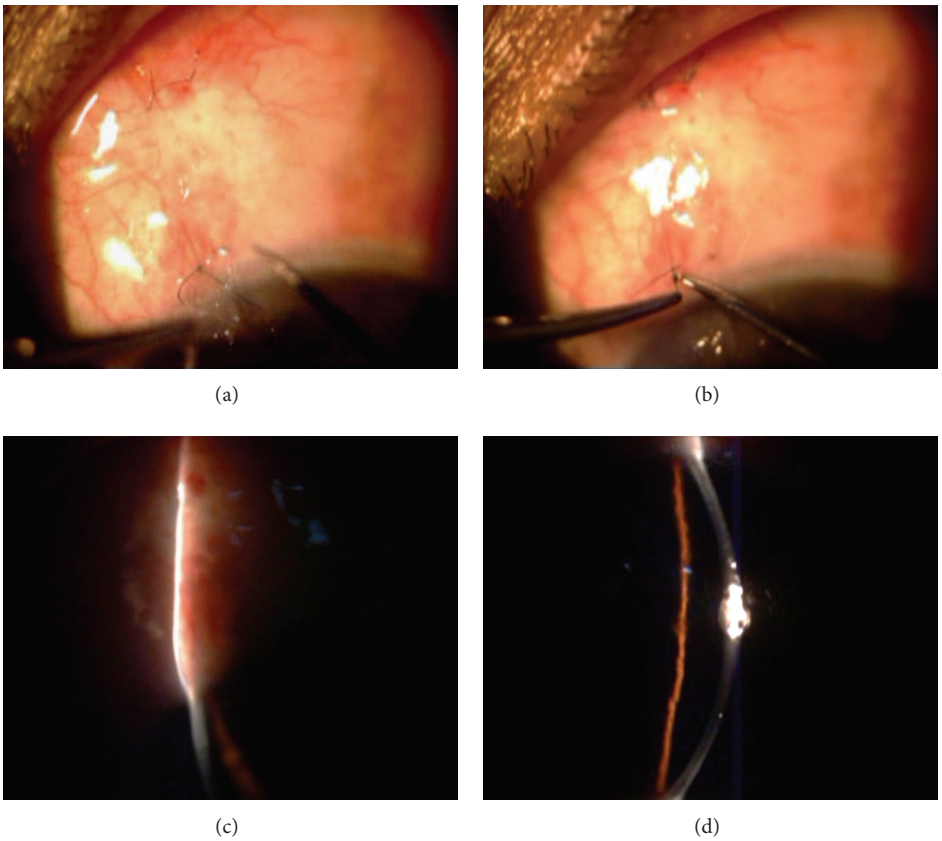

Figure 4: (a) Compression suture seen passed transconjunctivally. (b) Suture being removed after 3 weeks. (c) Shallow bleb seen formed after suture removal and mild massage. (d) Well-formed AC and controlled IOP at 15 mmHg.

was easier and faster. Larger area of intact conjunctiva also has additional advantage of allowing greater space for a second glaucoma surgery if required. The single step tunnel approach in SIGS offers advantages of posteriorly directed aqueous flow as compared to leakage under a flap where flow occurs to three sides. This can prevent complications such as overhanging blebs and bleb dysesthesia. Once the learning curve is crossed, other potential advantages of this technique include ease of creation, less manipulation compared to a scleral flap, less likelihood of flap tears and buttonholes, and less suture related inflammation. In the extreme event of an expulsive hemorrhage, it can be rapidly closed.

Tunnel trabeculectomies that use a scleral tunnel have been described in the past as a successful mode of filtration surgery [14–16]. These involve creating a triplanar scleral tunnel after raising a conjunctival flap. SIGS follows this principle of tunnel trabeculectomy. However, it differs from these in the absence of conjunctival flap creation and in utilizing a biplanar scleral tunnel. The entry in SIGS is one step and conjunctival incisions as well as subconjunctival dissection are therefore minimized. A biplanar incision is a more advantageous geometry than a triplanar incision for better aqueous leakage postoperatively.

Significant intraoperative complications encountered were premature entry and trapdoor hinging of the posterior corneal lip. Premature entry occurred when the keratome pass was deep and entered the AC directly without a corneal component. This was managed by taking a single small punch which was sufficient to attain adequate leakage. A trapdoor hinging occurred when the corneal tunnel was deep and the posterior corneal lip gave way. This was managed by excising the hinge with Vannas scissors and then proceeding as usual.

Success rates after trabeculectomy with target pressure between 18 and 22 mmHg have been variously reported to range from 43% to 86% without medications [17–26] and from 59% to 98% with medications [17, 21, 22]. In our study, postoperatively, a complete success was possible in 64.7% with an IOP at final follow-up of <18 mmHg without medication and 82.35% with IOP <18 mmHg with two or less medications. Three patients had to undergo repeat surgery. One patient who had postoperative hypotony was managed by transconjunctival compression suture that compressed the tunnel and decreased flow. Transconjunctival suturing was easy to perform as the scleral tunnel was visible through overlying conjunctiva on stretching conjunctiva out over the tunnel area. The conjunctiva did not need to be cut for tunnel exposure to apply the suture and the suture was removed after 3 weeks (Figures 4(a)–4(d)). Other complications encountered were minor.

Though we did not put releasable suture in any patient in this case series, it is possible to do postoperative IOP management using laser suture lysis or removable suture technique

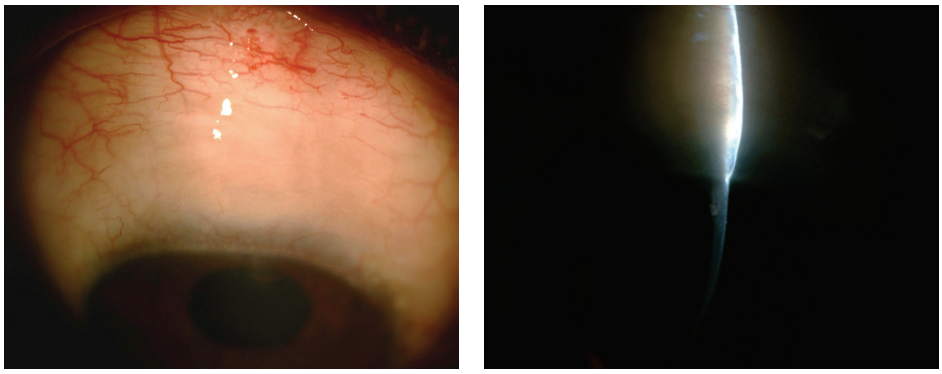

(a) (b)

Figure 5: (a), (b) Slit lamp view showing diffuse, low bleb after SIGS.

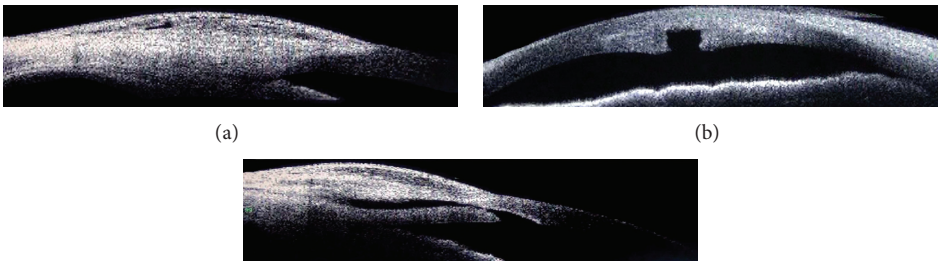

(a) (b)

(c)

Figure 6: Anterior segment optical coherence tomography (ASOCT) showing bleb with multiple subconjunctival cystic spaces (a), corneal punch (b), and postoperative scleral tunnel and subscleral filtration path (c) at 10 months.

in the same manner as is done in trabeculectomy [27]. This can be done by taking a releasable suture in the standard way through the tunnel and releasing it in the postoperative period. Unlike in trabeculectomy where suturing is possible under direct visualization, in SIGS visibility is comparatively more difficult. However, in our experience, the scleral lip of the tunnel is generally visible on pulling the conjunctival incision towards the limbus and this can make application of the releasable suture across the tunnel possible.

A potential disadvantage for this technique is that since all maneuvers are done under the tunnel, the technique appears partially blinded. However, we were able to visualize the scleral tunnel entrance under the conjunctiva, passage of the keratome, the corneal entry lip, corneal punch, and final diffuse bleb formation in all cases. Another potential disadvantage is the possibility of subconjunctival bleeding as cautery is not applied. In our experience, avoiding visible conjunctival and scleral blood vessels was generally enough to avoid large subconjunctival hemorrhage. Small oozing that occurred was not significant enough to interfere with surgery. However, patients on oral antiplatelet agents were advised to stop these medications for sufficient duration of time before surgery. The scleral tunnel incision though hidden underneath the conjunctiva could be visualized in all cases by withdrawing the conjunctival incision towards the limbus. Though only a gross assessment of flow was possible, in our experience, free flow of fluid and good ballooning of the bleb on side port irrigation when seen with a soft, yet stable AC lead to better outcomes (Figures 5(a) and 5(b); Figures 6(a)–6(c)).

4. Conclusion

Though long term results are still under evaluation, satisfactory IOP control was noted by us after SIGS in the interim follow-up. The small sample size and the limited follow-up make it difficult to draw a strong conclusion pertaining to long term outcomes and complication rate. This pilot study however serves to lay the foundation for further detailed analysis of this technique. A long term study in a larger population will be required to confirm the anatomical and functional outcomes of this modified technique.

Additional Points

Free paper on this technique presented at American Society of Cataract and Refractive Surgery 2014 at Boston won the best paper award. Video film on this technique also won film festival award at American Society of Cataract and Refractive Surgery 2014 at Boston.

Competing Interests

None of the authors have any financial or proprietary interest in any product, method, or material mentioned in the paper.

Acknowledgments

The paper has been read and approved by all the authors and the requirements for authorship have been met and represent honest work.

References

[1] J. E. Cairns, "Trabeculectomy. Preliminary report of a new method," *American Journal of Ophthalmology*, vol. 66, no. 4, pp. 673–679, 1968.

[2] J. G. Crowston, "Long-term outcomes of trabeculectomy," *Clinical and Experimental Ophthalmology*, vol. 36, no. 8, pp. 705–706, 2008.

[3] G. L. Skuta and R. K. Parrish II, "Wound healing in glaucoma filtering surgery," *Survey of Ophthalmology*, vol. 32, no. 3, pp. 149–170, 1987.

[4] C. A. Bruno, G. J. Fisher, and S. E. Moroi, "Is 'scarless wound healing' applicable to glaucoma surgery?" *Expert Review of Ophthalmology*, vol. 2, no. 1, pp. 79–90, 2007.

[5] H. Mietz, G. Arnold, B. Kirchhof, M. Diestelhorst, and G. K. Krieglstein, "Histopathology of episcleral fibrosis after trabeculectomy with and without mitomycin C," *Graefe's Archive for Clinical and Experimental Ophthalmology*, vol. 234, no. 6, pp. 364–368, 1996.

[6] D. I. M. Robinson, S. Lertsumitkul, F. A. Billson, and L. P. Robinson, "Long-term intraocular pressure control by trabeculectomy: a ten-year life table," *Australian and New Zealand Journal of Ophthalmology*, vol. 21, no. 2, pp. 79–85, 1993.

[7] P. Ehrnrooth, I. Lehto, P. Puska, and L. Laatikainen, "Long term outcome of trabeculectomy in terms of intraocular pressure," *Acta Ophthalmologica Scandinavica*, vol. 80, no. 3, pp. 267–271, 2002.

[8] C. E. Parc, D. H. Johnson, J. E. Oliver, M. G. Hattenhauer, and D. O. Hodge, "The long-term outcome of glaucoma filtration surgery," *American Journal of Ophthalmology*, vol. 132, no. 1, pp. 27–35, 2001.

[9] T. H. Bevin, A. C. B. Molteno, and P. Herbison, "Otago glaucoma surgery outcome study: long-term results of 841 trabeculectomies," *Clinical and Experimental Ophthalmology*, vol. 36, no. 8, pp. 731–737, 2008.

[10] P. T. Khaw, "Advances in glaucoma surgery: evolution of antimetabolite adjunctive therapy," *Journal of Glaucoma*, vol. 10, no. 5, supplement 1, pp. S81–S84, 2001.

[11] A. M. Agbeja and G. N. Dutton, "Conjunctival incisions for trabeculectomy and their relationship to the type of bleb formation—a preliminary study," *Eye*, vol. 1, no. 6, pp. 738–743, 1987.

[12] L. Chang, T. Wong, M. Ohbayashi et al., "Increased mast cell numbers in the conjunctiva of glaucoma patients: a possible indicator of preoperative glaucoma surgery inflammation," *Eye*, vol. 23, no. 9, pp. 1859–1865, 2009.

[13] D.-Y. Yu, W. H. Morgan, X. Sun et al., "The critical role of the conjunctiva in glaucoma filtration surgery," *Progress in Retinal and Eye Research*, vol. 28, no. 5, pp. 303–328, 2009.

[14] R. A. Schumer and S. A. Odrich, "A scleral tunnel incision for trabeculectomy," *American Journal of Ophthalmology*, vol. 120, no. 4, pp. 528–530, 1995.

[15] J. S. M. Lai and D. S. C. Lam, "Trabeculectomy using a sutureless scleral tunnel technique: a preliminary study," *Journal of Glaucoma*, vol. 8, no. 3, pp. 188–192, 1999.

[16] Y. Eslami, M. Mohammadi, M. Khodaparast et al., "Sutureless tunnel trabeculectomy without peripheral iridectomy: a new modification of the conventional trabeculectomy," *International Ophthalmology*, vol. 32, no. 5, pp. 449–454, 2012.

[17] J. M. Gonzalez-Rodriguez, G. E. Trope, L. Drori-Wagschal, D. Jinapriya, and Y. M. Buys, "Comparison of trabeculectomy versus Ex-PRESS: 3-year follow-up," *British Journal of Ophthalmology*, 2015.

[18] K. Nouri-Mahdavi, L. Brigatti, M. Weitzman, and J. Caprioli, "Outcomes of trabeculectomy for primary open-angle glaucoma," *Ophthalmology*, vol. 102, no. 12, pp. 1760–1769, 1995.

[19] T. Jerndal and M. Lundström, "330 trabeculectomies-a follow-up study through 1/2-3 years," *Acta Ophthalmologica*, vol. 55, no. 1, pp. 52–62, 1977.

[20] M. R. Wilson, U. Mendis, A. Paliwal, and V. Haynatzka, "Long-term follow-up of primary glaucoma surgery with ahmed glaucoma valve implant versus trabeculectomy," *American Journal of Ophthalmology*, vol. 136, no. 3, pp. 464–470, 2003.

[21] F. D'Ermo, L. Bonomi, and D. Doro, "A critical analysis of the long-term results of trabeculectomy," *American Journal of Ophthalmology*, vol. 88, no. 5, pp. 829–835, 1979.

[22] P. G. Watson and I. Grierson, "The place of trabeculectomy in the treatment of glaucoma," *Ophthalmology*, vol. 88, no. 3, pp. 175–196, 1981.

[23] S. Cillino, F. Di Pace, G. Cillino, and A. Casuccio, "Biodegradable collagen matrix implant vs mitomycin-C as an adjuvant in trabeculectomy: a 24-month, randomized clinical trial," *Eye*, vol. 25, no. 12, pp. 1598–1606, 2011.

[24] J. F. Panarelli, M. R. Banitt, S. J. Gedde, W. Shi, J. C. Schiffman, and W. J. Feuer, "A retrospective comparison of primary baerveldt implantation versus trabeculectomy with mitomycin C," *Ophthalmology*, vol. 123, no. 4, pp. 789–795, 2016.

[25] S. S. Palmer, "Mitomycin as adjunct chemotherapy with trabeculectomy," *Ophthalmology*, vol. 98, no. 3, pp. 317–321, 1991.

[26] D. J. Annen and J. Sturmer, "Trabeculectomy with low concentration of mitomycin (0.2 mg/ml for 1 minute). Independent evaluation of a retrospective non-randomised pilot study," *Klinische Monatsblatter fur Augenheilkunde*, vol. 206, no. 5, pp. 300–302, 1995.

[27] "SIGS releasable suture Soosan Jacob with audio 4.2 min," 2016, https://www.youtube.com/watch?v=sUWHZ6zQrDI.

Hindawi Publishing Corporation
Journal of Ophthalmology
Volume 2016, Article ID 3762674, 6 pages
http://dx.doi.org/10.1155/2016/3762674

Research Article

Comparison of Subconjunctival Mitomycin C and 5-Fluorouracil Injection for Needle Revision of Early Failed Trabeculectomy Blebs

Wei Liu, Jianrong Wang, Miaomiao Zhang, Yuan Tao, and Yan Sun

The Second People's Hospital of Jinan, No. 148 Jingyi Road, Jinan 250001, China

Correspondence should be addressed to Jianrong Wang; wangjianrong2000@sohu.com

Received 19 October 2015; Accepted 22 December 2015

Academic Editor: Vital P. Costa

Background. To compare the efficacy of needle revision with 5-fluorouracil (5-FU) and mitomycin C (MMC) on dysfunctional filtration blebs shortly after trabeculectomy. *Methods*. It is a prospective randomized study comparing needle revision augmented with MMC or 5-FU for failed trabeculectomy blebs. *Results*. To date 71 patients (75 eyes) have been enrolled, 40 eyes in the MMC group and 35 in the 5-FU group. 68 patients (72 eyes) have completed 12-month follow-up, 38 eyes in the MMC group and 34 in the 5-FU group. The mean IOP before and that after needle revision in the MMC group were 26.5 ± 4.3 mmHg and 11.3 ± 3.4 mmHg, respectively ($P < 0.05$), and in the 5-FU group were 27.1 ± 3.8 mmHg and 10.9 ± 3.4 mmHg, respectively ($P < 0.05$). At 12-month follow-up, complete success rates were 57.5% for MMC group and 34.3% for 5-FU group ($P = 0.042$; log-rank test) and 75% and 60% ($P = 0.145$; log-rank test), respectively, for the qualified success. Complication rates between the two groups were not statistically different ($P > 0.05$). *Conclusions*. Needle revision and subconjunctival MMC injection were more effective than needling and subconjunctival 5-FU injection for early dysfunctional filtration blebs after trabeculectomies.

1. Background

Trabeculectomy is the most common filtration procedure in the surgical treatment of glaucoma. Despite the increasing use of antifibrotic agents to modulate the wound healing response, bleb failure remains a common complication of glaucoma filtration surgery. Failure of the filtration bleb due to subconjunctival scar formation can constitute a significant problem in achieving satisfactory intraocular pressure (IOP) control after trabeculectomy. The rate of bleb failure has been reported to be as high as 10%–20% [1–5].

Needle revision of a failing filtration bleb with antimetabolite injections (either 5-fluorouracil [5-FU] [6–10] or mitomycin C [MMC]) [11–14] has been shown to be a simple and effective way to reestablish aqueous flow and lower IOP. It is difficult to make a literature comparison between 5-FU and MMC needle revisions because few reports have been published [15, 16] and those available mainly studied late bleb failure following trabeculectomy. To the best of our knowledge, this is the first study to directly compare needle revision with 5-FU and with MMC for failed filtration blebs shortly after trabeculectomy.

2. Methods

This is a prospective, comparative case series of 75 eyes (71 patients) that underwent needle revision augmented with MMC or 5-FU for failed trabeculectomy blebs between November 2009 and March 2012. The protocol was reviewed and approved by the Institutional Ethics Committee of The Second People's Hospital of Jinan. Each participant provided written informed consent before any study-related examination or procedure was performed and the study adhered to the tenets of the Declaration of Helsinki. Patients were randomly assigned to receive either subconjunctival MMC or 5-FU according to a computer generated randomization list.

All study eyes had unsuccessful filtering procedures, with or without the use of antifibrotic agents (mitomycin C 0.4 mg/mL was placed under the scleral flap for 1 to 2 minutes before irrigation with balanced salt solution).

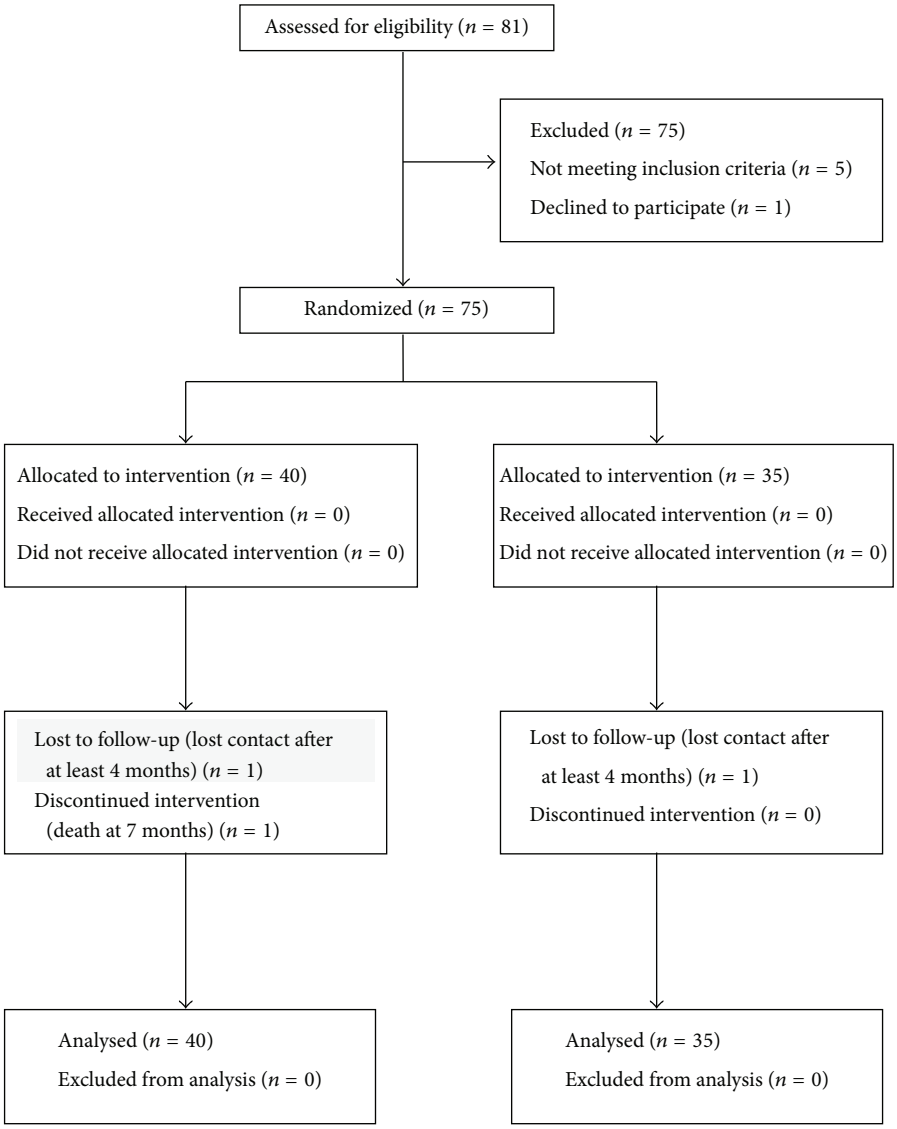

Figure 1: Flow chart for the randomization.

Bleb massage and suture removal or laser suture lysis were attempted before needle revision. Signs of a failed bleb included an unacceptably high IOP, an open corneoscleral window visible on gonioscopy, vascularization, thickening and flattening of the bleb, and loss of conjunctival microcysts. In all cases gonioscopy was undertaken to ensure that the internal stoma was patent. Patient demographics, glaucoma type, antimetabolite use with trabeculectomy, logMAR best-corrected visual acuity (BCVA), IOP, and time from trabeculectomy were noted. All study eyes had an IOP of >21 mmHg before needle revision. Needling and subconjunctival MMC or 5-FU were applied between 2 and 8 weeks (median = 4.9 weeks) following initial trabeculectomy. Randomization was determined before procedures according to a block randomization sequence prepared by SAS (version 9.1; SAS Institute Inc., Cary, NC, USA). No patients were excluded after the randomization (Figure 1).

A single surgeon (WJR) performed all bleb revisions, using the standard protocol, in an operating room under sterile conditions. A sterile tetracaine-soaked cotton swab was placed over the superotemporal quadrant of the ocular surface for approximately 5 minutes to locally anesthetize the ocular surface. Using a 29-gauge needle, the subconjunctival space was entered at least 10 mm from the filtration bleb site. Subconjunctival fibrosis was disrupted by multiple puncturing motions to restore aqueous drainage. Careful attention was given to avoid inadvertent perforation of the overlying conjunctiva and subconjunctival blood vessels. It was important that the needle insertion under the scleral flap or entering the anterior chamber was avoided. IOP was checked immediately afterward and the needling repeated if IOP had not dropped significantly. At the end of the procedure, a single subconjunctival injection of 5-FU (0.1 mL of 50 mg/mL) or MMC (0.1 mL of 0.2 mg/mL) was administered

Table 1: Patient demographic and clinical characteristics of the patients.

	MMC group	5-FU group	P
Age (year)	49.1 ± 10.4	47.6 ± 10.8	0.542
Gender (F/M)	19/18	23/11	
Baseline IOP (mmHg) [range]	26.5 ± 4.3 [22–38]	27.1 ± 3.8 [23–36]	0.526
BCVA (logMAR)	0.4 ± 0.1	0.4 ± 0.2	1.000
Antimetabolite used in trabeculectomy, number of eyes (%)	34 (85.0)	29 (83.8)	0.801
Time from trabeculectomy to needle revision (week) [range: 2–8 weeks]	5.3 ± 1.90	4.5 ± 1.81	0.066
Diagnosis, number of eyes (%)			
PCAG	23 (57.5)	20 (57.1)	
POAG	14 (35.0)	12 (34.3)	0.385
Juvenile glaucoma	3 (7.5)	1 (2.9)	
Traumatic glaucoma	0 (0)	2 (5.7)	

and the conjunctival sac was rinsed with sterile 0.9% saline. In both procedures, the antiproliferative agent was injected by a separate needle and at least 8 mm away from the bleb limbus, to prevent entry into the anterior.

Patients were examined daily for the first week and at 1, 2, 3, and 6 months and at 1 year. The minimum follow-up was 4 months. During follow-up, BCVA, IOP, glaucoma medications, and complications were recorded at each of the follow-up visits.

Criteria for success were defined before reviewing the data. Complete success was defined as $5 \leq \text{IOP} \leq 21$ mmHg without antiglaucomatous medications measured at the last visit. A qualified success was defined as $5 \leq \text{IOP} \leq 21$ mmHg with topical antiglaucomatous medications. Failure was considered to have occurred from the first visit when the IOP was higher than 21 mmHg and could not be controlled by topical antiglaucomatous medications in eyes. Hypotony was defined as IOP < 5 mmHg. For any patient who was lost to follow-up, success was determined by the clinical status of the patient at the time of the last visit.

Data are presented as mean ± standard deviation. Statistical analyses were performed using SPSS statistical software (ver. 18.0, SPSS, Inc., Chicago, IL). The normality of data was evaluated using an independent sample t-test. Descriptive statistics were used to evaluate patient demographic characteristics. Success rates in both groups were compared using Kaplan-Meier life table analysis and the log-rank test. Statistical significance was defined as a P value < 0.05.

3. Results

Table 1 shows the demographic and clinical characteristics of the patients. No statistically significant differences between the 5-FU and the MMC groups were observed ($P > 0.05$). Baseline IOP before the procedure was 26.5 ± 4.34 mmHg in the MMC group and 27.1 ± 3.85 mmHg in the 5-FU group, a difference that was not statistically significant ($P = 0.64$). Needling and subconjunctival MMC or 5-FU were applied between 2 and 8 (median, 5.3 and 4.5) weeks following trabeculectomy ($P = 0.054$).

Immediately after needle revision, IOP was 11.1 ± 3.4 mmHg (range: 6.0–18 mmHg) in the MMC group and 10.9 ± 3.4 mmHg (range: 6.0–20 mmHg) in the 5-FU group, a slight difference that was not statistically significant ($P = 0.813$). The decrease in IOP following the procedure was statistically significant in both groups ($P < 0.01$).

68 patients (72 eyes) have completed 12-month follow-up, 38 eyes in the MMC group and 34 in the 5-FU group. Twelve-month Kaplan-Meier life table rates for complete success (IOP ≤ 21 mmHg without medications) were 57.5% (23 eyes) and 34.3% (12 eyes) for the MMC group and the 5-FU group, respectively ($P = 0.042$; log-rank test) (Figure 2). The 12-month life table rates for qualified success (IOP ≤ 21 mmHg with medication use) were 75% (30 eyes) and 60% (21 eyes) for the MMC group and the 5-FU group, respectively ($P = 0.145$; log-rank test) (Figure 3).

Complications are listed in Table 2. Complications rates between the two groups were statistically the same. No statistically significant difference between the groups in terms of the occurrence of complications was observed ($P > 0.05$). Leaks through conjunctival entry site persisted for 1 month before resolving in 1 eye of MMC group. Most complications were self-limiting and all complications were resolved without surgical intervention.

4. Discussion and Conclusion

Needle revision is considered to be a simple and effective way to rejuvenate failing or failed filtration blebs months, or even years, after trabeculectomy. Since 1990, numerous studies, with variable sample sizes and follow-up periods, have reported various success rates in bleb needle revisions with both subconjunctival 5-FU [3, 6, 8–10, 15, 16] and MMC [11–16]. However, the success rates with both compounds have been highly variable, ranging from 39% to 91% [8, 9, 12, 13, 16] at 12-month follow-up. This is consistent with our

Table 2: Summary of complications that occurred following needle revision.

Complications	MMC group (%)	5-FU group (%)	P
Hypotony	3 (7.5)	2 (5.7)	0.756
Corneal punctate epitheliopathy	3 (7.5)	2 (5.7)	0.756
Anterior chamber reaction	5 (12.5)	4 (11.4)	0.887
Subconjunctival hemorrhage	17 (42.5)	14 (40.0)	0.826
Shallow anterior chamber	9 (22.5)	6 (17.1)	0.561
Leak through conjunctival entry site	11 (27.5)	7 (20)	0.446

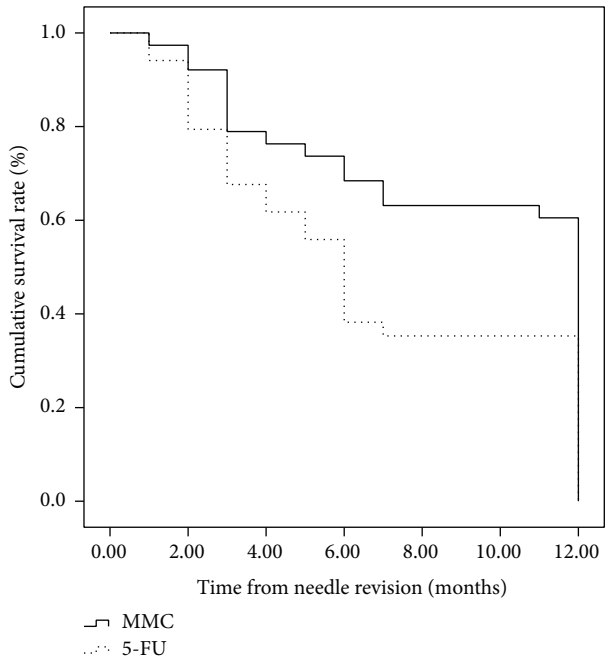

Figure 2: Survival curve with complete success defined as 5 < IOP < 21 mmHg without glaucoma medication (P = 0.042).

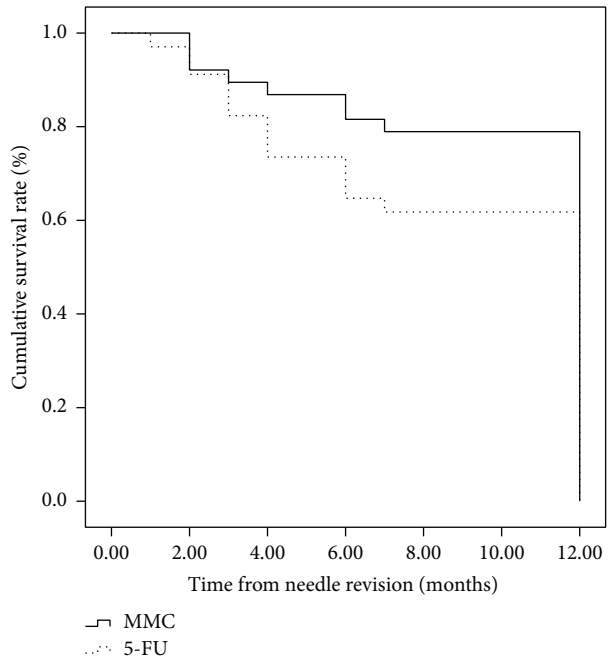

Figure 3: Survival curve with qualified success defined as 5 < IOP < 21 mmHg with and without glaucoma medication (P = 0.145).

findings. In the current study, the total success rates were relatively high, perhaps because revisions were performed sooner after trabeculectomy than other studies. Previous studies mainly examined late bleb failure. Gutiérrez-Ortiz et al. [13] found that the time from the initial filtering surgery to the needling revision was associated with the success rate. Surgery performed less than 4 months previously was found to be a significant factor contributing to the success of the needling procedure. In our study, needle revision was applied between 2 and 8 weeks (median = 4.9 weeks) following initial trabeculectomy. Within 1 month of trabeculectomy, eyes are still early in the wound healing processes. Fibroblast proliferation and early scar formation, which heavily influence filtering bleb morphology and function, are still occurring. Shortly after trabeculectomy, bleb cavities still exist, but the increase in fiber proliferation increases the aqueous flow resistance and can lead to filtering bleb failure. Ren and Qiao [17] proposed that the increased resistance to aqueous flow that results in filtering bleb failure is divided into two parts: those that resist flow upstream from the scleral flap and those that resist flow downstream from the scleral flap. More specifically, shortly after trabeculectomy, there is no resistance to flow upstream to the scleral flap because it is open. However, this is not the case downstream from it because subconjunctival fibrovascular tissue proliferates early in the healing process, creating flow resistance. When bleb needle revision is performed early in this proliferation process, the procedure can have a high success rate. Otherwise, the proliferation moves to the fibers of the scleral surface, causing scleral flap closure and subsequent filtering bleb failure. Eventually, the flap will scar over and, at this time, bleb needle revision is difficult and the procedural success rate is poor.

Palejwala et al. [16] found that there was no apparent difference between the use of 5-FU and the use of MMC. Our results show that subconjunctival MMC is more effective than 5-FU in achieving good pressure control. We believe that there are two reasons. First, wound healing occurs in 3 overlapping phases and in glaucoma filtering surgery, the production, contraction, and remodeling of collagen cause most blebs to fail. A number of factors can inhibit

this process, including the use of antiproliferative agents [18]. Considering the 3 phases of wound healing, the most appropriate time to perform MMC needling when signs of failure are detected should be during the cellular phase, which starts several weeks after surgery and continues for months, because MMC inhibits proliferation of fibroblasts during the cellular phase [13]. Second, the biochemical mechanisms of the two drugs are different. Mitomycin C has a greater inhibitory effect on tissues than 5-FU. Because 5-FU is a halogenated pyrimidine analog, it competitively inhibits thymidylate synthetase. The 5-FU becomes incorporated into DNA and RNA within actively replicating cells, leading to defective protein synthesis, and subsequent interference of the cell growth cycle. Therefore, once 5-FU is no longer present, cells that were not in the synthesis phase during drug exposure can still proliferate. On the other hand, MMC is an antibiotic derived from *Streptomyces caespitosus*. It is an alkylating agent, which cross-links DNA, inhibiting mitosis and protein and DNA synthesis. In contrast to 5-FU, it acts at all stages of the cell replication cycle, inhibiting both dividing and resting cells [18]. When applied to the ocular surface topically or injected subconjunctivally, MMC and 5-FU prevent fibroblast proliferation within the subconjunctival space and Tenon's capsule. Mitomycin C also has potent antiangiogenic properties and is thought to have longer-lasting effects than 5-FU on the resident fibroblast population. In animal studies, which compared fibroblast proliferation inhibition with both 5-FU and MMC, the effect of 5-FU only lasted for 7 days, but the effect of MMC was sustained for at least 1 month [19].

Several complications have been reported to be associated with needle revision and subconjunctival [11, 16] MMC or 5-FU application. These include choroidal effusion, shallow anterior chamber, subconjunctival hemorrhage, hypotony maculopathy, and suprachoroidal hemorrhage [16]. In our study, no significant differences in complication rates were observed between the 5-FU and MMC groups. In this study, we had a lower incidence of complications. This is mainly because we only damaged the proliferation of subconjunctival fibers and the needle insertion under the scleral flap or entering the anterior chamber was avoided. The complication that occurred most often in the current study was subconjunctival hemorrhage. This was not a surprise because the needle revision procedure takes place in the subconjunctival space and proliferation of subconjunctival fibers significantly disrupts vascular organization relatively early. All complications that occurred were resolved without surgical intervention.

Our study had limitations. First, in this study, the population were younger and had more angle-closure than the large majority of the needling literature [15, 16], and all patients were of the Chinese race. Young age is associated with needling failure [13]. Mardelli et al. [11] found that successful single-needling procedure was highly correlated with race (white). In future, we can have further study in this regard. Second, the number of complications is small in both groups given the small number of cases in this cohort; thus a significant effect is unlikely to be seen. A prospective, randomized controlled trial with a larger number of cases could resolve these problems.

In conclusion, needle revision and subconjunctival MMC or 5-FU injection was a relatively effective and safe method of treating encapsulated and scarred filtering blebs during the early postoperative stage. Needle revision and subconjunctival MMC injection were more effective than needle revision and subconjunctival 5-FU injection for bleb failure following trabeculectomy.

Conflict of Interests

The authors declare that they have no competing interests.

Authors' Contribution

Wei Liu, Miaomiao Zhang, and Jianrong Wang conceived the study and participated in its design, data acquisition, data analysis, literature search, main paper writing, and submission. Jianrong Wang performed all bleb revisions and data acquisition. Yuan Tao and Yan Sun participated in postoperative observation and data acquisition. All authors read and approved the final paper.

References

[1] A. Azuara-Blanco and L. J. Katz, "Dysfunctional filtering blebs," *Survey of Ophthalmology*, vol. 43, no. 2, pp. 93–126, 1998.

[2] I. U. Scott, D. S. Greenfield, J. Schiffman et al., "Outcomes of primary trabeculectomy with the use of adjunctive mitomycin," *Archives of Ophthalmology*, vol. 116, no. 3, pp. 286–291, 1998.

[3] I. Durak, Z. Özbek, A. Yaman, M. Soylev, and G. Çingil, "The role of needle revision and 5-fluorouracil application over the filtration site in the management of bleb failure after trabeculectomy: a prospective study," *Documenta Ophthalmologica*, vol. 106, no. 2, pp. 189–193, 2003.

[4] E. M. Van Buskirk, "Five-year follow-up of the fluorouracil filtering surgery study," *American Journal of Ophthalmology*, vol. 122, no. 5, p. 751, 1996.

[5] P. Palmberg, "The failing filtering bleb," *Ophthalmology Clinics of North America*, vol. 13, no. 3, pp. 517–530, 2000.

[6] D. C. Broadway, P. A. Bloom, C. Bunce, M. Thiagarajan, and P. T. Khaw, "Needle revision of failing and failed trabeculectomy blebs with adjunctive 5-fluorouracil: survival analysis," *Ophthalmology*, vol. 111, no. 4, pp. 665–673, 2004.

[7] A. S. Hawkins, J. K. Flanagan, and S. V. L. Brown, "Predictors for success of needle revision of failing filtration blebs," *Ophthalmology*, vol. 109, no. 4, pp. 781–785, 2002.

[8] D. H. Shin, M. S. Juzych, A. K. Khatana, R. P. Swendris, and K. A. Parrow, "Needling revision of failed filtering blebs with adjunctive 5-fluorouracil," *Ophthalmic Surgery*, vol. 24, no. 4, pp. 242–248, 1993.

[9] D. H. Shin, Y. Y. Kim, S. Y. Ginde et al., "Risk factors for failure of 5-fluorouracil needling revision for failed conjunctival filtration blebs," *American Journal of Ophthalmology*, vol. 132, no. 6, pp. 875–880, 2001.

[10] J. J. Pasternack, M. Wand, M. B. Shields, and D. Abraham, "Needle revision of failed filtering blebs using 5- fluorouracil and a combined ab-externo and ab-interno approach," *Journal of Glaucoma*, vol. 14, no. 1, pp. 47–51, 2005.

[11] P. G. Mardelli, C. M. Lederer Jr., P. L. Murray, S. A. Pastor, K. M. Hassanein, and C. V. Migliazzo, "Slit-lamp needle revision of

failed filtering blebs using Mitomycin C," *Ophthalmology*, vol. 103, no. 11, pp. 1946–1955, 1996.

[12] R. K. Shetty, L. Wartluft, and M. R. Moster, "Slit-lamp needle revision of failed filtering blebs using high-dose mitomycin C," *Journal of Glaucoma*, vol. 14, no. 1, pp. 52–56, 2005.

[13] C. Gutiérrez-Ortiz, C. Cabarga, and M. A. Teus, "Prospective evaluation of preoperative factors associated with successful mitomycin C needling of failed filtration blebs," *Journal of Glaucoma*, vol. 15, no. 2, pp. 98–102, 2006.

[14] G. J. Ben-Simon and Y. Glovinsky, "Needle revision of failed filtering blebs augmented with subconjunctival injection of mitomycin C," *Ophthalmic Surgery Lasers and Imaging*, vol. 34, no. 2, pp. 94–99, 2003.

[15] N. Anand and A. Khan, "Long-term outcomes of needle revision of trabeculectomy blebs with mitomycin C and 5-fluorouracil: a comparative safety and efficacy report," *Journal of Glaucoma*, vol. 18, no. 7, pp. 513–520, 2009.

[16] N. Palejwala, P. Ichhpujani, G. Fakhraie, J. S. Myers, M. R. Moster, and L. J. Katz, "Single needle revision of failing filtration blebs: a retrospective comparative case series with 5-fluorouracil and mitomycin C," *European Journal of Ophthalmology*, vol. 20, no. 6, pp. 1026–1034, 2010.

[17] Z.-Q. Ren and R.-H. Qiao, "Clinical observation of needle revision and 5-fluorouracil subconjunctival injection on the dysfunctional filtering blebs," *Zhonghua Yan Ke Za Zhi*, vol. 41, no. 12, pp. 1082–1085, 2005.

[18] V. P. Costa, G. L. Spaeth, R. A. Eiferman, and S. Orengo-Nania, "Wound healing modulation in glaucoma filtration surgery," *Ophthalmic Surgery*, vol. 24, no. 3, pp. 152–170, 1993.

[19] P. T. Khaw, J. W. Doyle, M. B. Sherwood, I. Grierson, G. Schultz, and S. McGorray, "Prolonged localized tissue effects from 5-minute exposures to fluorouracil and mitomycin C," *Archives of Ophthalmology*, vol. 111, no. 2, pp. 263–267, 1993.

Hindawi Publishing Corporation
Journal of Ophthalmology
Volume 2016, Article ID 3410469, 5 pages
http://dx.doi.org/10.1155/2016/3410469

Research Article

Comparison of Surgical Outcomes between Canaloplasty and Schlemm's Canal Scaffold at 24 Months' Follow-Up

Stefano A. Gandolfi, Nicola Ungaro, Stella Ghirardini, Maria Grazia Tardini, and Paolo Mora

Ophthalmology Unit, University Hospital of Parma, 43126 Parma, Italy

Correspondence should be addressed to Paolo Mora; paolo.mora@unipr.it

Received 30 November 2015; Revised 19 January 2016; Accepted 24 January 2016

Academic Editor: Antonio Ferreras

The results of canaloplasty (CP) and Hydrus Microstent (HM) implantation were retrospectively compared at 24 months' follow-up in a cohort of subjects referred to our Institution for uncontrolled IOP in primary or secondary (e.g., pseudoexfoliative and pigmentary) open-angle glaucoma. The outcome was labelled as "complete" success, "qualified" success, or "failure" if, two years after surgery, the eyes operated on needed "no" hypotensive medications, "some" hypotensive medications, or further glaucoma surgery to attain the target IOP, respectively. Both CP and HM implant allowed significant IOP reductions, with comparable rate of clinical success and safety profile. A slightly (albeit not significant) better trend for a "complete" clinical success was observed in the CP group.

1. Introduction

Creating an extraocular aqueous humour filtration is still the most popular surgical strategy in glaucoma worldwide. However, because of the well known bleb-related problems, a quest for new "bleb-free" procedures has been pursued for several years. For example, canaloplasty (CP) and the trabeculocanalicular devices implantable through a minimally invasive approach (the so called MIGS) are two surgical strategies not ending in external filtration.

CP consists of an "ab-externo" dilation of Schlemm's canal (SC) (via a transconjunctival and transscleral approach) obtained by intracanalicular injection of high molecular weight (HMW) viscoelastic and placement of a permanent intracanalicular tension suture [1]. MIGS devices are placed in the anterior chamber (AC) angle under gonioscopic view and via a clear cornea incision [2], sparing then the conjunctiva for later interventions. The Hydrus Microstent (Ivantis, Inc., Irvine, CA) is a MIGS device made of nitinol, (a nickel and titanium alloy widely used in ophthalmic and other medical applications [3]), currently approved for intraocular use in Europe. This device is an 8 mm long crescent-shaped open structure, curved to match the shape of SC. Once implanted, the microstent bypasses the trabecular meshwork and dilates SC over 3 clock hours to provide direct aqueous access from the AC to multiple collector channels [4, 5].

To date, some studies have compared the outcomes of CP with filtering surgery. The large majority of these reports showed that, in the short-to-mid term, both procedures are effective in achieving significant reduction of intraocular pressure (IOP), with a better efficacy profile for filtration surgery and a better safety profile for CP [6–9]. The hereby presented study was aimed to compare the 2-year clinical outcome of CP versus a bleb-free MIGS (i.e., the Hydrus Microstent (HM)), within the frame of a retrospective comparative study.

2. Methods

This was a retrospective, nonrandomized comparative case series (with the approval of the local Ethics Committee requiring no trial registration number). Medical records of consecutive patients, where either CP or HM implantation was uneventfully performed in one eye from January 2011 to January 2012 at the University Hospital of Parma (Italy), were

reviewed. All surgeries were performed by two surgeons (Stefano A. Gandolfi and Nicola Ungaro), and all study subjects signed a dedicated informed consent prior to surgery. The series included subjects under local treatment for primary or secondary (e.g., pseudoexfoliative and pigmentary) open-angle glaucoma, referred to as the Glaucoma Service of our Institution Parma for uncontrolled IOP. The eyes were addressed to either one of the two procedures since, according to the EGS guidelines [10], the estimated postsurgery target IOP was arbitrarily set in the mid-to-high teens range by the two surgeons (Stefano A. Gandolfi and Nicola Ungaro).

The following data were collected from a total of 45 patients (45 eyes, 24 CP, and 21 HM) with a minimum follow-up of two years: (a) demographics, (b) IOP, (c) best corrected visual acuity (BCVA, tested by logarithmic chart at 4 metres), (d) Visual Field Mean Defect (MD, Humphrey 24-2 SITA-Standard program, Carl Zeiss Meditec Inc., Dublin, CA), (e) the number and type of hypotensive medications, (f) and the need for further glaucoma surgery. IOP was measured using Goldmann applanation tonometer and following the standard operating procedures (SOP) of the European Vision Clinical Research network (EVICR.net) which certified our Institution (certificate number: ECR37/2014), namely, (a) patients in sitting position at the slit lamp; (b) fluorescein staining with a standard fluorescein paper strip; (c) two rapidly consecutive readings, averaged with ≤2 mmHg IOP difference, with a third reading being performed when the difference was >2 mmHg.

The eyes were labelled as "complete" success, "qualified" success, or "failure" if, two years after surgery, they needed *no* hypotensive medications, *some* hypotensive medications, or further glaucoma surgery to attain the target IOP, respectively.

2.1. Operative Techniques. All surgeries were single operations, not combined with phacoemulsification.

CP was performed according to the standard fashion described in previous reports [11, 12]. Briefly, after conjunctival dissection at the 12 o'clock limbus, a 5 × 5 mm partial thickness (50%) scleral flap was dissected followed by a 4 × 4 mm inner scleral flap at 95% depth. The inner flap dissection was carried forward until the SC was unroofed. The dissection was then carried into the clear cornea to create a 0.3 mm Descemet's window; the inner scleral flap was then removed and the inner wall of the canal was peeled off together with trabecular meshwork, until percolation of aqueous humour was observed. A microcatheter (iTrack-250A, iScience Interventional, Inc., Menlo Park, CA) was then inserted 360° in the canal; a 10-0 prolene suture was tied to the tip of the catheter, and the catheter was retracted backward and, in order to achieve viscodilation of the canal, sodium hyaluronate 1.4% (Healon GV, Advanced Medical Optics, Inc., Santa Ana, CA) was simultaneously injected. The 10-0 prolene suture was finally tightly tied in a loop with a slip knot, to obtain an inward traction. The scleral flap was secured back to the sclera with 10-0 nylon sutures to create a water-tight closure. The conjunctiva was then sutured to the limbus with 8-0 absorbable sutures.

HM implantation was performed as follows: after a peribulbar injection of 5 mL of lidocaine, the patients were placed under the microscope and the head tilted to allow a clear view of the angle structures with a gonioprism. A 1.2–1.5 mm clear cornea incision was properly made to access the targeted site for microstent placement. HMW viscoelastic was introduced for chamber maintenance and an optimum view. The Hydrus delivery cannula was then inserted through the incision. The bevelled tip of the cannula was used to perforate the trabecular meshwork, and the microstent was implanted into Schlemm's canal by advancing the tracking wheel with the index finger, leaving 1-2 mm (the inlet segment) remaining in the AC. In one of the selected cases, the microstent had to be retracted and reinserted in a different location. Upon confirmation of position in the canal, the delivery system was withdrawn and viscoelastic was removed; the AC was inflated with balanced salt solution to achieve normal IOP.

2.2. Statistical Analysis. Statistical data were processed with the SPSS package (SPSS Inc. Released 2007; SPSS for Windows, Version 16.0. Chicago, SPSS Inc.). In detail, Student's t-test was for mean confrontation between groups, Chi-squared test was for double and triple enter contingency tables. For 2 × 2 contingency tables, Fischer's test was applied. Statistical significance was set at $p < 0.05$. The normal distribution of the analyzed data was stated by verifying for each parameter that means were "almost equal to" medians and asymmetric within ±2.

3. Results

Twenty-four eyes of 24 patients (16 men, age range: 34–66 years) who underwent CP and twenty-one eyes of 21 patients (15 men, age range: 37–69 years) who underwent HM implantation were included in the study. We considered all the patients who successfully completed surgery and the 2-year follow-up (therefore no loss to follow-up). No significant difference was found between the two groups with respect to demographics (age: $p = 0.31$; gender: $p = 0.59$; race: all Caucasians; right versus left eye $p = 0.67$). The diagnosis was as follows: $n = 28$ primary open-angle glaucoma (POAG; 16 CP and 12 HM); $n = 15$ pseudoexfoliation syndrome (PEX: 8 CP and 7 HM); and $n = 2$ pigmentary glaucoma (PG: 2 HM). At preoperative evaluation (baseline), no significant differences in the number of ongoing hypotensive active substances ($p = 0.23$) and in the number of eyes previously treated with argon laser trabeculoplasty/selective laser trabeculoplasty (AST/SLT) were detected between groups ($p = 0.34$).

Eye parameters at baseline and 2 years after surgery are detailed in Table 1 (mean ± SD). "IOP initial" refers to the IOP (on current hypotensive therapy) measured before surgery at the time of completion of the inpatient's record. "IOP final" refers to the IOP values measured 2 years after surgery (with a ±30-day time window), with or without medications. No intergroup difference was detected in either efficacy (IOP) or safety (i.e., BCVA and MD) outcomes. Conversely, an intragroup analysis showed that IOP significantly diminished in both groups upon surgery ($p < 0.001$). The IOP changes

Table 1: Parameters considered for the study at the baseline (initial) and after a 24-month follow-up (final) for the two treatment groups.

Treatment groups	IOP initial (mmHg)	IOP final (mmHg)	BCVA initial (LogMAR)	BCVA final (LogMAR)	MD initial (dB)	MD final (dB)
HM	24 ± 6	15 ± 3	0.11 ± 0.08	0.08 ± 0.02	4.6 ± 1.9	4.2 ± 1.9
CP	26 ± 4	16 ± 2	0.11 ± 0.08	0.09 ± 0.08	4.0 ± 3.2	3.9 ± 3.3
Statistics	$p = 0.22$	$p = 0.18$	$p = 0.93$	$p = 0.58$	$p = 0.45$	$p = 0.70$

HM: Hydrus Microstent; CP: canaloplasty; IOP: intraocular pressure; mmHg: millimeters of mercury; BCVA: best correct visual acuity; LogMAR: logarithm of the minimum angle of resolution; MD: Visual Field Mean Defect; dB: decibel.

Table 2: Eyes' distribution according to the clinical outcome at the end of the follow-up.

	HM	CP	Total
Complete success			
Count	7	12	19
% within group	33.3%	50%	42.2%
Qualified success			
Count	12	10	22
% within group	57.1%	41.7%	48.9%
Failure			
Count	2	2	4
% within group	9.5%	8.3%	8.9%
Total			
Count	21	24	45
% within group	100%	100%	100%

HM: Hydrus Microstent; CP: canaloplasty.

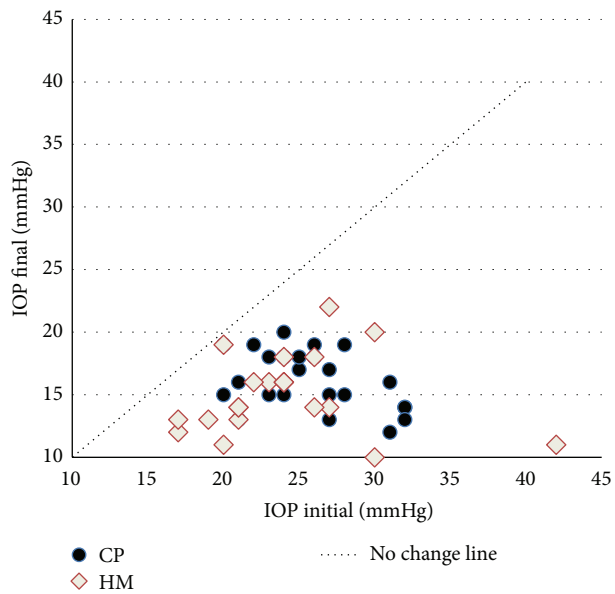

Figure 1: Scatterplot of preoperative (IOP initial) versus postoperative (IOP final) IOP values in the two treatment groups (CP = canaloplasty group; HM = Hydrus Microstent group).

of individual eyes in each treatment group are shown in a scatterplot (Figure 1). Table 2 shows the rate of each clinical outcome at the end of the follow-up. The distribution of the clinical success ("complete" or "qualified") was not significantly different between the two groups (Pearson Chi-Square, $p = 0.52$; Likely Ratio, $p = 0.51$). Also the event "failure" (i.e., the need for further glaucoma surgery) was similar in the two groups either in terms of the number of procedures or the number of temporal latencies. Namely, two cases in the HM group were performed after 12 and 18 months of follow-up; two cases in the CP groups 12 and 13 months postoperatively.

Concerning the number of hypotensive active substances administered at the end of the follow-up, the mean values were in the CP group 0.7 ± 0.9 and in the HM group 0.9 ± 0.9. Differences referred to the intensity of the regimen (i.e., none, 1 or more active substances) are shown in Figure 2; no statistical difference was observed (Pearson Chi-Square = Likely Ratio; $p = 0.74$).

The final distribution among the subgroups of clinical outcome of the eyes previously treated by AST/SLT is displayed in Table 3. A laser treatment was paralleled by a lower rate of complete success in the CP group versus the HM group with borderline significance (Fisher exact test, $p = 0.04$). No effect of AST/SLT on the failure rate was observed instead.

As far as complications are concerned, a transient hyphema proved to be the most commonly described adverse event (7/24 eyes in the CP group and 4/21 eyes in the HM group). The hyphema cleared completely over few days in

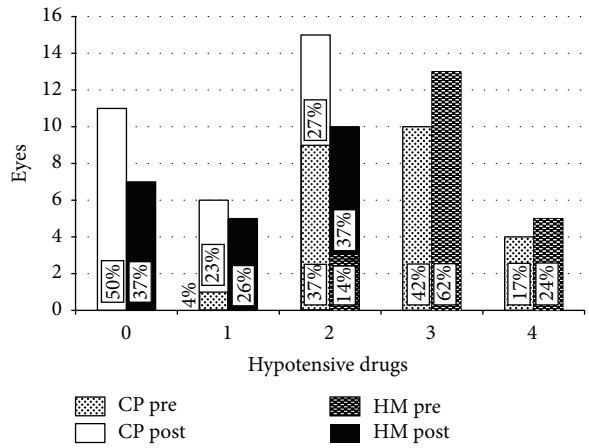

Figure 2: Distribution of eyes (eyes) referred to the number of required hypotensive medications (hypotensive drugs) in each treatment group, preoperatively and at the end of the 2-year follow-up. CP pre: preoperative distribution of eyes addressed to canaloplasty; CP post: distribution of eyes addressed to canaloplasty 24 months after surgery; HM pre: preoperative distribution of eyes addressed to Hydrus Microstent; HM post: distribution of eyes addressed to Hydrus Microstent 24 months after surgery.

Table 3: Distribution of eyes between the treatment groups according to a previous treatment (yes) by argon laser trabeculoplasty/selective laser trabeculoplasty (AST/SLT). Within brackets, the number eyes showing a complete clinical success (i.e., no medications) at the end of the follow-up.

Preoperative ALT/SLT	HM	CP	Total
Yes			
Count	10 (4)	14 (3)	24 (7)
No			
Count	11 (3)	10 (1)	21 (4)
Total			
Count	21 (7)	24 (4)	45 (11)

HM: Hydrus Microstent; CP: canaloplasty.

all the affected patients. An early postoperative IOP peak (≥30 mmHg within the first 48 hours) was recorded in 3 eyes in the CP group and in 1 eye after HM implantation. A YAG laser procedure was performed in 6 eyes in the CP group (goniopuncture) and in 4 eyes in the HM group (lysis of peripheral anterior synechiae) during follow-up.

4. Conclusion

An increasing interest in novel "blebless" antiglaucoma surgeries is documented worldwide. In particular, procedures aiming to restore the physiological outflow through the trabecular meshwork/SC complex are being developed. In the hereby presented study, we retrospectively compared the midterm clinical outcomes of CP, that is, an ab-externo approach to redilate the SC, versus an ab-interno procedure such as the implantation of a scaffold (HM).

Two years after surgery, both procedures were effective in decreasing IOP. The percentage of complete success in the CP group (50%) proved to be comparable with the 55% and 46% reported after a similar follow-up by Lewis and coworkers (2009) and Brusini (2014), respectively [13, 14]. Matlach and coworkers (2015) found a slightly lower rate of complete success (39%), but the two series are less directly comparable because of the lack of a cut-off IOP to define the postoperative success in our study [15]. Since the shortage of the so far published data, the results collected in our HM group cannot be valuably compared with prior series. A recent report showed the high rate of success (80%) of HM combined with cataract surgery [16]. If we had performed combined surgery, we would have probably achieved better results, too. However, since scaffolds aim to restore the outflow within the physiological range, the "midteens" IOP values observed postoperatively in our HM group are consistent with the expected mechanism of action of the procedure. Because of the retrospective nature of the study, no preset cut-off IOP values were planned. In fact, the target IOP was individually set by the surgeons according to what was suggested by the EGS guidelines for mild-to-moderate glaucoma damage with high starting IOP (i.e., a target IOP in the "mid-to-high teens").

Comparing the two treatment groups, in our study the efficacy profile of CP was statistically comparable to that of HM. Both procedures are theoretically endowed within similar mechanisms of action. Therefore, our results are not at all surprising. A slightly (albeit not significant) better trend for clinical success in the CP group could be inferred by a qualitative evaluation of data in Table 2 and Figure 2: two years after surgery, 50% of eyes treated by CP maintained the target IOP without medications; 57% of HM implanted eyes required any medical treatment to attain similar IOP. A greater sample size, together with a longer follow-up, could potentially offer statistical significance to this observation. Also the event "failure" (i.e., the need for further glaucoma surgery) occurred similarly in the two groups, either in terms of number of cases (two in each treatment group) or number of temporal latencies. However, since CP is not a conjunctival-sparing procedure, a further limbal filtration surgery, if needed, is likely to be less successful and technically compelling. Conversely, the clear cornea approach gives the HM procedure a less invasive profile in terms of surgical impact on the eye. In fact, when further surgery was needed in our study eyes, a tube was implanted after CP, meanwhile a plain nonpenetrating deep sclerectomy was successfully performed after HM.

Both procedures offered a comparable low complication rate in our study. In the literature, CP was widely associated with a low rate of side effects, mostly when compared to filtering surgery. Albeit more recent, also MIGS have been associated with a good safety profile in the short term to midterm [17].

In conclusion, our retrospective comparison showed that both CP and HM were safe and effective blebless procedures in early-to-mid stage open-angle glaucoma. However, along with the limited sample size and follow-up, its retrospective nature is a major point of weakness for the present study. This entailed the lack of preset: (a) randomization procedure, (b) cut-off values for target IOP, and (c) intermediate follow-up time points. The administration of a survey to evaluate quality of life, as proposed by Klink and coauthors in a quite similar setting, could represent a further improvement to the present findings [18].

What Was Known

(i) Glaucoma surgeries now include procedures aiming to restore the physiological outflow through the trabecular meshwork/SC complex. This latter in particular can be successfully redilated via either an ab-externo (the "canaloplasty") or an ab-interno (the "scaffolds") approach.

(ii) Outcomes of canaloplasty are quite well described and compared to other filtering techniques; much less is reported concerning scaffolds.

What This Paper Adds

Within the frame of this retrospective comparative study, one finds the following:

(i) two years after surgery, both CP and the HM were effective in decreasing IOP;

(ii) both procedures offered a low complication rate;

(iii) a slightly (albeit not significant) better trend for a "complete" clinical success for CP needs further confirmation.

Conflict of Interests

The authors declare that no conflicting relationship exists for any author.

References

[1] R. A. Lewis, K. von Wolff, M. Tetz et al., "Canaloplasty: circumferential viscodilation and tensioning of Schlemm canal using a flexible microcatheter for the treatment of open-angle glaucoma in adults: two-year interim clinical study results," *Journal of Cataract and Refractive Surgery*, vol. 35, no. 5, pp. 814–824, 2009.

[2] H. Saheb and I. I. K. Ahmed, "Micro-invasive glaucoma surgery: current perspectives and future directions," *Current Opinion in Ophthalmology*, vol. 23, no. 2, pp. 96–104, 2012.

[3] G.-Y. Ko, H.-Y. Song, T.-S. Seo, T.-H. Kim, K.-B. Sung, and H.-K. Yoon, "Obstruction of the lacrimal system: treatment with a covered, retrievable, expandable nitinol stent versus a lacrimal polyurethane stent," *Radiology*, vol. 227, no. 1, pp. 270–276, 2003.

[4] C. L. Hays, V. Gulati, S. Fan, T. W. Samuelson, I. I. K. Ahmed, and C. B. Toris, "Improvement in outflow facility by two novel microinvasive glaucoma surgery implants," *Investigative Ophthalmology and Visual Science*, vol. 55, no. 3, pp. 1893–1900, 2014.

[5] M. A. Johnstone, H. Saheb, I. I. K. Ahmed, T. W. Samuelson, A. T. Schieber, and C. B. Toris, "Effects of a Schlemm canal scaffold on collector channel ostia in human anterior segments," *Experimental Eye Research*, vol. 119, pp. 70–76, 2014.

[6] R. S. Ayyala, A. L. Chaudhry, C. B. Okogbaa, and D. Zurakowski, "Comparison of surgical outcomes between canaloplasty and trabeculectomy at 12 months' follow-up," *Ophthalmology*, vol. 118, no. 12, pp. 2427–2433, 2011.

[7] A. Brüggemann and M. Müller, "Trabeculectomy versus canaloplasty—utility and cost-effectiveness analysis," *Klinische Monatsblätter für Augenheilkunde*, vol. 229, no. 11, pp. 1118–1123, 2012.

[8] E. D. Schoenberg, A. L. Chaudhry, R. Chod, D. Zurakowski, and R. S. Ayyala, "Comparison of surgical outcomes between phacocanaloplasty and phacotrabeculectomy at 12 months' follow-up: a longitudinal cohort study," *Journal of Glaucoma*, vol. 24, no. 7, pp. 543–549, 2015.

[9] A. Brüggemann, J. T. Despouy, A. Wegent, and M. Müller, "Intraindividual comparison of canaloplasty versus trabeculectomy with mitomycin C in a single-surgeon series," *Journal of Glaucoma*, vol. 22, no. 7, pp. 577–583, 2013.

[10] European Glaucoma Society. EGS Guidelines, *Terminology and Guidelines for Glaucoma*, 3rd edition, 2015, http://www.eugs.org/eng/EGS_guidelines.asp.

[11] R. A. Lewis, K. von Wolff, M. Tetz et al., "Canaloplasty: three-year results of circumferential viscodilation and tensioning of Schlemm canal using a microcatheter to treat open-angle glaucoma," *Journal of Cataract and Refractive Surgery*, vol. 37, no. 4, pp. 682–690, 2011.

[12] B. Shingleton, M. Tetz, and N. Korber, "Circumferential viscodilation and tensioning of Schlemm canal (canaloplasty) with temporal clear corneal phacoemulsification cataract surgery for open-angle glaucoma and visually significant cataract: one-year results," *Journal of Cataract and Refractive Surgery*, vol. 34, no. 3, pp. 433–440, 2008.

[13] R. A. Lewis, K. von Wolff, M. Tetz et al., "Canaloplasty: circumferential viscodilation and tensioning of Schlemm canal using a flexible microcatheter for the treatment of open-angle glaucoma in adults. Two-year interim clinical study results," *Journal of Cataract & Refractive Surgery*, vol. 35, no. 5, pp. 814–824, 2009.

[14] P. Brusini, "Canaloplasty in open-angle glaucoma surgery: a four-year follow-up," *The Scientific World Journal*, vol. 2014, Article ID 469609, 7 pages, 2014.

[15] J. Matlach, C. Dhillon, J. Hain, G. Schlunck, F. Grehn, and T. Klink, "Trabeculectomy versus canaloplasty (TVC study) in the treatment of patients with open-angle glaucoma: a prospective randomized clinical trial," *Acta Ophthalmologica*, vol. 93, no. 8, pp. 753–761, 2015.

[16] N. Pfeiffer, J. Garcia-Feijoo, J. M. Martinez-de-la-Casa et al., "A randomized trial of a Schlemm's canal microstent with phacoemulsification for reducing intraocular pressure in open-angle glaucoma," *Ophthalmology*, vol. 122, no. 7, pp. 1283–1293, 2015.

[17] L. M. Brandão and M. C. Grieshaber, "Update on minimally invasive glaucoma surgery (MIGS) and new implants," *Journal of Ophthalmology*, vol. 2013, Article ID 705915, 12 pages, 2013.

[18] T. Klink, J. Sauer, N. J. Körber et al., "Quality of life following glaucoma surgery: canaloplasty versus trabeculectomy," *Clinical Ophthalmology*, vol. 9, pp. 7–16, 2014.

Hindawi Publishing Corporation
Journal of Ophthalmology
Volume 2016, Article ID 2401976, 8 pages
http://dx.doi.org/10.1155/2016/2401976

Research Article

Influence of Endothelin-1 in Aqueous Humor on Intermediate-Term Trabeculectomy Outcomes

Lars Choritz,[1] Benjamin Mahmoodi,[2] and Hagen Thieme[1]

[1] *University Hospital Magdeburg, Department of Ophthalmology, Otto-von-Guericke University, Leipziger Strasse 44, 39120 Magdeburg, Germany*
[2] *University Medical Center Mainz, Department of Ophthalmology, Johannes Gutenberg University, Langenbeckstrasse 1, 55131 Mainz, Germany*

Correspondence should be addressed to Lars Choritz; lars.choritz@med.ovgu.de

Received 16 November 2015; Revised 15 December 2015; Accepted 21 December 2015

Academic Editor: Michele Figus

Purpose. To investigate whether increased concentrations of ET-1 in aqueous humor of glaucoma patients influences surgical outcome of standard trabeculectomy with Mitomycin C. *Methods*. Retrospective chart review of 36 glaucoma patients with known ET-1 concentrations who had undergone trabeculectomy with Mitomycin C. Patients were divided into two groups based on their aqueous ET-1 concentration, a below-median (low ET-1) and an above-median (high ET-1) group. Postoperative IOP development, necessity of glaucoma medication, surgical success and complications, postoperative use of antifibrotics (5-FU), and number of additional glaucoma surgeries were compared between the groups. *Results*. Overall surgical success of trabeculectomy was comparable to published literature (90%, 81%, 76%, and 68% absolute success at 12, 24, 36, and 48 months after surgery). There was no difference between high and low ET-1 group in the postsurgical development of IOP, surgical success rate, or complication rate. There was no difference in postoperative scarring or indirect indicators thereof (e.g., number of 5-FU injections, needlings, suture lyses, or IOP lowering medications). *Conclusion*. In this set of patients, ET-1 in aqueous humor does not appear to have influenced surgical outcome of trabeculectomy with Mitomycin C. There is no indication of an increased likelihood of bleb fibrosis in patients with increased ET-1 concentrations.

1. Introduction

Endothelin-1 (ET-1), one of the most potent vasoconstrictors known, has been shown to be produced in the eye by the ciliary epithelium and to be released into the aqueous humor [1, 2]. The two endothelin receptors (ETAR and ETBR) are expressed by various ocular tissues, including ciliary and iris muscles, trabecular meshwork, cornea, vasculature, and astrocytes in the optic nerve head [3–6]. Despite this apparent ubiquity of endothelin signaling, the peptide's physiological role in the eye is poorly understood.

ET-1 has also been implicated in the pathophysiology of glaucoma. Several studies showed increased concentrations of ET-1 in the aqueous humor of patients with different forms of glaucoma and pleiotropic effects of the peptide on various ocular tissues. Consequently, ET-1 antagonists have been suggested as therapeutic principle for glaucoma [7].

In the anterior segment, ET-1 is believed to be involved in the regulation of intraocular pressure (IOP) via effects on the contractility of ciliary muscle and trabecular meshwork. Pharmacological studies on native bovine trabecular meshwork suggest that an increased contractility of the trabecular meshwork with subsequent reduction of intertrabecular spaces leads to increased outflow resistance and IOP [8, 9]. Evidence is inconclusive, however, as injection of ET-1 into intact eyes caused both increases and decreases of IOP depending on ET-1 concentration and animal species. In rabbits, for instance, injection of ET-1 into the anterior chamber caused a biphasic response: an initial increase in IOP for up to 2 hours, followed by a sustained decrease in IOP for up to 72 hours [10]. These differential effects are most likely related to differential actions of the two ET receptors, as ET-AR antagonists effectively abolished IOP increase but not IOP decrease [11], while ET-BR agonists caused only IOP decrease

without prior IOP increase [12]. Interestingly, damage to the trabecular meshwork of rabbits induced by Argon Laser Trabeculoplasty (ALT) leads to a transient increase in ET-1, followed by an increase in IOP that could be inhibited by an ET-AR antagonist as well [13, 14]. A similar IOP spike is often seen in humans after ALT [15] and might also be caused by ET-1 release [13], which is why only patients with no prior ocular surgery or trauma were included in the initial study [16].

More recently, Wang et al. showed that topical administration of a nonpeptide ETAR-antagonist (SPP 301) caused sustained, dose dependent IOP reductions in glaucomatous monkey eyes, giving creed to the notion of a regulatory role for ET-1 in IOP control [17].

In humans, evidence for contractility of the trabecular meshwork (TM) is scarce and indirect. Presence and functionality of a smooth muscle-like contractile apparatus have been shown by histological and molecular biological methods [18]. Pharmacologically induced contraction (e.g., by ET-1) of cultured human TM cells embedded in collagen gels implies that TM contractility may contribute to the physiological regulation of IOP [19, 20]. However, direct contraction of native human TM in response to ET-1 has yet to be shown. Moreover, despite the early finding of increased ET-1 in aqueous samples of glaucoma patients, a statistically significant correlation between ET-1 in aqueous and IOP just prior to sample acquisition was established only recently [16]. Much work is needed, to fully understand the complex actions of ET-1 in the eye in general, and its role in regulating IOP in particular.

ET-1 has also been shown to contribute to fibrosis and fibrotic disorders in various organ systems, including lung, skin, liver, kidney, heart, and vasculature. Several studies have shown ET-1 to facilitate transdifferentiation of resident fibroblasts as well as epithelial/endothelial cells, hepatic stellate cells, or monocytes into myofibroblasts, a predominant cell type in fibrotic disorders (for review see [21]). Since failure to control IOP after trabeculectomy is most often the result of excessive scarring, understanding the underlying mechanisms of bleb fibrosis is of major interest for the further improvement of success rates of filtering surgery. So far ET-1 has not been studied as a potential modulator of wound healing after glaucoma surgery.

The aim of this retrospective chart review therefore was to investigate whether increased concentrations of ET-1 in the aqueous samples of glaucoma patients influenced wound healing and bleb fibrosis after standard trabeculectomy with MMC. Secondly, postsurgical IOP development was assessed in order to elucidate whether bypassing the trabecular meshwork offsets the previously observed correlation between ET-1 and IOP.

2. Methods

2.1. Study Design/Patient Selection. This investigation was conducted as retrospective chart review of 36 patients who had previously been enrolled in a study to determine whether there was a correlation between ET-1 in aqueous humor and IOP. In this previous study aqueous humor samples from a total of 94 patients with either cataract (control), primary open angle glaucoma (POAG), or pseudoexfoliation glaucoma (PEXG) were collected during routine cataract surgery or trabeculectomy. ET-1 concentrations in the samples were determined by a subtype-specific ELISA and correlated with the last presurgical IOP (as determined by Goldman applanation tonometry). Written consent was obtained. Approval by the local ethics committee was granted (App. number 837.198.06 [5296]), and all tenets of the Declaration of Helsinki were observed.

Patient selection for the previous study was very rigid. In order to avoid any confounding conditions, all patients with ophthalmological disorders other than cataract, POAG, or PEXG were excluded. All eyes were naïve to any surgical intervention. Furthermore, all systemic conditions that are known to be associated with systemic changes to ET-1 concentration (e.g., cardiovascular diseases, diabetes mellitus, pulmonary diseases, and solid tumors) were also excluded. Thus, the patients included did not comprise a typical sample of the glaucoma or cataract population, with regard to typical comorbidity with other age-related diseases. For details on the patient selection and its rationale, see [16].

Of the 94 patients with known ET-1 concentrations in aqueous humor from the previous study, 56 were glaucoma patients. Of these, hospital records for at least three follow-up visits after initial discharge were on file for 53 patients. For the purpose of this investigation we chose all 36 records of the patients, who had undergone trabeculectomy during the initial study (25 POAG, 11 PEXG). Aqueous samples of the remaining 17 glaucoma patients were obtained during cataract surgery in the initial trial.

These 36 patients were divided into two groups based on their previously determined ET-1 aqueous concentration into an above-median (high ET-1, $n = 18$) and a below-median (low ET-1, $n = 18$) group. For subgroup analysis, both POAG and PEXG patients were subdivided by the same principle.

Importantly, the ophthalmologists performing follow-up visits were masked to the ET-1 concentrations obtained during the initial trial. Examination results and clinical decisions were therefore not biased.

2.2. Criteria for Surgical Success. Based on AGIS criteria and WGA guidelines for designing and reporting surgical success in glaucoma trials trabeculectomy was considered an "absolute success," if IOP was below 18 mmHg and IOP reduction >20% at all postsurgical follow-up visits without additional medication or the need for further surgical intervention. Patients requiring adjunct pressure lowering medication to reach 18 mmHg or who needed early revision surgery for complications were considered "relative success." Patients, whose IOP was not below 18 mmHg during one or more follow-up visits, or who needed late bleb revision due to fibrosis or additional pressure lowering surgery, were considered as "failure."

2.3. Statistical Analysis. All data are presented as mean ± standard deviation, unless indicated otherwise. All statistical analyses were performed using PASW (SPSS version 18) software (SPSS Inc.) or GraphPad Prism (Version 5,

Table 1: Patient characteristics.

	All patients	POAG	PEXG	Uncorrected p values
Number included	36	25	11	
Age (years)	63.3 (±11.9)	62.2 (±13.9)	65.9 (±4.8)	$p = 0.396$
Gender (m/f)	17/20	13/12	3/8	$p = 0.277$
Study eye (OD/OS)	13/23	11/14	2/9	$p = 0.259$
Last IOP before surgery (mmHg)	27.5 (±8.5)	25.2 (±5.8)	32.6 (±11.3)	**$p = 0.013$**
Number of medications	2.8 (±0.9)	2.9 (±0.8)	2.5 (±1.1)	$p = 0.199$
ET-1 in aqueous humor (pg/mL)	6.5 (±2.8)	5.9 (±2.9)	7.8 (±1.9)	$p = 0.062$

GraphPad software Inc.). Since the sample size in this study was relatively small and the investigation was exploratory in nature, no correction for multiple testing was employed. p values for group comparisons were calculated only as means of identifying potential parameters of interest for future confirmatory studies.

3. Results

3.1. Patient Characteristics before Surgery. Of the 36 patients investigated for this study, 25 had undergone trabeculectomy for POAG and 11 patients had PEXG. There was no difference with regard to age, gender, study eye, number of glaucoma medications, or follow-up time between these patients. The overall characteristics of the study patients as well as their last IOP before surgery (as measured by Goldmann applanation tonometry) and the ET-1 concentration in the aqueous samples collected during surgery are displayed in Table 1. As shown in the previous study, from which these patients were selected, there was a significantly higher IOP and a higher ET-1 concentration in aqueous in the PEXG group.

Based on their known ET-1 concentrations, all patients were divided into an above-median (high ET-1) and a below-median (low ET-1) group. As displayed in Table 2, the two groups showed no relevant differences apart from ET-1 concentration (the selection criterion) and IOP, the latter of which was to be expected based on the correlation between ET-1 and IOP that was found in the previous study. Notably more of the PEXG patients were in the high ET-1 group; this difference was not significant, however, and also to be expected based on the higher mean ET-1 concentration in this group.

3.2. IOP Development after Surgery. IOP was well controlled in almost all patients after surgery. There was no difference between IOP development between patients with high and those with low ET-1 concentrations in aqueous, both in the immediate follow-up period (up to ten days after surgery, Figure 1) and up to 24 months after surgery (Figure 2). Similarly, there was no difference between POAG and PEXG patients. The difference in IOP before surgery was quickly abolished after surgery and low pressure was maintained during long-term follow-up (data not shown).

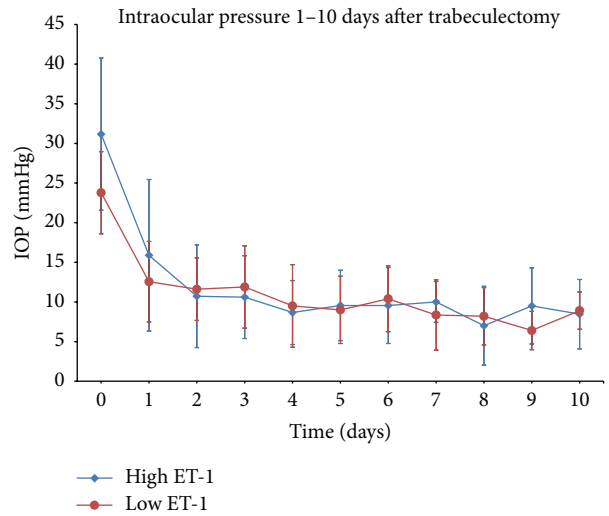

Figure 1: Mean intraocular pressure before and after trabeculectomy. The initial statistically significant difference in IOP, which is likely linked to the difference in ET-1 concentration, is quickly abolished after surgery. There is no difference in IOP after trabeculectomy.

3.3. Adjunct Medication and Interventions. At final follow-up visit on record, there was no difference in the average number of glaucoma medications needed to maintain a sufficiently low IOP. The high ET-1 group required 0.18±0.71 medications versus 0.22 ± 0.55 medications in the low ET-1 group (p = 0.794, Figure 3). All of the additional medications were used in POAG patients (0.3 ± 0.7), whereas the PEXG patients required none. This difference was not statistically significant (p = 0.220).

The number of postsurgical interventions was similar between patients with high and low ET-1 concentrations. The high ET-1 group required 5.5 ± 3.7 5-FU injections, 0.9 ± 1.1 suture lyses, and 0.2 ± 0.7 needlings, whereas the low ET-1 group had 5.1 ± 3.1 5-FU injections, 0.7 ± 0.9 suture lyses, and 0.1 ± 0.5 needlings (p = 0.736, p = 0.513, and p = 0.592, resp.; Figure 3). Comparison between POAG and PEXG showed a similar picture with 5.6 ± 3.7 versus 4.6 ± 2.6 5-FU injections (p = 0.440). More suture lyses to titrate IOP (1.1 ± 1.1 versus

Table 2: General characteristics of study groups.

	High ET-1	Low ET-1	
ET-1 in aqueous humor (pg/mL)	8.7 (±2.1)	4.4 (±1.5)	
Last IOP before surgery (mmHg)	31.2 (±9.6)	23.8 (±5.2)	**p = 0.007**
Age (years)	63.4 (±12.7)	63.3 (±11.4)	$p = 0.996$
Gender (m/f)	11/7	5/13	$p = 0.092$
Study eye (OD/OS)	3/15	10/8	$p = 0.035$
Number of medications	2.8 (±1.0)	2.7 (±0.8)	$p = 0.857$
Diagnosis (POAG/PEXG)	10/8	15/3	$p = 0.146$
Follow-up (months)	30.8 (±19.9)	27.8 (±21.4)	$p = 0.661$

Table 3: Complications.

Complication	High ET-1	Low ET-1
Corneal erosion	2	2
Iris prolapse	1	0
Hypotony	1	0
Choroidal detachment	0	1
Fibrosis of sclera flap	0	1
Bleb fibrosis	1	0

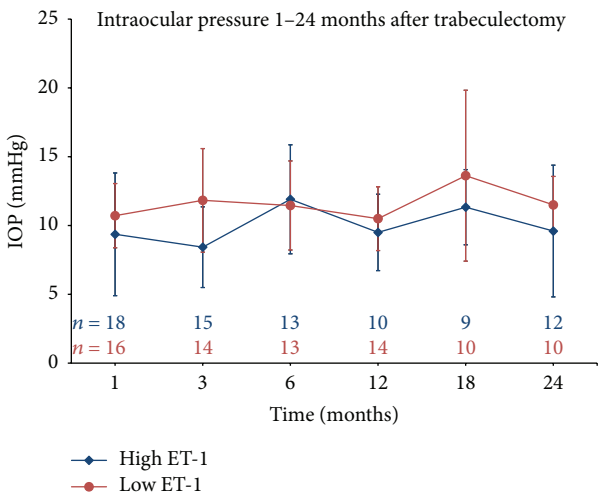

Figure 2: Long-term development of IOP up to 24 months after surgery. There is no significant difference between the groups.

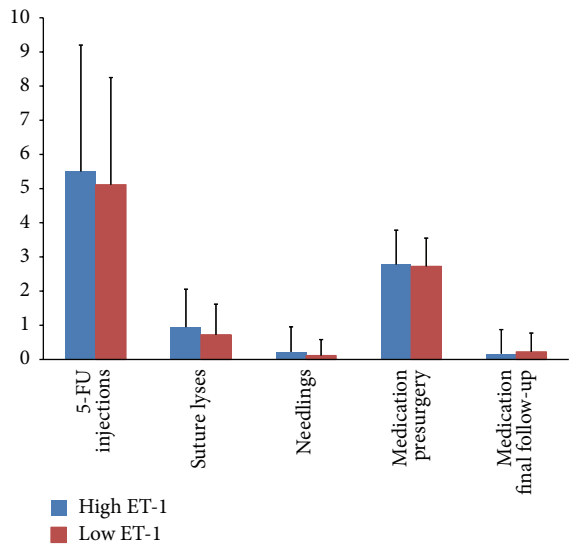

Figure 3: Comparison of different parameters indirectly indicative of fibrosis or failure to control IOP at the last follow-up visit. There is no difference between the high ET-1 group (blue bars) and the low ET-1 group (red bars) for any of the recorded parameters.

0.3 ± 0.5, $p = 0.023$) and less needlings (0.1 ± 0.4 versus 0.4 ± 0.9, $p = 0.203$) were required in the POAG group than in the PEXG group.

3.4. Complications. The number and type of complications during and after surgery are displayed in Table 3. Most of the early complications resolved spontaneously; the one case of iris prolapse required revision surgery to reposition the iris. Both cases of late complications (bleb fibrosis and scarring of the sclera flap) required surgical revision and were considered surgical "failure" based on the definitions given above. There was no relevant difference in complication rate or severity between the high and low ET-1 groups.

3.5. Surgical Success Rates. Absolute success, defined as IOP < 18 mmHg without additional medication or further surgical intervention, was achieved for 90%, 81%, 76%, and 68% at 12, 24, 36, and 48 months after surgery. Including relative success, with additional medication to maintain IOP below 18 mmHg or revision surgery due to complications, but not additional pressure lowering surgery, success rates were 93% at 12 months and remained at 89% for the entire follow-up time thereafter. There was no difference in surgical success between patients with high and those with low ET-1 concentrations in aqueous humor ($p = 0.715$ for absolute success and $p = 0.953$ for relative success, log-rank (Mantel-Cox) test; Figure 4) nor between POAG and PEX glaucoma (8% versus 9.1% failure rate, data not shown).

4. Discussion

Endothelin-1 has repeatedly been shown to be increased in different forms of open angle glaucoma [22–24]. While still controversially discussed, there is accumulating evidence for

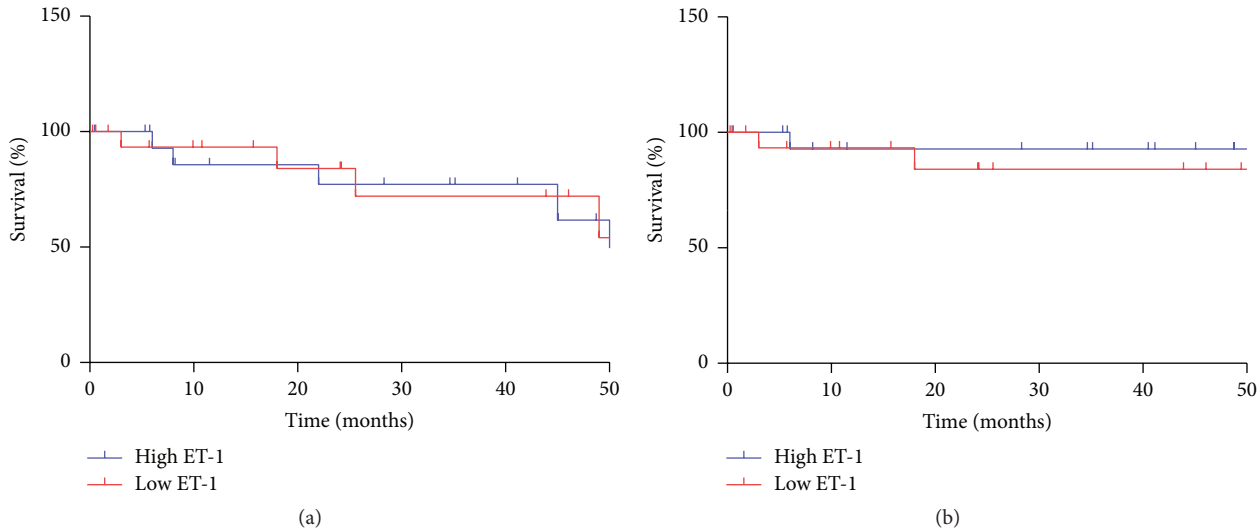

Figure 4: Absolute success rate (a) and survival including relative success (b) over time. Ticks indicate censored data (final follow-up visits to our clinic). There is no difference in overall success of trabeculectomy between patients with high (blue) and low (red) ET-1 concentration in aqueous humor. Both groups have comparable, very good long-term outcomes of surgery.

a physiological and/or pathophysiological role of the peptide in the regulation of IOP via effects on the contractility of ciliary muscle and trabecular meshwork. Evidence from animal models suggests that increases in ET-1 concentration may contribute to increases in IOP by eliciting a smooth muscle like contraction of the trabecular meshwork and thereby raising outflow resistance through the tissue [8, 9]. For human tissue, no direct observation of native trabecular meshwork contractility has been published yet, but experimental evidence with cultured human TM cells suggests that the proposed mechanism may be relevant to IOP regulation in glaucoma patients [19, 20]. Interfering with ET-1 signaling has therefore been proposed as a potential means of lowering IOP pharmacologically [7, 17].

In a recent study by our group, a statistically highly significant, albeit numerically small, correlation was shown between IOP and ET-1 in aqueous humor of glaucoma and cataract patients [16]. While this study did not allow establishing a causative relationship between the two parameters, an influence of ET-1 on IOP regulation via effects on the contractile state of the TM appears plausible. Assuming this mechanism is correct, bypassing the TM surgically, that is, by trabeculectomy, should in theory abolish, or at least diminish, the association between ET-1 in aqueous humor and IOP.

Our analysis of the postoperative IOP development of patients with known ET-1 concentrations shows this expected loss of association very well: while before surgery there was a significant difference in IOP between a patient group with high and a group with low ET-1 concentrations, no difference in IOP was observed at any point after surgery (Figures 1 and 2). Similarly, when comparing POAG patients with PEXG patients, who had higher ET-1 concentrations and higher IOP before surgery, there was no difference in IOP after surgery. These observations might therefore be indirect evidence for the proposed effect of ET-1 on human TM contractility and IOP regulation.

Since the major site of outflow resistance, the TM, is bypassed by trabeculectomy, the resulting long-term IOP is mainly determined by the amount of aqueous being resorbed by the conjunctival bleb that forms after surgery. Careful maintenance of a wide, thin-walled, hypovascular filtering bleb is therefore one of the major goals of postoperative care [25].

Failure to control IOP after trabeculectomy is most often the result of excessive scarring of the conjunctival wound. The drained aqueous fluid has been shown to contain various profibrotic growth factors, exposure to which leads to thick, fibrotic tissue with limited capacity for aqueous resorption [26, 27]. Bleb fibrosis was a common occurrence in the early days of trabeculectomy; this limitation has in recent years been partially overcome by the use of antifibrotics like Mitomycin C (MMC) during surgery and 5-fluorouracil (5-FU) during the early postsurgical phase. Both substances have greatly improved the surgical outcome of trabeculectomy [28, 29]. However, long-term results still show a cumulative failure rate of TE of up to 10% per year [30–32]. Moreover, MMC and 5-FU are associated with a number of unwanted side effects due to the fact that their mechanisms of action are not limited to the scarring tissue but affect the corneal epithelium, limbal, and conjunctival stem cells as well [33, 34]. There is a great need to better understand the scarring process in order to target it more specifically and with fewer side effects.

Likely the most important growth factor involved in bleb fibrosis is transforming growth factor beta 2 (TGF-β_2), which has been shown to be the major isoform in aqueous humor, and which is found in increased concentrations in the aqueous humor of patients with bleb fibrosis. However, not all patients with fibrotic blebs also have high concentrations of TGF-β_2 [26, 35]. Other growth factors must also contribute to the scarring process.

ET-1 has been shown to be involved in fibrosis in various organ systems. It is a major pharmaceutical target in primary

pulmonary hypertension as well as systemic sclerosis [36]. It has also been shown to contribute to fibrosis in the heart, liver, and kidney. In particular, ET-1 can facilitate the induction of a myofibroblast phenotype in various "precursor" cells, like fibroblasts, stellate cells of the liver, pericytes, monocytes, and epithelial/endothelial cells [21]. Moreover, ET-1 can work both in conjunction with and as a downstream effector of TGF-β [37, 38].

While the effects of ET-1 on conjunctival or Tenon's fibroblasts have never been investigated *in vitro* or *in vivo*, it appears reasonable to assume that similar mechanisms as described in various other tissues could also be found in the eye. In fibrotic filtering blebs after trabeculectomy as well as in the hypertrophic capsules surrounding failed glaucoma drainage devices myofibroblasts are the major cell type contributing to the deposition of collagen and fibronectin, two of the main constituents of fibrotic tissue [27, 39]. Moreover, it has been shown that contractility facilitated through Rho-kinase (ROCK) dependent mechanisms is a prerequisite for myofibroblast transdifferentiation in Tenon's fibroblasts and that inhibiting ROCK by specific inhibitors as well as statins prevents this change of phenotype [40, 41]. Since ET-1 has also been shown to act through ROCK in other ocular tissues, increased concentrations of the peptide in aqueous may well contribute to postoperative scarring of filtering blebs [18, 42, 43]. Our chart review therefore also aimed to assess bleb fibrosis or precursors thereof in relation to ET-1 concentrations.

Our results show no indication for an increased tendency for fibrosis in the high ET-1 group. There were only two patients with clear signs of fibrosis: one scarred bleb in the low ET-1 group and one scarred scleral flap in the high ET-1 group, which was deemed to be an "unusual finding" according to the surgeon.

In our study, all patients received the same amount of MMC (0.1 mL at 0.2 mg/mL for 5 minutes) during surgery. Therefore scarring was less likely to occur. Differences in fibrotic propensity might have shown indirectly, however, for example, in the number of 5-FU injections needed in the immediate aftermath of trabeculectomy. Application of 5-FU is typically used based on clinical signs of inflammation and impending early bleb fibrosis like hyperemia of the conjunctiva above the bleb and "cork screw vessels." Our data, however, show no difference in the use of 5-FU between the groups. Similarly, there was no difference in the average number of suture lyses needed to titrate IOP to desirable levels nor in the number of needlings required to detach the bleb walls from the sclera (Figure 3).

Another indirect measure for the onset of fibrosis might be the need for additional glaucoma medication in order to control IOP. As scarring progresses the amount of aqueous resorbed through the bleb walls drops, making the need for other means of controlling IOP more likely. In our study there was no difference in the number and timing of new glaucoma medications.

There are a number of limitations to our study, like its retrospective design, or the rigid selection criteria. The latter were necessary for the initial study in order to avoid any interference from systemic disorders with increased ET-1 concentrations in blood plasma. Such diseases might have masked the hypothesised correlation between ET-1 in aqueous and IOP. We therefore only included patients that were in excellent health. Patients had no potentially confounding systemic disorders (e.g., cardiovascular and vasospastic disorders, diabetes mellitus, pulmonary diseases, or solid tumors). Similarly, because manipulation of the eye might affect intraocular ET-1 concentrations, only patients without any other ophthalmological diseases, prior ocular surgery, or trauma were included (for further information see [16]). Our patients are therefore not a representative sample of glaucoma patients, who are typically afflicted with one or more of the diseases mentioned above. While this selectivity was quite necessary for the previous study, the results of this retrospective investigation may suffer from a selection bias and can therefore not be generalized.

On the other hand, our general results like age of the included patients, overall success rate, long-term IOP control, and use of additional medication are in good agreement with larger, more representative study populations. The Advanced Glaucoma Intervention Study (AGIS) and the Collaborative Initial Glaucoma Treatment Study (CIGTS), for instance, had similar baseline characteristics: 67.0 and 58.1 years of age versus 63.3 in our study; presurgical IOP of 25.5 and 27.4 mmHg versus 27.5 mmHg, respectively; presurgical number of medications of 2.7 in the AGIS versus 2.8 in our study [44, 45].

The sample size may also affect interpretation of the results. With only 18 patients per group, our study is greatly underpowered to detect small differences. Also, due to its retrospective nature not all patients were present for all selected time points of analysis. However, since the outcome in both groups are almost identical with regard to number of adjunct medications, 5-FU injections, suture lyses, and needlings, the required sample size to determine a significant difference would have been excessively large. Moreover, such small differences would most likely not be clinically relevant.

More importantly, nothing is currently known about the dynamics of ET-1 concentrations in aqueous humor. We only determined ET-1 levels once, in samples collected during the initial surgery. One cannot safely assume that ET-1 concentrations remain static or that they are unaffected by ocular or systemic conditions or medication. They might even have been altered by the surgery itself. Since we only included otherwise healthy subjects, systemic effects on ET-1 should have been minimal (as shown by the lack of difference in systemic ET-1 levels between groups). Yet, we cannot rule out that ET-1 levels in aqueous humor are highly dynamic and the single sample is not representative of long-term ET-1 concentrations. Since it is difficult to sample aqueous humor on a regular basis, we have to contend with this limitation.

In conclusion, our results demonstrate that a potential regulatory role of ET-1 on IOP through actions on the trabecular meshwork is effectively abolished by shunting this tissue. In our small sample of otherwise healthy glaucoma patients, increased concentrations of Endothelin-1 in the aqueous humor did not influence the surgical outcome of standard trabeculectomy with MMC during up to four years of follow-up. This does not preclude a long-term effect of

very high concentrations in aqueous humor or of systemically increased ET-1 on wound healing and bleb fibrosis. Further laboratory studies on the interactions of ET-1 with conjunctival and Tenon's fibroblasts as well as prospective clinical studies with larger, more representative patient groups may be useful to elucidate potential effects of ET-1 on trabeculectomy outcome.

Conflict of Interests

None of the authors declare any financial or nonfinancial interests in subject matter or materials discussed in this paper.

References

[1] M. Eichhorn and E. Lütjen-Drecoll, "Distribution of endothelin-like immunoreactivity in the human ciliary epithelium," *Current Eye Research*, vol. 12, no. 8, pp. 753–757, 1993.

[2] A. Lepple-Wienhues, M. Becker, F. Stahl et al., "Endothelin-like immunoreactivity in the aqueous humour and in conditioned medium from cultured ciliary epithelial cells," *Current Eye Research*, vol. 11, no. 11, pp. 1041–1046, 1992.

[3] V. R. Rao, R. R. Krishnamoorthy, and T. Yorio, "Endothelin-1 mediated regulation of extracellular matrix collagens in cells of human lamina cribrosa," *Experimental Eye Research*, vol. 86, no. 6, pp. 886–894, 2008.

[4] A. W. Stitt, U. Chakravarthy, T. A. Gardiner, and D. B. Archer, "Endothelin-like immunoreactivity and receptor binding in the choroid and retina," *Current Eye Research*, vol. 15, no. 1, pp. 111–117, 1996.

[5] X. Wang, T. L. LeVatte, M. L. Archibald, and B. C. Chauhan, "Increase in endothelin B receptor expression in optic nerve astrocytes in endothelin-1 induced chronic experimental optic neuropathy," *Experimental Eye Research*, vol. 88, no. 3, pp. 378–385, 2009.

[6] N. N. Osborne, N. L. Barnett, and W. Luttmann, "Endothelin receptors in the cornea, iris and ciliary processes. Evidence from binding, secondary messenger and PCR studies," *Experimental Eye Research*, vol. 56, no. 6, pp. 721–728, 1993.

[7] R. Rosenthal and M. Fromm, "Endothelin antagonism as an active principle for glaucoma therapy," *British Journal of Pharmacology*, vol. 162, no. 4, pp. 806–816, 2011.

[8] M. Wiederholt, H. Thieme, and F. Stumpff, "The regulation of trabecular meshwork and ciliary muscle contractility," *Progress in Retinal and Eye Research*, vol. 19, no. 3, pp. 271–295, 2000.

[9] L. Choritz, R. Rosenthal, M. Fromm, M. H. Foerster, and H. Thieme, "Pharmacological and functional characterization of endothelin receptors in bovine trabecular meshwork and ciliary muscle," *Ophthalmic Research*, vol. 37, no. 4, pp. 179–187, 2005.

[10] T. Taniguchi, K. Okada, M. S. R. Haque, K. Sugiyama, and Y. Kitazawa, "Effects of endothelin-1 on intraocular pressure and aqueous humor dynamics in the rabbit eye," *Current Eye Research*, vol. 13, no. 6, pp. 461–464, 1994.

[11] M. S. R. Haque, K. Sugiyama, T. Taniguchi, and Y. Kitazawa, "Effects of BQ-123, an ETA recepter-selective antagonist, on changes of intraocular pressure, blood-aqueous barrier and aqueous prostaglandin concentrations caused by endothelin-1 in rabbit," *Japanese Journal of Ophthalmology*, vol. 40, no. 1, pp. 26–32, 1996.

[12] M. S. R. Haque, K. Sugiyama, T. Taniguchi, K. Okada, Y. Nakai, and Y. Kitazawa, "The effects of ET(B) receptor-selective agonist on IOP and blood-aqueous barrier in rabbit eyes: role of cyclooxygenase products," *Japanese Journal of Ophthalmology*, vol. 39, no. 4, pp. 360–367, 1995.

[13] G. Holló, P. Lakatos, and P. Vargha, "Immediate increase in aqueous humour endothelin 1 concentration and intra-ocular pressure after argon laser trabeculoplasty in the rabbit," *Ophthalmologica*, vol. 214, no. 4, pp. 292–295, 2000.

[14] G. Holló, P. Kóthy, P. Lakatos, and P. Vargha, "Endothelin-A receptor antagonist BQ-485 protects against intraocular pressure spike induced by laser trabeculoplasty in the rabbit," *Ophthalmologica*, vol. 216, no. 6, pp. 459–462, 2002.

[15] "The Glaucoma Laser Trial. I. Acute effects of argon laser trabeculoplasty on intraocular pressure," *Archives of Ophthalmology*, vol. 107, no. 8, pp. 1135–1142, 1989.

[16] L. Choritz, M. Machert, and H. Thieme, "Correlation of endothelin-1 concentration in aqueous humor with intraocular pressure in primary open angle and pseudoexfoliation glaucoma," *Investigative Ophthalmology and Visual Science*, vol. 53, no. 11, pp. 7336–7342, 2012.

[17] R.-F. Wang, S. M. Podos, J. B. Serle, and O. C. Baltatu, "Effect of SPP 301, an endothelin antagonist, on intraocular pressure in glaucomatous monkey eyes," *Current Eye Research*, vol. 36, no. 1, pp. 41–46, 2011.

[18] R. Rosenthal, L. Choritz, S. Schlott et al., "Effects of ML-7 and Y-27632 on carbachol- and endothelin-1-induced contraction of bovine trabecular meshwork," *Experimental Eye Research*, vol. 80, no. 6, pp. 837–845, 2005.

[19] M. Cellini, P. Versura, D. Trerè, and E. C. Campos, "Effects of endothelin-1 on human trabecular meshwork cell contraction: an in vitro cell culture model," *Ophthalmic Research*, vol. 37, no. 1, pp. 43–49, 2005.

[20] W. M. Dismuke, J. Liang, D. R. Overby, and W. D. Stamer, "Concentration-related effects of nitric oxide and endothelin-1 on human trabecular meshwork cell contractility," *Experimental Eye Research*, vol. 120, pp. 28–35, 2014.

[21] F. Rodríguez-Pascual, O. Busnadiego, and J. González-Santamaría, "The profibrotic role of endothelin-1: is the door still open for the treatment of fibrotic diseases?" *Life Sciences*, vol. 118, no. 2, pp. 156–164, 2014.

[22] W. Noske, J. Hensen, and M. Wiederholt, "Endothelin-like immunoreactivity in aqueous humor of patients with primary open-angle glaucoma and cataract," *Graefe's Archive for Clinical and Experimental Ophthalmology*, vol. 235, no. 9, pp. 551–552, 1997.

[23] A. A. Ghanem, A. M. Elewa, and L. F. Arafa, "Endothelin-1 and nitric oxide levels in patients with glaucoma," *Ophthalmic Research*, vol. 46, no. 2, pp. 98–102, 2011.

[24] G. G. Koliakos, A. G. P. Konstas, U. Schlötzer-Schrehardt et al., "Endothelin-1 concentration is increased in the aqueous humour of patients with exfoliation syndrome," *British Journal of Ophthalmology*, vol. 88, no. 4, pp. 523–527, 2004.

[25] D. Marquardt, W. E. Lieb, and F. Grehn, "Intensified postoperative care versus conventional follow-up: a retrospective long-term analysis of 177 trabeculectomies," *Graefe's Archive for Clinical and Experimental Ophthalmology*, vol. 242, no. 2, pp. 106–113, 2004.

[26] C. Picht, U. Welge-Luessen, F. Grehn, and E. Lütjen-Drecoll, "Transforming growth factor $\beta 2$ levels in the aqueous humor in different types of glaucoma and the relation to filtering bleb development," *Graefe's Archive for Clinical and Experimental Ophthalmology*, vol. 239, no. 3, pp. 199–207, 2001.

[27] T. Meyer-ter-Vehn, F. Grehn, and G. Schlunck, "Localization of TGF-β type II receptor and ED-A fibronectin in normal conjunctiva and failed filtering blebs," *Molecular Vision*, vol. 14, pp. 136–141, 2008.

[28] M. Wilkins, A. Indar, and R. Wormald, "Intraoperative mitomycin C for glaucoma surgery," *Cochrane Database of Systematic Reviews*, no. 4, Article ID CD002897, 2005.

[29] A. M. Palanca-Capistrano, J. Hall, L. B. Cantor, L. Morgan, J. Hoop, and D. WuDunn, "Long-term outcomes of intraoperative 5-fluorouracil versus intraoperative mitomycin C in primary trabeculectomy surgery," *Ophthalmology*, vol. 116, no. 2, pp. 185–190, 2009.

[30] H. J. M. Beckers, K. C. Kinders, and C. A. B. Webers, "Five-year results of trabeculectomy with mitomycin C," *Graefe's Archive for Clinical and Experimental Ophthalmology*, vol. 241, no. 2, pp. 106–110, 2003.

[31] A. Reibaldi, M. G. Uva, and A. Longo, "Nine-year follow-up of trabeculectomy with or without low-dosage mitomycin-c in primary open-angle glaucoma," *British Journal of Ophthalmology*, vol. 92, no. 12, pp. 1666–1670, 2008.

[32] H. Fontana, K. Nouri-Mahdavi, J. Lumba, M. Ralli, and J. Caprioli, "Trabeculectomy with mitomycin C. Outcomes and risk factors for failure in phakic open-angle glaucoma," *Ophthalmology*, vol. 113, no. 6, pp. 930–936, 2006.

[33] C. Reiter, S. Wimmer, A. Schultheiß, T. Klink, F. Grehn, and G. Geerling, "Korneale epitheliopathie nach trabekulektomie mit postoperativer subkonjunktivaler 5-fluorouracil-injektion," *Klinische Monatsblätter Für Augenheilkunde*, vol. 227, no. 11, pp. 887–891, 2010.

[34] G. Coppens and P. Maudgal, "Corneal complications of intraoperative Mitomycin C in glaucoma surgery," *Bulletin de la Société Belge D'ophtalmologie*, vol. 314, pp. 19–23, 2010.

[35] R. C. Tripathi, J. Li, W. A. Chan, and B. J. Tripathi, "Aqueous humor in glaucomatous eyes contains an increased level of TGF-β2," *Experimental Eye Research*, vol. 59, no. 6, pp. 723–728, 1994.

[36] M. O. Becker, A. Kill, M. Kutsche et al., "Vascular receptor autoantibodies in pulmonary arterial hypertension associated with systemic sclerosis," *American Journal of Respiratory and Critical Care Medicine*, vol. 190, no. 7, pp. 808–817, 2014.

[37] K. Makino, M. Jinnin, J. Aoi et al., "Knockout of endothelial cell-derived endothelin-1 attenuates skin fibrosis but accelerates cutaneous wound healing," *PLoS ONE*, vol. 9, no. 5, Article ID e97972, 2014.

[38] C. L. Von Zee, K. A. Langert, and E. B. Stubbs Jr., "Transforming growth factor-β2 induces synthesis and secretion of endothelin-1 in human trabecular meshwork cells," *Investigative Ophthalmology and Visual Science*, vol. 53, no. 9, pp. 5279–5286, 2012.

[39] H. Thieme, L. Choritz, C. Hofmann-Rummelt, U. Schloetzer-Schrehardt, and U. B. Kottler, "Histopathologic findings in early encapsulated blebs of young patients treated with the ahmed glaucoma valve," *Journal of Glaucoma*, vol. 20, no. 4, pp. 246–251, 2011.

[40] T. Meyer-Ter-Vehn, S. Sieprath, B. Katzenberger, S. Gebhardt, F. Grehn, and G. Schlunck, "Contractility as a prerequisite for TGF-β-induced myofibroblast transdifferentiation in human tenon fibroblasts," *Investigative Ophthalmology and Visual Science*, vol. 47, no. 11, pp. 4895–4904, 2006.

[41] T. Meyer-ter-Vehn, B. Katzenberger, H. Han, F. Grehn, and G. Schlunck, "Lovastatin inhibits TGF-β-induced myofibroblast transdifferentiation in human tenon fibroblasts," *Investigative Ophthalmology and Visual Science*, vol. 49, no. 9, pp. 3955–3960, 2008.

[42] G. Renieri, L. Choritz, R. Rosenthal, S. Meissner, N. Pfeiffer, and H. Thieme, "Effects of endothelin-1 on calcium-independent contraction of bovine trabecular meshwork," *Graefe's Archive for Clinical and Experimental Ophthalmology*, vol. 246, no. 8, pp. 1107–1115, 2008.

[43] T. Koga, T. Koga, M. Awai, J.-I. Tsutsui, B. Y. J. T. Yue, and H. Tanihara, "Rho-associated protein kinase inhibitor, Y-27632, induces alterations in adhesion, contraction and motility in cultured human trabecular meshwork cells," *Experimental Eye Research*, vol. 82, no. 3, pp. 362–370, 2006.

[44] F. Ederer, D. E. Gaasterland, E. K. Sullivan, and AGIS Investigators, "The Advanced Glaucoma Intervention Study (AGIS): 1. Study design and methods and baseline characteristics of study patients," *Controlled Clinical Trials*, vol. 15, no. 4, pp. 299–325, 1994.

[45] D. C. Musch, P. R. Lichter, K. E. Guire, and C. L. Standardi, "The Collaborative Initial Glaucoma Treatment Study: study design, methods, and baseline characteristics of enrolled patients," *Ophthalmology*, vol. 106, no. 4, pp. 653–662, 1999.

Hindawi Publishing Corporation
Journal of Ophthalmology
Volume 2016, Article ID 3097379, 7 pages
http://dx.doi.org/10.1155/2016/3097379

Clinical Study

Outcomes of 23-Gauge Vitrectomy Combined with Phacoemulsification, Panretinal Photocoagulation, and Trabeculectomy without Use of Anti-VEGF Agents for Neovascular Glaucoma with Vitreous Hemorrhage

Hua Yan

Department of Ophthalmology, Tianjin Medical University General Hospital, No. 154, Anshan Road, Tianjin 300052, China

Correspondence should be addressed to Hua Yan; zyyyanhua@tmu.edu.cn

Received 26 October 2015; Revised 15 December 2015; Accepted 20 December 2015

Academic Editor: Antonio Ferreras

Purpose. To evaluate the outcomes of 23-gauge vitrectomy combined with phacoemulsification, PRP and trabeculectomy without use of anti-VEGF-agents for NVG. *Methods*. Eighteen eyes of 18 patients with NVG underwent 23-gauge vitrectomy combined with phacoemulsification, PRP and trabeculectomy without use of anti-VEGF agents. The preoperative BCVA ranged from light perception to 0.2. The preoperative IOP ranged from 38 mmHg to 64 mmHg with a mean of 54 ± 8 mmHg. The average follow-up time was 14.5 ± 3 months with a range from 11 to 24 months. *Results*. The postoperative VA increased in 14 eyes and was stable in 4 eyes at the final follow-up. The mean IOP was 12 ± 3 mmHg at postoperative day 1. The mean IOP was 15 ± 2 mmHg, 16 ± 3 mmHg, 23 ± 5 mmHg, 28 ± 4 mmHg, 22 ± 5 mmHg, 17 ± 3 mmHg, and 19 ± 4 mmHg at postoperative days 2 and 3, 1, 2, 3, and 12 weeks, and 1 year postoperatively, respectively, with a range from 10 to 30 mmHg at the final follow-up time point of one year. The IOP was significantly lower than the preoperative one 12 weeks postoperatively ($p < 0.05$). *Conclusion*. 23-gauge vitrectomy combined with phacoemulsification, PRP, and trabeculectomy without use of anti-VEGF-agents is a safe and effective method in treating NVG.

1. Introduction

Neovascular glaucoma (NVG) complicated by vitreous hemorrhage (VH) is commonly caused by retinal ischemia secondary to central retinal vein occlusion (CRVO), branch retinal vein occlusion (BRVO), and/or proliferative diabetic retinopathy (PDR) [1–3]. Vision can be severely affected by NVG, which often causes permanent damage to the optic nerve secondary to high intraocular pressures associated with angle closure. Ischemic neovascular vessels can form and occlude the angle. Hypoxia caused by CRVO, BRVO, and PDR induces production and release of vascular endothelial growth factor (VEGF) and inflammatory mediators. These neovascular vessels are leaky and fragile and can cause VH and NVG and are also associated with leakage of inflammatory molecules which can cause macular edema.

NVG is one of the most recalcitrant glaucoma types to treatment and has one of the worst outcomes of the many types of glaucoma. NVG often needs surgical treatment because medical treatment of elevated IOP is often inadequate. The standard of early treatment once NVG occurs is panretinal photocoagulation (PRP), which destroys ischemic retina and decreases the production of proangiogenic factors such as VEGF. PRP can prevent ischemic retina from progressing to NVG. Glaucoma drainage implants, trabeculectomy with mitomycin C, cyclocryotherapy, or diode laser coagulation of the ciliary body is another treatment option available for the treatment of recalcitrant and end-stage NVG [4–6]. Pars plana vitrectomy (PPV) combined with glaucoma drainage implantation can produce good control of intraocular pressure (IOP) in NVG patients with PDR [7, 8].

Antivascular endothelial growth factor (anti-VEGF) molecules have been used for many ocular diseases, including NVG. A number of studies have evaluated the use of anti-VEGF agents as stand-alone or adjunctive treatment for NVG [9]. Adjunctive anti-VEGF treatment promotes the surgical

success rate for NVG. IOP lowering surgery combined with PRP or intravitreal injection of anti-VEGF antibodies aids in regression of neovascularization and stabilization of vision [10, 11].

The optimal approaches to treating NVG with VH are to provide patients with an individualized management plan according to etiology, stage of disease, and visual potential among other factors. PPV combined with PRP can reduce the occurrence of NVG and increases visual acuity (VA) in CRVO with VH [12]. In this retrospective study, we investigated the long term surgical outcomes, including VA and IOP of NVG eyes complicated with VH, after treatment with 23-gauge vitrectomy combined with phacoemulsification, PRP, and trabeculectomy without use of anti-VEGF agents. We suggest that this is an effective method for the treatment of NVG induced by retinal vessel occlusion and PDR.

2. Patients and Methods

2.1. Patients. The study was approved by Tianjin Medical University General Hospital Medical Ethics Committee and complies with the Declaration of Helsinki, including current revisions, and with the Good Clinical Practice guidelines. The procedures followed were in accordance with institutional guidelines; all the subjects provided their written informed consent for sampling according to the Declaration of Helsinki. All the subjects were recruited from the ophthalmology department of Tianjin General Hospital.

Eighteen eyes of 18 consecutive patients who had NVG and VH underwent 23-gauge vitrectomy combined with phacoemulsification, PRP, and trabeculectomy without use of anti-VEGF agents from January 2012 to June 2014. Ten patients were males, and 8 were females. The age ranged from 58 to 76 years with a mean of 62 ± 6 years. Three patients were with hypertension, 7 patients were with diabetes mellitus complicated with hypertension, and 8 patients were with diabetes mellitus complicated with renal failure. Eight eyes had a history of CRVO, 6 eyes had PDR complicated with BRVO, and 4 eyes had PDR alone (Table 1). The rubeosis iridis conditions were present in 18 NVG eyes preoperatively (Figure 1). The preoperative VA ranged from light perception to 0.2. The preoperative IOP ranged from 38 to 64 mmHg with a mean of 54 ± 8 mmHg. The average follow-up was 14.5 ± 3 months with a range from 12 to 24 months.

Eyes with a prior history of intravitreal injection of steroids or anti-VEGF agents, VH without retinal vessels occlusion and PDR, ocular trauma, ocular tumors, and corneal opacity precluding PRP, or cataract extraction before NVG was diagnosed were excluded.

2.2. Pre- and Postoperative Examinations. Pre- and postoperative examinations included VA, slit-lamp examination, gonioscopy, indirect ophthalmoscopy, IOP, and B-scan.

2.3. Surgical Procedures. We performed 23-gauge PPV using a three-port technique in all patients. The eye received retrobulbar and peribulbar 2% lidocaine for anesthesia, and the eye was then prepared for a standard three-port 23-gauge vitrectomy. After the infusion cannula was placed, the cataract was extracted by phacoemulsification through a clear corneal incision approach. The posterior capsule was preserved in 10 eyes and was completely resected in 8 eyes. During PPV, posterior hyaloid separation was induced by suction using the vitreous cutter over the optic nerve head in eyes without posterior vitreous detachment. In each case, the meticulous shaving of the vitreous base under a wide-angle viewing system with assisted sclera depression was performed to remove as much residual blood as possible. After the VH was completely removed, any fibrovascular tissue present was removed using the microvitrector tip. Hemostasis was maintained by raising the IOP through the infusion fluid or by using endodiathermy intraoperatively.

PRP was performed in all eyes, and subsequent peripheral retinal cryotherapy was given only in severe NVG eyes during the surgery. A 4×3 mm lamellar sclera flap was created in the superior region to the limbal border, and then a mitomycin C trabeculectomy was performed. Postoperative examinations were completed at 1, 2, and 3 days, 1, 2, 3, and 12 weeks, and 1 year after the surgery. Intraocular lenses were implanted in 3 eyes 3 months after the combined surgery. No supplemental PRP was given in the postoperative period.

Paired Student's t-test was used to analyze changes in pre- and postoperative IOP.

3. Results

After the combined surgery, the conjunctival incisions healed well, and the conjunctival flap was formed significantly. Corneas were clear, and iridectomies were patent. Rubeosis iridis has regressed in all eyes 1 week postoperatively (Figure 1). At the final follow-up postoperatively, rubeosis iridis disappeared in the iris and conjunctiva filtering bleb was flat.

3.1. VA. The postoperative VA increased in 14 eyes with the BCVA ranging from 0.02 to 0.4 and was stable relative to the preoperative vision in 4 eyes at the final follow-up. The change trend of BCVA pre- and postoperatively was demonstrated in Figure 2. The BCVA significantly increased within three months postoperatively compared with the preoperative BCVA ($p < 0.05$) and then remained stable ($p > 0.05$).

3.2. IOP. The mean IOP was 12 ± 3 mmHg, 15 ± 2 mmHg, 16 ± 3 mmHg, 23 ± 5 mmHg, 28 ± 4 mmHg, 22 ± 5 mmHg, 17 ± 3 mmHg, and 19 ± 4 mmHg at 1, 2, and 3 days, 1, 2, 3, and 12 weeks, and 1 year, postoperatively. The IOP ranged from 10 to 30 mmHg 1 year postoperatively. The IOP was significantly lower at three months compared to the preoperative baseline IOP ($p < 0.05$) and then remained stable to the final follow-up ($p > 0.05$) (Figure 3). IOP was not in normal range in 8 eyes 1 month postoperatively, and 2% carteolol hydrochloride was used twice a day for 1 month in 5 eyes and combined with brinzolamide 3 times a day for 1 month in 3 eyes for making IOP to normal range.

3.3. Postoperative Complications. Postoperative complications mainly included fibrosis exudates in the anterior chamber (7 eyes), temporary IOP elevation at 2 weeks

Table 1: Clinical data of patients with NVG.

Case number	Sex	Age (y)	Systemic disease	Diagnosis	Previous treatment	BCVA		IOP (mmHg)		Complications	Follow-up (months)
						Preop.	Postop.	Preop.	Postop.		
1	M	76	Hypertension	CRVO	B + C	0.02	0.08	58	21	Fibrosis exudates in AC	16
2	M	61	DM + hypertension	CRVO	B + C, partial laser	0.04	0.04	53	22	None	17
3	F	58	DM + RF	PDR + BRVO	B + C	LP	0.02	60	30	Fibrosis exudates in AC	12
4	F	62	DM + hypertension	CRVO	B + C, partial laser	HM	0.04	58	20	None	15
5	M	59	DM + RF	PDR + BRVO	B + C	CF	0.04	59	18	Temporary IOP elevation	14
6	F	61	DM + RF	PDR	B + C	0.08	0.1	48	17	None	17
7	M	63	DM + hypertension	CRVO	B + C	0.06	0.1	61	19	Fibrosis exudates in AC	12
8	M	63	DM + RF	PDR	B + C, partial laser	0.1	0.3	40	15	Fibrosis exudates in AC	13
9	F	59	DM + RF	PDR + BRVO	B + C	0.08	0.08	39	16	None	12
10	M	58	DM + hypertension	CRVO	B + C, partial laser	0.04	0.06	56	21	Fibrosis exudates in AC	12
11	F	60	DM + hypertension	PDR + BRVO	B + C	HM	0.02	58	19	SCH	24
12	F	63	DM + hypertension	PDR + BRVO	B + C	HM	0.08	57	18	None	13
13	M	59	DM + RF	PDR	B + C, partial laser	0.02	0.02	56	20	Fibrosis exudates in AC	17
14	M	71	Hypertension	CRVO	B + C	0.02	0.04	54	18	Fibrosis exudates in AC	12
15	F	63	DM + RF	PDR + BRVO	B + C	LP	0.04	64	19	Temporary IOP elevation	16
16	M	58	DM + hypertension	CRVO	B + C	CF	0.06	55	17	None	14
17	M	63	DM + RF	PDR	B + C	0.04	0.04	54	18	None	13
18	F	65	Hypertension	CRVO	B + C, partial laser	0.2	0.4	38	10	None	13

F = female; M = male; DM = diabetes mellitus; RF = renal failure; BCVA = best corrected visual acuity; AC = anterior chamber; SCH = suprachoroidal hemorrhage; B = brinzolamide; C = 2% carteolol hydrochloride.

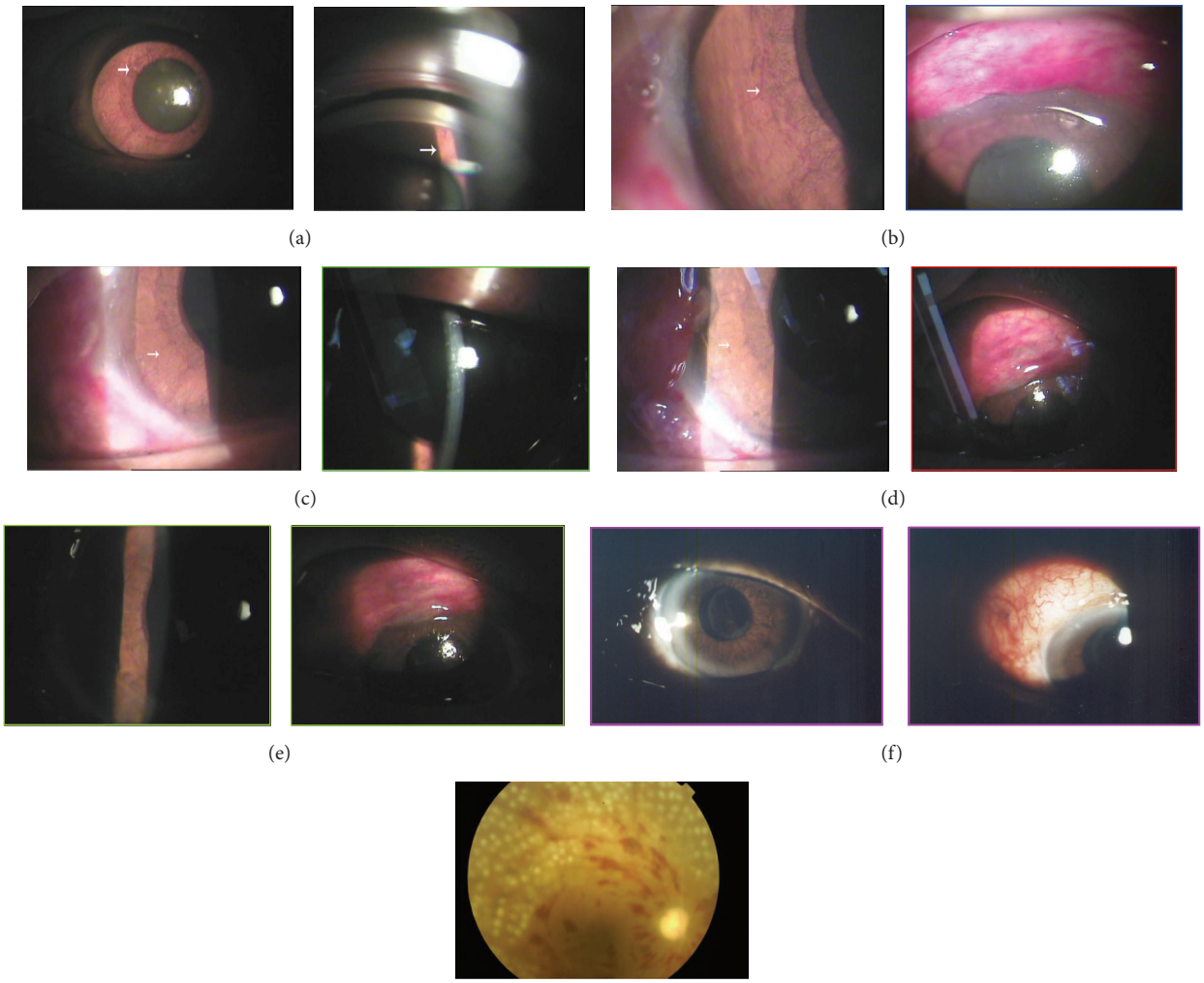

Figure 1: A 63-year-old woman with a history of diabetes mellitus complicated with renal failure underwent combined surgery for PDR complicated with NVG. The preoperative VA was LP and increased to 0.04 postoperatively, with IOP decreasing from 64 mmHg preoperatively to 19 mmHg at the final follow-up postoperatively. Rubeosis iridis was present in the iris preoperatively and regressed 1 week postoperatively. At the final follow-up postoperatively, rubeosis iridis disappeared in the iris and conjunctiva filtering bleb was flat. (a) Rubeosis iridis (white arrow) was present in the iris preoperatively, and new vessels (white arrow) were seen at the anterior chamber angle by gonioscopy. IOP was 64 mmHg. (b) Rubeosis iridis (white arrow) was still present in the iris 1 day postoperatively, and conjunctiva filtering bleb was formed. IOP was 16 mmHg. (c) Rubeosis iridis (white arrow) was significantly decreased in the iris 2 days postoperatively, and cornea was clear. IOP was 15 mmHg. (d) Rubeosis iridis (white arrow) was not significant in the iris 3 days postoperatively, and conjunctiva filtering bleb was obvious. IOP was 15 mmHg. (e) Rubeosis iridis regressed in the iris 1 week postoperatively, and conjunctiva filtering bleb was stable. IOP was 15 mmHg. (f) Rubeosis iridis disappeared in the iris at the final follow-up postoperatively, and conjunctiva filtering bleb was flat. IOP was 19 mmHg. (g) Intraoperative PRP for treatment of PDR complicated with BRVO in patients with NVG and optic nerve atrophy 1 week postoperatively.

postoperatively (2 eyes), and postoperative suprachoroidal hemorrhage (1 eye).

4. Discussion

A cyclodestructive method or glaucoma drainage surgery is frequently the final option for treatment of severe NVG, but the postoperative VA rarely increases, and IOP is sometimes poorly controlled after aggressive treatment [4, 5]. We treated NVG using 23-gauge vitrectomy combined with phacoemulsification, PRP, and trabeculectomy without use of anti-VEGF agents and obtained predictable results.

NVG develops secondary to extensive ischemic retinal changes, such as occurring with PDR and CRVO. In CRVO, when the retinal vein is occluded, the ischemic retina releases VEGF and inflammatory cytokines into the vitreous cavity, posterior chamber, anterior chamber, and anterior chamber angle [13]. The VEGF in the anterior chamber stimulates neovascularization of the iris and the angle, restricts aqueous outflow, and results eventually in the development of NVG.

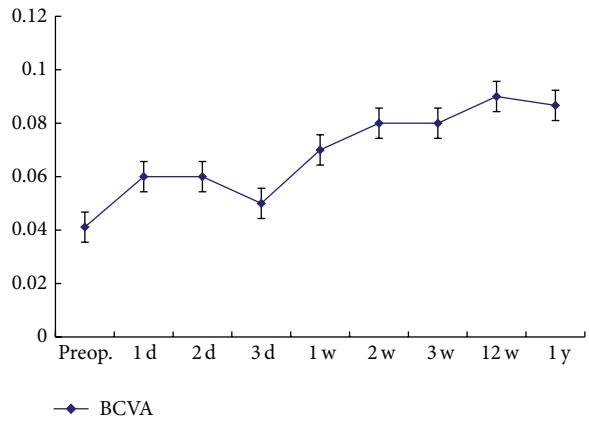

Figure 2: The chart clearly demonstrates the change trend of BCVA pre- and postoperatively. The BCVA significantly increased within three months postoperatively compared with the preoperative BCVA ($p < 0.05$) and then remained stable ($p > 0.05$).

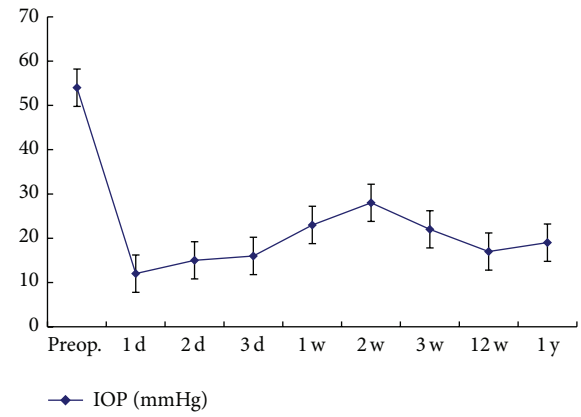

Figure 3: The chart clearly demonstrates the change trend of IOP pre- and postoperatively. The IOP was significantly lower within three months postoperatively compared with the preoperative baseline IOP ($p < 0.05$) and then remained stable ($p > 0.05$).

Wakabayashi et al. [14] reported high intraocular VEGF level at the time of primary vitrectomy in patients with PDR, which was identified as a significant risk factor for postoperative early VH. Goto et al. [15] reported that the risk factors for NVG after vitrectomy in eyes with PDR are independently associated with male sex, younger age, higher baseline IOP, preoperative neovascularization in the angle, and NVG in the fellow's eye.

In this study, 8 patients had hypertension complicated with CRVO, 6 patient had hypertension complicated with BRVO, and 4 patients had PDR. The 4 patients with PDR were also complicated with either CRVO or BRVO. PDR in these 4 patients was not very severe. Therefore, the main reason resulting in NVG was either CRVO or BRVO. In our experience, NVG caused by CRVO or BRVO occurs more quickly than by diabetic retinopathy. In patients with CRVO or BRVO, the observation of IOP, rubeosis irides, and retinal neovascularization should be emphasized, and PRP should be performed for decreasing the risk of developing NVG.

Phacoemulsification, vitrectomy, PRP, and trabeculectomy were adopted to treat NVG complicated with VH according to the different treatment mechanisms. Phacoemulsification to remove a cataract can improve the view so vitrectomy and PRP can be performed more easily. In patients without a posterior capsule preserved after phacoemulsification, the postoperative IOP may be lowered significantly because of the free communication of aqueous humor between the anterior chamber and vitreous cavity. However, postoperative suprachoroidal hemorrhage occasionally occurred because of sudden decrease of postoperative IOP or simultaneously ocular trauma. In this study, 1 eye without posterior capsule preservation developed suprachoroidal hemorrhage because of ocular trauma 3 days postoperatively and were treated with drainage of suprachoroidal hemorrhage through sclerotomies and placement of 30% C3F8 into the vitreous cavity.

The benefits of vitrectomy for NVG complicated by VH are as follows: (1) vitrectomy removes VH and clears the vitreous cavity which can increase VA, (2) vitrectomy removes and may reduce the expression of VEGF, which is a vital factor for neovascularization, (3) vitrectomy to remove VH can prevent hemolytic or ghost cell glaucoma, and (4) PRP can be performed completely and easily after PPV. In NVG with VH, performing complete PRP is often difficult even in cases with minimal VH.

PRP, the standard of care for treating NVG in ischemic CRVO and PDR, decreases oxygen consumption and production of VEGF and aids in the regression of rubeosis irides. In patients with previous partial retinal laser treatment, additional laser photocoagulation can be performed intraoperatively because it is conducted under anesthesia and patient feels no or minimal pain which allows for more complete PRP along with the greater peripheral retinal view for additional PRP. Rubeosis iridis does not regress immediately after PRP, and effect on IOP can be minimal or delayed after PRP. Therefore, in patients with open angle NVG, trabeculectomy is effective in decreasing the IOP temporarily as, in patients with angle closure NVG, trabeculectomy is used to decrease the IOP for a longer term.

In recent years, anti-VEGF agents have been widely applied for the treatment of ischemic retinopathy, including retinal vessel occlusion and PDR. Anti-VEGF agents used in PDR can reduce intra- and postoperative hemorrhage associated with the surgical removal of VH. Although very little information about the role of anti-VEGF treatment in NVG complicated with VH exists, trabeculectomy combined with injection of anti-VEGF agents into the vitreous body for NVG has been documented. However, the long term effect of decreasing the IOP does not appear to be significant compared with trabeculectomy alone. Anti-VEGF agents can cause temporary regression of iris neovascularization, but the long term use for anti-VEGF agents for NVG is not as clear as it is for age-related macular degeneration. Additionally, long term use of anti-VEGF agents for NVG can be very expensive.

Other protocols for treatment of NVG have been described. Bartz-Schmidt et al. [16] treated NVG with vitrectomy combined with PRP, direct laser coagulation of ciliary processes, and silicone oil tamponade. The IOP normalized

in 59% of eyes at 6 months postoperatively and in 72% of eyes after 1 year. Chuang et al. [12] reported 56 eyes with CRVO complicated by VH which underwent PPV combined with PRP, and the most important result was a lower incidence of NVG development and VA improvement. Kinoshita et al. [17] reported PPV combined with lensectomy with anterior capsule preservation, endophotocoagulation, and silicon oil tamponade for NVG. The IOP decreased from 29 ± 19 mmHg to 17 ± 6 mmHg 1 year postoperatively with a success rate of 69.2%. Luttrull and Avery [18] reported the treatment of NVG with vitrectomy combined with pars plana glaucoma drainage implant, and all patients had normal IOPs 1 year postoperatively. Wallsh et al. [7] reported pars plana placement of Ahmed valved glaucoma drainage implants in combination with PPV in the treatment of NVG. The IOP decreased from 37.6 mmHg to 13.8 mmHg. Jeong et al. [8] reported pars plana Ahmed GDI placement combined with 23-gauge vitrectomy for NVG in DR, and IOP decreased from 35.9 ± 6.3 mmHg to 13.3 ± 3.2 mmHg at the last visit. Control of IOP was achieved in all patients, but 91% needed antiglaucoma medications. Sevim et al. [19] reported the effect of intravitreal bevacizumab injection before Ahmed glaucoma valve implantation in NVG and the surgical success rate was 79%. In this study, the IOP was normal in 71.4% during postoperative follow-up, and the neovascularization of the iris disappeared in all eyes. Preoperative use of bevacizumab may be to have a better result when our combined surgery is not practical or feasible [20].

In conclusion, vitrectomy combined with phacoemulsification, PRP, and trabeculectomy without use of anti-VEGF agents is a safe and effective method in treating NVG complicated with VH. In some cases, loss of VA was decreased. This combined surgery may be considered as a first treatment option for NVG complicated VH, and the long term effects of the combined surgery should be investigated.

Conflict of Interests

The author has stated that he does not have a significant financial interest or other relationships with any product manufacturer or provider of services discussed in this paper. The author also does not discuss the use of off-label products, which includes unlabeled, unapproved, or noninvestigative products or devices.

References

[1] T.-S. An and S.-I. Kwon, "Neovascular glaucoma due to branch retinal vein occlusion combined with branch retinal artery occlusion," *Korean Journal of Ophthalmology*, vol. 27, no. 1, pp. 64–67, 2013.

[2] C. K. Chan, M. S. Ip, P. C. Vanveldhuisen et al., "SCORE study report #11: incidences of neovascular events in eyes with retinal vein occlusion," *Ophthalmology*, vol. 118, no. 7, pp. 1364–1372, 2011.

[3] G. H. Bresnick, G. De Venecia, F. L. Myers, J. A. Harris, and M. D. Davis, "Retinal ischemia in diabetic retinopathy," *Archives of Ophthalmology*, vol. 93, no. 12, pp. 1300–1310, 1975.

[4] A. Tzamalis, D.-T. Pham, and C. Wirbelauer, "Diode laser cyclophotocoagulation versus cyclocryotherapy in the treatment of refractory glaucoma," *European Journal of Ophthalmology*, vol. 21, no. 5, pp. 589–596, 2011.

[5] Y. Takihara, M. Inatani, M. Fukushima, K. Iwao, M. Iwao, and H. Tanihara, "Trabeculectomy with mitomycin C for neovascular glaucoma: prognostic factors for surgical failure," *American Journal of Ophthalmology*, vol. 147, no. 5, pp. 912.e1–918.e1, 2009.

[6] A. W. Fong, G. A. Lee, P. O'Rourke, and R. Thomas, "Management of neovascular glaucoma with transscleral cyclophotocoagulation with diode laser alone versus combination transscleral cyclophotocoagulation with diode laser and intravitreal bevacizumab," *Clinical and Experimental Ophthalmology*, vol. 39, no. 4, pp. 318–323, 2011.

[7] J. O. Wallsh, R. P. Gallemore, M. Taban, C. Hu, and B. Sharareh, "Pars plana Ahmed valve and vitrectomy in patients with glaucoma associated with posterior segment disease," *Retina*, vol. 33, no. 10, pp. 2059–2068, 2013.

[8] H. S. Jeong, D. H. Nam, H. J. Paik, and D. Y. Lee, "Pars plana Ahmed implantation combined with 23-gauge vitrectomy for refractory neovascular glaucoma in diabetic retinopathy," *Korean Journal of Ophthalmology*, vol. 26, no. 2, pp. 92–96, 2012.

[9] K. Kimoto and T. Kubota, "Anti-VEGF agents for ocular angiogenesis and vascular permeability," *Journal of Ophthalmology*, vol. 2012, Article ID 852183, 11 pages, 2012.

[10] Y. Takihara, M. Inatani, T. Kawaji et al., "Combined intravitreal bevacizumab and trabeculectomy with mitomycin C versus trabeculectomy with mitomycin C alone for neovascular glaucoma," *Journal of Glaucoma*, vol. 20, no. 3, pp. 196–201, 2011.

[11] A. A. Alkawas, E. A. Shahien, and A. M. Hussein, "Management of neovascular glaucoma with panretinal photocoagulation, intravitreal bevacizumab, and subsequent trabeculectomy with mitomycin C," *Journal of Glaucoma*, vol. 19, no. 9, pp. 622–626, 2010.

[12] L.-H. Chuang, N.-K. Wang, Y.-P. Chen et al., "Vitrectomy and panretinal photocoagulation reduces the occurrence of neovascular glaucoma in central retinal vein occlusion with vitreous hemorrhage," *Retina*, vol. 33, no. 4, pp. 798–802, 2013.

[13] L. P. Aiello, R. L. Avery, P. G. Arrigg et al., "Vascular endothelial growth factor in ocular fluid of patients with diabetic retinopathy and other retinal disorders," *The New England Journal of Medicine*, vol. 331, no. 22, pp. 1480–1487, 1994.

[14] Y. Wakabayashi, Y. Usui, Y. Okunuki et al., "Intraocular VEGF level as a risk factor for postoperative complications after vitrectomy for proliferative diabetic retinopathy," *Investigative Ophthalmology & Visual Science*, vol. 53, no. 10, pp. 6403–6410, 2012.

[15] A. Goto, M. Inatani, T. Inoue et al., "Frequency and risk factors for neovascular glaucoma after vitrectomy in eyes with proliferative diabetic retinopathy," *Journal of Glaucoma*, vol. 22, no. 7, pp. 572–576, 2013.

[16] K. U. Bartz-Schmidt, G. Thumann, A. Psichias, G. K. Krieglstein, and K. Heimann, "Pars plana vitrectomy, endolaser coagulation of the retina and the ciliary body combined with silicone oil endotamponade in the treatment of uncontrolled neovascular glaucoma," *Graefe's Archive for Clinical and Experimental Ophthalmology*, vol. 237, no. 12, pp. 969–975, 1999.

[17] N. Kinoshita, A. Ota, F. Toyoda, H. Yamagami, and A. Kakehashi, "Surgical results of pars plana vitrectomy combined with pars plana lensectomy with anterior capsule preservation,

endophotocoagulation, and silicon oil tamponade for neovascular glaucoma," *Clinical Ophthalmology*, vol. 5, no. 1, pp. 1777–1781, 2011.

[18] J. K. Luttrull and R. L. Avery, "Pars plana implant and vitrectomy for treatment of neovascular glaucoma," *Retina*, vol. 15, no. 5, pp. 379–387, 1995.

[19] M. S. Sevim, I. B. Buttanri, S. Kugu, D. Serin, and S. Sevim, "Effect of intravitreal bevacizumab injection before ahmed glaucoma valve implantation in neovascular glaucoma," *Ophthalmologica*, vol. 229, no. 2, pp. 94–100, 2013.

[20] E. Vandewalle, L. A. Pinto, T. Van Bergen et al., "Intracameral bevacizumab as an adjunct to trabeculectomy: a 1-year prospective, randomised study," *British Journal of Ophthalmology*, vol. 98, no. 1, pp. 73–78, 2014.

Hindawi Publishing Corporation
Journal of Ophthalmology
Volume 2015, Article ID 737198, 9 pages
http://dx.doi.org/10.1155/2015/737198

Research Article

Biodegradable PTLGA Terpolymers versus Collagen Implants Used as an Adjuvant in Trabeculectomy in Rabbit Eye

Weiran Niu,[1] Guanglin Shen,[1] Yuanzhi Yuan,[1] Xiaoping Ma,[1] Suming Li,[2] Jingzhao Wang,[2] Zhongyong Fan,[3] and Lan Liao[3]

[1]*Department of Ophthalmology, Zhongshan Hospital of Fudan University, Shanghai 200032, China*
[2]*Institute de High Performance Polymers, Qingdao University of Science and Technology, Qingdao 266042, China*
[3]*Department of Materials Science, Fudan University, Shanghai 200433, China*

Correspondence should be addressed to Xiaoping Ma; xiaopingma@126.com

Received 25 September 2015; Accepted 12 November 2015

Academic Editor: Antonio Ferreras

Purpose. To evaluate the effectiveness and safety of three biodegradable terpolymers prepared from L-lactide, trimethylene carbonate, and glycolide (PTLGA) as an aid for trabeculectomy compared with the Ologen (OLO). *Methods*. Trabeculectomy was carried out on rabbits with implantation made from OLO or three PTLGA terpolymers. Intraocular pressure (IOP) was recorded 1, 2, 3, and 6 months postoperatively and bleb evaluations were performed using ultrasound biomicroscopy (UBM) 3 months after surgery, optical coherence tomography (OCT) every month, and transmission electron microscopy (TEM) six months after surgery followed by histological examination 1, 2, 3, and 6 months postoperatively. *Result*. IOP was significantly reduced in all groups after surgery. There were no significant differences in the IOL between groups at any time after implantation. There was no significant difference between the groups examined by OCT, UBM, and TEM. Exposure of the implant was observed in one eye from the OLO group and one eye in the P1. Subconjunctiva hyperblastosis was observed in one eye from group P3 and two eyes from the OLO group. *Conclusions*. Subconjunctival implantation of filtering devices made from PTLGA may present a safe and effective additional surgical tool for the treatment of filtering surgery. Fewer complications were observed in the group with P2 implants compared to other groups.

1. Introduction

Since trabeculectomy was introduced in 1968, it has been the most common surgery to treat glaucoma [1]. Because scarring is still the major threat to the long-term success of glaucoma trabeculectomy surgery, mitomycin C (MMC) has been widely used as an antifibrotic agent to inhibit fibroblast proliferation and to maintain an ideal postoperative intraocular pressure (IOP) for more than two decades [2]. It has been proved that MMC raised the success rate of many types of glaucoma filtration surgery [3–5], and the use of MMC as a therapeutic agent has been well established as an effective clinical practice at achieving low final intraocular pressures (IOPs). However, severe complications such as leakage, infection, hypotony, and endophthalmitis with complete loss of vision may occur in surgeries with MMC, and surgery still fails in some individuals unfortunately [6, 7]. Less toxic antifibrotic agents or better therapeutic methods are needed.

Because of that, many promising new agents and implants to inhibit scar formation with fewer adverse effects have been evaluated in recent researches. Biodegradable implants such as Ologen (OLO), a porous collagen-glycosaminoglycan matrix, could potentially take the place of MMC to prevent the adhesion of the conjunctiva and sclera [8, 9] and the collapse of the subconjunctival space after trabeculectomy which leads to collagen deposition and microcyst formation after penetrating antiglaucomatous surgery. Use of OLO decreased early postoperative scarring and could be used to repair postoperative bleb leaks [10, 11]. Adverse effects of OLO included translocation or exposure of the implant or erosion of the conjunctiva.

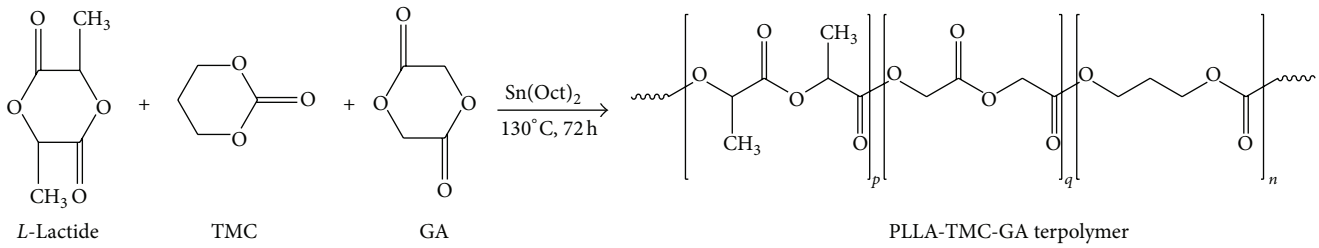

Figure 1: Synthesis route of PTLGA terpolymers. By permission from Shen et al. [12].

Biodegradable polymers such as poly(L-lactide) (PLLA), polyglycolide (PGA), poly(1,3-trimethylene carbonate) (PTMC), and their copolymers have attracted great attention for biomedical applications such as surgical implants, drug carrier, and tissue engineering scaffold because of their outstanding biocompatibility and biodegradability. In previous studies, terpolymers prepared from L-lactide, glycolide, and 1,3-trimethylene carbonate (PTLGA) have been successfully used as intravascular stent [12].

The goal of this study was to evaluate the efficacy and safety of PTLGA terpolymer in keeping the postoperative space between the conjunctiva and sclera functional and thus to maintain the filtering bleb active after trabeculectomy in rabbit eyes.

2. Materials and Methods

All experiments were carried out on the OD eye under a surgical microscope and general anesthesia. Rabbits weighing between 2.5 and 3.0 kg were anesthetized by intramuscular injection of ketamine hydrochloride (10 mg/kg) and xylazine (20 mg/kg). Topical anesthesia (0.5% proparacaine hydrochloride, Alcaine, Alcon-Couvreur, Belgium) was applied to the eyes. All rabbits were treated in accordance with the ARVO Statement on the Use of Animals in Ophthalmic and Vision Research, and the experimental protocol was approved by the Animal Care and Use Committee of Zhongshan Hospital, Fudan University.

2.1. Trabeculectomy in Rabbit Eyes. Four groups of eight female rabbits underwent trabeculectomy (32 animals in total). A fornix-based conjunctival incision was made and a 3 × 3 mm scleral flap was created. Trabeculectomy was performed at the scleral spur, followed by iridectomy. A 5 × 6 mm implant sheet was placed on the scleral flap, the implant inserted over the flap. The scleral flap and conjunctival wound were sutured with 10-0 nylon. The implants included OLO and 3 different kinds of PTLGA terpolymers, P1, P2, and P3, in the study groups (see Section 2.2 below). No antifibrotic agent such as MMC was applied. Filtering bleb formation and inflammation of the anterior chamber were observed with slit-lamp microscopy by masked observers.

2.2. Materials. PTLGA terpolymers [13] (Figure 1) were generously prepared [12] and provided by Dr. Suming Li and Dr. Zhongyong Fan. The implant has a shape of film and a thickness of 1 mm:

P1, PLLA : GA : TMC (95.8 : 5.4 : 4.2, mole : mole). Number average molecular weight is 232 KDa.

P2, PLLA : GA : TMC (60 : 13.2 : 22.8, mole : mole). Number average molecular weight is 45 KDa.

P3, PLLA : GA : TMC (2 : 1.19 : 0.8, mole : mole). Number average molecular weight is 28 KDa.

OLO (Ologen; Aeon Astron Group B.V. Leiden, the Netherlands). The implant size was 10 mm (W) × 10 mm (L) × 2 mm (H) (number 870051).

All implants were cut into 5 mm (W) × 6 mm (L) in the study.

2.3. Examining Methods

2.3.1. Intraocular Pressure (IOP) Measurements. After topical anesthesia of 0.5% proparacaine hydrochloride Alcaine (Alcon-Couvreur, Belgium), IOP was measured using a Goldman applanation tonometry at baseline and twice a month for 1, 2, 3, and 6 months after surgery in all groups. IOP measurements were made by a blinded investigator. An average of three tonometer readings, with a maximum 5% standard deviation (SD), was recorded per eye. The IOP of all the experimental rabbits was measured at approximately 3 p.m.

2.3.2. Hematoxylin-Eosin Staining. Rabbits were killed by excess ketamine (35 mg/kg) and xylazine (5 mg/kg) on months 1, 2, 3, and 6 after implantation. Eyes were quickly removed and fixed in 4% formaldehyde. The conjunctiva and implant with the underlying scleral bed were dissected, dehydrated, and embedded in paraffin. Sections were cut by a microtome at 7 micrometers and stained with hematoxylin and eosin (H&E) for general histologic observation.

2.3.3. Optical Coherence Tomography (OCT). The subconjunctival fluid space was classified as none, single small, multiple small, or large and scored as 0, 1, 2, and 3, respectively, using a Zeiss Visante OCT (Model 1000, Carl Zeiss Meditec Inc., Dublin, CA). The upper lid was gently lifted by the operator to maximize bleb exposure as best as possible without pressing on the globe. Several radial and transverse sections were assessed.

Table 1: Comparison of IOP measurements between the Ologen group and PTLGA terpolymer groups.

Time points	n	OLO (mean ± SD)	P1 (mean ± SD)	P2 (mean ± SD)	P3 (mean ± SD)
Preoperative	8	15.5 ± 1.2	15.3 ± 1.3	15.4 ± 1.3	15.4 ± 1.1[※*]
1 month after surgery	8	9.6 ± 1.1	9.3 ± 1.6	9.6 ± 1.5	9.7 ± 1.1[※*]
2 months after surgery	6	13.5 ± 1.2	13.3 ± 2.0	13.6 ± 0.9	13.7 ± 1.0[*]
3 months after surgery	4	15.1 ± 1.1	14.5 ± 1.9	15.1 ± 1.3	15.2 ± 1.2
6 months after surgery	2	16.3 ± 0.6	13.9 ± 0.5	16.2 ± 0.1	15.9 ± 1.5

[※] $P = 0.000$, paired-sample t-test.
[*] $P < 0.05$, paired-sample t-test.
Data are presented as mean ± standard deviation.

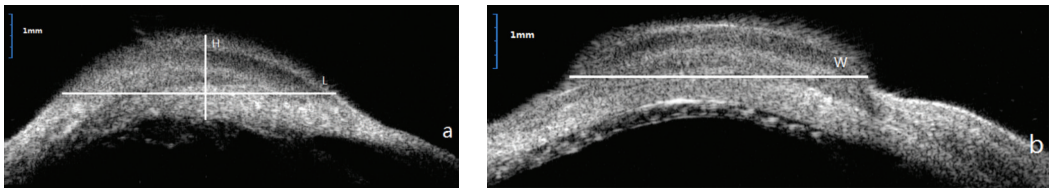

(a) (b)

Figure 2: Imaging of UBM examination. (a) Horizontal section of the filtering bleb. (b) Vertical section of the filtering bleb.

2.3.4. Ultrasound Biomicroscopy (UBM). UBM (SW-3200, SUOER, Tianjin, China) was used to evaluate the height of the postoperative filtering blebs, and the maximum height of the filtering bleb including the eyeball wall in each scan was manually measured and automatically calculated with the device's software. The vertical line was drawn through the maximum height point of the filtering bleb at the corneal limbus, whereas a horizontal line through the same point was used as a base (Figure 2); the bleb area and height within this section of the bleb were used to estimate the volume of the bleb area and analyzed.

2.3.5. Transmission Electron Microscope Examination. Rabbits were euthanized six months after surgery. Eyes were quickly removed and fixed in 4% formaldehyde. Sections of conjunctiva and implant with the underlying scleral bed were cut to a thickness of 1 μm stained with uranyl acetate, followed by lead citrate. Slices were observed using an electron microscope (JEOL 1200, JEOL Co., Japan).

2.4. Statistical Analysis. Statistical analyses were performed using SPSS statistical software (Windows version 20.0; SPSS Inc., Chicago, IL, USA). One-way analyses of variance (One-way ANOVA) and Fisher's exact test were used to compare between the groups. In comparison of pre/postoperative results, paired Student's t-test was used. Complete resorption time was compared using the log rank test and survival curves (Kaplan-Meier curves). The results are expressed as mean ± standard deviation, and $P < 0.05$ was deemed to be statistically significant.

3. Results

3.1. IOP Measurements. No animals were excluded from this study since there were no intraoperative complications. One month after surgery, postoperative mean intraocular pressure (IOP) was significantly lower ($P < 0.0001$) in all groups. At one, three, and six months after surgery, the mean IOP was not statistically ($P > 0.05$) different between groups (Table 1).

3.2. Morphology Observation. Only mild conjunctival hyperemia and edema were observed three to six days postoperatively and disappeared about two weeks later. No occurrence of keratitis, uveitis, or endophthalmitis was observed. During the postoperative follow-up observations, we did not detect allergy or translocation of the implants. Exposure of the implant was observed in one eye in the control group in the second week and group 1 in forth week. The implants were repositioned by conjunctival suture (Figure 3). Table 2 provided an overview of the recorded side effects between the OLO group and PTLGA terpolymer groups. Using the Kruskal-Wallis test, the frequency of postoperative complication did not significantly differ between the groups.

One month after surgery, the filtering bleb was obviously visible in all eyes. Three months later, the filtering blebs were observed flatter in eyes of the OLO group and groups P2 and P3 (Figure 4). Six months after surgery, except for group P1, it was quite difficult to observe the filtering blebs.

3.3. Histologic Evaluation. With hematoxylin-eosin staining we observed that all the biomaterials were found in the samples isolated at three months, except for P1 which had been observed at 3 months after surgery and undergone complete degradation six months after implantation. A weak fibrous capsule formation was observed around all of the biomaterials especially after one month after implantation (Figure 5). Three months after surgery, the fibrous capsule was difficult to observe in all eyes of group P3 and 3 eyes of the OLO group. Subconjunctiva hyperblastosis composed of fibroblasts, small vessels, and inflammatory cells was observed in one eye of

Table 2: Comparison of complications between the Ologen group and PTLGA terpolymer groups.

Complications	OLO number (%)	P1 number (%)	P2 number (%)	P3 number (%)	P
Mild conjunctival hyperemia	7 (87.5%)	8 (100%)	7 (87.5%)	7 (87.5%)	0.057
Mild conjunctival edema	2 (25%)	5 (62.5%)	3 (37.5%)	1 (12.5%)	1.000
Mild hyphema	0	0	0	0	—
Hypotony	0	0	0	0	—
Shallow anterior chamber	0	0	0	1 (12.5%)	0.057
Avascular cystic bleb	0	0	0	0	—
Cataract formation	0	0	0	0	—
Keratitis	0	0	0	0	—
Uveitis	0	0	0	0	—
Endophthalmitis	0	0	0	0	—
Choroidal detachment	0	0	0	0	—
Bleb leakage	1 (12.5%)	1 (12.5%)	0	1 (12.5%)	0.057
Implant exposure	1 (12.5%)	1 (12.5%)	0	0	0.086

Fisher's exact test.

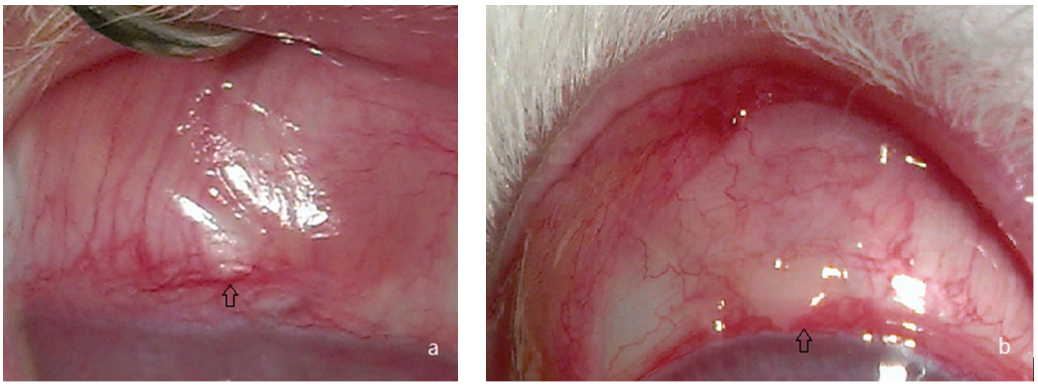

(a) (b)

Figure 3: Exposure of implant happened in 2 eyes; both of them were repositioned by conjunctival suture and recovered well. (a) Exposure of Ologen in control group. (b) Exposure of P1 in Group 1.

group P3 and 2 eyes of the OLO group even after the biomaterials were biodegraded (Figure 6).

3.4. Morphology Examination

3.4.1. Optical Coherence Tomography (OCT). Gradual resorption of the implant and subconjunctival fluid spaces was observed. The complete resorption time was 2 months in 10 eyes and 3 months in 14 eyes. The complete degradation time of group P1 was longer than others but not significantly different, 4 months in 2 eyes, 5 months in 1 eye, and 6 months in 1 eye; there were still implants left in 2 eyes when rabbits were executed. There were no significant differences of the Kaplan-Meier chart curves between the Ologen group and PTLGA terpolymer groups (log rank test, $P = 0.051$) (Figure 7). Three months after surgery, the OCT scores were not significantly ($F = 0.77$, $P = 0.53$) different between groups: 2 ± 1, 2.5 ± 0.6, 1.8 ± 0.5, and 2.0 ± 0.8 for the groups OLO, P1, P2, and P3, respectively. Because of its low depth of penetration, OCT could not be used to assess the route under the scleral flap in some cases, but it is easy to examine if there are implantations left (Figure 8).

3.4.2. Ultrasound Biomicroscopy (UBM). There were no significant ($F = 2$, $P = 0.18$) differences in mean bleb volume at three months: $26 \pm 7\,\text{mm}^3$, $21 \pm 7\,\text{mm}^3$, $33 \pm 3\,\text{mm}^3$, and $30 \pm 11\,\text{mm}^3$, for groups OLO, P1, P2, and P3, respectively.

3.5. Transmission Electron Microscope. A weak fibrous capsule formation was observed around all of the four biomaterials, and small amounts of macrophages were observed nearby (Figure 9).

4. Discussion

As stated in the introduction, trabeculectomy is the most common antiglaucoma surgical procedure. Although both of MMC and OLO had a good record of higher achievement ratio in the surgery [14, 15], because of some adverse effects of them, investigators have developed new materials to take

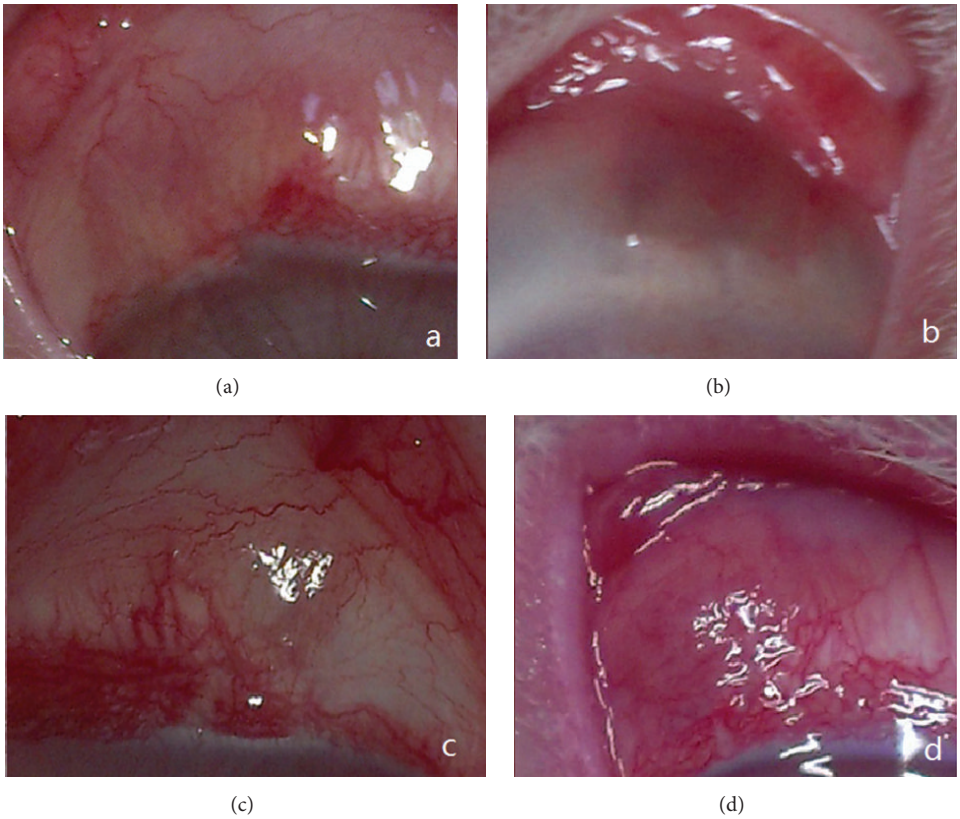

(a) (b) (c) (d)

Figure 4: Morphology observation of the filtering bleb 3 months after surgery. (a) Control group. (b) Group 1. Implant under the conjunctiva still can be seen. (c) Group 2. (d) Group 3.

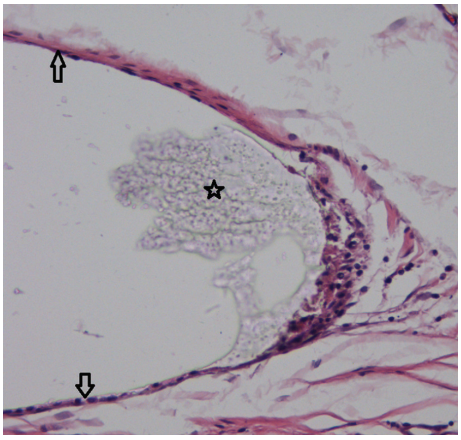

Figure 5: Weak fibrous capsule around the biomaterials marked by arrows.

their place. One intravascular stent material, PTLGA terpolymer, which has a good record of safety and histocompatibility [12], was tested as a biodegradable implant compared to OLO.

Published studies of our department had proved that there are reasons why trabeculectomy with Ologen has been a safe and effective procedure in patients with glaucoma even during a five-year follow-up. First, the structure of Ologen contained thousands of microscopic pores and can induce fibroblast growth, leading to a well organized and healthy healing process. Second, with a thickness of 2 mm and placed directly over the scleral flap and under the subconjunctival space, Ologen could provide space with a dynamic and physiological aqueous reservoir system. Subsequently, Ologen is biodegraded by the body within 90~180 days from its implantation which offered enough time to create a mature bleb structure [16]. In this study, we tested the PTLGA terpolymers, which have a similar structure and a similar degradation time to Ologen and have a thinner thickness

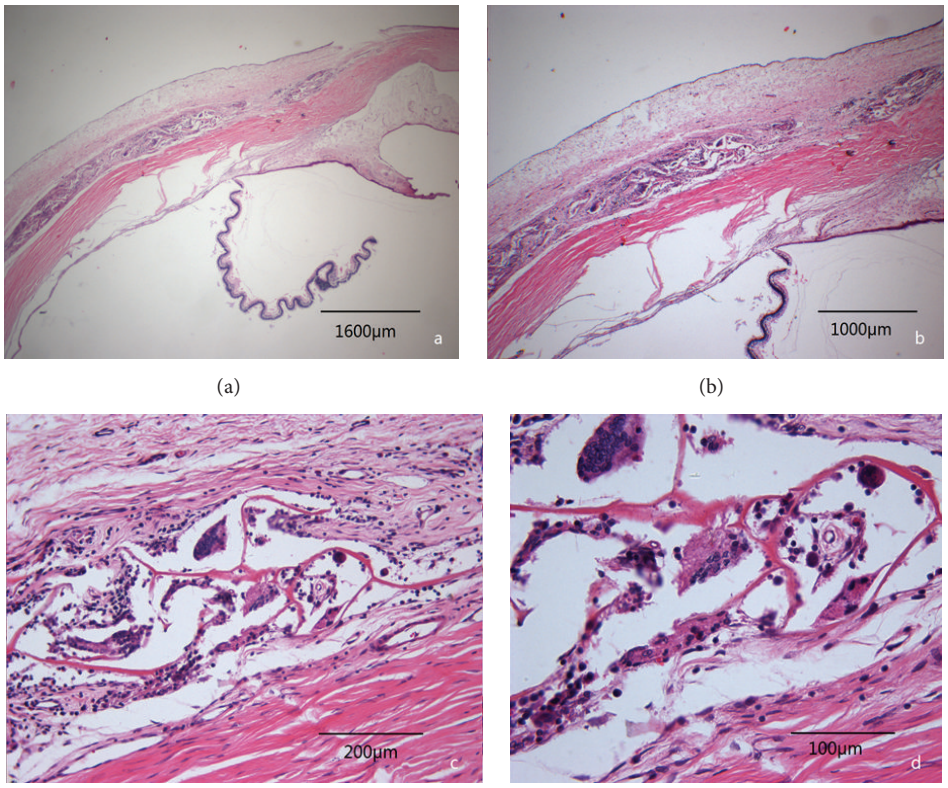

(a) (b) (c) (d)

Figure 6: Subconjunctiva hyperblastosis composed of fibroblasts, small vessels, and inflammatory cells had been observed in the control group; the biomaterials (Ologen) had already degraded. Hematoxylin-Eosin staining, (a) ×25. (b) ×40. (c) ×200. (d) ×400.

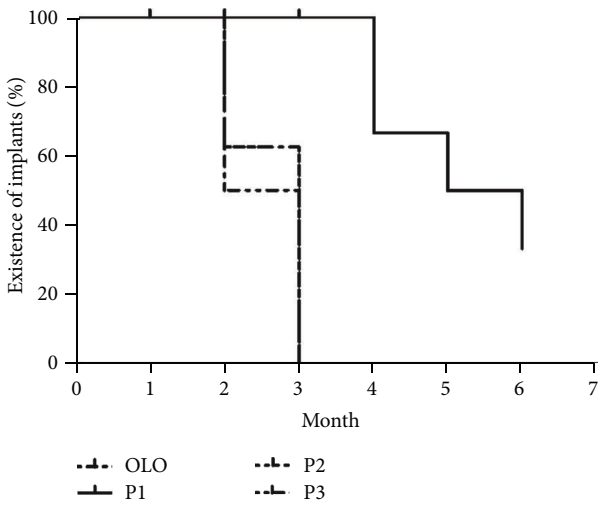

Figure 7: The Kaplan-Meier chart of complete resorption time between the Ologen group and PTLGA terpolymer groups. There were no significant differences of the curves between those groups (log rank test, $P = 0.051$).

of 1 mm, so, theoretically, these implants can get the similar outcome as Ologen in improving the surgical success of trabeculectomy without the adjunctive use of antifibrotic agents.

In this study, biodegradable implants made of PTLGA terpolymers were as safe as those made of OLO. Implants of PTLGA terpolymers were as effective as those made of OLO in achieving a low target IOP level. It was encouraging to confirm that P1 and P2 maintained the size of filtering blebs, even though there might be no strong correlation between IOP and bleb height [17]. The differences of the physical and chemical properties between the PTLGA terpolymers were due to the different percentages of components in the PTLGA terpolymer. The results of examinations and complications in the study included that the efficacy and safety of P2 made it the most suitable implant among the three kinds of PTLGA terpolymers.

Exposure of the implant was one of the complications we found. Exposure in the OLO group may have been due to the thickness of implant. Exposure of implant made from P1 may be due to the hardness of P1 with sharp edges, cusp angles, and a long biodegradation procedure. There were no significant differences of complete resorption time between the groups (we did not take the two rabbits killed before complete resorption of implants into account as perfect biodegraded); we presume that differences would be found and the longest complete resorption time would be seen in the P1 group, if our study has a bigger sample and a longer follow-up time. And we also presume that if the P1 implants were roundish shaped and with a blunt edge, the exposure of P1 would be avoidable.

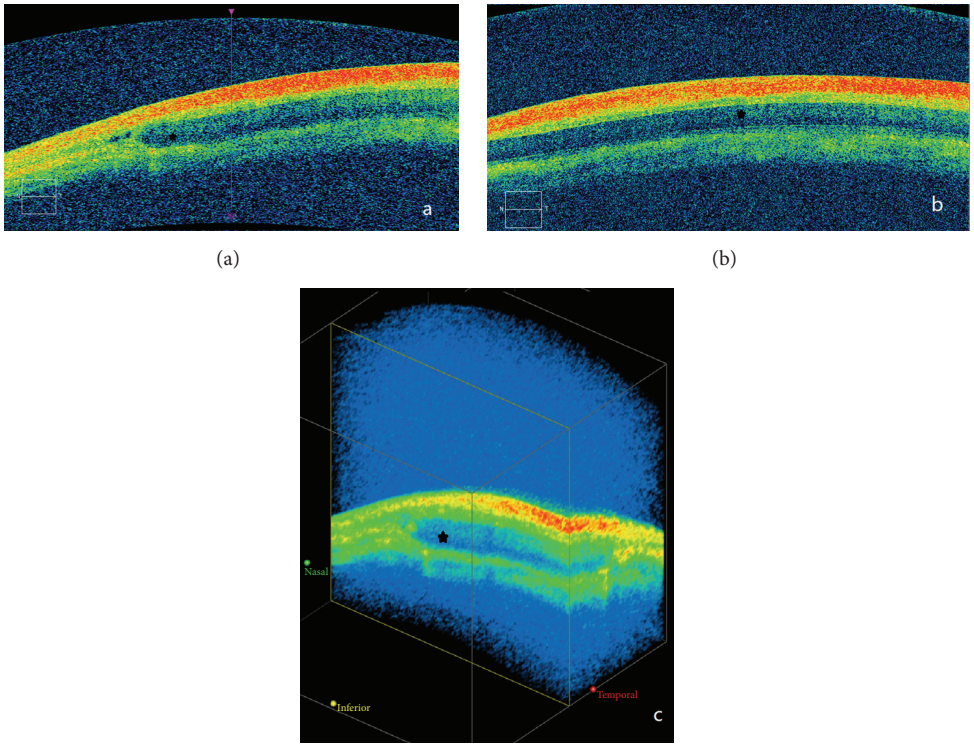

(a) (b) (c)

Figure 8: Imaging of OCT examination. (a) Horizontal section of the subconjunctival fluid space. (b) Three-dimensional reconstruction of the subconjunctival fluid space. (c) Vertical section of the subconjunctival fluid space.

Subconjunctiva hyperblastosis was a unique complication observed in our study which may be due to the response of the conjunctiva to the long-term stimulus from the more acid decomposition product of P3, because P3 has the highest percentage of GA. Subconjunctiva hyperblastosis has been observed in both P3 and OLO groups; however, it is arduous to find such reports in published studies; there may be some reasons behind this: in the first place, OLO has a fair histocompatibility itself; the low occurrence of subconjunctiva hyperblastosis could make it difficult to be observed; then, the subconjunctiva hyperblastosis did not raise the IOP so obviously or so frequently after the operation; third, there might be an absorption of it; the hyperblastosis could only be observed in a short time; the last, it might be hard to be observed by other testing methods. Although the subconjunctiva hyperblastosis in our research did not cause the significant difference of success rate between the groups, we cannot help but conceive the idea that when the subconjunctiva hyperblastosis grows large enough to block the aqueous humor outflow channel, the surgery might end in failure. Longer time follow-up observation was needed to confirm whether there will be a regression or a growth of the subconjunctiva hyperblastosis later, to find what stimulated the development of subconjunctiva hyperblastosis and what strategy is needed for avoiding it or controlling it.

There was a good control of IOP after surgery and no significantly different frequency of complications in all the 4 groups. In particular, complications such as exposure were not observed for implants made of P2, as supposed, due to the thin and soft characteristic of it, and there was no subconjunctiva hyperblastosis observed in the P2 group either, which has a chance to block the aqueous humor outflow of the artificial channel built in the trabeculectomy and cause the IOP to rise rapidly. All these results suggested that P2 may be an ideal material as a new choice of antifibrotic agents. Due to the low incidence of complications and small sample size of our study, more studies are needed to confirm this idea.

OCT measurements were more reproducible and easier to perform than those of UBM. Because of its low depth of penetration, although OCT could not be used to assess the route under the scleral flap in some cases, it is competent enough to observe the residue of implants under the conjunctiva. Detailed anatomic assessment of bleb morphology was made using UBM and OCT. Several investigators have established that UBM and OCT can be used to identify morphologic changes in blebs related to wound healing and to identify parameters for the functional prognosis of the filter blebs [18–22]. The complementary use of OCT and UBM made them irreplaceable.

It is widely accepted that OLO keeps an outstanding postoperative IOP; according to the results of our study, all the three kinds of PTLGA terpolymers played a similar role in the control of IOP after antiglaucoma surgical procedure. Results also implied that there were fewer adverse events in PTLGA terpolymer groups happening than that in the OLO group. Since P2 manifested the fewest complications among

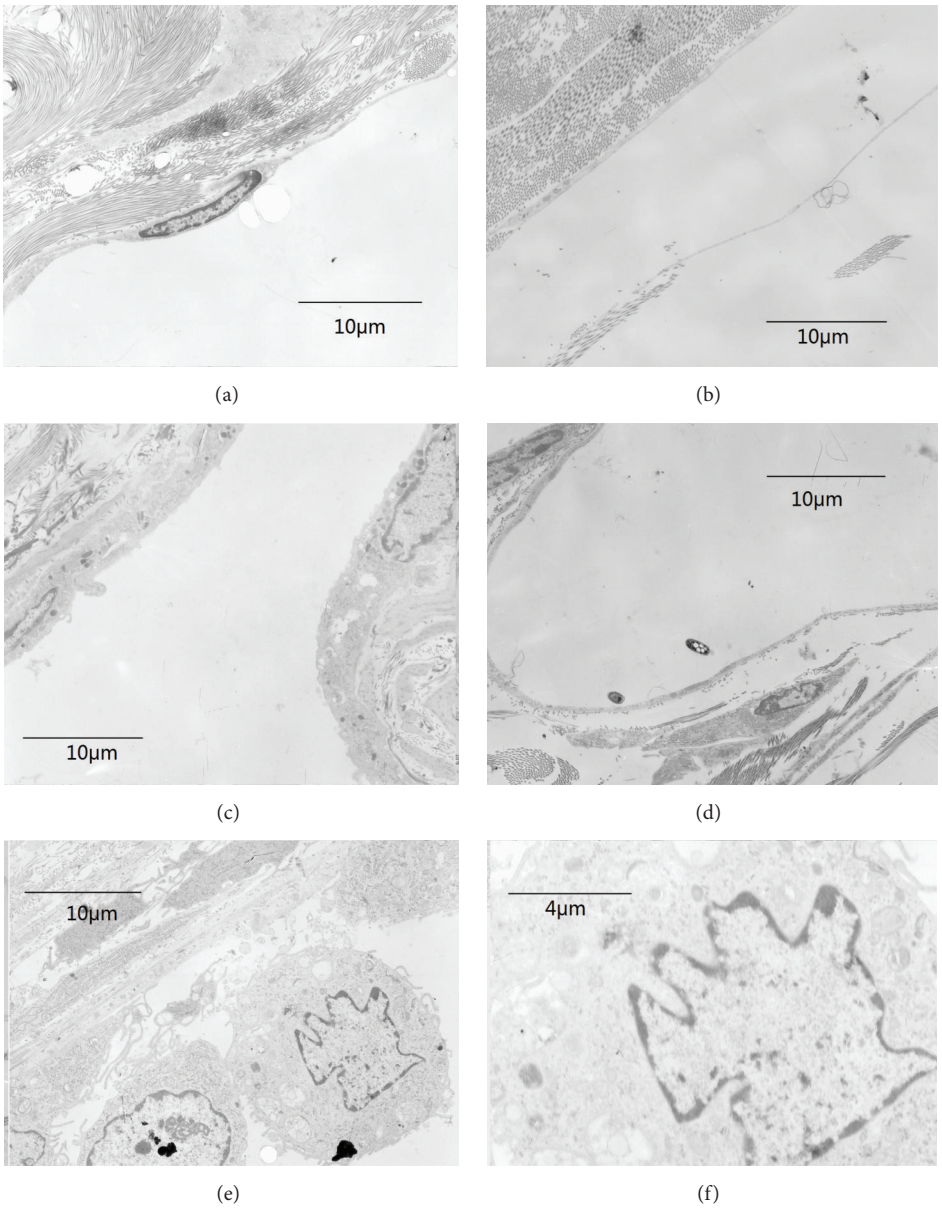

Figure 9: Transmission electron microscope. A weak fibrous capsule formation marked by arrows was observed around all of the 4 biomaterials: (a) control group, ×2500; (b) group 1, ×2500; (c) group 2, ×2500; (d) group 3, ×2500. And small amounts of macrophages marked by arrows had been observed nearby ((e) ×2500, (f) ×5000).

all the agents, consequently it has been considered as the most promising adjuvant in trabeculectomy.

Our study had several limitations. Our sample size was relatively small, and the study reported short-term outcomes.

5. Conclusions

In conclusion, OCT and UBM were useful tools to measure filtering blebs. Subconjunctival implants made from PTLGA may present a safe and effective additional surgical tool for the maintenance of filtering blebs in antiglaucoma surgery. Fewer complications were observed in the group with P2 implants. Longer-term observations of bigger sample size studies are needed to fully evaluate this new PTLGA terpolymer.

Conflict of Interests

The authors have no proprietary or commercial interest in any materials discussed in this paper.

References

[1] J. E. Cairns, "Trabeculectomy. Preliminary report of a new method," *American Journal of Ophthalmology*, vol. 66, no. 4, pp. 673–679, 1968.

[2] G. L. Skuta and R. K. Parrish II, "Wound healing in glaucoma filtering surgery," *Survey of Ophthalmology*, vol. 32, no. 3, pp. 149–170, 1987.

[3] J. Matlach, E. Panidou, F. Grehn, and T. Klink, "Large-area versus small-area application of mitomycin C during trabeculectomy," *European Journal of Ophthalmology*, vol. 23, no. 5, pp. 670–677, 2013.

[4] L. M. Meyer, N. E. Graf, S. Philipp et al., "Two-year outcome of repeat trabeculectomy with mitomycin C in primary open-angle and PEX glaucoma," *European Journal of Ophthalmology*, vol. 25, no. 3, pp. 185–191, 2015.

[5] S. Suominen, M. Harju, L. Kurvinen, and E. Vesti, "Deep sclerectomy in normal-tension glaucoma with and without mitomycin-c," *Acta Ophthalmologica*, vol. 92, no. 7, pp. 701–706, 2014.

[6] D. Z. Chen, V. Koh, C. Sng, M. C. Aquino, P. Chew, and S. Bhattacharya, "Complications and outcomes of primary phacotrabeculectomy with mitomycin C in a multi-ethnic asian population," *PLoS ONE*, vol. 10, no. 3, Article ID e0118852, 2015.

[7] N. Anand, S. Arora, and M. Clowes, "Mitomycin C augmented glaucoma surgery: evolution of filtering bleb avascularity, transconjunctival oozing, and leaks," *British Journal of Ophthalmology*, vol. 90, no. 2, pp. 175–180, 2006.

[8] A. Rosentreter, A. M. Schild, J. F. Jordan, G. K. Krieglstein, and T. S. Dietlein, "A prospective randomised trial of trabeculectomy using mitomycin C vs an ologen implant in open angle glaucoma," *Eye*, vol. 24, no. 9, pp. 1449–1457, 2010.

[9] D. Tanuj, S. Amit, M. Saptorshi, and G. Meenakshi, "Combined subconjunctival and subscleral ologen implant insertion in trabeculectomy," *Eye*, vol. 27, no. 7, p. 889, 2013.

[10] H. S.-L. Chen, R. Ritch, T. Krupin, and W.-C. Hsu, "Control of filtering bleb structure through tissue bioengineering: an animal model," *Investigative Ophthalmology and Visual Science*, vol. 47, no. 12, pp. 5310–5314, 2006.

[11] W.-C. Hsu, R. Ritch, T. Krupin, and H. S.-L. Chen, "Tissue bioengineering for surgical bleb defects: an animal study," *Graefe's Archive for Clinical and Experimental Ophthalmology*, vol. 246, no. 5, pp. 709–717, 2008.

[12] X. Shen, F. Su, J. Dong, Z. Fan, Y. Duan, and S. Li, "*In vitro* biocompatibility evaluation of bioresorbable copolymers prepared from L-lactide, 1, 3-trimethylene carbonate, and glycolide for cardiovascular applications," *Journal of Biomaterials Science, Polymer Edition*, vol. 26, no. 8, pp. 497–514, 2015.

[13] Y. Yuan, X. Jin, Z. Fan, S. Li, and Z. Lu, "In vivo degradation of copolymers prepared from l-lactide, 1,3-trimethylene carbonate and glycolide as coronary stent materials," *Journal of Materials Science: Materials in Medicine*, vol. 26, no. 3, p. 139, 2015.

[14] M. S. Johnson and S. R. Sarkisian Jr., "Using a collagen matrix implant (Ologen) versus mitomycin-C as a wound healing modulator in trabeculectomy with the Ex-PRESS mini glaucoma device: a 12-month retrospective review," *Journal of Glaucoma*, vol. 23, no. 9, pp. 649–652, 2014.

[15] T. Dada, R. Kusumesh, S. J. Bali et al., "Trabeculectomy with combined use of subconjunctival collagen implant and low-dose mitomycin C," *Journal of Glaucoma*, vol. 22, no. 8, pp. 659–662, 2013.

[16] F. Yuan, L. Li, X. Chen, X. Yan, and L. Wang, "Biodegradable 3D-porous collagen matrix (ologen) compared with mitomycin c for treatment of primary open-angle glaucoma: results at 5 years," *Journal of Ophthalmology*, vol. 2015, Article ID 637537, 7 pages, 2015.

[17] R. Fernández-Buenaga, G. Rebolleda, P. Casas-Llera, F. J. Muñoz-Negrete, and M. Pérez-López, "A comparison of intrascleral bleb height by anterior segment OCT using three different implants in deep sclerectomy," *Eye*, vol. 26, no. 4, pp. 552–556, 2012.

[18] D. Kazakova, S. Roters, C. C. Schnyder et al., "Ultrasound biomicroscopy images: long-term results after deep sclerectomy with collagen implant," *Graefe's Archive for Clinical and Experimental Ophthalmology*, vol. 240, no. 11, pp. 918–923, 2002.

[19] A. Labbé, P. Hamard, V. Iordanidou, S. Dupont-Monod, and C. Baudouin, "Utility of the Visante OCT in the follow-up of glaucoma surgery," *Journal Francais d'Ophtalmologie*, vol. 30, no. 3, pp. 225–231, 2007.

[20] G. Savini, M. Zanini, and P. Barboni, "Filtering blebs imaging by optical coherence tomography," *Clinical and Experimental Ophthalmology*, vol. 33, no. 5, pp. 483–489, 2005.

[21] M. Singh, T. Aung, D. S. Friedman et al., "Anterior segment optical coherence tomography imaging of trabeculectomy blebs before and after laser suture lysis," *American Journal of Ophthalmology*, vol. 143, no. 5, pp. 873–875, 2007.

[22] F. Aptel, S. Dumas, and P. Denis, "Ultrasound biomicroscopy and optical coherence tomography imaging of filtering blebs after deep sclerectomy with new collagen implant," *European Journal of Ophthalmology*, vol. 19, no. 2, pp. 223–230, 2009.