Hindawi Publishing Corporation
Stroke Research and Treatment
Volume 2012, Article ID 716919, 6 pages
doi:10.1155/2012/716919

Clinical Study

Altered Hemodynamics Associated with Pathogenesis of the Vertebral Artery Dissecting Aneurysms

Akira Kurata,[1] Sachio Suzuki,[1] Kazuhisa Iwamoto,[1] Kuniaki Nakahara,[1] Katsutoshi Abe,[1] Madoka Inukai,[1] June Niki,[1] Makoto Sasaki,[1] Kiyotaka Fujii,[1] Shingo Konno,[2] Shinichi Kan,[3] and Kazuaki Fukasaku[4]

[1] *Department of Neurosurgery, Kitasato University School of Medicine, Kanagawa 228-8555, Japan*
[2] *Department of Critical Care Medicine, Kitasato University School of Medicine, Japan*
[3] *Department of Radiology, Kitasato University School of Medicine, Japan*
[4] *Bio-Research Infrastructure Construction Team, RIKEN, Saitama, Japan*

Correspondence should be addressed to Akira Kurata, akirak@med.kitasato-u.ac.jp

Received 29 December 2011; Accepted 16 January 2012

Academic Editor: Stefan Schwab

The etiology of the vertebral dissecting aneurysms is largely unknown, and they frequently occurs in relatively healthy young men. *Objectives and Methods*. A series of 57 consecutive cases defined by angiography were evaluated with regard to deviation in the course of the affected and contralateral vertebral arteries. Division was into 3 types: Type I without any deviation, Type II with mild-to-moderate deviation but not over the midline; and Type III with marked deviation over to the contralateral side beyond the midline. *Results*. The most frequent type of VA running was Type III for the affected and Type I nonaffected side, with this being found in all 17 patients except one. All of the Type III dissections occurred just proximal to a tortuous portion, while in cases with Type-I- and Type-II-affected sides, the majority (33 of 39) occurred near the union of the vertebral artery. In 10 of 57, a non-dominant side was affected, all except one being of Type I or II. With 12 recent patients assessed angiographically in detail for hemodynamics, eleven patients showed contrast material retrograde inflowing into the pseudolumen from the distal portion of the dissection site. Turbulent blood flow was recognized in all of these patients with retrograde inflow. *Conclusions*. Turbulent blood flow is one etiology of vertebral artery dissection aneurysms, with the sites in the majority of the cases being just proximal to a tortuous portion or union of vessels. In cases with dissection proximal to the tortuous course of the vertebral artery, retrograde inflow will occur more frequently than antegrade, which should be taken into account in designing therapeutic strategies.

1. Introduction

The etiology of the spontaneous vertebral artery dissection is to a large extent unknown because it frequently occurs in relatively young men [1–3] without atherosclerotic factors [1]. Therefore, the pathogenesis of the dissection remains obscure [4]. In the present study, we investigated the course of vertebral arteries by angiography to cast light on the role of hemodynamics in etiology.

2. Materials and Methods

Since 1986, a total of 75 patients of vertebral artery dissecting aneurysms were experienced in our institute, all defined by angiography. The recent fifty-seven were evaluated in detail with reference to angiographic findings, focusing on the morphology of both affected and contralateral sides of the vertebral artery. The midline was defined as a line from the septum pellucidum to the anterior median fissure as assessed by basiparallel anatomic scanning (BPAS) MR imaging. No deviation was defined as a sharp angle configuration of the VA (Figure 1(a)). Mild-to-moderate deviation was defined as an obtuse angle configuration of the VA (Figure 1(b)). Severe deviation was defined as marked deviation to the contralateral side over the midline. First, the course of each vertebral artery was divided into 3 types: Type I showing no deviation (Figure 1(a)), Type II with mild-to-moderate deviation but not over the midline

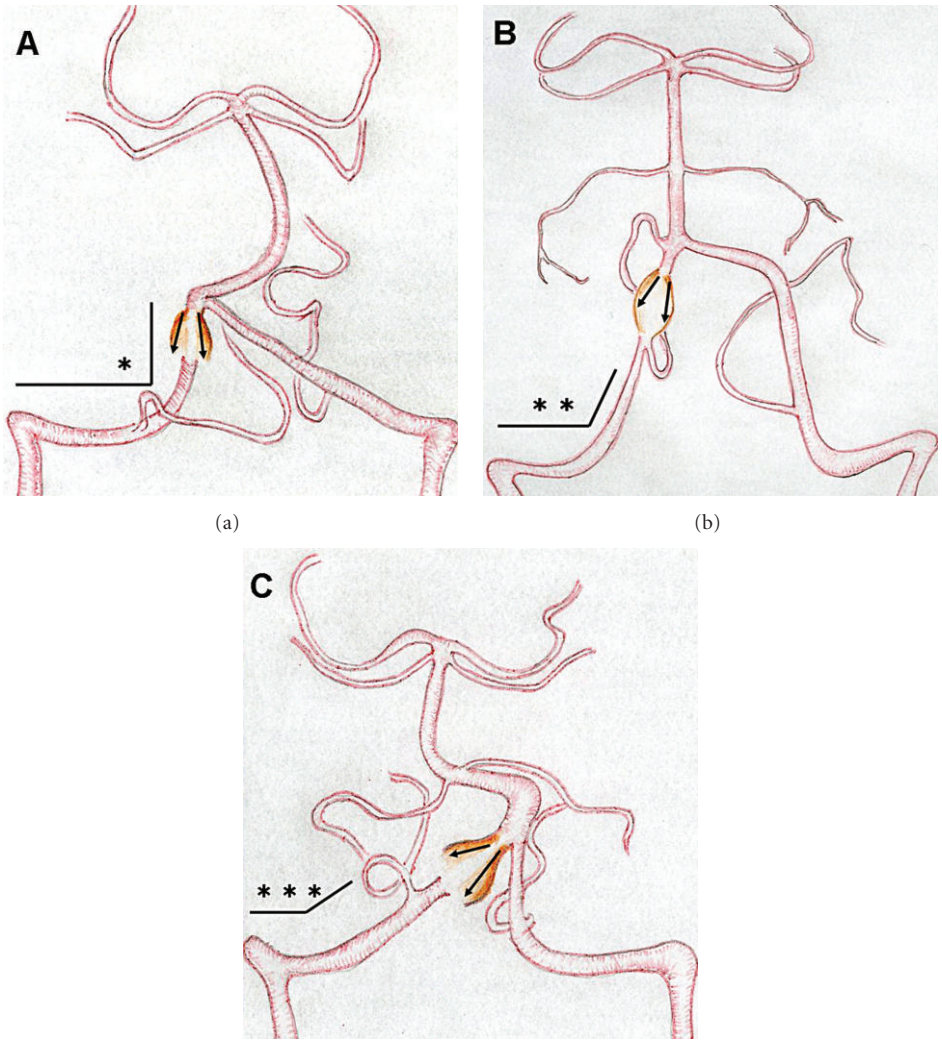

(a) (b) (c)

Figure 1: (a) Schematic drawing of a Type I vertebral artery showed no deviation of the running. *: the configuration of the right vertebral artery was a sharp angle less than 90 defined as no deviation. Arrows show retrograde inflow into the pseudolumen from the distal entry of the dissection site. (b) Schematic drawing of a Type II vertebral artery showing mild-to-moderate deviation but not over the midline. **: the configuration of the vertebral artery was an obtuse angle defined as mild-to-moderate deviation. The midline was defined as the line from the septum pellucidum to the anterior median fissure as assessed by basiparallel anatomic scanning (BPAS)—MR imaging. Arrows show retrograde inflow into the pseudolumen. from the distal entry of the dissection. (c): schematic drawing of a Type III vertebral artery deviating remarkably to the contralateral side over the midline. Arrows show retrograde inflow into the pseudolumen. from the distal entry of the dissection.

(Figure 1(b)), and Type III featuring marked deviation to the contralateral side over the midline (Figure 1(c)). Next, the location of the dissection with reference to tortuous portions and the distance from the union of the vertebral artery were evaluated, with a distance less than 1 cm counted as near. Thirdly, whether involvement was of dominant or nondominant side of the vertebral artery was assessed. Eleven most recent patients (10 without subarachnoid hemorrhage and the other 2 with subarachnoid hemorrhage) were evaluated angiographically in detail (6 flames/second) for hemodynamics.

3. Results

The most frequent type of VA on the affected side was Type III, all of the dissections in this group occurring just proximal to a tortuous portion. The 17 patients except one with lack of contralateral VA showed Type I VA course in contralateral side (Table 1). In Type I and Type II VA running on the affected side, the majority of the dissections occurred near the union of the VA (33/39) (Table 2), sometimes just proximal to a tortuous portion (12/39) (Table 1). In 10 of 57, non-dominant side of the VA was affected, all except

Table 1: The three types of vertebral artery with comparison of affected and nonaffected sides.

		Affected side		
		Type I	Type II	Type III
Non-affected side	Type I	11 (4)	7 (0)	17 (17)
	Type II	6 (3)	1 (1)	0 (0)
	Type III	11 (4)	2 (0)	0 (0)
	None	1 (0)	0 (0)	1 (1)
	Total	29 (11)	10 (1)	18 (18)

The location of the dissection with reference to tortuous portions.
( ): just proximal to the tortuous portion.

Table 2: The three types of VA with comparison of affected and nonaffected sides.

		Affected side		
		Type I	Type II	Type III
Non-affected side	Type I	11 (9)	7 (7)	17 (5)
	Type II	6 (4)	1 (1)	0 (0)
	Type III	11 (10)	2 (2)	0 (0)
	None	1 (0)	0 (0)	1 (1)
	Total	29 (23)	10 (10)	18 (6)

The location of the dissection with reference to the distance from the union of the vertebral artery was evaluated, with a distance less than 1 cm counted as near.
( ): near the union.

Table 3: Data for dominant sides in the three types of the vertebral artery with comparison of affected and nonaffected sides.

		Affected side		
		Type I	Type II	Type III
Non-affected side	Type I	11 (2)	7 (3)	17 (1)
	Type II	6 (0)	1 (0)	0 (0)
	Type III	11 (3)	2 (1)	0 (0)
	None	1 (0)	0 (0)	1 (0)
	Total	29 (5)	10 (4)	18 (1)

( ): affected side is nondominant.

one dissection being Type I and II (Table 3). In 12 most recent patients without subarachnoid hemorrhage, hemodynamics were evaluated in detail by angiography. Eleven patients showed contrast material retrograde inflow into the pseudolumen from the distal portion of the dissection. Only one patient showed antegrade inflow into the pseudo-lumen from the proximal vertebral artery. Turbulent blood flow was recognized in all of the patients with retrograde inflow.

3.1. Representative Cases

3.1.1. Case 1. A 46-year-old man suffered from sudden onset of headache, which persisted for three weeks, resulting in referral to our institute. MRI showed no abnormal findings, but right vertebral angiography revealed a dissecting aneurysm just distal to the PICA. Affected right vertebral artery was dominant and Type III featuring marked deviation to the contralateral side over the midline. The location of the dissection was just proximal to the tortuous portion. Contralateral left vertebral artery was Type I showing no deviation. Contrast medium retrograde inflow into the pseudolumen was evident (Figures 2(a), 2(b), 2(c)). Following successful performance of endovascular coil embolization at the dissection site (Figure 2(d)), the clinical course was uneventful.

3.1.2. Case 2. A 58-year-old woman developed dysarthria and gait disturbance deviating to the left.

MRA showed a left vertebral artery dissecting aneurysm just proximal to the PICA. Affected left vertebral artery was dominant and Type I showing no deviation. The location of the dissection was just proximal to the tortuous portion. Contralateral right vertebral artery was Type II with mild-to-moderate deviation but not over the midline. Retrograde inflow into the pseudolumen from the distal portion of the aneurysm was evident (Figure 3). Both of the symptoms with dysarthria and gait disturbance were rapidly improved and disappeared after 3 months with conservative followup. The clinical course was uneventful.

3.1.3. Case 3. A 64-year-old man presented with sudden onset of dysarthria and gait disturbance deviating to the right at the hospital. MRA showed a right vertebral artery dissecting aneurysm just distal to the PICA. Affected right vertebral artery was marked dominant and Type III featuring marked deviation to the contralateral side over the midline. The location of the dissection was just proximal to the tortuous portion and near the union. Contralateral left vertebral artery was hypoplastic and Type I showing no deviation. Right vertebral artery showed retrograde inflow into the pseudo-lumen from the distal portion of the aneurysm was evident (Figure 4). Both of the symptoms with dysarthria and gait disturbance were rapidly improved and disappeared after 1 month with conservative followup. The clinical course was uneventful.

4. Discussion

Relatively young men [1–3] who lack atherosclerotic factors [1] frequently suffer vertebral artery dissection, and therefore, the pathogenesis appears obscure [4]. The mean age of occurrence was reported ranging from 35 [1] to 53 years [5]. Male predominance of 60% [2] to 67% [3] have been documented. Results for hypertension are inconsistent, ranging from rare (19%) [1] or not usual present (29%) [3] to frequent (48%) [6]. Vertebral artery sites distal to the PICA origin are commonly affected (post PICA type) (61 [4] to 78% [5]), including the involving type (84% [5] to 86% [6]). Proximal types are reported to be a few (14% [6] to 16% [5]). As to size dominance of the affected vertebral artery, the few reports in the literature described the dominant vertebral artery to be usual, non-dominant arteries only account for 16% in one series [5], so that it is very important to verify the mechanism of the dissection considering hemodynamic stress. In the present series, the running course of the

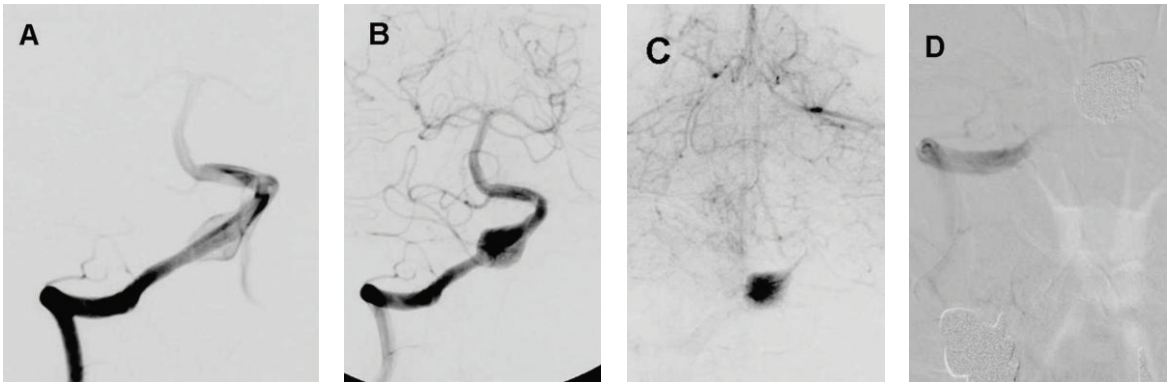

(a) (b) (c) (d)

Figure 2: Right vertebral angiogram ((a): early arterial phase, (b): slightly late arterial phase, (c): late arterial phase) showing retrograde inflow into the pseudolumen. Right vertebral angiogram (d) after coil embolization at the dissection site showing complete occlusion of the aneurysm.

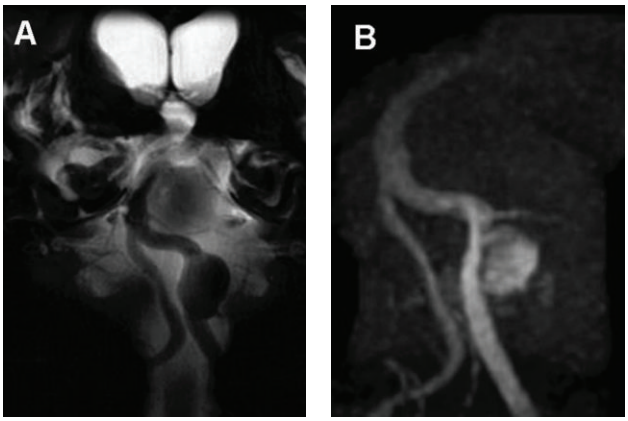

(a) (b)

Figure 3: Magnetic resonance angiography ((a): BPAS image, (b): Conventional image) showing retrograde inflow into the pseudolumen.

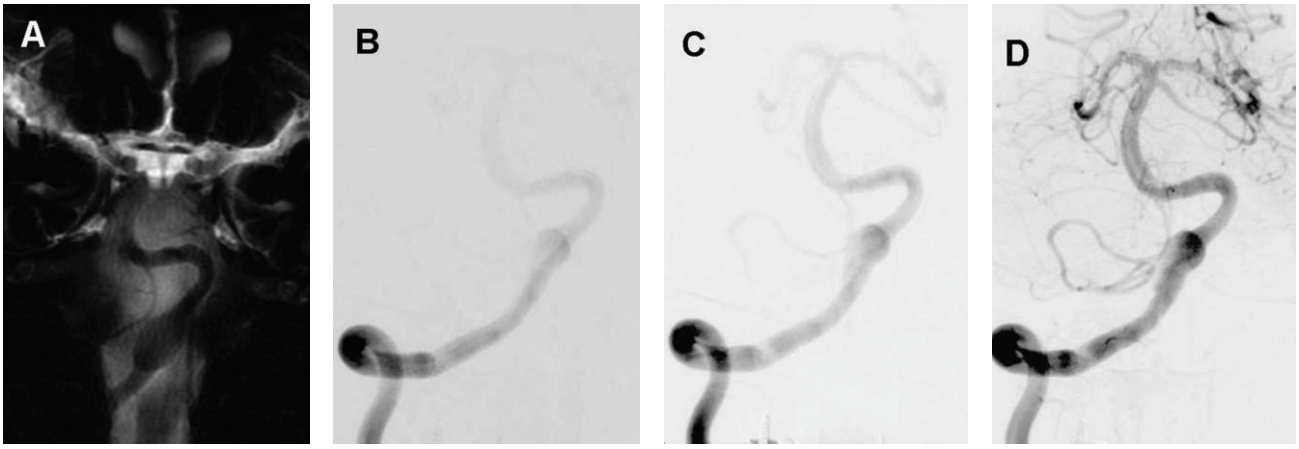

(a) (b) (c) (d)

Figure 4: Magnetic resonance angiography ((a): BPAS image) and right vertebral angiogram ((b): ultra-early arterial phase, (c): early arterial phase, (d): slightly late arterial phase) showing retrograde inflow into the pseudolumen.

affected and nonaffected vertebral arteries was evaluated in detail. In the cases involving dominant or same size of the vertebral arteries, Type III VAs deviating remarkably to the contralateral side over the midline were most frequent, with all dissections occurring just proximal to a tortuous portion indicating retrograde hemodynamic stress as turbulent flow to play an etiological role. In addition, 10 (18%) of 57 affected the non-dominant side, all except one being Type I and II and the dissections occurred near the union of the vertebral artery. Such results suggest that retrograde inflow from the dominant contralateral VA may have influenced development of dissection on the non-dominant side.

Proximal occlusion of the parent vertebral artery by endovascular techniques or clipping may be useful for the treatment of dissecting aneurysms [4, 7–10]. However, such treatment does not always completely prevent rerupture, because blood flow may persist from the contralateral vertebral artery [11]. Some instances of growth [10] or rebleeding [4, 12–15] after proximal occlusion of the parent artery have been reported. When the dissection site is located in the vertebral artery proximal to the PICA division, proximal occlusion may be effective [16], since retrograde blood flow from the contralateral vertebral artery will supply the PICA beyond this site. This is important, since the majority of vertebral artery dissections are of the post-PICA or PICA involving type. Trapping surgery may be more reliable to avoid rerupture; however, this is invasive and may precipitate the Wallenberg syndrome [14] or catastrophic events [5]. For the Type III VA with marked deviation to the contralateral side over the midline, which was the most frequent type of the affected VA in this series, trapping surgery should be avoided. Endovascular coil embolization at the dissection site has been reported [6, 17, 18], and this may be more effective than proximal occlusion because of immediate cessation of the blood flow to the affected site. Coil embolization is a less invasive technique as compared with trapping surgery. Efficacy of embolization from the proximal part of the dissection via the contralateral vertebral artery has been proposed because the dissection may be suspected to start from the proximal part caused by antegrade inflow [19]. Mizutani et al. [20] focused on pathological mechanisms and assessed three-dimensional structures of cerebral dissections. They concluded that sudden destruction of the internal elastic lamina is important, and the majority of aneurysms have only one entrance into the pseudolumen (entry only type). However, the site of the initial dissection caused by disruption of the internal elastic lamina cannot generally be determined because all of the VA dissections are hemorrhagic cases with massive destruction of the internal elastic lamina. In our series, angiography in all but one of 11 recent patients showed entry-only type, which suggested-retrograde dissection occurs frequently more frequently than ante-grade dissection.

5. Conclusion

In the majority of cases with VA dissection, the entry to the pseudolumen may often occurs at a distal part to the dissection caused by retrograde inflow just proximal to a tortuous portion or the union of the vertebral arteries, which should be taken into account in considering therapeutic strategy.

Acknowledgment

The authors thank Malcolm Moore for English editing the paper.

References

[1] M. S. Berger and C. B. Wilson, "Intracranial dissecting aneurysms of the posterior circulation. Report of six cases and review of the literature," *Journal of Neurosurgery*, vol. 61, no. 5, pp. 882–894, 1984.

[2] H. J. Manz and A. J. Luessenhop, "Dissecting aneurysm of intracranial vertebral artery: case report and review of literature," *Journal of Neurology*, vol. 230, no. 1, pp. 25–35, 1983.

[3] A. Yamaura, Y. Watanabe, and N. Saeki, "Dissecting aneurysms of the intracranial vertebral artery," *Journal of Neurosurgery*, vol. 72, no. 2, pp. 183–188, 1990.

[4] A. H. Friedman and C. G. Drake, "Subarachnoid hemorrhage from intracranial dissecting aneurysm," *Journal of Neurosurgery*, vol. 60, no. 2, pp. 325–334, 1984.

[5] T. Mizutani, T. Aruga, T. Kirino et al., "Recurrent subarachnoid hemorrhage from untreated ruptured vertebrobasilar dissecting aneurysms," *Neurosurgery*, vol. 36, no. 5, pp. 905–913, 1995.

[6] A. Kurata, T. Ohmomo, Y. Miyasaka, K. Fujii, S. Kan, and T. Kitahara, "Coil embolization for the treatment of ruptured dissecting vertebral aneurysms," *American Journal of Neuroradiology*, vol. 22, no. 1, pp. 11–18, 2001.

[7] K. Tanaka, S. Waga, T. Kojima, Y. Kubo, T. Shimizu, and S. Niwa, "Non-traumatic dissecting aneurysms of the intracranial vertebral artery. Report of six cases," *Acta Neurochirurgica*, vol. 100, no. 1-2, pp. 62–66, 1989.

[8] V. B. Graves, J. Perl, C. M. Strother, R. C. Wallace, P. P. Kesava, and T. J. Masaryk, "Endovascular occlusion of the carotid or vertebral artery with temporary proximal flow arrest and microcoils: clinical results," *American Journal of Neuroradiology*, vol. 18, no. 7, pp. 1201–1206, 1997.

[9] J. D. Barr and T. J. Lemley, "Endovascular arterial occlusion accomplished using microcoils deployed with and without proximal flow arrest: results in 19 patients," *American Journal of Neuroradiology*, vol. 20, no. 8, pp. 1452–1456, 1999.

[10] T. Tsukahara, H. Wada, K. Satake et al., "Proximal balloon occlusion for dissecting vertebral aneurysms accompanied by subarachnoid hemorrhage," *Neurosurgery*, vol. 36, no. 5, pp. 914–920, 1995.

[11] K. Irikura, Y. Miyasaka, H. Ohtaka, K. Yada, and K. Hirose, "Dissecting aneurysm of the vertebral artery with lateral medullary syndrome: a case report, with special reference to surgical treatment," *Japanese Journal of Stroke*, vol. 11, pp. 133–139, 1989.

[12] N. Aoki and T. Sakai, "Rebleeding from intracranial dissecting aneurysm in the vertebral artery," *Stroke*, vol. 21, no. 11, pp. 1628–1631, 1990.

[13] Y. Nakai, K. Yanaka, K. Meguro et al., "Rebleeding from dissecting vertebral aneurysm after endovascular proximal occlusion: case report," *Neurosurgery letters*, vol. 9, pp. 21–24, 1999.

[14] N. Takai, I. Ezuka, T. Sorimachi, T. Kumagai, and K. Sano, "Vertbral artery dissecting aneurysm rebleeding after proximal occlusion: case report," *Neurologia MedicoChirurgica*, vol. 33, no. 11, pp. 765–768, 1993.

[15] T. Yasui, H. Yagura, M. Komiyama, Y. Fu, Y. Nagata, and K. Tamura, "Surgical treatment for ruptured dissecting aneurysms: proximal clipping vs trapping," *Neurological Surgery*, vol. 21, no. 5, pp. 395–401, 1993.

[16] T. Yasui, H. Yagura, M. Komiyama et al., "Therapeutic occlusion of unilateral vertebral artery for unclippable aneurysms; special reference to postoperative brainstem ischemia," *Neurological Surgery*, vol. 20, no. 4, pp. 325–332, 1992.

[17] V. V. Halbach, R. T. Higashida, C. F. Dowd et al., "Endovascular treatment of vertebral artery dissections and pseudoaneurysms," *Journal of Neurosurgery*, vol. 79, no. 2, pp. 183–191, 1993.

[18] I. Yamaura, E. Tani, M. Yokota et al., "Endovascular treatment of ruptured dissecting aneurysms aimed at occlusion of the dissected site by using Guglielmi detachable coils," *Journal of Neurosurgery*, vol. 90, no. 5, pp. 853–856, 1999.

[19] R. A. Willinsky, "Vessel artery dissection and pseudoaneurysms: endovascular approaches," *Seminars in Neurosurgery*, vol. 11, no. 1, pp. 59–70, 2000.

[20] T. Mizutani, H. Kojima, S. Asamoto, and Y. Miki, "Pathological mechanism and three-dimensional structure of cerebral dissecting aneurysms," *Journal of Neurosurgery*, vol. 94, no. 5, pp. 712–717, 2001.