

# Prenatal Calcification of the Inferior Vena Cava and Renal Veins in a Normal Neonate

Daniel Ranch<sup>1</sup>, Michael O. Aigbe<sup>1,2</sup>, and Emmanuel C. Gorospe<sup>2,\*</sup>

<sup>1</sup>Department of Pediatrics, University of Nevada School of Medicine, Las Vegas;

<sup>2</sup>The Children's Nephrology Clinic, Las Vegas, Nevada

E-mail: [dranch999@yahoo.com](mailto:dranch999@yahoo.com); [AigbeM@unlv.nevada.edu](mailto:AigbeM@unlv.nevada.edu); [GorospeE@unlv.nevada.edu](mailto:GorospeE@unlv.nevada.edu)

Received April 19, 2006; Revised June 19, 2006; Accepted June 27, 2006; Published June 30, 2006

---

**Prenatal calcification of the inferior vena cava (IVC) and renal veins is a rare condition with unclear etiology and prognosis. It occurs with renal vein thrombosis *in utero* and is associated with congenital anomalies and abnormal prenatal hemodynamic status. We report a rare case of prenatal IVC and renal vein calcification in a normal neonate without any history of compromised prenatal or perinatal condition, or significant deterioration of kidney function.**

**KEYWORDS:** calcification, inferior vena cava, renal veins

---

## CASE REPORT

A 1-week old male neonate was referred for evaluation of possible nephrolithiasis based on prenatal ultrasound at 28 weeks of gestation, which suggested calcifications in the left kidney. At birth, an abdominal ultrasound confirmed vascular-like calcifications in the left kidney. On review of the medical history, the patient was born full term. There was no history of maternal illness, trauma during pregnancy, or complication at birth.

We requested an abdominal CT scan without contrast, which revealed calcifications in the left renal veins extending to the inferior vena cava (IVC) (Fig. 1). Hematologic parameters, serum electrolytes, blood urea nitrogen, and creatinine levels were all within normal range. Screening for possible prothrombotic factors such as lupus anticoagulant and protein C and S levels was not done in the initial consult. Nevertheless, clotting time, thrombin and prothrombin time remained within normal limits even on subsequent follow-up. Lastly, the patient did not have any clinical evidence of venous obstruction or renal dysfunction.

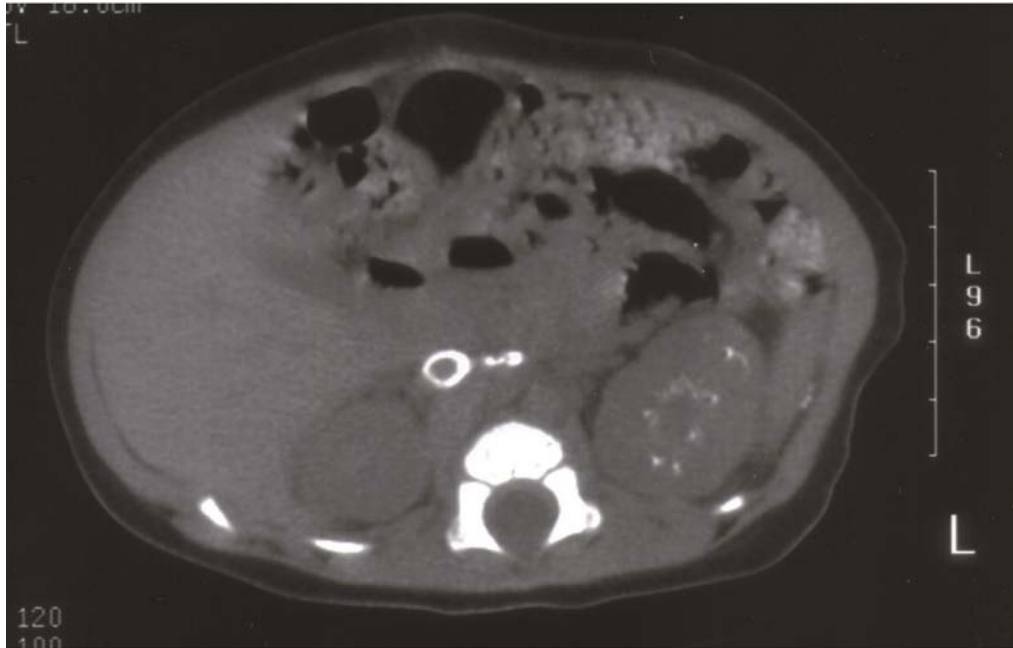
## DISCUSSION

Prenatal calcification of the renal veins and IVC is a rare event. It is attributed to idiopathic thrombus formation[1] from possible hypotension or hypoxia *in utero*[2]. It is associated with congenital anomalies or compromised hemodynamic status.

\*Corresponding author.

©2006 with author.

Published by TheScientificWorld, Ltd.; [www.thescientificworld.com](http://www.thescientificworld.com)



**FIGURE 1.** CT scan of the abdomen presenting ring calcification of the IVC with involvement of the renal veins.

In contrast, postnatal renal venous thrombosis is a common venous thromboembolic event in neonates[3]. It can be the result of postnatal hypercoagulable conditions, sepsis, and iatrogenic causes such as indwelling catheters. The usual calcified IVC thrombus is commonly described as a bullet-shaped radiodensity[4] that differs from the ring-shaped calcification of this case.

There are conflicting reports as to the prognosis of renal venous thrombosis. A series of reports[5,6,7,8] presented decreased renal function and subsequent atrophy of the involved kidney, while others[2,9,10] reported cases with preservation of normal kidney function. The management of renal venous thrombosis is also controversial[2]. Suggestions from experts range from conservative management[11] to invasive thrombectomy and nephrectomy[12].

In this case, continued observation was the treatment of choice as the patient was in good health without any clinical or laboratory manifestations of compromised kidney function. Our experience in this case supports the observation of Wilkinson et al.[2] that suggests that idiopathic prenatal renal venous thrombosis has better prognosis than its postnatal occurrence.

## REFERENCES

1. Sandler, M.A., Beute, G.H., Madrazo, B.L., et al. (1986) Ultrasound case of the day. Inferior vena cava calcification (calcified thrombus). *Radiographics* **6**(3), 512–514.
2. Wilkinson, A.G., Murphy, A.V., and Stewart, G. (2001) Renal venous thrombosis with calcification and preservation of renal function. *Pediatr. Radiol.* **31**(3), 140–143.
3. Marks, S.D., Massicotte, M.P., Steele, B.T., et al. (2005) Neonatal renal venous thrombosis: clinical outcomes and prevalence of prothrombotic disorders. *J. Pediatr.* **146**(6), 811–816.
4. Bloom, D. (2003) Vascular disease of the kidneys. In *Caffey's Pediatric Diagnostic Imaging*. 10th ed. Kuhn, J.P., Slovis, T., and Haller, J., Eds. Mosby, New York. p. 233.
5. Jobin, J., O'Regan, S., Demay, G., et al. (1982) Neonatal renal vein thrombosis - long-term follow-up after conservative management. *Clin. Nephrol.* **17**(1), 36–40.
6. Mocan, H., Beattie, T.J., and Murphy, A.V. (1991) Renal venous thrombosis in infancy: long-term follow-up. *Pediatr. Nephrol.* **5**(1), 45–49.
7. Rasoulpour, M. and McLean, R.H. (1980) Renal venous thrombosis in neonates. Initial and follow-up abnormalities.


- Am. J. Dis. Child.* **134(3)**, 276–279.
8. Sutton, T.J., Leblanc, A., Gauthier, N., et al. (1977) Radiological manifestations of neonatal renal vein thrombosis on follow-up examinations. *Radiology* **122(2)**, 435–438.
  9. Rypens, F., Avni, F., Braude, P., et al. (1993) Calcified inferior vena cava thrombus in a fetus: perinatal imaging. *J. Ultrasound Med.* **12(1)**, 55–58.
  10. Jayogapal, S., Cohen, H.L., Brill, P.W., et al. (1990) Calcified neonatal renal vein thrombosis demonstration by CT and US. *Pediatr. Radiol.* **20(3)**, 160–162.
  11. Ricci, M.A. and Lloyd, D.A. (1990) Renal venous thrombosis in infants and children. *Arch. Surg.* **125(9)**, 1195–1199.
  12. Clark, A.G., Saunders, A., Bewick, M., et al. (1985) Neonatal inferior vena cava and renal venous thrombosis treated by thrombectomy and nephrectomy. *Arch. Dis. Child.* **60(11)**, 1076–1077.

---

**This article should be cited as follows:**

Ranch, D., Aigbe, M.O., and Gorospe, E.C. (2006) Prenatal calcification of the inferior vena cava and renal veins in a normal neonate. *TheScientificWorldJOURNAL* **6**, 734–736. DOI 10.1100/tsw.2006.163.

---



**Hindawi**  
Submit your manuscripts at  
<http://www.hindawi.com>

